

We are IntechOpen, the world's leading publisher of Open Access books Built by scientists, for scientists

6,900

Open access books available

185,000

International authors and editors

200M

Downloads

Our authors are among the

154

Countries delivered to

TOP 1%

most cited scientists

12.2%

Contributors from top 500 universities



WEB OF SCIENCE™

Selection of our books indexed in the Book Citation Index
in Web of Science™ Core Collection (BKCI)

Interested in publishing with us?
Contact book.department@intechopen.com

Numbers displayed above are based on latest data collected.
For more information visit www.intechopen.com



Arthroscopic and Endoscopic Management of the Internal Snapping Hip Syndrome

Adinun Apivatgaroon

Abstract

Internal snapping hip syndrome or coxa saltans interna results from the iliopsoas tendon snapping over the superior pubic ramus, iliopectineal eminence, anterior hip joint, femoral head or the lesser trochanter. This condition occurs in either the native hip or a prosthetic hip joint. Conservative management is the mainstay treatment, but iliopsoas release continues to be the definitive treatment in patients with failed conservative measures. The arthroscopic iliopsoas release from the central or peripheral compartment is useful in the management of internal snapping syndrome and may have less hip flexion strength deficits postoperatively as compared to the releasing from the lesser trochanteric level. Endoscopic iliopsoas release at the lesser trochanter level is the preferred operative treatment option for internal snapping patients who have undergone a total hip replacement.

Keywords: internal snapping hip syndrome, iliopsoas impingement, coxa saltans interna, iliopsoas release

1. Introduction

Snapping hip syndrome or coxa saltans is an abnormal hip condition that includes a painful popping sensation and sound with movement around the hip joint. In the general population, snapping hip can be found in about 5–10% and for most are asymptomatic. Snapping hip syndrome can be divided as intra-articular and extra-articular snapping as seen in **Table 1**.

Internal snapping hip syndrome is snapping hip caused by the iliopsoas tendon migrating over the superior pubic ramus, iliopectineal eminence, anterior hip joint, femoral head or the lesser trochanter. Multiple or bifid iliopsoas tendons can also be found during transcapsular iliopsoas release in about 17.85% of cases [1].

Signs and symptoms include pain or a popping sensation in the area near the anterior groin. The clicking or popping sensation can be reproduced by allowing the patient to perform active hip extension and/or external rotation in a flexion position of the hip (**Figure 1**). Some patients present with a positive C-sign at the painful area. The patients may have focal tenderness over the iliopsoas (anterior groin) and a positive impingement test (Flexion-Adduction-Internal Rotation test, FADIR test) either with or without concomitant femoroacetabular impingement syndrome.

The resisted straight leg raise (RSLR) test is performed by the patient flexing the hip actively at approximately 30° in full knee extension. The examiner places a hand just above the patient's knee to resist hip flexion in that position (**Figure 2**).

Intra-articular snapping	Extra-articular snapping
Soft tissue <ul style="list-style-type: none">• Labral tears• Ligamentum teres rupture, impingement	Anterior or internal <ul style="list-style-type: none">• Iliopsoas snapping (internal snapping hip)
Bone and cartilage <ul style="list-style-type: none">• Chondral damage• Loose bodies• Chondromatosis• Femoroacetabular impingement (FAI)	Lateral or external <ul style="list-style-type: none">• Iliotibial band snapping (external snapping hip)

Table 1.
Approach of the snapping hip syndrome that can be divided as intra-articular and extra-articular causes.

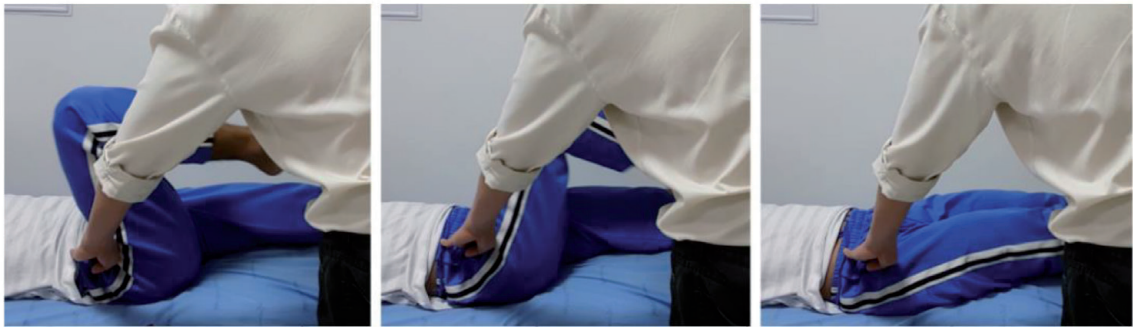

Figure 1.
The internal snapping test is performed by letting the patient performs active hip extension and/or external rotation from the starting flexion position of the examined hip. Positive result when the clicking or popping sensation can be reproduced.

A positive result is when there is pain at the anterior groin or weakness in the hip flexion that represents iliopsoas problems or intra-articular pathologies [2].

The investigations include plain radiographs of the pelvis/hip that might be helpful in ruling out other causes of hip pain or detecting associated pathologies that can affect the hip joint. MRI of the affected hip could aid in ruling out others causes of hip pain or detect associated pathologies, particularly, an anterior labral lesion. Some studies showed the correlation of a 3 O'clock positioned labral tear/ injury with iliopsoas impingement by the friction of the iliopsoas tendon to the predominately, anterior portion of the labrum caused tear [3, 4]. Dynamic ultrasonography is useful to detect snapping of the iliopsoas during actual hip motion and can be conjugate with an ultrasound-guided bursal injection. In iliopsoas impingement, the pain could be improved after an iliopsoas bursal injection rather than an intra-articular injection of anesthetic agents [4].

Nowadays, total hip replacements (THR) are increasing in numbers and indications [5]. An iliopsoas impingement can be a complication of this procedure from impingement of the iliopsoas tendon with the acetabular component [6, 7] (**Figure 3**). This is noticeable in the large size of the acetabular components or in patients with dysplastic morphology of the native hip associated with under coverage of the anterior/superior acetabular rim.

Conservative management of internal snapping hip syndrome includes rest, activity modification, anti-inflammatory medications, injections of a local anesthetic combined with a corticosteroid into the involved bursa or around the tendon sheath and the stretching of the iliopsoas (**Figure 4**).

The surgical treatment consists of iliopsoas release via an open, arthroscopic or endoscopic approach with or without intra-articular procedures. In the total hip

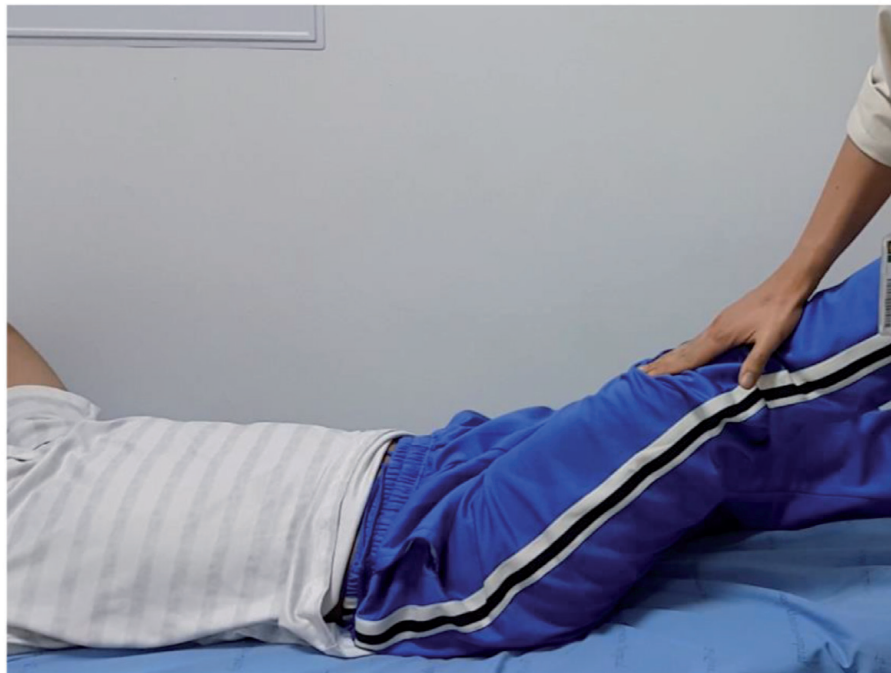

Figure 2.

The resisted straight leg raise (RSLR) test is performed by allowing the patient flex to the hip actively to approximately 30° in a full knee extension, the examiner places a hand just above the patient's knee to resist hip flexion in that position. Positive result when pain or weakness represents iliopsoas pathology or intra-articular causes.

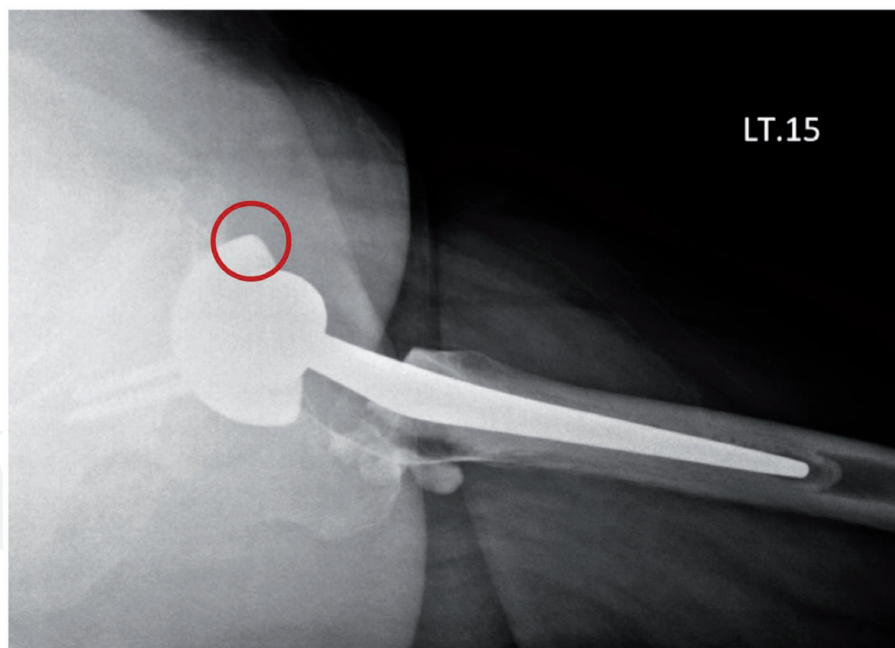


Figure 3.

A lateral cross table radiograph of the left hip following total hip arthroplasty demonstrates the anterior overhang of the acetabular component (red circle) at about 5 mm, leading to iliopsoas impingement.

replacement patient with obvious acetabular component malposition or prominence, acetabular cup revision maybe necessary [6]. For the arthroscopic/endoscopic iliopsoas release techniques, these can be performed using: 1. the transcapsular release (proximal arthroscopic release) via the central or peripheral compartment and 2. releasing at the lesser trochanteric level (distal endoscopic release) (**Figure 5**).

In this chapter, two common iliopsoas release procedures will be presented. The contents of indications, patients positioning, arthroscopic/endoscopic portals and

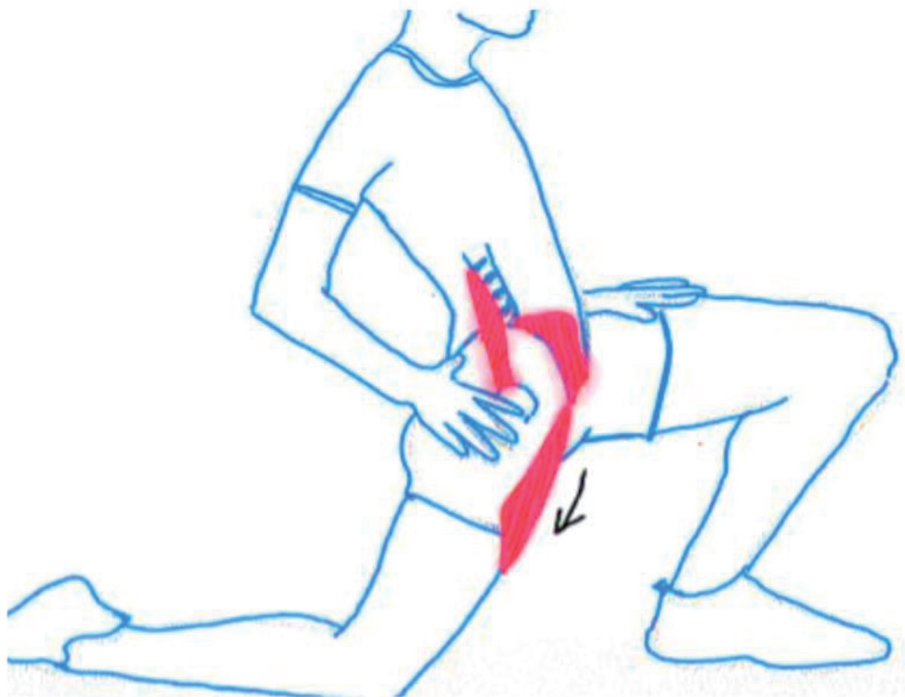

Figure 4.
Demonstrate the stretching method of the right iliopsoas muscle/tendon. The affected hip is extended during controlled trunk balancing.

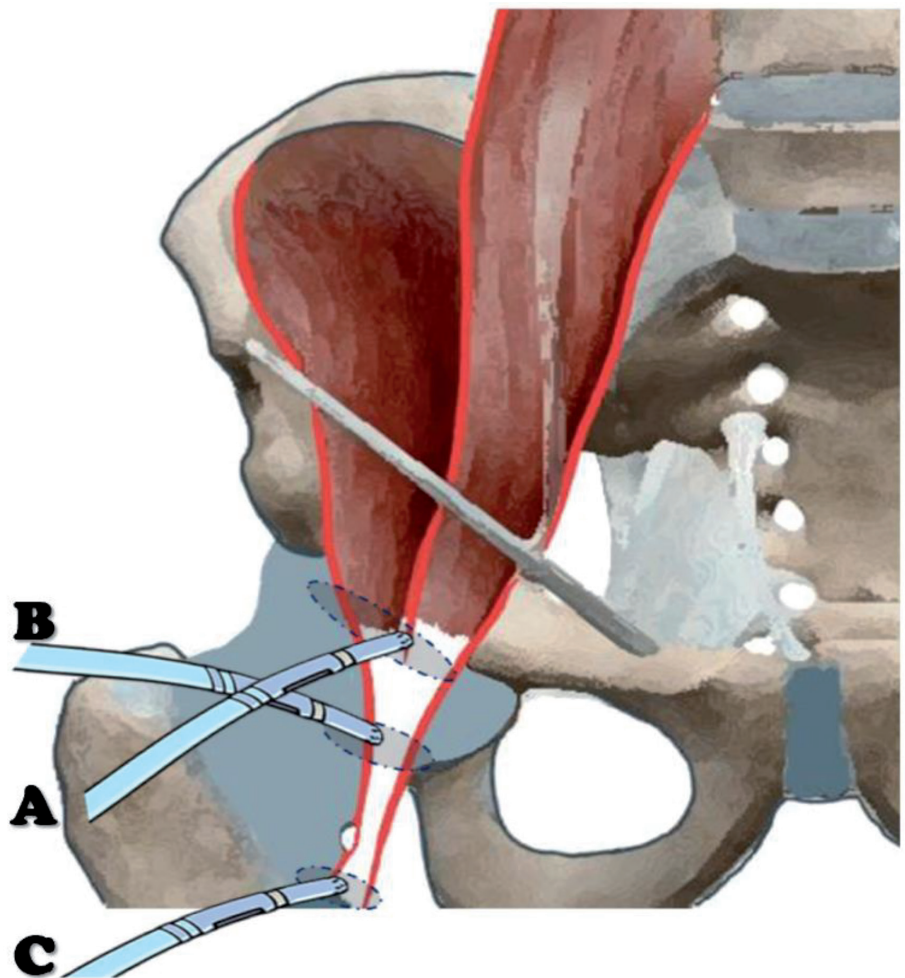


Figure 5.
Demonstration of the iliopsoas release techniques: (A) proximal arthroscopic transcapsular release via a central compartment approach; (B) proximal arthroscopic transcapsular release via a peripheral compartment approach; and (C) distal endoscopic release at the lesser trochanteric level.

the details of procedures are described. The evidence-based reviews of the procedures will also be presented.

2. Arthroscopic transcapsular release (proximal arthroscopic release)

2.1 Indications

- Internal snapping hip syndrome with failed conservative treatments for more than 4–6 months.
- Conjugate with the arthroscopic procedure of the hip (such as anterior labral repair).

2.2 Patient position

The iliopsoas release could be performed using the supine or lateral decubitus position. The author's preferred patient position is supine on a traction radiolucent table (Maquet, Rastatt, Germany). Both legs and feet are well padded and wrapped with soft cotton and hung on the footplate. A large, well-padded perineal post is used to prevent complications from pudendal nerve compression. The C-arm is placed at the non-operative side and positioned horizontally to check the antero-posterior view of the affected hip. Traction is performed to check the possibility of central compartment assess and intra-articular arthroscopic work.

2.3 Surgical technique

The peripheral compartment approach is introduced in hip flexion of 20–30° using a proximal anterolateral portal (PAL). Peripheral compartment examination and synovectomy are performed using an anterior working portal (**Figure 6**). Following the peripheral compartment work that includes synovectomy and cam resection, the central compartment is assessed under traction of the hip in a full extension position. Intra-articular examination and surgical procedures are completely performed. These include; debridement, acetabuloplasty, and labral surgery.

The arthroscopic iliopsoas tenotomy can performed by two methods: (1) central compartment approach under traction and (2) peripheral compartment approach with hip flexion of 20–30°.

In a central compartment approach. After performing the intra-articular procedures, the arthroscope is retracted to the peripheral compartment to assess under traction the anterior hip capsule at approximately the 3 O'clock position of the anterior labrum. This step uses the anterolateral viewing portal and the anterior portal for the procedure. Inflammation of the anterior labrum may represent evidence of iliopsoas impingement. The iliopsoas tendon is located near the anteromedial aspect of the anterior hip capsule. The anterior capsule at this area is thin and some patients have an anterior capsular hole directly connected to the iliopsoas tendon [8]. A capsulotomy of approximately 1–2 cm is performed to the 3 O'clock position of the right hip. After capsulotomy, the synovial tissue around the iliopsoas tendon is identified and resected using an arthroscopic shaver or electrocautery. The iliopsoas tendon is identified and released until the iliacus muscle can be observed beneath the released portion of the tendon. Keeping this portion of the iliacus muscle may decrease of the risk of hip flexion weakness, postoperatively (**Figure 7**).

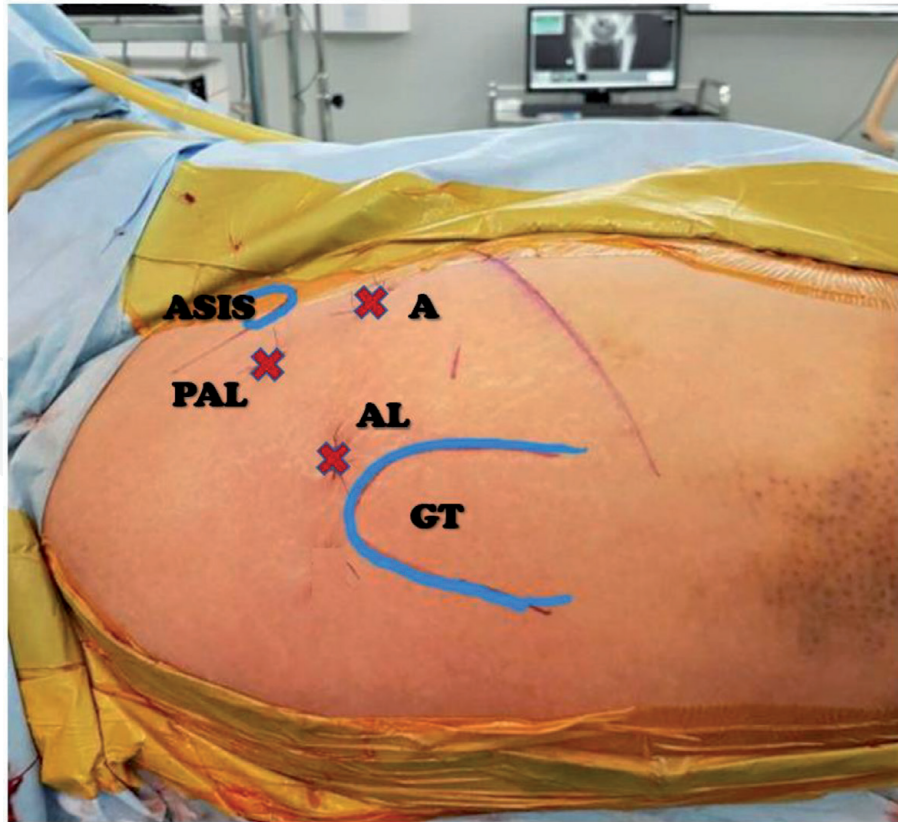


Figure 6.
The portals used in peripheral compartment approach of the right hip. Proximal anterolateral portal (PAL) is the start and viewing portal. Anterior (A) and anterolateral (AL) portals are shown. GT, greater trochanter; ASIS, anterior superior iliac spine.

In the peripheral compartment approach, following the intra-articular work, the traction is released to reduce the hip joint. The arthroscope is inserted via the same AL viewing portal or re-inserted from the PAL portal in the hip at 20–30° in a flexion position. Then, the zona orbicularis, medial synovial fold, and the anterior labrum are identified. The medial synovial fold is the landmark for the most inferomedial head–neck area, also known as, the 6 O’clock position. The 1–2 cm capsulotomy is performed at the capsular space between the anterior labrum and the zona orbicularis close to the proximal attachment of the medial synovial fold. After capsulotomy, the synovial tissue around the iliopsoas tendon is resected as previously described and the iliopsoas tendon is released while preserving the iliacus muscle.

It is not necessary to perform the capsular closure if the capsulotomy is less than 1–2 cm. With complete tenotomy of the iliopsoas, either in the central or peripheral approach, the portals are sutured simple and the wounds are closed in standard fashion.

2.4 Post-operative rehabilitation

Active hip range of motion is allowed immediately post operatively. The hip flexion strength may decrease in the first 6 to 8 weeks and usually restores after 8 weeks. Active hip flexor strengthening exercises are allowed after 6 weeks postoperatively.

Weight bearing is dependent on the intra-articular conditions. The patients apply partial weight bearing for 6 weeks if the cartilage or the labral lesions were repaired/fixated, or if osteochondroplasty of the cam lesion is done. In the isolated iliopsoas release patients, there is no need to protect weight bearing after post operatively. Return to sport activities are allowed after 3 months.

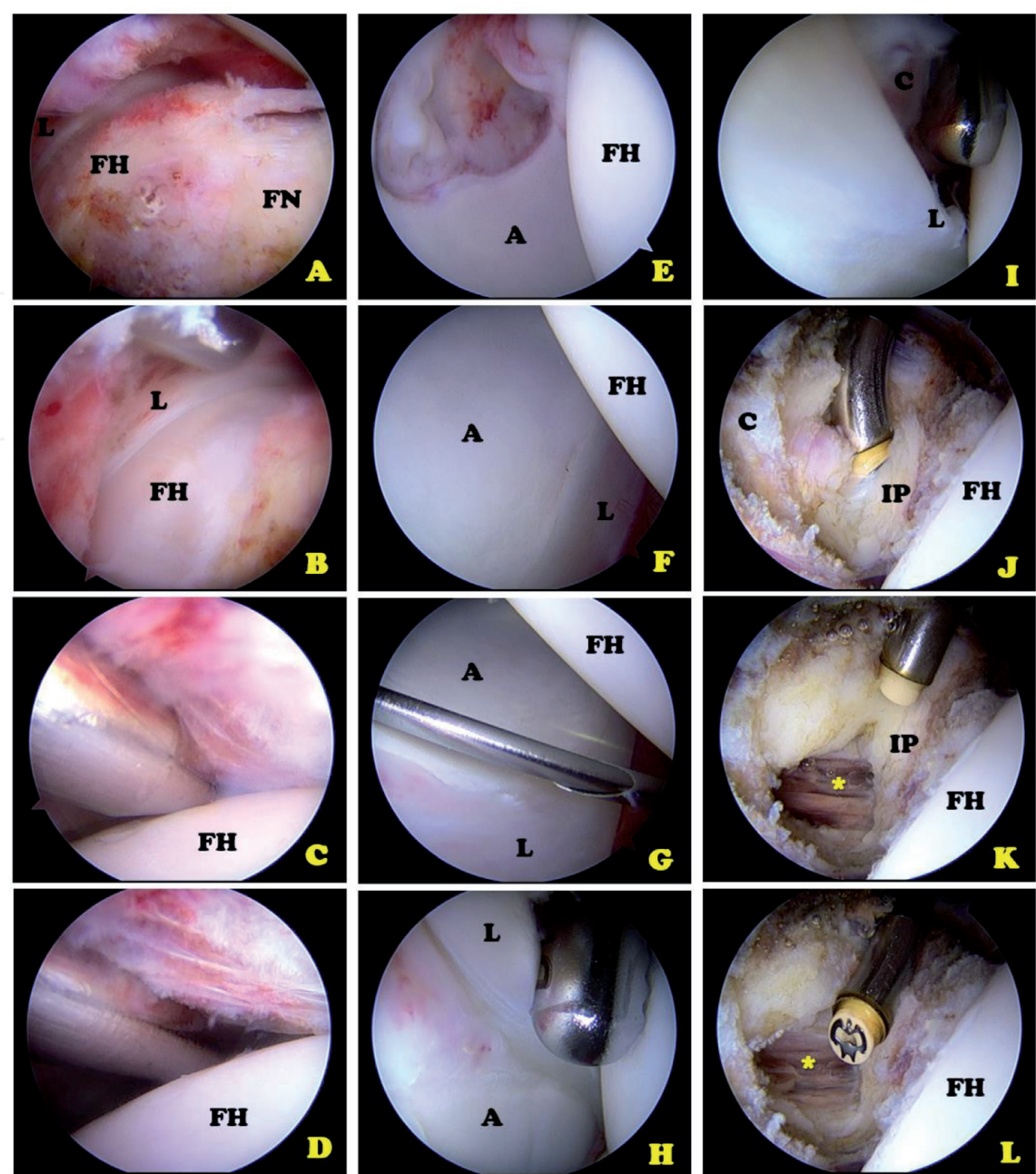


Figure 7.
Arthroscopic view of the central compartment transcapsular iliopsoas tenotomy of the right hip. (A and B) Peripheral compartment first approach using the proximal anterolateral (PAL) viewing portal and anterior working portal. (C and D) Approach to the central compartment by direct visualization and inserting the switching stick through the anterior portal. (E and F) Examination in the central compartment. (G) Create the anterolateral (AL) portal under direct visualization using anterior viewing portal. (H and I) Switch the scope to the AL viewing portal and working from the anterior portal. (J to L) After a small anterior capsulotomy to about the 3 O'clock position, the iliopsoas tendon (IP) is cut using electrocautery. The iliopsoas muscle () is preserved. [L-labrum, FH-femoral head, FN-femoral neck, A-acetabulum, C-capsule].*

3. Endoscopic iliopsoas release at the lesser trochanteric level (distal endoscopic release)

3.1 Indications

- Painful iliopsoas impingement following a total hip replacement, no obvious malposition of the acetabular cup and the anterior overhang is <8 mm.
- Failed conservative more than 4–6 months with positive iliopsoas injection test.
- No evidence of prosthesis loosening or infection.

3.2 Patient position

Preoperative physical examination, blood analysis for white blood cell count, erythrocyte sedimentation rate (ESR) and C-reactive protein (CRP), hip X-rays, and CT assessment are needed to evaluate possible other causes of hip/groin pain in total hip replacement patients. Infection and prosthesis loosening need to be ruled out.

The author's preferred patient position is supine on a radiolucent traction table (Maquet, Rastatt, Germany) similar for the patient with an arthroscopic proximal release. Both legs and feet are well padded, wrapped with soft cotton and hung to the footplate. A large, well-padded perineal post is used to prevent complications from pudendal nerve compression. The C-arm is placed at the non-operative side and positioned horizontally to check the anteroposterior view of the affected hip. Traction of the prosthetic component is not a requirement and the release is performed at the lesser trochanter level. The affected leg is placed in an externally rotated position of the hip in full knee extension. This moves the lesser trochanter further anteriorly (**Figure 8**).

3.3 Surgical technique

The endoscopic portals are marked as seen in **Figure 9**. The anterolateral portal (1–2 cm anterior to level of tip of greater trochanter) and distal anterolateral portal (5–7 cm distal to anterolateral portal) are identified. The direction of the instrument and arthroscope can be aligned under fluoroscopic control toward the tip of the lesser trochanter (**Figure 10**). The needle and guidewire are inserted through the anterolateral portal with the designed trajectory toward the lesser trochanter. A 4.5-mm cannulated switching-stick (Smith and Nephew, MA, USA) is inserted then changed to a 5.0-mm cannula and an obturator. Blunt dissection using the cannula is performed above the lesser trochanter in a superior-inferior direction to create more working space anteriorly under fluoroscopic guidance. A 70° arthroscope is inserted via this anterolateral portal and the distal anterolateral portal is created as a second

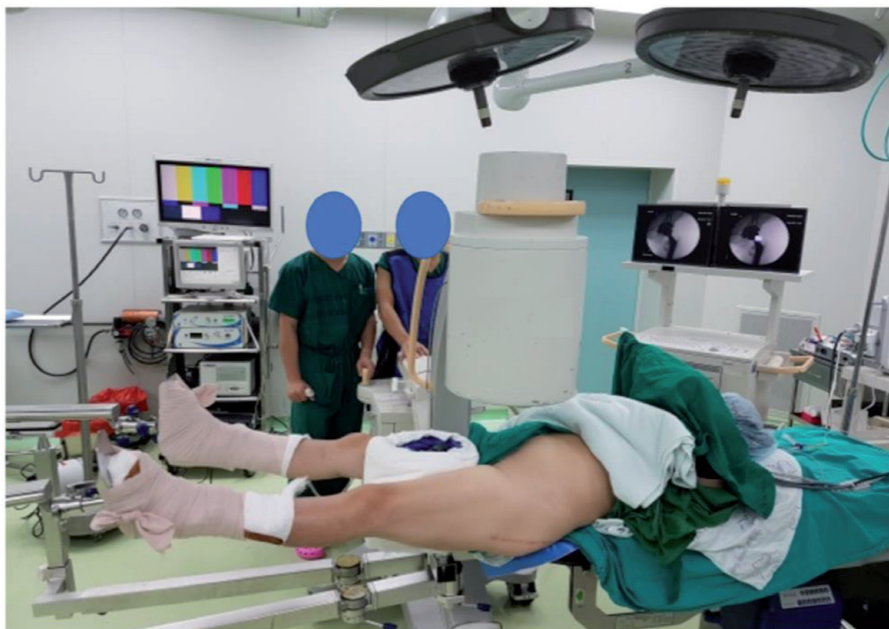

Figure 8. Patient positioned for the endoscopic iliopsoas release of the left hip. Supine on the radiolucent traction table. The surgical hip is in external rotation, fully stretched in full knee extension that brings the lesser trochanter further anteriorly.




Figure 9.
Endoscopic portals of the left hip in supine position without traction. Left hand is patient's up and right is the legs. AL, anterolateral portal; DAL, distal anterolateral portal; ASIS, anterior superior iliac spine; GT, greater trochanter.

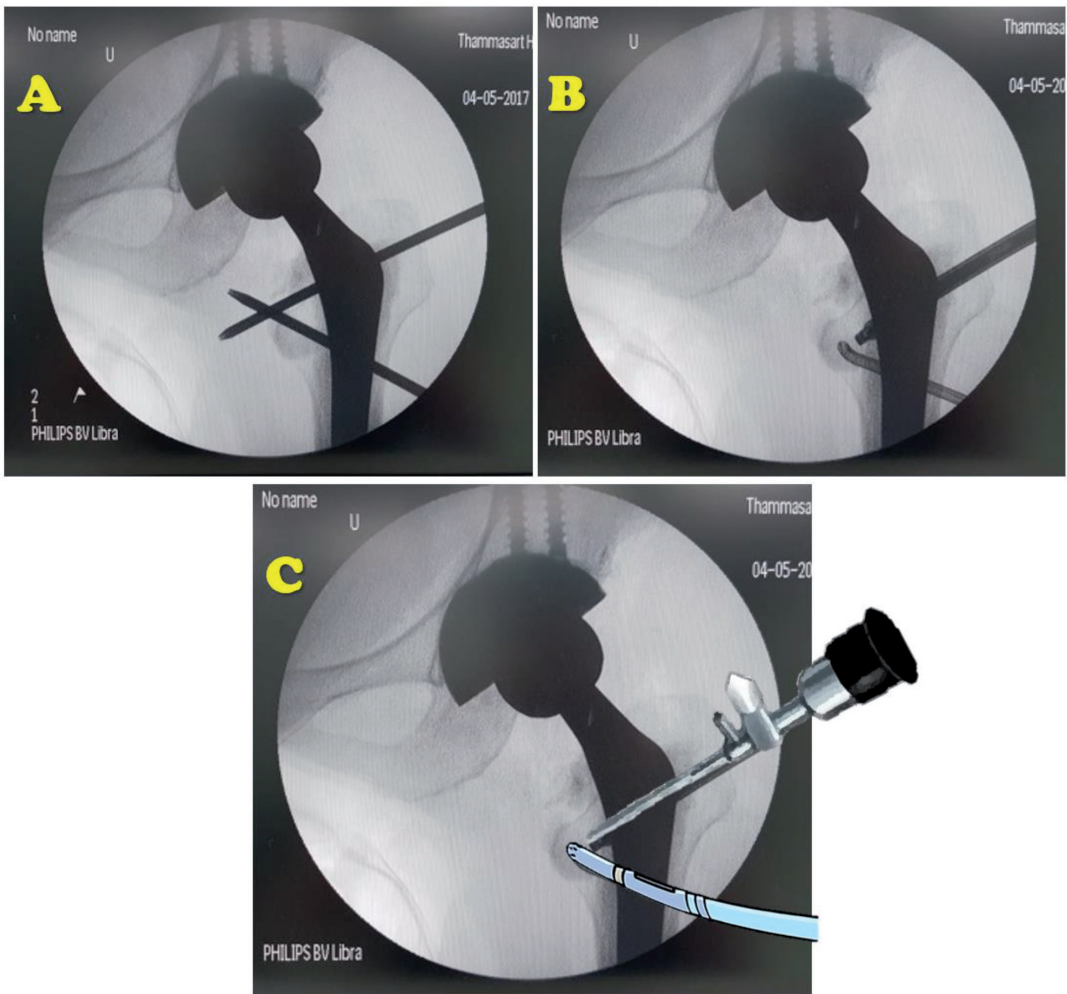


Figure 10.
Demonstration of the direction of the instrument and endoscope under fluoroscopic control in a left, prosthetic hip: (A) both instruments aimed toward tip of the lesser trochanter in the convergence direction. (B) and (C) the endoscope is inserted from the AL portal and the radiofrequency ablation is inserted from the DAL portal.

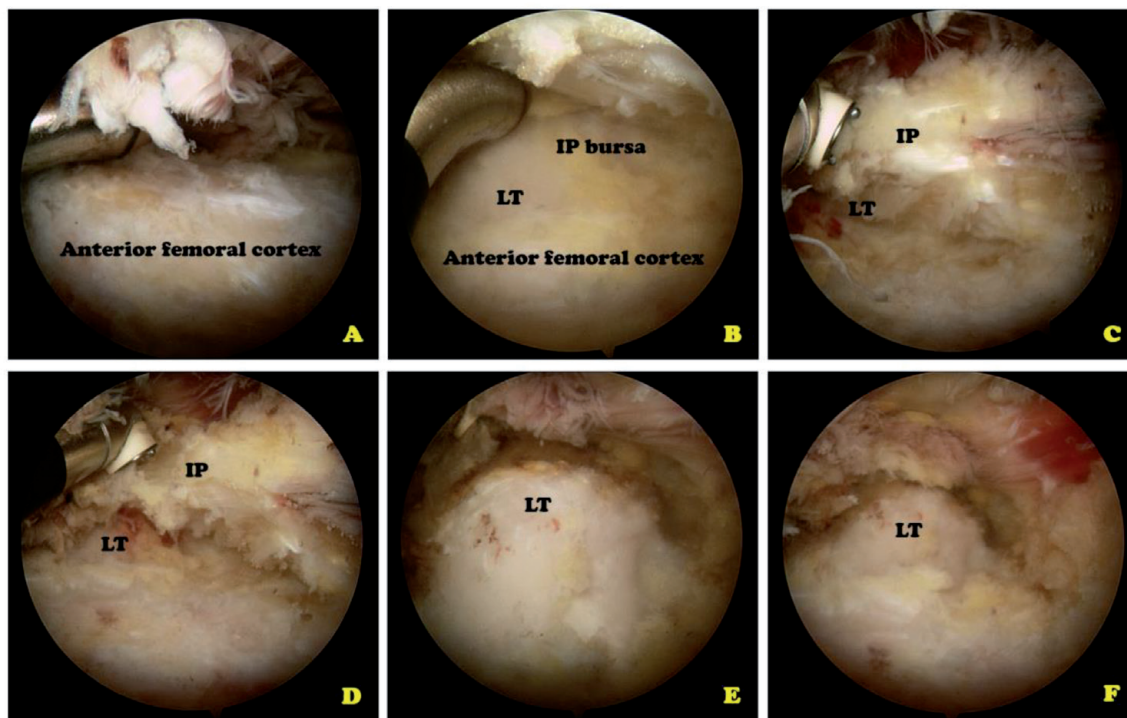


Figure 11.

Endoscopic view from the anterolateral portal of the left hip; right is the proximal aspect and left is the distal aspect of the proximal femur: (A) and (B) identification of the anterior femoral cortex, iliopsoas bursa (IP bursa) and lesser trochanter (LT) using the distal anterolateral working portal; (C) identification of the iliopsoas tendon (IP) which attaches to the lesser trochanter; (D) peeled-off iliopsoas tendon from the lesser trochanter using radiofrequency; and (E) and (F) lesser trochanter and the surrounding tissue after the iliopsoas tendon release.

portal using a needle and guidewire under fluoroscopy. The 4.5-mm, cannulated switching stick is inserted through the guidewire under endoscopic control. The iliopsoas tendon is identified at the lesser trochanteric insertion then, the radiofrequency or an arthroscopic shaver is used via the distal anterolateral portal to remove the iliopsoas bursa surrounding the tendon and to obtain adequate visualization of the tendon. The iliopsoas tendon is ‘peeled’ from the lesser trochanter using radiofrequency under direct vision (**Figure 11**). After completion of the tenotomy, the portals are simply sutured, and the wounds are closed in standard fashion.

3.4 Postoperative rehabilitation

Active hip range of motion exercises are allowed immediately following surgery. Hip flexion strength may decrease in the first 6–8 weeks and usually returns to baseline after 8 weeks. Active hip flexor strengthening exercises are allowed after 6 weeks postoperative. The patients progress to full weight bearing as soon as possible, postoperatively. Return to normal activities is allowed 6–8 weeks after surgery.

4. Discussion

An iliopsoas tenotomy has shown good to excellent postoperative outcomes in indicated patients with iliopsoas snapping/impingement. The systematic reviews of 11 eligible studies (248 patients), level IV studies revealed ‘the resolution of snapping’ as seen in 100% of patients who underwent an arthroscopic release and 77% of those who underwent open procedures. The complication rates

were higher in patients undergoing an open procedure (21%) compared with an arthroscopic procedure (2.3%). The analysis of the open procedure; either open transection of the iliopsoas tendon at the level of the lesser trochanter (14 patients) or open tendon lengthening of the iliopsoas tendon (105 patients) has shown 27 of 119 patients with recurrence of snapping and 4 of 119 experienced snapping with pain, 6 patients needed a second surgical intervention. There was an increased prevalence of recurrent snapping with open transection of the iliopsoas tendon as compared to patients with iliopsoas tendon lengthening (43% vs. 20%). The complications of the open procedure are postoperative pain (11–36%) and the hip flexion weakness (8–14%). In the arthroscopic group with transection at the lesser trochanter and transcapsular release, 3 of 37 (8%) patients of the group with transection at lesser trochanter reported complications including 2 cases of ischial bursitis and 1 case of greater trochanteric bursitis. No reported complications from the transcapsular release group. No hip flexion weakness was reported in the arthroscopic groups. None of the arthroscopically treated patients required a second surgical intervention [9].

A study of 25 patients with 2-year follow up following transcapsular release with intra-articular procedures in the internal snapping hip with combined pathologies revealed 88% of patients with good to excellent results without serious complications [10]. A comparative case-series with 20 patients, including 6 patients with a release at the lesser trochanter level vs. 14 central compartment release patients revealed the same favorable results based-on WOMAC scores. Just 1 of 14 patient with central compartment release had a recurrence of snapping that required surgical intervention. No complications were reported in both groups [11].

The iliopsoas release/tenotomy is the treatment option for iliopsoas tendinopathy or impingement following a total hip replacement. A systematic review of level IV studies in 18 studies (11 case series, 6 case reports and 1 prospective cohort) of 171 patients who underwent hip arthroscopy after an arthroplasty revealed the pathology, including 35.8% of iliopsoas tendinopathy, 24.6% of symptomatic hips with no clear diagnosis, 6.4% of periprosthetic infection, and 3.5% of intra-articular loose bodies. Almost all patients who underwent hip arthroscopy experienced positive outcomes from the procedure [12]. A systematic review of 11 studies, 280 hips treated for iliopsoas impingement, following a total hip replacement, showed improved outcome scores in all three treatment groups including: 1. conservative treatment group (54 patients using local injections and physical therapy), 2. Iliopsoas tenotomy group (133 patients using either arthroscopic, endoscopic or an open approach), and 3. Revision arthroplasty (93 patients by exchange of the acetabular component). The tenotomy group reported 5 (3.76%) complications that included 1 patient with a 13-mm acetabular prominence with continuing groin pain and subsequently needed component revision, 1 patient with a heterotrophic ossification, 1 anterior dislocation, 1 compressive hematoma affecting the peroneal nerve, and 1 periprosthetic ossification. The revision arthroplasty group reported 18 (19.4%) complications including 5 developing trochanteric bursitis, 4 with recurrent groin pain, 2 revision surgeries, 2 dislocations, 1 DVT, 1 deep infection, 1 trochanteric nonunion, 1 superficial wound infection, and 1 disarticulation [13].

A retrospective review of 49 patients [6] who had been treated for iliopsoas impingement after a primary total hip arthroplasty with 4 years of mean follow-up show 50% (10 patients) in the nonoperative group had groin pain resolution as compared to 76% (22 patients) in the operative group ($p = 0.06$). The patients with <8 mm of component prominent tenotomy stated 100% resolution of groin pain (5 patients) but patients with ≥ 8 mm of prominent tenotomy led to groin pain resolution at only 33% (3 patients). Acetabular revision in patients with ≥ 8 mm of prominence had groin pain resolution in 92% (12 of 13 patients) ($p = 0.07$). Thus, it

is suggested that use of tenotomy in patients with <8 mm of component prominence and acetabular revision in patients with ≥ 8 mm of prominence is indicated.

5. Conclusion

Iliopsoas snapping is one of the causes of hip pain in either, native or prosthetic hips. The mainstay treatment is conservative management, especially, in iliopsoas stretching. The iliopsoas release is the definite treatment in failed conservative patients. Either arthroscopic iliopsoas release from the central/peripheral compartment or, endoscopic iliopsoas release at the lesser trochanter level have shown good to excellent results in the postoperative outcomes. Acetabular revision may be considered in patients with ≥ 8 mm of prominence with persistent groin pain following a total hip replacement.

Acknowledgements

The author thanks the Orthopedics Department, Faculty of Medicine, Thammasat University and Thammasat University Hospital for the kind support. No funding was obtained regarding this manuscript.

Conflict of interest

The authors declare no conflict of interest.

Appendices and nomenclature


internal snapping hip syndrome
coxa saltans interna
iliopectineal eminence
arthroscopic iliopsoas release
endoscopic iliopsoas release
total hip replacement

Author details

Adinun Apivatgaroon
Orthopaedics Department, Thammasat University, Thailand

*Address all correspondence to: adino_ball@yahoo.com

IntechOpen

© 2020 The Author(s). Licensee IntechOpen. This chapter is distributed under the terms of the Creative Commons Attribution License (<http://creativecommons.org/licenses/by/3.0>), which permits unrestricted use, distribution, and reproduction in any medium, provided the original work is properly cited. 

References

- [1] Ilizaliturri VM Jr, Suarez-Ahedo C, Acuña M. Internal snapping hip syndrome: Incidence of multiple-tendon existence and outcome after endoscopic transcapsular release. *Arthroscopy*. 2015;**31**(10):1991-1995
- [2] Troelsen A, Mechlenburg I, Gelineck J, Bolvig L, Jacobsen S, Søballe K. What is the role of clinical tests and ultrasound in acetabular labral tear diagnostics? *Acta Orthopaedica*. 2009;**80**(3):314-318
- [3] Blankenbaker DG, Tuite MJ, Keene JS, del Rio AM. Labral injuries due to iliopsoas impingement: Can they be diagnosed on MR arthrography? *American Journal of Roentgenology*. 2012;**199**(4):894-900
- [4] Domb BG, Shindle MK, McArthur B, Voos JE, Magennis EM, Kelly BT. Iliopsoas impingement: A newly identified cause of labral pathology in the hip. *HSS Journal*. 2011;**7**(2):145-150
- [5] Singh JA, Yu S, Chen L, Cleveland JD. Rates of total joint replacement in the United States: Future projections to 2020-2040 using the National Inpatient Sample. *The Journal of Rheumatology*. 2019;**46**(9):1134-1140
- [6] Chalmers BP, Sculco PK, Sierra RJ, Trousdale RT, Berry DJ. Iliopsoas impingement after primary total hip arthroplasty: Operative and nonoperative treatment outcomes. *The Journal of Bone and Joint Surgery. American Volume*. 2017;**99**(7):557-564
- [7] Guicherd W, Bonin N, Gicquel T, Gedouin JE, Flecher X, Wettstein M, et al. Endoscopic or arthroscopic iliopsoas tenotomy for iliopsoas impingement following total hip replacement. A prospective multicenter 64-case series. *Orthopaedics & Traumatology, Surgery & Research*. 2017;**103**(8S):S207-S214
- [8] Wettstein M, Jung J, Dienst M. Arthroscopic psoas tenotomy. *Arthroscopy*. 2006;**22**(8):907.e1-4
- [9] Khan M, Philippon MJ, et al. Surgical management of internal snapping hip syndrome: A systematic review evaluating open and arthroscopic approaches. *Arthroscopy*. 2013;**29**(5):942-948
- [10] Hwang DS, Hwang JM, Kim PS, Rhee SM, Park SH, Kang SY, et al. Arthroscopic treatment of symptomatic internal snapping hip with combined pathologies. *Clinics in Orthopedic Surgery*. 2015;**7**(2):158-163
- [11] Ilizaliturri VM Jr, Buganza-Tepole M, Olivos-Meza A, Acuna M, Acosta-Rodriguez E. Central compartment release versus lesser trochanter release of the iliopsoas tendon for the treatment of internal snapping hip: A comparative study. *Arthroscopy*. 2014;**30**(7):790-795
- [12] Heaven S, de Sa D, Simunovic N, Williams DS, Naudie D, Ayeni OR. Hip arthroscopy in the setting of hip arthroplasty. *Knee Surgery, Sports Traumatology, Arthroscopy*. 2016;**24**(1):287-294
- [13] Shapira J, Chen SL, Wojnowski NM, Lall AC, Rosinsky PJ, Maldonado DR, et al. Outcomes of nonoperative management, iliopsoas tenotomy, and revision arthroplasty for iliopsoas impingement after total hip arthroplasty: A systematic review. *The Journal of Arthroplasty*. 2019;**34**(9):2184-2191