

We are IntechOpen, the world's leading publisher of Open Access books Built by scientists, for scientists

6,900

Open access books available

185,000

International authors and editors

200M

Downloads

Our authors are among the

154

Countries delivered to

TOP 1%

most cited scientists

12.2%

Contributors from top 500 universities



WEB OF SCIENCE™

Selection of our books indexed in the Book Citation Index
in Web of Science™ Core Collection (BKCI)

Interested in publishing with us?
Contact book.department@intechopen.com

Numbers displayed above are based on latest data collected.
For more information visit www.intechopen.com



Minimally Invasive Ventricular Assist Device Surgery

*Marina Comisso, Andrea Montalto, Francesca Nicolò,
Romina Pantanella and Francesco Musumeci*

Abstract

Heart failure is a growing disease that affects millions of people around the world. Heart transplantation is currently the therapy of choice for these patients. However, the lack of donors has forced the physician to evolve another kind of therapy such as ventricular assist device (VAD) as a bridge to transplant to compensate the lack of organs. Ventricular assist devices are today a successful therapy for the treatment of heart failure; the evolution of these devices and their progressive miniaturization have allowed an evolution of their implantation technique. To date, therefore, in addition to the traditional implant through sternotomy, there are more mini-invasive implant techniques. The purpose of the treaty is to describe these techniques, the implantation sites, and the benefits they can bring to patients.

Keywords: LVAD, minimally invasive, heart failure, ventricular assist device

1. Introduction

Heart failure is a chronic progressive disease characterized by decreased pump function. This may lead to venous congestion and also to hypoperfusion due to low cardiac output with severe organ comorbidities. Modern conservative therapies for heart failure have improved outcomes in adult patients [1]. Despite medical advances in treating this condition, the disease itself remains a progressive condition. For treating end-stage heart failure, cardiac transplantation remains the gold standard. Despite this evidence, cardiac transplantation as a therapeutic option is limited by donor organ shortage and is therefore limited to patients younger than 65 years [2]. However a promising alternative to cardiac transplantation is ventricular assist device (VAD) implantation. In consideration of these problems, the number of VAD implantations has exceeded the number of cardiac transplantations [3]. This therapeutic trend, i.e., the increasing number of patients who undergo VAD implantation also as a destination therapy (DT), has led to an obvious longer duration of the assistance period with the cardiovascular assistance system. This has also led to a change in the basal characteristics of patients who (especially DT patients) are increasingly older, are more fragile, have greater comorbidities, and, consequently, may have a higher incidence of surgical complications [4]. For several years the choice approach for VAD implantation was sternotomy. However, destination therapy patients suffered a greater intraoperative risk and increased mortality [5]. Nonetheless, Slaughter showed that treatment

with VADs significantly increased survival of DT patients. At that time the sternotomy approach was mandatory due to the size of the VADs [6]. Technological progress has allowed a miniaturization of the devices and their better hemodynamic performance. This has allowed the development of mini-invasive implant techniques that allow a lower surgical risk for patients, less trauma, less incidence of bleeding, and obviously less patient stay in intensive therapy [7]. The purpose of this chapter is to describe the mini-invasive VAD implantation techniques and to describe the possible benefits that these techniques can bring to the patient's outcome.

2. Indication and standard approach

The indications for the implantation of left ventricular device mainly concern patients suffering from left ventricular failure with ejection fraction $\leq 25\%$ and a preserved right ventricular function (**Table 1** summarizes the main indications as indicated by the European guidelines on heart failure 2016) [8]. The standard approach for left ventricular assist device (LVAD) implantation is full sternotomy; it is done as the “first choice” in many centers around the world based on the long-term experience. The advantages of this approach are various: certainly full sternotomy provides the best anatomical overview of the heart and the major vessel and structures; moreover full sternotomy allows to approach different procedures that can be correlated and necessary to the LVAD implantation such as closure of septal defects, repair of the tricuspid valve, or ligation of the left atrium due to atrial fibrillation [9]. The classical implant operation through median sternotomy also involves the use of the heart-lung machine; the operation is divided into three main steps:

1. Connection between the left ventricle (LV) and inflow cannula.
2. Tunneling of the driveline.
3. Anastomosis of the outflow cannula to the ascending aorta.

The cannulation sites to establish the heart-lung machine are classically the right atrium and ascending aorta. The main advantages in using the heart-lung machine are two: the first one is the possibility to view and resect the trabeculae that could later cause blood turbulence and thrombus formation; the second one is the possibility to do intraoperative ventricular inspection if there's echocardiography evidence of left ventricle thrombus. However the standard surgical approach has several disadvantages: sternotomy causes pericardial adhesions and possible dangerous conditions in case of reoperations (e.g., in case of transplantation in BTT patients or in the case of pump exchange). Moreover, sternotomy leads to greater risk of postoperative bleeding, sternal infections, and wound dehiscences and therefore increases the patient's surgical trauma and risk of secondary right heart failure [7].

As previously mentioned traditionally, the implantation of the LVAD is performed with the help of the heart-lung machine. It is known, however, that this machine plays an important role in the activation of inflammatory mediators, increased pulmonary vascular resistance, platelet activation, coagulopathy, and impaired renal function [10]. The patient population that requires VAD implantation often has evidence of end-organ dysfunction, including liver congestion, renal insufficiency, and pulmonary edema. VAD placement under cardiopulmonary

Patients with severe <u>symptoms</u> despite optimal medical therapy and more than 1 of the following:
- LVEF < 25% and peak VO2 < 12 mL/kg/min
- ≥ 3 HF hospitalizations in previous 12 month
- Dependence on <u>i.v.</u> inotropic therapy
- Progressive end-organ dysfunction (worsening renal and/or hepatic function) due to reduced perfusion and not to inadequate ventricular filling pressure (PCWP ≥ 20 mmHg and C.I. ≤ 2 L/min/m ²)
- Absence of severe right ventricular dysfunction together with severe tricuspid regurgitation
HF, heart failure; <u>i.v.</u> , intravenous; PCWP, pulmonary capillary wedge pressure; C.I., cardiac index.

Table 1.
Indication for implantation of LVAD.

bypass (CPB) often exacerbates these pre-existing conditions, resulting in postoperative coagulopathy, bleeding, and worsening right heart failure. VAD implantation without the use of CPB could help to minimize these postoperative complications [11].

3. Minimally invasive LVAD implantation (off-pump technique)

Minimally invasive implantation techniques require patient assessment and evaluation. Echocardiography helps identify patients with valvular disease who need concomitant valve procedure and would preferably be approached through a standard midline sternotomy. In the presence of left ventricle thrombus, an on-pump approach should be performed for thrombus removal. Noncontrast chest computed tomography is helpful in determining which intercostal space to be used and whether an anterolateral or lateral mini-thoracotomy should be utilized (most of the time, fifth or sixth intercostal space). Chest computed tomography will also be useful for the evaluation of the outflow aortic anastomosis site and to rule out aortic calcification and aneurysm [12].

The LVAD implantation is divided into three steps:

- 1. Inflow cannula and pump insertion.
- 2. Outflow graft (OG) insertion.
- 3. Driveline insertion.

The minimally invasive implantation procedure could be done for the first two steps.

4. Minimally invasive implantation of inflow cannula and pump insertion

There are two types of minimally invasive approaches to implant the VAD and the inflow cannula; the first one we describe is a left subcostal incision (**Figure 1**). This kind of approach was used mainly for the LVAD HeartMate II that is the largest of the contemporary LVAD devices [13]. A subcostal incision is used, running along the left-sided rib cage. After division of the abdominal muscles, preparation anteriorly to the diaphragm is performed. Through this access, the pericardium can be divided and the left ventricular apex easily identified [14].

The second one is via left anterior thoracotomy at the fifth or sixth intercostal space (**Figure 2**). Intraoperative echocardiography is used to identify the LV apex location and to determine the optimal location and intercostal space for left thoracotomy. A 6 cm thoracotomy incision is usually performed in the fifth or sixth intercostal space; upon entering the chest, the pericardium is identified and divided, and a pericardial cradle is created with pericardial sutures to expose the LV apex [12].

In case of an off-pump VAD placement, there are techniques that can be used to reduce the use of blood. Reliant on the experience in transcatheter valve implantation by the use of rapid pacing, multiple authors reported inserting off-pump LVAD with rapid pacing for the insertion [15]. Implantation of LVAD with non-fibrillatory technique by administering of an intravenous bolus of adenosine to induce a short bradycardic arrest during off-pump LVAD placement was also described [16], in order to reduce blood loss by reducing both the volume of the blood ejected from the heart during LVAD implant (reduction in blood pressure) and decreasing the heartbeats. In this method adenosine mediates pulmonary vasodilatation, which may reduce pulmonary resistance and protect the right ventricle function [17].

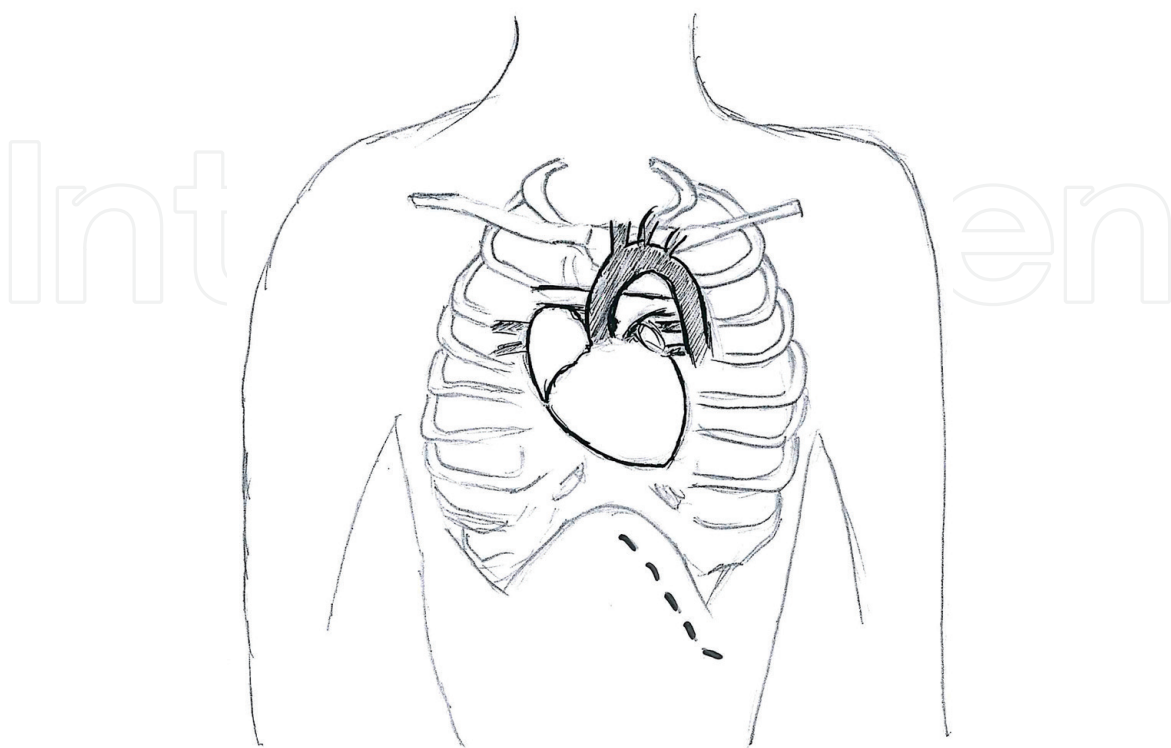


Figure 1.
Left subcostal incision.

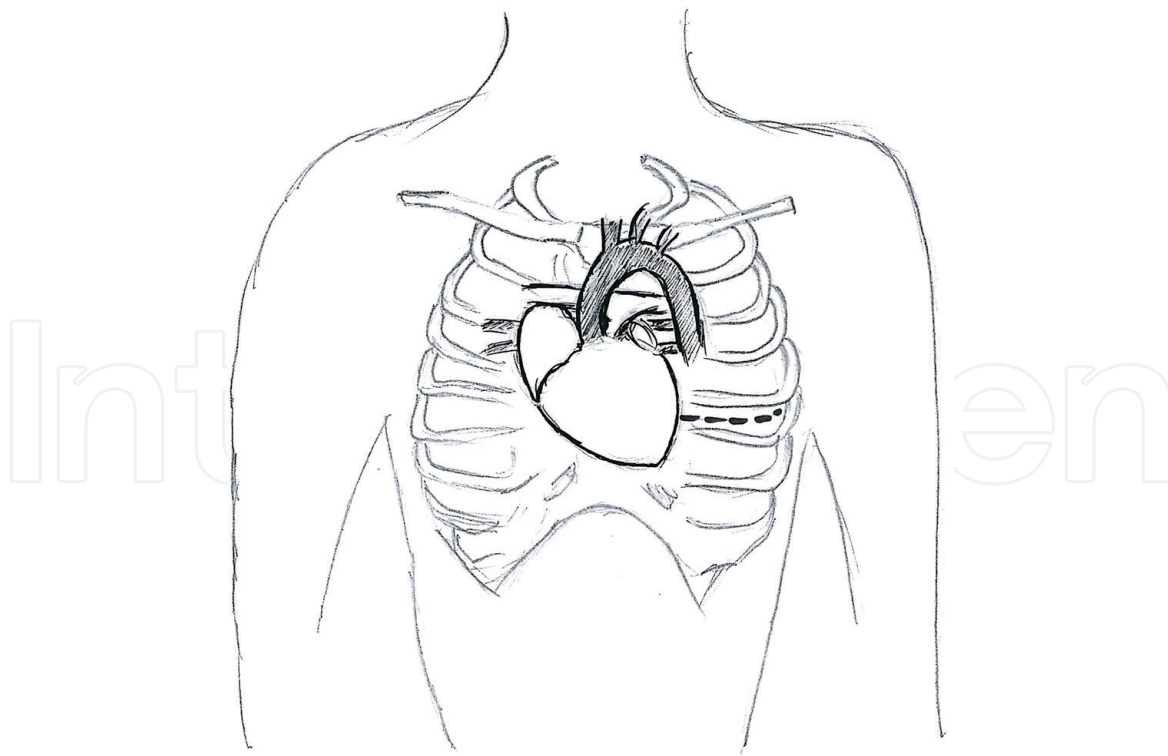


Figure 2.
 Left anterior thoracotomy at fifth or sixth intercostal space.

5. Outflow graft insertion

This step of LVAD implantation technique could be done by multiple ways in different locations: right mini-thoracotomy, split upper hemi-sternotomy, axillary and subclavian arteries, supraceliac abdominal aorta, innominate artery, and descending aorta [18].

The most commonly used technique for on-pump minimally invasive strategy of LVAD implantation is through upper hemi-sternotomy (**Figure 3**) [19]. A 4 cm upper hemi-sternotomy is performed to expose the ascending aorta; if CPB is planned, the distal ascending aorta could be used for arterial cannulation to assure adequate cerebral perfusion, and femoral vein is used for a percutaneous venous cannulation. It can be associated with either inflow pump incisions; for the majority of patients, the outflow graft is tunneled and passed within the pericardium and anastomosed to the proximal ascending aorta (**Figure 4**). The OG could be passed in the anterior mediastinum behind the sternum in case of previous sternotomy.

Another way to implant the OG is through right mini-thoracotomy (**Figure 5**). This kind of approach can be used if the ascending aorta demonstrated a right-side curvature on preoperative chest tomography. A 4–6 cm incision is made at second to third intercostal spaces which allows access to the ascending aorta to perform the outflow anastomosis: after passing the outflow graft from the left thoracotomy to the right thoracotomy, a side-biting clamp is attached on the ascending aorta, and after adequate incision of the aorta, the graft is anastomosed in the usual manner. Another method is the combination of the previous two approaches through an upper hemi-sternotomy with right hemi-thoracotomy J-shape incision (**Figure 6**). At least left subclavian outflow graft anastomosis has been increasingly utilized for patient's anatomy when OG anastomosis to the ascending or the descending aorta is prohibited (**Figure 7**). The OG is tunneled through the right or the left pleural cavity and passed through the second intercostal space to be anastomosed to the subclavian artery (**Figure 8**). If this technique is used, attention must be paid to the eventual

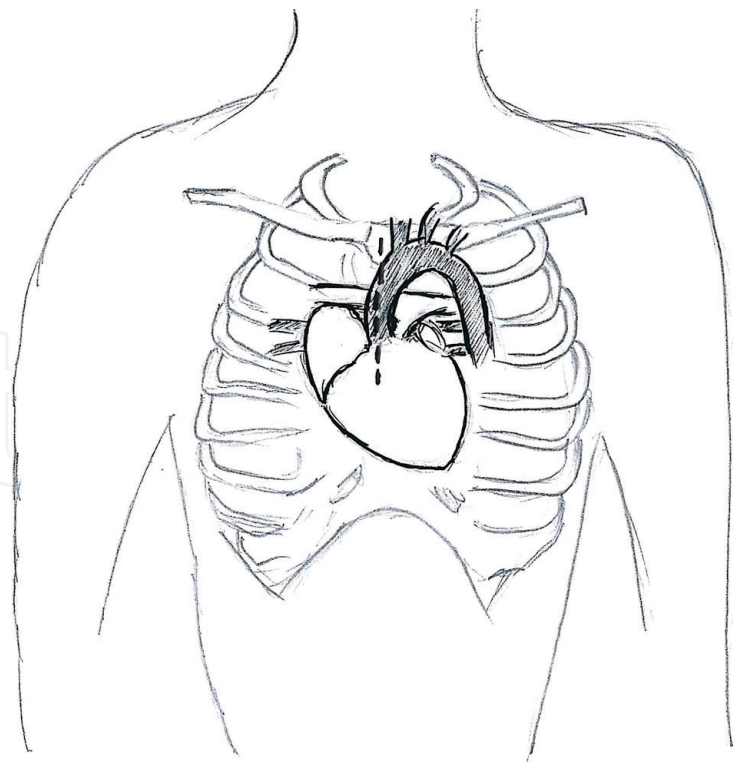


Figure 3.
Upper hemi-sternotomy.

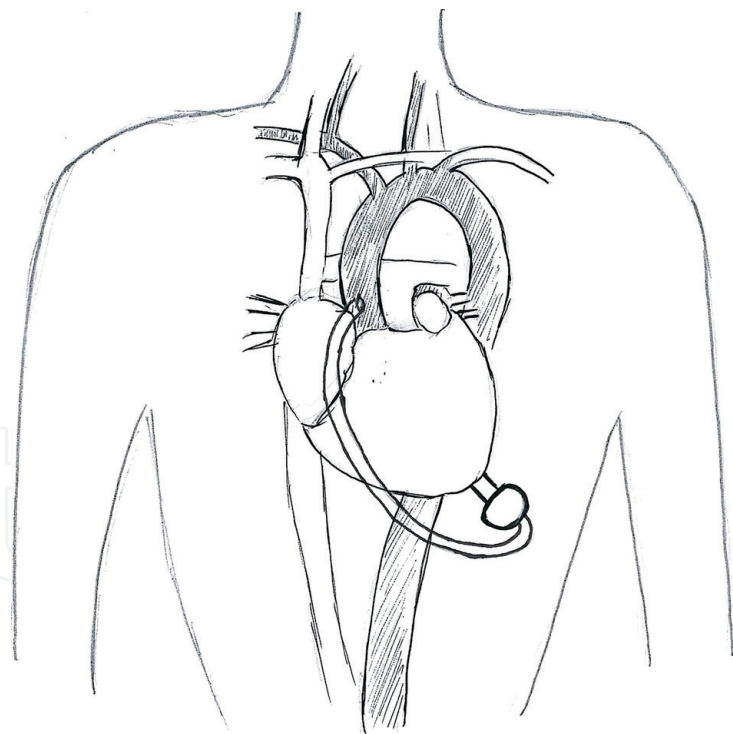


Figure 4.
The OG anastomosed to the proximal ascending aorta.

compression of the OG by adjacent structures; it is necessary to reduce the possibility of creating excess flow to the arm and also the turbulence of the flow in case of mobilization of the arm. Banding of the subclavian artery is mandatory if there is a mean pressure difference of more than 20 mmHg to avoid excessive blood flow to the arm [20].

Two further types of approaches are used less frequently: single left thoracotomy incision with descending aorta anastomosis (**Figure 9**) and supraceliac

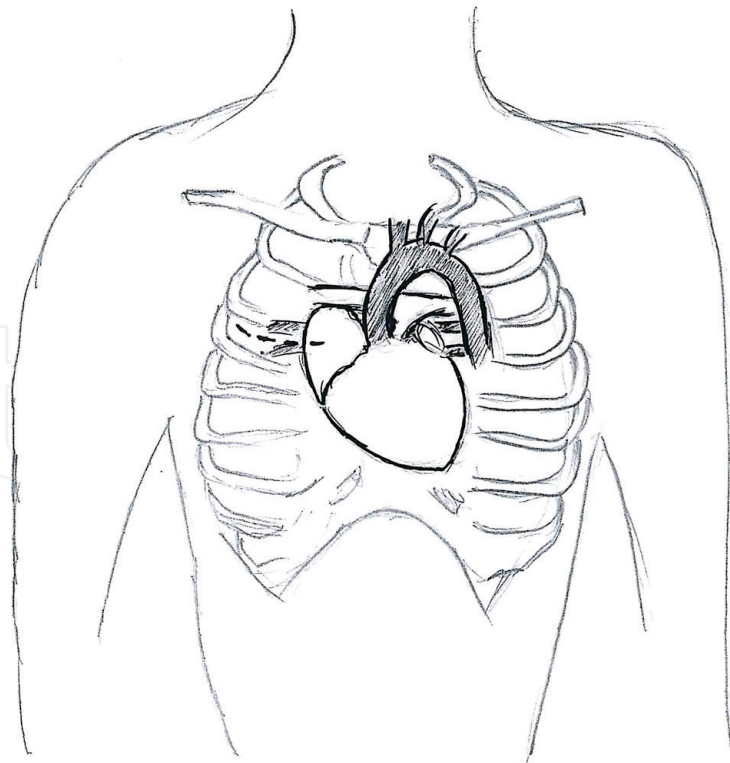


Figure 5.
Right hemi-thoracotomy.

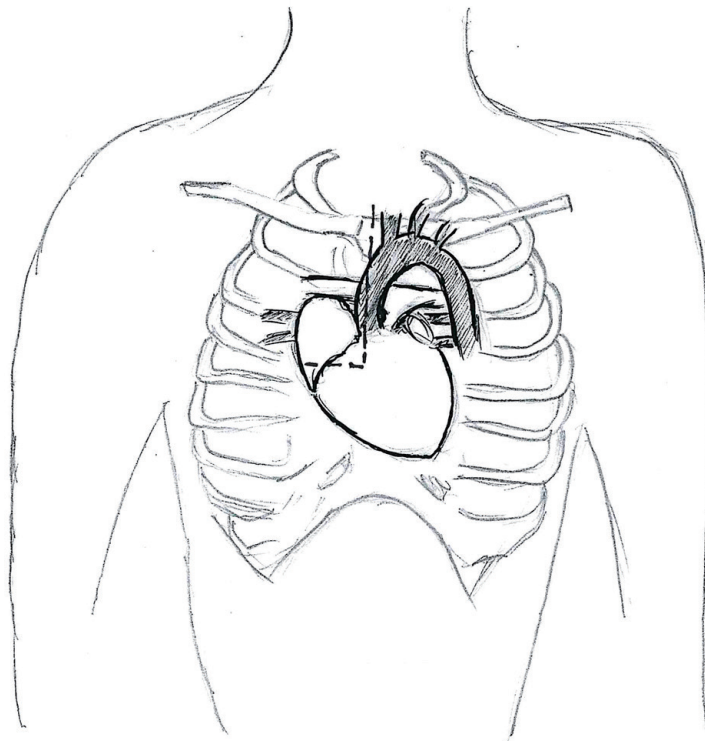


Figure 6.
Right hemi-sternotomy J-shape incision.

abdominal aorta anastomosis (**Figure 10**). In the first approach, the inferior pulmonary ligament is freed to optimize exposure; the OG is placed in the left pulmonary fissure, measured, and anastomosed end to side to the descending aorta or the aortic arch using a partial cross clamp [21]. The second one is used by making left subcostal incision and dividing the diaphragm to make the pocket. This allows the LVAD to be implanted on the diaphragmatic surface of

the left ventricle, and the supraceliac aorta is then exposed by extraperitoneal exposure. The outflow is trimmed and anastomosed end to side on the supraceliac aorta [22].

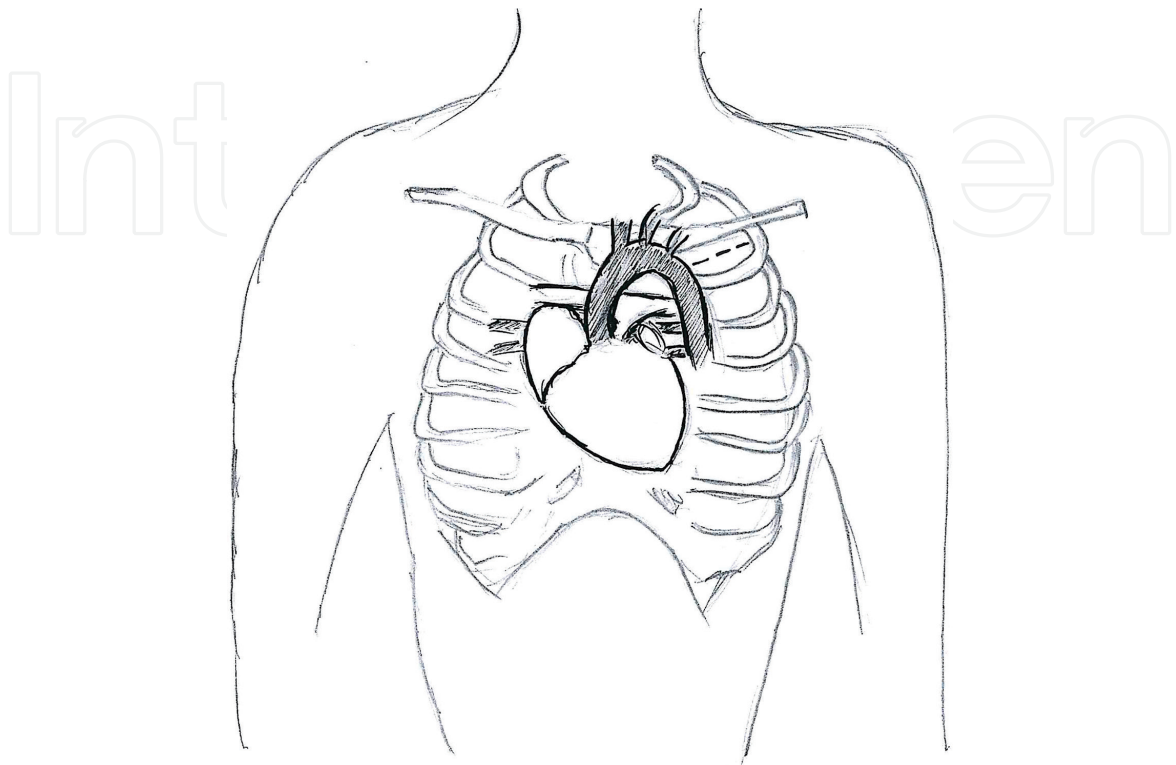


Figure 7.
Left hemi-thoracotomy.

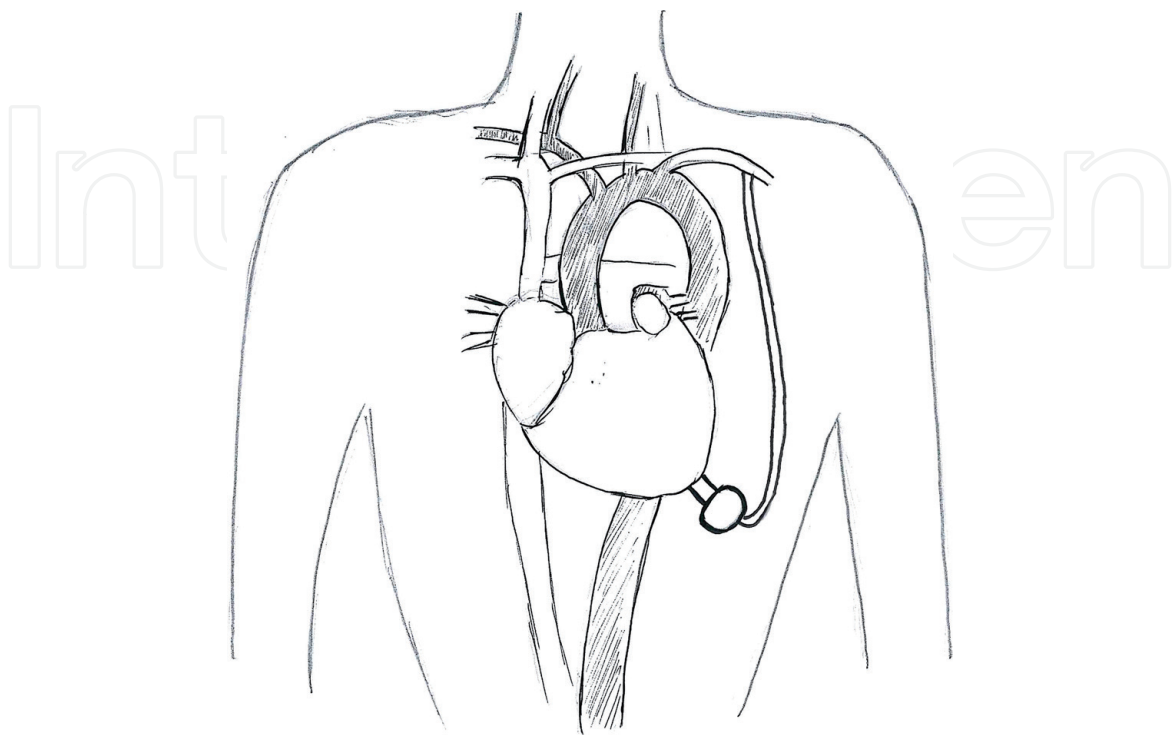


Figure 8.
The OG anastomosed to the subclavian artery.

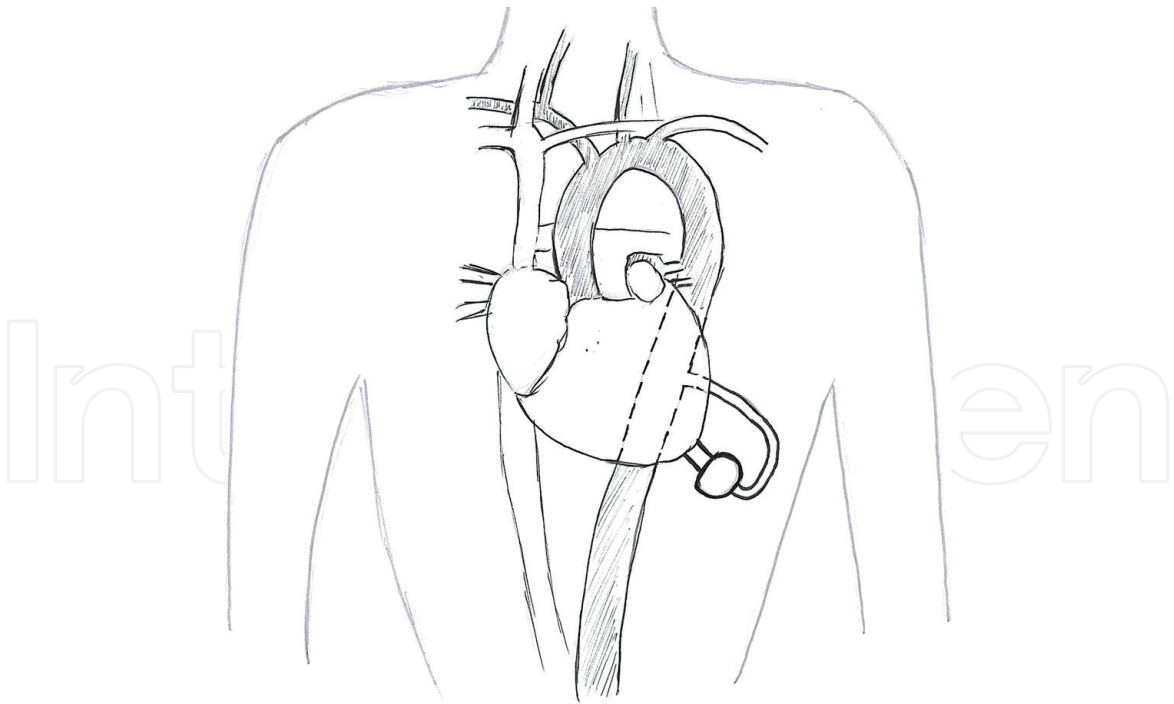


Figure 9.
Single left thoracotomy incision with descending aorta anastomosis.

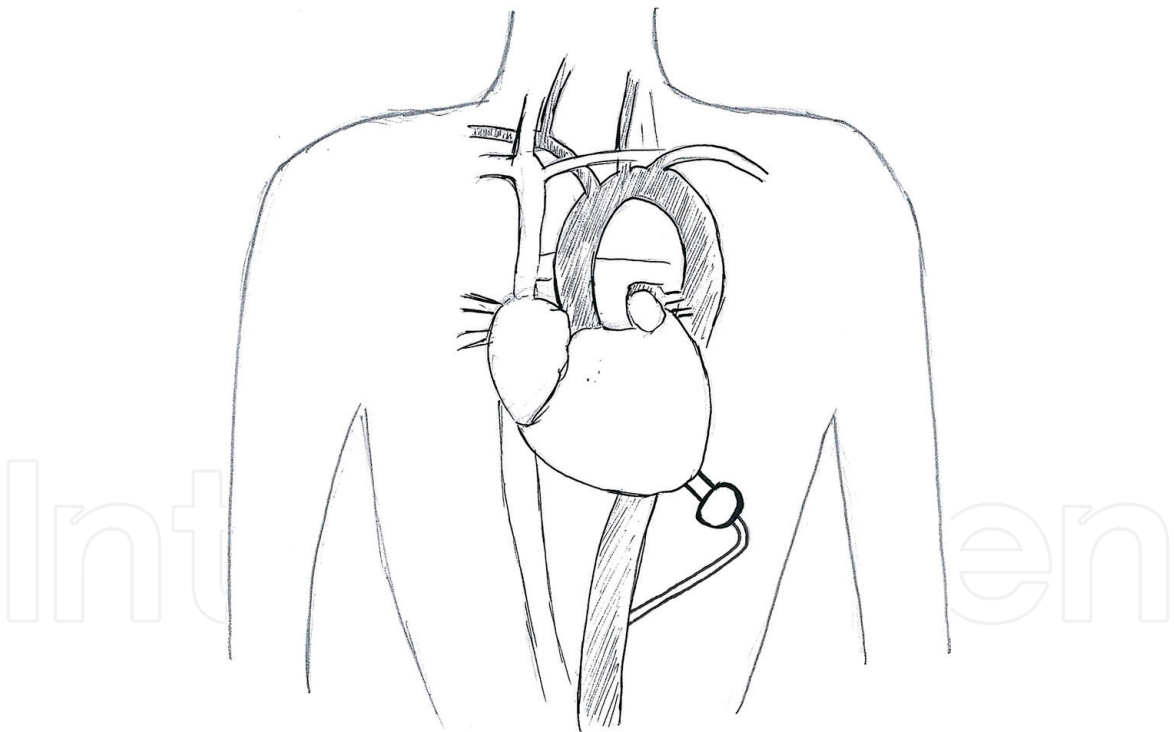


Figure 10.
Supraceliac abdominal aorta anastomosis.

6. Conclusions

The use of LVAD has increased significantly along with the rapidly expanding heart failure patient population. Like in other cardiac surgical procedures, minimally invasive approaches are becoming more commonly used, also in the field of VAD implantation. Multiple studies have shown minimally invasive cardiac surgery improves outcomes with reduced surgical trauma and complication rates, e.g., post-operative bleeding, reduced blood transfusion requirement, faster recovery rate, and

decreased hospital cost. However it remains a matter of debate if these approaches offer advantages in comparison to standard full-sternotomy access in LVAD implantation procedure. An undeniable advantage of the minimally invasive implantation technique is the lack of adhesions at the time of transplant, which facilitates heart transplantation and also reduces ischemia time resulting in improved graft performance. The use of off-pump LVAD implantation approach allows the avoidance of cardiopulmonary bypass and will decrease the incidence of vasoplegia and coagulopathy postoperatively. Another advantage of a less invasive approach is that the right ventricle remains in its natural position, as the surrounding pericardium stays intact and the right ventricular function remains sustained; in this way right ventricular failure is passively avoided [23]. The progressive miniaturization of VADs has provided a further boost to the research of mini-invasive implantation techniques, and future research will tend towards ever greater device miniaturization. LVAD implantation by minimally invasive procedure is feasible and safe; LVAD implantation without the use of CPB has the potential to minimize postoperative complication such as excessive bleeding during implantation without compromising hemodynamics. By minimizing the needs for blood transfusions, patients have decreased exposure to blood antigens which ultimately reduces the risk of sensitization in BT patients. The upcoming advancement of LVAD technology and miniaturization of mechanical circulatory support will only further advance the success of LVAD surgery and will benefit more patients especially with the rapidly growing heart failure population worldwide.

Conflict of interest

The author has no conflicts of interest to declare.

Notes/Thanks/Other declarations

We would like to thank S. Castellan for her work on the figures.

Author details

Marina Comisso^{1*}, Andrea Montalto¹, Francesca Nicolò¹, Romina Pantanella² and Francesco Musumeci¹

¹ Department of Cardiac Surgery and Heart Transplantation, San Camillo Hospital, Rome, Italy

² Department of Cardiac Surgery, Sant Andrea Hospital, Rome, Italy

*Address all correspondence to: marina.comisso@gmail.com

IntechOpen

© 2020 The Author(s). Licensee IntechOpen. This chapter is distributed under the terms of the Creative Commons Attribution License (<http://creativecommons.org/licenses/by/3.0>), which permits unrestricted use, distribution, and reproduction in any medium, provided the original work is properly cited. 

References

- [1] Nair AP, Timoh T, Fuster V. Contemporary medical management of systolic heart failure. *Circulation Journal*. 2012;**76**:268-277
- [2] Lund LH, Edwards LB, Kucheryavaya AY, et al. The registry of the International Society for Heart and Lung Transplantation: Thirty-second official adult heart transplantation report–2015; focus theme: Early graft failure. *The Journal of Heart and Lung Transplantation*. 2015;**34**:1244-1254
- [3] Kirklin JK, Naftel DC, Pagani FD, et al. Seventh INTERMACS annual report: 15000 patients and counting. *The Journal of Heart and Lung Transplantation*. 2015;**34**:1495-1504
- [4] Moazami N, Milano CA, John R, et al. Pump replacement for left ventricular assist device failure can be done safely and is associated with low mortality. *The Annals of Thoracic Surgery*. 2013;**95**:500-505
- [5] Coyle LA, Ising MS, Gallagher C, et al. Destination therapy: One year outcome in patients with a body mass index greater than 30. *Artificial Organs*. 2010;**34**:93-97
- [6] Slaughter MS, Rogers JG, Milano CA, et al. Advanced heart failure treated with continuous-flow left ventricular device. *The New England Journal of Medicine*. 3 Dec 2009;**361**(23):2241-2251
- [7] Hanke JS, Rojas SV, Avsar M, et al. Minimally-invasive LVAD implantation: State of the art. *Current Cardiology Reviews*. 2015;**11**:246-251
- [8] Ponikowski P, Voors AA, Anker SD, et al. 2016 ESC guidelines for the diagnosis and treatment of acute and chronic heart failure. *European Journal of Heart Failure*. 2016;**18**:891-975
- [9] Balsara KR, Bierhals A, Vader J, et al. Implantation of left ventricular assist device in patient with left ventricular non-compaction. *Journal of Cardiac Surgery*. Feb 2017;**32**(2):159-161
- [10] Belhaj A. Actual knowledge of systemic inflammation reaction during cardiopulmonary bypass. *Recent Patents on Cardiovascular Drug Discovery*. 2012;**7**:165-169
- [11] Cheung A, Lamarche Y, Kaan A, et al. Off-pump implantation of the HeartWare HVAD left ventricular assist device through minimally invasive incision. *The Annals of Thoracic Surgery*. 2011;**91**:1294-1296
- [12] Cheng A. Minimally invasive left ventricular assist device placement. *Journal of Visceral Surgery*. 2015;**1**:25
- [13] Pagani FD, Miller LW, Russel SD, et al. Extended mechanical circulatory support with continuous-flow rotary left ventricular assist device. *Journal of the American College of Cardiology*. 2009;**54**:312-321
- [14] Wiedemann D, Haberl T, et al. Minimally invasive approaches for implantation of left ventricular assist device. *Indian Journal of Thoracic and Cardiovascular Surgery*. 2018;**34**(Suppl 2):S177-S182
- [15] Centofanti P, La Torre M, Attisani M, et al. Rapid pacing for the off-pump insertion of the Jarvik left ventricular assist device. *The Annals of Thoracic Surgery*. 2011;**92**:1536-1538
- [16] Maltais S, Davis ME, Haglund N. Minimally invasive and alternative approaches for long term LVAD placement: The Vanderbilt strategy. *Annals of Cardiothoracic Surgery*. 2014;**3**:563-569
- [17] Galiè N, Ussia G, Passarelli P, et al. Role of pharmacologic tests in the treatment of primary pulmonary

hypertension. *The American Journal of Cardiology*. 1995;75:55A-62A

[18] El-Sayed Ahmed MM, Aftab M, Singh SK, et al. Left ventricular assist device outflow graft: Alternative sites. *Annals of Cardiothoracic Surgery*. 2014;3(5):541-545

[19] Ricklefs M, Hanke SJ, Schmitto JD, et al. Less invasive surgical approaches for left ventricular assist device implantation. *Seminars in Thoracic & Cardiovascular Surgery*. 2018;30(1):1-6. DOI: 10.1053/j.semtcvs.2018.01.002

[20] Riebandt J, Sandner S, Mahr S, et al. Minimally invasive thoratec Heartmate II implantation in the setting of severe thoracic aortic calcification. *The Annals of Thoracic Surgery*. 2013;96:1094-1096

[21] Popov AF, Mohite PN, Sabashnikov A, et al. Minimally invasive HeartWare LVAD implantation through single left thoracotomy. *Journal of Artificial Organs*. 2015;18:170-172

[22] Anyanwu AC. Technique for less invasive implantation of HeartMate II left ventricular assist device without median sternotomy. *Seminars in Thoracic and Cardiovascular Surgery*. 2011 Autumn;23(3):241-244

[23] Schmitto JD, Molitoris U, Haverich A, et al. Implantation of a centrifugal pump as a left ventricular assist device through a novel, minimized approach: Upper hemisternotomy combined with anterolateral thoracotomy. *The Journal of Thoracic and Cardiovascular Surgery*. 2012;143:511-513