

We are IntechOpen, the world's leading publisher of Open Access books Built by scientists, for scientists

6,900

Open access books available

185,000

International authors and editors

200M

Downloads

Our authors are among the

154

Countries delivered to

TOP 1%

most cited scientists

12.2%

Contributors from top 500 universities



WEB OF SCIENCE™

Selection of our books indexed in the Book Citation Index
in Web of Science™ Core Collection (BKCI)

Interested in publishing with us?
Contact book.department@intechopen.com

Numbers displayed above are based on latest data collected.
For more information visit www.intechopen.com



Adenomyosis

Wei Zheng and Boya Deng

Abstract

Adenomyosis is a benign uterus disease in which the invasion of the endometrial glands and/or stroma within myometrium is found and usually appears between the ages of 40 and 50 years in women. There are several differences in their pathogenesis. The secondary dysmenorrhea and menorrhagia are the common symptoms. Ultrasound sonography, MRI, CA125, and histological examination can be helpful for the diagnosis of adenomyosis. The treatment of adenomyosis depends on the patient's age, symptoms, and desire for future fertility, including medical treatment and surgical treatment.

Keywords: adenomyosis, hyperestrogenism, progesterone, laparoscopic, GnRHa, LNG-IUS

1. Introduction

Adenomyosis is a benign uterus disease in which the invasion of the endometrial glands and/or stroma within myometrium is found and usually appears between the ages of 40 and 50 years in women [1]. It can result in debilitating pelvic pain, abnormal uterine bleeding, and infertility. It was first described in 1860 by Rokitansky, and in 1896, Cullen suggested the term “adenomyosis.” Adenomyosis is an estrogen-dependent disease similar to endometriosis and it regresses rapidly after the menopause. However, adenomyosis is a poorly understood gynecologic disease.

2. Prevalence

Most cases of adenomyosis were discovered in multiparous women during the transitional years (40–50 years). Women of age range 30–60 years also can be affected. The incidence of adenomyosis remains unknown, because the disease is usually recorded on the base of hospital and surgical reports, it is generally estimated that 20% of women have adenomyosis. However, an analysis of multiple myometrial sections may reveal an incidence as high as 65% [2].

3. Pathogenesis

Endometriosis and adenomyosis are closely linked diseases, but there are several differences in their pathogenesis. Four theories have been proposed to explain adenomyosis: heredity, trauma, hyperketonemia, and viral transmission. Although the exact cause is unknown, the most widely accepted theory of histogenesis was proposed by Meyer in 1900. Meyer postulated that the normal barrier between

the endometrium and myometrium is somehow attenuated. The most held theory regarding adenomyosis is the endometrial basal layer invades through the endomyometrial junctional zone (JZ) into the myometrium after trauma on the endometrium [3]. Estrogen and progesterone likely play a role in its development after invagination of the endometrium. Another theory is that adenomyosis is caused by metaplasia of the Müllerian tissue [4]. Ren et al. demonstrated that Belin 1 expression was decreased in eutopic endometrium, and negatively correlated with serum CA125 and pelvic pain. Belin 1, therefore, may play a role in the pathogenesis and progression of adenomyosis [5]. The tissue injury and repair (TIAR) mechanism is activated in response to tissue auto-traumatization. This mechanism leads to a specific physiological process that promoted local production of Bcl-2, and plays an important role in the occurrence and development of adenomyosis [6]. The levels of anti-smooth muscle antibody positive and collagen I positive myofibroblasts are significantly higher in the JZ of women with adenomyosis than in those without [3], as the evidence of tissue microtrauma and activation of the TIAR mechanism.

Hyperestrogenism is suggested to result from increased local aromatization, and decreased local estrogen metabolism in the eutopic and ectopic endometrium of patients with adenomyosis. Hyperestrogenism may promote elevated mechanical strains and stresses that could injure cells in the junctional zone (JZ) [7, 8].

Recently, studies of embryonic pluripotent Müllerian remnants and differentiation of adult stem cells have also been reported [4, 9, 10]. Epithelial-mesenchymal transition (EMT) is biological process involved in embryological development, tissue repair, and cancer cell migration, but the mechanism triggering EMT in adenomyosis has not yet been elucidated [11].

4. Pathology

There are two types of adenomyosis: focal and diffuse. The typical uterus with adenomyosis is enlarged compared to normal ones. The thickening of the uterine

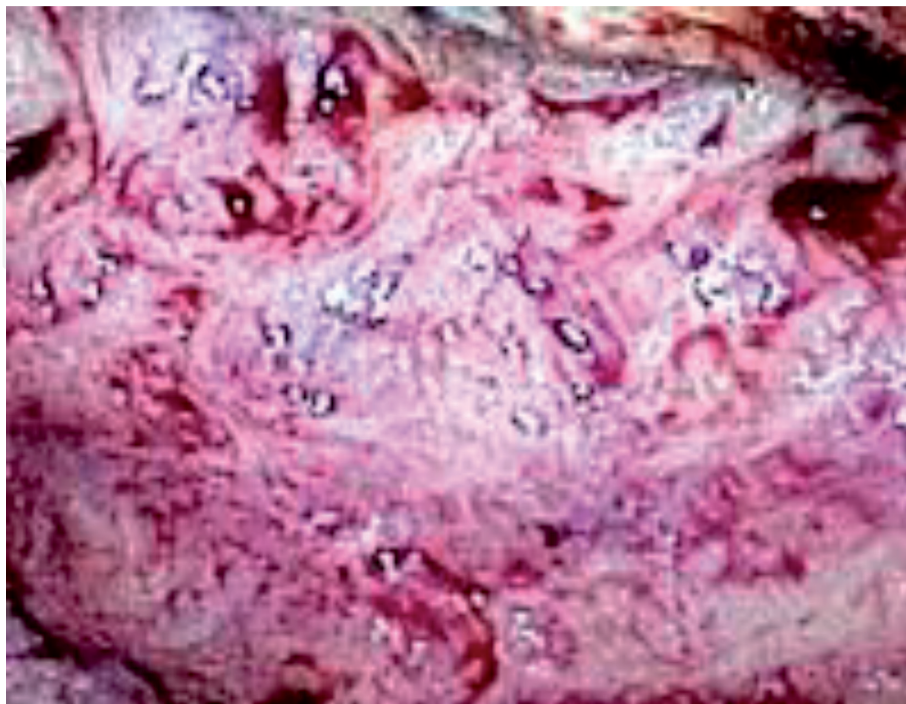


Figure 1.

The thickening of the uterine wall is made up of trabeculated areas, stippled or granular in appearance, with small yellow or darker cystic tissues which contain serous fluid or stale blood.

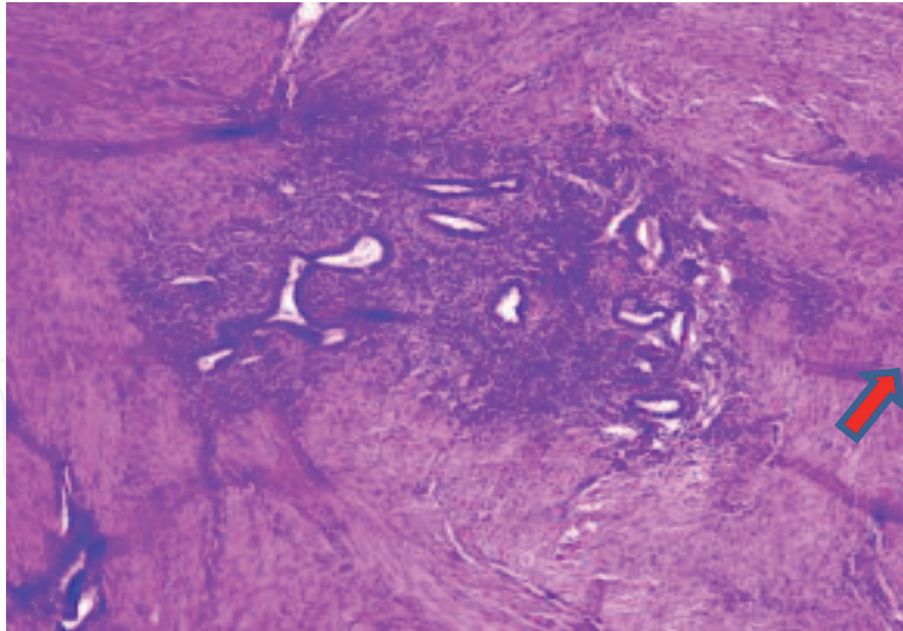


Figure 2.
The presence of endometrial tissue, glands and stroma are within the myometrium.

wall was made up of focal or diffused adenomyosis areas stippled or granular in appearance, with darker cystic lesions that may contain serous fluid or stale hemorrhage (**Figure 1**); in some rare cases, adenomyosis may present as a large chocolate cyst (cystic adenomyosis) [12].

The microscopic feature of adenomyosis is the presence of endometrial tissue including glands and stroma cells within the myometrium (**Figure 2**).

More than 80% of women with adenomyosis have some pathological process in the uterus. Patients have associated leiomyomas [13] and endometriosis [14].

5. Symptoms

Early adenomyosis is asymptomatic, only about one-third of women with adenomyosis have symptoms. Secondary dysmenorrhea and menorrhagia are the common symptoms. The severity of dysmenorrhea correlates with the increasing number of invasions. It is thought to be caused by increased prostaglandin production found in adenomyosis tissues compared with normal myometrium. Approximately 60% of women suffer from abnormal uterine bleeding; menorrhagia and dysmenorrhea are the two major adenomyosis-associated symptoms, and 30% of patients with these symptoms have typical secondary, progressive dysmenorrhea [15]. Menorrhagia with adenomyosis includes excessively heavy or prolonged menstrual bleeding. Some patients' symptoms are not common but may include menstrual irregularities. Some patients with adenomyosis have the history of infertility or abortion.

6. Diagnosis

6.1 Ultrasound sonography

Imaging with transvaginal ultrasound (TVUS) can identify the subtle myometrial changes of adenomyosis, the findings may include: (1) the anterior or posterior myometrial wall appearing thicker, (2) small myometrial hypoechoic cysts, (3) endometrium JZ extending into the myometrium, (4) appearance of

focal adenomyosis as discrete hypoechoic nodules that may be differentiated from leiomyoma by poorly defined margins, and (5) myometrial hyperplasia. Three-dimensional transvaginal ultrasonography can improve the diagnostic accuracy with variable ranges of sensitivity between 70 and 93% and specificity between 86 and 93% for diagnosing adenomyosis by TVUS [16].

6.2 MRI

MRI has been shown to be highly accurate in the diagnosis of adenomyosis.

It can differentiate between adenomyosis and the fibroids. MR imaging may be complimentary (**Figure 3**). The main MRI criterion for diagnosing adenomyosis is by detection of high-intensity tiny myometrial cysts in the inner myometrium, irregularity, and asymmetric junctional zone. MRI can distinguish the subtypes of adenomyosis: diffuse and solid or cystic adenomyoma.

6.3 CA-125

There are studies find the levels of the ovarian epithelial tumor antigen CA-125 patients with adenomyosis might be high. After the therapy, it might decrease.

6.4 Histological examination

The gold standard for the diagnosis of adenomyosis is histological examination. The diagnosis is usually based on histologic findings in surgical specimens after hysterectomy.

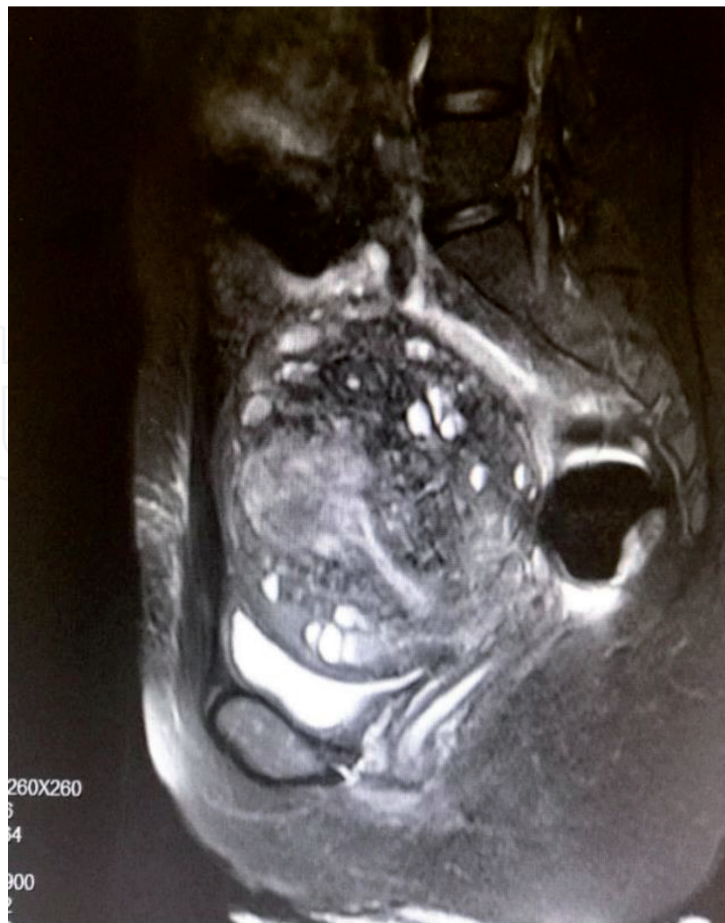

Figure 3.
MRI of adenomyosis.

7. Treatment

The treatment of adenomyosis depends on the patient's age, symptoms, and desire for fertility.

7.1 Medical treatment

7.1.1 GnRHa

Gonadotropin-releasing hormone (GnRH) agonists have been shown to release pain and reduce the adenomyotic lesions' size [17].

GnRHa agonists cause hypoestrogenism, resulting in adverse effects such as hot flashes, vaginal dryness, and bone mineral loss.

7.1.2 Oral dienogest

Dienogest, a novel 19-nortestosterone derivative, is a synthetic oral progestin that is highly selective for progesterone receptors. Dienogest reduces the painful symptoms in women with endometriosis [18].

A recent study of the oral dienogest for premenopausal menorrhagia and pelvic pains in women with uterine adenomyosis indicated that oral dienogest might be a valuable alternative for treatment of premenopausal pelvic pains in women with uterine adenomyosis [19]. Another pilot study presented the results on the efficacy and safety of dienogest in the treatment of symptomatic adenomyosis. Dienogest significantly reduced adenomyosis-associated pelvic pain as well as serum CA-125 and CA 19-9 levels [20].

7.1.3 LNG-IUS

Menorrhagia associated with adenomyosis can be treated with levonorgestrel-releasing IUS that releases levonorgestrel, 20 µg/day. It is placed in uterus within 7 days of menstruation.

7.1.4 Other drugs

Danazol has been the medical therapy for treatment of adenomyosis for several years. Danazol has a direct antiestrogen effect on endometriotic lesions

Nonsteroidal anti-inflammatory drugs (NSAIDs) can relieve mild pain associated with adenomyosis. NSAIDs are the analgesia and anti-inflammatory agents through the pathway of inhibition of PGE2 and COX-2.

Combination oral contraceptives can be used to induce endometrial atrophy and decrease endometrial prostaglandin production to improve dysmenorrhea and menorrhagia.

7.2 Surgical treatment

7.2.1 Hysterectomy

This is the definitive treatment of adenomyosis; however, most of the patients do not accept the surgery of total hysterectomy, with or without ovarian conservation. Patients who have a desire for pregnancy can be treated by focal adenomyosis resection using either laparotomy or laparoscopic surgery.

7.2.2 Ablation of adenomyosis using high-intensity focused ultrasound (HIFU)

High-intensity focused ultrasound (HIFU) ablation, which was initially developed for the treatment of solid tumors, is now successfully implemented in the treatment of uterine fibroids and adenomyosis [21–23]. Several prospective studies have demonstrated ranges of effectivity between 81 and 87% [21–24]. After HIFU therapy, MRI showed the diffuse adenomyosis in **Figure 4(a)** and the nonperfused area of the lesion without damage to the surrounding normal tissue in **Figure 4(b)**. Rarely serious complications including major permanent injuries were observed. Ultrasound-guided HIFU ablation may be a safe and effective noninvasive alternative in the treatment of symptomatic adenomyosis.

7.2.3 Ablation of endometrium with adenomyosis using MEA or NovaSure

Endometrial ablation or resection using hysteroscopy has been used to successfully treat dysmenorrhea and menorrhagia caused by adenomyosis. But it is not acceptable if future pregnancy desired.

7.2.4 Uterine artery embolization (UAE)

It has been used to relieve symptoms for adenomyosis. UAE has favorable outcomes in symptomatic adenomyosis, both short-term and long-term [25]. Due to the limited clinical data, the side effects on ovarian function and future pregnancy after UAE are still not clear.

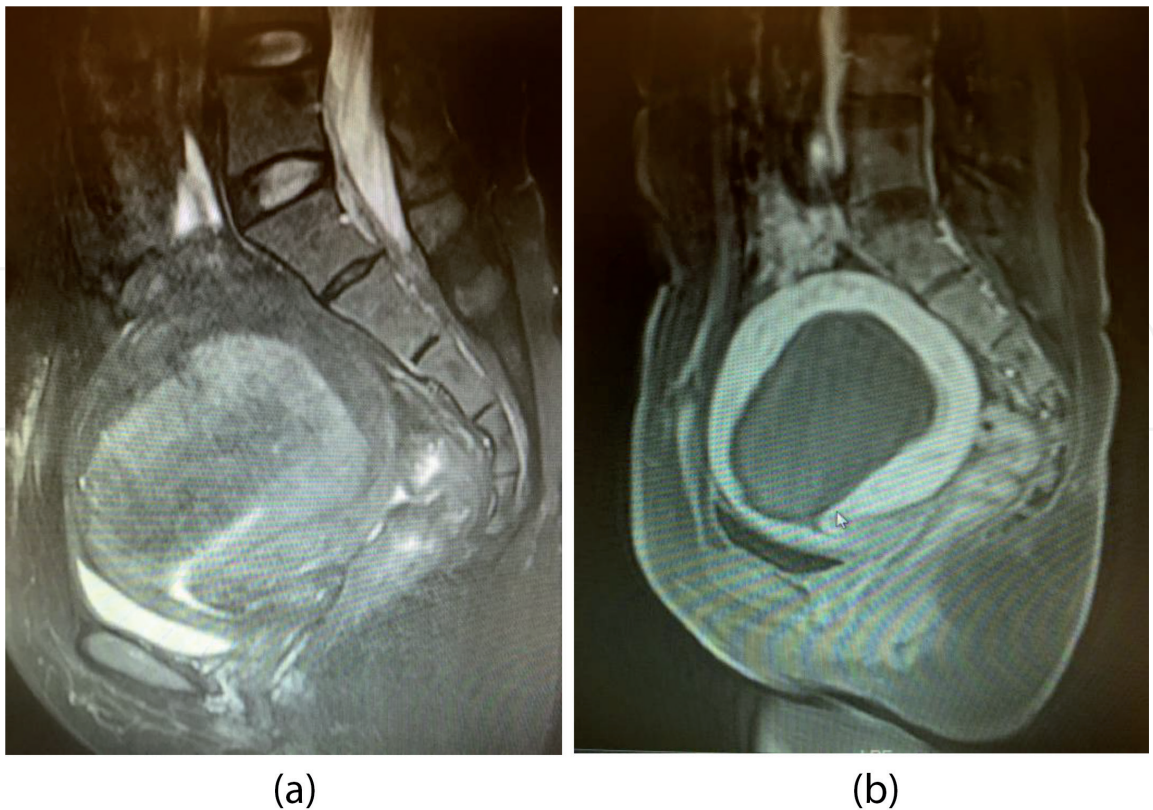


Figure 4. MRI of adenomyosis in (a) showed the diffuse lesion before HIFU, and (b) showed the nonperfused area of the lesion without damage to the surrounding normal tissue after HIFU.

8. Adenomyosis malignant transformation

As with other pathologies of endometriosis, adenomyosis may go through malignant transformation. It is not clear whether some malignancies begin as such or progress from benign disease to malignant. The neoplasia arises coincidentally in continuity with endometriotic implants.

Although adenomyosis is usually benign, it might also be a precursor of malignant disease. As the incidence of adenomyosis malignant transformation is low, and its clinical manifestation is nonspecific, it may only be confirmed by postoperative pathological examination. Malignant neoplasia occurs rarely in the glands and/or stroma; these tumors may be in the form of adenocarcinomas, sarcomas, or carcinosarcomas. Further investigations with large samples may provide additional data on the prognosis of adenomyosis malignant transformation [26]. Some of the risk factors of malignant adenomyosis include age between 40 and 50 years, early menarche, short menstrual cycle, first delivery at young age, fertility, curettage during early trimester of pregnancy, obesity, and history of tamoxifen intake. The expression of both PR and ER was positive in patients with endometrial carcinoma combined with adenomyosis or endometrial carcinoma combined with uterine fibroids, and the expression of p53 and Ki67 was positive in eutopic malignant endometrium and negative in normal ectopic endometrium, which may provide additional pathological data on adenomyosis malignant transformation [26, 27].

9. Conclusion

Adenomyosis is a condition in which the inner lining of the uterus (the endometrium) breaks through the uterine myometrium. Adenomyosis can cause menstrual cramps, lower abdominal pain, and heavy periods, and negatively impact on a woman's quality of life. The condition can be located throughout the entire endometrium or localized in one spot. Nonsteroidal anti-inflammatory drugs (NSAIDs) can relieve mild pain associated with adenomyosis. Symptoms such as heavy or painful periods can be controlled with hormonal therapies. HIFU focused on a small focal region to increase tissue temperature sufficiently, which causes irreparable cell damage in the target adenomyosis lesions at a certain depth. And uterine artery embolization, the minimally invasive procedure, used to block the blood vessels therefore causes adenomyosis to shrink. Endometrial ablation destroys the lining of the uterus and relieves heavy bleeding. The only definitive cure for adenomyosis is a hysterectomy.

Acknowledgements

Thanks to Dr. Courtney Marsh, his book "Endometriosis" is an influential reference in organizing our paper.

IntechOpen

IntechOpen

Author details

Wei Zheng* and Boya Deng
Department of Gynecology, The Second Affiliated Hospital, School of Medicine,
Zhejiang University, Hangzhou, Zhejiang Province, China

*Address all correspondence to: zhengwei@zju.edu.cn

IntechOpen

© 2020 The Author(s). Licensee IntechOpen. This chapter is distributed under the terms of the Creative Commons Attribution License (<http://creativecommons.org/licenses/by/3.0>), which permits unrestricted use, distribution, and reproduction in any medium, provided the original work is properly cited. 

References

- [1] McElin TW, Bird CC. Adenomyosis of the uterus. *Obstetrics and Gynecology Annual*. 1974;**3**(0): 425-441
- [2] Devlieger R, D'Hooghe T, Timmerman D. Uterine adenomyosis in the infertility clinic. *Human Reproduction Update*. 2003;**9**(2): 139-147
- [3] Ibrahim MG et al. Myofibroblasts are evidence of chronic tissue microtrauma at the endometrial-myometrial junctional zone in uteri with adenomyosis. *Reproductive Sciences*. 2017;**24**(10):1410-1418
- [4] Vannuccini S et al. Pathogenesis of adenomyosis: An update on molecular mechanisms. *Reproductive Biomedicine Online*. 2017;**35**(5):592-601
- [5] Ren Y et al. Decreased expression of Beclin 1 in eutopic endometrium of women with adenomyosis. *Archives of Gynecology and Obstetrics*. 2010;**282**(4):401-406
- [6] Li J et al. The expression of Bcl-2 in adenomyosis and its effect on proliferation, migration, and apoptosis of endometrial stromal cells. *Pathology, Research and Practice*. 2019;**215**(8):152477
- [7] Leyendecker G, Wildt L, Mall G. The pathophysiology of endometriosis and adenomyosis: Tissue injury and repair. *Archives of Gynecology and Obstetrics*. 2009;**280**(4):529-538
- [8] Leyendecker G, Wildt L. A new concept of endometriosis and adenomyosis: Tissue injury and repair (TIAR). *Hormone Molecular Biology and Clinical Investigation*. 2011;**5**(2):125-142
- [9] Chan RW, Schwab KE, Gargett CE. Clonogenicity of human endometrial epithelial and stromal cells. *Biology of Reproduction*. 2004;**70**(6):1738-1750
- [10] Gargett CE, Schwab KE, Deane JA. Endometrial stem/progenitor cells: The first 10 years. *Human Reproduction Update*. 2016;**22**(2):137-163
- [11] Chen YJ et al. Oestrogen-induced epithelial-mesenchymal transition of endometrial epithelial cells contributes to the development of adenomyosis. *The Journal of Pathology*. 2010;**222**(3):261-270
- [12] Chapron C et al. Relationship between the magnetic resonance imaging appearance of adenomyosis and endometriosis phenotypes. *Human Reproduction*. 2017;**32**(7):1393-1401
- [13] Brucker SY et al. Clinical characteristics indicating adenomyosis coexisting with leiomyomas: A retrospective, questionnaire-based study. *Fertility and Sterility*. 2014;**101**(1):237-241.e1
- [14] Di Donato N et al. Prevalence of adenomyosis in women undergoing surgery for endometriosis. *European Journal of Obstetrics, Gynecology, and Reproductive Biology*. 2014;**181**:289-293
- [15] Garcia L, Isaacson K. Adenomyosis: Review of the literature. *Journal of Minimally Invasive Gynecology*. 2011;**18**(4):428-437
- [16] Rasmussen CK, Hansen ES, Dueholm M. Inter-rater agreement in the diagnosis of adenomyosis by 2- and 3-dimensional transvaginal ultrasonography. *Journal of Ultrasound in Medicine*. 2019;**38**(3):657-666
- [17] Nelson JR, Corson SL. Long-term management of adenomyosis with a gonadotropin-releasing hormone agonist: A case report. *Fertility and Sterility*. 1993;**59**(2):441-443

- [18] Gordts S, Grimbizis G, Campo R. Symptoms and classification of uterine adenomyosis, including the place of hysteroscopy in diagnosis. *Fertility and Sterility*. 2018;**109**(3):380-388.e1
- [19] Harada T et al. Dienogest is as effective as intranasal buserelin acetate for the relief of pain symptoms associated with endometriosis--a randomized, double-blind, multicenter, controlled trial. *Fertility and Sterility*. 2009;**91**(3):675-681
- [20] Fawzy M, Mesbah Y. Comparison of dienogest versus triptorelin acetate in premenopausal women with adenomyosis: A prospective clinical trial. *Archives of Gynecology and Obstetrics*. 2015;**292**(6):1267-1271
- [21] Liu X et al. Clinical predictors of long-term success in ultrasound-guided high-intensity focused ultrasound ablation treatment for adenomyosis: A retrospective study. *Medicine*. 2016;**95**(3):e2443
- [22] Fan TY et al. Feasibility of MRI-guided high intensity focused ultrasound treatment for adenomyosis. *European Journal of Radiology*. 2012;**81**(11):3624-3630
- [23] Zhou M et al. Ultrasound-guided high-intensity focused ultrasound ablation for adenomyosis: The clinical experience of a single center. *Fertility and Sterility*. 2011;**95**(3):900-905
- [24] Guo Q et al. High intensity focused ultrasound treatment of adenomyosis: A comparative study. *International Journal of Hyperthermia*. 2018;**35**(1):505-509
- [25] de Bruijn AM et al. Uterine artery embolization for the treatment of adenomyosis: A systematic review and meta-analysis. *Journal of Vascular and Interventional Radiology*. 2017;**28**(12):1629-1642.e1
- [26] Mao X, Zheng W, Mao W. Malignant changes in adenomyosis in patients with endometrial adenocarcinoma: A case series. *Medicine*. 2017;**96**(43):e8336
- [27] Sasaki T et al. Endometrioid adenocarcinoma arising from adenomyosis: Report and immunohistochemical analysis of an unusual case. *Pathology International*. 2001;**51**(4):308-313