

We are IntechOpen, the world's leading publisher of Open Access books Built by scientists, for scientists

6,900

Open access books available

186,000

International authors and editors

200M

Downloads

Our authors are among the

154

Countries delivered to

TOP 1%

most cited scientists

12.2%

Contributors from top 500 universities



WEB OF SCIENCE™

Selection of our books indexed in the Book Citation Index
in Web of Science™ Core Collection (BKCI)

Interested in publishing with us?
Contact book.department@intechopen.com

Numbers displayed above are based on latest data collected.
For more information visit www.intechopen.com



Hemorheological Evaluation and Cytokine Production in Dogs Naturally Infected with Anaplasmataceae

*Saulo Pereira Cardoso, Giane Regina Paludo,
José Nivaldo da Silva, Adenilda Honório-França
and Eduardo Luzia França*

Abstract

In this chapter, we describe that naturally infected dogs with Anaplasmataceae show altered rheological parameters. Also, we have showed that lower viscosity correlated with the lower erythrocyte number and release of IFN- γ . The rheometry of the fresh blood samples was measured by using the Modular Compact Rheometer—MCR 102 (Anton Paar® GmbH, Ostfildern, Germany), and the graphs were obtained using Rheoplus software. Blood count data were obtained by analysis in a private laboratory. Diagnostic confirmation was obtained by molecular PCR technique that was used to determine the groups of not infected and infected by Anaplasmataceae. Serum cytokines were dosed by flow cytometry (FACScalibur BD®) using BD® Biosciences Cytometric Bead Array (CBA) Human Th1/Th2/Th17 Cytokine kits. The results showed a correlation between blood viscosity ($p < 0.05$, $r = 0.73$) and shear rate ($p < 0.05$; $r = -0.676$) with IFN- γ in the group of infected dogs that presented anemia, as well as correlations of shear rate with erythrocytes ($p < 0.05$; $r = -0.88$). Thus, IFN- γ appears to play an important role in the immunomodulation of the rheological behavior of naturally infected dogs to Anaplasmataceae. The alterations in cytokines profile and their relationship with blood viscosity and hematological parameters was related in this study the first time of dogs naturally infected with Anaplasmataceae.

Keywords: Anaplasmataceae, rheology, immunomodulation, cytokines, dogs

1. Introduction

In the environment, animals can naturally suffer from co-infections with more than one pathogen, primarily high-incidence diseases such as invertebrate vector-borne hemoparasites, which multiply in short cycles. The diseases caused by microorganisms of the Anaplasmataceae family, transmitted by the *Rhipicephalus sanguineus* ectoparasite vector, such as *Ehrlichia canis* and *Anaplasma platys* [1] are highly prevalent in Brazil and worldwide [2, 3].

E. canis is a causative bacterium of Canine Monocytic Ehrlichiosis (CME) that infects mononuclear cells, mainly found in monocytes, where they develop and replicate using the cellular apparatus, and subsequently spread and infect new cells [4]. The *A. platys* only infects platelets leading to transient thrombocytopenia [5] without developing severe dog disease, known as Canine Cyclic Thrombocytopenia [6].

Infectious diseases may alter the hematological parameters of the affected individuals and, consequently, there is alteration of hemorheological behavior [7–9]. In addition, immunological factors are also responsible for the change in blood viscosity. On the other hand, cytokines may play an important role in the immunomodulation of hemorheological behavior. Cytokine IL-17 has immunomodulatory effect on blood viscosity of human patients infected with *Plasmodium vivax*, such response may be important for maintaining erythrocyte integrity [7].

The therapeutic use of cytokines may help in the treatment of individuals with changes in blood viscosity [7]. In addition, it can modulate Th1 type responses [10, 11].

Studies on the hemorheological behavior of dogs with infectious diseases, as well as the immunomodulation of this process help to understand the immunophysio-pathological mechanisms [7, 9].

This chapter deals with cytokines involved in the immunomodulation of hematological and rheological parameters of the blood of dogs naturally infected by bacteria from Anaplasmataceae family.

1.1 Etiology, occurrence, and distribution

The microorganisms of the Anaplasmataceae family belong to the order Alphaproteobacteria and to the class Rickettsiales. They are gram negative, intracellular-obligatory [12]. They have coccoid or rod shapes, varying in size from 0.2 to 0.5 micrometers (μm) in diameter and 0.8–2.0 μm in length. They are found forming colonies within intracytoplasmic vacuoles. These colonies are surrounded by a membrane that delimits them, being this colony-vacuole set called morula [13].

The Rickettsiales class microorganisms have an infective form, the dense nucleus cell. After infection, it develops the vegetative form, the reticulated cell, which multiplies by binary fission. In the process of infection, they are phagocytized by the host cell and remain inside vacuoles or phagosomes, where fusion with lysosomes does not occur, and develop there and form the morula. After vegetative forms mature, they can become infectious forms and be released from the cytoplasm by exocytosis or lysis of host cells, thereby infecting new cells [4].

The Anaplasmataceae family comprises the following species reported as infectious agents of dogs: *E. canis*, *E. ewingii*, *E. chaffeensis*, *A. phagocytophilum*, *A. platys*, and *Nanophyetus helminthoeca* [14, 15]. There are also reports of *E. risticii* infection [16]. However, to date in the Brazilian territory, the clinically important species for pets that cause hematological disorders in dogs are *E. canis* and *A. platys* [17, 18]. *E. canis* has mononuclear cell tropism, mainly monocytes, whereas *A. platys* infects platelets [19]. *E. ewingii* infections in dogs can also cause hematological changes and other signs of hemoparasitosis [2].

Prevalence studies of Anaplasmataceae show that these infectious agents are widely distributed in tropical and subtropical countries [20]. Dogs with suspected CME have high rates of positivity for Anaplasmataceae infections [1, 21], whereas in domestic cats, this rate is low [22].

Most studies involving the Anaplasmataceae family aim not only to identify the taxonomic family of agents, but also to try to identify genus and species. Thus, the epidemiology of *E. canis* and *A. platys*, which are the main species of this family that affect dogs in Brazil, will be presented below.

1.1.1 *Ehrlichia canis*

In the year 1935, researchers first detected a rickettsial microorganism parasitizing dog mononuclear cells [23]. Only in 1945 did Mashkovsky reclassify this agent as *E. canis* [24]. However, it has become known worldwide as a causative agent of CME in an outbreak of infection with a high mortality rate in German shepherd dogs used by the US military during the Vietnam War [25]. In Brazil, it had its first report in dogs in the 1970s [26].

Dogs infected with *E. canis* develop CME, a worldwide disease found in different continents: South America, Central America, Europe, Asia, Oceania [27], North America [28], and Africa [29]. They are in the tropical and subtropical regions of these continents where there is the ectoparasite vector *R. sanguineus* and the highest prevalence rates of CME [27, 30].

The genus *Ehrlichia* is widely distributed in Brazil [17], being positive for 20% of dogs seen in the country [31]. In 1996, in Venezuela, the first report of chronic *E. canis* infection in humans occurred [32]. There are also reports in humans in the United States causing a chronic disease that can be fatal [33, 34]. Clinical signs are variables such as fever, weakness, muscle and bone pain, headache, nausea, vomiting, abdominal pain, arthralgia, and rash. Hematological parameters present anemia, thrombocytopenia, and leukopenia [32]. Thus, *E. canis* infection can also be treated as a public health issue and not just veterinary [27, 35].

1.1.2 *Anaplasma platys*

A. platys is the causative agent of Canine Cyclic Thrombocytopenia (CRT), which colonizes and replicates in dog platelets. Its first description was in the 1970s, Florida-USA, as a *Rickettsia*-like organism capable of infecting dog platelets [6]. In addition to reporting the visualization of this agent in blood smears, Harvey et al. [6] reproduced the infection experimentally in other dogs. No animal showed macroscopic alteration, the only alteration being a transient thrombocytopenia, without causing evident hemorrhages in the infected ones [6].

In different countries in Europe, the prevalence of this agent can range from 0.4 to 70.5% according to molecular research using blood samples from dogs, age, animal breed or gender does not appear to influence the development of CRT [36, 37].

In Brazil, the prevalence of *A. platys* infection in dogs varies in different regions, being higher in the northeast [1, 2, 22, 38–40].

Molecular studies have also detected *A. platys* in humans in the United States and Venezuela, indicating potential risk of zoonosis [41, 42].

1.1.3 Coinfecção por *E. canis* e *A. platys*

E. canis and *A. platys* coinfection using molecular detection in dogs are reported in Brazil [43], with prevalence ranging from 5.5 to 53.3% [1, 44, 45].

In other countries, co-infections with these bacteria also occur in dogs. In the USA, they found a 5% prevalence in dogs with a history of tick exposure [46]. This same rate was found by Yabsley et al. [47, 48] in blood samples from dogs from Granada, Spain.

1.2 Transmission

The microorganisms of the Anaplasmataceae family are transmitted to their hosts mainly by vectors that inoculate them in susceptible animals. The increase in the number of cases of infections in dogs by these bacteria in a given region is linked

to the presence of the transmitting vector in the environment and its behavior of feeding on mammalian blood, with a preference for canids. Infection occurs at the moment when the tick *R. sanguineus* performs hematophagy and ends up injecting saliva contaminated with Anaplasmataceae at the bite site [47, 48].

Both larvae and nymphs, as well as adult forms of the *R. sanguineus* tick infected by *E. canis*, are capable of transmitting it to the host [47, 48]. There is no transovarian transmission from adult ticks to their larval forms in the reproduction process of *R. sanguineus* [27]. Ticks only become infected when they feed on infected animals that are in the bacteremia phase of the disease [49]. Although vector transmission of *E. canis* is the main mode of infection, it can also occur in cases of blood transfusion from an infected to an uninfected host [50, 51].

Regarding *A. platys* transmission, it is not clear how it occurs. It is suspected to be similar to *E. canis* by ticks, but the process has not yet been confirmed experimentally [52, 53]. Some more recent studies point to possible vertical transmission from mother to pups, but the transmission process has not been confirmed [53, 54].

The *R. sanguineus* ectoparasite (Acari: Ixodida), known as the brown dog tick, is the main vector of *E. canis* [55]. It is also believed to serve as a vector for *A. platys*, although the infection has not been reproduced in the laboratory so far. One of the main evidence of this possibility is the discovery of *A. platys* DNA in female *R. sanguineus* using molecular technique [44, 56]. This tick has a cosmopolitan distribution in tropical regions and, taking advantage of global warming, proliferates in regions of temperate climate, but under conditions of shelter that provides its development [47, 48].

Once infected with *E. canis*, this vector becomes a source of lifelong infection. Thus, a larva may remain infected even after undergoing changes in its life cycle, maintaining trans-state transmission [57]. *E. canis* colonizes oral salivary gland cells and is also found in vector cells, called hemocytes, and tick intestinal cells [58].

Other ticks like *Ixodes* spp. and *Dermacentor* spp. are also capable of transmitting the Anaplasmataceae family pathogens to susceptible hosts at the time of the bite [59, 60].

1.3 Immunological response and mechanisms of immune evasion of microorganisms from Anaplasmataceae family

Host resistance to the *Anaplasma* genus is linked to IFN- γ production [61]. This protective effect is potentiated by TNF- α [62]. On the other hand, there is a description that TNF- α may favor the aggravation of the clinical condition of dogs, as observed in cases of distemper [63].

The process of immune response to members of the Anaplasmataceae family can lead to tissue damage in the liver of the infected host regardless of the bacterial load in their body, due to a simple induction of proinflammatory mechanisms that induce a cellular response that develops such damage. These lesions are generally more severe than those directly induced by the infectious agent itself, as observed in a study with experimental *A. phagocytophilum* infection in mice [64].

Ehrlichia-infected monocytes have a slower response to LPS when compared to uninfected monocytes, as this pathogen inhibits activation of the nuclear factor kappa beta (NF- κ B) transcription factor. This infection also disrupts toll-like receptor expression (TLR 2 and 4) and inhibits other signaling pathways that rely on monocyte activation receptors [65]. In addition, infection induces inhibition of gene transcription for IL-12, IL-15, and IL-18 production [66].

In persistent *Ehrlichia* infections, it has been experimentally demonstrated in mice that the host maintains its survival when there is increased IFN- γ production

by CD4 + and CD8 + T lymphocytes, low concentration of TNF- α and antibody production to *Ehrlichia*, mainly IgG2 [67].

The survival of the genus *Ehrlichia* in monocytes depends on the mechanisms that this bacterium uses to block the fusion of phagosomes with lysosomes, inhibiting cell apoptosis to utilize its nutrients and energy longer [68].

Susceptibility to the development of CME has immunomodulatory mechanisms involved in the process. Experimental infections in mice with *E. muris*, intracellular mononuclear leukocyte parasite demonstrated high concentration CD8 + T production of TNF- α as well as systemic inflammatory response mediated by this cytokine and inhibition of Th1 profile T CD4 proliferation [67].

Regarding *E. canis*, NK cells play their role in the immune response, but are not primordial in the host resistance process [69]. Although some animals with CME have bone marrow cell depletion in the chronic phase, subclinical neutropenia and transient lymphopenia in the acute phase, it was found in an experimental study that in the acute and subacute phases of the disease, *E. canis* was not able to induce immunosuppression in young dogs, up to 1 year old on average [69].

One study showed that dogs experimentally infected with *E. canis* had elevated TNF- α production by splenocytes and leukocytes during acute CME, followed by high levels of IL-10 for both cell lines and, finally, only the leukocytes showed IFN- γ production in small scale [70]. TNF- α production at high levels in the experimental infection with *E. canis* was also verified by Rikihisa and Tajima [5]. Since in naturally infected dogs, Lima et al. [71] found elevated levels of TNF- α and IL-10, but the analysis found no difference between the means of groups infected and uninfected for both cytokines.

Studies report that specific immune response to *A. platys* is innovative. Research involving *Anaplasma* genus and its immune response mostly describe the species *A. phagocytophilum*, which infects granulocytes of different animal species [72], or *A. marginale* which infect red blood cells and bovine monocytes [73].

The control of infection by *A. phagocytophilum* in humans and other animals, including the dog, is dependent on the IFN- γ production and macrophage activation, which leads to the control of a recent bacteremia [74]. This occurs in an initial immune response, with the role of NK cells to produce IFN- γ , but that is not important for eliminating the infectious agent.

Contrary to expectation, the immune response to *A. phagocytophilum* is not dependent Th1 cytokines such as IL-12 and IFN- γ , but CD4 + effector T cells are also strictly necessary for the eradication of the pathogen [75].

A. marginale infections induce CD4 T cell proliferation as well as a humoral response with high levels of IgG1 and IgG2. This bacterium has great ability to generate variant forms by converting gene segments, which allows an escape from the immune response [76].

Intracellular organisms have different mechanisms of escape from the immune response to maintain their survival and multiply. Some may induce non-fusion of phagosome with lysosome, while others escape from phagosome to cytosol. By using their structural apparatus to disrupt the phagosome environment and inhibit its fusion to lysosomes, these pathogens gain time to take on a more resistant form to the acid and proteolytic environment and perpetuate within the infected cell [77].

In many cases, these infectious agents may induce a Th2-type cellular response. IL-10 secretion by Th2 inhibits Th1 response and macrophage activation by the classical pathway [78]. Intracellular organisms may also inhibit IL-12 production by infected macrophages [79].

1.4 Pathophysiology of CME and CRT and clinical signs

E. canis uses different strategies from other traditional intracellular bacteria in the process of infection because is a bacterium with deficiency of structural membrane components such as peptidoglycan and LPS. Its genome has genes that encode proteins responsible for evasion to the immune system and for playing an important role in parasite-host interaction. Surface proteins present in the genus *Ehrlichia* with repeats of serine and threonine components are responsible for membrane attack and host cell entry [80]. Twelve tandem repeating proteins, three specific for *E. canis*, were identified, demonstrating a variability of membrane protein repertoire, which facilitates escape to the immune system [81].

The manifestations and clinical signs in positive dogs can be variable and are observed in the different phases of the CME. The acute phase occurs after an incubation period ranging from 8 to 20 days [82]. The subclinical course of infection, which occurs when no clinical signs of the disease are observed, may develop after an acute course of course in dogs that have not cleared the agent. And finally, there is the chronic course phase with signs of severe disease [83].

Significant low platelet count in CME is the main sign observed in the hematological parameters of dogs [84]. Such a fall is linked to different factors: excessive platelet consumption due to endothelial lesions, destruction by immunological action, and an increased splenic sequestration of these platelets [85]. It has been reported that there is a platelet migration inhibiting factor that favors splenic sequestration [86].

In CRT, the mechanism of platelet reduction occurs by phagocytosis of these blood components that have been damaged by the bacteria or destroyed in an immunomediated manner [6]. In addition, it has been shown that *A. platys* infection can occur in platelet-generating myeloid precursors, such as promegakaryocytes and megakaryocytes [87].

1.4.1 Fase aguda da CME

During the acute phase of CME, there is an elevation of inflammatory cytokines linked to the immune response, such as TNF- α , IL-10, and IFN- γ [70]. However, Lima et al. [71] reported in their work that TNF- α and IL-10 are not associated with early-stage clinical signs of CME. Some dogs may present in the acute phase thrombocytopenia and anemia; however, thrombocytopenia is also detected in dogs in the subclinical phase when the animal is not treated [84], and leukopenia may also occur [88]. In the acute phase, there are the appearances of several nonspecific clinical signs such as anorexia, fever, weight loss, lymphadenomegaly, splenomegaly, and apathy, also occurring vasculitis [83].

In the study by Sousa et al. [89], dogs with *E. canis* infection showed nonspecific clinical signs, such as apathy, anorexia, fever, and mucosal pallor. They also presented ophthalmic disorders, tendencies to hemorrhage and splenomegaly. Other studies reported diarrhea, emesis, hematemesis, abdominal pain, dilation of the abdomen, difficulty in walking [90].

Ophthalmologic lesions can occur at any stage of CME and include anterior uveitis, retinal or subretinal hemorrhage with detachment, chorioretinitis, and blindness [91].

Clinical and laboratory findings consist of an increase or decrease in the number of leukocytes (neutrophils and lymphocytes) and platelets and predominantly anemia [89]. It also presents anemia as the most frequent hematological disorder, followed by thrombocytopenia [90].

1.4.2 Subclinical phase of CME

The chronic course can last up to 5 years, in a subclinical state, until the serious disease develops. In the subclinical phase, there is thrombocytopenia [88], high antibody production, mainly due to hypergammaglobulinemia, but with hypoalbuminemia [88, 92].

1.4.3 Chronic phase of CME

In the severe phase, weight loss, wasting, lymphadenopathy, fevers, hemorrhages, non-regenerative anemia, thrombocytopenia, spinal cord pancytopenia, and death are observed [88, 93, 94]. Hyperglobulinemia is also observed and may favor the development of blood hyperviscosity [95]. Animals die due to bleeding or septicemia caused by *E. canis* [88].

1.4.4 Acute phase of TRC

TRC caused by *A. platys* has an acute and cyclic phase following an incubation period of 1–2 weeks, with a parasitemia occurring every 10 to 14 days causing a transient thrombocytopenia accompanied by fever [96]. One study has shown that experimental *A. platys* infection has developed lymph node enlargement in dogs [96]. However, many dogs present asymptomatic TRC [97].

In Europe and the Middle East, there are descriptions of *A. platys* strains that are more virulent and cause disease with clinical signs similar to dogs with CME [98, 99]. Thus, dogs with infection with virulent *A. platys* strains may show clinical signs of abdominal pain, splenomegaly, high fever, thrombocytopenia, hypoproteinemia, large platelets, monocytosis, and low hematocrit [88, 100]. Another study found dogs naturally infected with *A. platys* with acute clinical signs of anorexia, depression, weight loss, transient epistaxis, pale mucosae, severe thrombocytopenia, anemia, leukopenia, and hyperproteinemia [98].

1.4.5 Chronic phase of TRC

In Brazil, TRC does not develop severe clinical signs in dogs, only a decrease in platelet counts in general. Dogs that have *A. platys* infection have cyclic thrombocytopenia, but do not have bleeding episodes as in dogs with CME [101].

The chronic phase demonstrates an adaptation of the infected animal's organism to infection. At this stage, infected dogs have a cyclic period of low parasitemia accompanied by moderate thrombocytopenia [102].

2. Diagnostic methods

2.1 Parasitological diagnosis

Pathogen identification can be done using blood smears. In the acute phase of the disease, *E. canis* morulae can be observed inside mononuclear cells or, in the case of *A. platys*, on platelets. However, these agents may not be found in many of these cases, as they are more commonly found in dogs sick in the febrile phase [103].

Direct visualization of the agent in mononuclear cells, especially lymphocytes, seen in blood smears is known to be a definitive diagnosis of CME, as visualization

of morulae with correct morphological characterization is considered a pathognomonic sign of the disease [103]. However, there are other agents that infect mononuclear cells, and differential diagnosis should be made correctly in order to avoid false-negative diagnosis [104].

2.2 Serologic diagnosis

For the detection of CME, there are several diagnostic methods. At the veterinary clinic, a rapid test with only one drop of blood is routinely performed based on the serum evaluation of anti-*Ehrlichia* antibodies [88]. Similarly, there are kits for detection of *A. platys* and *A. phagocytophilum* [105].

Indirect immunofluorescence a serological test used more in research, marks the specific target with antibodies to be viewed and can be used as a definitive diagnosis [55, 106].

2.3 Culture and isolation

Members of the Rickettsiales family, such as *Ehrlichia*, can be cultured in cultured cells under controlled conditions, but proliferation time is prolonged. This, in addition to the fact that many techniques depend on purification of the agent relative to the host cell component of the culture, makes the process even more difficult and time consuming [107].

2.4 Molecular diagnosis

The definitive diagnosis can also be performed by molecular examinations by detecting genetic material from microorganisms in the samples [108, 109] and specificity [110]. Over the years, it has become an increasingly modern and improved technique for pathogen identification and safe against possible contamination, such as quantitative PCR (qPCR) [111].

2.5 Clinical and laboratory diagnosis

The presumptive clinical diagnosis of CME made by the professional in the veterinary office can be performed by observing clinical signs; however, there is a high chance of giving a different result than the real one, since CME has a multisystemic character and nonspecific clinical signs, thus requiring other tools [35].

In clinical and laboratory analyzes, thrombocytopenia presented by dogs with clinical signs suggestive of CME helps to rule out other diseases, being this parameter used in routine veterinary clinics as a strong suspicion of being positive for *E. canis* [112]. Other signs such as anemia, leukocytosis, and leukopenia are observed in dogs with CME, which helps in the diagnosis [89]. Observation of isolated thrombocytopenia without other clinical signs are suggestive of CRT [6].

2.6 Differential diagnosis

The clinical and laboratory signs presented observed in CME and CRT can be observed in other diseases caused by other infectious agents, especially those transmitted by ticks. Infections such as hepatozoonosis, babesiosis, and distemper may present similar clinical signs and should be considered in the differential diagnosis [113]. Another disease to be considered is canine visceral leishmaniasis (CVL) in cases of thrombocytopenia, anemia, medular aplasia, and hemorrhages [114], especially in regions endemic for CVL [113].

2.7 Hemorheological diagnosis

Animals infected with hematozoa, including Anaplasmatidae, may present changes in hematological parameters [89]. However, hematozoa can also lead to alteration of the rheological behavior of the blood, as a work that demonstrated alteration of blood viscosity of humans infected with *Plasmodium* spp. [7], and another that demonstrated changes in blood viscosity of dogs infected with *Leishmania* spp. [9].

Rheometry is an auxiliary tool that allows the measurement of the fluid viscosity curve, as well as the blood, and can be used to monitor these altered parameters in dogs with hematological and rheological disorders, thus serving as an ally in the therapeutic monitoring of sick dogs. Such a tool has been used experimentally to measure blood viscosity in both *Plasmodium* spp. infected humans [7], as in dogs infected with *Leishmania* spp. [9].

2.8 Rheology

Rheometric blood analysis or hemoreometry is a technique for measuring blood viscosity that helps in understanding the pathogenesis of diseases affecting the blood [9]. Blood functions as a viscous fluid, with different viscosities depending on the amount of cells, platelets, and other blood solutes [114, 115], so if a disease alters the amount of cells, the deformability erythrocyte or serum components, the viscosity also changes.

Rheometry allows the measurement of blood viscosity using the rheometer, a device that measures the ability of a liquid to flow based on its resistance to dissipation when pressure is applied to it [116]. To understand how immunomodulation of blood rheological behavior occurs in metabolic or infectious diseases, the change in blood viscosity can be compared between sick and healthy, and these data correlate with cytokine profile for investigation of the immunopathological process, as demonstrated by França et al. [8] and Scherer et al. [7].

This branch of science allows an understanding of how hemorheological behavior is influenced by cellular components and blood plasma on blood viscosity, peripheral resistance, circulating volume, and blood pressure. The capacity of erythrocyte deformation is influenced by blood pressure, and this phenomenon is important for maintaining macro and micro blood flow as well as microcirculation [114]. Blood viscosity is also influenced by blood cell count. Patients with anemia demonstrate decreased blood viscosity [117].

The increased amount of leukocytes and platelets disturbs the normal flow of erythrocytes, especially in microcirculation. Another phenomenon that impairs this flow is when the erythrocytes lose their capacity for deformation, or when the pressure of the blood vessels is increased, making it difficult to pass, such as diabetes mellitus, changes in the physical characteristics of erythrocytes are observed [114].

Viscosity and blood flow become compromised to cellular and plasma changes that occur in various diseases. Metabolic diseases such as diabetes mellitus lead to erythrocyte changes [118], in addition to other factors such as increased serum osmolarity [119] and endothelial lesions lead to blood hyperviscosity syndrome [120]. In infectious diseases, such as those caused by obligate intracellular parasites, increased blood viscosity occurs, as observed in dogs with Canine Visceral Leishmaniasis [9] and in humans with malaria [7].

This technique has been used in research to help understand diseases by blood parasites such as *Plasmodium* spp., causative agent of malaria. Infected individuals showed elevated blood viscosity and high levels of IFN- γ and IL-17, as well as low TGF- β concentration compared to uninfected ones [7]. In addition to infectious

diseases, metabolic diseases such as diabetes melittus lead to changes in blood viscosity [8]. Thus, blood viscosity may also be influenced by the action of substances present in serum such as cytokines.

Rheometry, considered as a low-cost auxiliary technique, can be used as a tool for monitoring the hematological condition and haemorrheological behavior of animals infected with infectious diseases, as shown in a study that evaluated dogs naturally infected with *Leishmania* sp. [9].

3. Metodology aspects, results, and discussion

The procedures were previously approved by the Animal Use Ethics Committee-CEUA/UFMT, Brazil, and collection of clinical samples was authorized by the dog owners by signing the informed consent form.

Blood samples were collected from 72 dogs, regardless of males and females, of different ages and breeds, during the 19 months in Barra do Garças—MT (52.2599 15° 53' 35 South, 52° 15' 36" Oeste), Midwest region of Brazil to analyze the rhreometry parameters and cytokines concentrations. Diagnostic confirmation was obtained by molecular Polymerase Chain Reaction (PCR) technique that was used to determine the groups of not infected and infected by Anaplasmataceae. The rheometry of the fresh blood samples was measured by using the Modular Compact Rheometer—MCR 102 (Anton Paar® GmbH, Ostfildern, Germany), and the graphs were obtained using Rheoplus software. Blood count data were obtained by analysis in a private laboratory. Serum cytokines were dosed by flow cytometry (FACScalibur BD®) using BD® Biosciences Cytometric Bead Array (CBA) kits.

For the statistical analysis of the concentration of cytokines, rheological and hematological parameters used the Student t test. For the correlation analyses, the Pearson correlation test was used. Data were expressed as mean ± standard error. Values less than 0.05 ($p < 0.05$) were considered significant.

Thus, serological screening was initially performed to check for natural infection using the SNAP 4DX Plus of IDEXX ELISA test for detection of both *Ehrlichia* spp. and *Anaplasma* spp. High rates of infection (75%) with Anaplasmataceae were observed (**Table 1**). Interestingly, studies on dogs with suspected infection also had high rates of infection with these bacteria [21].

Seroprevalence of 51% (29/57) for *Ehrlichia* spp. was higher in dogs evaluated when compared with other studies [1, 21, 55]. In the literature, there are data on seroprevalence of *A. platys* in Brazil and worldwide [2, 3]. In this work, the prevalence of *Anaplasma* spp. was 25%, whereas in other studies in Brazil and Asia were showed lower prevalence [2, 3].

Diagnostic confirmation was performed by PCR molecular examination using the primer oligonucleotides shown in **Table 2**. The results showed a prevalence of 52% of Anaplasmataceae infection, which is slightly lower compared to other similar work also developed in Mato Grosso [1]. Such high rates are also found in a

	Negative	Anaplasmataceae	<i>Ehrlichia</i> spp.	<i>Anaplasma</i> spp.	<i>Ehrlichia</i> + <i>Anaplasma</i>	Total
Number	14	43	29	14	12	57
Prevalence (%)	25	75	51	25	21	

Table 1.
Detection of specific antibody for Anaplasmataceae family (*Ehrlichia* spp. and *Anaplasma* spp.) using SNAP 4DX Plus of IDEXX ELISA test in dogs from the city of Barra do Garças—MT.

Identification	Sequence 5'-3'	Author	Primer
Anaplasmataceae	GGTACCYACAGAAGAAGTCC	Inokuma et al. [121]	EHR16sd
	TAGCACTCATCGTTTACAGC	Inokuma et al. [121]	EHR16sr
<i>E. canis</i>	CAATTATTTATAGCCTCTGGCTATAGGA	Murphy et al. [122]	ECAN5
	TATAGGTACCGTCATTATCTTCCCTAT	Murphy et al. [122]	HE3
<i>A. platys</i>	GATTTTTGTCTAGCTTGCTATG	Lima et al. [22]	PLATYS
	TAGCACTCATCGTTTACAGC	Lima et al. [22]	EHR16sr

Table 2.
Primers used in the PCR tests of the present study.

seroprevalence study in northeastern Brazil that shows to be greater than 50% in the Alagoas state [17].

In contrast, in the amplification of the *E. canis* and *A. platys* DNA gene16S, there were prevalences of 28 and 32%, respectively. Regarding *E. canis*, other authors found a prevalence of 38.4–59% [1, 21]. Studies with *A. platys* using molecular techniques in Mato Grosso revealed 26.2% [1]. However, higher prevalence of infection has been reported in other regions of Brazil [11, 123].

Coinfection by *A. platys* and *E. canis* are also commonly found in dogs in areas containing the *R. sanguineus* vector [34]. In the animals evaluated in this study, it was observed a prevalence of 20% of coinfection (**Table 3**).

Table 4 presents the results of the mean values of erythrogram, leukogram, platelet, and total protein parameters that were analyzed in the samples of negative dogs positive for Anaplasmataceae. Blood count showed a significant difference between mean erythrocyte values ($p = 0.03$) in the group of animals infected with Anaplasmataceae, suggesting a mild to severe anemia in these animals. Reduction in erythrocyte count showed a strong positive correlation ($p = 0.013$; $r = 0.7$) with blood viscosity, but was more evident in a negative erythrocyte correlation with shear rate in this same group ($p = 0.0001$; $r = -0.88$).

Dogs naturally infected by Anaplasmataceae showed changes in blood viscosity compared to uninfected dogs (**Table 5**). Viscosity values were inversely proportional to shear rate in both groups studied (**Figure 1**). Also, there were differences in shear rate ($p = 0.008$). Previous work on dogs infected with Leishmania also showed changes in blood viscosity [9]. Blood flow curves and their respective hysteresis areas in infected animals revealed lower shear rates compared to uninfected animals (**Figure 2**).

The mean viscosity and shear rate values in both groups revealed significant differences for both parameters (**Table 5**). There were differences in shear rate ($p = 0.008$) and also in viscosity ($p < 0.0001$). There was no difference in the averages analyzed between the groups regarding the leukocyte, platelet, and total protein concentrations.

The serum profile of inflammatory, anti-inflammatory, and regulatory cytokines, IL-2, IL-4, IL-6, IL-10, TNF- α , IFN- γ , IL-17A were evaluated according to Scherer et al. [7] and Silva et al. [9]. Among the cytokines, the only one that showed difference between the infected and uninfected groups was IL-10 (**Table 6**). The serum concentration of this interleukin was lower in the infected group when compared to dogs Anaplasmataceae negative.

The hemogram, rheometry, and serum cytokines parameters were correlated using Pearson's correlation test (**Figure 3**). There was an inversely proportional correlation between viscosity and shear rate, shear rate and erythrocytes, and shear

	Negative	Anaplasmataceae	E. canis	A. platys	E. canis + A. platys
Number	12	13	7	8	5
Prevalence (%)	48	52	28	32	20

Table 3.
Results of PCR tests for detection of Anaplasmataceae, E. canis and A. platys bacteria.

	Negative	Anaplasmataceae	Statistical
Erythrocytes (tera/L)	7.5 ± 1.09	5.76 ± 1.91	p < 0.05
Hemoglobin (g/dL)	17.18 ± 2.46	13.09 ± 4.19	p < 0.05
Hematocrit (%)	50.3 ± 6.77	38.4 ± 12.7	p < 0.05
Leukocytes(1/μL)	10.92 ± 2.40	11.81 ± 5.29	p > 0.05
Neutrophils (1/μL)	6.57 ± 1.87	8.02 ± 3.98	p > 0.05
lymphocytes (1/μL)	2.87 ± 0.98	2.5 ± 1.7	p > 0.05
Monocytes (1/μL)	0.42 ± 0.25	0.4 ± 0.24	p > 0.05
Platelets (1/μL)	177.16 ± 81.74	191.58 ± 103.56	p > 0.05
Total Protein (g/dL)	6.83 ± 0.86	6.15 ± 1.2	p > 0.05

Table 4.
Hemogram and total protein values of dogs negative and positive for Anaplasmataceae bacteria.

	Negative	Anaplasmataceae	Statistical
Viscosity (Pa/s)	7.44 ± 5.8 × 10 ⁻³	5.5 ± 5.67 × 10 ⁻³	p < 0.05
Share rate (1/s)	405.68 ± 51.09	592.56 ± 223.24	p < 0.05

Table 5.
Mean and standard deviation of the rheology of healthy dogs and dogs naturally infected by bacteria of the Anaplasmataceae.

rate and IFN-γ. We also observed directly proportional correlations between erythrocytes and blood viscosity, IFN-γ and blood viscosity, and IFN-γ and erythrocytes.

Dogs naturally infected by *Leishmania* have altered blood viscosity related to decreased erythrocytes [9]. In this study, there was a negative correlation between shear rate and hematocrit (p = 0.0004; r = -0.85).

The explanation for the occurrence of hemorheological alterations observed in dogs infected by Anaplasmataceae in this study may be related to alteration of erythrocyte morphology which, in turn, leads to alteration of blood viscosity as a systemic disease. Diseases caused by infectious agents that parasitize erythrocytes or monocytes lead to changes in the rheological properties of blood [7, 9, 124].

Infectious agents of the Anaplasmataceae family cause diseases with systemic manifestations in dogs, with morphological changes in erythrocytes and anemia in dogs with CME are common [21].

Morphological changes in leukocytes, platelets, and erythrocytes have also been described in cattle infected with a variety of agents including Anaplasmataceae bacteria, protozoa, and filaroid parasites [125]. Dogs with different types of anemia also have morphological changes, including anemia secondary to systemic inflammatory disease [126].

Dogs infected with *Leishmania* showed no correlation between blood viscosity or shear rate and leukocyte, platelet, total protein and globulin parameters [9]. In this study, dogs naturally infected by bacteria of the Anaplasmataceae showed no

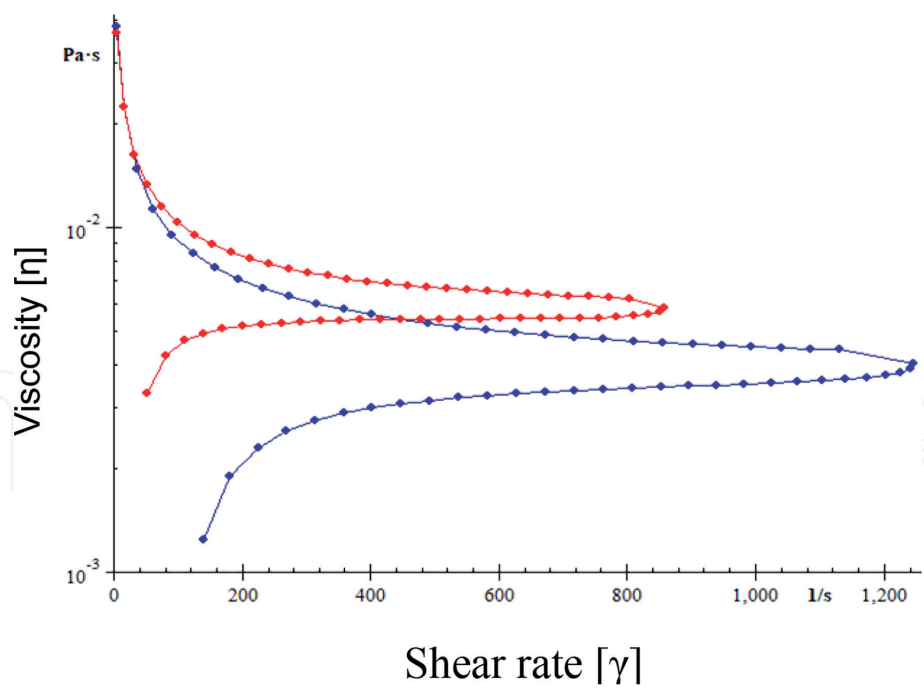


Figure 1.
Viscosity curves of dog whole blood infected or not by bacteria of Anaplasmatataceae.

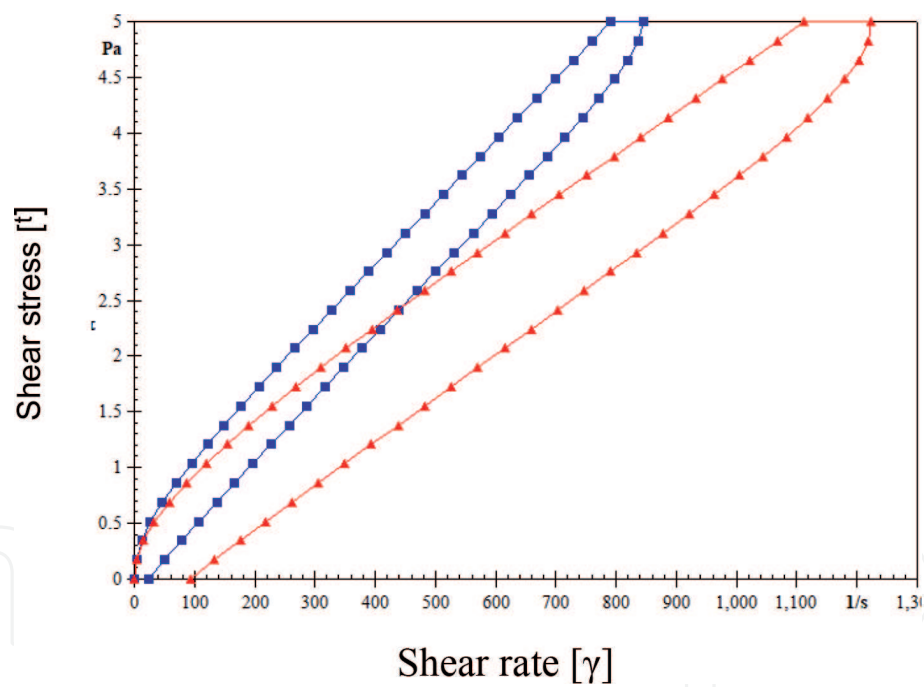


Figure 2.
Histerese area of flow curve of dog whole blood infected or not by bacteria of Anaplasmatataceae.

correlation between viscosity and leukocytes, platelets and interleukins (IL-2, IL-4, IL-6, IL-10, TNF- α , and IL-17a).

The cytokine TNF- α may aggravate the clinical signs in animals infected by Anaplasmatataceae [63], but in this study no correlations of this cytokine with alteration of viscosity, anemia or leukocytes were found. The data presented corroborate the one presented by Lima et al. [71] who found no correlation of anemia with TNF- α and IL-10 in dogs naturally infected with *E. canis*.

Total proteins were strongly correlated with blood viscosity in relation to the group of animals infected by Anaplasmatataceae bacteria ($p = 0.0007$; $r = 0.84$). Studies by Silva et al. [9] found no correlation between these parameters in

Cytokines	Anaplasmatataceae (–)	Anaplasmatataceae (+)
IL-2	671.1 ± 10.6	73.0 ± 14.7
IL-4	31.2 ± 9.9	34.5 ± 4.9
IL-6	31.3 ± 11.6	32.0 ± 3.8
IL-10	32.7 ± 8.2	37.1 ± 3.7*
IL-17	371.7 ± 224.2	502.1 ± 379.1
TNF-α	533.8 ± 260.4	319.6 ± 245.4
IFN-γ	253.8 ± 172.5	256.2 ± 156.4

The results were expressed in mean and standard error.
*P < 0.05.

Table 6.
Cytokine concentrations in dogs non-infected and dogs with Anaplasmatataceae.

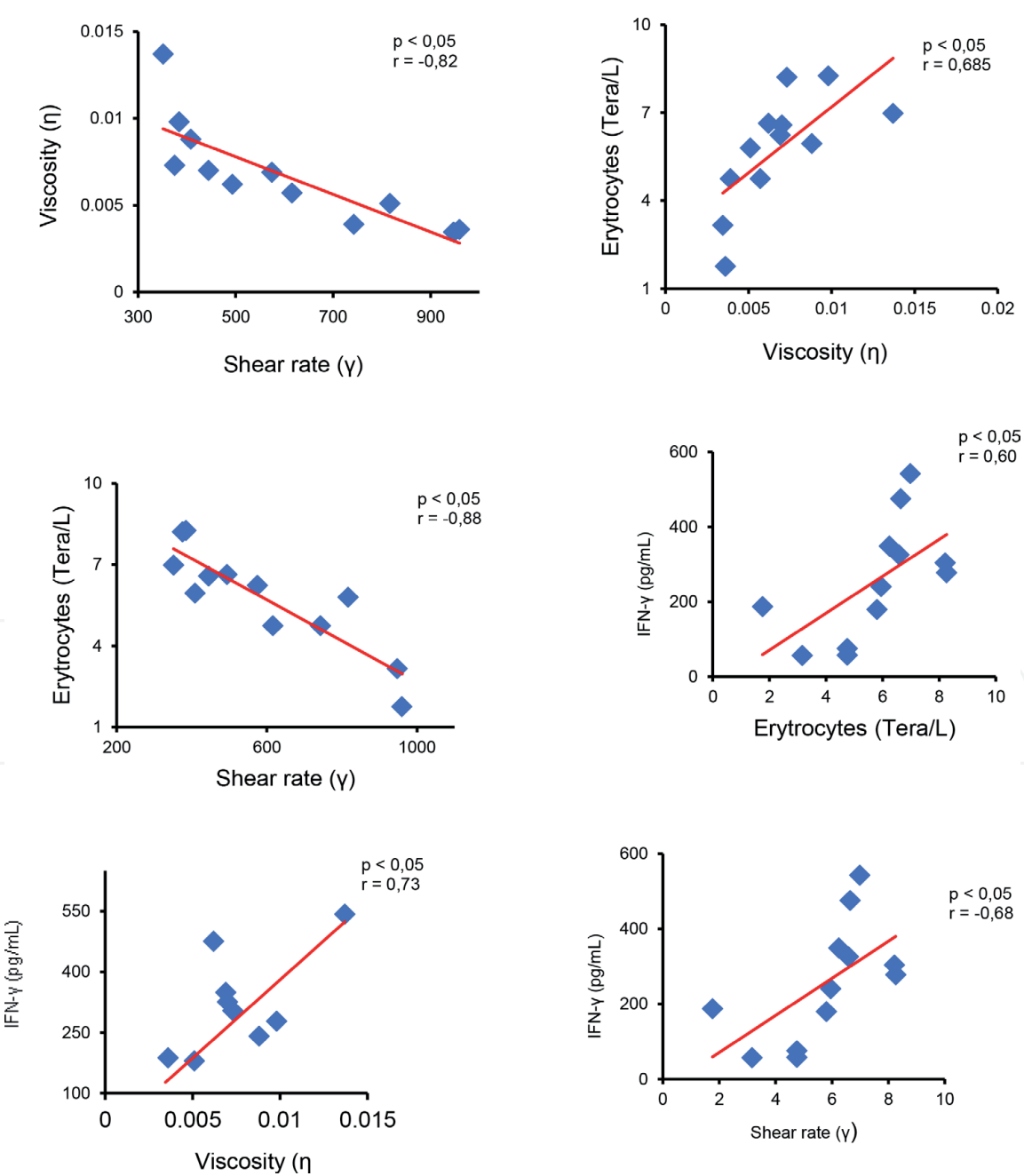


Figure 3.
Correlation between viscosity with erythrocytes, shear rates and IFN-γ; erythrocytes with shear rates and IFN-γ; and IFN-γ with shear rates of dogs infected with Anaplasmatataceae.

Leishmania-positive dog samples, nor even a correlation between viscosity and immunoglobulins. However, it has been reported that fibrinogen binding may occur in erythrocytes due to increased serum fibrinogen concentration [127].

Interestingly, in this work, the serum IFN- γ concentration was promising. Regarding the group of animals infected by bacteria of the Anaplasmataceae family, this interleukin showed a strong positive correlation with blood viscosity ($p = 0.007$; $r = 0.73$), negative correlation with shear rate ($p = 0.016$; $r = -0.68$), which may indicate a modulation of hemorheological behavior, mainly a decrease in blood viscosity and, consequently, an increase in shear rate in animals infected by bacteria of the Anaplasmataceae family.

Cytokine immunomodulation is also reported in other mandatory intracellular parasite infections. Studies by Scherer et al. [7] demonstrated that in *P. vivax*-infected patients, IL-17a was the cytokine responsible for decreasing blood viscosity, which probably decreased erythrocyte rupture, as these cells demonstrated easy osmotic shock due to infection.

The possible correlation of IFN- γ with erythrocytes ($p = 0.04$; $r = 0.6$) in relation to the group of infected animals allows us to infer that IFN- γ was able to pathologically immunomodulate, aggravating the anemic condition in dogs. Martin et al. [61] described that IFN- γ is linked to the survival of the Anaplasmataceae infected patient, and this cytokine may have its effect increased in the presence of TNF- α [62]. No correlations were found between IFN- γ and TNF- α , even though there were serum concentrations of both cytokines in the blood of animals infected by bacteria from Anaplasmataceae family. Perhaps, TNF- α may influence the effect of IFN- γ on disease stage differences caused by Anaplasmataceae family bacteria in dogs.

Although IFN- γ is important in controlling infection with a Th1-type immune response [75], it can also be detrimental to erythrocytes in animals infected with Anaplasmataceae as it may lead to a severe decrease in cell count, if not immunoregulated by another cytokine.

Serum IL-10 levels showed a difference between the studied groups [Table 6], being relevant the increase of its concentration in dogs infected by Anaplasmataceae bacteria. Studies by Faria et al. [70] demonstrated that experimentally infected *E. canis* infected lymphocytes and splenocytes have high IL-10 and low IFN- γ production, indicating modulation to a Th2-like profile, as IL-10 negatively modulates IFN- γ production.

The use of IL-12 [11] and continuous use of IFN- γ [10] assist in the treatment of Leishmania infected animals, as the Th1 response profile is effective in eliminating the parasite. Experimental controlled use of anti-IL-10 antibodies also demonstrated improvement in Leishmania positive animals [128]. Thus, dogs undergoing treatment with Anaplasmataceae are likely to have a better chance of eliminating the agent using IFN- γ at controlled doses. In the case of dogs with anemia, perhaps the regulated use of IL-10 may immunomodulate the response and prevent the deleterious action of IFN- γ on erythrocytes.

4. Conclusion

Dogs naturally infected by Anaplasmataceae have serum concentration of different cytokines, but IFN- γ seems to be responsible for decreasing blood viscosity in these animals and causing disturbances in erythrocytes that are harmful. However, IFN- γ is also important in eliminating Anaplasmataceae by regulating the proliferation of these bacteria in infected dogs.

Alteration of blood rheology in dogs naturally infected with Anaplasmataceae probably occurs due to the systemic character of the infection that leads to erythrocyte alterations, which in turn disrupt the normal blood flow in these animals.

Thus, cytokine modulation reflects the hemorheological profile of infected animals and mainly the viscosity and shear rates.

It is not known which proteins could be involved in this process of viscosity alteration in dogs infected by bacteria of the Anaplasmataceae family. Thus, further studies are needed to understand which proteins are related to the decrease in viscosity in these animals.

It is proposed that the determination of blood rheological parameters as well as their therapeutic accompaniment may be important for dogs naturally infected with Anaplasmataceae. Controlled use of IFN- γ may be a tool to aid treatment, but anemia rates should be considered. In addition, infected dogs with moderate to severe anemia rates could benefit from IL-10 treatment.

Acknowledgement

This research received grants from the Mato Grosso Research Support Foundation (FAPEMAT No299032/ 2010), from the National Council for Scientific and Technological Development (CNPq No. 447218/ 2014-0 No. 308600/2015-0), in Brazil and Propes/IFMT (No. 36/2017).

Conflict of interests

The authors declare that there is no conflict of interest and non-financial competitors.

Author details

Saulo Pereira Cardoso^{1,2}, Giane Regina Paludo³, José Nivaldo da Silva¹, Adenilda Honório-França^{1*} and Eduardo Luzia França¹

1 Institute of Biological and Health Sciences, Federal University of Mato Grosso, Barra do Garças, MT, Brazil

2 Federal Institute of Education, Science and Technology of Mato Grosso, Departament of Education, Barra do Garças, MT, Brazil

3 Faculty of Agronomy and Veterinary Medicine, Federal University of Brasilia, Brasilia, DF, Brazil

*Address all correspondence to: adenilda@ufmt.br

IntechOpen

© 2020 The Author(s). Licensee IntechOpen. This chapter is distributed under the terms of the Creative Commons Attribution License (<http://creativecommons.org/licenses/by/3.0>), which permits unrestricted use, distribution, and reproduction in any medium, provided the original work is properly cited. 

References

- [1] Almeida ABPF, Paula DAJ, Dutra V, Nakazato L, Mendonça AJ, Sousa VRF. Infecção por *Ehrlichia canis* e *Anaplasma platys* em cadelas e neonatos em Cuiabá, Mato Grosso. Archives of Veterinary Science. 2010;15:127-134
- [2] Lasta CS, Santos AP, Messick JB, Oliveira ST, Biondo AW, Vieira RF, et al. Molecular detection of *Ehrlichia canis* and *Anaplasma platys* in dogs in southern Brazil. Revista Brasileira de Parasitologia Veterinária. 2013;22:360-366
- [3] Yuasa Y, Tsai YL, Chang CC, Hsu TT, Chou CC. The prevalence of *Anaplasma platys* and a potential novel *Anaplasma* species exceed that of *Ehrlichia canis* in asymptomatic dogs and *Rhipicephalus sanguineus* in Taiwan. Journal of Veterinary Medical Science. 2017;79:1494-1502
- [4] Pruneau L, Moumène A, Meyer DF, Marcelino I, Lefrançois T, Vachiéry N. Understanding Anaplasmataceae pathogenesis using “Omics” approaches. Frontiers in Cellular and Infection Microbiology. 2014;4:1-7
- [5] Rikihisa Y. Diagnosis of emerging ehrlichial diseases of dogs, horses, and humans. Journal of Veterinary Internal Medicine. 2000;14:250-251
- [6] Harvey JW, Simpson CF, Gaskin JM. Cyclic thrombocytopenia induced by rickettsi-like agent in dogs. The Journal of Infectious Diseases. 1978;137:182-188
- [7] Scherer EF, Cantarini DG, Siqueira R, Ribeiro EB, Braga EM, Honório-França AC, et al. Cytokine modulation of human blood viscosity from vivax malaria patients. Acta Tropica. 2016;158:139-147
- [8] França EL, Ribeiro EB, Scherer EF, Cantarini DG, Pessôa RS, França FL, et al. Effects of *Momordica charantia* L. on the blood rheological properties in diabetic patients. BioMed Research International. 2014;2014:1-8
- [9] Silva JN, Cotrim AC, Conceição LAV, Marins CMF, Marchi PGF, Honório-França AC, et al. Immunohaematological and rheological parameters in canine visceral leishmaniasis. Revista Brasileira de Parasitologia Veterinária. 2018;27:211-217
- [10] Murray HW. Effect of continuous administration of interferon- γ in experimental visceral leishmaniasis. The Journal of Infectious Diseases. 1990;161:992-994
- [11] Murray HW, Montelibano C, Peterson R, Sypek JP. Interleukin 12 regulates the response to chemotherapy in experimental visceral leishmaniasis. The Journal of Infectious Diseases. 2000;182:1497-1502
- [12] Correa ES, Paludo GR, Scalón MC, Machado JA, Lima ACQ, Pinto ATB, et al. Investigação molecular de *Ehrlichia* spp. e *Anaplasma platys* em felinos domésticos: alterações clínicas, hematológicas e bioquímicas. Pesquisa Veterinária Brasileira. 2011;31:899-909
- [13] Hackstadt T. The diverse habitats of obligate intracellular parasites. Current Opinion in Microbiology. 1998;1:82-87
- [14] Ganta RR. Anaplasmataceae: *Anaplasma*. In: Mcvey DS, Melissa K, Chengappa MM, editors. Veterinary Microbiology. Chichester: John Wiley & Sons, Inc; 2013a. pp. 302-305
- [15] Ganta RR. Anaplasmataceae: *Ehrlichia* and *Neorickettsia*. In: Mcvey DS, Melissa K, Chengappa MM, editors. Veterinary Microbiology. Chichester: John Wiley & Sons, Inc; 2013b. pp. 297-301

- [16] Suksawat J, Hegarty BC, Breitschwerdt EB. Seroprevalence of *Ehrlichia canis*, *Ehrlichia equi*, and *Ehrlichia risticii* in sick dogs from North Carolina and Virginia. Journal of Veterinary Internal Medicine. 2000;**14**:50-55
- [17] Vieira RFC, Biondo AW, Guimaraes MAS, Santos AP, Santos RP, Dutra LH, et al. Ehrlichiosis in Brazil. Revista Brasileira de Parasitologia Veterinária. 2011;**20**:1-12
- [18] Ribeiro CM, Matos AC, Azzolini T, Bones ER, Wasnieski EA, Richini-Pereira VB, et al. Molecular epidemiology of *Anaplasma platys*, *Ehrlichia canis* and *Babesia vogeli* in stray dogs in Paraná, Brazil. Pesquisa Veterinária Brasileira. 2017;**37**:129-136
- [19] Zobba R, Anfossia AG, Visco S, Sotgiu F, Dedola C, Pinna Parpaglia ML, et al. Cell tropism and molecular epidemiology of *Anaplasma platys*-like strains in cats. Ticks and Tick-borne Diseases. 2015;**6**:272-280
- [20] Fontalvo MC, Braga IA, Aguiar DM, Horta MC. Serological evidence of exposure to *Ehrlichia canis* in cats. Ciência Animal Brasileira. 2016;**17**:418-424
- [21] Dagnone AS, Souza AI, André MR, Machado RZ. Molecular diagnosis of Anaplasmatidae organisms in dogs with clinical and microscopical signs of ehrlichiosis. Revista Brasileira de Parasitologia Veterinária. 2009;**18**:20-25
- [22] Lima MA, Aquino LC, Paludo GR. Evaluation of Anaplasmatidae family agents infection in domestic cats. Pakistan Veterinary Journal. 2017;**37**:201-204
- [23] Donatien A, Lestoquard F. Existence en Algérie d'une *Rickettsia* du chien. Bulletin de la Société de Pathologie Exotique. 1935;**28**:418-419
- [24] Machado RZ. Erliquiose canina. In: XIII Congresso Brasileiro de Parasitologia Veterinária & I Simpósio Latino-Americano de Rickettsioses. Revista Brasileira de Parasitologia Veterinária. 2004;**13**:53-57. Available from: <https://docplayer.com.br/15106223-Xiii-congresso-brasileiro-de-parasitologia-veterinaria-i-simpósio-latino-americano-de-rickettsioses-ouro-preto-mg-2004.html> [Accessed on: 07 February 2019]
- [25] Huxsoll DL, Hildebrandt PK, Nims RM, Walker JS. Tropical canine pancytopenia. Journal of the American Veterinary Medical Association. 1970;**157**:1627-1632
- [26] Costa JO, Silva M, Batista Júnior JA, Guimarães MP. *Ehrlichia canis* infection in dog in Belo Horizonte – Brazil. Arq Esc Vet Bela Horizonte. 1973;**25**:199-200
- [27] Straube J. Canine Ehrlichiosis – From acute infection to chronic disease. CVBD: Digest. 2010;**7**:1-12
- [28] Ojeda-Chi MM, Rodriguez-Vivas RI, Esteve-Gasent MD, Pérez de León AA, Modarelli JJ, Villegas-Perez SL. *Ehrlichia canis* in dogs of Mexico: Prevalence, incidence, co-infection and factors associated. Comparative Immunology, Microbiology and Infectious Diseases. 2019;**67**:101351
- [29] Keefe TJ, Holland CJ, Salyer PE, Ristic M. Distribution of *Ehrlichia canis* among military working dogs in the world and selected civilian dogs in the United States. Journal of the American Veterinary Medical Association. 1982;**181**:236-238
- [30] Hildebrandt PK, Conroy JD, McKee AE, Nyindo MB, Huxsoll DL. Ultrastructure of *Ehrlichia canis*. Infection and Immunity. 1973;**7**:265-271
- [31] Labarthe N, Pereira M, Barbarini O, McKee W, Coimbra C, Hoskins J. Serologic prevalence of *Dirofilaria immitis*,

Ehrlichia canis, and *Borrelia burgdorferi* infections in Brazil. Veterinary Therapeutics. 2003;4:67-75

[32] Perez M, Rikihisa Y, Wen B.

Ehrlichia canis-like agent isolated from a man in Venezuela: antigenic and genetic characterization. Journal of Clinical Microbiology. 1996;34(9):2133-2139

[33] Dumler JS, Barbet AF, Bekker CP, Dasch GP, Palmer GH, Ray SC, et al. Reorganization of genera in the families Rickettsiaceae and Anaplasmataceae in the order Rickettsiales: Unification of some species of *Ehrlichia* with *Anaplasma*, *Cowdria* with *Ehrlichia* and *Ehrlichia* with *Neorickettsia*, descriptions of six new species combinations and designation of *Ehrlichia equi* and 'HGE agent' as subjective synonyms of *Ehrlichia phagocytophila*. International Journal of Systematic and Evolutionary Microbiology. 2001;5:2145-2165

[34] Mcquiston JH, McCall CL, Nicholson WL. Ehrlichiosis and related infections. Journal of the American Veterinary Medical Association. 2003;223:1750-1756

[35] Neer TM, Harrus S. Ehrlichiosis, Neorickettsiosis, Anaplasmosis, and Wolbachia infection. In: Greene CE, editor. Infectious Diseases of the Dog and Cat. St Louis: Elsevier; 2006. pp. 203-232

[36] De La Fuente J, Torina A, Naranjo V, Nicosia S, Alongi A, Lamantia F, et al. Molecular characterization of *Anaplasma platys* strains from dogs in Sicily, Italy. BMC Veterinary Research. 2006;2:1-5

[37] De Caprariis D, Dantas-Torres F, Capelli G, Mencke N, Stanneck D, Breitschwerdt EB, et al. Evolution of clinical, haematological and biochemical findings in young dogs naturally infected by vector-borne pathogens. Veterinary Microbiology. 2011;149:206-212

[38] Rodrigues D, Daemon E, Rodrigues AFSF, Feliciano EA,

Soares AO, Souza AD. Levantamento de hemoparasitos em cães da área rural de Juiz de Fora, Minas Gerais, Brasil. Revista Brasileira de Parasitologia Veterinaria. 2004;3:371

[39] Ferreira RF, Cerqueira AMF, Pereira AM, Guimarães CM, Sá AG, Abreu FS, et al. *Anaplasma platys* diagnosis in dogs: Comparison between morphological and molecular tests. International Journal of Applied Research in Veterinary Medicine. 2007;5:113-119

[40] Ramos CAN, Ramos RAN, Araujo FR, Guedes DSJr., Souza IIF, Ono TM, Vieira AS, Pimentel DS, Rosas EO, Faustino MAG, Alves LC. Comparison of nested-PCR with blood smear examination in detection of *Ehrlichia canis* and *Anaplasma platys* in dogs. Revista Brasileira de Parasitologia Veterinária. 2009;1:58-62

[41] Maggi RG, Mascarelli PE, Havenga LN, Naidoo V, Breitschwerdt EB. Co-infection with *Anaplasma platys*, *Bartonella henselae* and *Candidatus Mycoplasma haematoparvum* in a veterinarian. Parasites & Vectors. 2013;6:103

[42] Arraga-Alvarado CM, Qurollo B, Parra OC, Berrueta MA, Hegarty BC, Breitschwerdt EB. Molecular evidence of *Anaplasma platys* infection in two women from Venezuela. The American Journal of Tropical Medicine and Hygiene. 2014;91:1161-1165

[43] Sousa VRF, Bomfim TCB, Almeida ABPF, Barros LA, Sales KG, Justino CHS, et al. Coinfecção por *Anaplasma platys* e *Ehrlichia canis* em cães diagnosticada pela PCR. Acta Scientiae Veterinariae. 2009;37:281-283

[44] Santos AS, Alexandre N, Sousa R, Nuncio MS, Bacellar F, Dumler JS. Serological and molecular survey of *Anaplasma* species infection in dogs with suspected tickborne disease

in Portugal. The Veterinary Record. 2009;**164**:168-171

[45] Silva GCF, Benitez NA, Girotto A, Taroda A, Vidotto MC, Garcia JL, et al. Occurrence of *Ehrlichia canis* and *Anaplasma platys* in household dogs from northern Parana. Revista Brasileira de Parasitologia Veterinaria. 2012;**21**:379-385

[46] Diniz PPVP, Beall MJ, Omark K, Chandrashekar R, Daniluk DA, Cyr KE, et al. High prevalence of tick-borne pathogens in dogs from an Indian reservation in northeastern Arizona. Vector Borne and Zoonotic Diseases. 2010;**10**:117-123

[47] Souza DMB, Coletto ZF, Souza AF, Silva SV, Andrade JK, Gimenez GC. Erliquiose transmitida aos cães pelo carrapato marrom (*Rhipicephalus sanguineus*). Ciência Veterinária nos Trópicos. 2012;**15**:21-31

[48] Yabsley MJ, McKibben J, Macpherson CN, Cattán PF, Cherry NA, Hegarty BC, et al. Prevalence of *Ehrlichia canis*, *Anaplasma platys*, *Babesia canis vogeli*, *Hepatozoon canis*, *Bartonella vinsonii berkhoffii*, and *Rickettsia* spp. in dogs from Grenada. Veterinary Parasitology. 2008;**151**:279-285

[49] Piranda EM, Faccini JLH, Pinter A, Pacheco RC, Cançado PHD, LABRUNA MB. Experimental infection of *Rhipicephalus sanguineus* ticks with the bacterium *Rickettsia rickettsii*, using experimentally infected dogs. Vector-Borne and Zoonotic Diseases. 2011;**11**:29-36

[50] Sherding RG. Rickettsiosis, Ehrlichiosis, Anaplasmosis, and Neorickettsiosis. In: Birchard SJ, Sherding RG, editors. Manual Saunders of Small Animal Practice. St Louis: Saunders Elsevier; 2006. pp. 178-185

[51] Borin S, Crivelenti LZ, Ferreira FA. Aspectos epidemiológicos, clínicos e

hematológicos de 251 cães portadores de mórula de *Ehrlichia* spp. naturalmente infectados. Arquivo Brasileiro de Medicina Veterinária e Zootecnia. 2009;**61**:566-571

[52] Harvey JW. Veterinary Hematology: A Diagnostic Guide and Color Atlas. Saunders: Elsevier; 2011. p. 368

[53] Matei IA, Stuen S, Modrý D, Degan A, D'amico G, Mihalca AD. Neonatal *Anaplasma platys* infection in puppies: Further evidence for possible vertical transmission. Veterinary Journal. 2017;**219**:40-41

[54] Latrofa MS, Dantas-Torres F, De Caprariis D, Cantacessi C, Capelli G, Lia RP, et al. Vertical transmission of *Anaplasma platys* and *Leishmania infantum* in dogs during the first half of gestation. Parasites & Vectors. 2016;**9**:149-269

[55] Silva JN, Almeida ABPF, Sorte ECB, Freitas AG, Santos LGF, Aguiar DM, et al. Soroprevalência de anticorpos anti-*Ehrlichia canis* em cães de Cuiabá, Mato Grosso. Revista Brasileira de Parasitologia Veterinaria. 2010;**19**:108-111

[56] Sanogo YO, Davoustb, Inokuma H, Camias JL, Parola P, Brouqui P. First evidence of *Anaplasma platys* in *Rhipicephalus sanguineus* (Acari: Ixodida) collected from dogs in Africa. The Onderstepoort Journal of Veterinary Research. 2003;**70**:205-212

[57] Bremer WG, Schaefer JJ, Wagner ER, Ewing SA, Rikihisa Y, Needham GR, et al. Transstadial and intrastadial experimental transmission of *Ehrlichia canis* by male *Rhipicephalus sanguineus*. Veterinary Parasitology. 2005;**131**:95-105

[58] Smith RD, Sells DM, Stephenson EH, Ristic MR, Huxsoll DL. Development of *Ehrlichia canis*, causative agent of canine Ehrlichiosis, in the tick

Rhipicephalus sanguineus and its differentiation from a symbiotic rickettsia. American Journal of Veterinary Research. 1976;**37**:119-126

lipopolysaccharide activation of NF- κ B, ERK 1/2 and p38 MAPK in host monocytes. Cellular Microbiology. 2004;**6**:175-186

[59] Breitschwerdt EB. Canine and feline anaplasmosis: Emerging infectious diseases. In: Breitschwerdt EB, editor. Proceedings of the 2nd Canine Vector-Borne Disease (CVBD) Symposium. Sícilia, Itália: CBVD World of Knowledge; 2007. pp. 6-14

[66] Lee EH, Rikihisa Y. Protein kinase A-mediated inhibition of gamma interferon-induced tyrosine phosphorylation of Janus kinases and latent cytoplasmic transcription factors in human monocytes by *Ehrlichia chaffeensis*. Infection and Immunity. 1998;**66**:2514-2520

[60] Welc-Faleciak R, Kowalec M, Karbowiak G, Bajer A, Behnke JM, Sinski E. Rickettsiaceae and Anaplasmataceae infections in Ixodes ricinus ticks from urban and natural forested areas of Poland. Parasites & Vectors. 2014;**7**:1-13

[67] Ismail N, Soong L, McBride JW, Valbuena G, Olano JP, Feng H-M, et al. Overproduction of TNF- α by CD8+ type 1 cells and down-regulation of IFN- γ production by CD4+ Th1 cells contribute to toxic shock-like syndrome in an animal model of fatal monocytoprotropic ehrlichiosis. Journal of Immunology. 2004;**172**:1786-1800

[61] Martin ME, Carspersen K, Dumler JS. Immunopathology and ehrlichial propagation are regulated by interferon- γ and interleukin-10 in a murine model of human granulocytic ehrlichiosis. The American Journal of Pathology. 2001;**158**:1881-1888

[68] Zhang JZ, Sinha M, Luxon BA, Yu XJ. Survival strategy of obligately intracellular *Ehrlichia chaffeensis*: Novel modulation of immune response and host cell cycles. Infection and Immunity. 2004;**72**:498-507

[62] Feng HM, Walker DH. Mechanisms of immunity to *Ehrlichia muris*: A model of monocytoprotropic ehrlichiosis. Infection and Immunity. 2004;**72**:966-971

[69] Hess PR, English RV, Hegarty BC, Brown GD. Breitschwerdt EB, Experimental *Ehrlichia canis* infection in the dog does not cause immunosuppression. Veterinary Immunology and Immunopathology. 2006;**109**:117-125

[63] Beineke A, Markus S, Borlak J, Thum T, Baumgärtner W. Increase of pro-inflammatory cytokine expression in non-demyelinating early cerebral lesions in nervous canine distemper. Viral Immunology. 2008;**21**:401-410

[70] Faria JLM, Munhoz TD, João CF, Vargas-Herández G, André MR, Pereira WAB, et al. *Ehrlichia canis* (Jaboticabal strain) induces the expression of TNF- α in leukocytes and splenocytes of experimentally infected dogs. Revista Brasileira de Parasitologia Veterinária. 2011;**20**:71-74

[64] Scorpio DG, Von Loewenich FD, Göbel H, Bogdan C, Dumler JS. Innate immune response to *Anaplasma phagocytophilum* contributes to hepatic injury. Clinical and Vaccine Immunology. 2006;**13**:806-809

[71] Lima AL, Santos GJL, Roatt BM, Reis AB, Freitas JCC, Nunes-Pinheiro DCS. Serum TNF- α and IL-10 in *Ehrlichia* spp. naturally infected dogs. Acta Scientiae Veterinariae. 2015;**43**:1-7

[65] Lin M, Rikihisa Y. *Ehrlichia chaffeensis* downregulates surface toll-like receptors 2/4, CD14 and transcription factors PU.1 and inhibits

- [72] Dumler JS. The biological basis of severe outcomes in *Anaplasma phagocytophilum* infection. FEMS Immunology and Medical Microbiology. 2012;**64**:13-20
- [73] Kocan KM, De La Fuente J, Blouin EF, Coetzee JF, Ewing SA. The natural history of *Anaplasma marginale*. Veterinary Parasitology. 2010;**167**:95-107
- [74] Akkoyunlu M, Fikrig E. Gamma interferon dominates the murine cytokine response to the agent of human granulocytic ehrlichiosis and helps to control the degree of early rickettsemia. Infection and Immunity. 2000;**68**:1827-1833
- [75] Birkner K, Steiner B, Rinkler C, Kern Y, Aichele P, Bogdan C, et al. The elimination of *Anaplasma phagocytophilum* requires CD4+ T cells, but is independent of Th1 cytokines and a wide spectrum of effector mechanisms. European Journal of Immunology. 2008;**38**:3395-3410
- [76] Han S, Norimine J, Brayton KA, Palmer GH, Scoles GA, Brown WC. *Anaplasma marginale* infection with persistent high-load bacteremia induces a dysfunctional memory CD4+ T lymphocyte response but sustained high IgG titers. Clinical and Vaccine Immunology. 2010;**17**:1881-1890
- [77] Desjardins M, Descoteaux A. Inhibition of phagolysosomal biogenesis by the *Leishmania* lipophosphoglycan. The Journal of Experimental Medicine. 1997;**185**:2061-2068
- [78] Bogdan C, Rollinghoff M. The immune response to *Leishmania*: Mechanisms of parasite control and evasion. International Journal for Parasitology. 1998;**28**:121-134
- [79] Sacks D, Sher A. Evasion of innate immunity by parasitic protozoa. Nature Immunology. 2002;**3**:1041-1047
- [80] Popov VL, Yu X, Walker DH. The 120 kDa outer membrane protein of *Ehrlichia chaffeensis*: Preferential expression on dense – Core cells and gene expression in *Escherichia coli* associated with attachment and entry. Microbial Pathogenesis. 2000;**28**:71-80
- [81] Mavromatis K, Doyle CK, Lykidis A, Ivanova N, Francino MP, Chain P, et al. The genome of the obligately intracellular bacterium *Ehrlichia canis* reveals themes of complex membrane structure and immune evasion strategies. Journal of Bacteriology. 2006;**188**:4015-4023
- [82] Troy GC, Forrester SD. Canine ehrlichiosis. In: Greene CE, editor. Infectious Diseases of the Dog and Cat. Philadelphia: WB Saunders; 1990. pp. 404-418
- [83] Harrus S, Waner T, Bark H. Canine monocytic ehrlichiosis – An update. Compendium on Continuing Education for the Practising Veterinarian. 1997b;**19**:431-444
- [84] Waner T, Harrus S, Weiss DJ, Bar H, Keysary A. Demonstration of serum antiplatelet antibodies in experimental acute canine ehrlichiosis. Veterinary Immunology and Immunopathology. 1995;**48**:177-182
- [85] Smith RD, Ristic M, Huxsoll DL, Baylor RA. Platelet kinetics in canine ehrlichiosis: Evidence for increased platelet destruction as the cause of thrombocytopenia. Infection and Immunity. 1975;**11**:1216-1221
- [86] Abeygunawardena I, Kakoma, Smith RD. Pathophysiology of canine ehrlichiosis. In: Williams JC, Kakoma I, editors. Ehrlichiosis: A Vector-Borne Disease of Animals and Humans. Washington: Kluwer Academic Press; 1990. pp. 78-92
- [87] De Tommasi AS, Baneth G, Breitschwerdt EB, Stanneck D,

- Dantas-Torres F, Otranto D, et al. *Anaplasma platys* in bone marrow megakaryocytes of young dogs. *Journal of Clinical Microbiology*. 2014;**52**:2231-2234
- [88] Nakaghi ACH, Machado RZ, Costa MT, André MR, Baldani CD. Canine Ehrlichiosis: Clinical, hematological, serological and molecular aspects. *Ciência Rural*. 2008;**38**:766-770
- [89] Sousa VRF, Almeida ABPF, Barros LA, Sales KG, Justino CHS, Dalcin L, et al. Avaliação clínica e molecular de cães com erliquiose. *Ciência Rural*. 2010;**40**:1309-1313
- [90] Bassi PB, Moreira TK, Silva CC, Bittar ER, Bittar JFF. Aspectos clínicos, epidemiológicos, hematológicos e sorológicos de animais diagnosticados com *Ehrlichia canis* no Hospital Veterinário de Uberaba-MG. *Medvop - Revista Científica de Medicina Veterinária - Pequenos Animais e Animais de Estimação*. 2011;**9**:678-680
- [91] Harrus S, Waner T. Diagnosis of canine monocytotropic ehrlichiosis (*Ehrlichia canis*): An overview. *Veterinary Journal*. 2011;**187**:292-296
- [92] Kataoka A, Santana AE, Seki MC. Alterações do proteinograma sérico de cães naturalmente infectados por *E. canis*. *Ars Veterinaria*. 2006;**22**:98-102
- [93] Mcdade JE. Ehrlichiosis – A disease of animals and humans. *The Journal of Infectious Diseases*. 1990;**161**:609-617
- [94] Kelly PJ. Canine ehrlichioses: An update. *Journal of the South African Veterinary Association*. 2000;**71**:77-86
- [95] Shaw SE, Day MJ, Birtles RJ, Breitschwerdt EB. Tick-borne infectious diseases of dogs. *Trends in Parasitology*. 2001;**17**:74-80
- [96] Gaunt SD, Baker DC, Babin SS. Platelet aggregation studies in dogs with acute *Ehrlichia platys* infection. *American Journal of Veterinary Research*. 1990;**51**:290-293
- [97] Cardozo GP, Oliveira LP, Zissou VG, Donini IAN, Roberto PG, Marins M. Analysis of the 16S rRNA gene of *Anaplasma platys* detected in dogs from Brazil. *Brazilian Journal of Microbiology*. 2007;**38**:478-479
- [98] Kontos VC, Papadopoulos O, French TW. Natural and experimental canine infections with a Greek strain of *Ehrlichia platys*. *Veterinary Clinical Pathology*. 1991;**20**:101-105
- [99] Harrus S, Aroch I, Lavy E, Bark H. Clinical manifestations of infectious canine cyclic thrombocytopenia. *The Veterinary Record*. 1997a;**141**:247-250
- [100] Aguirre E, Tesouro MA, Ruiz L, Amusategui I, Sainz A. Genetic characterization of *Anaplasma (Ehrlichia) platys* in dogs in Spain. *Journal of Veterinary Medicine. B, Infectious Diseases and Veterinary Public Health*. 2006;**53**:197-200
- [101] Dantas-Torres F. Canine vector-borne diseases in Brazil - review. *Parasites & Vectors*. 2008;**1**:1-17
- [102] Harvey JW. Thrombocytotropic anaplasmosis (*A. platys* [*E. platys*] infection). In: Greene CG, editor. *Infectious Diseases of the Dog and Cat*. St. Louis: Saunders Elsevier; 2006. pp. 229-231
- [103] Elias E. Diagnosis of ehrlichiosis from the presence of inclusion bodies or morulae of *E. canis*. *Journal of Small Animal Practice*. 1991;**33**:540-543
- [104] Mylonakis ME, Koutinas AF, Billinis C, Leontides LS, Kontos V, Papadopoulos O, et al. Evaluation of cytology in the diagnosis of acute canine

- monocytic ehrlichiosis (*Ehrlichia canis*): A comparison between five methods. Veterinary Microbiology. 2003;**91**:97-204
- [105] Bowman D, Little SE, Lorentzen L, Shields J, Sullivan MP, Carlin EP. Prevalence and geographic distribution of *Dirofilaria immitis*, *Borrelia burgdorferi*, *Ehrlichia canis*, and *Anaplasma phagocytophilum* in dogs in the United States: Results of a national clinic-based serologic survey. Veterinary Parasitology. 2009;**160**:138-148
- [106] Davoust B, Parzy D, Vidor E, Hasselot N, Martet G. Ehrlichiose canine experimentale: étude clinique et thérapeutique. Revue de Médecine Vétérinaire. 1991;**167**:33-40
- [107] McClure EE, Chávez ASO, Shaw DK, Carlyon JA, Ganta RR, Noh SM, et al. Engineering of obligate intracellular bacteria: Progress, challenges and paradigms. Nature Reviews. Microbiology. 2017;**15**:544-558
- [108] Martin AR, Brown GK, Dunstan RH, Roberts TK. *Anaplasma platys*: An improved PCR for its detection in dogs. Experimental Parasitology. 2005;**109**:176-180
- [109] Aguiar DM, Saito TB, Hagiwara MK, Machado RZ, Labruna MB. Diagnóstico sorológico de erliquiose canina com antígeno brasileiro de *Ehrlichia canis*. Ciência Rural. 2007;**46**:796-802
- [110] Nakaghi ACH, Machado RZ, Ferro JÁ, Labruna MB, Chrysafidis AL, André MR, et al. Sensitivity evaluation of a single-step PCR assay using *Ehrlichia canis* p28 gene as a target and its application in diagnosis of canine ehrlichiosis. Revista Brasileira de Parasitologia Veterinaria. 2010;**19**:75-79
- [111] Doyle CK, Labruna MB, Breitschwerdt EB, Tang YW, Corstvet RE, Hegarty BC, et al. Detection of medically important *Ehrlichia* by quantitative multicolor TaqMan real-time polymerase chain reaction of the dsb gene. The Journal of Molecular Diagnostics. 2005;**7**:504-510
- [112] Mendonça CS, Mundim AV, Costa AS, Moro TV. Erliquiose Canina: Alterações hematológicas em cães domésticos naturalmente infectados. Bioscience Journal. 2005;**21**:167-174
- [113] Birkenheuer AJ, Lvey MG, Breitschwerdt EB. Development and evaluation of a seminested PCR for detection and differentiation of *Babesia gibsoni* (Asian genotype) and *B. canis* DNA in canine blood samples. Journal of Clinical Microbiology. 2003;**41**:4172-4177
- [114] Llera JL, López-García ML, Martín RE, De Vivar GR. Differential serological testing by simultaneous indirect immunofluorescent antibody test in canine leishmaniosis and ehrlichiosis. Veterinary Parasitology. 2002;**109**:185-190
- [115] Baskurt OK, Meiselman HJ. Blood Rheology and hemodynamics. Seminars in Thrombosis and Hemostasis. 2003;**29**:435-450
- [116] Rosencraz R, Bogen SA. Clinical laboratory measurement of serum, plasma, and blood viscosity. American Journal of Clinical Pathology. 2006;**125**:78-86
- [117] Mendlowitz M. The effect of anemia e polycythemia on digital intravascular blood viscosity. The Journal of Clinical Investigation. 1948;**27**:565-571
- [118] Linderkamp O, Ruef P, Zilow EP, Hoffmann GF. Impaired deformability of erythrocytes and neutrophils in children with newly diagnosed insulin-dependent diabetes mellitus. Diabetologia. 1999;**42**:865-869
- [119] Rizvi SI, Zaid MA. Intracellular reduced glutathione content in normal

and type 2 diabetic erythrocytes: Effect of insulin and (–) epicatechin. *Journal of Physiology and Pharmacology*. 2001;**52**:483-488

[120] Moutzouri AG, Athanassiou GA, Dimitropoulou D, Skoutelis AT, Gogos CA. Severe sepsis and diabetes mellitus have additive effects on red blood cell deformability. *The Journal of Infection*. 2008;**57**:147-151

[121] Inokuma H, Raoult D, Brouqui P. Detection of *Ehrlichia platys* DNA in Brown Dog Ticks (*Rhipicephalus sanguineus*) in Okinawa Island, Japan. *The Journal of Clinical Microbiology*. 2000;**38**:4219-4221

[122] Murphy GL, Ewing SA, Whitworth LC, Fox JC, Kocan AA. A molecular and serologic survey of *Ehrlichia canis*, *E. chaffeensis*, and *E. ewingii* in dogs and ticks from Oklahoma. *The Journal Veterinary Parasitology*. 1998;**79**:325-339

[123] Ramos R, Ramos C, Araújo F, Oliveira R, Souza I, Pimentel D, et al. Molecular survey and genetic characterization of tick-borne pathogens in dogs in metropolitan Recife (North-Eastern Brazil). *Parasitology Research*. 2010;**107**:1115-1120

[124] Fedosov DA, Caswell B, Kamiadakis GE. Wall shear stress-based model for adhesive dynamics of red blood cells in malaria. *Biophysical Journal*. 2011;**100**:2084-2093

[125] Al-Abadi BH, Al-Badrani BA. Cattle blood analyses for parasitic infestation in Mosul, Iraq. *Research Opinions in Animal & Veterinary Sciences*. 2012;**2**:535-542

[126] Schaefer DMW, Stokol T. The utility of reticulocyte indices indistinguishing iron deficiency anemia from anemia of inflammatory disease, portosystemic shunting, and

breed-associated microcytosis in dogs. *Veterinary Clinical Pathology*. 2015;**44**:109-119

[127] Lominadze D, Dean WL. Involvement of fibrinogen specific binding in erythrocyte aggregation. *FEBS Letters*. 2002;**517**:41-44

[128] Murray HW, Lu CM, Mauze S, Freeman S, Moreira AL, Kaplan G, et al. Interleukin-10 (IL-10) in experimental visceral leishmaniasis and IL-10 receptor blockade as immunotherapy. *Infection and Immunity*. 2002;**70**:6284-6293