

We are IntechOpen, the world's leading publisher of Open Access books Built by scientists, for scientists

6,900

Open access books available

185,000

International authors and editors

200M

Downloads

Our authors are among the

154

Countries delivered to

TOP 1%

most cited scientists

12.2%

Contributors from top 500 universities



WEB OF SCIENCE™

Selection of our books indexed in the Book Citation Index
in Web of Science™ Core Collection (BKCI)

Interested in publishing with us?
Contact book.department@intechopen.com

Numbers displayed above are based on latest data collected.
For more information visit www.intechopen.com



Echinococcus granulosus

*Khadeeja Abees Hmood Al-Khalidi, Hiba Riyadh Al-Abodi,
Hayder Kamil Jabbar and Baheeja A. Hmood*

Abstract

Echinococcus granulosus is also called the hydatid worm, which is a parasite that infects humans and animals. It causes zoonotic disease known as echinococcosis (hydatidosis). Adult worms live in the intestines of dogs that are the definitive host. Hydatidosis is known since ancient times and is one of the epidemic diseases that is dangerous to humans in terms of health and economy in most countries of the world. Hydatidosis or echinococcosis unilocular is common in many Arab countries, including Libya, Sudan, Egypt, Lebanon, Syria, Algeria, Palestine, Iraq, and others as well as North, East, and South Africa, Western and Southern Europe, and South America. Studies indicate that the disease is spreading in areas that were previously completely free of it such as North America and Canada. It was also noted that the incidence of the disease in rural areas is close to 50%, and this is due to the large breeding of farm animals and the presence of meat eaters, which helps to complete the life cycle of this parasite, which needs the intermediate host (farm animals and humans) and the definitive host (Canidae).

Keywords: *E. granulosus*, hydatid worm, echinococcosis, hydatidosis, zoonotic disease

1. Introduction

Echinococcus granulosus is one of the cestodes that caused cystic hydatid disease (Echinococcosis), and this parasite is transmitted from carnivores (dogs, foxes, leopards, lions, and hyenas), which are the definitive hosts of *E. granulosus* and the parasite (the adult stages) lives in their intestines, to herbivores (sheep, goats, camels, cows, buffaloes, horses, donkeys, pigs, rabbits, and humans), which are intermediate hosts of the parasite where the larvae (hydatid cyst) live [1].

E. granulosus has three different stages of development: eggs, larvae, and adult worms, which are small and do not exceed 7 mm in length as shown in **Figure 1** and live adjacent to the mucous layer of the small intestine of the definitive hosts until they reach the adult phases of sexual maturity in about 5–4 weeks [2, 3]. The adult worm has a spherical head of 0.3 mm diameter with a short neck and three types of connected segments, and the head contains a sucker surrounded by two rows of spines ranging from 50 to 28 forks, with four side suckers. The segment that follows the head is immature and contains immature genitals, while the middle segment is mature and contains the testes and ovaries and is located in the middle of the genital opening [4, 5]. The third segment is called gravid segment and contains a branched uterus and has 15–12 branches containing 1000–500 eggs [6].

Parasite of the Hydatid Cyst




Figure 1.
E. granulosus adult.

2. *E. granulosus* eggs

The eggs are spherical in shape (**Figure 2**) and have a diameter of about 40–30 μm and are similar in appearance to the eggs of other tapeworms, containing a hexacanth or oncosphere embryo because the embryo has sixth-hooks lets. The eggs are surrounded by clear coatings [8] and the eggs contain a sticky layer that adheres to the fur of animals and other things, which helps them to spread, as well as insects such as flies, beetles, and birds that play the role of mechanical carrier of eggs, in case of optimal conditions, the eggs remain viable for weeks or months in pastures and gardens as well as they remain viable with the right humidity and moderate temperatures, and the eggs are found in water and wet sand for 3 weeks at 30°C and 225 days at 6°C and 32 days at 10–21°C, also the eggs remain for a short time when exposed to sunlight and dry conditions and kill eggs when exposed to 3.75% of sodium hypochlorite for 10 minutes as well as killed when frozen at -70°C for 4 days or -80°C for 2 days or by heat larger from 60°C for 3 minutes [9].

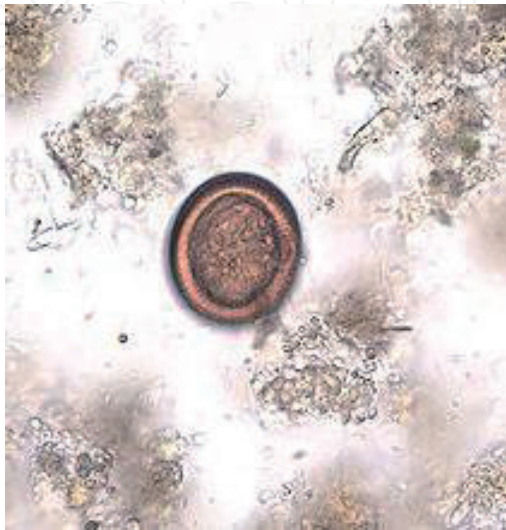

Figure 2.
E. granulosus egg in feces [7].

3. Larval stage (hydatid cyst)

When intermediate hosts (farm animals) or humans (accidental host) ingest the eggs, the embryo (oncospheres) hatches and becomes active, transmitted by the bloodstream to the liver or any other organ. As soon as the hexacanth embryo reaches its definitive position, it develops into unilocular hydatid cyst that enlarges and produces daughter cysts or protoscoleces inside the inner layer of the hydatid cyst [10, 11].

4. Transmission

Transmission to humans is caused by fecal-oral route while eating food and water contaminated with parasite eggs, and these eggs are thrown out with feces of the definitive hosts such as dogs or through contamination of hands with eggs found in contaminated soil or sand or in the hair of infected dogs. The definitive hosts become infected with the adult worm when they feed on the hydatid cysts, which are found in the organs of the intermediate host, such as infected sheep [9, 11].

5. Strains of *E. granulosus*

Species of *E. granulosus* is divided into several strains such as G1–G10 and these strains have a high degree of adaptation to their hosts, as these strains are named according to the names of their intermediate hosts that play an important role in the continuity of the life cycle of these strains. These strains vary in shape, rate of development, pathogenicity, and geographical extent of their presence: G1 is found in sheep, G2 in Tasmania sheep, and G3 in buffalo. These strains all fall within the *E. granulosus* species, and G4 strain in equine is therefore called *E. equinus*; G5 in cows is called *E. ortleppi*; G6 in camels; G7 in pigs; G9, which is characterized weak, has been isolated from cystic disease in human cases in Poland; G7, G8, and G9 may fall into *E. canadensis*, and some researchers consider the G9 strain a type of G7 strain in pigs [12].

6. Parasite classification

The classification of Echinococcus genus has been controversial for a long time, and 16 species and 13 subspecies of this genus have been described, based on the difference in the structural and phenotypic properties of the parasite and the characteristics of the host and its type, but only 4 of them are taxonomically adopted: *E. granulosus*, *E. multilocularis*, *E. oligarthrus*, and *E. vogeli* [13]. According to [14], the classification system of granulocytic parasitic parasite is as follows:

Kingdom: Animalia
Phylum: Platyhelminthes
Superclass: Eucestoda
Class: Cestoda
Subclass: Cestoda
Order: Cyclophyllidea (Ben; Braun, 1900)
Family: Taeniidae (Ludwig, 1886)

Genus: *Echinococcus* (Rud, 1801)
Species: *granulosus* (Batsch, 1786)

7. The life cycle of the parasite

The adult phases of the *E. granulosus* lives in the mucous layer of the definitive host's small intestine, and the eggs are highly resistant to harsh environmental conditions for several months or even a year depending on environmental conditions [15]. Therefore, it remains a source of infection to the intermediate hosts during drinking contaminated water and food, including humans that may also be infected by contact with infected dogs, especially in children, whereas eggs adhere to dog hair around the anus [16, 17].

The eggs reach the stomach of the intermediate host and then decompose the chitinous cortex by digestive juices and release the embryo (oncospheres) of the sixth-hooks, and the oncospheres penetrate the intestine and reach the liver, lungs, and other organs including the brain and muscles to develop into hydatid cysts at the end of about 5 months [18].

When the definitive host feeds on infected organs of the intermediate host, the parasite will reach its small intestine, where the primary heads grow into adult worms within 7–4 weeks, and each worm produces thousands of eggs per day, starting the cycle again [15] (Figure 3).

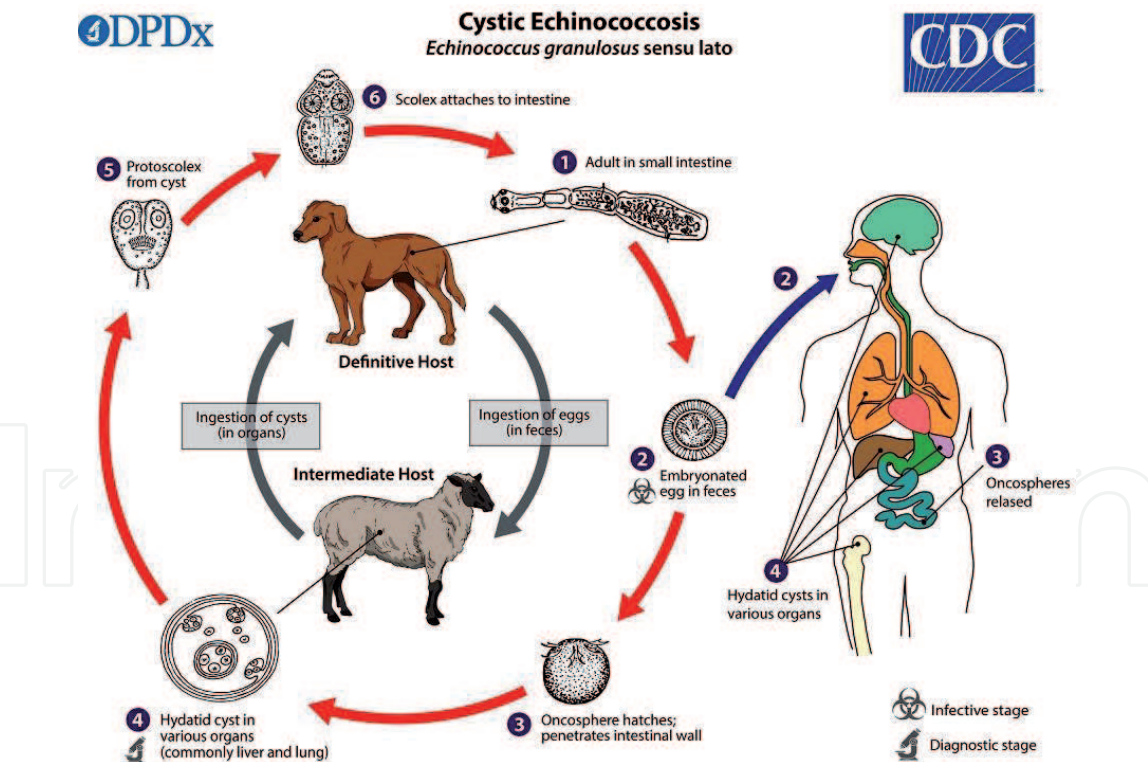


Figure 3. The adult *E. granulosus* (*sensu lato*) (2–7 mm long) **1** resides in the small intestine of the definitive host. Gravid proglottids release eggs **2** that are passed in the feces and are immediately infectious. After ingestion by a suitable intermediate host, eggs hatch in the small intestine and release six-hooked oncospheres **3** that penetrate the intestinal wall and migrate through the circulatory system into various organs, especially the liver and lungs. In these organs, the oncosphere develops into a thick-walled hydatid cyst **4** that enlarges gradually, producing protoscolices and daughter cysts that fill the cyst interior. The definitive host becomes infected by ingesting the cyst-containing organs of the infected intermediate host. After ingestion, the protoscolices **5** evaginate, attach to the intestinal mucosa, and develop into adult stages **6** in 32–80 days. Humans are aberrant intermediate hosts and become infected by ingesting eggs **2**. Oncospheres are released in the intestine **3**, and hydatid cysts develop in a variety of organs **4**. If cysts rupture, the liberated protoscolices may create secondary cysts in other sites within the body (secondary echinococcosis) [19].

8. Structure of hydatid cyst (larval stage)

The hydatid cysts (**Figure 4**) of *E. granulosus* are often spherical or semispherical if not compressed by adjacent organs. The size of the hydatid cysts varies with age, approximately 15–1 cm³ [21].

8.1 The outer (pericyst) layer

The outer layer is also called adventitia or ectocyst that encases the hydatid cyst, and this layer is produced by the host cells (modified dense fibrous protective tissue) as the host's response to the infection. There is a close interaction between the host tissue and the parasite, and this layer plays an important role in the development and survival of the cyst. Any degradation of the outer layer leads to the degeneration or explosion of the hydatid cyst; the diameters of a pericyst layer vary depending on the host organ where the hydatid is present, but in general, the diameters are about a few millimeters [22].

8.2 Laminated (medial) layer

It is a solid, noncellular chitinous layer, white in color, consisting of microfibrils and dense granules rich in amino carbohydrates observed under electron microscopy [23]. It plays a role in protecting the parasite from the immune response of host and providing the suitable environment for its continued growth in addition to its role in reducing the effect of drugs used in the treatment of the disease [6].

8.3 Germinal (inner) layer

This is the inner layer of hydatid cyst, a cellular living layer containing nuclei and associated with the lamellar layer by fingerprints formed by the germinal layer [20, 24]. It acts to protect components of the cyst and controls the osmotic pressure of the cyst wall [25]. The buds are formed from the germinal layer and grow toward the cavity of the cyst, and after the buds become vacuolated and stalked, the process of forming buds from the inner layer of cells begins from

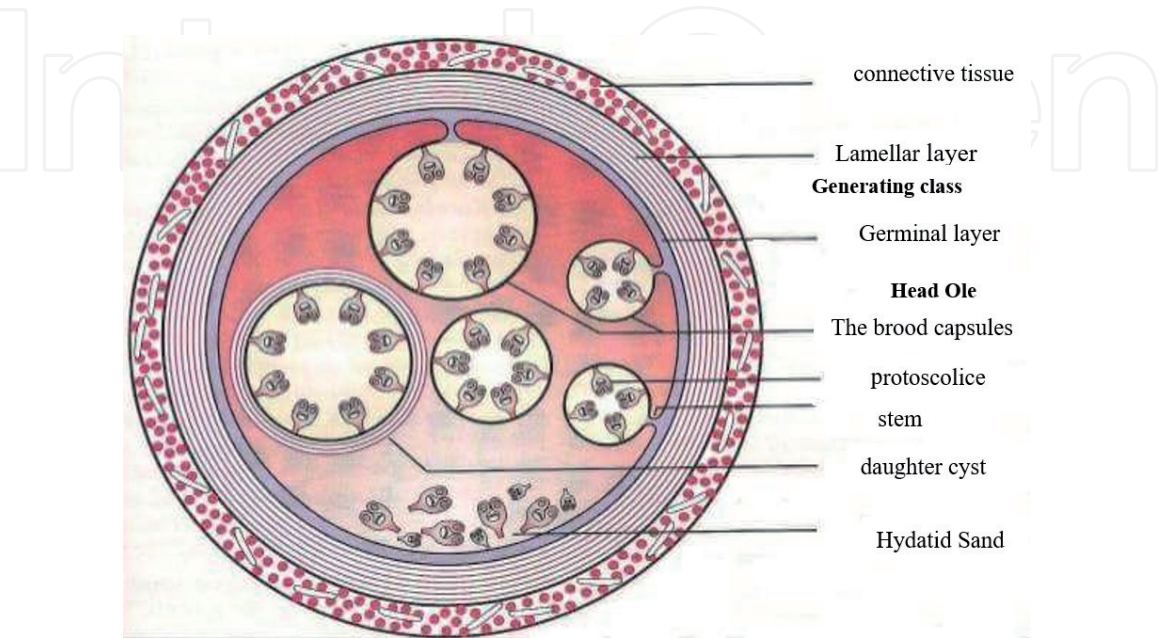


Figure 4.
Cross section in the hydatid cyst [20].

those cavities that lead to the formation of protoscolices [26]. The fertility of the aqueous cyst is determined by the presence of protoscolices, their increasing growth, and their association with the germinal layer, as well as other criteria for determining the cyst fertility through the white color and thickness of the germinal layer [27].

9. Components of hydatid cyst

9.1 Daughter vesicles (brood capsules)

These capsules consist of the generated layer by several endogenous budding, which are small buds formed from the germinal layer toward the cavity of the cyst [15]. These buds enlarge, and each capsule is connected to the germinal layer of the parental cyst by the stem. The process of budding is repeated, and each capsule contains large numbers of protoscolices, which have about 30–10 heads per capsule [28]; capsules are gradually separated from the germinal layer and float in the cyst fluid. These capsules are similar in their structure to the parental cyst [29].

The capsules may rupture and protoscolices may be released together with the free capsules, and this is the so-called hydatid sand. Occasionally, cysts are free from brood capsules when they grow in an inappropriate medium or due to bacterial invasion or calcification. The capsules are formed but do not produce protoscolices, and these are called sterile cysts, whereas capsules that produce protoscolices are called fertile cysts [14].

9.2 Hydatid sand

A term of hydatid sand refers to the contents of the hydatid cyst, which includes the daughter cysts, brood capsules, and protoscolices that present in the hydatid fluid of the *E. granulosus* [30].

9.3 Hydatid cyst fluid

It is a clear colorless or yellowish liquid with a specific weight of 1.005–1.009, a pH of 7.2–6.7, and inorganic substances such as iron, chlorine, magnesium, sodium, calcium, cadmium, nickel, chromium, copper, and some enzymes such as glutamic pyruvic transaminase (GTP), glutamic oxaloacetic transaminase (GOT), Acid phosphatase with lipase, oxidase, phosphatase, and dehydrate enzymes. They vary in quantity and quality depending on the source of the parasite and the location of the cyst and metabolism of parasites such as ammonia, bilirubin, and creatinine [31].

10. Epidemiology of *E. granulosus*

The *E. granulosus* parasite spreads almost all over the world, but it is more common in rural areas with large pastoral areas, where there are large numbers of animals that are hosts of the parasite, such as cattle, sheep, and others, with the presence of definitive hosts in these areas especially dogs [32]. Echinococcosis is a health and economic problem in most parts of the world and some studies have recorded more than 50 cases per 100,000 people annually in high endemic areas, where the prevalence of the disease in China, Argentina, and East Africa

was about 5–10%. The disease also kills about 1 million people a year around the world and also causes a loss of about \$3 billion, including treatment and livestock expenses [15, 33].

It is also highly endemic in parts of Africa, Europe, Australia, Asia, and the Mediterranean countries [34], as well as Middle Eastern countries including Iran, Saudi Arabia, Kuwait, Jordan, Palestine, Syria, Lebanon, and Iraq [35]. The epidemiology of the disease depends on the economic and agricultural factors and the level of learning and health and social culture in the human society where the parasite is spread, and what helps to spread the disease is the mixing with pets, especially dogs, in the absence of appropriate health conditions [36].

Iraq is a highly endemic country for the disease, due to the spread of loose parasite-infected dogs [37]. Although there are many recent studies of the epidemic of this disease, it is still a major health problem and is still endemic in Iraq, where there were not enough attempts to combat it despite the availability of modern conditions and equipment for diagnosis and treatment [38].

Epidemiology of hydatosis and cystic type (CE) is still on the rise due to its global distribution and high regional prevalence, and alveolar type (AE) has been observed during the past two decades and a decrease in the rate of morbidity and mortality, especially in Asia, as a result of intensive studies of epidemiology in all countries of the world [39].

11. Hydatidosis (Echinococcosis)

Hydatidosis is one of the oldest known diseases of the human being. This disease was described by the Egyptians in a document dating back to 1534 BC, as mentioned by the Babylonians in the Bible Talmud. It described the cyst as a bladder filled with fluid [40]. This disease arises from the formation of hydatid cysts of different sizes in different locations such as the liver and lungs in both animals and humans, and the severity of the disease depends on the number of cysts, size, and location. These cysts may lead to loss of human life in addition to economic losses in the field of livestock; the incidence of this disease is high in humans because its risk is that it is detected only by chance during radiological examinations or various surgical operations, but in animals, it is discovered during routine detection in massacres [1].

The cause of hydatidosis disease is due to two important factors. The first is that it is not possible to know the infection in the early stages since the onset of the disease because it does not show symptoms until the cyst has increased in size of the cyst, which puts pressure on the adjacent tissues [41]. The second factor is the loss of therapeutic means, and the disease is very similar to the severity of its metastasis in the metastasis stage [42]. These cysts are found in all parts of the body except hair and nails [43].

This disease is one of the endemic diseases in Iraq and it has an economic, social and health impact on the human, so conducted many studies and research to investigate methods of treatment, which surgical intervention is the most important of these methods, although the patient is exposed to many problems during surgery which may be difficult to perform at times and cannot be performed at other times [44, 45], or the patient is not surgically qualified or as a result of other serious diseases such as immune compromised patients or because of age or anesthesia or the occurrence of the cyst in places difficult for the surgeon to deal with, such as in the cysts of the heart, brain or spine, so the importance of the use of extracts of a different chemical nature treatment of aquatic cyst disease [46].

12. Clinical symptoms of hydatidosis

Hydatid cyst disease (HCD) is slow at the onset of infection and unseen due to slow growth and development of the cyst, which reaches a diameter of about 10–1 mm per year [33]. The appearance of clinical signs depends on the location of the affected organ, the size of the cyst, its location within the affected organ, the stages of its development, and the fertility of its components with the interaction between the related cysts between adjacent organs, especially between the hepatic vessels and bile ducts [47]. In humans, the symptoms are dependent on the affected organ, and the liver is the most exposed organ, with a rate of about 70–60%, followed by lungs 22–20%, spleen, heart, muscles, eye, and thyroid gland 6%, and the kidneys, brain, and bones 1% and don't hardly any organ of body free from hydatid cyst except teeth, nails and hair [48].

Symptoms in the liver are: an enlarged, and it becomes sensitive when palpated with liver abscesses, in addition abdominal pain, vomiting and nausea, as well as an increase in hepatic blood pressure and in cavity of the lower vena cava also there secondary fibrosis in the ducts bile, the hydatid cyst causes significant pressure on the diaphragm when adhesion to it and leads to a breach and exit of the contents of the cyst in the chest [49]. In the lung, clinical symptoms depend on the size of the cyst and its condition whether it is healthy or torn, causing the presence of pressure of cyst inside the lobes of the lung [50] with varying severity of chest pain and coughing, hemoptysis, shortness of breath, and hemorrhage, and in the lungs, these symptoms do not appear at the first sight of the disease [51–53]. When the cyst penetrates into the pulmonary vesicles, it is a suitable environment for fungal and bacterial infections, leading to pneumonia after infection and thus destroying the lung [54].

The explosion of the hydatid cyst inside the abdominal cavity leads to a shock known as anaphylactic shock due to acute allergic reactions, and this shock leads to the severe spread of secondary cysts in the affected organ and adjacent organs, and is sometimes followed by the explosion of the cyst at any site within the body leaking its contents into the blood circulation that leads to headaches and other complications that may lead to sudden death [28].

The symptoms develop even when the cyst is small, and most cases of cerebral cyst disease were diagnosed in children [11]. This infection is serious that sometimes it leads to death; cysts in the eye are rare and cause an external tumor of the eye, dysfunction of vision, exophthalmoses, and sometimes blindness around the eyelid [17].

In the bones, cystic hydatid disease often leads to fracture because of the gradual erosion of the cortex and shows symptoms in the form of pain in the upper and lower extremities, and bone bags are abnormal in the form where the laminar layer does not form [55].

In animals, the infection is hidden, and they may be slaughtered sometimes before the onset of symptoms [56]. The severity of the symptoms varies depending on the severity of the disease and the location of the hydatid cyst. Clinical signs generally appear in the affected animal such as decrease in milk production, poor wool, and organ damage in the affected area [57, 58].

13. Conclusion

The current review included the identification of the *E. granulosus* worm and its intermediate and final hosts. The canine family represents the final host, while the human and farm animals represent the intermediate hosts. Several strains of *E. granulosus* were also observed such as G1, G2, G3, G4, G5, G6, G7, G8, G9, and G10.

Acknowledgements

The authors thank the Central Library, Library College of Science/University of Al-Qadisiyah, for providing them with the references adopted in this chapter.

Author details

Khadeeja Abees Hmood Al-Khalidi^{1*}, Hiba Riyadh Al-Abodi¹, Hayder Kamil Jabbar² and Baheeja A. Hmood²

¹ Department of Environment, College of Sciences, University of AL-Qadisiyah, Iraq

² Department of Medical and Basic Science, College of Nursing, University of AL-Qadisiyah, Iraq

*Address all correspondence to: khadeeja.abees@qu.edu.iq; khadeejaalkhalidi@gmail.com

IntechOpen

© 2020 The Author(s). Licensee IntechOpen. This chapter is distributed under the terms of the Creative Commons Attribution License (<http://creativecommons.org/licenses/by/3.0>), which permits unrestricted use, distribution, and reproduction in any medium, provided the original work is properly cited. 

References

- [1] Arafa MI. Hydatids vesicular disease in humans and animals, the growing disease in the spread. *Assiut Journal of Environmental Studies*. 2003;(12):181-188
- [2] Siracusano A, Delunardo F, Teggi A, Ortona E. Cystic echinococcosis: Aspects of immune response, immunopathogenesis and immune evasion from the human host. *Endocrine, Metabolic & Immune Disorders—Drug Targets*. 2012;12(1):16-23
- [3] Mandal S, Mandal MD. Human cystic echinococcosis: Epidemiologic, zoonotic, clinical, diagnostic and therapeutic aspects. *Asian Pacific Journal of Tropical Medicine*. 2012;5(4):253-260
- [4] Brozova A, Jankovska I, Bejcek V, Nechybova S, Perinkova P, Horakova B, et al. *Echinococcus* spp.: Tapeworms that pose a danger to both animals and humans—A review. *Scientia Agriculturae Bohemica*. 2017;48(8):193-201
- [5] Patkowski W, Krasnodebski M, Grat M, Masior L, Krawczyk M. Surgical treatment of hepatic *Echinococcus granulosus*. *Przegląd Gastroenterologiczny*. 2017;12(3):199-202
- [6] Al-Qaisi GHJ. The effect of immune activation in reducing the pathogenicity *Echinococcus granulosus* in mice [master thesis]. Faculty of Education, University of Diyala
- [7] Available from: <https://en.wikipedia.org/wiki/Echinococcosis>
- [8] John DT, Petri WA. Markell and Voge's Medical Parasitology. 9th ed. United States of America: Elsevier; 2006. 468p
- [9] Krauss H, Weber A, Appel M, Enders B, Isenberg H, Schiefer HG, et al. Parasitic zoonoses. In: *Zoonoses: Infectious Diseases Transmissible from Animals to Humans*. 3rd ed. Washington, DC: ASM Press; 2003. pp. 334-343
- [10] Badley AD, Steckelberg JM, Wilson WR. Cestodes. In: Wilson WR, Sande MA, editors. *Current Diagnostics and Treatment in Infectious Diseases*. United States: McGraw Hill; 2001
- [11] Moro P, Schantz PM. Echinococcosis: A review. *International Journal of Infectious Diseases*. 2009;13(2):125-133
- [12] Centers for Disease Control and Prevention (CDC). Available from: <http://www.dpd.cdc.gov/dpdx/HTML/Echinococcosis.htm>, <https://www.cdc.gov/dpdx/az.html>, <https://www.cdc.gov/dpdx/echinococcosis/index.html>
- [13] McManus DP. Current status of the genetics and molecular taxonomy of *Echinococcus* sp. *Parasitology*. 2013;140(13):1617-1623
- [14] Rahman WA, Elmajdoub LE, Noor S, Wajidi MF. Present status on the taxonomy and morphology of *Echinococcus granulosus*. 2015
- [15] Higueta NIA, Brunetti E, McCloskey C. Cystic echinococcosis (Review). *Journal of Clinical Microbiology*. 2016;54(3):518-523
- [16] Yang S, Zhao Y, McManus DP, Yang Y. Current research advance on Echinococcosis. In: *Echinococcosis*. IntechOpen; 2017. pp. 9-23
- [17] Thatte S, Thatte S. Ocular hydatid cyst. *Annals of Clinical Pathology*. 2016;4(5):1-5
- [18] FAO Manual on Meat Inspection for Developing Countries. Available from: <http://www.fao.org/docrep/003/t0756e/t0756e00.htm>

- [19] Available from: <https://www.cdc.gov/parasites/echinococcosis/biology.html>
- [20] Thompson RCA, McManus DP. In: Eckert J, Gemmell MA, Keslin FX, Pawlawski S, editors. Aetiology: Parasite and Live-cycles. 2001
- [21] Salhi SFC. Study of biochemical changes in serum of sheep with hydatosis disease in liver [higher diploma]. College of Veterinary Medicine, University of Al-Qadisiyah; 2011
- [22] Golzari SEJ, Sokouti M. Pericyst: The outermost layer of hydatid cyst. World Journal of Gastroenterology. 2014;**20**(5):1377-1378
- [23] Muller N, Frei E, Nunez S, Gottstein B. Improved serodiagnosis of alveolar echinococcosis of humans using an in vitro-produced *Echinococcus multilocularis* antigen. Parasitology. 2007;**134**(6):879-888
- [24] Arora K. Liver and intrahepatic bile ducts—Nontumor infection infectious (nonviral) disorders. Echinococcal cyst. 2017. Retrieved from: <http://www.pathologyoutlines.com/liver.html>
- [25] Al-Omari MM. Effect of stamper and myrtle extracts on the vitality and growth of *Echinococcus granulosus* primates of human and sheep origin and growth in vivo [master thesis]. College of Education, Mosul University; 2005
- [26] Mario G, Mjulieta G, Norbel G. *Echinococcus granulosus* protoscolex formation in natural infections. Biological Research. 2002;**35**(3-4)
- [27] Bortoletti G, Ferrett G. Ultrastructural aspects of fertile and sterile cysts of *Echinococcus granulosus* developed in hosts of different species. International Journal for Parasitology. 1978;**8**:421-443
- [28] Bogitsh BJ, Carter CE, Oeltmann TN. Human Parasitology. Academic Press; 2013. pp. 254-265
- [29] Mehlhorn H. Encyclopedic Reference of Parasitology. Berlin: Springer; 2008
- [30] Chiou MT, Wang F-I, Chang PH, Liu C-H, Jeng CR, Cheng CH, et al. Hydatidosis in a Chapman's zebra (*Equus burchelli antiquorum*). Journal of Veterinary Diagnostic Investigation. 2001;**13**:534-537
- [31] Taher AJ. Blood, biochemical and immunological study of patients with echinococcosis [master thesis]. College of Education (Ibn Al Haytham), University of Baghdad; 2009
- [32] Craig PS, Li T, Qiu J, Zhen R, Wang Q, Giraudoux P, et al. Echinococcosis and Tibetan communities. Emerging Infectious Disease. 2008;**14**(10):1674-1675
- [33] Pakala T, Molina M, Wu GY. Hepatic echinococcal cysts. Journal of Clinical and Translational Hepatology. 2016;**4**(1):39-48
- [34] McManus DP, Gray DJ, Zhang W, Yang Y. Diagnosis, treatment, and management of Echinococcosis. British Medical Journal. 2012;**344**(7861):39-44
- [35] Nasrieh MA, Abdel-Hafez SK, Kamhawi SA. Cystic echinococcosis in Jordan: Socioeconomic evaluation and risk factors. Parasitology Research. 2003;**90**:456-466
- [36] Al-Shahwani TA. The effect of some plant extracts on the vitality of protoscoleces of *E. granulosus* of sheep origin and its growth within vivo [master thesis]. University of Mosul; 2010. 160 p
- [37] Kshash QH. Study of some epidemiological aspect of important endemic parasitic diseases in

Al-Qadisiyah province. Basrah Journal of Veterinary Research. 2005;4(2):72-79

[38] Al-Saimary IE, Al-Shemari MN, Al-Fayadh MMA. Epidemiological and immunological findings on human hydatidosis. Journal of Medical Practice and Review. 2010;1:26-34

[39] Deplazes P, Rinaldi L, Alvarez Rojas CA, Torgerson PR, Harandi MF, Romig T, et al. Global distribution of alveolar and cystic echinococcosis. Advances in Parasitology. 2017;95:315-493

[40] Sabau AD. Laparoscopic Surgery for Hepatic Hydatid Cyst. Lucian Blaga University of Sibiu, Victor Papilian Faculty of Medicine; 2011

[41] Andersen FI, Tolly HD, Shantz PM, Ding Z. Cystic echinococcosis in the Xinjiang/Uygur Autonomous Region, People's Republic of China. II. Comparison of three levels of a local preventive and control program. The Journal of Tropical Medicine and Parasitology. 1991;42:1-10

[42] Novak M. Efficacy of mitomycin against alveolar *Echinococcus*. International Journal for Parasitology. 1990;20:119-120

[43] Al-Gharawi AKH. Phenotypic study to determine some strains of *Echinococcus granulosus* in sheep, cows and goats in Salah al-Din Governorate, Iraq [master thesis]. College of Education, Tikrit University; 2004. p. 88

[44] Menten A, Yalaz S, Killi R, Altintas N. Radical treatment for hepatic echinococcosis. HPB. 2000;2(1):49-54

[45] Elissondo MC, Dopchiz MC, Denegri G. Human hydatidosis in Mar del Plata, Buenos Aires Province, Argentina (1992-1995): A preliminary study. Parasitología Latinoamericana. 2002;57:124-128

[46] Al-Humairi AKO. Evaluation of efficacy of *Datura stramonium* seed extract on growth and development of hydatid cysts of *E. granulosus* protein cysts in Balb/c eggs (Pharmacological, Histological and Immunological Study) [PhD thesis]. Faculty of Science, University of Kufa; 2010. p. 2

[47] Ammann R, Eckert J. Clinical diagnosis and treatment of Echinococcosis in humans. In: Thompson RCA, Lymbery AJ, editors. *Echinococcus* and Hydatid Disease. Wallingford, UK: CAB International; 1995. pp. 411-451

[48] Marquardt WC, Demaree RS, Grieve RB. Parasitology and Vector Biology. 1st ed. London: Harcourt/Academic Press; 2000

[49] Brunetti E. Echinococcosis hydatid cyst medication. Medscape. 2015. Retrieved from: <http://emedicine.medscape.com/article/216432-medication>

[50] Alloubi I. Thoracic hydatid cyst: Clinical presentation, radiological features and surgical treatment. In: Principles and Practice of Cardiothoracic Surgery. IntechOpen; 2013. pp. 195-217

[51] Brunetti E, Filice C. Echinococcosis hydatid cyst. Medicine. 2007;1-23

[52] Cobzaru RG, Popa GT. Historical aspects regarding the regarding the hydatic disease. Section: Social Sciences, Psychology, Sociology and Education Sciences. 2016;16(7):103-107

[53] Ekim M, Yilmaz H, Ekim H, Tuncer M, Ozdemir Z. Importance of laboratory tests in the diagnosis and follow up of patients with intrathoracic hydatidosis. Journal of International Research in Medical and Pharmaceutical Sciences. 2016;6(2):57-62

[54] Albadawi AAM. Molecular and serological studies on cystic hydatid infection in man and camels in Sudan [PhD thesis]. Sudan University of Science and Technology; 2017

[55] Song XH, Ding LW, Wen H. Bone hydatid disease. Postgraduate Medical Journal. 2007;**83**(982):536-542

[56] Al-Khafaji AMAR. Study of pathological and biochemical changes of cyst disease in humans, sheep and cows in Al-Diwaniya city [master thesis]. College of Veterinary Medicine, University of Al-Qadisiyah; 2006

[57] Eckert J, Deplazes P. Biological, epidemiological and clinical aspects of echinococcosis a zoonosis of increasing concern. Clinical Microbiology. 2004;**17**(1):107-135

[58] Eddi C, de Katalin B, Juan L, William A, Andrew S, Daniela B, et al. Veterinary public health activities at FAO: Cysticercosis and echinococcosis. Parasitology International. 2006;(55):305-308