

We are IntechOpen, the world's leading publisher of Open Access books Built by scientists, for scientists

6,900

Open access books available

186,000

International authors and editors

200M

Downloads

Our authors are among the

154

Countries delivered to

TOP 1%

most cited scientists

12.2%

Contributors from top 500 universities



WEB OF SCIENCE™

Selection of our books indexed in the Book Citation Index
in Web of Science™ Core Collection (BKCI)

Interested in publishing with us?
Contact book.department@intechopen.com

Numbers displayed above are based on latest data collected.
For more information visit www.intechopen.com



Role of Hybrid Operating Room: Present and Future

Evan Qize Yuan and Calvin Sze Hang Ng

Abstract

With the dramatic progress of medical imaging modalities and growing needs for high-resolution intraoperative imaging in minimally invasive surgery, hybrid operative room (OR) has been developed as a powerful tool for different surgical scenarios. Under the guidance of high-definition cone beam CT (CBCT), an electromagnetic navigation bronchoscopy (ENB)-based marker implantation and subsequent localization of the pulmonary nodules can be implemented within a hybrid OR. Furthermore, the unparalleled real-time imaging capabilities and the ability to perform multiple tasks within the hybrid OR can facilitate image-guided single-port video-assisted thoracic surgery (iSPVATS), increasing the precision and improving outcomes of the procedure. With the help of a hybrid theatre, catheter-based thermal ablation can provide a safer and less invasive treatment option for select patient groups with early-stage non-small cell lung carcinomas (NSCLC) or metastases. In the future, the combination of hybrid operating room and other inspiring innovative techniques, such as robotic bronchoscopy, 3D-printing, natural orifice transluminal endoscopic surgery (NOTES) lung surgery could lead to a paradigm shift in the way thoracic surgery is conducted.

Keywords: 3-D printing, ablation, cone beam CT, electromagnetic navigation bronchoscopy, hookwire, hybrid operating room, localization, lung cancer, metastases, non-small cell lung carcinoma, natural orifice transluminal endoscopic surgery, robotic bronchoscopy, single-port video-assisted thoracic surgery

1. Introduction

In recent decades, thoracic surgery has undergone revolutionary progress. With the help of imaging technology, surgeons can perform minimally invasive surgery through several small incisions instead of thoracotomy [1]. With the advantages of less pain, quicker recovery, fewer postoperative complications and better cosmesis, minimally invasive surgery has gradually become the mainstream of thoracic disease treatment [2]. Among the many techniques, the single-port video-assisted thoracic surgery (VATS) is becoming more and more popular in recent years [3–5]. When combined with medical imaging techniques and adjuvant instruments, such as computed tomography (CT) guided placement of hookwire/microcoil or dye labeling for localization, the single-port VATS can safely be used to resect lung lesions in a less invasive way [3, 6]. However, there exist some deficiencies in the traditional mode of treatment paradigms, in which the imaging and surgery are operated in separate chambers. The time interval between adjunctive localization techniques conducted under computed tomography guidance and

surgery may increase the risk of pneumothorax and wire migration or dislodgement [7]. Moreover, by performing procedures in multiple localities with the risks as described could increase the complexity of care and cost. The emergence of hybrid operating room (OR) provides patients with a less invasive diagnostic and therapeutic option [8]. By conducting the localization and the lung surgery in a hybrid operating room, the rate of pneumothorax, marker dislodgement, and dye diffusion can be minimized, with decreased procedural time and lower costs [3]. More importantly, thoracic surgeons will be able to conduct precise excisions in a much more secure way, even for multifocal lesions, preserving pulmonary tissue and function because of this innovative approach for diagnosing and localizing the nodules [8].

2. What is a hybrid operating room?

The “hybrid operating room (OR)” concept consists of a surgical workspace that integrates imaging devices with a multifunctional surgical table. It allows surgeons to perform diagnostic and therapeutic procedure in a single room, reducing risks caused by delay and patient transfer [9]. Moreover, it is a potentially safer and time-saving option for patients facing different medical situations [10]. Despite its wide utilization in many medical fields, cardiology and vascular surgery in particular, the first hybrid operating room (advanced multimodal image-guided operating [AMIGO] suite) for general thoracic surgery was only reported in 2013 by Professor Raphael Bueno’s group at Harvard University, Brigham and Women’s Hospital, Boston [11]. Equipped with three functional compartments that incorporate magnetic resonance imaging (MRI), near-infrared imaging, cone-beam computed tomography (CBCT), and positron emission tomography (PET), the 5700-square-foot AMIGO suite is capable of providing sterling real-time imaging of the patients undergoing different types of surgeries.

In the subsequent year, a reduced scale hybrid theater (Artis zeego, Siemens Healthcare GmbH, Erlangen, Germany) was set up in the authors’ hospital [12]. Similarly, this suite can provide imaging support for different types of surgical scenarios, making it possible for the surgeons to conduct image-guided electromagnetic navigation bronchoscopy (ENB) and VATS procedures. The robotic C-arm CBCT can move flexibly without affecting the surgical procedure. It is worth mentioning that this operating room has a relatively smaller area (approximately 760 square feet), which is meaningful when it comes to space-saving considerations. The complete content of the hybrid operating room is listed in **Table 1** [12].

In the same year, a hybrid operating room consisting of a mobile O-arm CT scan system (Medtronic Japan Co., Ltd., Tokyo, Japan) was reported by Ohtaka’s et al. in Japan [13]. The team managed to conduct localization for small pulmonary nodules in their newly established hybrid suite. Nevertheless, limiting radiation exposure to the patient and its time-consuming characteristic remain to be resolved.

In 2017, Ujiie’s group introduced their multiple detector CT (MDCT) (Definition FLASH; Siemens, Washington, DC, USA) system assembled within a hybrid operating room [14]. With the assistance of the novel minimally invasive near-infrared thoracoscopic technique, they successfully localized small lung nodules of the patient. Although the imaging of the target lesion and the surgery were conducted in the same hybrid operating room, the possibility of wire dislocation and complication caused by patient transfer was not decreased.

Chao et al. also in 2017 described an imaging guided thoracoscopic resection of a ground-glass opacity lesion by percutaneous hookwire localization, which is performed in a hybrid operating room equipped with a robotic C-arm CT (Artis zeego,

Artis zeego multi-axis robotic imaging system (Siemens Healthcare AG, Forchheim, Germany) with PURE™ Platform
Free-floating Artis OR table
Large display mounted on rails
syngo X Workplace (Siemens Healthcare AG, Forchheim, Germany)
Steris OR lamps
Dräger anesthetic workplace & Dräger Motiva supply unit
Olympus and Karl-Storz endoscopic systems with near-infrared capabilities
Medtronic SuperDimension™ navigation system (Covidien, Minneapolis, MN, USA)
Emprint™ Microwave Ablation System (Medtronic, USA)
2.5 m × 2.5 m (8.2 ft × 8.2 ft) laminar airflow field

Table 1.
Configurations of the hybrid operation room (OR) (Prince of Wales Hospital, Hong Kong).

Year	Authors	Imaging device
2013	Bueno et al. [11]	CBCT, MRI, PET, near-infrared imaging
2014	Ng et al. [12]	Robotic C-arm CBCT
2014	Ohtaka et al. [13]	O-arm CT
2017	Ujiie et al. [14]	Multiple detector CT (MDCT)
2017	Chao et al. [15]	Robotic C-arm CBCT

Table 2.
Summary of recently reported hybrid OR for image-guided thoracic surgery.

Siemens Healthcare GmbH, Erlangen, Germany) system [15]. The C-arm CT is considered better than MDCT and O-arm CT because of its flexibility and ability to perform circumferential scanning around the surgical table. However, there are still several limits of the single-stage approach, such as the availability of the high-cost hybrid OR, the time-consuming and complicated repositioning of the C-arm instrument, and the risk of air embolism because of needle placement (**Table 2**) [16].

3. Current needs in thoracic surgery

With the popularization of lung screening by chest computed tomography (CT), the detection rate of pulmonary nodules continues to rise [17]. According to a previous study by Gill, for about 8–51% of patients screened on a CT scan, it is unclear that whether their detected pulmonary nodules are benign or malignant [18]. Since early detection and subsequent treatment for lung cancer can reduce mortality [19], the efficient and rapid identification of the nodules' nature has become an increasing challenge for both thoracic clinicians and researchers. Despite the emergence of many innovative techniques which can potentially assist in the diagnosis of pulmonary nodules, the most reliable diagnosing method is surgical excision biopsy with pathological section [20]. Compared with conventional multiport VATS or open biopsy procedure, single-port video-assisted thoracoscopic surgery (VATS) can provide a less invasive way to the resection of pulmonary nodules [3, 6]. However, there are some inherent drawbacks in SPVATS. First, the single-port approach increases the difficulty in localizing the target lesion with limited access for finger palpation

[10] and surgical instrument manipulation within a small incision [21]. Palpating a small lung lesion via minimally invasive access wounds is especially challenging when the lesion is located in a spot far from the pleural surface or it consists of part-solid component with high ground-glass opacity (GGO) [22].

Several techniques have been developed to aid the identification of lung nodules. The conventional two-stage approach for localization of pulmonary nodules includes two steps: image guided preoperative adjunctive localization of the lesion such as hookwire/microcoil implantation or dye marking, and subsequent resection of the nodule in a surgery suite [23]. However, in the procedure of metallic implantation, the metallic bar or hookwire may dislocate during the transfer of the patient to the OR or during the surgical procedure. The lung deflation or the retraction of the wire by the operator can also cause the displacement of the marker [22]. As for dye marking, the diffusion of the dye contrast over time will increase the risk of failure localization. In addition, allergy and embolism are two important side effects of this localizing method which may cause serious consequences [24]. The application of a hybrid operating room can implement the localization and therapeutic procedure within a single room, which can not only save time and cost, but also reduce the rate of pneumothorax, marker dislocation, and dye diffusion [25].

4. Localization via percutaneous approach

As mentioned above, many localization techniques have been developed to help thoracic surgeons with navigation to the pulmonary nodules. By combining the imaging method with adjunctive instruments, such as hookwire or dye marking, the target lesion can be marked in different ways. The family of localization markers can be classified as two types: physical markers, such as hookwire and metallic fiducials, and chemical markers, such as dye marking and radionuclide labeling.

4.1 Hookwire and metallic markers

As the most commonly used localization method for small pulmonary lesions, hookwire has a place in thoracic surgery because of its high success rate [26–28]. Hookwires have long been used in marking breast lesions and relatively solid breast tissues. It was then applied to pulmonary nodules localization by radiologists and thoracic surgeons inspired by its success in treating breast diseases [29]. In a conventional preoperative localization approach, the hookwire is usually inserted into the chest at a radiology suite a few hours before the surgery to facilitate lung nodule localization; however, problems remain such as hookwire migration, pneumothorax, hemothorax, patient discomfort, and potential cost due to the patient transfer between different suites [30]. According to a recent study by Yasufuku et al., around 24% of the patients that underwent hookwire implantation would suffer from pneumothorax. Likewise, the metallic markers are usually implanted before the procedure through percutaneous path and detected by intraoperative fluoroscopy, or occasionally may be palpated [31, 32]. They have the same drawbacks as hookwires (post-procedural pain, pneumothorax, hemothorax, air embolus). When the hookwire or the metallic marker insertion is performed within the hybrid OR setting, their potential complications and risks can be minimized by reducing transfer time which equals “at risk” time for those complications to develop (**Figure 1**). The authors’ team has developed a treatment paradigm for small nodules or those with GGO components, known as image guided single-port VATS (iSPVATS) [7]. In their approach, the discussed disadvantages of metallic markers are decreased due to a shortened delay between the localization and the surgery.

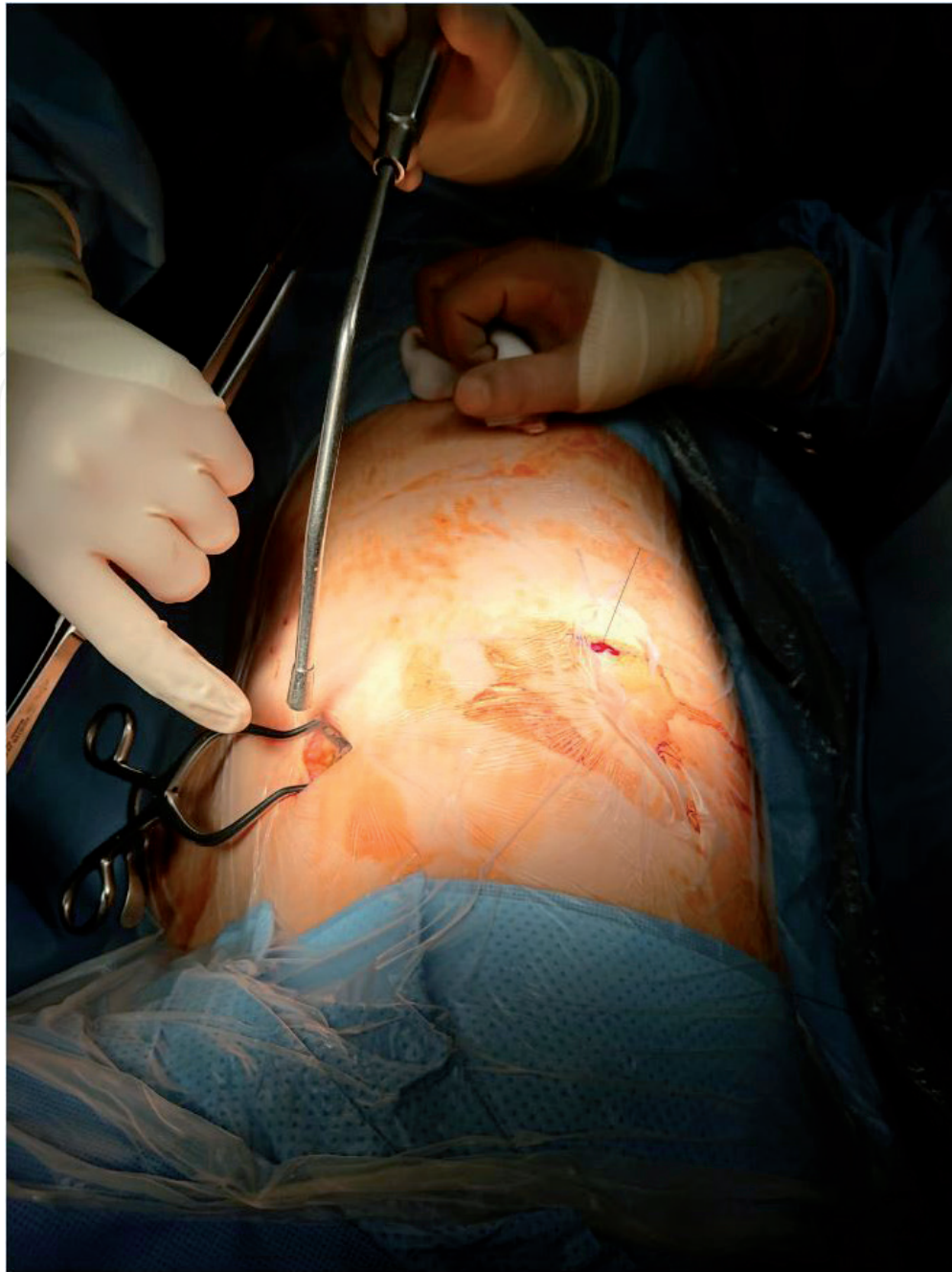

Figure 1.
Patient undergoing uniportal VATS lung resection following posterior hookwire placement in hybrid operating room.

Moreover, if the marker dislodgement happens accidentally, the real-time imaging ability of the hybrid OR allows for a salvage CT scan to be performed to re-localize the target spot.

4.2 Dye marker

Different from hookwire, the dye markers, including methylene blue, barium sulfate, lipiodol and others, are normally injected into the tumor region to help the surgeons localize the lesion usually via either direct vision through a white-light thoracoscopy or fluoroscopy [22]. This marking method also has pleural complications due to the invasive percutaneous approach; besides, it can also be affected by the diffusion of the dye into the parenchyma, and spillage into the pleural cavity leading to difficulty or failure of localization for surgery. More recently, indocyanine green (ICG) has been used as a dye, particularly for deeper lesions as

the fluorescence using near infra-red light thoracoscopy could be seen up to 2 cm from pleura. Numerous methods have been described to reduce diffusion of dye into parenchyma over time, include mixing the dye with albumin, biological glue or lipiodol. Other important issues of the percutaneous dye approach are possible allergy and air embolism during the injection of the dye marking which may cause serious and even life-threatening sequelae. An early study on 25 patients undergoing image-guided percutaneous dye localization in the hybrid OR was reported by a group in Taiwan [33]. During the procedure, cone-beam CT was applied for the confirmation of the successful injection. Nevertheless, the drawbacks described before, though rare could still occur; and furthermore, nodules that are located near the apex, diaphragm and mediastinum are often difficult or risky to approach from percutaneous route.

5. Localization via endobronchial approach

5.1 Electromagnetic navigation bronchoscopy (ENB)

Electromagnetic navigation bronchoscopy (ENB) is a superior bronchoscopic technique utilizing electromagnetic sensor technology to facilitate the navigation of the probe to the target region [34]. The typical technological process of an ENB-assisted biopsy or marking includes:

1. Navigational stage implemented by “electromagnetic sensor technology in combination with virtual three-dimensional (3D) bronchial reconstruction of CT images that can be paired with the true bronchoscopic images” [34].
2. The lock of extended working channel (EWC) after successful navigation and withdrawing the sensor tip.
3. The delivery of different tools for biopsy or marking the lesions.

Over the last ten years or so, this approach has been developed into a powerful tool for localization and following diagnosis of the peripheral pulmonary lesions [35]. Success rate of nodule localization can be as high as 93% when combining ENB with endobronchial ultrasound [36]. Nevertheless, identifying a small lesion with a high GGO component can be a challenging task for ENB with adjunctive methods such as endobronchial ultrasound and standard fluoroscopy [5]. To improve the performance of ENB-related techniques, the author's group developed an innovative paradigm which combines the ENB with cone-beam computed tomography (CBCT) [37] (**Figure 2**). The steps of this new approach are as following:

1. Standard ENB-guided localization.
2. Anchoring of EWC.
3. Switch-off of ENB system.
4. Activation of CBCT.
5. A 6-second CBCT scan allows visualization of the target lesion, adjacent structures, and the relative position of the EWC and tools.

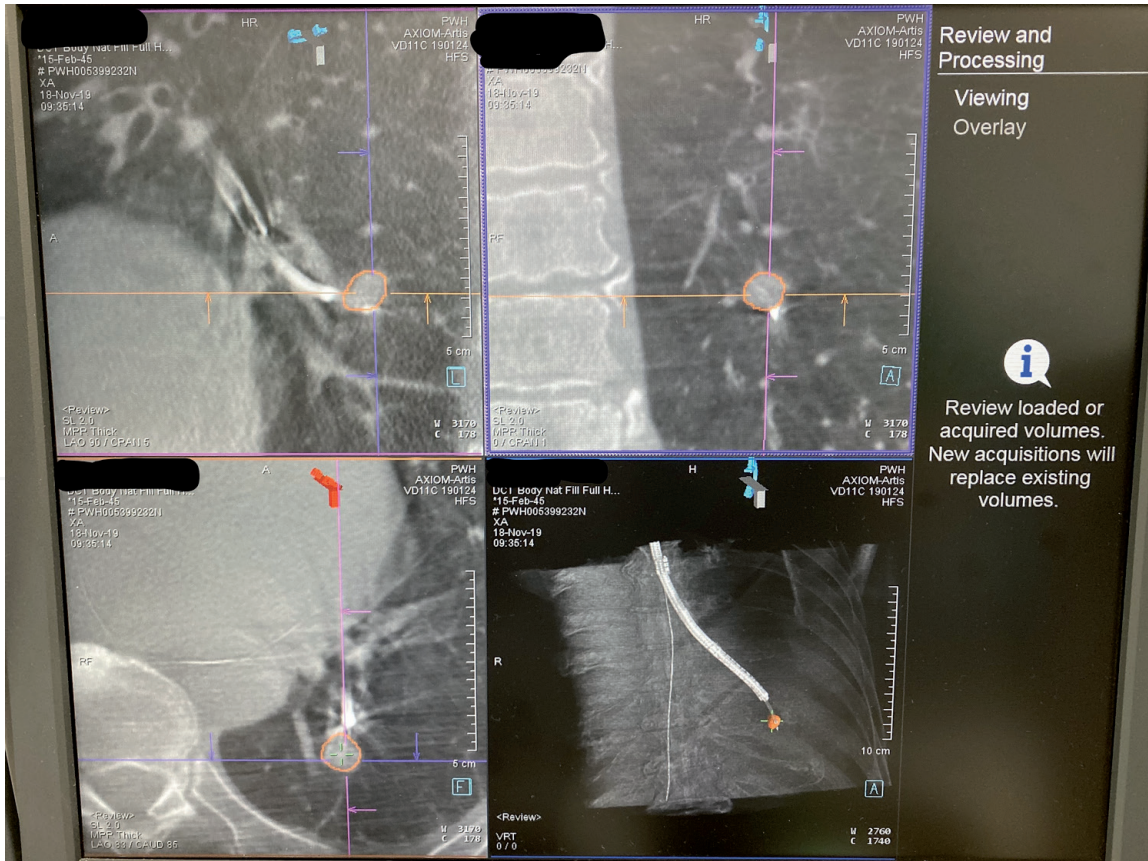


Figure 2.
Cone-beam CT images from hybrid OR showing successful left lower lobe 9 mm nodule electromagnetic navigation bronchoscopy biopsy guided by cone-beam computed tomography scan and assistance from PURE™ platform segmentation software.

Notably, two CBCT scans during the procedure would provide the best outcomes: the first CBCT is the pre-procedure scan that provides the latest information on positional relation of the lesion to allow software (such as i-guide, Siemens, Germany) to mark your lesion, while the second CBCT is for confirming whether the biopsy tool or marker has been deployed in the right position. This technique has been applied on 12 patients with nodules from 8 mm to 39 mm. There is no complication found, and the diagnostic rate was 83.3% [38].

5.2 Metallic marker

The utilization of ENB has been broadened in recent years to encompass enabling adjunctive therapies and direct therapies. Apart from the navigation system for biopsy, it can also be used to assist in the placement of different kinds of markers. Fiducials are dense markers made of gold or platinum, and they are often used for simultaneous tumor tracking due to its imaging characteristics, to aid in specialized targeted radiotherapies and surgery, in particularly for lesion localization. Anantham's group reported ENB-guided insertion of 39 metallic fiducials into 9 patients for robotic stereotactic radiosurgery of lung tumors. Not surprisingly, dislodgement is one of the major problems of this approach [39]. In addition, the small risk of allergic reaction and complications arising from the prolonged duration of implantation of these markers are also issues to be considered when placing these markers.

5.3 Dye marker

Apart from metallic materials, dye markers have also been developed as a combination with ENB for localization of lung nodules. Bolton et al. reported dye

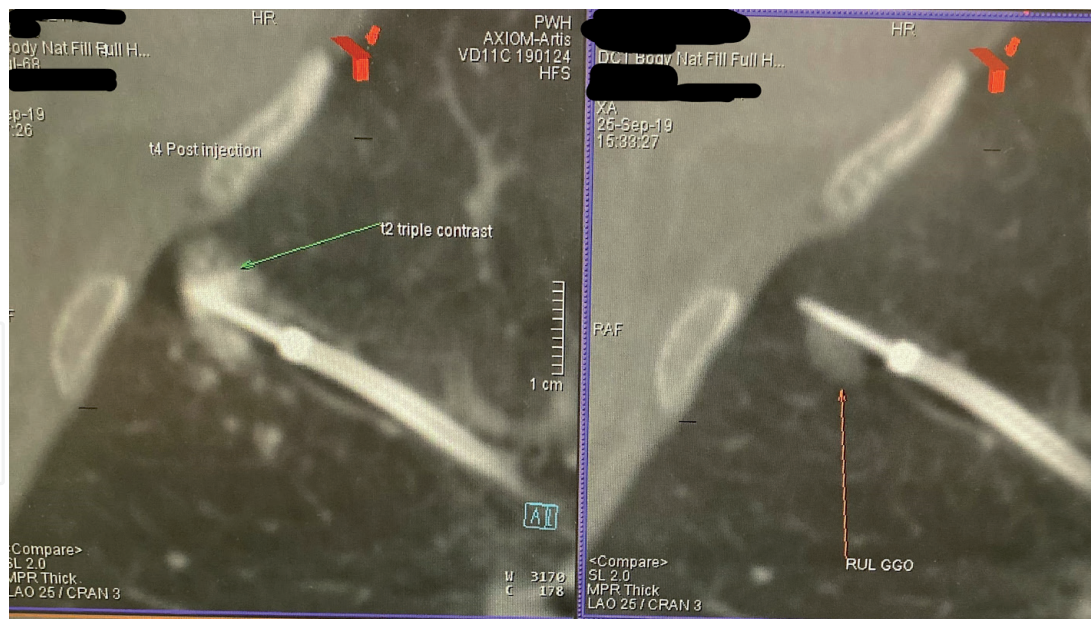


Figure 3.

Cone-beam CT images of dye marking of right upper lobe 7 mm nodule for surgical resection. The right image is the deployed injection needle before injection of dye while the left image is the CT immediately after injection of dye.

marking via ENB under fluoroscopic assistance for 19 subjects. In this case, methylene blue was injected into the target lesion, and the use of intraoperative fluoroscopy is required as confirmation of a successful localization [40]. Dye marker injection by ENB in the hybrid operating room setting can lead to a lower risk of dye diffusion as the time interval between injection and surgery can be reduced.

In 2016, Marino et al. studied ENB-guided trans-bronchial dye injection followed by VATS sublobar resection [41]. Among all the 72 lung nodules ranging from 4 mm to 17 mm, 70 were identified successfully. Notably, an extra shot of methylene blue was injected to the pleura once it is confirmed that the distance between the nodule and the surface of the pleura is over 4 mm. It is believed that the application of hybrid OR technique will improve the success rate of dye placement and enables the precise visualization of the margin of the tumor [41].

In recent years, the fluorescent dye indocyanine green (ICG) has been applied in medical research including optical mapping of cardiac activity, measurements of liver blood flow and ophthalmology [42, 43]. In 2018, Wen's team reported their ICG marking in the hybrid OR for 26 patients with pulmonary nodules [44]. The ICG can remain at the target spot for more than six hours in vivo, and the near-infrared (NIR) light thoracoscopy can detect the dye's wavelength without being affected by the color change of the visceral pleura due to anthracosis (**Figure 3**). Also, it will not influence the result of the pathological examination. Similar to other dye markers, risk of diffusion is one limitation of ICG, as well as specific requirement for NIR device.

6. Bronchoscopic ablation

Lung cancer can be divided into small cell lung cancer (SCLC) and non-small cell lung cancer (NSCLC), among which nearly 80% are NSCLCs [45]. Surgical resection is the gold standard treatment for resectable early stage NSCLCs [46]; however, thermal ablation is considered a safe, cost-effective and ultra-minimally invasive treatment for patients with small tumors who are not suitable for surgery [53]. Thermal or energy-based ablation of tumors means “the local application of extreme temperatures

to cause irreversibly pathological cell injury, tumor apoptosis and coagulative necrosis”. Catheter-based alternative therapies include radiofrequency ablation (RFA), microwave ablation (MWA), and cryoablation (CRA). Among the thermal therapies, RFA and MWA are most commonly used for lung cancer as alternative approaches.

The most popular approach for ablation has been percutaneous. More recently, bronchoscopic approach to ablation has increasingly been accepted as an alternative to percutaneous approach. Bronchoscopic ablation has advantages over percutaneous of having less complications of pneumothorax and pulmonary-pleural fistula, as well as being scarless. The use of the hybrid OR and CBCT allows the confirmation of appropriate bronchoscopic navigation and positioning of the ablation catheter, calculation of the predicted ablation zone, monitoring of ablation progress, and assessment of the final ablated zone. Thus, for the foreseeable future, CBCT like image quality is critical to enable this form of bronchoscopic catheter therapeutic intervention.

6.1 Radiofrequency ablation (RFA)

In a radiofrequency ablation, one or more radiofrequency electrodes are placed into the tumor under the guidance of computed tomography or ultrasound. A high-frequency alternating current produced by the electrodes can generate 60–100°C temperature by inducing frictional heating in tissues [47]. It is reported that in most recently published RFA cases, conscious sedation or general anesthesia, and no less than 24 h postoperative observation are required. Depending on the size and shape of the tumor, the adjacent normal lung tissue might be burned during the process [48].

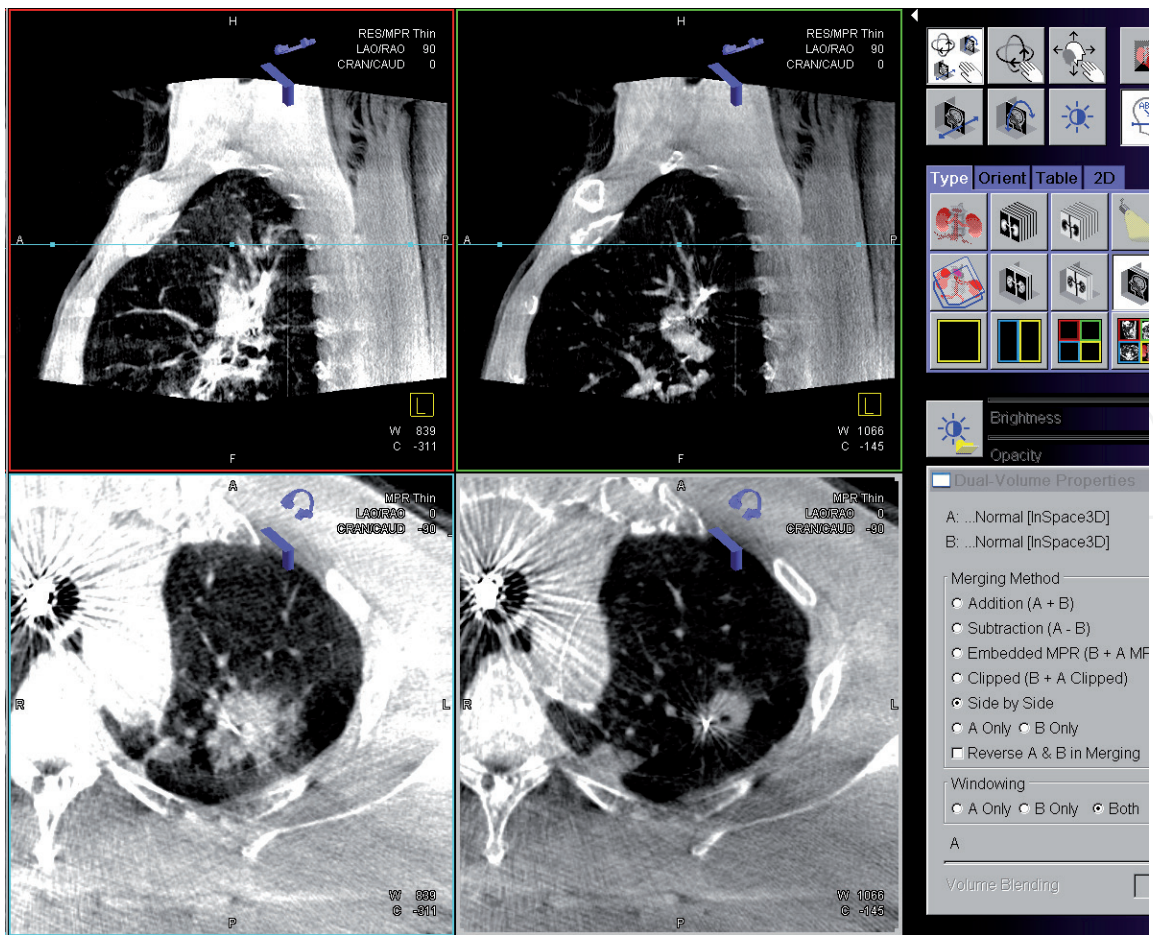


Figure 4. Cone-beam CT images showing left upper lobe adenocarcinoma bronchoscopically ablated by microwave energy. The right images show the Emprint™ catheter within the tumor before ablation while the left images show CT performed 10 min post ablation.

Because of the mechanism of radiofrequency ablation, the feasibility of this catheter-based approach is determined by the electrical conductance of the target organ. Since the normal lung tissues have a poor electrical conductance and a higher impedance than lung tumors, most current generated by the electrodes will pass through the tumor [49]. Moreover, a phenomenon called “heat sink effect” is another limitation of RFA, which happens when heat absorbed by blood flow or air is carried away from the ablated region, leading to a loss of temperature and decreased RFA efficacy [50, 51].

6.2 Microwave ablation (MWA)

Similar to RFA, MWA utilizes electromagnetic waves to cause localized hyperthermia and induce cell injury and death. During an MWA procedure, heat is generated by the oscillation of electromagnetic field between active dipoles at the tip of MW antennas, causing following realignment and agitation of water molecules and increased kinetic energy. With much higher frequencies compared with RF, electromagnetic radiation is not largely influenced by tissue impedance. As a result, MWA is considered as a more powerful and predictable thermal approach for lung tumors [52]. In a study by Han et al., 28 elderly patients (over 75 years old) with stage I or lymph node-negative stage IIA underwent MWA [53]. As the result shows, the local recurrence rate was 32.1%, and no significant difference was found between the outcome of MWA and RFA. As a limited amount of data available on comparative studies on this topic, further research is needed to evaluate the efficacy of MWA and RFA (**Figure 4**).

7. One-stop-shop: “value” and costs of hybrid OR

As a surgical workspace that integrates imaging devices with a multifunctional surgical table, hybrid OR can provide unparallel imaging support for a variety of surgical scenarios. This one-stop-shop hybrid OR can help with the localization and biopsy of suspected pulmonary nodules in a more efficient and time-saving way. In contrast to conventional approaches, a hybrid OR can provide real-time imaging and increase the success rate for a hookwire insertion or ENB, and also functions as an adjunct in the intraprocedural ultrasonography technique during single-port VATS. In a CT-guided injection of dye makers (barium or lipiodol) within a hybrid OR, the delay between the adjunct placement and the surgery is shorter, minimizing the potential risk of percutaneous complications and diffusion [27]. ENB-guided therapeutic methods such as RFA and MWA provide a safe and effective option for patients with early-stage NSCLCs. Overall, the utilization of hybrid OR on diagnosis, staging, and treating the lung-related diseases has been gaining more and more popularity.

The costs of a hybrid OR depends on the country and institution-specific operational and manual cost. As there is lacking data and knowledge on this issue, future investigations are needed to compare approaches conducted within hybrid OR and those through conventional multi-stop multi-shop means.

8. Future developments of hybrid OR

The hybrid operating room is progressively used in the thoracic surgery to improve the accuracy of the procedures and to provide useful guidance to both endoscopy and surgical procedures. The new era of hybrid thoracic surgery does not depend only on its imaging superiority but also the integration of other technologies, including 3D printing, robotic bronchoscopy and NOTES lung surgery, just to name a few. The application of the precise imaging provided by the real-time

cone-beam computed tomography will be greatly improved as a result of the development of adjunct related technologies.

The hybrid operating room with real-time cone-beam computed tomography can be combined with 3D printing to provide precise customization of prostheses. This facility can provide images of post-resection chest wall defects which can be used for 3D image reconstruction and segmentation to generate an accurate stereo vision of the chest wall defect. The immediate transfer of data for 3D printing within the operating room could make the process of surgery more tailored by custom 3D printing prostheses for that specific defect and stature of the patient.

Recently, the number of navigational bronchoscopy or catheter-based platforms is increasing rapidly which will enable more accurate navigation and will improve the safety and efficacy of the operation. The hybrid operating room can provide precise imaging support to the implementation of these technologies which is of vital importance because the positioning of lesions is the foundation for conducting surgery and its accuracy will provide guidance to the specific operational technologies. Furthermore, these platforms will promote the main use of navigational bronchoscopy in the hybrid operating room at the same time which means more precise localization of the lesions. The combination of robotic bronchoscopy with the hybrid operating room may further enhance localization accuracy and allow thoracic surgery with greater precision.

It is said that the natural orifice transluminal endoscopic surgery (NOTES) platforms and single incision robotic platforms will become the next generation of tools for performing uniportal VATS and incisionless “surgery” enabling further reduction in access trauma and more surgical precision. Some of the shortcomings of current NOTES platforms could be at least in part be addressed by using high precision imaging from hybrid operation room for localization, assisting the surgery and confirming efficacy of the procedure.

In summary, it is anticipated that the hybrid operating room will play a more and more important role in image-guided thoracic surgery as it establishes an efficient and integrated procedural flow for the operation process. It can be combined with many promising technologies to achieve the accurate control of the endoscopic and surgical procedure. More advanced modalities of imaging could be further incorporated in to this set up to provide additional imaging information and precise details which will lead us to a safer and more meticulous surgery of the future.

Acknowledgements

This work is partly supported by the Academic Equipment Grant (AEG) Project codes 3029988; 3029992; 3029993 (2018/19), from the Chinese University of Hong Kong; and Research Grants Council (RGC) Grant 2019/20; Project reference no: 14119019.

Conflict of interest

EQY has no conflicts of interest. CSHN is a consultant for Siemens Healthineers, Medtronic and Johnson and Johnson.

Notes/thanks/other declarations

Nil.

IntechOpen

IntechOpen

Author details

Evan Qize Yuan and Calvin Sze Hang Ng*
Division of Cardiothoracic Surgery, Department of Surgery, Prince of Wales
Hospital, The Chinese University of Hong Kong, Hong Kong SAR

*Address all correspondence to: calvinng@surgery.cuhk.edu.hk

IntechOpen

© 2020 The Author(s). Licensee IntechOpen. This chapter is distributed under the terms of the Creative Commons Attribution License (<http://creativecommons.org/licenses/by/3.0>), which permits unrestricted use, distribution, and reproduction in any medium, provided the original work is properly cited. 

References

- [1] Ng CS, Gonzalez-Rivas D, D'Amico TA, Rocco G. Uniportal VATS—A new era in lung cancer surgery. *Journal of Thoracic Disease*. 2015;7(8):1489-1491. DOI: 10.3978/j.issn.2072-1439.2015.08.19
- [2] Zhao ZR, Ng CSH. Hookwire localization of pulmonary nodules in uniportal VATS. In: *Atlas of Uniportal Video Assisted Thoracic Surgery*. Singapore: Springer; 2019. pp. 95-99. DOI: 10.1007/978-981-13-2604-2_14
- [3] Ng CS, Lau KK, Gonzalez-Rivas D, Rocco G. Evolution in surgical approach and techniques for lung cancer. *Thorax*. 2013;68:681. DOI: 10.1136/thoraxjnl-2012-203157
- [4] Ng CS, Rocco G, Wong RH, Lau RW, Yu SC, Yim AP. Uniportal and single-incision video-assisted thoracic surgery: The state of the art. *Interactive Cardiovascular and Thoracic Surgery*. 2014;19:661-666. DOI: 10.1093/icvts/ivu200
- [5] Zhao ZR, Li Z, Situ DR, Ng CS. Recent clinical innovations in thoracic surgery in Hong Kong. *Journal of Thoracic Disease*. 2016;8(Suppl 8):S618-S626. DOI: 10.21037/jtd.2016.03.93
- [6] Ng CS. Uniportal VATS in Asia. *Journal of Thoracic Disease*. 2013;5:S221-S225
- [7] Ng CS, Man Chu C, Kwok MW, Yim AP, Wong RH. Hybrid DynaCT scan-guided localization single-port lobectomy [corrected]. *Chest*. 2015;147:e76-e78
- [8] Zhao ZR, Lau RW, Yu PS, Wong RH, Ng CS. Image-guided localization of small lung nodules in video-assisted thoracic surgery. *Journal of Thoracic Disease*. 2016;8(Suppl 9):S731-S737. DOI: 10.21037/jtd.2016.09.47
- [9] Zhao ZR, Lau RW, Yu PS, Ng CS. Devising the guidelines: The techniques of pulmonary nodule localization in uniportal video-assisted thoracic surgery—Hybrid operating room in the future. *Journal of Thoracic Disease*. 2019. DOI: 10.21037/jtd.2019.01.82
- [10] Saleh WK, Abu OAJ, Lumsden A, Ramchandani MK. Simultaneous localization and removal of lung nodules through extended use of the hybrid suite. *Methodist DeBakey Cardiovascular Journal*. 2015;11(4):245-246. DOI: 10.14797/mdcj-11-4-245
- [11] Advanced Multimodality Image Guided Operating (AMIGO). 2016. Available from: <http://www.brighamandwomens.org/research/amigo/default.aspx> [Accessed: 01 September 2018]
- [12] Zhao ZR, Ng CSH. Image-guided uniportal VATS in the hybrid operating room. In: *Atlas of Uniportal Video Assisted Thoracic Surgery*. Singapore: Springer; 2019. pp. 269-278. DOI: 10.1007/978-981-13-2604-2_39
- [13] Ohtaka K, Takahashi Y, Kaga K, et al. Video-assisted thoracoscopic surgery using mobile computed tomography: New method for locating of small lung nodules. *Journal of Cardiothoracic Surgery*. 2014;9:110
- [14] Ujiie H, Kato T, Hu HP, et al. A novel minimally invasive near-infrared thoracoscopic localization technique of small pulmonary nodules: A phase I feasibility trial. *The Journal of Thoracic and Cardiovascular Surgery*. 2017;154:702-711
- [15] Hsieh CP, Hsieh MJ, Fang HY, Chao YK. Imaging-guided thoracoscopic resection of a ground-glass opacity lesion in a hybrid operating room equipped with a robotic C-arm CT system. *Journal of Thoracic Disease*.

2017;**9**(5):E416-E419. DOI: 10.21037/jtd.2017.04.48

[16] Freund MC, Petersen J, Goder KC, et al. Systemic air embolism during percutaneous core needle biopsy of the lung: Frequency and risk factors. *BMC Pulmonary Medicine*. 2012;**12**:2

[17] Team NLSTR, Aberle DR, Adams AM, Berg CD, Black WC, Clapp JD, et al. Reduced lung-cancer mortality with low-dose computed tomographic screening. *The New England Journal of Medicine*. 2011;**365**:395-409

[18] Gill RR, Jaklitsch MT, Jacobson FL. Controversies in lung cancer screening (internet). *Journal of the American College of Radiology*. 2013;**10**:931-936

[19] Team NLSTR, Church TR, Black WC, et al. Results of initial low-dose computed tomographic screening for lung cancer. *The New England Journal of Medicine*. 2013;**368**:1980-1991

[20] Chow SC, Ng CS. Recent developments in video-assisted thoracoscopic surgery for pulmonary nodule management. *Journal of Thoracic Disease*. 2016;**8**(Suppl 6): S509-S516. DOI: 10.21037/jtd.2016.03.18

[21] Ng CS, Pickens A, Siegel JM, et al. A novel narrow profile articulating powered vascular stapler provides superior access and haemostasis equivalent to conventional devices. *European Journal of Cardio-Thoracic Surgery*. 2016;**49**(Suppl 1):i73-i78

[22] Zhao ZR, Lau RW, Ng CS. Hybrid theatre and alternative localization techniques in conventional and single-port video-assisted thoracoscopic surgery. *Journal of Thoracic Disease*. 2016;**8**(Suppl 3):S319-S327. DOI: 10.3978/j.issn.2072-1439.2016.02.27

[23] Chao Y-K, Pan K-T, Wen C-T, Fang H-Y, Hsieh M-J. A comparison of efficacy and safety of preoperative versus intraoperative computed tomography-guided thoracoscopic lung resection. *The Journal of Thoracic and Cardiovascular Surgery*. 2018;**156**(5):1974-1983. DOI: 10.1016/j.jtcvs.2018.06.088

[24] Watanabe K, Nomori H, Ohtsuka T, et al. Usefulness and complications of computed tomography-guided lipiodol marking for fluoroscopy-assisted thoracoscopic resection of small pulmonary nodules: Experience with 174 nodules. *The Journal of Thoracic and Cardiovascular Surgery*. 2006;**132**:320-324

[25] Zhao Z-R, Lau RWH, Ng CSH. Hybrid theatre and uniportal video-assisted thoracic surgery. *Thoracic Surgery Clinics*. 2017;**27**(4):347-355. DOI: 10.1016/j.thorsurg.2017.06.003

[26] Chen Y-R, Yeow K-M, Lee J-Y, Su IH, Chu S-Y, Lee C-H, et al. CT-guided hook wire localization of sub-pleural lung lesions for video-assisted thoracoscopic surgery (VATS). *Journal of the Formosan Medical Association*. 2007;**106**:911-918

[27] Klinkenberg TJ, Dinjens L, Wolf RFE, van der Wekken AJ, van de Wauwer C, de Bock GH, et al. CT-guided percutaneous hookwire localization increases the efficacy and safety of VATS for pulmonary nodules. *Journal of Surgical Oncology*. 2017;**115**:898-904

[28] Ichinose J, Kohno T, Fujimori S, Harano T, Suzuki S. Efficacy and complications of computed tomography-guided hook wire localization. *The Annals of Thoracic Surgery*. 2013;**96**:1203-1208

[29] Kothapalli PR, Wyler von Ballmoos MC, Chinnadurai P,

Lumsden AB, Ramchandani MK. Value of the hybrid operating theater for an integrated approach to diagnosis and treatment of pulmonary nodules in 2019. *Frontiers in Surgery*. 2019;**6**:36. DOI: 10.3389/fsurg.2019.00036

[30] Ciriaco P, Negri G, Puglisi A, Nicoletti R, Del Maschio A, Zannini P. Video-assisted thoracoscopic surgery for pulmonary nodules: Rationale for preoperative computed tomography-guided hookwire localization. *European Journal of Cardio-Thoracic Surgery*. 2004;**25**:429-433. DOI: 10.1016/j.ejcts.2003.11.036

[31] Miyoshi T, Kondo K, Takizawa H, et al. Fluoroscopy- assisted thoracoscopic resection of pulmonary nodules after computed tomography-guided bronchoscopic metallic coil marking. *The Journal of Thoracic and Cardiovascular Surgery*. 2006;**131**:704-710

[32] Mayo JR, Clifton JC, Powell TI, et al. Lung nodules: CT-guided placement of microcoils to direct video-assisted thoracoscopic surgical resection. *Radiology*. 2009;**250**:576-585

[33] Yang SM, Ko WC, Lin MW, et al. Image-guided thoracoscopic surgery with dye localization in a hybrid operating room. *Journal of Thoracic Disease*. 2016;**8**(Suppl 9):S681-S689

[34] Schwarz Y, Mehta AC, Ernst A, et al. Electromagnetic navigation during flexible bronchoscopy. *Respiration*. 2003;**70**:516-522

[35] Chee A, Stather DR, Maceachern P, et al. Diagnostic utility of peripheral endobronchial ultrasound with electromagnetic navigation bronchoscopy in peripheral lung nodules. *Respirology*. 2013;**18**:784-789

[36] Eberhardt R, Anantham D, Herth F, et al. Electromagnetic navigation diagnostic bronchoscopy in peripheral lung lesions. *Chest*. 2007;**131**:1800-1805

[37] Ng CS, Yu SC, Lau RW, Yim AP. Hybrid DynaCT-guided electro-magnetic navigational bronchoscopic biopsy†. *European Journal of Cardio-Thoracic Surgery*. 2016;**49**:i87-i88

[38] Lau WH, Chow CYS, Ho YKJ, et al. Hybrid operating room DynaCT real-time image guided electromagnetic navigation bronchoscopic biopsy (iENB)—The initial experience. *Respirology*. 2016;**21**(Suppl 3):74

[39] Anantham D, Feller-Kopman D, Shanmugham LN, et al. Electromagnetic navigation bronchoscopy-guided fiducial placement for robotic stereotactic radiosurgery of lung tumors: A feasibility study. *Chest*. 2007;**132**:930-935

[40] Bolton WD, Howe H 3rd, Stephenson JE. The utility of electromagnetic navigational bronchoscopy as a localization tool for robotic resection of small pulmonary nodules. *The Annals of Thoracic Surgery*. 2014;**98**:471-475. discussion 475-6

[41] Rocco R, Rocco G. Future study direction on single port (uniportal) VATS. *Journal of Thoracic Disease*. 2016;**8**:S328-S332

[42] Yannuzzi LA. Indocyanine green angiography: A perspective on use in the clinical setting. *American Journal of Ophthalmology*. 2011;**151**:745-51.e1

[43] Zelken JA, Tufaro AP. Current trends and emerging future of Indocyanine green usage in surgery and oncology: An update. *Annals of Surgical Oncology*. 2015;**22**(Suppl 3):S1271-S1283

[44] Wen CT, Liu YY, Fang HY, et al. Image-guided video-assisted thoracoscopic small lung tumor resection using near-infrared marking. *Surgical Endoscopy*. 2018;**32**:4673-4680

[45] Non-Small Cell Lung Cancer Treatment (PDQ®)–Patient Version. n.d. Available from: <https://www.cancer.gov/types/lung/patient/non-small-cell-lung-treatment-pdq>

[46] Ng CS, Zhao ZR, Lau RW. Tailored therapy for stage I non-small-cell lung cancer. *Journal of Clinical Oncology*. 2017;**35**:268-270

[47] Chu KF, Dupuy DE. Thermal ablation of tumours: Biological mechanisms and advances in therapy. *Nature Reviews Cancer*. 2014;**14**(3):199-208. DOI: 10.1038/nrc3672

[48] Zhao ZR, Lau RW, Ng CS. Catheter-based alternative treatment for early-stage lung cancer with a high-risk for morbidity. *Journal of Thoracic Disease*. 2018;**10**(Suppl 16):S1864-S1870. DOI: 10.21037/jtd.2018.03.151

[49] Tafti BA, Genshaft S, Suh R, Abtin F. Lung ablation: Indications and techniques. *Seminars in Interventional Radiology*. 2019;**36**(03):163-175. DOI: 10.1055/s-0039-1693981

[50] Muralidharan V, Malcontenti-Wilson C, Christophi C. Effect of blood flow occlusion on laser hyperthermia for liver metastases. *The Journal of Surgical Research*. 2002;**103**:165-174

[51] Whelan WM, Wyman DR, Wilson BC. Investigations of large vessel cooling during interstitial laser heating. *Medical Physics*. 1995;**22**:105-115

[52] Brace CL. Radiofrequency and microwave ablation of the liver, lung, kidney, and bone: What are the differences? (/products/ejournals/linkout/10.1055/s-0039-1693981/id/JR001155-7). *Current Problems in Diagnostic Radiology*. 2009;**38**(03):135-143

[53] Gage AA, Baust J. Mechanisms of tissue injury in cryosurgery. *Cryobiology*. 1998;**37**:171-186