

We are IntechOpen, the world's leading publisher of Open Access books Built by scientists, for scientists

6,900

Open access books available

186,000

International authors and editors

200M

Downloads

Our authors are among the

154

Countries delivered to

TOP 1%

most cited scientists

12.2%

Contributors from top 500 universities



WEB OF SCIENCE™

Selection of our books indexed in the Book Citation Index
in Web of Science™ Core Collection (BKCI)

Interested in publishing with us?
Contact book.department@intechopen.com

Numbers displayed above are based on latest data collected.
For more information visit www.intechopen.com



Synthetic Mesh in Immediate Breast Reconstruction

Susana Gómez-Modet and Luis Tejedor

Abstract

The use of biological matrices in immediate implant-based breast reconstruction arose with the need to reinforce the lower pole of the breast and to cover the implant to reduce the risk of implant exposure. Synthetic mesh appears to be a lower cost alternative to biological matrices. This literature review aims to assess the usefulness of the use of synthetic meshes in breast reconstruction compared with the traditional techniques and whether outcomes and complications of synthetic meshes and biological matrices are comparable. The positioning of the implants and meshes, either submuscular or subcutaneous, has also been considered.

Keywords: breast cancer, breast reconstruction, synthetic breast meshes, biological breast meshes, complications of breast reconstruction

1. Introduction

Breast cancer is a life-changing diagnosis. Presently, breast conserving therapy can be performed in 70–80% of all breast cancer patients, but in about 20–30% of them mastectomy is indicated as the primary therapeutic management [1–3]. As mastectomy can profoundly affect body image and self-esteem, breast reconstruction should be offered to improve quality of life. Reconstruction may be immediate or delayed, performed with implants or autologous tissue. Immediate reconstruction has several advantages: it provides a psychological benefit, reducing emotional stress and helping to preserve a positive body image [4, 5].

Numerous surgical techniques have been developed, including the use of autologous tissue flaps or silicone implants with or without prior insertion of a tissue expander [1]. Implant-based breast reconstruction (IBBR) accounts for approximately 40–60% of all breast reconstructions in Europe and around 75% in the United States [6]. The American Society of Plastic Surgeons documented a 4% increase in these techniques from 2014 to 2015 and a 35% increase over the last 15 years. A similar trend has also been shown in the United Kingdom, where the rate of IBBR has doubled over the period 1996–2012 [7]. As the number of autologous procedures remains approximately the same, the increased number of immediate procedures can be primarily attributed to an increase in implant/expander reconstructions. This number has substantially increased since skin- and nipple-sparing mastectomies (SSM/NSM) have proven to be oncologically safe procedures.

In IBBR, complete implant coverage has been the mainstay target of surgeons in order to reduce the risk of implant exposure [8]. In the last years, biological and synthetic meshes have emerged as a useful adjunct to breast reconstruction,

although the decision to add some mesh to an alloplastic reconstruction is controversial. However, there is no high-quality evidence comparing clinical and patient-reported outcomes with mesh-assisted IBBR and traditional IBBR [9]. Finally, the decision for using mesh or not and a particular type of matrix or mesh depends predominately on the surgeons' experience [3, 10].

2. Methods

A literature search has been performed in PubMed, Cochrane, and Embase databases using the keywords "Breast" and "Reconstruction" and "Mesh" and "Synthetic" which rendered 80, 3, and 107 articles, respectively. No date limits were set.

Papers written in English reporting on the complications and/or outcome of IBBR in women aged 18 years or over, either with expander or implants, as a single- or two-stage procedure, either immediate or delayed, both in submuscular and in prepectoral position in which synthetic meshes had been used, were selected for inclusion. Authors screened these articles discarding duplicates, those reporting less than 10 cases, and those unrelated to the subject, leaving a total of 49 papers. The reference list of the retrieved studies was searched manually looking for potentially relevant reports.

3. Synthetic meshes

Usually, the term "matrices" are used for biological materials and the term "meshes" for synthetic materials. There are numerous studies explaining the pros and cons of the matrices, but minimal data are available regarding the synthetic meshes.

Biological meshes or matrices are flexible sheets of tissue that have been stripped of their antigenic cells through a specialised procedure, resulting in decellularisation but leaving the extracellular matrix intact. They provide a scaffold of tissue that the patient's own cells can repopulate and revascularise.

The acellular dermal matrix (ADM), introduced in 1994 [11], is a plate of dermis produced from cadaveric human (Alloderm, Allured, Allomax, Flex HD, Dermacell, Dermamatrix, NeoForm), porcine (Strattice, Permacol, Protexa, XenMartix, XCM), or bovine (SurgiMend) dermis. Other biological meshes come from bovine pericardium (Veritas, Tutopatch, Periguard, Esaflex), porcine peritoneum (Meso Biomatrix), bovine intestine (Surgisis), or fish skin (Kerecis Omega 3 Pectus) [3]. Their utility has been demonstrated in various reconstructive techniques, particularly in burn, abdominal wall repair, and breast reconstruction [11–13].

With the introduction of these meshes, the indications for IBBR became extended, since they provided surgeons with alternative means of obtaining sufficient vascularized soft tissue to cover the implant. Breuing first reported the use of human acellular dermis in IBBR in 2005 [14]. Increased filling volumes of expanders and improved aesthetic outcomes have been reported since then by several authors [4, 15–17]. As new data become available, the use of biological meshes in IBBR will evolve in the following years.

Synthetic meshes are flexible sheets made of plastic-like material that may play a similar role to biological ones in breast reconstruction, becoming an alternative with low cost. The tensile strength of most of these materials is enough to support the physiological demand, although an excessive strength increases inflammation

and decreases elasticity. The size of their pores directly impacts on the incorporation of the mesh into the surrounding tissues. Small pores generate a strong inflammatory response that can reduce tissue ingrowth; larger pores allow more ingrowth, preserving elasticity, but promoting more fibrous tissue. Moreover, the mesh can be constructed by knitting or weaving the material. Knitted meshes are generally more porous and flexible than woven meshes that, because of the increased fibre density, are generally stronger and are a poor skeleton for fibrous ingrowth [18].

Besides that, these meshes may be absorbable or non-absorbable. The former are made of polyglycolic acid (Dexon), polyglactin (Vicryl)—both of them are resorbed within a few months—a copolymer of glycolide, lactide and trimethylene carbonate (TIGR Matrix), silk protein (SERI Surgical Scaffold), or a poly-4-hydroxybutyrate polymer (Galatea Scaffold) which is long-term resorbable. Non-absorbable meshes are composed of polypropylene (PP), polyester, (Mersilene), or expanded polytetrafluoroethylene, though just the first material has been used in breast reconstruction (TiLOOP Bra, ULTRAPRO, SERAGYN BR).

3.1 Vicryl

Vicryl mesh is comprised of polyglactin 910 and is a cheap, ready-to-use, and widely available mesh. It causes minimal inflammatory reaction and is non-allergenic and resistant to bacteria biofilm formation. However, because of its rapid resorption, it does not provide a long-lasting tissue reinforcing advantage.

3.2 TiLOOP

This mesh is made of non-resorbable, titanised, lightweight PP with a monofilament structure and was initially invented for hernia repair, showing a good biocompatibility. Production involves introducing titanium in gaseous form so that it reaches all parts of the mesh, forming covalent bonds with the plastic surface. Cellular reactions like proliferation and apoptosis were at the lowest level when using this material compared to not titanium-coated mesh (pure PP), pure lightweight PP mesh, or PP mesh incorporating resorbable polyglactic acid, thus reducing the inflammatory reaction and causing significantly less shrinkage [10]. Clinical studies show that 2 1/2 months after their use, the mesh fibres have been well embedded in the surrounding tissue.

TiLOOP[®] Bra is intended for extension of the pectoralis major, in the case of subpectoral, implant-based (permanent implant or expander) breast reconstruction. It covers and fixes the caudal pole of the breast implant (**Figure 1**). TiLOOP Bra Pocket is designed to cover a prepectoral implant, providing tissue supporting and preventing displacement.

3.3 SERAGYN BR

The SERAGYN BR mesh is a tightly woven, partially resorbable mesh made of polyglycolic acid-caprolactone and PP. The resorbable part is absorbed within 90–120 days while the non-resorbable part remains in place for additional support. Its biocompatibility is similar to that of the TiLOOP Bra, although surgeons have reported more difficult intraoperative handling due to its firmer characteristics [10].

3.4 ULTRAPRO mesh

ULTRAPRO is manufactured from approximately equal parts of absorbable poliglecaprone-25 monofilament fibre and non-absorbable PP monofilament fibre.

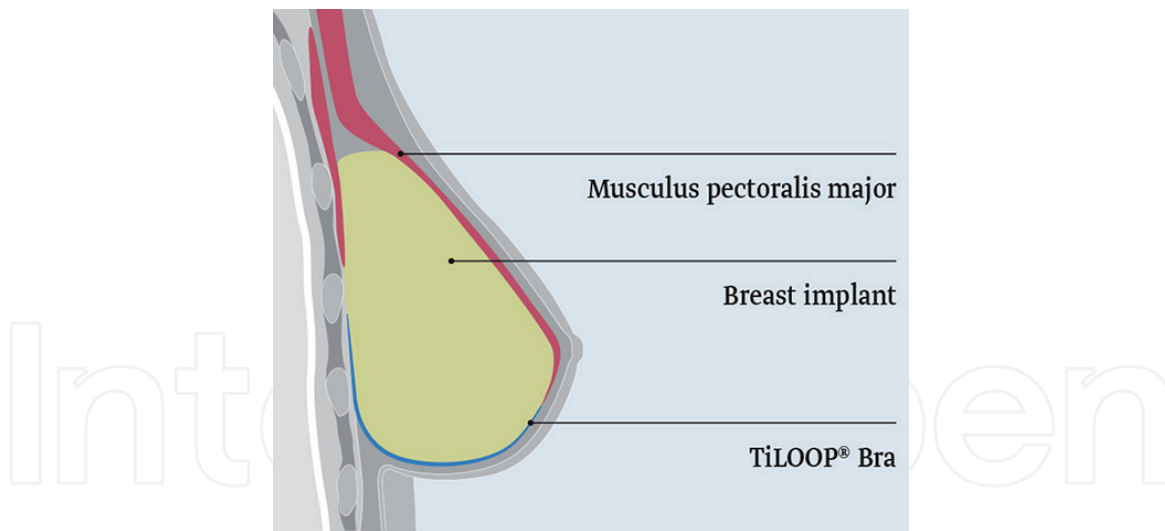


Figure 1.
Tiloop bra.

The absorbable poliglecaprone part of the mesh helps keep the PP structure rigid, thus making intraoperative manipulation and positioning of the mesh easier. The poliglecaprone-25 copolymer is essentially absorbed at 84 days after implantation, remaining only the PP component. Due to the wide pore construction of the mesh, a strong, three-dimensional collagen fibre network is formed [19].

3.5 SERI surgical scaffold

This bioengineered mesh is derived from silk purified to result in ultrapure fibroin (one of the two proteins of the silk). It is a knitted, multifilament, macroporous, and long-term bioresorbable mesh (more than 24 months) intended to resorb slowly, while neovascularization and tissue ingrowth occur. Accordingly, it behaves more like an ADM mesh since it is not just absorbed but accompanied by new tissue generation so that its strength is transferred to the newly ingrown tissue [20].

3.6 TIGR matrix

TIGR Matrix is a long-term resorbable synthetic mesh. The fast-resorbing fibre is a copolymer of lactide, glycolide, and trimethylene carbonate, while the slow-resorbing part is a copolymer of lactide and trimethylene carbonate, completely absorbed after 3 years. Despite its description “matrix” (a term generally used to refer to biological products), the mesh is manufactured synthetically. After implantation, the synthetic fibres degrade at different rates by bulk hydrolysis. It provides additional support in the first 6 months, and complete resorption is achieved after 3 years. In vivo investigations revealed good biocompatibility with the formation of blood vessels and well-structured collagen fibres. The largest series using these meshes is reported by Becker and Lind [21].

3.7 Galatea scaffold

This mesh is made of a poly-4-hydroxybutyrate (P4HB) polymer, which degrades primarily by bulk hydrolysis into a natural metabolite (4HP) that is rapidly metabolised via the Krebs cycle and eliminated as carbon dioxide and water. The mesh is a knitted macroporous scaffold intended to elevate, reinforce, and repair soft tissue. It acts as a lattice for new tissue growth, which is rapidly vascularised and becomes fully integrated with adjacent tissue as the fibres resorb. It retains 50%

of its strength at 16 weeks in vivo and provides a gradual transfer of strength to host tissue over the course of 52 weeks. It is essentially fully resorbed by 18–24 months, allowing the formation of mature strong healthy collagen to support the repair. Its use in breast surgery has recently been described [22].

4. Surgical technique

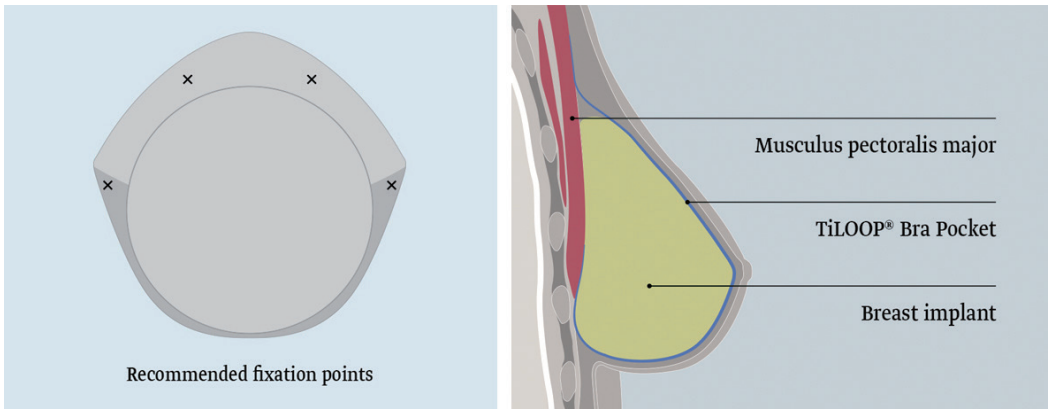
Primary candidates for mesh reconstruction are patients suited for heterologous breast reconstruction with a small, mid-sized breast and moderate ptosis. Preoperative planning is necessary. Markings must be performed on the day with the patients in an upright position and including the middle and parasternal lines, inframammary folds, and the incision site [23]. There are some possibilities concerning the type of incision technique; in most of the cases, surgeons chose inframammary fold, inverted T, or periareolar.

Prosthetic submuscular IBBR is the most frequent type of reconstruction technique performed nowadays. Placing the implant under the muscular plane traditionally had less major complications than the subcutaneous technique, notwithstanding its burden of pain, limited expansion, implant dislocation, and breast animation. However, adding a mesh to the prepectoral prosthesis allows a complete implant envelope, confers an extra cover, acts as an internal “bra” to relieve pressure on the skin, and defines the implant pocket, preventing lateral displacement. The acceptable complication rate reported in the published studies using this procedure, although with short-term follow-up, has revived this technique [7] (Figure 2).

In the submuscular IBBR, after completion of the mastectomy flaps, the inferomedial pectoralis major muscle is elevated for implant placement, serving as a cover towards the maximal thinned out mastectomy flap. Usually, this coverage can often be achieved only for the upper and lower medial quadrant, which can lead to increased implant palpability, with a lack of support and subsequent skin erosion. Although additional coverage can be obtained by mobilising the serratus or the anterior layer of the rectus muscle, this approach involves even more trauma to native tissue and may not be technically possible, particularly in thin patients.

The mesh is fixed to the inferior border of the released pectoral major muscle using running or interrupted resorbable sutures. After placing the implant under the muscle, the mesh is spread over the implant and fixed to the inframammary fold either by single sutures or by wrapping around the implant to gain control of the lower pole [3, 24]. Otherwise, sutures may be given in the opposite order. Mesh

Figure 2. Recommended implantation procedure in prepectoral reconstruction.



allows to create a more spacious pocket with a natural inframammary fold, bridging the gap between the muscle and chest wall fascia [3, 7] and protecting the pectoralis major from cranial movement.

In the prepectoral IBBR, the mesh or matrix is folded onto itself to create a pocket for the implant or the expander (filled with its final expansion volume and then deflated), and this pocket is sutured to the pectoral major fascia with at least three stitches, apical, medial, and lateral [25]. Advantages of this approach include less tissue dissection, less postoperative pain, better filling of the medial breast, avoidance of lateral fallout, and absence of hyperanimation deformity. This technique is frequently used in combination with new technologies such as autologous fat grafting and perfusion analysis of the skin flaps.

5. Complications

Mesh use in breast reconstruction is associated with many complications. Infection, seroma, hematoma, capsular contracture, skin flap necrosis, explantation or implant loss are the most commonly reported. Of course, some characteristics of patients are associated with increased complication rates, with or without use of a mesh. These include age (older than 65 years), large breasts (more than 600 g), obesity (BMI greater than 30), smoking, diabetes, hypertension, long drain removal time, previous radiotherapy to the ipsilateral breast, and receipt of neoadjuvant chemotherapy [1, 2].

Infection is one of the most common complications seen in both biological and synthetic mesh use, which often leads to tissue necrosis and may result in explantation, revision, or even complete loss of implant [1, 26]. Ellis et al. reported rates of infection shifting between 0.2 and 35.8%, the higher numbers seen after ADM use [1, 2]. A high-throughput assay comparing synthetic meshes (Prolene and Vicryl) and biological matrices (Alloderm and Flex HD) as substrates for bacterial adhesion concluded that *Staphylococcus aureus* adhered more readily to ADMs than to meshes, therefore showing a greater potential propensity for biofilm development [27].

Seroma and haematoma are commonly occurring complications and can both lead to an increased risk of infection and tissue necrosis, particularly when large enough to require drain insertion. Haematoma formation is thought to occur in the immediate postoperative period as a result of trauma during surgery—although the use of electrocautery has significantly reduced its incidence—or as a late complication due to small tears in the capsule formed around the implant, often after physical trauma [1]. There seems to be different seroma formation rates between the two types of meshes. Matrices have smooth surfaces, allowing increased fluctuation between the matrix and the subcutaneous tissue and resulting in the development of seromas. Meshes have rougher surfaces and thus a potentially faster interaction with the subcutaneous tissue, lesser fluctuation, and a consequent decrease in seroma formation [10]. Rates are between 0 and 5.7% for meshes and between 1.5 and 24.3 for ADM [1].

Capsular contracture is described as the formation of a fibrous capsule around the implant that thickens progressively and may contract, compressing the implant and resulting in a hard breast with deformed contouring of the surrounding skin. This may also cause severe pain due to nerve entrapment or muscle mobility interference. Although the aetiology is unclear, some believe that it is initiated by blood products like haematomas, while others consider infection and chronic inflammation to be most likely the cause, either by bacteria colonisation from within the ductal breast tissue or from the skin [1, 28]. Studies have reported significantly lower rates of capsular contracture with the use of ADM than without it, but the

length of the follow-up is short [20]. Although no high-quality study has directly compared the incidence of capsular contracture between synthetic and biological matrices IBBR, rates are similar for both types (1.3–8.6% for meshes and 0.4–8.1% for matrices) [1, 3, 28, 29]. Dieterich et al. [30] reported a histological analysis with mild inflammation using TiLOOP, suggesting a low risk of capsular contracture.

Loss of vascular supply to the overlying mastectomy skin flap is the reason of skin necrosis after ischaemic changes. This is a multifactorial event: patient comorbidities, thin mastectomy skin flaps, or over expansion may contribute [1]. Regarding the surgical technique, rates of skin necrosis up to 30% have been associated with the use of inverted T-incision, especially at the T-junction [24].

Rates of 1.8–4.3% for meshes and 1.4–24.3% for matrices have been published [1].

All of the above complications, if severe enough, may lead to implant explantation, often resulting in complete implant loss. Most of the studies showed comparable rates of implantation loss using matrices or synthetic meshes (between 0 and 8.7%), although some reports explantation rates as high as 33.3% for ADM [1, 29].

6. Discussion

Reconstructive breast techniques with expander or implant without biologic or synthetic meshes can have disadvantages. In the short run, they may present with a thin or insufficient coverage of the implant, a risky stress of the inferior pole along with a decreased skin perfusion with a too early or too extensive expansion, and a herniation and sequential skin erosion towards the lateral border of the pectoralis major muscle or the inferior pole. In the medium and long term, a high-riding implant due to muscle stiffness, a restricted expansion of the inferior pole, or a loss of definition of the inframammary fold may appear. By using these meshes to support and cover these weak points, these disadvantages can be diminished or even resolved [30].

Benefits of their use include improved coverage over the device, lengthening and support of the pectoralis muscle, support for the lower pole, more rapid expansion, improved definition of the breast boundaries and folds, and possible modification of capsule formation. Disadvantages include added risk of infection, seroma formation, risk of flap necrosis and implant exposure, added surgical time, and increased cost [31, 32]. These complications may be higher than traditional implant reconstruction, and there is no yet evidence on long-term outcomes of these mesh procedures, including the need for further surgery over time [33].

Although the choice of using a mesh or a matrix is controversial and depends basically on individual surgeon preference, there are indications where matrices may be advisable, such as in revisional breast surgery or after irradiation, since reported data suggest a better blood flow to the irradiated skin and, for some author, a decreased rate of capsular contracture compared with meshes [24]. Published guidelines, though largely based on poor-quality evidence and expert opinion, offer sensible advice regarding current best practice. The American Society of Plastic Surgeons recommends using mesh on a per patient basis. The United Kingdom professional associations (Association of Breast Surgery and the British Association of Plastic, Reconstructive, and Aesthetic Surgeons) advocate careful patient selection and employing mesh-assisted IBBR with caution in high-risk groups (current smokers, previous breast radiotherapy, high BMI) [21, 34]. A joint consensus guide on prepectoral IBBR from European and US surgeons has been recently published [35]. After a systematic review, Cabalag et al. offer a summary of recommendations for ADM use [36].

Regarding outcomes when using these materials, a recent systematic review noted a higher rate of infection with mesh-assisted IBBR than traditional IBBR, but the quality of evidence is low [37]. Improved cosmetic results have been advocated for the use of matrices, although the outcomes of the reported studies are of limited value [20, 29]. Sigalove et al. found less than 5% of aesthetic complications (capsular contracture, implant malposition, and rippling) after prepectoral reconstruction with ADM. Their complication rate was 9.1%: 4.5% infections, 2.0% seromas, and 2.5% necrosis [38]. Obtaining data from 14,249 patients, Pannucci et al. reported a significant increased risk of 0.7% (1.85 vs. 2.58%) expander/implant loss when ADM was used [39].

Salibian et al. showed 85.2% of patients as having very good or good results with prepectoral expander/implant without any additional material (together with infection in 2.4%, necrosis in 6.8%, capsular contracture Baker grade III or IV in 7.6%, and rippling in 3.6% of the patients) [40].

In a small pilot randomised controlled trial comparing biological and synthetic meshes, Gschwantler-Kaulich et al. [24] found no statistically significant differences in cosmetic outcome and overall complications between the groups, but patients in the ADM group experienced substantially higher rates of implant loss than those undergoing IBBR with synthetic mesh (although the first group was more exposed to radiotherapy). Nevertheless, this study is insufficiently designed to look at the target difference between the treatment groups and is of very low-quality evidence.

A recent cohort study reported no differences in satisfaction and quality of life between the use of matrix (Surgisis) or mesh (TIGR) in IBBR [41]. Reitsemmer et al. reported low complication rates after 200 prepectoral reconstructions with the use of ADM or TIGR mesh, but with no comparison between both [42]. A systematic review comparing subcutaneous IBBR using ADM or meshes (without any information about the types of meshes) concluded that short-term complication rates are low and similar but refers that statistical analysis was not possible given differing study designs, confounding variables, and lack of comparative data in each study [43].

In a retrospective cohort study comparing the benefits of mesh (TiLOOP) versus non-mesh reconstructions, there was no statistical significance either in complications or in patient-reported outcomes [3]. In a large retrospective multicenter study of 231 procedures using synthetic mesh (TiLOOP Bra), Dieterich revealed major complications (those needing additional surgery) occurring in 13.4%, minor complications (requiring just conservative measures) in 15.6%, and implant loss in 8.7% of patients. The overall infection rate was 6.1% of which only 1.7% needed revision, and the seroma rate was 4.8%. In this chapter, risk factors for postoperative complications included a bilateral procedure or a previous skin expansion. The authors concluded that these were acceptable complication rates, that the mesh should only be used in primary cases, and that, when adhering to the proposed indications, it was a safe and convenient option in implant-based breast reconstruction [26].

Low complication rates (6.6%, including implant loss of 1.3%) and good aesthetic results have also been reported by Tessler et al. with the use of Vicryl meshes, which add to their economic advantage over matrices, but again with insufficient power to obtain clear-cut conclusions [44].

Hallberg et al. noticed complications in 23% of the patients with IBBR using TIGR Matrix, including two implant losses. Reported risk factors were age over 51 years, BMI over 24.5 kg/m², large resection weight, and a Wise pattern excision of the skin [45]. A similar rate of complications with the same material was stated by Pompei et al., with 11.6% of the patients requiring revisional surgery but with

removal of the mesh only in 3.3% of them. These authors found that this mesh caused low seroma (3.6%) and infection rates (1.6%) when compared with other nonreabsorbable or semiresorbable synthetic meshes, but also this study has a low quality of evidence [46]. A recent abstract reports on 34 patients reconstructed with TIGR Matrix encountered 9% cases with infections, 9% with necrosis, 5.9% with seromas, and 3% with reoperations [47]. Schrenk et al. found just one case of seroma and another of skin necrosis, needing reoperation, after 37 IBBR with the same mesh [48]. Irwin et al. had 11 implant losses out of 94 cases with the same material [49].

In a prospective study with 187 patients treated with prepectoral expander and TiLOOP Bra mesh and with a mean follow-up of 36.5 months, Casella et al. found complications requiring a second operation in 6.7% of the cases, with implant loss in half of them. Capsular contracture, implant malposition, and, above all, rippling appeared in 16.4%. Patients scored a high level of satisfaction [50].

In a study comparing reconstruction with a prepectoral titanium mesh wrap to subpectoral titanium sling, there was only one implant failure in the prepectoral cohort. There were no significant differences between the two groups with any complication, including infection, implant loss, skin necrosis, hematoma, or reoperation at 1-year follow-up [51]. Two-year follow-up demonstrated no capsular contracture in the prepectoral cohort and 12% in the partial subpectoral cohort [52]. Other paper by Casella et al. on 250 cases of prepectoral implant immediate reconstruction and TiLOOP recounts complications in 2.4% of the cases, but aesthetic complications are brought to reoperations in 19.5% of the breasts [53].

A reported side effect of titanium-coated permanent mesh in IBBR is the formation of granulomas in the inframammary fold, probably in the area where the mesh had been folded or fixed, mimicking a local recurrence [54]. Other papers state good cosmetic results and/or a low rate of complications with the use of this mesh [3, 55, 56].

A retrospective analysis of 320 cases comparing TiLOOP Bra mesh with SERAGYN mesh reported no differences in complication rates (and no differences in performance when compared to ADM) [58, 59]. A similar report about 131 patients with SERAGYN showed a rate of complication comparable to the use of other meshes or matrices (seroma in 25.7%, reconstructive failure in 11.5%, wound healing issues in 13.5%, wound infections in 10.8%), without severe complications in 83.8% of operations [60]. Other retrospective study with 102 patients and 174 IBBR using ULTRAPRO, which included 45.1% patients with previous radiotherapy and pre-existing scars, recorded complications in 18.3%, (6.9% minor and 11.4% major, requiring revision) [19]. A similar report with 70 cases of reconstructed breast using SURGIMESH found no statistical significances in outcomes compared with standard IBBR without meshes [61]. Another paper about the use of polyester mesh (Mersilene) in 73 patients reported an explantation rate of 4.1%, although the surgical technique included an abdominal advancement flap [62]. One abstract reported similar results with polyester mesh, titanium mesh, and ADM in 104 cases, with excellent results in 67.3% of them [63].

The best report till the date is a prospective, multicentre cohort study in the United Kingdom, where 2108 patients were recruited to establish the short-term safety of immediate IBBR performed with and without mesh, either biological or synthetic, in prepectoral or submuscular pockets. After 3 months of surgery, 9% of the patients suffered implant loss, 18% required readmission, 18% needed a second surgery because of the complications, and 25% had treatment for an infection, with no differences regarding mesh use or type [2]. This analysis also identified an association between infection and previous radiotherapy. Ages, neoadjuvant chemotherapy, bilateral surgery, indication for surgery, nipple-sparing procedure,

Ref. No	Surgical technique	Mesh type	Breasts no.	Infection	Explantation	Necrosis	Seroma/hematoma	Contracture grade III–IV	Reoperation	Total	Aesthetic Ex+G	RT
[2]	All	ADM TiLOOP	1133 243	22.0 26.0	8.0 10.0				17.0 20.0			7.0
[3]	All	TiLOOP None	48 42	6.0 14.2		4.1 14.2	2/0 6/4.1	4.1 16.6	6.0 4.1	21.1 28.6	NS	
[8]	Submuscular	TIGR	54	1.7		5.0	3.3/6.7	1.7	11.6	23.3		10.2
[9]		TiLOOP Strattice	79 35		6.0 6.0					18.0 22.0		
[19]	Submuscular	ULTRAPRO	174	4.5		4.0	5.1/1.2	1.2	6.3	18.3		41.5
[21]	Revisional	TIGR	112	3.6		1.8	1.8		15.2	20.5		14.5
[22]		P4HB ADM	110 198	8.0 15.0	6.0 8.0							28.0 37.0
[24]		Protexa TiLOOP	25* 23*	12.0 4.3	30.4 7.7		12.0 4.3/8.6			39.1 24.0	79.0 87.5	16.0 0.0
[26]	Submuscular	TiLOOP	231	6.1	8.7	4.3	4.8/9.5	2.2		29.0		2.1
[41]		Surgisis TIGR	116 65		15.1 4.9			5.5 4.9		35.8 29.3	NS	
[42]	Prepectoral	ADM and TIGR	200		3.5		0.0/4.0	0.0			90.0	13.0
[44]	Submuscular	Vicryl	76	1.3	1.3	2.6	0.0/0.0	1.3	3.9	6.6		18.4
[45]	Submuscular	TIGR	65	1.5	3.1	1.5	3.1/1.5		1.5	23.2		
[46]	Submuscular	TIGR	54	1.7		5.0	3.3/6.7	1.7	11.6			10.2
[47]	All	TIGR	40	7.5		7.5	5.0/0.0					22.5
[48]	Submuscular expander	TiLOOP	237	2.5		1.3	1.2/0.0	3.8	6.7		BREAST-Q 1	26.5

Ref. No	Surgical technique	Mesh type	Breasts no.	Infection	Explantation	Necrosis	Seroma/hematoma	Contracture grade III–IV	Reoperation	Total	Aesthetic Ex+G	RT
[49]	Submuscular Prepectoral	TiLOOP	34	5.8	0.0	0.0	0.0/0.0					
			39	0.0	2.5	2.5	0.0/2.5					
[51]	Prepectoral	TiLOOP	250	0.8	1.2	0.8	0.0/0.4	4.0	2.4		BREAST-Q 2	7.2
[53]		TiLOOP	87*	10.3			9.2/17.2					
[57]	Submuscular	TiLOOP	269*			0.7		0.3			BREAST-Q 3	9.7
[60]	All	SERAGYN	148	14.2		8.1	25.7/14.2	1.4	22.9			17.6
[19]	Submuscular	ULTRAPRO	174	4.5		4.0	5.1/1.2	1.2	11.4			45.1
[61]	Submuscular	SURGIMESH	70	10.0	7.1	10.0	8.5/1.4	7.1				12.7
		None	136	5.88	10.0	10.0	7.3/0.0					
[62]	Submuscular	Mersilene	73*	1.4	4.1			13.6	19.2		77.5	

Aesthetic Ex+G: aesthetic results excellent and goods.

RT: % of cases with pre- and postoperative radiotherapy.

NS: not significant.

*Number of patients (number of cases not reported).

BREAST-Q 1: overall satisfaction with outcome 74.0, satisfaction with breasts 72.2, psychosocial wellness 77.5, and sexual well-being 61.6.

BREAST-Q 2: overall satisfaction with outcome 73.8, satisfaction with breasts 72.5, psychosocial wellness 77.7, and sexual well-being 57.9.

BREAST-Q 3: overall satisfaction with outcome 74.8, satisfaction with breasts 60.2, psychosocial wellness 71.3, and sexual well-being 56.4.

Table 1.
Number of complications is given in percentage.

fixed-volume implant, and type of reconstruction were not significant risk factors. A summary of all these data is shown in **Table 1**. A number of studies are currently underway in Europe [64].

It is well known that radiotherapy has a significantly detrimental effect on most breast reconstruction outcomes, whether given pre- or postoperatively (but without differences in complication rates between both) [65], since it impedes neovascularisation and mesh incorporation into the host [1]. Most published studies identify radiotherapy as adversely affecting the cosmetic outcome by precipitating the inflammatory reaction of the implant to the surrounding tissues. Becker described frequent complications in patients that received radiotherapy and were reconstructed with TIGR mesh [21]. Similar results were reported by Dieterich et al. using TiLOOP mesh [26] and by others using ADM [1, 4, 66–68]. On the other hand, some protective effects of matrices against radiotherapy, compared with those patients without them, have been reported, since biological meshes appear to limit the elastosis and chronic inflammation seen in irradiated IBBR [69, 70].

To sum up, the literature on this subject is difficult to interpret because there is neither high-quality evidence comparing outcomes of mesh-assisted IBBR with traditional IBBR or comparing matrices with meshes. Most studies in this area are small, single-centre, retrospective cohort studies and case series with methodological limitations: different surgical techniques, with different meshes and matrices, differing in sizes and positions, with very disparate ways of reporting complications (in fact, it is often unclear what complications have been included and how they have been diagnosed and how and when capsular contracture and aesthetic outcome have been evaluated), thus carrying a low level of evidence [37]. Randomised clinical trials with sufficient periods of follow-up should be carried out to determine whether the cost of these products is justified in terms of the benefits provided [71].

7. Conclusions

Although it is still unclear whether mesh procedures are a safe alternative to traditional IBBR regarding patient-reported outcomes, matrices and meshes have proven to wear valuable advantages. Moreover, there is not even a consensus on which of the two types produces the best outcomes, although there is a trend to consider that meshes bring comparable aesthetic outcomes to matrices, with lower costs and complication rates. Regarding the uncertainty about the best position for the implant, either submuscular or subcutaneous, the prepectoral position is gaining ground quickly among surgeons and patients.

Most of the literature have focused on the complication and safety profiles of these meshes, but, given that the purpose of breast reconstruction is to improve body image and psychosocial function, it is equally important that cosmesis and patient satisfaction are also included when evaluating the results of these techniques.

Conflict of interest

The authors declare no conflict of interest.

IntechOpen

IntechOpen

Author details

Susana Gómez-Modet and Luis Tejedor*
Punta Europa Hospital, Algeciras, Spain

*Address all correspondence to: tejedor@comcadiz.es

IntechOpen

© 2020 The Author(s). Licensee IntechOpen. This chapter is distributed under the terms of the Creative Commons Attribution License (<http://creativecommons.org/licenses/by/3.0>), which permits unrestricted use, distribution, and reproduction in any medium, provided the original work is properly cited. 

References

- [1] Ellis HL, Asaolu O, Nebo V, et al. Biological and synthetic mesh use in breast reconstructive surgery: A literature review. *World Journal of Surgical Oncology*. 2016;**14**:121. DOI: 10.1186/s12957-016-0874-9
- [2] Potter S, Conroy EJ, Cutress RI, et al. Short-term safety outcomes of mastectomy and immediate implant-based breast reconstruction with and without mesh (iBRA): A multicentre, prospective cohort study. *The Lancet Oncology*. 2019;**20**:254-266
- [3] Dieterich M, Angres J, Stachs A, et al. Patient-report satisfaction and health-related quality of life in tiloop bra- assisted or implant-based breast reconstruction alone. *Aesthetic Plastic Surgery*. 2015;**39**:523-533
- [4] Spear SL, Parikh PM, Reisin E, et al. Acellular dermis-assisted breast reconstruction. *Aesthetic Plastic Surgery*. 2008;**32**:418-425
- [5] Nava M. Breast reconstruction with form-stable implants. In: *Surgery of the Breast, Principles and Art*. 3rd ed. Vol. 36. 2011. pp. 429-437
- [6] Paepke S, Ohlinger R, Klein E, et al. Prepectoral implant placement in plastic-reconstructive breast surgery- a contribution to the discussion. *Senology*. 2018;**15**:115-119
- [7] Tasoulis MK, Iqbal FM, Cawthorn S, et al. Subcutaneous implant breast reconstruction: Time to reconsider? *European Journal of Surgical Oncology*. 2017;**43**:1636-1646
- [8] Pompei S, Evangelidou D, Arelli F, et al. The use of TIGR matrix in breast aesthetic and reconstructive surgery. Is a resorbable synthetic mesh a viable alternative to acellular dermal matrices? *Clinics in Plastic Surgery*. 2018;**45**:65-73
- [9] McKenna A, Hamilton-Burke W, Bathia S, et al. A comparative study of titanium-coated propylene mesh with acellular dermal matrix in implant based breast reconstruction. *European Journal of Surgical Oncology*. 2017;**43**:S47. DOI: 10.1016/j.ejso.2017.01.180
- [10] Dieterich M, Faridi A. Biological matrices and synthetic meshes used in implant-based breast reconstruction- a review of products available in Germany. *Geburtshilfe und Frauenheilkunde*. 2013;**73**:1100-1106
- [11] Wainwright DJ. Use of an acellular allograft dermal matrix (AlloDerm) in the management of full-thickness burns. *Burns*. 1995;**21**(4):243-248
- [12] Butler CE, Langstein HN, Kronowitz SJ. Pelvic, abdominal, and chest wall reconstruction with AlloDerm in patients at increased risk for mesh-related complications. *Plastic and Reconstructive Surgery*. 2005;**116**(5):263-275
- [13] Chaplin JM, Costantino PD, Wolpoe ME, et al. Use of an acellular dermal allograft for dural replacement: An experimental study. *Neurosurgery*. 1999;**45**(2):320-327
- [14] Breuing KH, Warren SM. Immediate bilateral breast reconstruction with implants and inferolateral AlloDerm slings. *Annals of Plastic Surgery*. 2005;**55**(3):232-239
- [15] Salzberg CA. Nonexpansive immediate breast reconstruction using human acellular tissue matrix graft (AlloDerm). *Annals of Plastic Surgery*. 2006;**57**(1):1-5
- [16] Bindingnavele V, Gaon M, Ota KS, et al. Use of acellular cadaveric dermis and tissue expansion in postmastectomy breast reconstruction. *Journal of Plastic, Reconstructive & Aesthetic Surgery*. 2007;**60**(11):1214-1218

- [17] Preminger BA, McCarthy CM, Hu QY, et al. The influence of AlloDerm on expander dynamics and complications in the setting of immediate tissue expander/implant reconstruction: A matched-cohort study. *Annals of Plastic Surgery*. 2008;**60**(5):510-513
- [18] Fitzgerald JF, Kumar AS. Biologic versus synthetic mesh reinforcement: What are the pros and cons? *Clinics in Colon and Rectal Surgery*. 2014;**27**(4):140-148. DOI: 10.1055/s-0034-1394155
- [19] Pukancsik D, Kelemen P, Gulyás G, et al. Clinical experiences with the use of ULTRAPRO mesh in single-stage direct-to-implant immediate postmastectomy breast reconstruction in 102 patients: A retrospective cohort study. *European Journal of Surgical Oncology*. 2017;**47**:1244-1251
- [20] Cook LJ, Kovacs T. Novel devices for implant-based breast reconstruction: Is the use of meshes to support the lower pole justified in terms of benefits? A review of the evidence. *Ecancermedicalscience*. 2018;**10**(12):796. DOI: 10.3332/ecancer.2018.796
- [21] Becker H, Lind JG. The use of synthetic mesh in reconstructive, revision, and cosmetic breast surgery. *Aesthetic Plastic Surgery*. 2013;**37**:914-921
- [22] Levy AS, Bernstein JL, Otter-burn DM. Biosynthetic mesh compares favorably to ADM in tissue expander-based breast reconstruction. *Plastic and Reconstructive Surgery*. *Global Open*. 2017;**5**(48):86-87. DOI: 10.1097/01.GOX.0000516637.00470.c0
- [23] de Vita R, Buccheri EM, Villanucci A, et al. Breast reconstruction actualized in nipple-sparing mastectomy and direct-to-implant, prepectoral polyurethane positioning: Early experience and preliminary results. *Clinical Breast Cancer*. 2019;**19**(2):e358-e363
- [24] Gschwantler-Kaulich D, Schrenk P, Bjelic-Radisic V, et al. Mesh versus acellular dermal matrix in immediate implant-based breast reconstruction-a prospective randomized trial. *European Journal of Surgical Oncology*. 2016;**42**:665-671
- [25] Marcasciano M, Kaliulyte J, Gen Tilucci M, et al. Skin-reduction breast reconstructions with prepectoral implant covered by a combined dermal flap and titanium-coated polypropylene mesh. *Journal of Plastic, Reconstructive & Aesthetic Surgery*. 2018;**71**(8):1123-1128. DOI: 10.1016/j.bjps.2018.05.005
- [26] Dieterich M, Paepke S, Zwiefel K, et al. Implant-based breast reconstruction using a titanium-coated polypropylene mesh (TiLOOP bra): a multicenter study of 231 cases. *Plastic and Reconstructive Surgery*. 2013;**132**:8e-19e
- [27] Nyame TT, Lemon KP, Kolter R, et al. High-throughput assay for bacterial adhesion on acellular dermal matrices and synthetic surgical materials. *Plastic and Reconstructive Surgery*. 2011;**128**:1061-1068
- [28] Bengtson B. Discussion: Use of dermal matrix to prevent capsular contracture in aesthetic breast surgery. *Plastic and Reconstructive Surgery*. 2012;**130**:1374-1375
- [29] Wagner RD, Braun TL, Zhu H, et al. A systematic review of complications in prepectoral breast reconstruction. *Journal of Plastic, Reconstructive & Aesthetic Surgery*. 2019;**72**:1051-1059
- [30] Dieterich M, Dieterich H, Timme S, et al. Using a titanium-coated polypropylene mesh (TiLOOP (R)) bra for implant-based breast reconstruction: Case report and histological analysis.

Archives of Gynecology and Obstetrics. 2012;**286**:273-276

[31] Kim JYS, Davila AA, Persing S, et al. A meta-analysis of human acellular dermis and submuscular tissue expander breast reconstruction. *Plastic and Reconstructive Surgery*. 2012;**129**(1):28-41. DOI: 10.1097/PRS.0b013e3182361fd6

[32] Brown M, Namnoum JD. Indications and controversies for implant-only based breast reconstruction. *Clinics in Plastic Surgery*. 2018;**45**:47-54

[33] Potter S, MacKenzie M, Blazeby JN. Does the addition of mesh improve outcomes in implant based breast reconstruction after mastectomy for breast cancer? *BMJ*. 2018;**362**:k2607. DOI: 10.1136/bmj.k2607

[34] Martin L, O'Donoghue JM, Horgan K, et al. Acellular dermal matrix (ADM) assisted breast reconstruction procedures: Joint guidelines from the Association of Breast Surgery and the British Association of Plastic, Reconstructive and Aesthetic Surgeons. *European Journal of Surgical Oncology*. 2013;**39**(5):425-429. DOI: 10.1016/j.ejso.2012.12.012

[35] Vidya R, Berna G, Sbitany H, et al. Prepectoral implant-based breast reconstruction: A joint consensus guide from UK, European and USA breast and plastic reconstructive surgeons. *ecancer*. 2019;**13**:927. DOI: 10.3332/ecancer.2019.927

[36] Cabalag MS, Rostek M, Miller GS, et al. Alloplastic adjuncts in breast reconstruction. *Gland Surgery*. 2016;**5**(2):158-173. DOI: 10.3978/j.issn.2227-684X.2015.06.02

[37] Hallberg H, Rafnsdottir S, Selvaggi G, et al. Benefits and risks with acellular dermal matrix (ADM) and mesh support in immediate breast reconstruction: a systematic review and

meta-analysis. *Journal of Plastic Surgery and Hand Surgery*. 2018;**52**:130-147. DOI: 10.1080/2000656X.2017.1419141. 29320921

[38] Sigalove S, Maxwell GP, Sigalove NM, et al. Prepectoral implant-based breast reconstruction: Rationale, indications, and preliminary results. *Plastic and Reconstructive Surgery*. 2017;**139**:287-294

[39] Pannucci CJ, Antony AK, Wilkins EG. The impact of acellular dermal matrix on tissue expander/implant loss in breast reconstruction: An analysis of the tracking outcomes and operations in plastic surgery database. *Plastic and Reconstructive Surgery*. 2013;**132**(1):1-10. DOI: 10.1097/PRS.0b013e318290f917

[40] Salibian AH, Harness JK, Mowlds DS. Staged suprapectoral expander/implant reconstruction without acellular dermal matrix following nipple-sparing mastectomy. *Plastic and Reconstructive Surgery*. 2017;**139**(1):30-39. DOI: 10.1097/PRS.00000000000002845

[41] Hallberg H, Flander a KL, et al. A biological or a synthetic mesh in immediate breast reconstruction? A cohort study of long-term health related quality of life (HrQoL). *European Journal of Surgical Oncology*. 2019;**45**(10):1812-1816. DOI: 10.1016/j.ejso.2019.03.013

[42] Reitsamer R, Peintinger F, Klaassen-Federspiel F, et al. Prepectoral direct-to-implant breast reconstruction with complete ADM or synthetic mesh coverage. 36-months follow-up in 200 reconstructed breasts. *Breast*. 2019;**48**:32-37. DOI: 10.1016/j.breast.2019.08.002

[43] Salibian AH, Frey JD, Choi M, et al. Subcutaneous implant-based breast reconstruction with acellular dermal matrix/mesh: A systematic review.

Plastic and Reconstructive Surgery
 Global Open. 2016;**23**(4):11, e1139. DOI:
 10.1097/GOX.0000000000001139

[44] Tessler O, Reish RG, Maman DY,
 et al. Beyond biologics: Absorbable
 mesh as a low-cost, low-
 complication sling for implant-
 based breast reconstruction.
 Plastic and Reconstructive Surgery.
 2014;**133**(2):90e-99e. DOI: 10.1097/01.
 prs.0000437253.55457.6339

[45] Hallberg H, Lewin R, Elander A,
 et al. TIGR[®] matrix surgical mesh—A
 two-year follow-up study and
 complication analysis in 65
 immediate breast reconstructions.
 Journal of Plastic Surgery and Hand
 Surgery. 2018;**52**(4):253-258. DOI:
 10.1080/2000656X.2018.1478841

[46] Pompei S, Evangelidou D, Arrelli F,
 et al. The use of TIGR matrix in breast
 aesthetic and reconstructive surgery. Is
 a reabsorbable synthetic mesh a viable
 alternative to acellular dermal matrices?
 Clinics in Plastic Surgery. 2018;**45**:65-73.
 DOI: 10.1016/j.cps.2017.08.005

[47] Cuffolo G, Holford N, Contractor K,
 et al. TIGR matrix synthetic long-term
 reabsorbable mesh for prepectoral
 and subpectoral implant based breast
 reconstruction: Outcomes of two
 years practice. European Journal of
 Surgical Oncology. 2019;**45**(5):915. DOI:
 10.1016/j.ejso.2019.01.138

[48] Schrenk P. Immediate implant-
 based breast reconstruction using the
 TIGR[®] matrix mesh. Breast Cancer
 Management. 2016;**5**(2):53-59

[49] Irwin G, Darragh L, Mallon P,
 et al. TIGR matrix mesh in breast
 reconstruction. A single unit
 experience. European Journal of
 Surgical Oncology. 2017;**43**(5):S24. DOI:
 10.1016/j.ejso.2017.01.099

[50] Casella D, Di Taranto G,
 Marcasciano M, et al. Subcutaneous

expanders and synthetic mesh for breast
 reconstruction: Long-term and patient-
 reported BREAST-Q outcomes of a
 single-center prospective study. Journal
 of Plastic, Reconstructive & Aesthetic
 Surgery. 2019;**72**(5):805-812. DOI:
 10.1016/j.bjps.2018.12.018

[51] Casella D, Bernini M, Bencini L,
 et al. TiLoop[®] bra mesh used for
 immediate breast reconstruction:
 Comparison of retropectoral and
 subcutaneous implant placement in a
 prospective single-institution series.
 European Journal of Plastic Surgery.
 2014;**37**(11):599-604

[52] Bernini M, Calabrese C, Cecconi L,
 et al. Subcutaneous direct-to-implant
 breast reconstruction: Surgical,
 functional, and aesthetic results
 after long-term follow-up. Plastic
 and Reconstructive Surgery. Global
 Open;**3**(12):-e574

[53] Casella D, Di Taranto G,
 Marcasciano M, et al. Evaluation of
 prepectoral implant placement and
 complete coverage with TiLoop bra
 mesh for breast reconstruction: A
 prospective study on long-term and
 patient-reported BREAST-Q outcomes.
 Plastic and Reconstructive Surgery.
 2019;**143**(1):1e-9e. DOI: 10.1097/
 PRS.00000000000005078

[54] Riggio E, Chifu C, Martelli G,
 et al. Can titanium mesh influence
 local recurrence management after
 implant-based breast reconstruction?
 Springerplus. 2015;**4**(4):482. DOI:
 10.1186/s40064-015-1273-3

[55] Klein E, Kiechle M, Paepke S.
 Analysis of immediate breast
 reconstruction with the use of titanized
 polypropylene mesh (TiLOOP[®] bra).
 European Journal of Surgical Oncology.
 2013;**39**(5):482. DOI: 10.1016/j.
 ejso.2013.01.109

[56] Rezai M, Strauss S, Kimmig R,
 et al. Risk-reducing, conservative

mastectomy—Analysis of surgical outcome and quality of life in 272 implant-based reconstructions using TiLoop[®] bra versus autologous corial flaps. *Gland Surgery*. 2016;**5**(1):1-8. DOI: 10.3978/j.issn.2227-684X.2015.07.03

[57] Paepke S, Klein E, Kiechle M, et al. Implant-based mesh supported breast reconstruction: Patient reported outcome data (PRO-BRA trial, TiLOOP[®] bra) and perspectives. *European Journal of Cancer*. 2018;**92**(3):S87

[58] Caldon L, Allison C, Cain H, et al. The use of titanium mesh (TiLOOP) in immediate breast reconstruction; low cost, low complications. *European Journal of Surgical Oncology*. 2015;**41**(6):S69-S70. DOI: 10.1016/j.ejso.2015.03.193

[59] Eichler C, Schulz C, Thangarajah F, et al. A retrospective head-to-head comparison between TiLoop bra/ TiMesh[®] and Seragyn[®] in 320 cases of reconstructive breast surgery. *Anticancer Research*. 2019;**39**(5):2599-2605. DOI: 10.21873/anticancer.13383

[60] Machleidt A, Schmidt-Feuerheerd N, Blohmer JU, et al. Reconstructive breast surgery with partially absorbable bi-component Seragyn[®] BR soft mesh: An outcome analysis. *Archives of Gynecology and Obstetrics*. 2018;**298**(4):755-761. DOI: 10.1007/s00404-018-4859-5

[61] Baldelli I, Cardoni G, Franchelli S, et al. Implant-based breast reconstruction using a polyester mesh (Surgimesh-PET): A retrospective single-center study. *Plastic and Reconstructive Surgery*. 2016;**137**(6):931e-939e. DOI: 10.1097/PRS.0000000000002180

[62] Rietgens M, De Lorenzi F, Venturino M, et al. The suspension technique to avoid the use of tissue expanders in breast reconstruction.

Annals of Plastic Surgery. 2005;**54**:467-470. DOI: 10.1097/01.sap.0000155283.77188.63

[63] Sukhotko A, Zikiryahodjaev AD, Ermoshchenkova MV, et al. Implant-based breast cancer reconstruction with biological matric or synthetic mesh. *Annals of Oncology*. 2019;**30**(3):iii44

[64] Paepke S, Kiechle M, Ankel C, et al. Surgical studies of reconstructive breast surgery—An overview of the topics at the 2019 annual meeting of the Working Group for Reconstructive Surgery in oncology-gynecology. *Geburtshilfe und Frauenheilkunde*. 2019;**79**:584-590

[65] Momoh AO, Ahmed R, Kelley BP, et al. A systematic review of complications of implant-based breast reconstruction with pre-reconstruction and post-reconstruction radiation therapy. *Annals of Surgical Oncology*. 2014;**21**(1):118-124. DOI: 10.1245/s10434-013-3284-z

[66] Nahabedian MY. AlloDerm performance in the setting of prosthetic breast surgery, infection, and irradiation. *Plastic and Reconstructive Surgery*. 2009;**124**(6):1743-1753

[67] Rawlani V, Buck DW 2nd, Johnson SA, et al. Tissue expander breast reconstruction using prehydrated human acellular dermis. *Annals of Plastic Surgery*. 2011;**66**(6):593-597

[68] Chun YS, Verma K, Rosen H, et al. Implant-based breast reconstruction using acellular dermal matrix and the risk of postoperative complications. *Plastic and Reconstructive Surgery*. 2010;**125**(2):429-436

[69] Moyer HR, Pinell-White X, Losken A. The effect of radiation on acellular dermal matrix and capsule formation in breast reconstruction: Clinical outcomes and histologic analysis. *Plastic and Reconstructive Surgery*. 2014;**133**:214-221

[70] Seth AK, Hirsch EM, Fine NA, et al. Utility of acellular dermis-assisted breast reconstruction in the setting of radiation: A comparative analysis. *Plastic and Reconstructive Surgery*. 2012;**130**:750-758

[71] Mylvaganam S, Conroy E, Williamson PR, et al. Variation in the provision and practice of implant-based breast reconstruction in the UK: Results from the iBRA national practice questionnaire. *Breast*. 2017;**35**:182-190. DOI: 10.1016/j.breast.2017.07.016