

# We are IntechOpen, the world's leading publisher of Open Access books Built by scientists, for scientists

6,900

Open access books available

185,000

International authors and editors

200M

Downloads

Our authors are among the

154

Countries delivered to

TOP 1%

most cited scientists

12.2%

Contributors from top 500 universities



WEB OF SCIENCE™

Selection of our books indexed in the Book Citation Index  
in Web of Science™ Core Collection (BKCI)

Interested in publishing with us?  
Contact [book.department@intechopen.com](mailto:book.department@intechopen.com)

Numbers displayed above are based on latest data collected.  
For more information visit [www.intechopen.com](http://www.intechopen.com)



# Vascular Calcifications

*Mehmet Erin Tüysüz and Mehmet Dedemoğlu*

## Abstract

Calcium-phosphate levels have an effect on the vascular wall. Calcium is a cation in human body. It has a crucial effect on intracellular and extracellular mechanisms. Extracellular calcium levels are more than intracellular levels. In total serum, the calcium level is approximately 8.8–10.4. Parathormone and vitamin D regulate blood calcium levels. Phosphorus is more common than calcium in the human body. Most of the phosphorus is present in the skeletal system. Phosphorus level is approximately 2.5–4.5 mg/dl in blood. It is often observed calcification in cardiovascular system in some diseases such as chronic renal failure due to increased calcium-phosphate levels. While the calcification seems in tunica intima layer of the vessel in atherosclerotic disease, it seems in tunica media layer of vessel in chronic renal failure with high uremic level. Vascular calcification is due to arterial stiffness, stenosis, and occlusion. Vascular and valvular calcifications are irreversible. Increased arterial stiffness destroys vascular compliance, causes left ventricular hypertrophy, and disrupts coronary perfusion. As a result, increased vascular calcification is associated with cardiovascular mortality.

**Keywords:** cardiovascular calcification, arterial stiffness, vascular compliance, hyperparathyroidism, hyperphosphatemia

## 1. Introduction

Cardiovascular pathologies are still one of the most serious diseases in the world and are also known to be an important reason of mortality and morbidity. Furthermore, they cause a significant burden on the health costs. The understanding of pathophysiology of cardiovascular diseases has an important role for the treatment success. In this chapter, vascular calcification mechanism and its results will be discussed.

There are several reasons leading to vascular calcifications (**Table 1**). Vascular calcifications often occur in the advanced stage of the atherosclerosis [1]. In addition to this, these calcifications may also occur as a complication of metabolic disorders in the end stage of chronic renal failure. Calcium deposits accumulate in vascular tissues as a result of secondary hyperparathyroidism that occurs in chronic renal failure [2, 3]. Another cause of vascular calcifications is familial hypercholesterolemia. Particularly severe aortic calcifications are seen in these patients [4]. Vascular calcifications associated with diabetes mellitus also affect the media and intima layer of vessels [5]. Hypertension is associated with calcifications in the abdominal aorta [6]. The other causes of vascular calcification include smoking [7], male gender [6], and older age [7]. Recently, it has been observed thanks to intravascular invasive images that the use of statins increases vascular calcification. Despite the antilipidemic and anti-inflammatory effects of it, statins cause an

Causes of vascular calcification
• Atherosclerosis
• Chronic renal failure
• Familial hypercholesterolemia
• Diabetes mellitus
• Hypertension
• Smoking
• Male gender
• Older age

**Table 1.**  
*The causes of vascular calcification.*

increased calcification in vascular tissue with an unknown mechanism. This effect is defined as the statin paradox [8].

2. Pathophysiology

Vascular smooth muscle cells (VSMCs) play an important role in the pathology of vascular calcifications. Vascular smooth muscle cells are of mesenchymal origin. These cells may turn into osteoblasts and chondrocytes under stress. Osteoblast-like cells that contain hydroxyapatite crystals appear in the extracellular matrix during vascular smooth muscle calcification. Subsequently, the number of osteochondrogenic cells increases, and calcification inhibitors are suppressed; an increased regulation of bone mineralization regulating genes and the release of calcified membrane-dependent carriers from smooth muscle cells in these calcifications are observed. In addition, intracellular phosphate concentration increases in osteoblast-like cells due to developing hyperphosphatemia in chronic renal failure. Apoptosis in smooth muscle cells, oxidative stress, remodeling in extracellular matrix, and high levels of metalloproteinases increase vascular calcification, resulting in endothelial dysfunction [9].

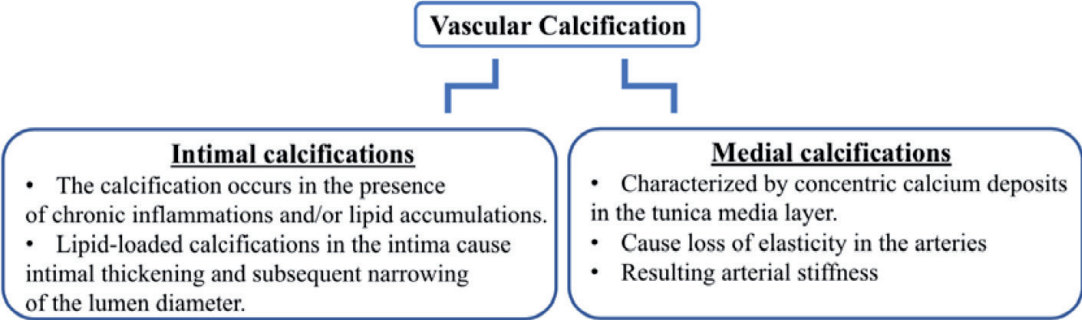
Vascular smooth muscle cells are the predominant cell type in the arterial wall. VSMCs are mainly composed of the medial layer of the blood vessels, which are subjected to mechanical stress and pressure of blood flow, and maintain vascular tone and resistance [10]. Calcium functions as a stimulator, and under physiological conditions, intracellular calcium is present in VSCMs to regulate many biophysical and biochemical processes [11]. Although the agents responsible for production of vasospasm have not yet been clearly identified, recently the molecular mechanisms involved in the development of vasospasm mainly based on experimental data in canine two-hemorrhage model are reviewed. The blood products after subarachnoid hemorrhage most likely stimulate many cell membrane receptors to activate the tyrosine kinase pathway of WSCMs. The activation of the tyrosine kinase pathway is associated with continuous elevation of intracellular Ca++ levels and activation of mu-calpain. The increased intracellular Ca++ concentration stimulates Ca++/calmodulin and depends on myosin light-chain kinase to phosphorylate myosin light-chain continuously during vasospasms [12]. Cerebral vasospasm is the most frequent and troublesome complication after aneurysmal subarachnoid hemorrhage. Cerebral vasospasm is considered a treatable clinicopathological entity; it is still responsible for many deaths and serious disabilities among patients suffering from intracranial aneurysm rupture [13].

### 3. Classification

Vascular calcifications are divided into two subtypes (**Figure 1**). These are called intima and media calcifications according to the localization of calcification.

Intimal calcifications or the so-called atherosclerotic calcifications begin to occur in the presence of chronic inflammations and/or lipid accumulations. Lipid-loaded calcifications in the intima cause intimal thickening and subsequent narrowing of the lumen diameter.

Medial calcifications are characterized by concentric calcium deposits in the tunica media layer. Here, elastin lamellae occur between the smooth muscle cells and the elastin fibers. Medial calcifications cause loss of elasticity in the arteries, resulting in arterial stiffness [9].



**Figure 1.**  
*The classification of vascular calcification.*

### 4. Imaging methods

Various methods are used to visualize calcifications. Macrocalcifications can be seen in three ways:

1. Speckled: spotty calcification flecks, up to 50  $\mu\text{m}$  diameters
2. Sheetlike fragments: linear or wide single focus of calcium, >2 mm in diameter
3. Diffuse: segments of continuous calcification,  $\geq 5$  mm in diameter

Imaging methods can be performed as noninvasive and invasive (**Table 2**).

#### 4.1 Noninvasive methods

Computerized tomography (CT) is the gold standard for imaging calcifications. 400  $\mu\text{m}$  of calcification can be shown as 2D and 3D with the help of CT. However, the calcifications sometimes can be seen as more exaggerated than usual because of the absorption of high X-rays by neighboring tissues in CT imaging. This exaggerated image (artifact) may mask parts of calcification in the proximal region of the lesions. In this case, the artifact can be distinguished from the surrounding soft tissue with the help of magnetic resonance imaging (MRI). MRI is also superior to CT in differentiating multiple components including the coexistence of lipid accumulation, fibrotic tissue, and calcifications.

Microcalcifications can be detected by the use of positron emission tomography (PET) which is one of the other noninvasive methods. Early microcalcifications are shown using indirect gamma rays with the aid of 18F-sodium fluoride. With the use

The imaging methods for vascular calcification
Noninvasive methods
• Computerized tomography (CT)
• Magnetic resonance imaging (MRI)
• Positron emission tomography (PET)
Invasive methods
• Intravascular ultrasound (IVUS)
• Optical coherence tomography (OCT)

**Table 2.**  
*The imaging methods for vascular calcifications.*

of MRI or CT combined with PET, we can obtain more detailed information about the effects of calcifications, interactions with fibrotic tissue, and plaque geometry.

4.2 Invasive methods

In recent years, intravascular ultrasound (IVUS) has been widely used in the detection of vascular calcifications, and its success is 50% higher than CT imaging. However, in the vessels with severe calcifications, they may not be able to adequately measure volume and wall thickness due to acoustic shadowing and insufficient penetration into macrocalcific deposits.

Optical coherence tomography (OCT) is an alternative modality using infrared ray. The specificity and sensitivity of this method is higher than other methods. OCT also identifies superficial calcifications in the vessels. In addition, in the case of acute plaque rupture, OCT detects spot calcifications in the areas of plaque near the lumen and the thinning of the vessel wall [14].

5. Clinical properties

The calcifications may occur in all anatomic structures of the cardiovascular system. Pericardial calcifications occur secondary to inflammation. Calcification of this type is usually asymptomatic; however, the clinical findings are observed when it causes constrictive pericarditis [15].

Myocardial calcifications are metastatic or dystrophic calcifications. Metastatic calcifications develop after impaired calcium metabolism due to chronic renal failure or hyperparathyroidism. Dystrophic calcifications develop as a result of myocardial fibrosis, infections, sarcoidosis, and hemorrhagic events in the myocardium. The cell necrosis occurs in this pathology, resulting in myocardial damage. This type of calcification leads to local myocardial contraction disorder, diastolic dysfunction, arrhythmia, and eventually congestive heart failure [16].

Epidemiological studies have found a strong association between calcification and coronary artery-related event and mortality using coronary artery calcification scores. Cardiovascular prognosis and mortality can be predicted with these scoring. Calcifications have an important role in thrombotic complications of atherosclerosis. Progression in coronary artery calcification shows active atherosclerosis and high rupture risk in unstable plaques. On the other hand, calcifications in the coronary artery cause some problems in the invasive treatments. During percutaneous transluminal coronary angioplasty (PTCA), a high dilatation pressure is required due to calcific coronary artery structure. Technical difficulties also arise when adjusting the position



of the stent. As a result, coronary artery calcifications cause dissection, thrombosis, and restenosis during PTCA [17]. Another issue is that long-term prognosis of patients who underwent PTCA for moderate and severe coronary artery calcification is also poor [18].

Calcifications also affect heart valves. The annulus of the mitral valve is affected from this calcification, especially in female, elder patients and in case of chronic renal failure, radiotherapy applications. The pathophysiology of mitral annular calcification (MAC) is similar to that of atherosclerosis. Excessive MAC makes it difficult to perform balloon valvuloplasty and valve-sparing surgical procedures. On the other hand, in patients with MAC who underwent valve replacement, para-valvular leakage, the circumflex coronary artery injury, arrhythmia, and patient artificial valve mismatch (because of the condition of small-size valve usage) may be observed [19]. During transcatheter mitral valve replacements, calcifications may lead to left ventricle outflow obstruction and paravalvular leakage [20].

Calcific aortic valve disease is the most common form of calcific valvular pathology. When we look at the pathogenesis of this disease, the ectopic calcium nodules are located on the aortic surface of the aortic valve and in the aortic annulus. The incidence of calcific aortic valve increases with age. However, calcification of bicuspid valves may be seen at an early age. Risk factors are similar to other cardiovascular diseases. Calcifications can reduce the success of prosthetic aortic valve surgery [21]. In the late stages of valve replacement for calcific aortic valve stenosis, fistulas may develop between the left ventricle and the right atrium [22]. In transcatheter aortic valve implantations (TAVI), the degree of valve calcification is routinely evaluated by preoperative multi-slice CT. In this way, the information about the presence of asymmetric calcification is obtained before the procedure [23]. As a complication, cerebral emboli originating from calcific aortic valve stenosis may occur [24]. In addition, valve degeneration may occur secondary to calcification in patients undergoing valve replacement with bioprosthetic valve [25].

Excessive aortic valve calcification and metastatic calcifications due to chronic renal failure and hyperparathyroidism may affect the conduction system of the heart. Many arrhythmia types, from nodal rhythm to branch blocks, may be observed due to these calcifications [26–28].

Calcifications in the arcus and thoracic aorta cause aneurysm development, aortic occlusions, and distal embolization. These calcifications in the aortic wall also affect the success of endovascular stenting and surgical interventions [29]. It has been observed that the possibility of developing intermittent claudication is increased in the follow-up of patients with abdominal aortic calcification [30].

Intracranial artery calcification has been demonstrated to be correlated with ischemic stroke, cognitive decline, and other vascular events by accumulating evidence from both Western and Asian populations [31]. As atherosclerotic vasculopathy is a systemic process, vascular calcification may play a role in cerebrovascular events in both qualitative and quantitative calcium scoring with intracranial atherosclerosis and ischemic events [32]. On the other hand, some studies showed that ruptured intracranial aneurysms had a lower calcification fraction and lacked macrocalcifications than unruptured intracranial aneurysms [33]. Another study showed that arterial calcification correlated with white matter hyperintensities and lacunes [34].

Calcification is rarely seen in the venous system. Venous calcifications in the literature are mostly associated with the portal vein [35].

## 6. Treatment

Treatment of vascular calcifications is distributed over a wide range. Developing new medications and technical devices reconstruct our treatment modalities with

that disease. As is known, vascular calcifications are the major factor limiting endovascular treatment methods. One of the methods developed to overcome this problem is the peripheral intravascular lithotripsy (IVL) system. With this method, calcific lesions can be eliminated by applying pulsatile mechanical energy under fluoroscopy [36].

Obstructive disease of infra-inguinal arteries is treated with atherectomy methods. Various atherectomy devices have been developed for this method. Some of these are rotational, phoenix, directional, orbital, etc. The B-Laser atherectomy system is one of the new generation devices. This device is equipped with an optical fiber and circumferential designed blades for transmitting laser energy. Calcifications, fibrotic atherosclerotic plaques, and re-stenotic tissues are removed with the aspiration catheter added to the system [37].

There are several studies to improve medical treatment. Experimental animal studies have shown that angiotensin II receptor inhibitors prevent the vascular calcification due to hyperphosphatemia [38]. In another experimental animal study, the use of teniposide which inhibits DNA topoisomerase II in the treatment of cancer has been shown to prevent the development of vascular calcification [39]. Vitamin K II, added to the diet in chronic renal failure, acts on calcium hemostasis by preventing bone loss. Thus, it is shown that vitamin K II can prevent vascular calcification by adding it to the treatment regimen [40]. Another treatment modality is parathyroidectomy which is applied especially in vascular calcifications as a result of calcium and phosphate metabolism-related disorders [41].

## **Author details**


Mehmet Erin Tüysüz<sup>1\*</sup> and Mehmet Dedemoğlu<sup>2</sup>

1 Department of Cardiovascular Surgery, Mersin City Training and Research Hospital, Mersin, Turkey

2 Department of Pediatric Cardiovascular Surgery, Mersin City Training and Research Hospital, Mersin, Turkey

\*Address all correspondence to: [drmehmeterin@yahoo.com](mailto:drmehmeterin@yahoo.com)

## **IntechOpen**

© 2020 The Author(s). Licensee IntechOpen. This chapter is distributed under the terms of the Creative Commons Attribution License (<http://creativecommons.org/licenses/by/3.0>), which permits unrestricted use, distribution, and reproduction in any medium, provided the original work is properly cited. 

## References

- [1] Boström K. Insight into the mechanism of vascular calcification. *The American Journal of Cardiology*. 2001;**88**:29E-22E
- [2] Giachelli CM. Vascular calcification: In vitro evidence for the role of inorganic phosphate. *Journal of the American Society of Nephrology*. 2003;**14**(Suppl 4):s300-s304
- [3] Thomson C. Vascular calcification in chronic renal failure. *Nephron. Clinical Practice*. 2003;**93**(4):c124-c130
- [4] Grenom S, Lachepelle K, Marcil M, Omeroğlu A, Genest J, Varennes B. Surgical strategies for severe calcification of the aorta (porcelain aorta) in two patients with homozygous familial hypercholesterolemia. *The Canadian Journal of Cardiology*. 2007;**23**:1159-1161
- [5] Schoen F, Cotran R. Blood vessels. In: Cotran R, Kumar V, Collins T, editors. *Robbins Pathological Basis of Disease*. 6th ed. London: W.B. Saunders; 1999. pp. 493-541
- [6] Allison M, Criqui M, Wriht C. Patterns and risk factors for systemic calcified atherosclerosis. *Arteriosclerosis, Thrombosis, and Vascular Biology*. 2004;**24**(2):331-336
- [7] Reaven P, Saks J. Reduced coronary artery and abdominal calcification in Hispanics with type 2 diabetes. *Diabetes Care*. 2004;**27**(5):1115-1120
- [8] Lee D, Joo H, Jung H, Lim D. Investigating potential mediator between statin and coronary artery calcification. *PLoS One*. 2018;**13**(9):e0203702
- [9] Belay T. Involvement of vitamin k-dependent proteins in vascular calcification. *Journal of Cardiovascular Pharmacology and Therapeutics*. 2019;**24**(4):323-333
- [10] Li N, Sanyour H, Remund T, Kelly P, et al. Vascular extracellular matrix and fibroblasts-coculture directed differentiation of human mesenchymal stem cells toward smooth muscle-like cells for vascular tissue engineering. *Materials Science and Engineering: C*. 2018;**93**:61-69. DOI: 10.1016/j.msec.2018.07.061
- [11] Huang H, Sun Z, Hill M, et al. A calcium mediated mechanism coordinating vascular smooth muscle cell adhesion during KCl activation. *Frontiers in Physiology*. 2018;**9**:a1810. DOI: 10.3389 phys.2018.01810
- [12] Tani E. Molecular mechanisms involved in development of cerebral vasospasm. *Neurosurgical Focus*. 2002;**12**:ECP1. DOI: 10.3171/foc.2002.12.3.8
- [13] Hop J, Rinkel G, Algra A, et al. Case-fatality rates and functional outcome after subarachnoid hemorrhage: A systematic review. *Stroke*. 1997;**28**:660-664
- [14] Barret H, Van der Heiden K, Farel E, et al. Calcifications in atherosclerotic plaques and impact on plaques biomechanics. *Journal of Biomechanics*. 2019;**87**:1-12
- [15] Khalid N, Ahmad SA, Shlofmitz E. Pericardial Calcification. [Updated 2019 Nov 14]. In: StatPearls [Internet]. Treasure Island (FL): StatPearls Publishing; Jan 2019. Available from: <https://www.ncbi.nlm.nih.gov/books/NBK538342/>
- [16] Yuki K, Osamu J, Atsushi K, Manabu M, Yuto K, et al. Massive bioventricular myocardial calcification in a patient with fulminant myocarditis requiring ventricular assist device support. *Internal Medicine*. 2019;**58**(9):1283-1286
- [17] Loich P, Olivier L, Jean R, Michel G, Didier C, Jean F. Coronary



- artery calcification: From crystal to plaque rupture. *Archives of Cardiovascular Diseases*. 2017;**110**(10):550-561
- [18] Zhang Y, Song L, Song Y, Xu L, Wang H, et al. Impact coronary artery lesion calcification on the long-term outcome of patients with coronary heart disease after percutaneous coronary intervention. *Zhonghua Xin Xue Guan Bing Za Zhi*. 2019;**47**(1):33-41
- [19] Philippe B, Christo M, Evin Y. Mitral annular calcification mitral stenosis: Therapeutic challenges and considerations. *Current Treatment Options in Cardiovascular Medicine*. 2019;**21**(4):19
- [20] Mohammed H, Abdallah S, Mayra G, Charanjit R, Mackram E. Paravalvular leak repair after balloon-expandable transcatheter mitral valve implantation in mitral annular calcification: Early experience and lessons learned. *Catheterization and Cardiovascular Interventions*. 2019;**94**(5):764-772
- [21] Viral M, Soy L. The genetic regulation of aortic valve development and calcific disease. *Frontiers in Cardiovascular Medicine*. 2018;**5**:162
- [22] Anderson C, Rodriguez E, Kupson A. Delayed left ventricle-to-right atrial fistula following aortic valve replacement. *The Journal of Heart Valve Disease*. 2012;**21**(3):364-365
- [23] Christian B, Maki O, Gerhard S, Cladius J, Jurgan R, Hendrick T, et al. Degree of valve calcification in patients undergoing transfemoral transcatheter aortic valve implantation with and without balloon aortic valvuloplasty: Findings from the multicenter EASE-IT TF registry. *Catheterization and Cardiovascular Interventions*. 2019;**94**(3):469-478
- [24] Vernhet H, Torres G, Laharotte S, Tournut P, Bierme T, Froment S, et al. Spontaneous calcific cerebral emboli from calcified aortic valve stenosis. *Journal of Neuroradiology*. 1993;**20**(1):19-23
- [25] Rutkovskaya N, Kagan E, Kondyukova N, Kuzmina O, Barborash L. Prediction of risk of calcification of heart valve bioprostheses on the basis of comprehensive assessment of recipients clinical factors and their compliance with therapy. *Kardiologia*. 2018;**10**:27-33
- [26] Mauntner R, Phillips J. Atrioventricular and intraventricular conduction disturbance in aortic valvular disease. *Southern Medical Journal*. 1980;**73**(5):572-578
- [27] Vosnakidis A, Polymeropoulos K, Zarogoulidis P, Zarifis I. Atrioventricular nodal dysfunction secondary to hyperparathyroidism. *Journal of Thoracic Disease*. 2013;**5**(3):E 90-E 92
- [28] Isotalo P, Halil A, Green M, Tang A, Lach B, Veinot J. Metastatic calcification of the cardiac conduction system with heart block: An under-reported entity in chronic renal failure patients. *Journal of Forensic Sciences*. 2000;**45**(6):1335-1338
- [29] Jayalath R, Mangan S, Golledge J. Aortic calcification. *European Journal of Vascular and Endovascular Surgery*. 2005;**30**:476-488
- [30] Niskanen L, Suhonen M, Siitonen O, Lehtinen J. Aortic and lower limb artery calcification in type 2 (non-insulin-dependent) diabetic patients and non-diabetic control subject. A five-year follow-up study. *Atherosclerosis*. 1990;**84**(1):61-71
- [31] Wu X, Wang L, Zhong J, et al. Impact of intracranial artery calcification on cerebral hemodynamic changes. *Neuroradiology*. 2018;**60**:357-363

- [32] Erbay S, Han R, Baccei S, et al. Intracranial carotid artery calcification on head CT and its association with ischemic changes on brain MRI in patients presenting with stroke-like symptoms: Retrospective analysis. *Neuroradiology*. 2007;**49**:27-33
- [33] Gade P, Tulamo R, Lee K, et al. Calcification in human intracranial aneurysms is highly prevalent and displays both atherosclerotic and nonatherosclerotic types. *Arteriosclerosis, Thrombosis, and Vascular Biology*. 2019;**39**:2157-2167. DOI: 10.1161/ATVBAHA.119.312922
- [34] Chen Y, Wei X, Lu J, et al. Correlation between intracranial arterial calcification and imaging of cerebral small vessel disease. *Frontiers in Neurology*. 2019;**10**:426. DOI: 10.3389/fneur.2019.00426
- [35] Shammass NW, Chandra P, Brodmann M, Weinstock B, Sedillo G, Cawich I, et al. Acute and 30-day safety and effectiveness evaluation of Eximo Medical's B-Laser™, a novel atherectomy device, in subjects affected with infrainguinal peripheral arterial disease: Results of the EX-PAD-03 trial. *Cardiovascular Revascularization Medicine*. 29 Nov 2018. pii: S1553-8389(18)30565-7. DOI: 10.1016/j.carrev.2018.11.022. [Epub ahead of print]
- [36] Price L, Faries P, McKinsey J, Prakash K, Tang G, Kovacic J, et al. The epidemiology, pathophysiology, and novel treatment of calcific arterial disease. *Surgical Technology International*. 2019;**34**:351-358
- [37] Shammass N, Chanda P, Brodman M, Weinstock B, Sedillo G, Cawich I, et al. Acute and 30-day safety and effectiveness evaluation of Eximo medical's B-Laser™, a novel atherectomy device, in subjects affected with infrainguinal peripheral arterial disease. Result of the EX-PAD-03 trial. *Cardiovascular Revascularization Medicine*. 2018. PII: S1553-8389(18)30565-7
- [38] Kukida M, Mogi M, Ken-No H, Tsukada K, Bai H, Shan B, et al. AT2 receptor stimulation inhibits phosphate-induced vascular calcification. *Kidney International*. 2019;**95**(1):138-148
- [39] Liu L, Zeng P, Yang X, Duan Y, Zhang W, Ma C, et al. Inhibition of vascular calcification. *Arteriosclerosis, Thrombosis, and Vascular Biology*. 2018;**38**(10):2382-2395
- [40] Wasilewski G, Verloet M, Schurgers L. The bone-vasculature axis: Calcium supplementation and the role of vitamin K. *Frontiers in Cardiovascular Medicine*. 2019;**6**:6
- [41] Gao Z, Li X, Miao S, Lun L. Impacts of parathyroidectomy on calcium and phosphorus metabolism disorder, arterial calcification and arterial stiffness in haemodialysis patients. *Asian Journal of Surgery*. 2019;**42**(1):6-10