

We are IntechOpen, the world's leading publisher of Open Access books Built by scientists, for scientists

6,900

Open access books available

186,000

International authors and editors

200M

Downloads

Our authors are among the

154

Countries delivered to

TOP 1%

most cited scientists

12.2%

Contributors from top 500 universities



WEB OF SCIENCE™

Selection of our books indexed in the Book Citation Index
in Web of Science™ Core Collection (BKCI)

Interested in publishing with us?
Contact book.department@intechopen.com

Numbers displayed above are based on latest data collected.
For more information visit www.intechopen.com



Cesarean Scar Defect Manifestations during Pregnancy and Delivery

*Ospan Mynbaev, Ioannis Kosmas, Zhongjie Shi,
Sergei Firichenko, Avinoam Tzabari, Lin Ma,
Leila Kindarova, Tatiana Babenko, Styliani Salta,
Antonio Malvasi, Ivano Raimondo, Andrea Tinelli,
Victor Gomel and Michael Stark*

Abstract

The cesarean scar is a significant risk factor for the following pregnancies and especially deliveries. In this chapter, we discussed the diagnosis, incidence, detection, manifestations, and prognosis of pregnancy and delivery with cesarean scars. A systematic review of current literature showed that a manifestation of cesarean scars during the following pregnancies is not predictable, in general, although modern visualization technologies could reveal some specific features of scar defects that are associated with complications during pregnancy and delivery. However, there is no factor, which could serve as the main prognostic guide for obstetricians to make a decision for VBAC, thus Edwin Cragin's phrase "once a cesarean, always a cesarean" has represented the essential healthcare issue over the century. At the moment, the most reasonable measurements to prevent uterine scar complications are reducing the rate of Cesarean Sections, opening the uterus transversely in the lower segment, and stitching the uterus with one layer only continuously using a big needle preferable by Stark technique of Cesarean section.

Keywords: cesarean scar, pregnancy, delivery

1. Introduction

Cesarean scar defect is diagnosed in the presence of a hypo-echogenic indentation (a filling defect) within the myometrium of the lower uterine segment on the site of a previous cesarean incision that is communicated with the uterine or cervical cavity [1]. The cesarean scar is a significant risk factor for the following pregnancies and especially for future deliveries. All pregnancies in women who experienced previous cesarean sections (CSs) are considered to be at a high-risk due to the possibility of scar defect complications.

2. The manifestation of cesarean scar pregnancy

Au et al. [1] reviewed the data of 183 women with the previous CSs with the aim to determine whether the cesarean scar defect parameters assessed by transvaginal ultrasonography (TVS) might affect the outcome of early termination of pregnancy (TOP) with mifepristone-misoprostol. Once identified, the myometrial defects were evaluated in the longitudinal plane (**Figure 1A**) by recording the following parameters: scar width (length of the widest gap along the isthmico-cervical canal), scar depth (vertical distance between base and apex of the defect), thickness of the residual myometrium over the defect, and thickness of the myometrium adjacent to the defect (**Figure 1B**) [1].

The authors also calculated the ratio of the residual myometrial thickness over the defect and the adjacent myometrial thickness, and the women were divided into three subgroups accordingly (myometrial thickness ratio <30%, 30–70%, and >70%) [1]. The intrauterine gestational age was determined by measuring the crown-rump length at TVS. When it was estimated 10–15 mm, it was decided as a gestational age of 42–56 days [1]. A successful TOP was defined as absence of an intrauterine gestational sac at TVS without surgical intervention, whereas a failed TOP was defined as a need for D&C after a complete medical regimen for any of the following reasons: (a) excessive vaginal bleeding; (b) intractable lower abdominal pain; (c) suspected septic TOP; (d) persistent incomplete TOP; or (e) ongoing pregnancy in follow-up visits [1].

The authors demonstrated that the parity, previous TOP, and the number of previous CSs were not associated with failed TOP, although the proportion of women with cesarean scar defects was significantly higher in the group with TOP failure as compared with the successful TOP group (53.5 vs. 25.7%). However, after adjusting for these three parameters, on multivariate logistic regression analysis, the women with a defective scar had similar odds of failed TOP compared with those who had an intact scar (**Table 1**) [1].

The significant value of this study is the defect size comparison between women with successful and those with failed TOP among 59 women with cesarean scar defects (**Table 2**) [1]. The authors demonstrated that the median defect width was not significantly different between women with successful and those with failed TOP, but the median defect depth was considerably larger in women with failed TOP if compared with those with successful TOP [1]. The median myometrial

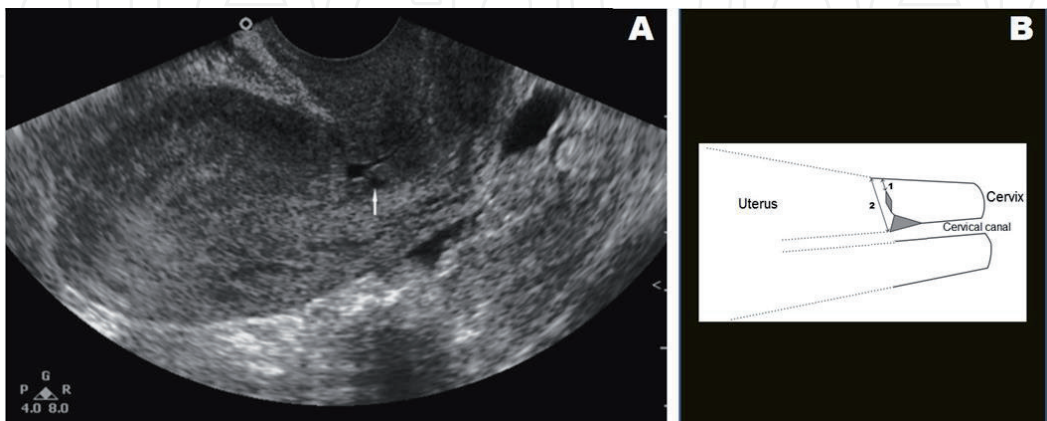


Figure 1. Cesarean scar defect presented as a hypoechoic indentation within the myometrium in the LUS (arrow) with ultrasound longitudinal scan of the uterus (A) and measurement of the cesarean scar defect in a schematic drawing (B): Thickness of residual myometrium over the defect (1) and thickness of myometrium adjacent to the defect (2), and the gray shaded areas representing a scar defect. Modified from Au et al. [1].

Variable		Univariate		Multivariate	
		OR (95% CI)	P	OR (95% CI)	P
Cesarean scar	Intact scar [*]	Reference	—	Reference	—
	Defective scar	3.32 (1.64–6.75)	<0.001	3.34 (1.63–6.83)	<0.001
Parity	1	Reference	—	Reference	—
	≥2	1.19 (0.59–2.41)	0.622	0.82 (0.22–3.07)	0.773
Previous TOP	No	Reference	—	Reference	—
	Yes	1.24 (0.61–2.54)	0.548	1.22 (0.58–2.57)	0.602
Number of previous Cesarean deliveries	1	Reference	—	Reference	—
	≥2	1.18 (0.60–2.35)	0.63	1.36 (0.38–4.88)	0.638

Modified from Au et al. [1]. Data are given as median (interquartile range) or n (%). OR, odds ratio.
^{*}Ratio between the thickness of residual myometrium over the defect and thickness of myometrium adjacent to the defect.

Table 1.
Association between obstetric factors and failed early termination of pregnancy (TOP) by oral mifepristone and misoprostol in 183 women with previous cesarean delivery.

thickness adjacent to the defect was not significantly different between the groups, but the median of the residual myometrium over the defect was substantially lower in women with failed TOP as compared with those with successful TOP. The median ratio of the thickness of the residual myometrium over the defect of the thickness of the myometrium adjacent to the defect was considerably higher in women with failed TOP as compared with those with successful TOP. Based on these results, Au et al. [1] concluded that women with cesarean scar defects are at increased risk of failed TOP, especially if a defect with the residual myometrial thickness is smaller than one-third of the adjacent myometrial thickness, tended to have a greater chance of the failed TOP.

Lincenberg et al. [2] recently reported a case of extruding a fetal part through the ruptured cesarean scar defect in the lower uterine segment (LUS) in a 28-year-old patient with previous four CSs and presence of a dichorionic diamniotic pregnancy of 10 weeks and 2 days of gestation age (**Figure 2**).

During emergency surgery, the authors removed the exteriorized fetus and saved the remaining fetus in the uterine cavity. Then, they repaired the ruptured scar defect in the LUS with a single layer running-locking suture with good hemostasis. This pregnancy was prolonged up to 23 weeks, an emergency CS was performed by a classical uterine incision and the fetus was delivered together with the placenta. The remaining piece of placenta was removed from the anterior LUS with Banjo curettage. The uterine incision was sutured and good hemostasis was achieved. The postoperative period was complicated by acute blood loss followed by blood transfusion. The patient recovered well and was discharged home in good condition on postoperative day 3 [2].

Analogous case of surgical management of a heterotopic cesarean scar pregnancy with preservation of an intrauterine pregnancy was described by Vetter et al. [3]. A 29-year-old pregnant woman was admitted at 5 weeks of gestational age (WGA) with mild discharge as a spot. Ultrasound revealed a heterotopic cesarean scar pregnancy. The patient underwent resection of the ectopic pregnancy through

Parameters	Successful TOP (n = 36)	Failed TOP (n = 23)	P
Width of defect (mm)	3.4 (1.50–5.50)	3.2 (2.10–4.50)	0.363 [†]
Depth of defect (mm)	8.4 (4.35–10.30)	10.4 (7.60–13.50)	0.035 [†]
Residual myometrium over defect (mm)	6.4 (4.20–10.70)	3.4 (1.80–6.80)	0.017 [†]
Myometrial thickness adjacent to defect (mm)	15.3 (13.80–16.15)	15.2 (13.30–15.80)	0.610 [†]
Myometrial thickness ratio (%) [*]	58.5 (32.4–73.6)	75.0 (55.8–88.5)	0.014 [†]
Ratio [*]	<30%	12 (33.3)	0.023 [‡]
	30–70%	15 (41.7)	
	>70%	9 (25.0)	

Modified from Au et al. [1]. Data are given as median (interquartile range) or n (%). *Ratio between the thickness of residual myometrium over the defect and thickness of myometrium adjacent to the defect.
[†]Mann-Whitney U-test.
[‡]Chi-square test.

Table 2.
Cesarean scar defect size in 59 women with previous cesarean delivery and CSD at transvaginal ultrasound who received oral mifepristone and misoprostol for early termination of pregnancy (TOP), according to whether TOP was successful or failed.

mini-laparotomy with the preservation of an intrauterine pregnancy, which resulted in the delivery of a pre-term baby [3].

Naji et al. [4] evaluated the cesarean scar changes longitudinally throughout the pregnancy to relate the initial scar measurements (**Figure 3**). These findings were incorporated with demographic and obstetric variables, as well as with final pregnancy outcomes. LUS was assessed by using real-time ultrasound to identify the cesarean scar defects. Two components of the cesarean scars were identified: a hypoechoic part or “apparent defect” and any residual myometrium located above the scar defect expressed as the residual myometrial thickness for measurement purposes as (A) width of hypoechoic part, (B) depth of hypoechoic part, (C) residual myometrial thickness, (D) utero-vesical fold, and (E) internal Cervical Os [4].

The prospective observational study by Naji et al. [4] included 320 patients in total, among them 284 patients with visible scars and 36 women with nonvisible scars. There were 153 and 14 patients with two CSs among the women with visible and nonvisible scars, respectively, whereas 131 and 22 patients experienced only one CS among the women with visible and non-visible scars, respectively. While analyzing the changes of the cesarean scar size throughout pregnancy, Naji et al. [4] found the average increase of 1.8 (95% CI, 1.7–1.9) mm in the width of the hypoechoic part of the scar per trimester (**Table 3**), whereas the depth and length of the hypoechoic part decreased over time, with an average decrease of 1.8 (95% CI, 1.7–1.9) mm and 1.9 (95% CI, 1.8–2.0) mm per trimester, respectively. RMT decreased by an average of 1.1 (95% CI, 1.0–1.2) mm per trimester. These changes were clear in a mixed modeling analysis of the cesarean scar disturbances over time (**Figure 4**).

Naji et al. [4] reported two cases of a cesarean scar rupture among their study population. They also found that the decrease in the residual myometrial thickness (RMT) between the first and second trimester was 2.7 and 2.5 mm, respectively, in those patients with cesarean scar ruptures. An average RMT in these cases was

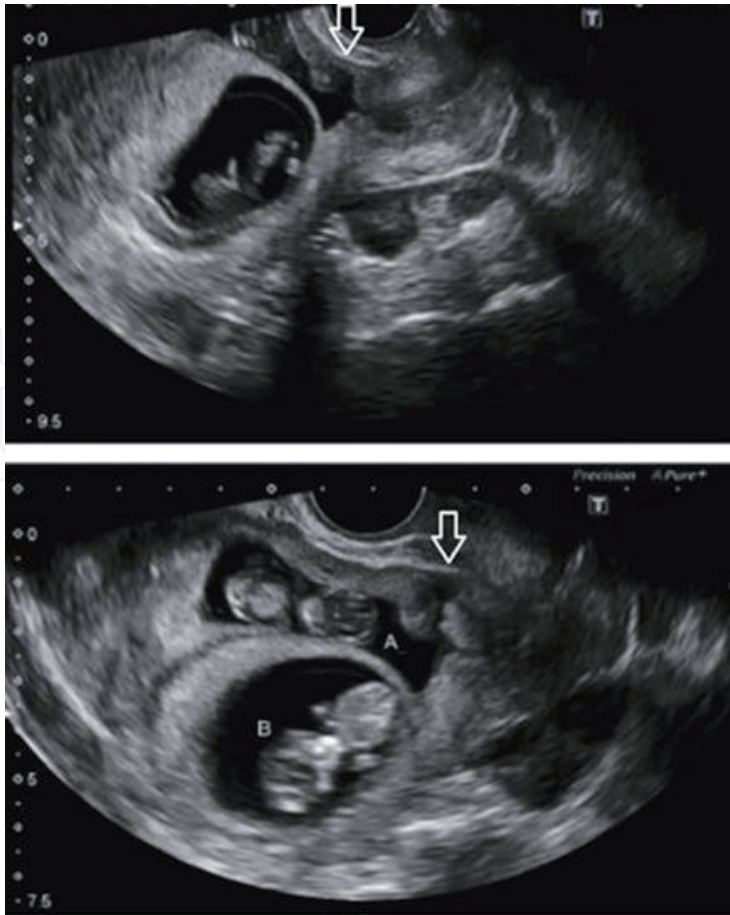


Figure 2.
The arrows are used to demonstrate the cesarean scar in the LUS, into which implanted twin (A). Modified from Lincenberg et al. [2].

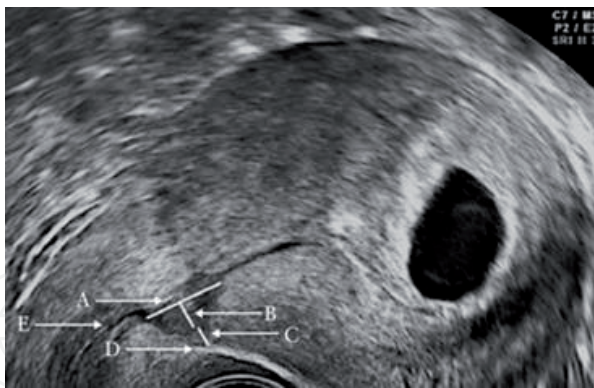


Figure 3.
Sagittal ultrasound image showing anatomical location of features measured to quantify the size of component parts of cesarean scar defects by using TVS in the first trimester of pregnancy. A-width of hypoechoic part; B-depth of hypoechoic part; C-residual myometrial thickness; D-utero-vesical fold; E-internal cervical os. Modified from Naji et al. [4].

0.5 mm at the second trimester scan, as compared to 3.6 mm for the other cases [4]. Based on the obtained clinical results and their mixed model analysis, Naji et al. [4] concluded that the changes of cesarean scar dimensions throughout pregnancy and cesarean scar rupture were associated with a smaller residual myometrial thickness and a greater decrease in this parameter during pregnancy. They also suggested that there is a potential to test absolute values and observed alterations in cesarean scar measurements as predictors of uterine scar rupture or vaginal birth after cesarean (VBAC) trial outcome [4].

Scar characteristic	Trimester 1	Trimester 2	Trimester 3	P*
Scar width (mm)	3.6 (3.0–4.7)	5.3 (4.0–6.6)	7.4 (6.1–8.9)	0.0001
Scar depth (mm)	8.3 (6.6–10.2)	6.2 (5.1–7.5)	4.8 (3.7–5.6)	0.0001
Scar length (mm)	10.4 (8.6–12.7)	8.0 (7.2–9.9)	6.8 (5.9–8.1)	0.0001
RMT (mm)	5.3 (4.7–6.2)	3.5 (2.8–4.2)	3.5 (2.5–3.6)	0.0001

Data are shown as median (interquartile range). RMT, residual myometrial thickness; False discovery rate. Modified from Naji et al. [4].

*One-way repeated-measures ANOVA.

Table 3.
Cesarean scar size and dimensions in each trimester of pregnancy.

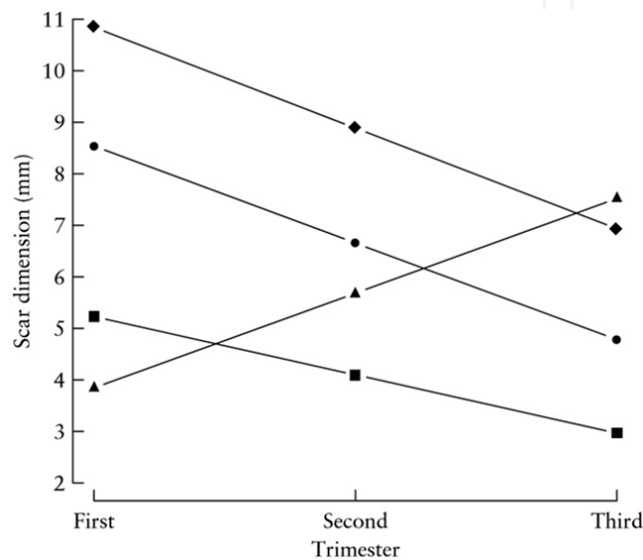


Figure 4.
Mean scar dimensions according to trimester, relating to the fitted fixed effects from mixed-effects modeling. Modified from Naji et al. (2013). Diamond, residual myometrial thickness; Circle, scar depth; Square, scar length; Triangle, scar width.

Xiaoxia et al. [5] analyzed 67 cases of uterine rupture out of 128,599 deliveries in a single-center retrospective study in China. Uterine wall ruptures were found in 88.0% of cases (59/67). They found cesarean scar spontaneous incomplete ruptures in 52 cases, which were repaired without maternal and fetal complications. Emergency rescue operations were performed in 15 cases because of fetal distress or death, severe acute abdomen, prepartum or postpartum vaginal bleeding, maternal hypovolemia, and 12 perinatal fetal deaths. Among them, the uterine rupture was diagnosed with a history of clinical symptoms and signs in 6/15 cases. Ultrasound showed a dead fetus in the peritoneal cavity in 3/15 cases before the exploratory LT, while during LT a dead fetus was found in 6/15 cases in the abdomen. The uterus was preserved in 5/15 cases and hysterectomy took place in 10/15 cases [5]. The authors concluded that a previous cesarean scar became the leading cause of uterine rupture among other surgical procedures, such as assisted delivery operations, intrauterine manipulations and surgical treatment of large myomas and uterine malformations.

The most important issue related with cesarean scar pregnancies is the possibility of uterine rupture, especially in cases of VBAC. Subsequently, in the 1980s, ultrasound was applied to diagnose scar defects following CS [6, 7]. Václavinková and Westin [6] in a retrospective study of 2542 cases found 11.3% CS rate. Among them, 2.8% cesarean scars exhibited deficient healing.

The authors found smooth or pathologically deformed structures corresponding to the cesarean scar region [6, 7]. Further 68 women were under more detailed prospective examination, and the authors observed a uterine scar rupture in two patients. They concluded that the sensitivity of the ultrasonic method was 67% and the specificity 96% in the diagnosis of cesarean scar healing disturbances [6]. Bedi et al. [7] reported that ultrasound examination was able to diagnose uterine rupture by demonstrating intra- or extraperitoneal hematoma in the correct clinical setting.

Fukuda et al. [8] assessed LUS thickness perioperatively in 35 women with previous CS and in 29 women without CS who were subjected to elective CS before the labor. LUS thickness was assessed immediately before CS by ultrasound and intraoperatively by ophthalmic calipers before delivery of the fetus, and surgeons were asked to classify the thickness of LUS according to the Grade system (Table 4). Fukuda et al. [8] found complete dehiscence of the scar in three cases (8.6%), thin LUS in 4 cases (11.4%) and no scar defect in 28 cases (80.0%) among 35 women with previous CS. The authors demonstrated correlations between LUS thickness assessed by ultrasound prior to CS and intraoperative ophthalmic caliper measurements before and immediately after delivery, as well as results of visual grading by surgeons [8].

Michaels et al. [9] examined 58 high-risk patients to diagnose cesarean scar defects in the LUS. These patients delivered by CS, and 12 nulliparous women with no risk were used as control. The authors found cesarean scar defects in 20.7% (12/58) cases among high-risk women who experienced CS. The positive and negative predictive values were 92.3 and 100%, respectively.

Uterine scar dehiscence can happen, especially, in cases of a very short interval between pregnancies. The repeated ultrasound performed during

Characteristics of women and grades	N	LUS thickness before		Correlation coefficient and p-value	LUS thickness fetus delivery (ophthalmic calipers, mm)
		CS (US, mm)	Fetus delivery (ophthalmic calipers, mm)		
Women without previous CS	29	2.7 ± 0.6	2.7 ± 0.6	r = 0.980 P < 0.001	4.4 ± 1.1 (n = 11)
Women with previous CS					
Overall	35	1.9 ± 0.9	1.8 ± 0.9	r = 0.985 P < 0.001	3.4 ± 1.1 (n = 17)
Grade I: neither thinning nor loss of continuity of the LUS – no scar defect	28	2.2 ± 0.7	2.1 ± 0.8	R = 0.970 <0.001	3.7 ± 0.9 (n = 14)
Grade II: thinning and/ or loss of continuity of the LUS but fetal hair not visible – thin LUS	4	1.0 ± 0.2	0.8 ± 0.1	R = 0.707 =0.29	2.4 ± 0.1 (n = 2)
Grade III: thinning or absence of the LUS and fetal hair visible – complete dehiscence of the scar	3	0.4 ± 0.1	0.4 ± 0.1	R = 0.866 =0.33	1.1 (n = 1)

Modified from CS Fukuda et al. [13].

Table 4.
LUS thickness immediately before, during and after.

pregnancy can help to define the cesarean scar dehiscence in women with previous CS. Supplementation of the above-presented case reports by the systematic review of the LUS measurements performed between 35 and 40 WGA by Jastrow et al. [10] can improve our understanding. In this study uterine rupture and uterine scar dehiscence diagnosed during CS in 1834 women were extracted from 12 studies. One study was an exception, when a pelvic bimanual revision of the LUS was performed after delivery to diagnose uterine scar dehiscence. Thus, cesarean scar defects were identified among the women subjected to VBAC and CSs. The authors demonstrated that the weighted mean difference with (95% CI) was 0.98 mm (0.37–1.59 mm) for the thinner full LUS, and 1.13 mm (0.32–1.94 mm) for thinner myometrial layer in the women with uterine scar defects. Further, additional summary receiver operating characteristic (SROC) analysis and summary diagnostic odds ratios were used to evaluate and compare the area under the curve and the association between the LUS thickness and uterine scar defect. Subsequently, the SROC analysis revealed a stronger association between the full LUS thickness and uterine scar defect than the association between myometrial layer thickness and scar defect [10].

The characteristics of the ultrasound studies examining the full LUS thickness were additionally analyzed, taking into account the predicting value of TAS [11–15] and TVS [16, 17] ultrasound approaches for cesarean scar defects (**Table 5**).

Although the authors included the data by Bujold et al. [18] into the TA subgroup, we excluded this study from our analysis.

Our supplementary analysis of these results showed that scar defects were registered in 6.1% (64/1051) and in 14.4% (19/132) cases by TA and TV, respectively, during ultrasound examinations of full LUS thickness before delivery. According to this analysis, there was a higher rate of cesarean scar defects after examining the full LUS thickness by the TV approach, as compared to the TA ultrasound (see **Table 5**).

Then, the characteristics of ultrasound studies that examined the myometrial layer of the LUS, were also re-analyzed, taking into account the predicting

References	SA/SS (n)	BSR	TOL (n)	VBAC, n	CS, n	SD, n (%)	total, n
1. Fukuda et al. [13]	TA/84	No	NA	24	60	5 (6.0)	84
2. Rozenberg et al. [11]	TA/642	Yes	517	386	256	25 (3.9)	642
3. Tanik et al. [14]	TA/50	No	0	0	50	23 (46.0)	50
4. Rozenberg et al. [12]	TA/198	No	170	131	62	2 (1.0)	192
5. Suzuki et al. [15]	TA/83#	No	44	27	56	9 (10.8)	83
6. Montanari et al. [16]	TV/61	Yes	NA	8	53	17 (27.9)	61
7. Sen et al. [17]	TV/71*	Yes	52	33	38	2 (2.8)	71
Total	TA-1293	Yes –1	856	658	630	64 (6.0)	1051
	TV-132	Yes –2	52	41	91	19 (14.4)	132

LUS, lower uterine segment; SA, ultrasound approach; SS, sample size; BSR, blinded sonographic results; TOL, trial of labor; VBAC, vaginal birth after cesarean section; CS, cesarean section; SD, scar defect; TA, transabdominal; TV, transvaginal; #, number of VBAC and CSs; *, incorporated into total TA or TV approaches.

Table 5.
Characteristics of the ultrasound studies examined full LUS thickness.

value of TA [19–21] and TV [18, 22] ultrasound approaches for cesarean scar defects (**Table 6**).

Moreover scar defects were registered in 7.9% (28/356) and in 3.5% (10/289) cases after evaluating the myometrial layer of the LUS before delivery by TA and TV ultrasound, respectively (see **Table 6**). According to these results, there was a higher rate of scar defects after evaluation of the myometrial layer of the LUS before delivery by TA, as compared to TV ultrasound.

The authors demonstrated the optimal cut-off value, which varied from 2.0 to 3.5 mm, for the full LUS thickness (**Figure 5A**), and from 1.4 to 2.0 mm for a myometrial layer (**Figure 5B**). However, the authors concluded that at present there is not an ideal cut-off value to be recommended, taking into account the requirements for more standardized measurement methods.

References	SA/SS (n)	BSR	TOL, n	VBAC, n ^{\$}	CS, n ^{\$}	SD, n (%)	Total, n ^{\$}
1. Asakura et al. [19]	TA/186	Yes	132	63	123	9 (4.8)	186
2. Gotoh et al. [20]	TA/68	No	0	0	68	17 (25.0)	68
3. Cheung et al. [21]	TA/102 [*]	No	50	32	70	2 (2.0)	102
4. Bujold et al. [18]	TV/223	No	125	90	146	9 (3.8)	236
5. Cheung et al. [22]	TV/53	No	28	18	35	1 (1.9)	53
Total	TA-356	Yes –1	182	95	261	28 (7.9)	356
	TV-276	Yes –0	153	108	181	10 (3.5)	289

LUS, lower uterine segment; SA, ultrasound approach; SS, sample size; BSR, blinded sonographic results; TOL, trial of labor; VBAC, vaginal birth after cesarean section; CS, cesarean section; SD, scar defect; TA, transabdominal; TV, transvaginal; \$, number of VBAC and CSs; &*, incorporated into total TA or TV approaches. *LUS appearance described only for CSs.

Table 6.
Characteristics of ultrasound studies examining the myometrial layer of the LUS.

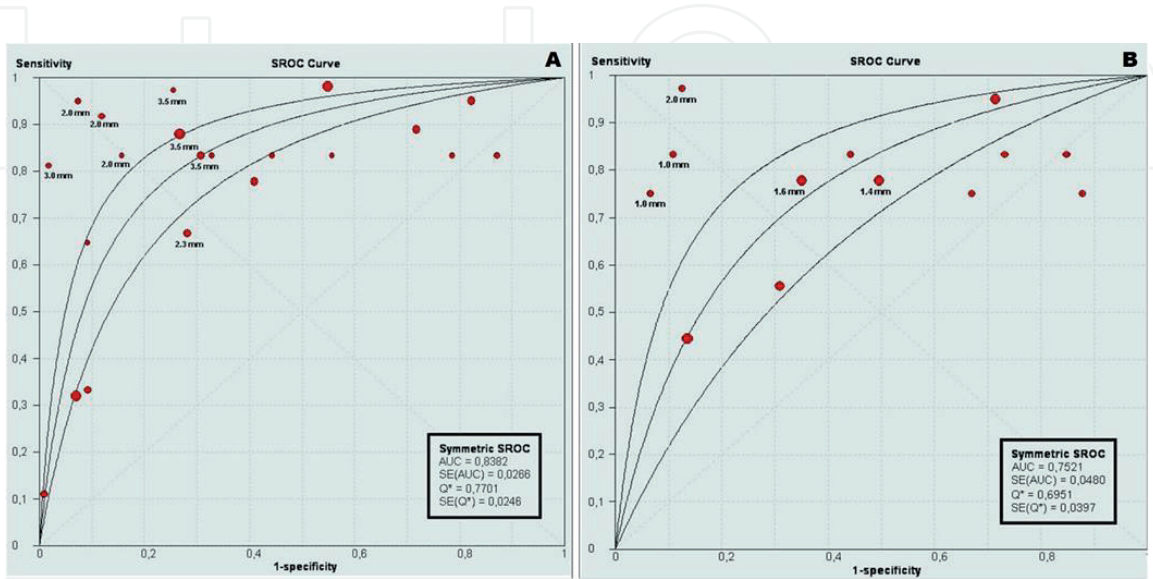


Figure 5.
Summary receiver operating characteristic curve analyses of the association between: Full LUS thickness and the risk of uterine scar defect (A); Myometrial thickness and the risk of uterine scar defect (B).

3. Discussion

Today Cragin's opinion "once a Caesarean, always a Caesarean" [23] is proved by highly increasing CS rate worldwide.

In the last decades, the number of Cesarean Sections increased steadily [24]. One of the reasons is the promoting of Cesarean Section by request of the mother [25].

As a result, more placental implantation pathologies occur [26], and certainly more problems related to scar dehiscence following repeated pregnancies following Cesarean Sections.

The best way to prevent these complications is certainly by reducing the number of Cesarean Sections, mainly at low-risk pregnancies. In our group, it was successfully achieved by asking for a documented second opinion for each non-emergency Cesarean Section.

When a Cesarean Section is done, it is important to perform the operation in a way that the full thickness of the uterine wall, as well as its strength, will be preserved.

It is important to analyze what are the reasons for uterine wall defects and how are they related to the surgical method.

It was shown by Di Spiezio et al. that one or two layers suturing of the uterine wall do not make any difference concerning the incidence of Cesarean scar defects as well as the uterine dehiscence and rate of ruptures in subsequent pregnancies [27].

Although a second layer did not show any benefit concerning the thickness of the uterine wall [28].

If one or two layers of sutures are not the etiology of dehiscence in subsequent pregnancies, it is important to analyze the relevant reason.

It is known that sutured muscle tissue will never regain its original strength, in contrary to fibrous tissue. Therefore, the less muscle tissue to be cut the better are the chances for a stronger scar.

Rorie analyzed the histological structure of the uterus and found out that the amount of smooth muscle in the upper third of the cervix is 28%, and in the body of the uterus 68.8% [29].

It means the lower the incision in the uterus, the less damage to the uterine wall.

As a result, it is important to incise the urine bladder plica, push the bladder down, and cut the uterine wall as low as possible. This is in contrary to the nowadays practice to open the uterus above the plica [30].

The uterus contracts immediately after delivery, and after a few weeks regains its original size. The sutures cannot contract together with the uterus, and their function is to enhance hemostasis in the first hours. Thereafter, the more stitching material is left the more foreign body reaction occurs which might weaken the scar.

Therefore, in order to leave as little suturing material as possible, it is important to use big needles as possible [31].

Technique of this Cesarean section and advantages was described in earlier publications [31–36] with systematic review of literature [37].

This will result in less suture material left behind. We believe that opening the uterus in the lower segment and suture the uterus with one layer using a big needle will reduce the scar dehiscence in future pregnancies.

4. Conclusions

The cesarean scar is a significant risk factor for the following pregnancies and especially deliveries. In this chapter, we discussed the diagnosis, incidence, detection, manifestations, and prognosis of pregnancy and delivery with cesarean scars.

A systematic review of current literature showed that a manifestation of cesarean scars during the following pregnancies is not predictable, in general, although modern visualization technologies could reveal some specific features of scar defects that are associated with complications during pregnancy and delivery. However, there is no factor, which could serve as the main prognostic guide for obstetricians to make a decision for VBAC, thus Edwin Cragin's phrase "once a cesarean, always a cesarean" has represented the essential health care issue over the century. At the moment, the most reasonable measurements to prevent uterine scar complications are reducing the rate of Cesarean Sections, opening the uterus transversely in the lower segment, and stitching the uterus with one layer only continuously using a big needle preferable by Stark technique of Cesarean section.

Acknowledgements

The authors would like to sincerely thank Mrs. Maya A. Bessarabova for her inestimable assistance of the manuscript preparation.

Conflict of interest

No conflict of interest exists.

Author details

Ospan Mynbaev^{1,2}, Ioannis Kosmas³, Zhongjie Shi^{1,4*}, Sergei Firichenko^{1,5}, Avinoam Tzabari^{1,2,6}, Lin Ma^{1,7}, Leila Kindarova⁸, Tatiana Babenko^{1,9}, Styliani Salta^{2,10}, Antonio Malvasi^{1,2}, Ivano Raimondo^{2,11}, Andrea Tinelli^{1,12}, Victor Gomel^{1,13} and Michael Stark^{1,2,14,15}

1 The International Bureau of Human Body Design, Biomodeling, and Biosensing, Moscow Institute of Physics and Technology (State University), Moscow, Russia

2 The New European Surgical Academy, Berlin, Germany

3 Ioannina University, Ioannina, Greece

4 Wayne State University, Detroit, USA

5 Moscow State University of Medicine and Dentistry, Moscow, Russia

6 Emergency Obstetrics and Gynecologic Unit, Mayanei Hayeshua Medical Center, Bnei Brak, Israel

7 Henry Ford Hospital, Detroit, USA

8 Russian-German Center of Reproduction and Clinical Embryology “Generation NEXT”, Moscow, Russia

9 City Clinical Hospital for Emergency Medical Services N4, Stavropol Krai, Russia

10 Haemophilia Centre, University Hospitals of Leicester, Leicester, UK

11 Gynecologic and Obstetric Clinic, Sassari University, Sassari, Italy

12 Division of Experimental Endoscopic Surgery, Imaging, Technology and Minimally Invasive Therapy, Department of Obstetrics and Gynecology, Vito Fazzi Hospital, Lecce, Italy

13 Department of Obstetrics and Gynecology, Women’s Hospital, University of British Columbia, Vancouver, BC, Canada

14 Department of Gynecological Oncology, Berlin Humboldt University Hospital Charite, Berlin, Germany

15 The ELSAN Group, Paris, France

*Address all correspondence to: zshi@med.wayne.edu

IntechOpen

© 2020 The Author(s). Licensee IntechOpen. This chapter is distributed under the terms of the Creative Commons Attribution License (<http://creativecommons.org/licenses/by/3.0>), which permits unrestricted use, distribution, and reproduction in any medium, provided the original work is properly cited. 

References

- [1] Au HK, Liu CF, Tzeng CR, Chien LW. Association between ultrasonographic parameters of cesarean scar defect and outcome of early termination of pregnancy. *Ultrasound in Obstetrics & Gynecology*. 2016;**47**:506-510. DOI: 10.1002/uog.14877
- [2] Lincenberg KR, Behrman ER, Bembry JS, Kovac CM. Uterine rupture with cesarean scar heterotopic pregnancy with survival of the intrauterine twin. *Case Reports in Obstetrics and Gynecology*. 2016;**2016**:6832094. DOI: 10.1155/2016/6832094
- [3] Vetter MH, Andrzejewski J, Murnane A, Lang C. Surgical management of a heterotopic cesarean scar pregnancy with preservation of an intrauterine pregnancy. *Obstetrics and Gynecology*. 2016;**128**:613-616. DOI: 10.1097/AOG.0000000000001514
- [4] Naji O, Daemen A, Smith A, Abdallah Y, Saso S, Stalder C, et al. Changes in cesarean section scar dimensions during pregnancy: A prospective longitudinal study. *Ultrasound in Obstetrics & Gynecology*. 2013;**41**:556-562. DOI: 10.1002/uog.12334
- [5] Xiaoxia B, Zhengping W, Xiaofu Y. Clinical study on 67 cases with uterine rupture. *Zhonghua Fu Chan Ke Za Zhi*. 2014;**49**:331-335
- [6] Václavinková V, Westin B. Ultrasonic diagnosis of scar defects following cesarean section. *Zentralblatt für Gynäkologie*. 1984;**106**(10):686-692
- [7] Bedi DG, Salmon A, Winsett MZ, Fagan CJ, Kumar R. Ruptured uterus: Sonographic diagnosis. *Journal of Clinical Ultrasound*. 1986;**14**:529-533
- [8] Fukuda M, Fukuda K, Shimizu T, Bujold E. Ultrasound assessment of lower uterine segment thickness during pregnancy, labour, and the postpartum period. *Journal of Obstetrics and Gynaecology Canada*. 2016;**38**:134-140. DOI: 10.1016/j.jogc.2015.12.009
- [9] Michaels WH, Thompson HO, Boutt A, Schreiber FR, Michaels SL, Karo J. Ultrasound diagnosis of defects in the scarred lower uterine segment during pregnancy. *Obstetrics and Gynecology*. 1988;**71**:112-120
- [10] Jastrow N, Chaillet N, Roberge S, Morency AM, Lacasse Y, Bujold E. Sonographic lower uterine segment thickness and risk of uterine scar defect: A systematic review. *Journal of Obstetrics and Gynaecology Canada*. 2010;**32**:321-327. DOI: 10.1016/S1701-2163(16)34475-9
- [11] Rozenberg P, Goffinet F, Phillippe HJ, Nisand I. Ultrasonographic measurement of lower uterine segment to assess risk of defects of scarred uterus. *Lancet*. 1996;**347**:281-284
- [12] Rozenberg P, Goffinet F, Philippe HJ, Nisand I. Thickness of the lower uterine segment: Its influence in the management of patients with previous cesarean sections. *European Journal of Obstetrics, Gynecology, and Reproductive Biology*. 1999;**87**:39-45
- [13] Fukuda M, Fukuda K, Mochizuki M. Examination of previous caesarean section scars by ultrasound. *Archives of Gynecology and Obstetrics*. 1988;**243**:221-224
- [14] Tanik A, Ustun C, Cil E, Arslan A. Sonographic evaluation of the wall thickness of the lower uterine segment in patients with previous cesarean section. *Journal of Clinical Ultrasound*. 1996;**24**:355-357
- [15] Suzuki S, Sawa R, Yoneyama Y, Asakura H, Araki T. Preoperative diagnosis of dehiscence of the lower

uterine segment in patients with a single previous caesarean section. The Australian & New Zealand Journal of Obstetrics & Gynaecology. 2000;**40**:402-404

[16] Montanari L, Alfei A, Drovanti A, Lepadatu C, Lorenzi D, Facchini D, et al. Transvaginal ultrasonic evaluation of the thickness of the section of the uterine wall in previous cesarean sections [article in Italian]. Minerva Ginecologica. 1999;**51**:107-112

[17] Sen S, Malik S, Salhan S. Ultrasonographic evaluation of lower uterine segment thickness in patients of previous cesarean section. International Journal of Gynecology & Obstetrics. 2004;**87**:215-219

[18] Bujold E, Jastrow N, Simoneau J, Brunet S, Gauthier RJ. Prediction of complete uterine rupture by sonographic evaluation of the lower uterine segment. American Journal of Obstetrics and Gynecology. 2009;**201**:320.e1-320.e6. DOI: 10.1016/j.ajog.2009.06.014

[19] Asakura H, Nakai A, Ishikawa G, Suzuki S, Araki T. Prediction of uterine dehiscence by measuring lower uterine segment thickness prior to the onset of labor: Evaluation by transvaginal ultrasonography. Journal of Nippon Medical School. 2000;**67**:352-356

[20] Gotoh H, Masuzaki H, Yoshida A, Yoshimura S, Miyamura T, Ishimaru T. Predicting incomplete uterine rupture with vaginal sonography during the late second trimester in women with prior cesarean. Obstetrics and Gynecology. 2000;**95**:596-600

[21] Cheung VY. Sonographic measurement of the lower uterine segment thickness in women with previous caesarean section. Journal of Obstetrics and Gynaecology Canada. 2005;**27**:674-681

[22] Cheung VY, Constantinescu OC, Ahluwalia BS. Sonographic evaluation of the lower uterine segment in patients with previous cesarean delivery. Journal of Ultrasound in Medicine. 2004;**23**:1441-1447

[23] Cragin EB. Conservatism in obstetrics. The New York Medical Journal. 1916;**104**:1-3

[24] Barber EL, Lundsberg LS, Belanger K, et al. Indications contributing to the increasing cesarean delivery rate. Obstetrics and Gynecology. 2011;**118**(1):29-38

[25] Husslein P, Wertaschnigg D. Elective cesarean section--delivery mode of the future or social misconception? Therapeutische Umschau. 2002;**59**(12):660-666

[26] El Gelany S, Mosbeh MH, Ibrahim EM, et al. Placenta Accreta Spectrum (PAS) disorders: Incidence, risk factors and outcomes of different management strategies in a tertiary referral hospital in Minia, Egypt: A prospective study. BMC Pregnancy and Childbirth. 2019;**19**(1):313

[27] Di Spiezio Sardo A, Saccone G, McCurdy R, et al. Risk of cesarean scar defect following single- vs double-layer uterine closure: Systematic review and meta-analysis of randomized controlled trials. Ultrasound in Obstetrics & Gynecology. 2017;**50**(5):578-583

[28] Bennich G, Rudnicki M, Wilken-Jensen C, et al. Impact of adding a second-layer to a single unlocked closure of cesarean uterine incision: A randomized controlled trial. Ultrasound in Obstetrics & Gynecology. 2016;**47**(4):417-422

[29] Rorie DK, Newton M. Histologic and chemical studies of the smooth muscle in the human cervix and uterus. American Journal of Obstetrics and Gynecology. 1967;**99**(4):466-469

[30] O'Neill HA, Egan G, Walsh CA, et al. Omission of the bladder flap at caesarean section reduces delivery time without increased morbidity: A meta-analysis of randomised controlled trials. *European Journal of Obstetrics, Gynecology, and Reproductive Biology*. 2014;**174**:20-26

[31] Stark M. Does size matter? *Journal Of The Turkish-German Gynecological Association*. 2016;**17**(3):175

[32] Stark M, Chavkin Y, Kupfersztain C, Guedj P, Finkel AR. Evaluation of combinations of procedures in cesarean section. *International Journal of Gynaecology and Obstetrics*. 1995;**48**(3):273-276

[33] Holmgren G, Sjöholm L. The Misgav Ladach method of caesarean section: Evolved by Joel-Cohen and Michael Stark in Jerusalem. *Tropical Doctor*. 1996;**26**(4):150-157

[34] Holmgren G, Sjöholm L, Stark M. The Misgav Ladach method for cesarean section: Method description. *Acta Obstetrica et Gynecologica Scandinavica*. 1999;**78**(7):615-621

[35] Stark M. Clinical evidence that suturing the peritoneum after laparotomy is unnecessary for healing. *World Journal of Surgery*. 1993;**17**(3):419

[36] Stark M. In the era of 'non-closure of the peritoneum', how to open it? (not every simple method is optimal, but every optimal method is simple). *Acta Obstetrica et Gynecologica Scandinavica*. 2009;**88**(1):119

[37] Mynbaev O, Babenko TI, Ahmadi F, Raimondo I, Kosmas IP, Mishutina AA, et al. Uterine morbidity: Cesarean section scar complications. In: Tinelli A, Pacheco LA, Haimovich S, editors. Chapter 41 in *Hysteroscopy*. Cham: Springer; 2018. pp. 421-468. DOI: 10.1007/978-3-319-57559-9_41