

# We are IntechOpen, the world's leading publisher of Open Access books Built by scientists, for scientists

6,900

Open access books available

186,000

International authors and editors

200M

Downloads

Our authors are among the

154

Countries delivered to

TOP 1%

most cited scientists

12.2%

Contributors from top 500 universities



WEB OF SCIENCE™

Selection of our books indexed in the Book Citation Index  
in Web of Science™ Core Collection (BKCI)

Interested in publishing with us?  
Contact [book.department@intechopen.com](mailto:book.department@intechopen.com)

Numbers displayed above are based on latest data collected.  
For more information visit [www.intechopen.com](http://www.intechopen.com)



# Minimally Invasive Surgical Treatment of Migraine

*Francesco Simonacci, Nicolò Bertozzi, Gianluigi Lago,  
Carlo Fante, Giuseppe Sanese and Edoardo Raposio*

## Abstract

Migraine headache (MH) is a very common disorder affecting 10–12% of the world's adult population. The first line therapy for migraine is usually a combination of conservative treatments but some patients seem to be refractory. For this group of patients, the minimally invasive surgical treatment of migraine might offer a solution. Migraine is usually caused by extracranial sensitive nerve compression due to vascular, fascial or muscular structures nearby. The aim of migraine surgery is to relieve such compression at specific trigger points located in the occipital, temporal and frontal regions. From June 2011 until July 2019, we performed MH decompression surgeries in over 269 patients with either frontal, occipital, or temporal migraine trigger sites. In the occipital and temporal areas, nerve decompression was achieved by occipital and superficial temporal artery ligation, respectively. In patients suffering from frontal headache we performed both endoscopic nerve decompression and transpalpebral decompression. Among patients suffering from occipital migraine, 95% of them showed improvement of their condition, with 86% reporting complete relief. As for temporal migraine, positive outcome was achieved in 83% of the patients (50% complete elimination and 33% partial improvement). In patients suffering from frontal migraine, positive results were observed in 94% of the patients (32% complete elimination, 62% partial improvement). Migraine is a common and debilitating condition that can be treated successfully with minimally invasive surgical procedure especially for those patients non-responding to medical therapies.

**Keywords:** migraine, tension-type headache, surgical therapy, minimally invasive surgery

## 1. Introduction

Migraine headache (MH) is known to affect over 324.1 million people worldwide [1, 2]. However, MH is still widely undiagnosed and undertreated. In the US alone, MH treatment cost accounts for over \$17 billion each year, without taking into consideration the indirect costs due to the 112 million annual workdays lost, which has an estimated cost of \$14 billion [2–4]. Furthermore, MH has an even greater burden on patients' everyday life, their families, and the society.

Despite its prevalence and debilitating nature, MH is still widely undiagnosed and undertreated. A combination of pharmacologic (both abortive and preventive drugs) and non-pharmacological interventions (such as behavioral and lifestyle

changes) are still the main treatment for MH patients. Nevertheless, most MH sufferers remain refractory and does not achieve satisfactory relief.

Among the numerous hypotheses proposed over the years regarding MH etiology, none has come to clearly highlight its true nature. Some researchers have proposed that MH might be originated from a central neurovascular phenomenon, others have hypothesized a cortical neuronal hyperexcitability, others a cortical spreading depression, others an abnormal modulation of brain nociceptive system, and eventually others have demonstrated a central/peripheral activation with sensitization of the trigeminal system [2, 5]. But still MH pathophysiology is unclear and a matter of international debate.

Plastic surgeons were never looking for a surgical treatment for MH; however, this idea came into their eyes in 1999 following the reports made by patients that underwent corrugator supercilii muscle resection for forehead rejuvenation surgery and experienced elimination or improvement in their MH after [2, 5]. In 2000, Guyuron et al. [5] first reported in a retrospective study this association between corrugator supercilii muscle resection and disappearance or significant improvement in MH attacks, paving the way for a new MH origin and thus a new treatment option. Indeed MH appeared to be triggered by a peripheral activation of the trigeminal nerve, due to overstimulation of its branches (trigger points), followed by peripheral and central sensitization [5]. And therefore, surgical decompression of these trigger sites might end up as an effective treatment modality of MH.

In the following years, independent researchers demonstrated the efficacy of botulin toxin injection for the treatment of MH [2]. These evidences supported the hypothesis that MH was determined by the peripheral activation of trigeminal nerve branches.

The trigger site was defined as the point where the MH attack starts and corresponds to the anatomical area of potential irritation of the trigeminal nerve branches [2, 6]. As a pathophysiological consequence of the chronic mechanical stimulation and irritation of the trigeminal nerve terminal branches, calcitonin gene-related peptide, substance P, and neurokinin are released [2, 5, 6]. These neuropeptides may cause the activation of the trigeminovascular system and the neurogenic inflammation leading to meningeal irritation, altered microvascular blood flow, central and peripheral trigeminal sensitization recognized as hyperalgesia, and cutaneous allodynia.

Eventually, multiple anatomical studies strengthened the trigger point theory of MH origin by demonstrating that musculature, vessels, bony foramen, and fascial bands could entrap or compress nerve branches at proposed migraine trigger sites [2, 6, 7].

Over the last 15 years, Guyuron conducted several studies providing foundation for this hypothesis and reported a reduction of the frequency, duration, and intensity of MH by at least half in 80–90% of patients [2, 5, 7–9]. In the same years, other independent groups reported similar findings by employing Guyuron's surgical approach, demonstrating the effectiveness of the procedure and the reproducibility of the results [2, 6]. However, the most striking evidence for the effectiveness of peripheral nerve decompression surgery for MH treatment came from a double-blind, sham-controlled study of Guyuron et al. [2, 8]. In this trial, 49 patients underwent decompressive surgery, while 26 underwent sham surgery. At least 50% reduction in MH was reported from 57.7% of patients of the sham surgery group and 83.7% in the actual surgery group ( $p < 0.05$ ). Moreover, 57.1% of actual surgical group reported complete elimination of MH symptoms, compared with only 3.8% of patients in the sham surgery group ( $p < 0.001$ ). At 1 year, all migraine headache measurements were significantly improved in the actual surgical group and were not influenced by the trigger site.

Following these studies, four were the main trigger sites identified:

1. I Trigger Site (Frontal): patients present with frontal symptoms; the glabellar muscles and/or supratrochlear and supraorbital vessels may irritate corresponding nerves.
2. II Trigger Site (Temporal): patients with temporal headaches; the temporalis muscle or the superficial temporal artery may cause inflammation of the zygomatic temporal branch of the trigeminal nerve (ZTN) or the auriculotemporal nerve (ATN).
3. III Trigger Site (Rhinogenic): patients complain of paranasal and retrobulbar headaches; deviated septum, contact between the turbinates and the septum, concha bullosa, septa bullosa, and other intranasal abnormalities may irritate the trigeminal end branches. This site will not be covered in the present chapter.
4. IV Trigger Site (Occipital): patients refer occipital symptoms: occipitalis, trapezius, and semispinalis capitis muscles, fascial bands, or the occipital artery can irritate the greater occipital nerve (GON) and/or the lesser occipital nerve (LON).

Following these evidences, it came to be clearly known that an essential step was detecting the precise site of pain onset (the trigger point) [2, 10–12]. Although patients might report diffuse headache, once they were asked to locate where the pain begins, they could precisely pinpoint it with one fingertip, and that was where the surgical treatment had to be performed in order to release the putative nerve branch. Surgeons' finger compression over the trigger point usually can evoke pain, thus confirming the exact location of trigger point. Nerve blocks and portable Doppler were also successfully investigated in order to confirm the trigger points and help less experienced surgeons, while preoperative botulinum toxin injections proved to be less useful. Lack or incomplete response should be carefully interpreted since it does not automatically exclude the suspected trigger point; indeed, incomplete release might have been performed. Careful analysis of patients' symptoms and meticulous physical examination can reliably guide the surgical planning. Indeed, MH origin and surgical deactivation procedures resembles closely upper limb compressing neuropathies. Therefore, surgical treatment for MH can successfully eliminate or reduce the MH frequency, intensity, and duration in a lasting manner, reducing the economic burden of MH sufferers, improving patients' performances and participation in daily life activities [2, 3–10]. But still, a percentage of patients are refractory to surgery [2, 7]. Possible explanations are that incomplete or incorrect detection of all of the trigger sites have occurred or that irritation sites are not correctly dealt by current surgical approaches [2, 6]. Rigorous patient screening and selection with proper identification of MH trigger points are mandatory for a successful surgical outcome; yet a thorough understanding of the anatomy is essential to ensure complete nerve release and prevent postoperative complications.

## **2. Surgical treatment**

In order to be regarded eligible to undergo the surgery patients had to be diagnosed by a board-certified neurologist with: migraine without aura, tension-type headaches, or new daily persistent headaches with 4 or more attack each month for

at least 6 months. Also, patients that do not benefit from any medications for their headache might undergo the procedure. However, patients with cluster headache, episodic tension-type headache, or secondary headaches are considered ineligible to undergo our procedure. Furthermore a CT scan or an MRI study must be performed prior to be regarded eligible for migraine deactivation surgery in order to rule out any cause of secondary migraine headache.

## **2.1 Frontal trigger site**

The supraorbital nerve is a sensory nerve originating from the frontal branch of the ophthalmic division of the trigeminal nerve. In the majority of the cases, it passes through a supraorbital notch, which can be occasionally completed by a fibrous band. Here the nerve displays an intimate relationship with the corrugator supercilii muscle. The reason why some patients do not respond to the surgical decompression of the only supraorbital nerve and need a more medial muscular resection is that the supratrochlear nerve may be involved [2, 13–16]. The supratrochlear nerve is the smallest terminal branch of the frontal nerve, which itself originates from the ophthalmic division of the trigeminal nerve. It emerges between the trochlea and the supraorbital foramen. Another source of compression can be the interaction of nerves with the vascular structures. The main vessels that may be involved are the supratrochlear and the supraorbital arteries.

Patients who suffered from frontal migraine headache can be treated with either endoscopic or transpalpebral approach. In our experience, we performed both procedures to decompress supraorbital and supratrochlear nerves [13–16]. However, endoscopic nerve decompression cannot be performed on patients with long foreheads (8 cm measured from the anterior hairline to the supraorbital ridge) or on patients with significant curvature to the forehead, as endoscopic access would have been difficult to impossible. In our experience, endoscopic approach did not allow to treat the vascular compression of supraorbital and supratrochlear nerves by corresponding ectasic arteries [2, 13–16]. Transpalpebral approach for frontal trigger site deactivation was performed by means a supratarsal crease incision involving up to two-thirds of the medial limit of the caudal portion of the conventional upper blepharoplasty incision. The upper eyelid, glabellar area, and the lower forehead were infiltrated with local anesthesia composed by 40-cc Carbocaine 1% + 40-cc NaCl 0.9% and 20-cc sodium bicarbonate 8.4%. After raising a skin-orbicularis oculi muscle flap above the level of the septum, the orbicularis muscle was dissected in a cephalic direction. The dissection was continued to the supraorbital rim. The corrugator supercilii muscle protecting the supraorbital and supratrochlear nerves was elevated and by dissection the exposure of depressor supercilii muscle was performed. After selective myotomy of depressor and corrugator supercilii muscles, the lateral fibers of the procerus muscle encasing the supratrochlear nerve were dissected. Once the supraorbital and supratrochlear nerves were isolated, they were decompressed by the cauterization of the concomitant ectasic arteries. The cutaneous access was closed with absorbable sutures, and steri-strips were positioned at level of superior eyelids bilaterally. The endoscopic selective myotomies technique was performed with a single access by mean a specifically modified endoscope (Karl Storz, Tuttlingen, Germany). With the patient supine and the head in a neutral position, frontal trigger nerves were located. Skin markings were drawn above the eyebrow bilaterally, at the mid-pupillary line (supraorbital nerve) and 1 cm medially (supratrochlear nerve). Local anesthesia with diluted 40-cc Carbocaine 1% + 40-cc NaCl 0.9% and 20-cc sodium bicarbonate 8.4% was injected in the forehead, between the glabellar region and about 2 cm behind the anterior hairline. A single 1.5-cm incision was then performed on the midline, 1 cm behind the frontal

hairline. All tissues were dissected until the periosteum layer. The lateral anatomic limit of the undermined area was the temporal region, bilaterally. In order to lift the frontal skin during the endoscopic procedure (and better visualize the anatomic structures) nylon 1-0 sutures were placed in the superciliary region at each side of both supratrochlear and supraorbital nerves bilaterally. Our modified endoscope (Karl Storz, Tuttlingen, Germany) consists of a 9-mm trocar with an air/insufflator/suction triple valve, a straight Hopkins telescope with fiber-light transmission, a Wittmöser operating sheath with a connection for high-frequency diathermy, and a specifically designed elliptical-tipped wire loop electrode for electrocautery. The modified endoscope was inserted through the incision in the subgaleal plane and used to perform endoscopically assisted section of the corrugator supercilii, depressor supercilii, and procerus muscles bilaterally, with the purpose of decompressing the supraorbital and supratrochlear nerves bilaterally. At the end of the procedure, after an accurate hemostasis, the cutaneous access was closed with absorbable suture, without any drainage; a compressive bandage was positioned all around undermined region [2, 13–16] (**Figure 1**).

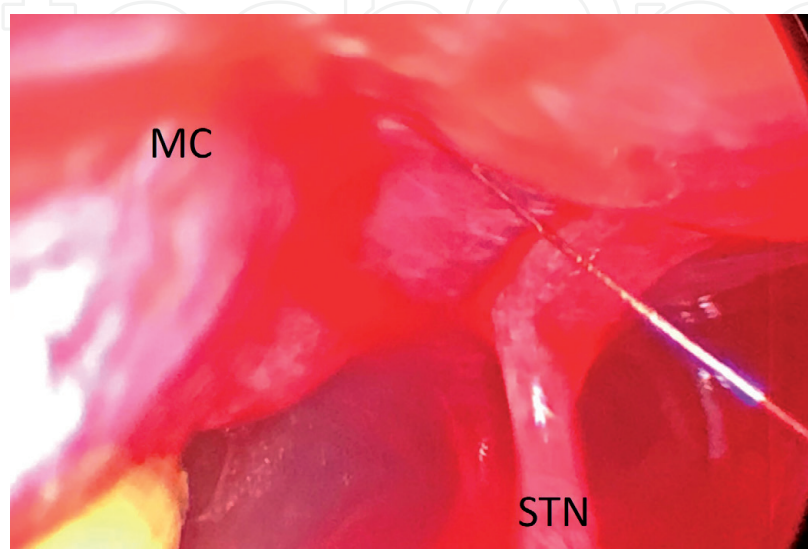
## 2.2 Temporal trigger site

The ATN and ZTN are the two primary trigger points in the temporal migraine. The ATN is one of the terminal branches of the mandibular (V1) division of the trigeminal nerve. The ZTN is one of the terminal branches of the maxillary division (V2) of the trigeminal nerve [17–21].

It is our experience that the ATN is more often involved than the ZTN as temporal MH trigger given the close relationship with the superficial temporal artery (STA). Therefore, our surgical procedure primarily aims at eliminating the pulsatile irritation of the STA to the ATN by ligating the artery prior to and above the intersection or coiling segment. However, we perform ZTN decompression whenever STA-ATN relationship is not intraoperatively observed.

We perform both our personal decompression techniques under local assisted anesthesia [17].

For ATN decompression surgery, we usually marked a 1.5-cm incision where patients pinpoint the painful spot above the insertion of auricular helix at level of temporal area. A handheld Doppler was regularly used to locate the STA, since we



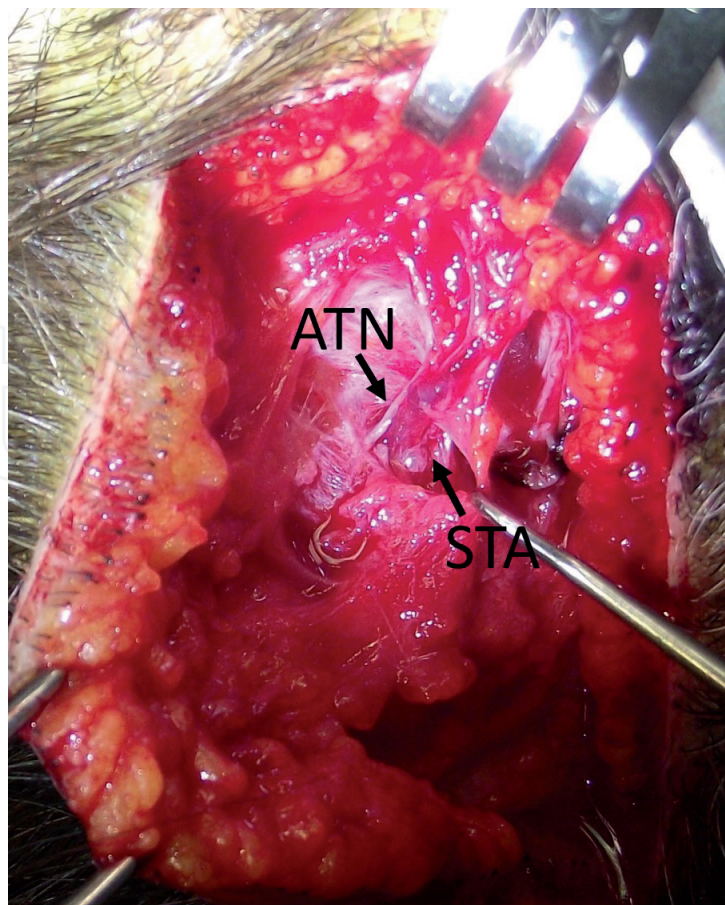
**Figure 1.**  
*Endoscopic selective myotomies of corrugator supercilii muscle (MC) with decompression of supraorbital nerve (STN).*

observed 100% correlation rate between the trigger point identified and a close ATN-STA relationship (being either a simple crossover or a helical intertwining). Once the incision was made, dissection was taken with the help of blunt tipped scissors to expose and isolate both ATN and STA, which was ligated both proximally and caudally to the area of nerve-artery intersection [17].

When it was necessary to decompress the ZTN, we made 3-cm cutaneous incision 8–10 mm behind the temporal hairline and took dissection deep to the deep temporal fascia by the blunt tip scissors. We opened the inferior temporal septum exposing the inferior temporal compartment that contains the ZTN, sentinel vessels, and temporal branches of facial nerve (that must be carefully preserved by incorporating it in the roof of the elevated flap). Then we widened the exit of the ZTN through temporal muscle and fascia, and the sentinel vessels were cauterized only when patients described a pulsating pain in the temporal region [17] (**Figure 2**).

### 2.3 Occipital trigger site

The common occipital headache symptoms here can be caused by the compression of the greater, lesser, and third occipital nerves. This is due to the presence of muscular and fascial entrapments and also because of their interaction with the vascular structures [2, 4, 7, 22]. The greater occipital nerve originates from the medial branch of the C2 dorsal root. It curves to reach the occipital region, running caudal to the inferior oblique muscle and sometimes piercing it. Then it reaches the semispinalis muscle, where it is possible to identify the deepest potential compression point of the nerve. The course of the nerve in the area of the superior nuchal



**Figure 2.**  
*Close auriculotemporal nerve (ATN) and superficial temporal artery (STA) relationship.*

line is variously described, because of the large anatomical variability that these structures present. The latest studies have shown the exact location of the intramuscular course of the nerve: it is located 3 cm below and 1.5 cm lateral to the occipital protuberance [2, 4, 7, 22]. Possible trigger points can be found at its entrance into the deep fascia underlying the semispinalis or the muscle itself or at level of the entrance of the nerve in the semispinalis capitis and trapezius muscles. Other possible compression is where the nerve pierces the tendinous insertion of the trapezius into the nuchal line [2, 4, 7, 22].

Because of the surgical decompression of the nerve, the semispinalis capitis and the trapezius together with the splenius and the occipital muscles are resected with multiple myotomies.

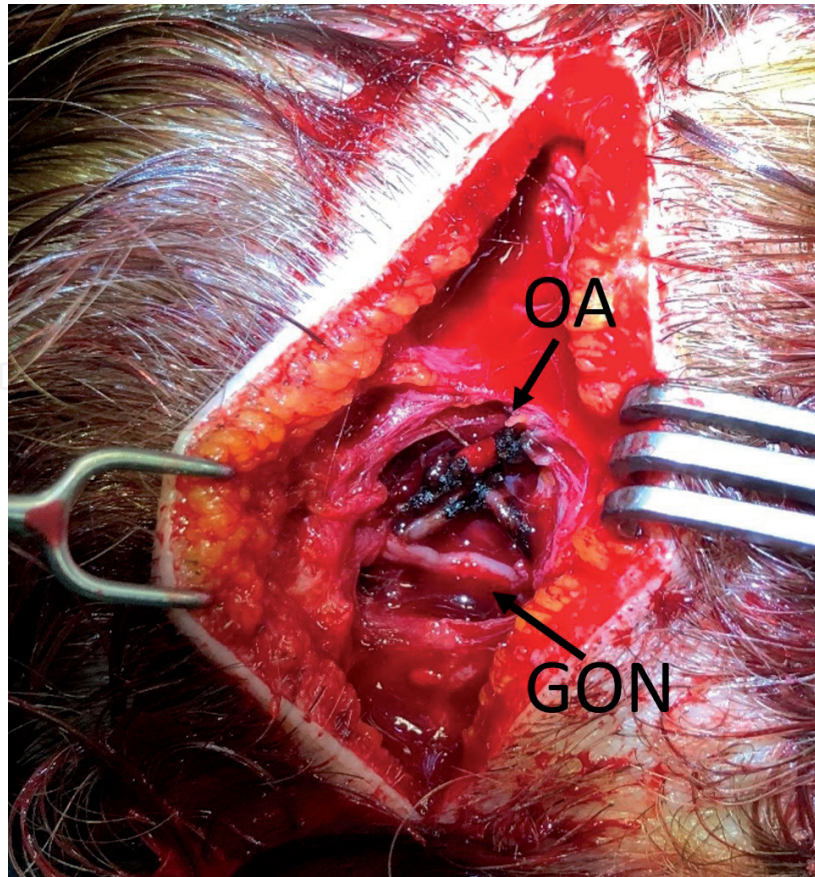
However, based on our study, the close relationship found between the great occipital nerve and the occipital artery in the region of the superior nuchal line is the principal trigger point of occipital migraine.

This artery is the main vessel running through the occipital area. It arises from the external carotid artery, and it runs medially to the mastoid process on the temporal bone. It then reaches the occipital region, boring the deep cervical fascia between the sternocleidomastoid and the cranial attachment of the trapezius. At this point it can be found in the subcutaneous layer leaving many convoluted branches and anastomosing with the contralateral artery [3]. In more than 50% of the cases, an intimate anatomical relationship was found. There are two possible types of interaction: they can coil together (70%) or the other possibility is a simple crossing (30%) with the nerve passing superficial to the artery [2, 4, 7, 22].

Furthermore, minor trigger sites are also described in this area [2, 4, 7, 22]. It is related to the lesser occipital nerves, which can be similarly compressed by fascial bands and the occipital artery branches. If the lesser occipital nerve is affected, it can be responsible of laterally located pain symptoms. It arises from C2 or rarely from C3 dorsal root; it emerges from the posterior border of the sternocleidomastoids, seldom piercing it, and then ascends along it. The emergence point was found with a 3-cm diameter located 6.5 cm from midline and 5.3 cm below the line drawn between the two external auditory canals.

Surgical treatment of occipital trigger site aims at removing the potential compression points of the greater and the lesser occipital nerve along their course throughout the semispinalis, the splenius and the trapezius muscles to the subcutaneous tissue of the occipital scalp. The avulsion of the third occipital nerve (TON) during the occipital migraine surgery does not improve clinical outcomes. According to Guyuron et al. [7], Lin et al. [23], Dash et al. [24], and Lee et al. [25], the currently adopted procedure for treatment of the occipital trigger site, undertaken under general anesthesia, relies first on an incision in the occipital scalp and extensive undermining through which a small portion of the semispinalis capitis muscle is removed. This muscle is usually pierced by the greater occipital nerve (GON), lesser occipital nerves (LON) bilaterally. Subsequently, a subcutaneous flap is transposed between the GON and the muscle to avoid nerve impingement [7, 23–25].

As regards our experience [26–28], we performed the occipital decompression surgical technique with the patient prone, under local assisted anesthesia. After injecting 40-cc of diluted Carbocaine 1% + 40-cc NaCl 0.9% and 20-cc sodium bicarbonate 8.4%, two horizontal occipital scalp incisions 5 cm in length were performed along the superior nuchal line bilaterally, at the location of arterial signal detected preoperatively by portable Doppler. Underneath the subcutaneous tissue, an accurate dissection of occipital, trapezius, splenius capitis and semispinalis capitis muscles allowed to identify the GON and vascular bundle (occipital



**Figure 3.**  
*Cauterization of ectasic occipital artery (OA) with decompression of greater occipital nerve (GON).*

artery). When we found a dilated (or frankly aneurysmatic) occipital artery in close connection with the GON, we ligated or cauterized the vessel without any other surgical maneuvers except for accurate hemostasis and skin closure.

In the remaining cases in which vascular compression was not found we adopted a more conventional approach based on neurolysis of the GON and LON by undermining the occipital, trapezius, splenius capitis and semispinalis capitis muscles and following the nerve course caudally as possible [26, 27]. At the end of the procedure, after an accurate hemostasis, the cutaneous access was sutured with absorbable threads, without any drainage. No trichotomy was needed, and the scar from the incision was hidden in the patient's hair. The total operative time was no longer than 90 min for bilateral incisions, but often it was less than 60 minutes when the relevant anatomical structures were easily identified [27, 28] (**Figure 3**).

### 3. Results

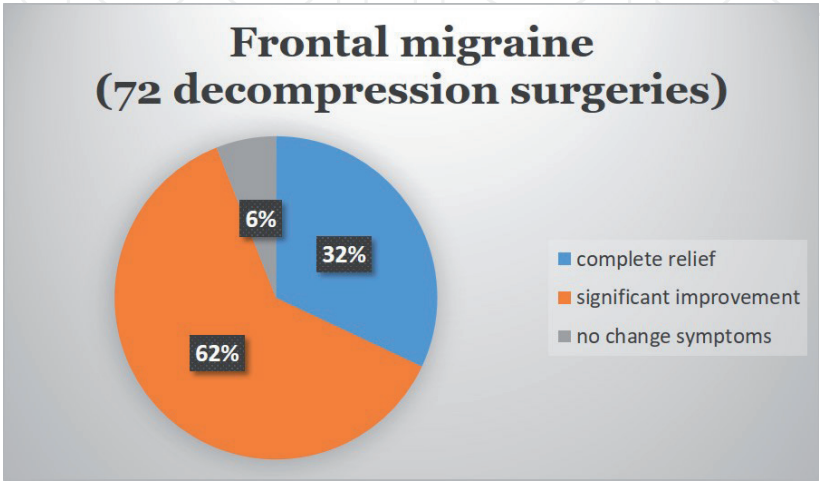
From June 2011 until July 2019, we performed MH decompression surgeries in over 269 patients with either frontal, occipital, or temporal migraine trigger sites [2, 13–17, 26–28].

As concern the frontal migraine we performed 72 decompression surgeries (65 bilateral and 7 unilateral). After a mean follow-up of 24 months (range: 12–97 months), patients with frontal trigger site migraine reported a 94% positive response to surgery (32% complete relief and 62% significant improvement), while 6% had no change in their symptoms. Among total patients underwent MH frontal decompression surgeries, 24 patients (34.2%) experienced secondary trigger point emergence following primary occipital and/or temporal migraine surgery.

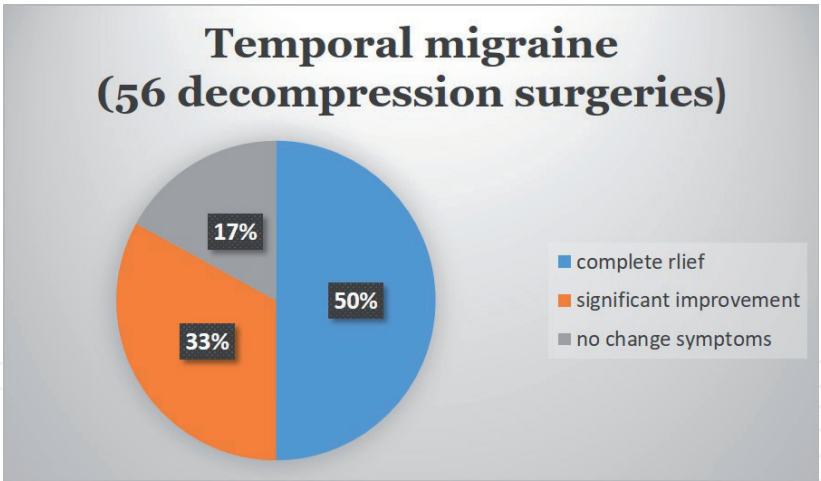
Among these, 20 patients had two trigger points (18 frontal and occipital, 2 frontal and temporal) while 4 patients had all three trigger points. All patients continue to experience a quality of life better than before surgery, and all would have the surgery again. The learning curve and the experience of the operator play also an important role when evaluating clinical outcomes (**Figure 4**).

Decompression surgeries to treat temporal trigger point were 56. Among these, 53 had monolateral localization, while 3 had bilateral one. Because the ATN-STA close relationship was observed intraoperatively in 47 surgeries the only ATN decompressions were performed. Whereas ZTN deactivation procedures were performed during the same operative session 6 times, since no ATN-STA close relationship was encountered. Therefore, we observed ATN-STA close relationship in 85.3% of patients; single STA-ATN intersection accounted for 83.7% of the cases, while helical intertwining accounted for 16.3%. After a mean follow-up of 24 months (range, 3–67 months), patients complaining for temporal MH had 83% positive surgical outcome (50% complete MH elimination, 33% significant improvement). Among total MH temporal decompression surgeries, 29 patients (49%) experienced secondary or tertiary trigger point emergence following primary migraine surgery. Among these 22 had two trigger points (20 temporal and occipital, 2 frontal and occipital) while 4 patients had all three trigger points (**Figure 5**).

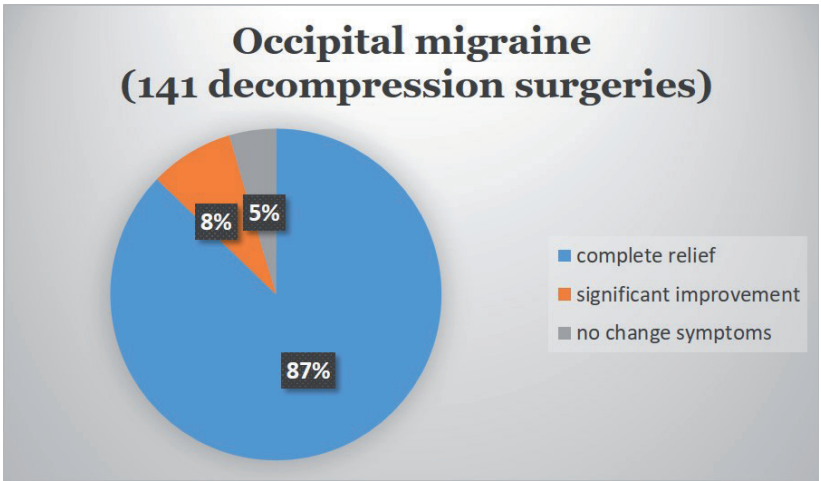
As concern occipital migraine we performed 141 decompression surgeries (94 bilateral and 47 unilateral). In 119 patients with occipital migraine, we found a dilated occipital artery in close connection with the GON and we ligated the vessel without any other surgical maneuvers. In 22 patients with occipital migraine, vascular compression was not found and we adopted a conventional approach based on neurolysis of the GON and LON from muscles. We gathered data from questionnaires completed before and after surgery. After a mean follow up of 24 months (range: 3–67 months), patients with occipital migraine had positive response in 94.9% (86.8% complete relief and 8.1% significant improvement), and 5.1% did not get any better. As for the 119 patients who underwent dilated occipital artery ligation, positive response 95.5% (90% complete relief and 5.5% significant improvement) and 4.5% did not get any better. As for the 22 patients who did not undergo occipital artery ligation, we observed positive response in 91% (76% complete relief and 15% significant improvement) of the subjects while 9% did not get any better. All the patients without improvement of the symptoms after occipital artery ligation (3.5%) suffered of unilateral occipital migraine and referred complete relief after contralateral secondary surgery. Total patients underwent MH decompression



**Figure 4.**  
Results of fontal migraine decompression surgeries from June 2011 until July 2019.



**Figure 5.**  
*Results of temporal migraine decompression surgeries from June 2011 until July 2019.*



**Figure 6.**  
*Results of occipital migraine decompression surgeries from June 2011 until July 2019.*

surgeries, 42 patients (29.7%) experienced secondary or tertiary trigger point emergence following primary migraine surgery. Among these, 38 patients had two trigger points (18 occipital and frontal, 20 occipital and temporal) while 4 patients had all three trigger points (**Figure 6**).

**4. Complications**

Migraine surgery is regarded as a minimally invasive procedure; thus, no concerning side effects are usually reported. Temporary anesthesia occurred in all patients, which lasted 163 days on average [2, 13–17, 26–29]. Minor and transient complications reported in literature are lasting occipital numbness, intense itching after surgery, hypertrophic scar, incisional cellulitis, transient mild incisional alopecia or hair thinning, lasting neck stiffness that have an incidence ranging from 1 to 5% [2, 13–17, 26–29]. As regard our experience, intense itching after surgery was present in 30% of patients, temporary anesthesia in all patients while postoperative infections, seromas, or hematomas were not observed. All patients that were refractory to surgery did not report worsening in their MH at any follow-up. As concern frontal migraine decompression surgeries all patients experienced frontal and/or upper eyelid edema of various degrees. Usually the edema resolves by the

fifth postoperative day. Ecchymosis of both upper and lower eyelids follows surgery. No treatment needed to be given as these collateral events resolve by themselves; boric water applications three times a day helped the process of reabsorption of the edema. As previously stated, the only hypothetical serious complication that might occur within the 12 h following the surgery is the compression of the optical nerve due to the descent of the edema into the posterior orbicular space. In these cases, prompt recognition of patient's sight modification is mandatory in order to urgently decompress the optic nerve. Patients with particularly thin skin of the frontal region may develop postoperative burn-like scar because of the endoscopic electrocautery. The most common complication after site temporal migraine surgeries is slight hollowing of the temple (54% incidence rate). Nerve avulsion might be associated with neuroma formation, although it is not reported in literature of any neuroma following avulsion of ATN and/or ZTN [2, 13–17, 26–28].

Based on our data collected, secondary trigger point emergence following primary occipital migraine surgery occurred in 35% of patients. However, we routinely deactivate the main trigger site first, and then a second or third surgery is performed at the remaining sites 3 months after each surgery. MH recurrence may occur from 1 up to 3 months after surgery; thus the result may be regarded as permanent only after the third postoperative month [2, 13–17, 26–28].

## Conflict of interest

The authors declare no conflict of interest.

## Author details


Francesco Simonacci<sup>1\*</sup>, Nicolò Bertozzi<sup>1</sup>, Gianluigi Lago<sup>1</sup>, Carlo Fante<sup>1</sup>,  
Giuseppe Sanese<sup>2</sup> and Edoardo Raposio<sup>1</sup>

<sup>1</sup> Department of Medicine and Surgery, Plastic Surgery Unit, University of Parma, Parma, Italy

<sup>2</sup> Division of Plastic and Reconstructive Surgery, University “Tor Vergata”, Rome, Italy

\*Address all correspondence to: francescosimonacci@hotmail.it

## IntechOpen

© 2019 The Author(s). Licensee IntechOpen. This chapter is distributed under the terms of the Creative Commons Attribution License (<http://creativecommons.org/licenses/by/3.0>), which permits unrestricted use, distribution, and reproduction in any medium, provided the original work is properly cited. 

## References

- [1] World Health Organization. The Global Burden of Disease, 2004 Update. Geneva, Switzerland: World Health Organization; 2004
- [2] Raposio E, Bertozzi N, Bordin C, Simonacci F. Surgical therapy of migraine and tension-type headaches. In: Turker H, editor. *Current Perspectives on Less-Known Aspects of Headache*. Zagreb, Croatia: InTech; 2017. pp. 93-114
- [3] Faber C, Garcia RM, Davis J, Guyuron B. A socioeconomic analysis of surgical treatment of migraine headaches. *Plastic and Reconstructive Surgery*. 2012;**129**:871-877
- [4] Chmielewski L, Liu MT, Guyuron B. The role of occipital artery resection in the surgical treatment of occipital migraine headaches. *Plastic and Reconstructive Surgery*. 2013;**131**:351e-356e
- [5] Guyuron B, Varghai A, Michelow BJ, Thomas T, Davis J. Corrugator supercilii muscle resection and migraine headaches. *Plastic and Reconstructive Surgery*. 2000;**106**:429-437
- [6] Janis JE, Barker JC, Javadi C, Ducic I, Hagan R, Guyuron B. A review of current evidence in the surgical treatment of migraine headaches. *Plastic and Reconstructive Surgery*. 2014;**134**:131-141
- [7] Guyuron B, Kriegler JS, Davis J, Amini SB. Comprehensive surgical treatment of migraine headaches. *Plastic and Reconstructive Surgery*. 2005;**115**(1):1-9
- [8] Guyuron B, Reed D, Kriegler JS, Davis J, Pashmini N, Amini S. A placebo-controlled surgical trial of the treatment of migraine headaches. *Plastic and Reconstructive Surgery*. 2009;**124**:461-468
- [9] Guyuron B, Kriegler JS, Davis J, Amini SB. Five-year outcome of surgical treatment of migraine headaches. *Plastic and Reconstructive Surgery*. 2011;**127**:603-608
- [10] Punjabi A, Brown M, Guyuron B. Emergence of secondary trigger sites after primary migraine surgery. *Plastic and Reconstructive Surgery*. 2016;**137**:712e-716e
- [11] Guyuron B, Nahabet E, Khansa I, Reed D, Janis JE. The current means for detection of migraine headache trigger sites. *Plastic and Reconstructive Surgery*. 2015;**136**:860-867
- [12] Liu MT, Armijo BS, Guyuron B. A comparison of outcome of surgical treatment of migraine headaches using a constellation of symptoms versus botulinum toxin type A to identify the trigger sites. *Plastic and Reconstructive Surgery*. 2012;**129**:413-419
- [13] Raposio E, Caruana G. Frontal endoscopic myotomies for chronic headache. *The Journal of Craniofacial Surgery*. 2015;**26**:e201-e203
- [14] Raposio E, Caruana G. Minimally invasive endoscopic surgical treatment of headache. In: Raposio E, editor. *Atlas of Endoscopic Plastic Surgery*. New York, N.Y: Springer; 2016. pp. 17-21
- [15] Caruana G, Bertozzi N, Boschi E, Grieco MP, Grignaffini E, Raposio E. Endoscopic forehead surgery for migraine therapy personal technique. *Annali Italiani di Chirurgia*. 2014;**85**:583-586
- [16] Caruana G, Grignaffini E, Raposio E. Endoscopic forehead muscle resection for nerve decompression: A modified procedure. *Plastic and Reconstructive Surgery*. *Global Open*. 2015;**3**:e342

- [17] Bertozzi N, Simonacci F, Lago G, Bordin C, Raposio E. Surgical therapy of temporal triggered migraine headache. *Plastic and Reconstructive Surgery*. Global Open. 2018;**6**:e1980
- [18] Chim H, Okada HC, Brown MS, et al. The auriculotemporal nerve in etiology of migraine headaches: Compression points and anatomical variations. *Plastic and Reconstructive Surgery*. 2012;**130**:336-341
- [19] Janis JE, Hatef DA, Ducic I, et al. Anatomy of the auriculotemporal nerve: Variations in its relationship to the superficial temporal artery and implications for the treatment of migraine headaches. *Plastic and Reconstructive Surgery*. 2010;**125**:1422-1428
- [20] Janis JE, Hatef DA, Thakar H, et al. The zygomaticotemporal branch of the trigeminal nerve: Part II. Anatomical variations. *Plastic and Reconstructive Surgery*. 2010;**126**:435-442
- [21] Iwanaga J, Watanabe K, Saga T, et al. Anatomical study of the superficial temporal branches of the auriculotemporal nerve: Application to surgery and other invasive treatments to the temporal region. *Journal of Plastic, Reconstructive & Aesthetic Surgery*. 2017;**70**:370-374
- [22] Gfrerer L, Raposio E, Ortiz R, Austen WG Jr. Surgical treatment of migraine headache: Back to the future. *Plastic and Reconstructive Surgery*. 2018;**142**:1036-1045
- [23] Lin SH, Lin HC, Jeng CH, Hsieh CH, Lin YH, Chen CC. Experience of surgical treatment for occipital migraine in Taiwan. *Annals of Plastic Surgery*. 2016;**76**:S80-S84
- [24] Dash KS, Janis JE, Guyuron B. The lesser and third occipital nerves and migraine headaches. *Plastic and Reconstructive Surgery*. 2005;**115**:1752-1758
- [25] Lee M, Lineberry K, Reed D, Guyuron B. The role of the third occipital nerve in surgical treatment of occipital migraine headaches. *Journal of Plastic, Reconstructive & Aesthetic Surgery*. 2013;**66**:1335-1339
- [26] Polotto S, Simonacci F, Grignaffini E, Grieco MP, Raposio E. Surgical treatment of frontal and occipital migraines: A comparison of results. *Plastic and Reconstructive Surgery*. Global Open. 2016;**4**:e653
- [27] Raposio E, Caruana G. Tips for the surgical treatment of occipital nerve-triggered headaches. *European Journal of Plastic Surgery*. 2017;**40**:177-182
- [28] Raposio E, Simonacci F, Bertozzi N, Bellini E. Occipital migraine: A vascular approach. *Plastic and Reconstructive Surgery*. Global Open. 2017;**5**:78
- [29] Ducic I, Hartmann EC, Larson EE. Indications and outcomes for surgical treatment of patients with chronic migraine headaches caused by occipital neuralgia. *Plastic and Reconstructive Surgery*. 2009;**123**:1453-1461