

# We are IntechOpen, the world's leading publisher of Open Access books Built by scientists, for scientists

6,900

Open access books available

185,000

International authors and editors

200M

Downloads

Our authors are among the

154

Countries delivered to

TOP 1%

most cited scientists

12.2%

Contributors from top 500 universities



WEB OF SCIENCE™

Selection of our books indexed in the Book Citation Index  
in Web of Science™ Core Collection (BKCI)

Interested in publishing with us?  
Contact [book.department@intechopen.com](mailto:book.department@intechopen.com)

Numbers displayed above are based on latest data collected.  
For more information visit [www.intechopen.com](http://www.intechopen.com)



# Hepatic Involvement in Hemophagocytic Lymphohistiocytosis

*Somanath Padhi, RajLaxmi Sarangi, Susama Patra and Subash Chandra Samal*

## Abstract

Hemophagocytic lymphohistiocytosis (HLH) is a hyperinflammatory syndrome which results in uncontrolled systemic proliferation of benign macrophages in all reticuloendothelial organs producing worsening peripheral blood cytopenia(s); hypercytokinemia leading to hepatic injury producing hyperferritinemia, hypertriglyceridemia, hypofibrinogenemia; and if not diagnosed and treated early may lead to disseminated intravascular coagulation (DIC), multiorgan dysfunction, and death in nearly all individuals. It is postulated that hepatic injury/dysfunction starts early in the course of the disease which may mimic nonspecific hepatitis like prodrome to fulminant hepatic failure; possibly requiring liver transplant. While HLH as an entity is being increasingly recognized nowadays across wide specialties (both pediatric and adults); hepatic involvement in this setting has been poorly characterized. This chapter is aimed to highlight on the diagnosis and classification of HLH with a special emphasis on the pathophysiology of hepatic dysfunction, histomorphology of liver; and the current concept and controversies on the role of liver transplantation in this clinical setting.

**Keywords:** cytokine storm, HLH, liver, transplant, outcome

## 1. Introduction

Hemophagocytic lymphohistiocytosis (HLH) or hemophagocytic syndrome is a potentially catastrophic hyperinflammatory syndrome occurring in genetically susceptible individuals which results due to hyperactive, yet inappropriate, immune system going run amok [1]. This results due to impaired cytotoxic T lymphocyte (CTL)/natural killer (NK) cell activity producing uncontrolled proliferation of benign macrophages in all reticuloendothelial organs such as bone marrow, spleen, liver, and lymph nodes; causing histiocytic hemophagocytosis, worsening unexplained peripheral blood cytopenia (s), cytokine storm, cytokine mediated hepatic injury/dysfunction producing spectrum of biochemical alteration such as hyperferritinemia, hypertriglyceridemia, hypofibrinogenemia, coagulopathy, disseminated intravascular coagulation (DIC), multi organ dysfunction (MOD); and if not diagnosed and treated early, may lead to death in virtually all case [2]. Since the first description of cases coined as “histiocytic medullary reticulocytosis” by Scott Robin and Smith in 1939, there has been a sequential change in nomenclature of this entity [3–6]. While HLH

as an entity is being increasingly recognized nowadays across wide specialties (both pediatric and adults); hepatic involvement in this setting has been poorly characterized [7–9]. Hepatomegaly and hepatic dysfunction, including elevated serum transaminases and bilirubin, cholestasis, and coagulopathy typically occur early in the disease and are associated with marked hematologic and/or neurological abnormalities. In rare instances acute hepatic failure may dominate the clinical picture, which in combination with hyperferritinemia, may mimic neonatal hemochromatosis [10].

2. Classification of HLH

Traditionally, HLH has been broadly classified into two forms: (i) primary HLH which is known to harbor documented genetic abnormalities implicated in the cytotoxic functions of the NK cell/CTL; and (ii) a secondary form which occurs in adults/elderly population without any genetic abnormality. However, upon the realization that HLH defining genetic abnormality can occur in any age, that these defects may be uncommon even in pediatric age group, the designations *primary and secondary* have become less relevant; and stratification into *genetic and acquired* forms seems more appropriate [11]. The genetic variant is again subdivided into autosomal recessive familial HLH (FHL) involving the several mutations in the CTL/NK

Type	Examples with proportions in parentheses
<b>A. Genetic</b>	
i. Autosomal recessive/familial HLH	PFR1/perforin 1 (20-50%), UNC13D/Munc 13-4 (20%), STX11/syntaxin 11 (1%), STXB2/syntaxin binding protein 2 or UNC18B (unknown)
ii. Associated with primary immunodeficiency syndromes	Chediak-Higashi syndrome (LYST), Griscelli syndrome type 2 (RAB27A/Rab27a), Hermansky-Pudlak syndrome type 2 (AP3B1), X-linked proliferative syndrome (XLP) type 1 (SHD2D1A/SAP protein), X-linked proliferative syndrome (XLP) type 2 (BIRC4/XIAP protein)
<b>B.Acquired</b>	
i. Virus associated	Herpes viruses (EBV, CMV, HHV-8, HSV), HIV, HTLV, adenovirus, HAV, HBV, HCV, measles, mumps, rubella, dengue, hantavirus, parvovirus B19, Enterovirus, influenza
ii. Bacteria associated	<i>Staphylococcus aureus</i> , <i>Campylobacter</i> spp., <i>Fusobacterium</i> spp., <i>Mycoplasma</i> spp., <i>Chlamydia</i> spp., <i>Legionella</i> spp., <i>Salmonella typhi</i> , <i>Rickettsia</i> spp., <i>Brucella</i> spp., <i>Ehrlichia</i> spp., <i>Borrelia burgdorferi</i> , <i>Mycobacterium tuberculosis</i>
iii. Fungal associated	<i>Candida</i> spp., <i>Cryptococcus</i> spp., <i>Pneumocystis</i> spp., <i>Histoplasma</i> spp., <i>Aspergillus</i> spp., <i>Fusarium</i> spp.
iv. Parasitic	<i>Plasmodium falciparum</i> , <i>Plasmodium vivax</i> , <i>Toxoplasma</i> spp., <i>Babesia</i> spp., <i>Strongyloides</i> spp., <i>Leishmania</i> spp.
v. Malignancy associated	Peripheral T-cell/NK-cell lymphomas, ALCL, ALL, Hodgkin lymphoma, multiple myeloma, acute erythroid leukemia Prostate and lung cancer, hepatocellular carcinoma
vi. Autoimmune disease associated (macrophage activation syndrome, MAS)	Systemic-onset juvenile idiopathic arthritis, Kawasaki disease, systemic lupus erythematosus, seronegative spondyloarthropathies

**Table 1.**  
Classification of hemophagocytic lymphohistiocytosis (HLH) (adopted from Rosado et al. [1] and Gholam et al. [12]).

cell cytotoxic pathways [PFR1/perforin 1 (20–50%), UNC13D/Munc 13-4 (20%), STX11/syntaxin 11 (1%), STXB2/syntaxin binding protein 2 or UNC18B (unknown)] and those associated with primary immunodeficiency syndromes such as Chédiak-Higashi syndrome (LYST), Griscelli syndrome type 2 (RAB27A/Rab27a), Hermansky-Pudlak syndrome type 2 (AP3B1), and X-linked proliferative syndrome (XLP) type 1 (SHD2D1A/SAP protein) and type 2 (BIRC4/XIAP protein) [12] (**Table 1**).

Acquired form of HLH is known to be triggered by diverse etiologies in susceptible individuals; and are segregated as (i) infection associated secondary to viruses (notably EVB, CMV, HHV-8, HSV, dengue, parvo B19, HAV, HBV, HCV, etc.; any bacteria, fungi, parasites such as Plasmodia, Leishmania, Strongyloides), (ii) malignancy associated (NK-T cell lymphoma/leukemia, anaplastic large cell lymphoma, plasma cell myeloma, Hodgkin lymphoma, B cell non Hodgkin lymphoma, acute lymphoid and myeloid leukemias; and solid malignancies such as lung cancer, hepatocellular carcinoma, etc.), and (iii) macrophage activation syndrome or MAS (associated with autoimmune disorders) [1, 3, 13].

### 3. Diagnostic criteria

There has been a paradigm shift of focus in the diagnosis of HLH since 2004 (**Table 2**) [3]. The 2004 diagnostic criteria developed for the pediatric HLH have been widely adopted in adult medicine without systematic validation. Both 2004 and 2009 guidelines incorporated mutational/genetic analysis as a “major criterion” which has subsequently been taken out, especially for adult HLH case. Moreover, two important parameters that were incorporated in previous criteria such as “impaired NK cell activity” and “increased soluble interleukin 2 receptor” are likely to be removed sooner or later as these tests are available in only very few specialized centers all over the world and are very costly. Therefore, in practice, the necessary five out of eight criteria as per the HLH 2004 guidelines are actually five out of six parameters tested. In addition, the criteria of “bone marrow hemophagocytosis” is becoming increasingly less important nowadays as histiocytic hemophagocytosis has a poor specificity in the diagnosis of HLH and this may not even be evident during initial marrow evaluation [1]! In order to overcome these shortcomings, the French investigators proposed to adopt a new objective scoring system (HLH probability score or HScore) (**Table 3**). A total probability score of 169 was found to have a higher sensitivity and specificity for the diagnosis of HLH [6]. Furthermore, simpler routine laboratory parameters (extended variables) have been incorporated to diagnose the disease early. These include peripheral blood monocytosis, hyponatremia, elevated lactate dehydrogenase, elevated  $\beta 2$  microglobulin, impaired coagulation parameters, and CSF pleocytosis [14].

Another interesting change has been made in regard to the measurement of serum ferritin. A  $\geq 500$   $\mu\text{g/L}$  cut off among pediatric population (up to 18 years of age) was found to have 84% sensitivity in HLH-1994 trial and therefore was included in the HLH 2004 guidelines [15]. Subsequently, pediatricians have revised their ferritin cut off value to  $\geq 10,000$   $\mu\text{g/L}$  with a higher sensitivity and near 100% specificity for the diagnosis of HLH [16]. On the contrary, recent reports from adult intensive care units (ICUs) have suggested a lower ferritin cut off value of 3000 to 4000  $\mu\text{g/L}$  with  $>80\%$  sensitivity and specificity in HLH diagnosis [17]. While hyperferritinemia is not specific to HLH, the same in the clinical context of fever, worsening cytopenia (s), and splenomegaly is highly valuable in the ICUs where sepsis is the major overlapping clinical condition [18]. Recent studies have shown that a high serum soluble interleukin 2 receptor to ferritin ratio is an important biomarker in distinguishing lymphoma associated HLH compared to benign disease associated HLH (8.56 vs. 0.66, respectively,  $P = 0.0004$ ) [19].

Diagnostic parameters	HLH diagnostic criteria					
	HLH-1994	HLH-1997	HLH-2004	HLH-2009	HLH-2014	HLH-2016
Molecular diagnosis	x	x	√	√	x	x
Immunosuppression (Table 3)	x	x	x	x	√	x
Fever	√	√	√	√	√	√
Splenomegaly	√	√	√	√	√	√
Cytopenia (s) <sup>‡</sup>	√	√	√	√	√	√
Hyperferritinemia <sup>§§</sup>	x	x	√	√	√	√
Hypertriglyceridemia <sup>§§§</sup>	√	√	√	√	√	√
Hypofibrinogenemia <sup>‡</sup>	√	√	√	√	√	√
Hemophagocytosis	√	√	√	√	√	√ <sup>§</sup>
Decreased NK cell activity <sup>§§</sup>	x	x	√	√	x	x
Increased soluble IL2 receptor <sup>§§</sup>	x	x	√	√	x	x
Raised SGOT	x	x	x	x	√	x
Required number of criteria	All	All	5/8 or molecular diagnosis	2 major or 1 major and 4 minors	HScore (probability score) (Table-3)	
Supportive features <sup>‡</sup>	x	x	x	x	√	√

<sup>‡</sup>Hemoglobin; <90 g/L (in infants <4 weeks old, <100 g/L); Platelets <100 × 10<sup>9</sup>/L; Neutrophils <1.0 × 10<sup>9</sup>/L).  
<sup>§</sup>≥ 500 µg/L.  
<sup>§§</sup>Fasting triglycerides ≥3.0 mmol/L (≥265 mg/dL).  
<sup>‡</sup>≤1.5 g/L.  
<sup>§</sup>In bone marrow aspirate.  
<sup>§§</sup>Likely to be dropped as a criteria.  
<sup>‡</sup>Coagulopathy, hyperbilirubinemia, hypoalbuminemia, hyponatremia, raised lactate dehydrogenase, elevated β2 microglobulin, peripheral blood monocytois, CSF pleocytosis, etc.  
<sup>√</sup>Included in the criteria. <sup>x</sup> Not included in the criteria.

Table 2.  
Updated diagnostic criteria for HLH [3–6, 14].

4. Pathophysiology of HLH

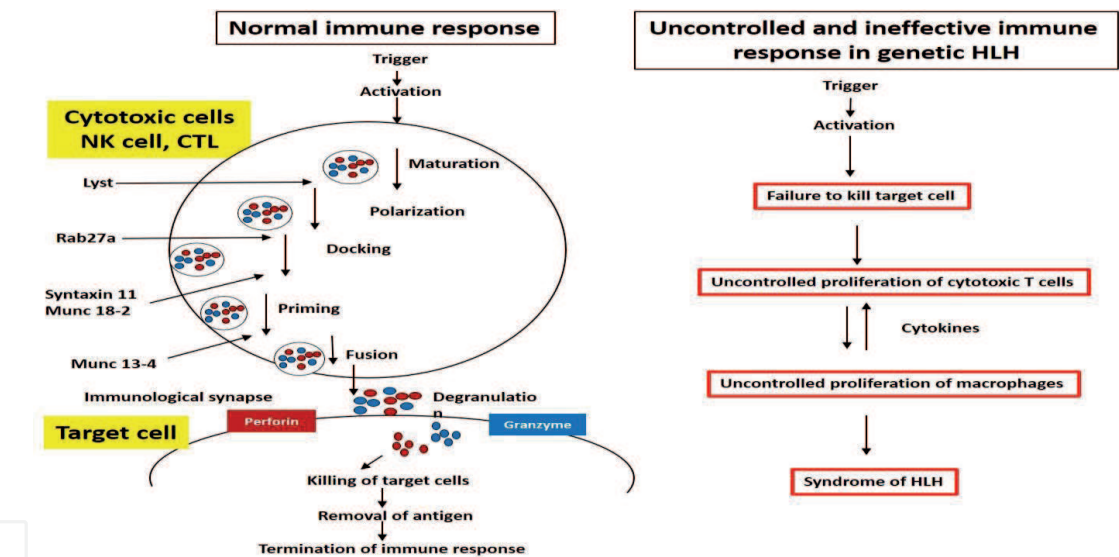
Genetic HLH results due to inability to clear the antigenic stimulus and thus turn off the inflammatory response is what ultimately leads to *cytokine storm* characteristic of HLH. In healthy individuals, viral and tumor antigenic stimuli leads to Th1 mediated cytokine response (IFN-γ, TNF-α, GM-CSF) which in turn, stimulates CTL and NK cells to clear off target cells (viral infected cells, tumor cells, etc.) through release of perforin and granzyme granules at the synaptic site. Perforin is a key cytolytic protein that acts by inserting itself in the membrane of the target cell and creating pores that lead to osmotic lysis of the target cell. The normal production of vesicle granule content requires orchestrated steps of maturation, polarization, docking, fusion, and finally degranulation in the immunological synapse. All the genetic defects described in FHL involve either inadequate levels of perforin itself (FHL2) or improper granule exocytosis (FHL3–5 and immunodeficiency syndromes) (see above in the classification) (**Figure 1**) [2, 20].



Parameters	Number of points (criteria for scoring)
Known immunosuppression <sup>¶</sup>	0 (no) or 18 (yes)
Temperature (°C)	0 (<38.4), 33 (38.4–39.4), or 49 (>39.4)
Organomegaly	0 (no), 23 (hepatomegaly or splenomegaly), or 38 (hepatomegaly and splenomegaly)
Number of cytopenia (s) <sup>‡</sup>	0 (1 lineage), 24 (2 lineages), or 34 (3 lineages)
Ferritin (µg/L)	0 (< 2000), 35 (2000–6000), or 50 (>6000)
Triglyceride (mmoles/L)	0 (<1.5), 44 (1.5–4), or 64 (>4)
Fibrinogen (g/L)	0 (>2.5), or 30 (≤ 2.5)
Serum SGOT (IU/L)	0 (< 30), or 19 (≥ 30)
Hemophagocytosis in marrow aspirate	0 (no) or 35 (yes)

<sup>¶</sup>Human immunodeficiency virus or receiving long term immunosuppressive therapy (glucocorticoids, cyclosporine, azathioprine).  
<sup>‡</sup>Hb ≤ 92 g/L, total leukocyte count ≤ 5000/mm<sup>3</sup>, platelet count ≤ 110,000/mm<sup>3</sup>.

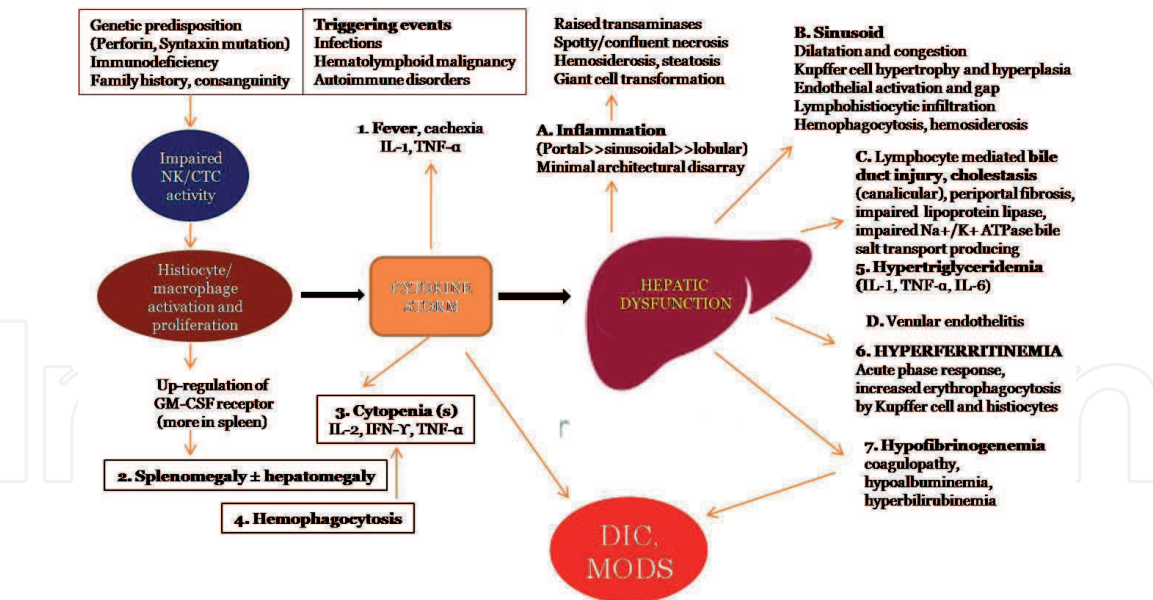
**Table 3.**  
Hemophagocytic lymphohistiocytosis probability score (HScore) as proposed by Fardet et al. [6].



**Figure 1.**  
Immune response in healthy subjects and uncontrolled, ineffective immune response in patients with genetic HLH. Adopted and modified from Janka GE [2].

5. Pathophysiology of hepatic dysfunction: the cytokine theory

It is now postulated that hepatic injury/dysfunction HLH is mainly due to cytokine storm which results due to impaired NK/Cytotoxic T lymphocyte function in a *genetically susceptible* individual while triggering factors playing a crucial role. The up regulation of granulocytic monocytic colony stimulating factor receptor on the macrophages along with macrophage proliferation leads to splenohepatomegaly. The macrophage derived IL-2, IFN-γ, and TNF-α mediated inflammation is reported to be predominantly porto-sinusoidal rather than lobular without any significant alteration in lobular architecture; which in turn produces raised transaminases, hepatocyte hemosiderosis; sinusoidal dilatation and congestion, Kupffer cell hyperplasia and hypertrophy producing hemosiderosis and hemophagocytosis. Furthermore, lymphocyte or lymphohistiocyte mediated biliary ductular injury



**Figure 2.** Cytokine basis of HLH associated hepatic dysfunction. GM-CSF; granulocytic monocyte colony stimulating factor, IL; interleukin, IFN- $\gamma$ ; interferon gamma, TNF- $\alpha$ ; tumor necrosis factor alpha, DIC; disseminated intravascular coagulation, MODS; multiorgan dysfunction syndrome. Note the parameters from no. 1 to 7 are incorporated in the HLH criteria. The pathophysiologic features assigned A to D are related to cytokine mediated liver parenchymal alteration (see below). Schematic representation summarized from de Kerguenec et al. [9] and Billiau et al. [21].

and cytokine (IL 1, IL 6, and TNF- $\alpha$ ) mediated impaired lipoprotein lipase activity causes cholestasis, hyperbilirubinemia and hypertriglyceridemia. Finally, hyperferritinemia so characteristic of HLH, is nothing but the result of acute phase reaction as well as increased erythrophagocytosis by Kupffer cells. All these cytokine basis of hepatic injury may culminate in severe hepatic functional compromise leading to hypofibrinogenemia, hypoalbuminemia, disseminated intravascular coagulation, and multiorgan dysfunction with a fatal outcome (Figure 2).

## 6. Histology of liver in HLH

The morphology of liver in HLH is not well characterized because of insufficient biopsy data, late diagnosis, sampling bias (needle biopsy vs. wedge biopsy); and associated triggering factors such as virus associated histological alterations; especially in acquired cases (Table 4).

Morphological changes as observed in several large series of liver biopsy specimens have shown relatively well-preserved hepatic parenchyma with a portal and sinusoidal lymphohistiocytic, CD 3+, CD8+, Granzyme B+, and variable perforin+ T cell-rich infiltrate [7–9, 21, 22]. Diverse histological patterns have been described in such cases (Table 4): (i) adult type *chronic hepatitis* like characterized by *mild* portal lymphocytic infiltrate with mild bile duct injury and endothelialitis, reported to be so characteristic of neonatal/childhood HLH; (ii) *leukemia like* pattern characterized by *extensive* portal, lymphohistiocytic infiltrate expanding the tracts and encroaching upon the lobular periphery blurring the portal limiting plate and infiltrating the sinusoids; (iii) *histiocytic storage disorder-like* pattern characterized by massive infiltration of histiocyte rich infiltrate plugging and distending the sinusoids and venules; (iv) *neonatal giant cell hepatitis-like* pattern characterized by extensive giant cell transformation of hepatocytes with prominent *architectural disarray*; (v) increased hepatic hemosiderosis along with marked hyperferritinemia and features of acute liver failure mimicking *neonatal hemochromatosis*; (vi) post stem cell transplantation graft

Sl.no, age, gender	C/F as per HLH-2004	Architecture disarray (present/absent); Inflammation: location, nature, Pattern, necrosis, hemosiderosis	Cholestasis/ steatosis	Lymphocyte mediated bile duct injury; nature of inflammation	Sinusoid(dilatation/ inflammation	Kupffer cell (number/ hemosiderosis	Hp	Venules (endothelialitis)	Outcome
1. 12d, M	All	Present; Severe, lobular >> portal, <i>Giant cell hepatitis like</i> , spotty necrosis	++/x	++; <i>Giant cell hepatitis like</i> ; CD8/ Gr. B/Perforin+ T cell	Yes/LH type	↑/x	+++	Yes	Death
2. 7m, M	All	Absent; Moderate to severe, centrilobular hepatitis, <i>chronic active GVHD</i>	++/x	+, fibrosis, Perforin+ T cells	Yes/lymphocytic	↑/+	Mild	No	Death
3. 16d, M	All	Present; lobular >> portal, <i>Giant cell hepatitis like</i> , increased iron in hepatocytes (+++) <i>mimicking neonatal hemochromatosis</i>	++/x	++, <i>Giant cell hepatitis like</i> ; CD8+/Perforin– T cells	Yes/LH type	↑/+++	+++	Yes	Death
4. 25d, -	ALF	Absent; Portal >> lobules; centrilobular necrosis	+++	+++, <i>leukemia like</i> , CD8/Gr. B/ Perforin+	Yes/dense lymphocytic	↑/x	+++	Yes, Congestion	
5. 2m, M	ARF	Absent; Portal >> lobules	+ / ++	+++; <i>chronic persistent hepatitis like</i> , CD8/Gr B/ Perforin+ T cells	Yes/lymphocytic	↑/+	+++	Yes	Death
6.2m, F	All	Absent; Portal >> lobules	+ / ++	+++; <i>leukemia like</i> ; Perforin+ T cells	Yes/LH type	↑/+	++	Yes	Alive



Sl.no, age, gender	C/F as per HLH-2004	Architecture disarray (present/absent); Inflammation: location, nature, Pattern, necrosis, hemosiderosis	Cholestasis/ steatosis	Lymphocyte mediated bile duct injury; nature of inflammation	Sinusoid(dilatation/ inflammation	Kupffer cell (number/ hemosiderosis	Hp	Venules (endothelialitis)	Outcome
7. 2m, M	All	Absent; Portal >> lobules, hemosiderosis (+)	++/x	+++; <i>leukemia like</i> ; CD8/Gr B/ Perforin+ T cells	Yes/LH type	↑/+	+	Yes	Death
8. 3m, M	All	Absent; lobular >> portal, <i>chronic hepatitis like</i>	+++/+	+; <i>chronic persistent hepatitis like</i> ; CD8/ Gr B+/Perforin– T cells	Yes/LH type	↑/++	+	Yes	Death
9. 3m, M	ALF	Absent; Portal>>lobular, hepatic siderosis (+++)	++/+	+++; <i>leukemia like</i> , CD8/Gr B+/ Perforin+ T cells	Yes/leukemia like	↑/+	+++	Yes	Death
10. 3m, M	Sibling	Absent; Portal>>lobular	++/x	+++; <i>leukemia like</i> , CD8/Gr B+/ Perforin+ T cells	Yes/LH type	↑/x	+++	ND	Death
11. 3m, M	All	Present, Lobular>>portal; <i>Giant cell hepatitis</i>	+/+	++, CD8/Gr B+/ Perforin+ T cells	Yes/LH type	↑/x	+++	Yes	Death
12. 3m, F	All	Present; Portal>>lobular; <i>Giant cell hepatitis like pattern</i>	+/+	++, <i>chronic persistent hepatitis like</i> CD8/Gr B+/ Perforin+ T cells	Yes/LH type	↑/x	+++	Yes	
13. 3m, M	All, consanguinity	Absent; Portal>>lobular	+/x	+++; <i>Leukemia like</i> , CD8/Gr B+/ Perforin+ T cells	Yes/LH type	↑/x	+++	Yes	Death

Sl.no, age, gender	C/F as per HLH-2004	Architecture disarray (present/absent); Inflammation: location, nature, Pattern, necrosis, hemosiderosis	Cholestasis/ steatosis	Lymphocyte mediated bile duct injury; nature of inflammation	Sinusoid(dilatation/ inflammation	Kupffer cell (number/ hemosiderosis	Hp	Venules (endothelialitis)	Outcome
14. 3m, M	All	Absent; Portal>>lobular; <i>chronic hepatitis like</i>	+/x	++, <i>chronic persistent hepatitis like</i> , CD8/Gr B+/ Perforin+ T cells	Yes/LH type	↑/x	+++	Yes	Death
15. 4m, M	Sibling	Absent, Portal>>lobular; chronic hepatitis like	+/x	+++, <i>Leukemia like</i> , CD8/Gr B+/ Perforin+ T cells	Yes/LH type	↑/x	+++	Yes	Death
16. 8m, F	ALF	Absent, centrilobular hemorrhage, atrophy of hepatic cords	++/++	++, <i>Storage histiocytic like</i> , CD8/Gr B+/ Perforin+ T cells, perivenous fibrosis	Yes/histiocytic infiltrate like storage cells	↑/++	+++	Yes	Death
17. 8m, M	All, HCV positive	Absent, portal>>lobular, hepatic hemosiderosis (+++)	++/+	+++; <i>leukemia like</i> , CD8/Gr B+/ Perforin+ T cells	Yes/LH type	↑/++	+++	Yes	Lost to follow-up
18. 9m, M	All	Absent, portal>>lobular	+/+	++; <i>chronic persistent hepatitis like</i> , CD8/Gr B+/ Perforin+ T cells	Yes/LH type	↑/++	+++	Yes	Death
19. 11m, F	All	Absent, portal>>lobular	++/++	+++; <i>leukemia like</i> , CD8/Gr B+/ Perforin+ T cells	Yes/LH type	↑/+	+++	Yes	Death

Sl.no, age, gender	C/F as per HLH-2004	Architecture disarray (present/absent); Inflammation: location, nature, Pattern, necrosis, hemosiderosis	Cholestasis/ steatosis	Lymphocyte mediated bile duct injury; nature of inflammation	Sinusoid(dilatation/ inflammation	Kupffer cell (number/ hemosiderosis	Hp	Venules (endothelialitis)	Outcome
27. children	1 <sup>o</sup> HLH (11 M, 16 F)	Absent; portal >>> lobular	Not described	++ to +++, <i>chronic persistent hepatitis like (characteristic)</i>	Yes/LH type	↑/x	+	Not studied	Autopsy series [8]
30. adults	2 <sup>o</sup> HLH (19 M, 11 F) ALF like in 19/29	Absent; portal >>> lobular; hepatocyte necrosis (focal in 10; diffuse in 4), siderosis in 11	++/++	++ to +++; LH type to tumoral infiltration, no ductular proliferation or damage or ductopenia, <i>no Hp in portal area</i>	Yes/LH type, erythrophagocytosis	↑/++	++/+++	Not described	Ref. [9]

Footnotes: d; days, m; months, M; male, F; female, C/F; clinical feature, ALF; acute liver failure, ARF; acute renal failure, GVHD; graft versus host disease, +; mild/inconspicuous, ++; moderate, +++; marked, x; not present, Gr. B; granzyme B, LH; lymphohistiocytic, ↑; increase in number, ND; not described, Hp; hemophagocytosis.

**Table 4.**  
Histopathology of liver in cases with hemophagocytic lymphohistiocytosis as described in several series (Chen et al. [10], n = 19; Ost et al. [8], n = 27; de Kerguenec et al. [9], n = 30).

*versus host disease related changes; (vii) lymphocyte depleted morphology unrelated to prior immunosuppressive or immunomodulator therapy; especially later in the course of the disease or as a part of aberrant cytokine modulation [10].*

Common to all specimens and helpful in diagnosing HLH are a constellation of *additional* features that included distinctive lymphocyte-mediated bile duct injury, significant endothelialitis of terminal portal and central veins, sinusoidal congestion and dilatation, increased Kupffer cell activity with or without hemosiderosis, erythrophagocytosis, and histiocytic hemophagocytosis which is reported as inconspicuous to florid. Steatosis and cholestasis were also usually present [8–10]. The *lymphocyte-mediated bile duct injury* is characterized by nests or circumferential sheaths of lymphomononuclear cells interposed between the epithelium and the basal lamina eliciting *little damage* to the epithelium. The portal inflammation with cholangitis observed in FHL is reminiscent of primary sclerosing cholangitis, primary biliary cirrhosis, and vanishing bile duct syndrome; though neutrophils, plasma cells, granulomatous inflammation, periductal sclerosis, or ductopenia common in latter conditions are reported to be rare in HLH cases [10]. *Endothelialitis* of terminal hepatic and portal veins may result in transmural phlebitis and hemorrhage and extensive apoptosis of perivenular hepatocytes. The degree of inflammation, bile duct damage, endothelialitis, cholestasis, and steatosis seem to reflect the clinical stage of the disease.

## 7. Liver transplantation: current concept and controversies

The mortality rate is very high in HLH associated acute liver failure cases. However, this association is extremely rare. Moreover, the presence of two clinical conditions (HLH and acute liver failure) together makes its further complicated and delays the diagnosis. The average time from earliest diagnosis of liver failure to a definitive diagnosis of HLH has been reported to be 17.27 days [23]. This suggests that HLH is a late occurring phenomenon in the process of ALF. On the contrary, there are reports which support the viewpoint of HLH causing liver injury and thus culminating in ALF [24, 25]. The exact mechanism is still not known, as far as HLH induced liver injury is concerned. It is most probably the infiltration of activated macrophage or over production of cytokine in HLH can explain the degree of liver injury. In a clinical scenario, where the patient present with prolonged fever, jaundice and pancytopenia; HLH should be considered as a differential diagnosis [23]. The role of liver transplantation in the treatment of HLH – ALF is controversial. It is so, because of the primarily systemic nature of the disease, the risk of hepatic recurrence of HLH during the post-transplant period, increased in rejection rate and poor general condition of the patient to tolerate the transplant procedure [26]. The post-transplant survival at the end of 6 months is only 33% for the primary HLH – ALF patient [27]. However, a small clinical series involving nine pediatric patients, reported a better survival rate among the secondary HLH – ALF group [26].

In the secondary form of HLH, the liver transplantation is also not very helpful in the situation such as absence of ALF (MELD score < 20–22); when the clinical severity is due to the combined effect of ALF and HLH, rather than ALF alone; and when the HLH is severe and highly likely to be irreversible. In these situations, high mortality from advanced and likely irreversible HLH may limit the benefits of liver transplantation [28]. Liver biopsy should be performed to decide the extent of the liver injury and the role played by the hepatic injury vs. systemic HLH in the patients with ALF. However, liver transplant is still an option in HLH – ALF cases with predominant liver involvement from HLH and this should be undertaken before the highly lethal complication of HLH, such as, septic shock, DIC, bone marrow failure, explosive immune activation from HLH supervenes.

IntechOpen

## Author details

Somanath Padhi<sup>1\*</sup>, RajLaxmi Sarangi<sup>2</sup>, Susama Patra<sup>1</sup> and Subash Chandra Samal<sup>3</sup>

<sup>1</sup> Department of Pathology with Laboratory Medicine, All India Institute of Medical Sciences, Bhubaneswar, India

<sup>2</sup> Department of Biochemistry, Kalinga Institute of Medical Sciences, Bhubaneswar, India

<sup>3</sup> Department of Gastroenterology, All India Institute of Medical Sciences, Bhubaneswar, India

\*Address all correspondence to: [patol\\_somanath@aiimsbhubaneswar.edu.in](mailto:patol_somanath@aiimsbhubaneswar.edu.in)

## IntechOpen

© 2019 The Author(s). Licensee IntechOpen. This chapter is distributed under the terms of the Creative Commons Attribution License (<http://creativecommons.org/licenses/by/3.0>), which permits unrestricted use, distribution, and reproduction in any medium, provided the original work is properly cited. 



## References

- [1] Rosado FGN, Kim AS. Hemophagocytic lymphohistiocytosis: An update on diagnosis and pathogenesis. *American Journal of Clinical Pathology*. 2013;**139**:713-727. DOI: 10.1309/AJCP4ZDKJ4ICOUAT
- [2] Janka GE. Familial and acquired hemophagocytic lymphohistiocytosis. *Annual Review of Medicine*. 2012;**63**:233-246. DOI: 10.1146/annurev-med-041610-134208
- [3] Hayden A, Park S, Giustini D, Lee AY, Chen LY. Hemophagocytic syndromes (HPSs) including hemophagocytic lymphohistiocytosis (HLH) in adults: A systematic scoping review. *Blood Reviews*. 2016;**30**:411-420. DOI: 10.1016/j.blre.2016.05.001
- [4] Henter JI, Horne A, Aricó M, Egeler RM, Filipovich AH, Imashuku S, et al. HLH-2004: Diagnostic and therapeutic guidelines for hemophagocytic lymphohistiocytosis. *Pediatric Blood & Cancer*. 2007;**48**:124-131. DOI: 10.1002/pbc.21039
- [5] Filipovich AH. Hemophagocytic lymphohistiocytosis (HLH) and related disorders. *Hematology. American Society of Hematology. Education Program*. 2009;**2009**:127-131. DOI: 10.1182/asheducation-2009.1.127
- [6] Fardet L, Galicier L, Lambotte O, Marzac C, Aumont C, Chahwan D, et al. Development and validation of the HScore, a score for the diagnosis of reactive hemophagocytic syndrome. *Arthritis & Rheumatology*. 2014;**66**:2613-2620. DOI: 10.1002/art.38690
- [7] Favara BE. Histopathology of the liver in histiocytosis syndromes. *Pediatric Pathology & Laboratory Medicine*. 1996;**16**:413-433. DOI: 10.1080/15513819609168681
- [8] Ost A, Nilsson-Ardnor S, Henter JI. Autopsy findings in 27 children with haemophagocytic lymphohistiocytosis. *Histopathology*. 1998;**32**:310-316. DOI: 10.1046/j.1365-2559.1998.00377.x
- [9] de Kerguenec C, Hillaire S, Molinié V, Gardin C, Degott C, Erlinger S, et al. Hepatic manifestations of hemophagocytic syndrome: A study of 30 cases. *The American Journal of Gastroenterology*. 2001;**96**:852-857. DOI: 10.1111/j.1572-0241.2001.03632.x
- [10] Chen JH, Fleming MD, Pinkus GS, Pinkus JL, Nichols KE, Mo JQ, et al. Pathology of the liver in familial hemophagocytic lymphohistiocytosis. *The American Journal of Surgical Pathology*. 2010;**34**:852-867. DOI: 10.1097/PAS.0b013e3181dbbb17
- [11] Janka GE, Lehmborg K. Hemophagocytic lymphohistiocytosis: Pathogenesis and treatment. *Hematology*. 2013;**2013**:605-611. DOI: 10.1182/asheducation-2013.1.605
- [12] Gholam C, Grigoriadou S, Gilmour KC, Gaspar HB. Familial haemophagocytic lymphohistiocytosis: Advances in the genetic basis, diagnosis and management. *Clinical and Experimental Immunology*. 2011;**163**:271-283. DOI: 10.1111/j.1365-2249.2010.04302.x
- [13] Padhi S, Varghese RG, Ramdas A, Phansalkar MD, Sarangi R. Hemophagocytic lymphohistiocytosis: Critical reappraisal of a potentially under-recognized condition. *Frontiers in Medicine*. 2013;**7**:492-498. DOI: 10.1007/s11684-013-0292-0
- [14] Tamamyian GN, Kantarjian HM, Ning J, Jain P, Sasaki K, McClain KL, et al. Malignancy-associated hemophagocytic lymphohistiocytosis in adults: Relation to hemophagocytosis, characteristics, and outcomes. *Cancer*.

2016;**122**:2857-2866. DOI: 10.1002/cncr.30084

[15] Allen CE, Yu X, Kozinetz CA, McClain KL. Highly elevated ferritin levels and the diagnosis of hemophagocytic lymphohistiocytosis. *Pediatric Blood & Cancer*. 2008;**50**:1227-1235. DOI: 10.1002/pbc.21423

[16] Schram AM, Campigotto F, Mullally A, Fogerty A, Massarotti E, Neuberg D, et al. Marked hyperferritinemia does not predict for HLH in the adult population. *Blood*. 2015;**125**:1548-1552. DOI: 10.1182/blood-2014-10-602607

[17] Lachmann G, Spies C, Schenk T, Brunkhorst FM, Balzer F, La Rosée P, et al. Hemophagocytic lymphohistiocytosis: Potentially underdiagnosed in intensive care units. *Shock*. 2018;**50**:149-155. DOI: 10.1097/SHK.0000000000001048

[18] Sackett K, Cunderlik M, Sahni N, Killeen AA, Olson AP. Extreme hyperferritinemia: Causes and impact on diagnostic reasoning. *American Journal of Clinical Pathology*. 2016;**145**:646-650. DOI: 10.1093/ajcp/aqw053

[19] Tsuji T, Hirano T, Yamasaki H, Tsuji M, Tsuda H. A high sIL-2R/ferritin ratio is a useful marker for the diagnosis of lymphoma-associated hemophagocytic syndrome. *Annals of Hematology*. 2014;**93**:821-826. DOI: 10.1007/s00277-013-1925-8

[20] Janka G. Hemophagocytic lymphohistiocytosis: When the immune system runs amok. *Klinische Pädiatrie*. 2009;**22**:278-285. DOI: 10.1055/s-0029-1237386

[21] Billiau AD, Roskams T, Van Damme-Lombaerts R, Matthys P, Wouters C. Macrophage activation syndrome: Characteristic findings on liver biopsy illustrating the key role

of activated, IFN-gamma-producing lymphocytes and IL-6- and TNF-alpha-producing macrophages. *Blood*. 2005;**105**:1648-1651. DOI: 10.1182/blood-2004-08-2997

[22] Kapelari K, Fruehwirth M, Heitger A, Königsrainer A, Margreiter R, Simma B, et al. Loss of intrahepatic bile ducts: An important feature of familial hemophagocytic lymphohistiocytosis. *Virchows Archiv*. 2005;**446**:619-625. DOI: 10.1007/s00428-005-1238-y

[23] Dong J, Xie F, Jia L, Li J, Hu Z, Zhu Y, et al. Clinical characteristics of liver failure with hemophagocytic lymphohistiocytosis. *Scientific Reports*. 2019;**9**:8125. DOI: 10.1038/s41598-019-43909-w

[24] Jagtap N, Sharma M, Rajesh G, Rao PN, Anuradha S, Tandan M, et al. Hemophagocytic lymphohistiocytosis masquerading as acute liver failure: A single center experience. *Journal of Clinical and Experimental Hepatology*. 2017;**7**:184-189. DOI: 10.1016/j.jceh.2017.01

[25] Lin S, Li Y, Long J, Liu Q, Yang F, He Y. Acute liver failure caused by hemophagocytic lymphohistiocytosis in adults: A case report and review of the literature. *Medicine (Baltimore)*. 2016;**95**:e5431. DOI: 10.1097/MD.0000000000005431

[26] Amir AZ, Ling SC, Naqvi A, Weitzman S, Fecteau A, Grant D, et al. Liver transplantation for children with acute liver failure associated with secondary hemophagocytic lymphohistiocytosis. *Liver Transplantation*. 2016;**22**:1245-1253. DOI: 10.1002/lt.24485

[27] Guthery SL, Heubi JE. Liver involvement in childhood histiocytic syndromes. *Current Opinion in Gastroenterology*. 2001;**17**:474-478

[28] Capel MS, Hader I, Amin M. Acute liver failure secondary to severe systemic disease from fatal hemophagocytic lymphohistiocytosis: Case report and systematic literature review. *World Journal of Hepatology*. 2018;**10**:629-636. DOI: 10.4254/wjh.v10.i9.629

IntechOpen

IntechOpen