

We are IntechOpen, the world's leading publisher of Open Access books Built by scientists, for scientists

6,900

Open access books available

185,000

International authors and editors

200M

Downloads

Our authors are among the

154

Countries delivered to

TOP 1%

most cited scientists

12.2%

Contributors from top 500 universities



WEB OF SCIENCE™

Selection of our books indexed in the Book Citation Index
in Web of Science™ Core Collection (BKCI)

Interested in publishing with us?
Contact book.department@intechopen.com

Numbers displayed above are based on latest data collected.
For more information visit www.intechopen.com



Nasal Cavity Hemangiomas

Ahmet Baki

Abstract

Hemangiomas are benign tumors originating from vascular structures in the body. Although it is common in the head and neck region, it is rarely seen in the nasal cavity and paranasal sinuses. Histologically, there are three types of hemangiomas including capillary, cavernous, and mixed types, the most common being a cavernous hemangioma. Cavernous hemangiomas in the nasal cavity usually originate from the lateral nasal wall and cause symptoms such as nasal congestion and nosebleeds.

Keywords: hemangioma, nasal septum, paranasal sinus

1. Introduction

Vascular lesions in the head and neck region originate from blood vessels or lymphatics [1].

While the terminology used to describe vascular lesions was related to the clinical appearance of the lesions rather than their physiopathological development, the first distinction that formed the basis of today's classification was made by Mulliken and Glowacki in 1982 according to the clinical and histochemical findings and cell types [2].

Nasal hemangioma was first described by Poncet and Dor in 1897 as human botryomycosis. More than half of the hemangioma affects the head and neck region, rarely the nasopharynx. Therefore it is safe to presume that hemangioma in the nasal region is a rare disease [3].

2. Hemangiomas

Hemangiomas are common, benign endothelial lesions of the skin and mucous membranes. Hemangiomas have capillary, cavernous, mixed, and hypertrophic subtypes. Capillary hemangioma is the most common subtype and is mostly seen on anterior septal cartilage. Capillary hemangioma is seen mostly in the first years of life and may show spontaneous regression (**Figure 1**) [4, 6].

Cavernous hemangioma is seen mostly in adulthood, and traumatic etiology is present. Cavernous hemangioma is rare and seen in the bone septum or lateral nasal wall. On macroscopic examination, hemangiomas can be observed to have a polypoid, smooth surface and a lobed pattern, whereas in the microscopic examination, it consists of capillaries covered with flat epithelium separated by collagen stroma. Cavernous hemangioma shows large proliferation of thin-walled blood vessels of various sizes covered with endothelium, while the mixed endothelial vascular areas

form the large endothelium. These pathologies do not always differentiate from other forms of inflammatory pseudotumor (**Figure 2**) [5, 6].

Cavernous hemangiomas are uncommon in the paranasal sinuses and nose. It has been defined to originate from the inferior turbinate, vomer, lamina perpendicularis, and sinus maxillaris. Nasal mucosal hemangiomas ought to be distinguished from hemangiomas that originate from the maxilla or nasal bones which are primary osseous lesions, of which the symptoms and surgical approach are entirely different [7–12].

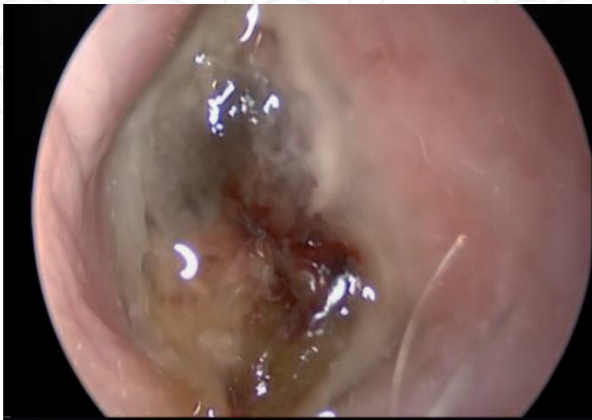

Figure 1.
Capillary Hemangioma of the Nasal Septum [5].

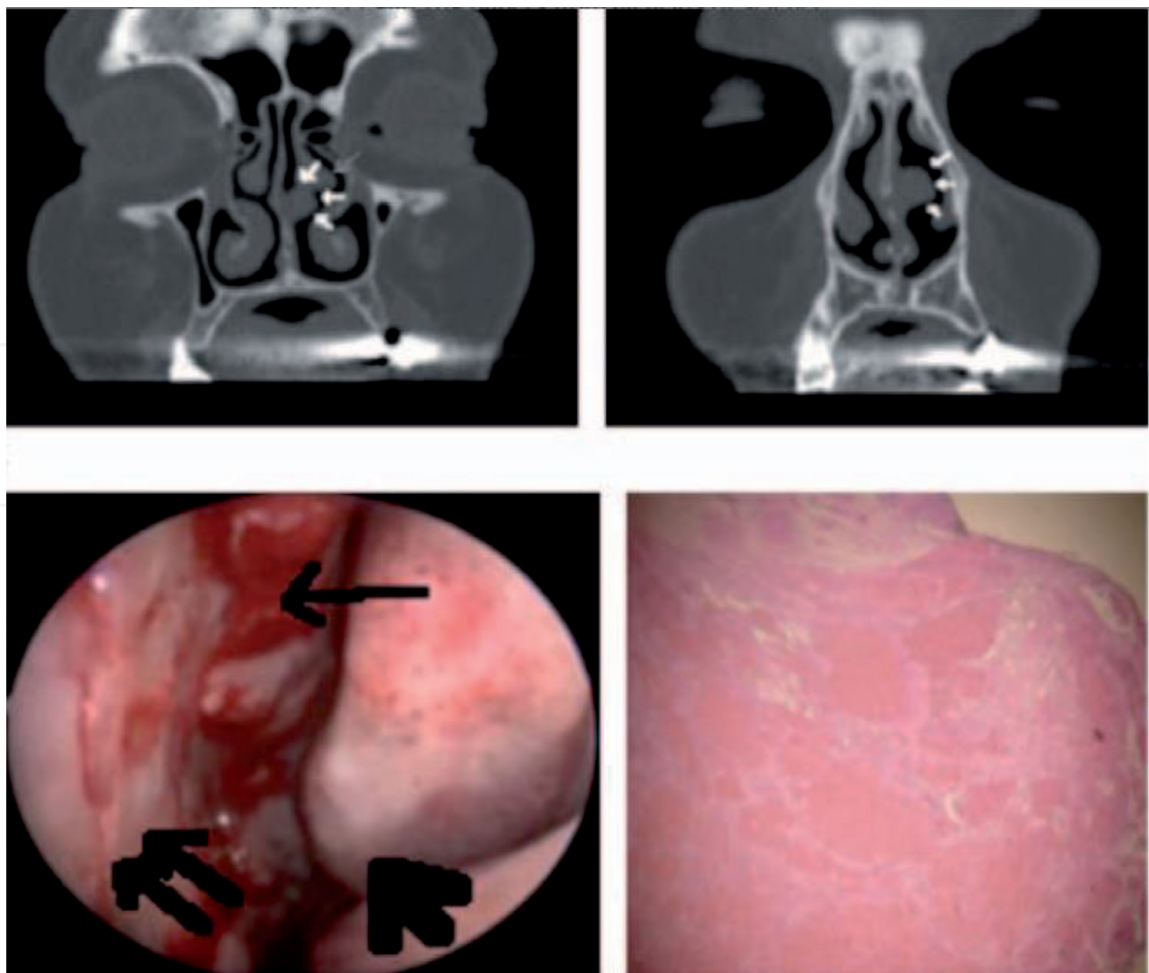


Figure 2.
Nasal septal cavernous hemangioma [6].

Although nasal hemangiomas common in the head and neck region, it is uncommonly seen in the nasal mucosa. In the nasal cavity, the most common cause is the septum and the lateral nasal wall [13].

Although nasal hemangiomas commonly affect the anterior septum as described in prior literature, nasal hemangioma has also been reported in other nasal sites such as middle turbinates, inferior turbinates, posterior part of the septum, and vestibule [14].

The most common symptom in hemangiomas located in the nasal cavity is nose bleeding; also other rare visible symptoms are nasal obstruction, runny nose, and epiphora [15]. Epistaxis and unilateral nasal obstruction were the most common presenting symptoms, followed by other nasal symptoms such as rhinorrhea. Epistaxis is the most common symptom, as demonstrated by previously published studies. In addition, extra nasal symptoms, such as facial pain and headache, are much less common [16].

In differential diagnosis, lymphangioma, venous hemangioma, angiofibroma, hemangioendothelioma, glomus tumor, and malignant nasal cavity tumors, metastatic malignancies, Wegener granulomatosis, angiofibroma, and sinonasal papilloma should be kept in mind [3, 17].

The diagnosis of cavernous hemangioma can be made based on the patient's history and clinical features of the lesion. Cavernous hemangiomas are tumors composed of vascular ectasia. They can be placed deeper in the skin, and mucous membranes additionally can involve deeper structures such as subcutaneous tissue, muscle, and bone. Hemangiomas may be localized in an area or may be common. All midline lesions such as subcutaneous cavernous hemangioma, nasal gliomas, meningocele or meningoencephaloceles, teratomas, sebaceous cysts, dermoid cysts, and fibromas, which have atypical clinical features in the nasal dorsum, should be differentiated [18].

Imaging tests such as ultrasonography (USG), computed tomography (CT), or magnetic resonance imaging (MRI) are needed to confirm vascular pathology and to demonstrate venous, arterial, or lymphatic components and whether deeper structures are involved. CT can be performed to exclude bone erosion or possible malignant transformations.

According to some authors, MRI is more effective in evaluating the connection with soft tissue and intracranial. Also, there is no radiation exposure. MRI is the first diagnostic tool that should be used for screening in patients with midline nasal mass. Negative results on imaging studies, even with contrast, do not exclude the intracranial communication. Phlebitis is typical for cavernous hemangiomas. Hypointense on T1-weighted images on MRI and hyperintense on T2 indicate the absence of coagulated blood [14, 19–22].

According to their histopathological appearance, it is possible to examine them as cavernous and capillary hemangiomas. They generally occur on the skin, and on the mucosal surfaces of the body, capillary hemangioma is a capillary ball that is located close to each other, separated by a connective tissue stroma [23]. Cavernous hemangiomas should be treated because they will never undergo involution [24].

3. Conclusion

Hemangiomas should be treated because they have the potential to cause bleeding problems and complications such as infection in the head and neck, especially in the face, ear, and nose. Agents such as steroids, interferon, and vincristine may be used in the medical treatment of hemangiomas. The use of these agents is limited due to the large number of serious toxic side effects. Propranolol, which is

a nonselective beta blocker, was first introduced by Leaute-Lebeze, and it has been reported that it can be used safely in many later studies [25, 26].

Surgical excision is the treatment of choice for the treatment of nasal hemangiomas. Various surgical methods can be employed for this lesion such as excisional surgery, laser ablation, cryotherapy, and electrocoagulation. Surgical excision is a key for confirmation via histological examination and should be and remains the mode of choice of treatment for nasal hemangiomas. Surgical operation of cavernous hemangioma depends on the nature and localization of the lesion, but it should not cause functional and esthetic problems. All the patients can be successfully treated with adequate endoscopic surgical excision from the site of origin and no complications. Endoscopic resection of midline nasal tumors without intracranial extension can be performed because external approaches cause postoperative esthetic problems. Tumor resection can be removed endoscopically, leaving a safe margin. Endoscopic technique provides better esthetic results. Sclerotherapy and laser are commonly used treatment modalities. Embolization with super-selective arteriography can be used in cases with arterial component or arteriovenous fistula [14, 18, 24].

Midline elliptical incision has good functional outcomes and maintains the nasal contours, although the surgical technique for these lesion outcomes marked a scar on the midline. Treated with inferior rhinotomy and achieved excellent results [27, 28].

Lesions in the nasal type region are easily accessible after incision where transcolumellar and alar rim incisions are combined, but it is difficult to reach larger and more complex lesions because the incision does not extend cranially [29]. A central wedge excision with vertical closure, removing excess skin, leads to a marked scar on the tip of the nose and columella, and as a result, it is recommended to avoid this wedge excision if possible [30].

Open rhinoplasty approach, and put forward that the extra skin will not be removed but rather left in place to let for contraction, which may take many months. In this approach, the excess skin remaining after the treatment of hemangioma can be considered as a disadvantage [31].


Author details

Ahmet Baki

Otorhinolaryngology Clinic, Uskudar State Hospital, Istanbul, Turkey

*Address all correspondence to: dr.ahmet170@gmail.com

IntechOpen

© 2020 The Author(s). Licensee IntechOpen. This chapter is distributed under the terms of the Creative Commons Attribution License (<http://creativecommons.org/licenses/by/3.0>), which permits unrestricted use, distribution, and reproduction in any medium, provided the original work is properly cited. 

References

- [1] Puttgen KB, Pearl M, Tekes A, Mitchell SE. Update on pediatric extracranial vascular anomalies of the head and neck. *Child's Nervous System*. 2010;**26**(10):1417-1433
- [2] Mulliken JB, Glowacki J. Hemangiomas and vascular malformations in infants and children: A classification based on endothelial characteristics. *Plastic and Reconstructive Surgery*. 1982;**69**:412-422
- [3] Chi TH, Yuan CH, Chien ST. Lobular capillary hemangioma of the nasal cavity: A retrospective study of 15 cases in Taiwan. *Balkan Medical Journal*. 2014;**31**(1):69-71. DOI: 10.5152/balkanmedj.2014.13178
- [4] Journal of Medical Case Reports. Elmer Press Inc. ISSN: 1923-4155 print, 1923-4163 online, Open Access; Journal website: <http://www.journalmc.org>
- [5] Journal of Craniofacial Surgery. Mar 2018;**29**(2):e135-e136. DOI: 10.1097/SCS.00000000000004220
- [6] Kodama S, Yoshida K, Nomi N, Fujita K, Suzuki M. Successful treatment of nasal septum hemangioma with the harmonic scalpel: A case report. *Auris, Nasus, Larynx*. 2006;**33**(4):475-478
- [7] Kim HJ, Kim JH, Kim JH, Hwang EG. Bone erosion caused by sinonasal cavernous hemangioma: CT findings in two patients. *American Journal of Neuroradiology*. 1995;**16**:1176-1178
- [8] Hayden RE, Luna M, Goepfert H. Hemangiomas of the sphenoid sinus. *Otolaryngology and Head and Neck Surgery*. 1980;**88**:136-138
- [9] Nakahira M, Kishimoto S, Miura T, Saito H. Intraosseous hemangioma of the vomer: A case report. *American Journal of Rhinology*. 1997;**11**:473-477
- [10] Graumüller S, Terpe H, Hingst V, Dommerich S, Pau HW. Intraossäres Hämangiom der Lamina perpendicularis ossis ethmoidalis. *HNO*. 2003;**5**:142-145
- [11] Engels T, Schörner W, Felix R, Witt H, Jahnke V, Kavernöses Hämangiom d. Sinus maxillaris. *HNO*. 1990;**38**:342-344
- [12] Osborn DA. Hemangiomas of the nose. *The Journal of Laryngology and Otology*. 1959;**73**:174-179
- [13] Çaylaklı F, Çagici AC, Hürcan C, Bal N, Kizilkiliç O, Kiroglu FMD. Cavernous hemangioma of the middle turbinate: A case report. *Ear, Nose, & Throat Journal*. 2008;**87**(7):391-393
- [14] Puxeddu R, Berlucchi M, Ledda GP, Parodo G, Farina D, Nicolai P. Lobular capillary hemangioma of the nasal cavity: A retrospective study on 40 patients. *American Journal of Rhinology*. 2006;**20**(4):480-484
- [15] Işılai D, Fuat B. Nazal Septumda Pyojenik Granülom: Olgu Sunumu. *Acıbadem Üniversitesi Sağlık Bilimleri Dergisi*. 2011;**2**(1):8
- [16] Fasunla AJ, Adebola OS, Okolo CA, Adeosun AA. Nasal septal lobular capillary haemangioma in West Africa sub-region: A case report. *Cases Journal*. 2009;**8**, 2:8952
- [17] Batsakis JG. Tumors of the head and neck. In: *Clinical and Pathological Considerations*. 2nd ed. Baltimore, MD: Williams & Wilkins; 1979. pp. 291-312
- [18] Harley EH. Pediatric congenital nasal masses. *Ear, Nose, & Throat Journal*. 1991;**70**:28-32
- [19] Reilly JR, Koopman CF, Cotton R. Nasal mass in a pediatric patient. *Head & Neck*. 1992;**14**:415-418

- [20] Lusk RP, Lee PC. Magnetic resonance imaging of congenital midline nasal masses. *Otolaryngology and Head and Neck Surgery*. 1986;**95** (3 Pt 1):303-306
- [21] Barkovich AJ, Vandermarck P, Edwards MS, Cogen PH. Congenital nasal masses: CT and MR imaging features in 16 cases. *AJNR. American Journal of Neuroradiology*. 1991;**12**:105-116
- [22] Itoh K, Nishimura K, Togashi K, Fujisawa I, Nakano Y, Itoh H, et al. RM imaging of cavernous hemangioma of face and neck. *Journal of Computer Assisted Tomography*. 1986;**10**:831-835
- [23] Chawla OP, Oswal VH. Hemangiopericytoma of the nose and paranasal sinuses. *The Journal of Laryngology and Otology*. 1987;**101**:729-737
- [24] Yokoyama M, Inouye N, Mizuno F. Endoscopic management of nasal glioma in infancy. *International Journal of Pediatric Otorhinolaryngology*. 1999;**51**:51-54
- [25] Evans SE. İnfantil Hemanjiyomlar. *Türk Derm*. 2011;**45**:133-137
- [26] Hsu TC, Wang JD, Chen CH, Chang TK, Wang TM, Chou CM, et al. Treatment with propranolol for infantile hemangioma in 13 Taiwanese newborns and young infants. *Pediatrics and Neonatology*. 2012;**53**:125-132
- [27] Pitanguy I, Machado BH, Radwanski HN, Amorim NF. Surgical treatment of hemangiomas of the nose. *Annals of Plastic Surgery*. 1996;**36**(6):586-592
- [28] Demiri EC, Pelissier P, Genin-Etcheberry T, Tsakoniatis N, Martin D, Baudet J. Treatment of facial haemangiomas. *British Journal of Plastic Surgery*. 2001;**54**(8):665-674
- [29] Faguer K, Domp martin A, Labbé D, Barrellier MT, Leroy D, Theron J. Early surgical treatment of Cyrano-nose haemangiomas with Rethi incision. *British Journal of Plastic Surgery*. 2002;**55**(6):498-503
- [30] Mc Carthy JG, Borud LJ, Schreiber JS. Hemangiomas of the nasal tip. *Plastic and Reconstructive Surgery*. 2002;**109**(1):31-40
- [31] Jackson IT, Sosa J. Excision of nasal tip hemangioma via open rhinoplasty: A skin-sparing technique. *European Journal of Plastic Surgery*. 1998;**21**:265-268