

We are IntechOpen, the world's leading publisher of Open Access books Built by scientists, for scientists

6,900

Open access books available

185,000

International authors and editors

200M

Downloads

Our authors are among the

154

Countries delivered to

TOP 1%

most cited scientists

12.2%

Contributors from top 500 universities



WEB OF SCIENCE™

Selection of our books indexed in the Book Citation Index
in Web of Science™ Core Collection (BKCI)

Interested in publishing with us?
Contact book.department@intechopen.com

Numbers displayed above are based on latest data collected.
For more information visit www.intechopen.com



Bizarre Leiomyoma of the Uterus: Therapeutic Mapping

Chrisostomos Sofoudis

Abstract

Leiomyomas represent the most common type of benign tumors of the female genital tract. Assiduous preoperative imaging findings reflect proper therapeutic mapping. In cases of female patients of reproductive age, the ultimate goal remains the fertility preservation and the quality of life of the patient. According to recent bibliography, bizarre leiomyomas remain a controversial issue regarding the preoperative and postoperative therapeutic mapping. Giant cells with pleomorphic nuclei and little or no mitotic activity compose the microscopic analysis of such lesions. Multidisciplinary approach is mandatory in order to establish ultimate diagnosis and treatment. Bizarre leiomyomas still represent a gray scale among the whole scientific community.

Keywords: bizarre myomas, uterus, fertility preservation

1. Introduction

The incidence of uterine fibroid tumors increases as women grow older, and they may occur in more than 30% of women 40–60 years of age (**Figure 1**). Risk factors include null parity, obesity, family history, black race, and hypertension.

Many tumors are asymptomatic and may be diagnosed incidentally. Many studies have indicated the proper therapeutic mapping in cases of nulliparous young patients.

Therapeutic strategy is strongly accompanied with age and fertility capacity of the patient. In cases of degenerated uterine fibroids in nulliparous patients, laparoscopic approach represents the gold standard of surgical confrontation.

In reproductive age women, 15–30% of these tumors are responsible for menstrual disorders, anemia due to perfuse uterine bleeding, pelvic pain, pregnancy loss, rarely preterm birth, and percentage of infertility [1].

In order to establish a proper diagnosis and treatment, especially in women of reproductive age, there is a classification of uterine fibroids [2].

Major categories consist of submucosal, intramural, subserosal, and others (cervical, parasitic) (**Table 1**).

Many factors affect the therapeutic mapping of uterine myomas. Age of the patient, gynecologic or obstetrical history, previous surgical procedures and fertility preservation.

Uterine fibroids consist of smooth muscular tissue with always the possibility of malignant transformation. Tumor size and anatomic location are strongly accompanied with assiduous therapeutic strategy.

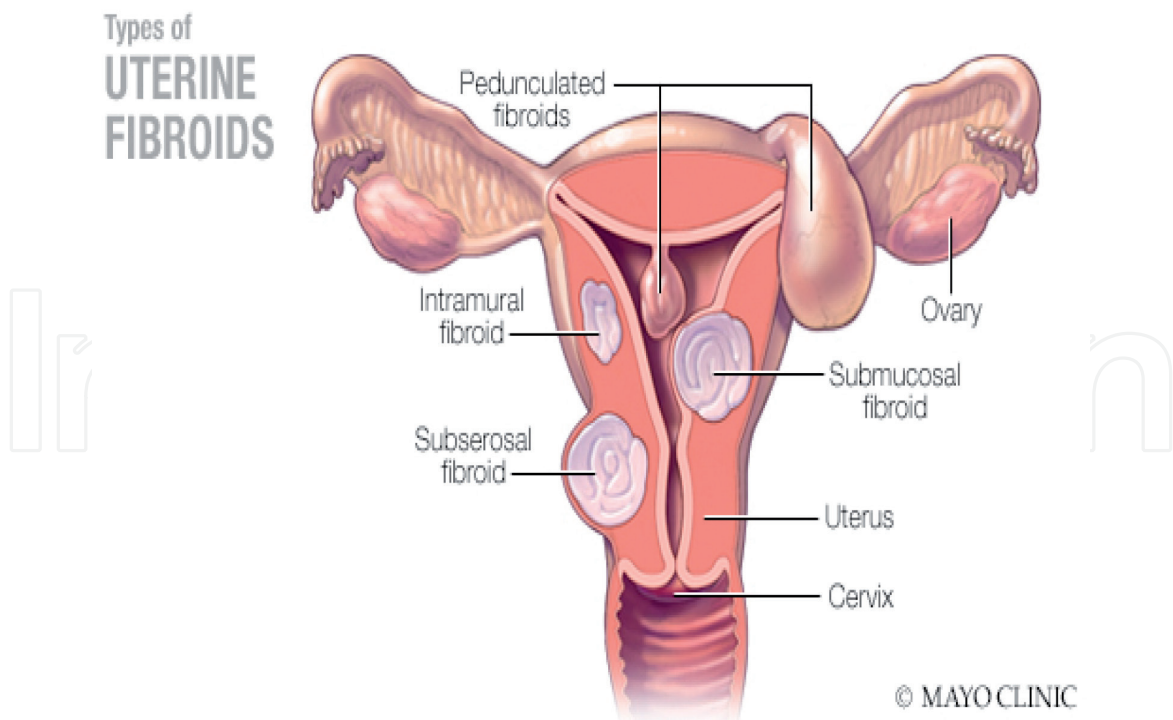


Figure 1. Uterine fibroids. *newsnetwork.mayoklinic.org*.

Polyp	Submucosal	Coagulopathy
Adenomyosis		Ovulatory dysfunction
Leiomyoma		Endometrial
Malignancy and hyperplasia		Iatrogenic
		Not yet classified

Leiomyoma subclassification system

Submucosal	0	Pedunculated intracavitary
	1	<50% intramural
	2	≥50% intramural
Other	3	Contacts endometrium; 100% intramural
	4	Intramural
	5	Subserosal ≥50% intramural
	6	Subserosal <50% intramural
	7	Subserosal pedunculated
	8	Other (specify e.g., cervical, parasitic)
Hybrid leiomyomas (impact both endometrium and serosa)	Two numbers are listed separated by a hyphen. By convention, the first refers to the relationship with the endometrium, while the second refers to the relationship to the serosa. One example below:	
	2-5	Submucosal and subserosal, each with less than half the diameters in the endometrial and peritoneal cavities, respectively

Medscape

Source: Women's Health © 2014 Future Medicine Ltd

Table 1. Classification of uterine fibroids. *Women's Health 2014. Future Medicine Ltd.*

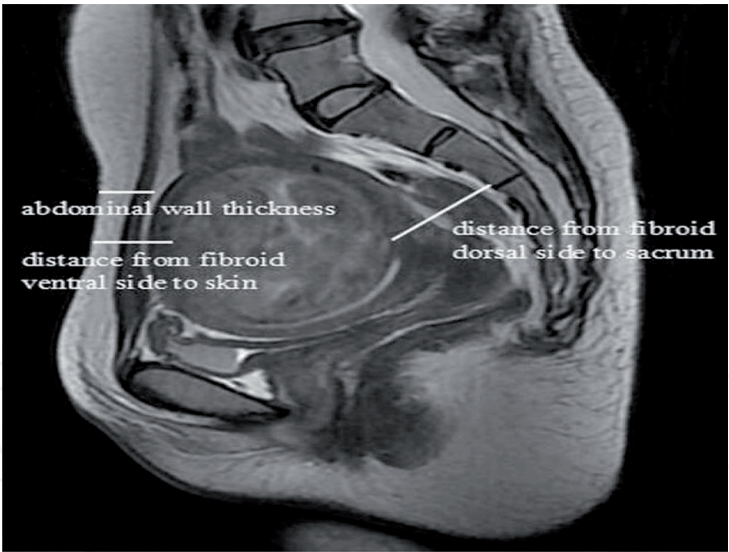


Figure 2.
Abdominal MRI with enlarged uterine fibroid depiction. Researchgate.net.

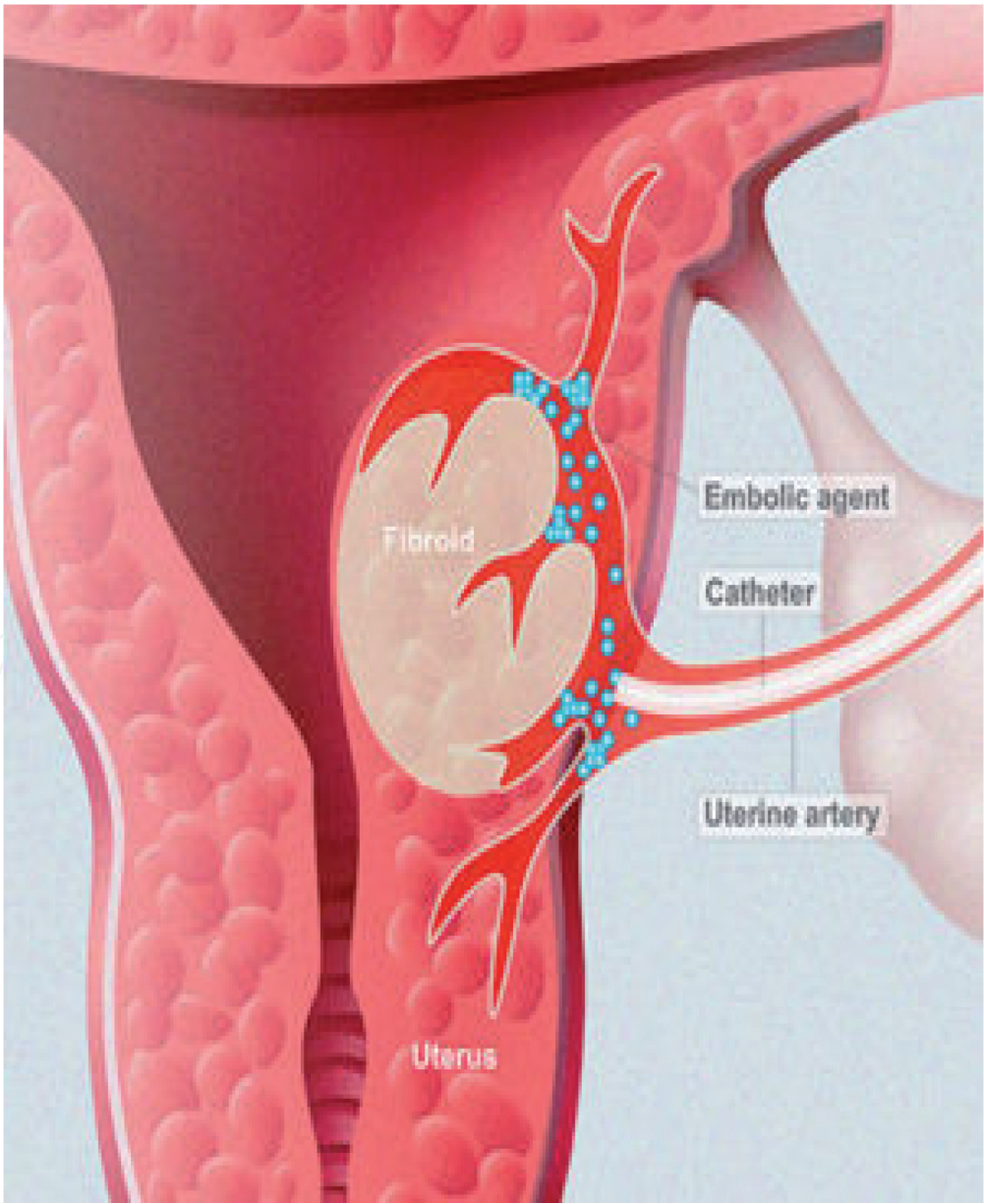


Figure 3.
Uterine fibroid embolization. Interventionalnews.com.

Transvaginal ultrasonography reflects the first preoperative procedure, depending on the physician's experience and technical sufficiency of the ultrasound machine.

Imaging findings as areas of cystic degeneration, enlarged and asymmetric vascularization, papillary protrusions, and possibly increased tumor markers as Ca-125/Ca 15-3/Ca 19-9 reveal preoperative procedures of malignant metaplasia [3].

In such cases, abdominal MRI can, without a doubt, guide the preoperative management [4] (**Figure 2**).

In order to avoid diffuse menorrhagia and procedures of diffuse intravascular coagulation, an appropriate solution consists of uterine fibroid embolization [5]. With the use of colloid substances, we can lead to fibroid necrosis and cell apoptosis (**Figure 3**).

There are cases after fibroid surgical dissection and abdominal or vaginal hysterectomy where the histopathologic evaluation confirms bizarre myomas. The dilemma is controversial especially in cases of female patients of reproductive age. The ultimate goal remains fertility preservation of such patients.

2. Discussion

All mentioned scientific guidelines reflect the pathway from general depictions of uterine anatomy and physiology to specific fibroid pathology.

Many authors complete their monograph concerning uterine fibroids. They described several tumors with similar macroscopic view as uterine fibroid, but microscopically they include large multinucleated tumor cells.

After WHO (World Health Organization) classification bizarre leiomyomas presented as fibroids with giant cells with pleomorphic nuclei and little or no mitotic activity [6].

In many cases they represent a histologic gray zone concerning the therapeutic mapping in female patients of reproductive age.

Before final diagnosis is established, assiduous examination of the specimen is mandatory focusing on terms of atypia or necrosis (simple, moderate, or severe).

Along with genetic predisposition and ovarian hormone stimulation, many growth factors are identified.

Besides genetic predisposition and ovarian hormones that play a major role in tumor expansion, a large number of growth factors have also been identified which favor expansion.

These are insulin-like growth factor (IGF), epidermal growth factor (EGF) and platelet-derived growth factor (PDGF), transforming growth factor beta (TGF beta), and basic fibroblast growth factor (BFGF) [7]. These may have a role to play in tumor expansion.

The major differential dilemma remains the establishment of bizarre uterine myomas versus endometrial stromal sarcoma (ESS) (**Figure 4**).

The main characteristics of ESS consist of infiltrative myometrium growth and vascular invasion, presence of necrotic areas, and mitotic activity [8].

Due to infiltration of the myometrial basal membrane, surgical dissection after staging of the lesion represents the gold standard. Multidisciplinary approach is mandatory in order to establish proper postoperative treatment.

In cases of metastatic ESS, neoadjuvant therapy or series of radiotherapy will understage the tumor expansion and make the tumor staging surgically feasible.

On the other hand, patients with positive progesterone or estrogen receptors (ER+, PR+), can be treated postoperatively with hormonal agents such as progestogens [9].

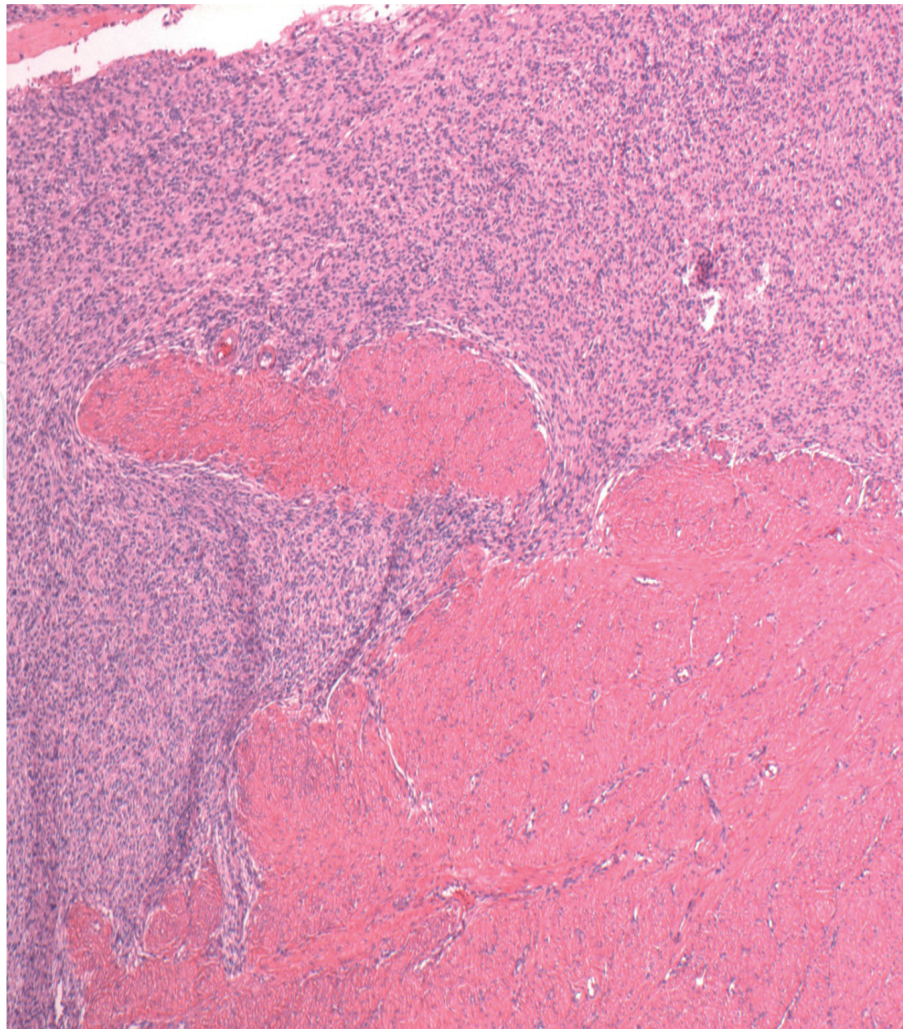


Figure 4.
Endometrial stromal sarcoma. H&E stain. Wikipedia.

Ki-67 as exceptional biomarker is strongly accompanied with proliferative activity and presence of necrotic areas. Many conducted studies have adjusted Ki-6 and successful postoperative management.

In primary stages of the lesion, fertility preservation in female patients of reproductive age remains a controversial dilemma [10].

The impact of bizarre leiomyoma on fertility is not well known. Bizarre leiomyoma consists of a rare entity composing pleomorphic or symplastic cells which require assiduous histopathologic evaluation.

If fertility preservation is not required, the standard surgical intervention for bizarre leiomyoma that shows a benign clinical course is a simple hysterectomy [11, 12].

Due to rare incidence of bizarre myomas, in cases of female patients of reproductive age with ultimate scope the fertility preservation, simple myomectomy as the gold standard remains a controversial issue.

Etiology concerning this issue depends on the identification difficulty during myomectomy between specimen surgical borders and myometrium. After histopathologic evaluation and not clear surgical margins, there is an increased incidence of tumor recurrence [13].

On the other hand, surgical treatment with dissection part of the associated myometrium, can lead in a future pregnancy, to spontaneously membrane rupture and episodes of preterm birth.

Precise scientific evaluation of current bibliography, focusing on optimal treatment in patients of reproductive age, reveals a lack of scientific guidelines.

The ultimate scope of the above presentation reflects the stimulus of completion and composition new conducted studies, which will guide assiduously and clear all controversial issues.

Bizarre uterine myomas, as rare entity, still represent a gray area among the whole scientific society.

3. Conclusion

Bizarre uterine fibroids represent a controversial scientific zone in the current bibliography. More studies must be conducted in order to establish proper diagnosis and treatment.

Multidisciplinary approach is mandatory in cases of patients of reproductive age. The ultimate goal remains in such cases, always fertility preservation.

Acknowledgements

Significant role to the completion of this book chapter, exploration and searching throughout medical data bases such as PubMed and Cochrane database.

Disclosure of interest


The author declares no financial procedure with respect to this manuscript.

Author details

Chrisostomos Sofoudis
Department of Obstetrics and Gynecology, Konstandopoulou General Hospital,
Athens, Greece

*Address all correspondence to: chrisostomos.sofoudis@gmail.com

IntechOpen

© 2019 The Author(s). Licensee IntechOpen. This chapter is distributed under the terms of the Creative Commons Attribution License (<http://creativecommons.org/licenses/by/3.0>), which permits unrestricted use, distribution, and reproduction in any medium, provided the original work is properly cited. 

References

- [1] Bulun S. Uterine fibroids. *New England Journal of Medicine*. 2013;**369**:1344-1355
- [2] Laughlin-Tommaso SK, Hesley GK, Hopkins MR, Brandt KR, Zhu Y, Stewart EA. Clinical limitations of the International Federation of Gynecology and Obstetrics (FIGO) classification of uterine fibroids. *International Journal of Gynaecology and Obstetrics*. 2017;**139**(2):143-148
- [3] Chander B, Shekhar S. Osseous metaplasia in leiomyoma: A first in a uterine leiomyoma. *Journal of Cancer Research and Therapeutics*. 2015;**11**(3):661
- [4] Nakai G, Yamada T, Hamada T, et al. Pathological findings of uterine tumors preoperatively diagnosed as red degeneration of leiomyoma by MRI. *Abdominal Radiology (New York)*. 2017;**42**(7):1825-1831
- [5] Duvnjak S, Ravn P, Green A, Andersen PE. Uterine fibroid embolization with acrylamido polyvinyl microspheres: Prospective 12-month clinical and MRI follow-up study. *Acta Radiologica*. 2017;**58**(8):952-958
- [6] Downes KA, William RH. Bizarre leiomyomas of the uterus. A comprehensive pathologic study of 24 cases with long term follow up. *The American Journal of Surgical Pathology*. 1997;**21**:1261-1270
- [7] Srinivasan R, Saraiya U. Recurrent fibroids. *Journal of Obstetrics and Gynecology of India*. 2004;**54**:363-366
- [8] Chang KL, Grabtree GS, Lim-Tan Kempson RL, Hendrickson MR. Primary uterine endometrial stromal neoplasms. A clinicopathologic study of 117 cases. *The American Journal of Surgical Pathology*. 1994;**18**:635-658
- [9] Yang KH, Shin JA, Jung JH, et al. A case of metastatic low-grade endometrial stromal sarcoma treated with letrozole after ovarian ablation by radiotherapy. *Cancer Research and Treatment*. 2015;**47**(4):958-962
- [10] Xie W, Cao D, Yang J, Jiang X, et al. Fertility-sparing surgery for patients with low-grade endometrial stromal sarcoma. *Oncotarget*. 2017;**8**(6):10602-10608
- [11] Solomon LA, Schimp VL, Ali-Fehmi R, Diamond MP, Munkarah AR. Clinical update of smooth muscle tumors of the uterus. *Journal of Minimally Invasive Gynecology*. 2005;**12**:401-408
- [12] Sung CO, Ahn G, Song SY, et al. Atypical leiomyomas of the uterus with long-term follow-up after myomectomy with immunohistochemical analysis for p16INK4A, p53, Ki-67, estrogen receptors, and progesterone receptors. *International Journal of Gynecological Pathology*. 2009;**28**:529-534
- [13] Toledo G, Oliva E. Smooth muscle tumors of the uterus: A practical approach. *Archives of Pathology & Laboratory Medicine*. 2008;**132**:595-605