

# We are IntechOpen, the world's leading publisher of Open Access books Built by scientists, for scientists

6,900

Open access books available

185,000

International authors and editors

200M

Downloads

Our authors are among the

154

Countries delivered to

TOP 1%

most cited scientists

12.2%

Contributors from top 500 universities



WEB OF SCIENCE™

Selection of our books indexed in the Book Citation Index  
in Web of Science™ Core Collection (BKCI)

Interested in publishing with us?  
Contact [book.department@intechopen.com](mailto:book.department@intechopen.com)

Numbers displayed above are based on latest data collected.  
For more information visit [www.intechopen.com](http://www.intechopen.com)



# Interventional Treatment Options for Trigeminal Neuralgia

*Yashar Eshraghi, Sarah J. Vitug and  
Maged Guirguis*

## Abstract

Trigeminal neuralgia is characterized by sudden and severe shock-like episodes of transient unilateral pain in the trigeminal nerve distribution. Most cases are idiopathic and are known to respond favorably to anticonvulsants. For patients who fail at least three drug trials or experience intolerable side effects, surgery may be warranted. First, a diagnostic block at the trigeminal nerve or Gasserian ganglion to confirm clinical diagnosis is performed. Surgical intervention can be either ablative or nonablative, each with its respective indications, contraindications, and risk-benefit profile. Most common are the percutaneous rhizotomies: conventional and pulsed radiofrequency ablation (RFA), chemical glycerol injections, and mechanical balloon compression. Stereotactic or gamma knife radiosurgery (GKRS) is the least invasive with only a moderate duration of pain relief, whereas microvascular decompression (VMD) is the most invasive, but associated with greatest long-term benefit. RFA has consistently shown favorable results and is the only modality with evidence of pain relief in  $\geq 50\%$  of patients treated 20 years postoperatively. Auxiliary interventional options such as peripheral neurectomy, botulinum toxin type-A (BTX-A) injections, and cryotherapy are available for those with contraindications to rhizotomies, radiosurgery, or neurosurgery. Ultimately, physicians must tailor their management of trigeminal neuralgia to the needs of the patient.

**Keywords:** trigeminal neuralgia, Meckel's cave, Gasserian ganglion, ophthalmic division, maxillary division, mandibular division, classic approach, coronoid approach, trigeminal nerve block, Gasserian ganglion block, percutaneous radiofrequency rhizotomy, percutaneous glycerol rhizotomy, percutaneous balloon compression, stereotactic radiosurgery, gamma knife radiosurgery, microvascular decompression, peripheral neurectomy, botulinum toxin type-A, cryotherapy, cryoanalgesia

## 1. Introduction

Trigeminal neuralgia, also known as “tic douloureux,” is characterized by distinctive, transient episodes of unilateral lancinating pain in the trigeminal

nerve distribution [1]. Most often, etiology is unknown and is not attributed to another disorder. This presentation is referred to as Type I or classic trigeminal neuralgia. Inflammatory causes (e.g., multiple sclerosis, infection, etc.), compression of the trigeminal roots (e.g., tumors and arteriovenous malformation), abnormalities of the skull base [2], or pain due to underlying disease processes comprise Type II or secondary trigeminal neuralgia. Atypical or mixed trigeminal neuralgia is when patients experience sensory loss or dull, burning pain in the trigeminal nerve distribution in between the characteristic paroxysms [2], and often without an identifiable trigger zone. Atypical disease is more commonly associated with a symptomatic presentation or background pain of milder intensity for up to 50% of the time [3].

Patients usually describe the pain as sudden and severe electric, shooting or shock-like, and superficial pain lasting anywhere from a few seconds to several minutes [2]. Attacks are considered paroxysmal, where frequency of episodes can range from a few to several dozens in 1 day [3]. Additionally, paroxysms are generally similar in nature for individual patients. The pain associated with the classic presentation can be precipitated by light mechanical stimulation to the face or oral mucosa (e.g., facial hair grooming and tooth brushing) or by thermal stimulation (e.g., cold or heat exposure) [2]. It is common for patients to develop an aversion to eating, drinking, or previous noxious stimuli for fear of triggering another episode. More so, the psychological impact may cause patients to appear distressed or anxious during physical examination [4]. For these reasons, the unique presentation with the absence of other neurologic abnormalities makes trigeminal neuralgia a clinical diagnosis [2]. Dental X-rays or MRIs may be warranted to clarify differential diagnoses or confirm a suspected etiology which may guide management.

Overall, trigeminal neuralgia is considered a rare disease according to population-based studies, with estimated 4–13 cases diagnosed per 100,000 individuals each year [5]. However, regional biases exist where countries with less stringent diagnostic criteria yield a higher incidence. For example, the annual incidence of disease in the United Kingdom (26.8 per 100,000 cases) is based off general practitioner lists and fewer diagnostic criteria, compared to the United States (5.9) and Netherlands (12.6), respectively [3].

Anatomically, the vast majority of cases affect either the maxillary or mandibular division (V2 or V3), alone or in combination. In approximately 5% of patients, the symptoms occur solely in the ophthalmic division (V1). In terms of disease onset, trigeminal neuralgia rarely manifests in individuals younger than age 40, with incidence peaking in the elderly and more than twice as many women affected than men [6]. However, it is important to note that trigeminal neuralgia is considered a progressive disease with symptomatic treatment with repeat procedures becoming less effective over time [3].

## **2. First-line management of medication-resistant trigeminal neuralgia**

The primary treatment for trigeminal neuralgia is pharmacologic. Pain associated with trigeminal neuralgia responds poorly to analgesics and favorably to antiepileptic drugs. First-line medical treatment is carbamazepine, with other adjuncts such as phenytoin, gabapentin, lamotrigine, or baclofen added for persistent pain [4].

Patients with intolerable medication side effects or who experience pain refractory to three attempted drug trials and are surgically fit as dictated by medical status/age may be considered for surgery [7]. Patients may first undergo preliminary nerve blocks either at the level of a trigeminal nerve branch or at the Gasserian ganglion to confirm the diagnosis of trigeminal neuralgia. If patients experience pain relief with this diagnostic procedure, patients may elect further therapeutic treatment with the same modality or discuss different surgical treatment options with their neurologist, neurosurgeon, anesthesiologist, or other physicians involved in their care [8].

Surgical methods for the treatment of trigeminal neuralgia can be separated into four broad categories—peripheral lesions to the terminal branches, lesions to the trigeminal (Gasserian) ganglion, lesions to the ganglion root by stereotactic radiosurgery or gamma knife radiosurgery (GKRS), and posterior fossa intervention with microvascular decompression (MVD) [9]. Alternatively, surgical intervention can be divided into non-ablative/nondestructive (MVD) and ablative (all other surgical interventions).

The non-ablative MVD is a complex posterior fossa procedure requiring a craniotomy and thus is performed exclusively by neurosurgeons [10]. This approach is rapidly becoming the surgical intervention of choice when there is MRI-confirmed vascular compression by the nerve root as pain relief is significant, and severe complication risks such as death and relapse rate are among the lowest of all surgical treatment modalities [3]. If no compression is found, percutaneous rhizotomies via thermal (pulsed radiofrequency or thermocoagulation), chemical (glycerol), or mechanical (balloon compression) techniques or gamma knife radiosurgery (GKRS) are preferred. As sensory ablation by rhizotomy demonstrate similar pain relief results in comparison to MVD, it is important for patients to consider the slightly higher risk of complications and slightly lower patient satisfaction at 5-year follow-up with rhizotomies [10]. GKRS is also a safe and effective treatment; however, patients are counseled on the likelihood of a delayed onset of pain relief following treatment, and those with a significant surgical history involving the head may make poor candidates for GKRS [9].

### **3. Second-line management of medication-resistant trigeminal neuralgia**

Ultimately, patient preferences for surgical intervention are always taken into consideration and only if medical status permits. For patients who wish to undergo intervention for management of their medically refractory disease and do not wish to have MVD, any form of rhizotomy, or GKRS, patients may elect to have other treatments such as peripheral neurectomy, botulinum toxin type-A (BTX-A) injections, or cryotherapy. Such interventions can be administered by a variety of physicians such as oral and maxillofacial surgeons, anesthesiologists, neurologists, and other certified providers in both inpatient and outpatient settings.

Peripheral or mental neurectomy under local anesthesia is still offered for management of pharmacologically resistant trigeminal neuralgia; however, it is most often used in rural areas where more advanced surgical options (MVD, rhizotomy, GKRS) are unavailable or unaffordable [11]. Neurectomies essentially are too underreported to gauge its actual utility compared to other treatments. BTX-A is

another minimally invasive approach, which can be performed in an outpatient setting and repeated a number of times without significant adverse effects. However, the location (intradermal or intramuscular) and dosage (25–75 units) per injection have yet to be standardized [12]. Anecdotally, cryotherapy is one of the more painful procedures and does not appear to have significant long-term efficacy in pain relief compared to other interventions. It is maintained that cryogenic insult varies with nerve diameter and is thus associated with variable nerve regeneration and shorter pain-free intervals [13].

Often, patients electing these auxiliary interventions have major contraindications for neurosurgery, are unfit for general anesthesia, or simply prefer less invasive procedures [14–16]. However, the effectiveness, duration of pain relief, rate of relapse and complication, and overall patient satisfaction with auxiliary interventions are generally based on case reports and studies with small sample sizes; thus, overall impression of such modalities is less favorable compared to MVD, rhizotomy, and GKRS [17].

#### **4. Complications**

As with any invasive procedure, patients must be counseled on postoperative risk for infection and bleeding (hematomas) at the site of needle entry or incision. With trigeminal nerve and Gasserian ganglion blocks, a small risk of dysesthesias or a loss of consciousness may occur if CSF is inadvertently injected with local anesthetic [8]. For patients undergoing MVD, rhizotomy procedures, or GKRS, postoperative hyperesthesia, facial asymmetry, masseter weakness, alteration in corneal sensation, and meningitis are extremely rare complications; however, patients must always be informed of potential risks [8]. As with the auxiliary intervention options, patients are educated on the similar complications such as dysesthesias, facial weakness, and asymmetry, albeit rare. Of note, cryotherapy is one technique that attempts to preserve sensation post-procedure.

#### **5. Conclusion**

It is imperative that patients accurately assess pain levels before and after surgical intervention to better guide treatment options in the future if relapse occurs. Patients must understand that most of these surgical interventions may not rid their symptoms of trigeminal neuralgia permanently and that large, randomized controlled trials are needed to thoroughly predict the long-term efficacy of these interventions and disease prognosis. The paucity of standardization in the follow-up period for patients undergoing surgical treatment is generally physician-specific and on a case-by-case basis, depending on the severity of disease and wishes of the patient. However, the consensus in the literature is that surgical management for the treatment of medication-refractory trigeminal neuralgia is safe and effective.

##### **5.1 Trigeminal (Gasserian) ganglion, maxillary nerve, and mandibular nerve blocks**

Gasserian ganglion, maxillary nerve, and mandibular nerve blocks play an integral role as a diagnostic block prior to trigeminal neurolysis, if indicated.



Patients who report significant pain reduction (greater than 50% compared to preoperative baseline) from two consecutive diagnostic blocks are recommended subsequent percutaneous procedures for a more sustained therapeutic effect.

## 5.2 Gasserian ganglion nerve block

### 5.2.1 Anatomy

The trigeminal nerve contains sensory and motor fibers. Somatic afferent fibers transmit pain, light touch, and temperature sensation from the skin of the face, the oral and nasal mucosa, the teeth, and the anterior two thirds of the tongue. Visceral efferent fibers innervate muscles of facial expression, the tensor tympani, and muscles of mastication. Also, the trigeminal nerve has multiple communications with autonomic nervous system through the ciliary, sphenopalatine, and optic and submaxillary ganglia.

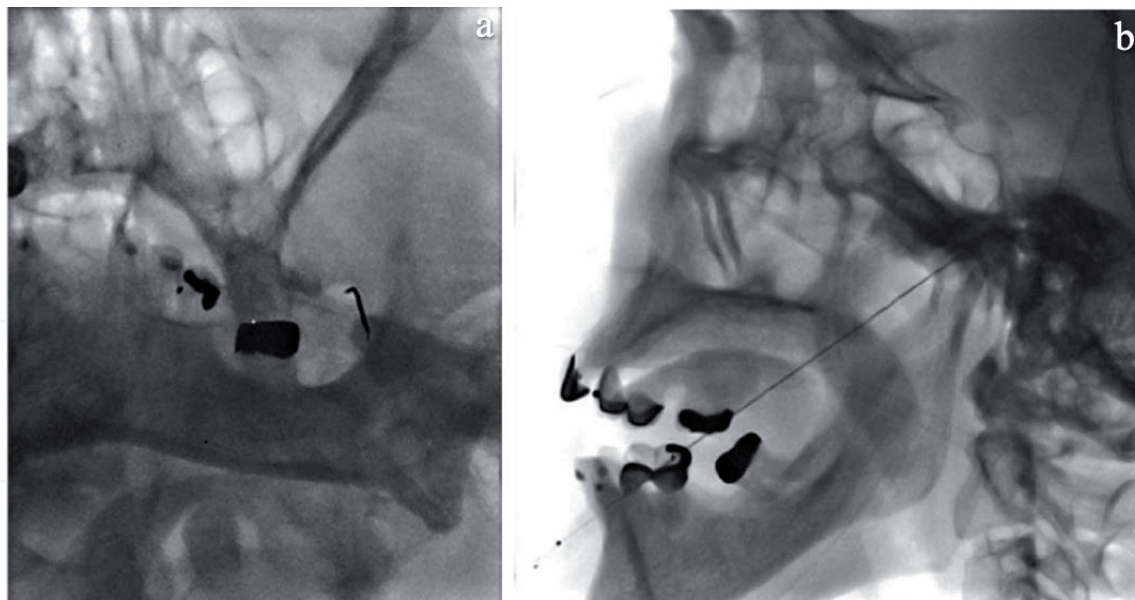
The trigeminal nerve travels as follows: brain stem, prepontine fossa, Meckel's cave (trigeminal/Gasserian ganglion location), and extracranial. The ganglion (approximately 1 × 2 cm) can be found within a reflection of dura mater known as Meckel's cave, which lies in the middle cranial fossa adjacent to the petrous bone. Superior to Meckel's cave is the inferior surface of the temporal lobe, posterior is the brain stem, and medial is the cavernous sinus and internal carotid artery. After the Gasserian ganglion, the nerve separates somatotopically into the following divisions: ophthalmic (craniomedially), mandibular (caudolaterally), and maxillary in between [8].

#### **Indications:**

- Diagnostic block to confirm clinical diagnosis of trigeminal neuralgia [8]
- Therapeutic block in medically refractory cases
- Prognostic indicator for planned neuroablative or surgical procedure
- Diagnosis and management of various orofacial pain syndromes (e.g., cluster headache, persistent ocular pain, palliation of cancer pain)

**Contraindications:** the contraindications to Gasserian ganglion nerve block are the same as those for trigeminal nerve block: patient refusal, local infection, sepsis, coagulopathy, increased intracranial pressure, behavioral abnormalities, allergy to local anesthetics, and lack of patient cooperation.

**Approach:** the patient is positioned supine with the cervical spine extended. As the patient's cooperation is paramount, the procedure is usually done under local anesthetic and sedation [18]. Under fluoroscopic guidance, submental (**Figure 1a**) and lateral (**Figure 1b**) views are obtained to identify the foramen ovale [18]. Approximately 2.5 cm lateral to the corner of the mouth, a needle is advanced perpendicular to the pupil of the eye in a cephalad direction toward the auditory meatus. Once the needle tip has made contact with the base of the skull, the needle is withdrawn slightly and walked posteriorly into the foramen ovale. The needle is carefully aspirated to confirm the absence of CSF/blood prior to therapeutic



**Figure 1.**  
Submental (a) and lateral (b) view of needle in foramen ovale [18].

injection. After needle position is confirmed and aspiration is negative, an average volume of 0.4 mL of neurolytic solution is injected.

**Complications:** due to the close relation between the Gasserian ganglion and the dural reflection, Meckel's cave, inadvertent local anesthetic injection into CSF causing loss of consciousness is a feared complication of this procedure [19]. Additionally, dysesthesias [17] and hematoma formation upon needle entry into the foramen ovale are other complications associated with this technique.

**Outcome:** the overall therapeutic benefit of the Gasserian ganglion block is largely similar to that of trigeminal nerve block, with most patients reporting pain relief greater than 50% of baseline for up to 6–12 months [18] and much shorter duration if used as a diagnostic block.

### 5.3 Maxillary nerve and mandibular nerve blocks

#### 5.3.1 Anatomy

The maxillary division (V2) is the second division of the trigeminal nerve, which exits the middle cranial fossa through the foramen rotundum, located at the roof of the pterygopalatine fossa (PPF) [8]. V2 provides purely sensory fibers to the lower eyelid, cheek, nares, upper lip, upper teeth, upper gums, nasal mucosa, palate, roof of the pharynx, maxillary sinus, ethmoid sinus, sphenoid sinus, and parts of the meninges.

Its branches are divided into four groups, depending on the location where they branch off: the cranium, the pterygopalatine fossa, the infraorbital canal, or the face [20]. The intracranial group includes the middle meningeal nerve [20]. The pterygopalatine group includes the zygomatic nerve, the superior alveolar nerves, the nasopalatine nerve, the palatine nerves, and the pharyngeal nerve [21]. The infraorbital group includes the infraorbital nerve and the anterior superior alveolar nerve [8]. The facial group includes the inferior palpebral nerve, the superior labial nerve, and the lateral nasal nerve.

*The mandibular division (V3)* is the third division of the trigeminal nerve, which exits the middle cranial fossa via the foramen ovale ( $\leq 1$  cm in diameter), situated immediately dorsolateral to the pterygoid process [19]. V3 contains a large sensory root and a small motor root that provide innervation to the lower lip, lower teeth, gums, chin, jaw, parts of the external ear, and parts of the meninges. However, the mandibular division is known for providing motor innervation to the muscles of mastication.

Its branches are divided into three groups: the main trunk, the anterior division, and the posterior division [20]. The main trunk group includes efferent branches for the medial pterygoid, tensor tympani, tensor veli palatini muscles, and an afferent nerve for the meningeal branch [20]. The anterior group includes the efferent masseteric, deep temporal, and lateral pterygoid nerves and the afferent buccal nerve [21]. The posterior group includes the efferent/afferent inferior alveolar nerve and the afferent auriculotemporal and lingual nerves.

### **Indications:**

- Diagnostic block in assessment and management of trigeminal neuralgia and atypical facial pain [8]
- Anatomic differential neural blockade when more selective nerve block needed for diagnosis of various orofacial pain syndromes
- Therapeutic block for acute pain emergencies [18]
- Diagnosis and management of various orofacial pain syndromes (e.g., cluster headache, persistent ocular pain, palliation of cancer pain)

**Contraindications:** the contraindications for performing maxillary and mandibular nerve blocks include but are not limited to the following: patient refusal, local infection, sepsis, coagulopathy, increased intracranial pressure, behavioral abnormalities, allergy to local anesthetics, and lack of patient cooperation.

**Approach:** patients are placed supine with cervical spine extended. The anesthesiologist should be at the patient's side, approximately shoulder level. The site of needle puncture is medial to the masseter muscle (~3 cm lateral to the corner of the mouth) which can be identified by asking the patient to clench his or her teeth. Following the initial numbing, evidenced by the raised skin wheal, a 22-gauge, 10-cm needle is inserted with fluoroscopic guidance [19]. Needle insertion is aligned with the pupil to a depth of 4.5–6 cm to contact the infratemporal surface of the greater wing of the sphenoid, immediately anterior to the foramen ovale [19]. The needle is then retracted and advanced into the foramen ovale to a final depth of 6–7 cm, often resulting in mandibular paresthesia, followed by paresthesia in the ophthalmic and maxillary nerve distribution with further needle advancement. Injection of contrast will identify vascular uptake and extent of injectate spread [22]. Prior to injection with local anesthetic, the needle should be carefully aspirated to confirm the absence of CSF/blood. One millimeter of local anesthetic is generally adequate for a diagnostic nerve block to occur within 5–10 minutes.



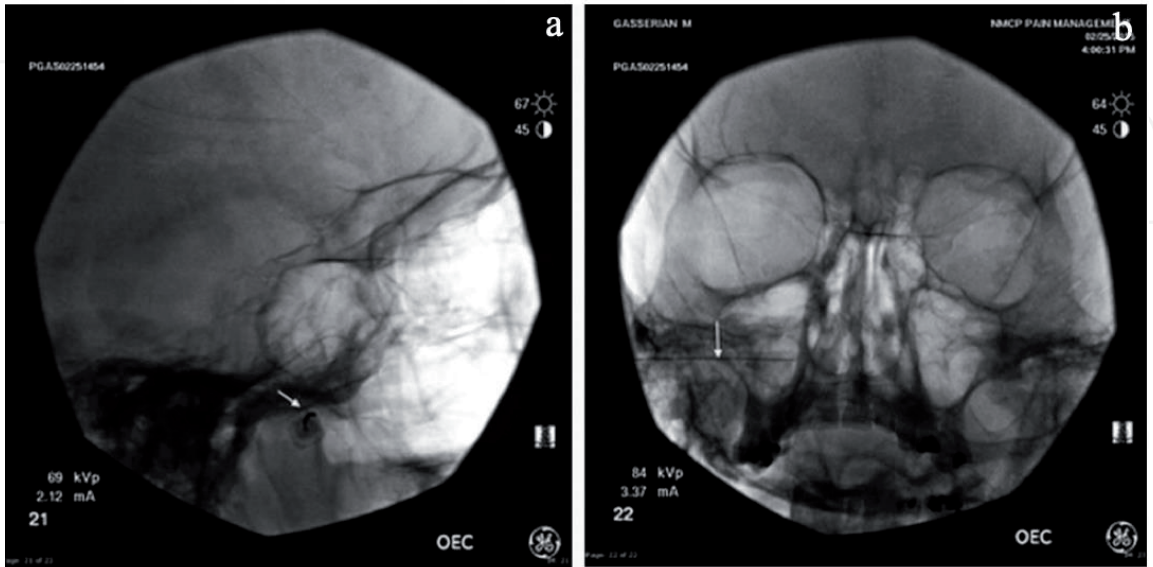
The coronoid approach may be utilized for selective maxillary and mandibular nerve block. The coronoid notch is identified by asking the patient to open and close the mouth several times and palpating the area just anterior and slightly inferior to the acoustic auditory meatus. A needle is inserted just below the zygomatic arch directly in the middle of the coronoid notch and placement verified on lateral view (**Figure 2a**). The needle is advanced 2.5–5 cm in a plane perpendicular to the skull until the lateral pterygoid plate is encountered. Needle placement is verified on PA view (**Figure 2b**). Injection of contrast will identify vascular uptake and extent of injectate spread. The needle is withdrawn slightly, and an incremental injection technique of 3–5 mL of local anesthetic is administered to each nerve [22].

**Complications:** hematoma formation upon needle entry into the foramen ovale and local anesthetic toxicity are the major complications associated with this procedure [22]. However, dysesthesias, weakness of the muscles of mastication, secondary facial asymmetry, meningitis, intracranial hemorrhage with inadvertent intracranial needle placement, total spinal anesthesia, and anesthesia dolorosa are other complications associated with trigeminal nerve blocks [22].

**Outcome:** as a therapeutic block, effects of trigeminal nerve block are relatively short term, with most patients reporting pain relief greater than 50% of baseline for up to 6–12 months [18]. However, as trigeminal nerve blocks are primarily diagnostic, short-term pain relief is expected.

5.4 Interventional treatment for trigeminal neuralgia: percutaneous rhizotomies and neuromodulation

Peripheral lesions to the terminal branches with therapeutic intent are usually via radiofrequency thermocoagulation or highly concentrated alcohol injections [9] and less commonly with neurectomy, Botox injections, or cryolesions; however, adequate trials supporting these modalities are yet to surface [17].



**Figure 2.** Lateral view (a): needle inserted (white arrow) coaxially in coronoid notch. PA view (b): needle (white arrow) advanced medially until contact is made with lateral pterygoid plate [22].

Percutaneous lesions to the Gasserian ganglion are traditionally in the form of rhizotomies, radiofrequency, and chemical lesions by glycerol, phenol, or alcohol injection [18] but also via mechanical compression from balloon inflation. Ganglion-level procedures are generally preferred as they are safer and more effective than peripheral techniques [23], as all procedures are carried out under fluoroscopic guidance [9].

#### *5.4.1 Percutaneous radiofrequency rhizotomy (PRR): pulsed radiofrequency ablation and radiofrequency thermocoagulation*

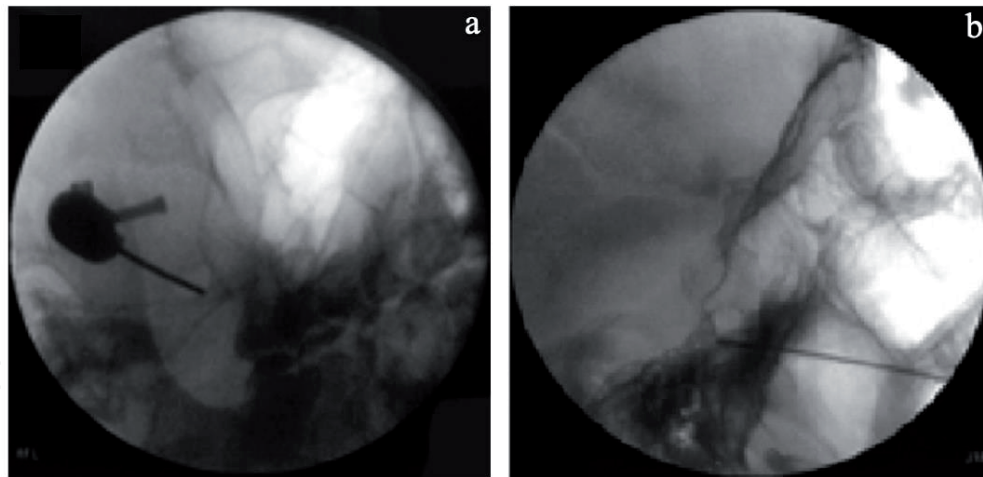
##### **Indications:**

- Treatment of trigeminal neuralgia in a medically refractory or side-effect-intolerable patient
- High-risk operative patients such as the medically ill or elderly [24]
- Secondary trigeminal neuralgia due to multiple sclerosis [25]
- Diagnostic procedure in patients with atypical disease (constant or near constant pain in addition to the classic sharp stabbing pains in trigeminal nerve distribution) [26]
- Patient preference for minimally invasive procedure

**Contraindications:** contraindications for PRR are patient refusal, local infection, sepsis, coagulopathy, increased intracranial pressure, behavioral abnormalities, allergy to local anesthetics, and lack of patient cooperation. Radiofrequency thermocoagulation may be contraindicated in postherpetic neuralgia [25].

**Approach:** the patient is placed supine with cervical spine slightly extended. Procedure requires patient cooperation; thus, it is performed under local anesthetic and light sedation [18]. Under C-arm fluoroscopic guidance, a needle is introduced 2.5 cm lateral to the corner of the mouth. Advancement of the needle medial to the ramus of the jaw into the foramen ovale is verified on oblique view (**Figure 3a**). The use of bony landmarks and fluoroscopic guidance facilitates accurate radiofrequency needle placement to locate Meckel's cave through the foramen ovale. Needle placement is confirmed with lateral fluoroscopic view (**Figure 3b**) prior to neurolysis [24].

Through stepwise advancement of the needle toward the Gasserian ganglion, V3 is first encountered, followed by V2 and lastly V1 [26]. Once in Meckel's cave, aspiration may yield CSF. The stylet is then replaced with the electrode to confirm that nerve root stimulation coincides with location of paresthesia felt by patient. Following accurate needle placement, the patient is anesthetized prior to thermal lesioning in cycles of 45–90 seconds at temperatures between 60 and 90°C [26]. Other parameters have utilized 60-second cycles at 70°C [8]. Pulsed radiofrequency is set to 42°C for 120-second cycles. Patient is awakened in between cycles for manual sensory testing throughout the face until complete pain resolution has been achieved.



**Figure 3.**

*Oblique view (a) verifies needle placement medial to the ramus of the jaw prior to entry into the foramen ovale. Lateral view (b) confirms needle position prior to injuring the trigeminal nerve, a technique used with PRR, percutaneous glycerol rhizotomy (PGR), or percutaneous balloon compression (PBC) [24].*

**Complications:** complications associated with PRR are decreased corneal sensation with increased risk of keratitis, masseter weakness, hyperesthesia, and although very rare, anesthesia dolorosa.

**Outcome:** pain relief immediately following procedure is very high, with 97.6–99% of patients reporting full resolution. Pain relief was reported to be 61.8% at 1 year, 57.7% at 5 years, 52.3% at 10 years, and 41% at 20 years. PRR appears to be the only surgical intervention with long-term follow-up at 20 years [24].

#### 5.4.2 Percutaneous glycerol rhizotomy (PGR)

##### **Indications:**

- Treatment of trigeminal neuralgia in a medically refractory or side-effect-intolerable patient and other high-risk operative patients such as the medically ill or elderly [24]
- Patients who have previously undergone MVD or have history of multiple sclerosis [27]
- Diagnostic procedure in patients with atypical disease (constant or near constant pain in addition to the classic sharp, stabbing pains in trigeminal nerve distribution) [26]
- Patient preference for a minimally invasive procedure

**Contraindications:** contraindications to PGR are patient refusal, local infection, sepsis, coagulopathy, increased intracranial pressure, behavioral abnormalities, allergy to local anesthetics, and lack of patient cooperation.

**Approach:** the patient is placed supine with the cervical spine slightly extended. Percutaneous techniques require patient cooperation during intermittent anesthetization; thus, procedures are performed under local anesthetic and sedation [18]. Under C-arm fluoroscopic imaging, a needle is introduced

2.5 cm lateral to the corner of the mouth. The needle is inserted into the trigeminal cistern through the foramen ovale. Precise needle placement must be ascertained prior to puncture as subarachnoid entry beneath the temporal lobe may yield significant complications. CSF may be encountered when the needle contacts the Gasserian ganglion, unless patient has previously received surgical intervention in this area [26]. Radiopaque contrast is then utilized to visualize the cistern prior to glycerol gangliolysis. Patient is repositioned to a sitting position for a test dose of sterile anhydrous glycerol, followed by dose escalation of 0.1–0.4 mL total. Patient must remain seated for approximately 2 hours postinjection [26].

**Complications:** complications associated with PGR are hyperesthesia, decreased corneal sensation, facial hematoma, aseptic meningitis, hearing loss, bacterial meningitis, buccal mucosa penetration, and carotid puncture.

**Outcome:** pain relief immediately following PGR is good, however, still below that from PRR and with greater variability; 71–97.9% of patients report full resolution immediately following procedure. Pain relief was reported to be between 53 and 63% at 1 year and 43.5% at 5 years [24]. No further time points have been collected for PGR.

#### *5.4.3 Percutaneous balloon compression (PBC)*

##### **Indications:**

- Treatment of trigeminal neuralgia in a medically refractory or side-effect-intolerable patient and other high-risk operative patients such as the medically ill or elderly [24]
- Diagnostic procedure in patients with atypical disease (constant or near constant pain in addition to the classic sharp, stabbing pains in trigeminal nerve distribution) [26]
- Patient preference for minimally invasive procedure

**Contraindications:** PBC may be relatively contraindicated in patients with underlying cardiac disease as trigeminal reflex bradycardia and hypotension may occur [28].

**Approach:** the patient is placed in a supine position with the neck and thorax slightly extended [29]. However, another approach involves the patient semi-seated with head retroflexed to obtain a submental vertical X-ray beam for a horizontal view of the foramen ovale [30]. Patient undergoes endotracheal intubation and general anesthesia. C-arm fluoroscopy is used for anteroposterior and lateral images to confirm needle placement. A 14-gauge needle is inserted approximately 2.5 cm lateral to the corner of the mouth, parallel to the sagittal plane to protect the oral mucosa. Under fluoroscopic guidance, the catheter is redirected to the foramen ovale. A no. 4 Fogarty catheter is then advanced to 10–15 mm beyond the needle tip. The balloon is inflated until proximal to the posterior fossa with approximately 300 mg of I<sub>2</sub>/mL iohexol [29]. Compression volume is patient specific, until pear-shaped balloon is achieved with respect to the nearby structures (e.g., clivus, sella, and petrous bones). The contrast medium is aspirated, catheter is withdrawn, and pressure is applied to needle entry site.



**Complications:** complications associated with PBC are hyperesthesia with persistent symptoms, masseter weakness, facial hematoma, hearing loss, anesthesia dolorosa, decreased corneal sensation, pseudoaneurysm, bacterial meningitis, septic meningitis, trigeminal reflex bradycardia, and hypotension.

**Outcome:** pain relief immediately following PBC is also promising, however, still below that from PRR; 82–93.8% of patients report full resolution immediately following procedure. Pain relief was reported to be between 74.6% at 1 year, 69.8% at 5 years, and between 30 and 51.5% at 10 years [24]. No further time points have been collected for PBC.

#### 5.4.4 Stereotactic radiosurgery/gamma knife radiosurgery (GKRS)

**Indications:**

- Patients who are surgically unfit for MVD due to significant medical comorbidities
- Patients who refuse to take anticonvulsants
- Patients currently on anticoagulation therapy [31]

**Contraindications:** as this noninvasive outpatient procedure is considered one of the safest surgical techniques in the treatment of trigeminal neuralgia, few contraindications have been reported. Patients who have had an extensive history of surgical intervention may be at an increased risk of complications [24].

**Approach:** the patient is supine with mild oral or intravenous sedation. A Leksell Model G stereotactic frame is secured to the patient's head with local anesthetic [26]. MRI maps the neurovascular compression at the entry zone of the trigeminal nerve. Once exact intracranial location is confirmed, a 4-mm collimator is used, with radiation dose prescribed to 100% isodose line [32]. The isocenter is placed near the pars triangularis and highly focused beams of radiation (70–90 Gy) to the trigeminal nerve root in the posterior fossa [7].

**Complications:** complications of GKRS are dose dependent, with increased rate of occurrence rate with cumulative radiation dose exceeding 115 Gy. Alternatively, the rate of complications increases when GKRS is performed following failed treatment with other surgical interventions [24]. Hyperesthesias were reported in 6–42% of patients, and anesthesia dolorosa occurred at a rate of 0.2% [33].

**Outcome:** pain relief associated with GKRS can be delayed up to 8 weeks [9] postoperatively (mean time of 1 month) and is highly dependent on the accuracy of the stereotactic system used [7]. Between 79 and 91.8% of individuals had pain relief; however, a mean delay of 10 days to 3.4 months was experienced prior to initial pain relief. Further follow-ups identified 75–90% of patients with pain relief at 1 year, 44–65% at 5 years, and 30–51.5% of individuals with pain relief at 10 years.

#### 5.4.5 Microvascular decompression (MVD)

**Indications:**

- Medically refractory patients who are deemed surgically fit as by medical status/age [7]

- First-line treatment in younger patients due to long-term improvement in quality of life [34]

**Contraindications:** although advanced age is a relative contraindication, there is no age limit for this procedure as long as patients are fit to undergo general anesthesia [26].

**Approach:** the patient is placed in a lateral decubitus position, which allows for easier lumbar puncture and CSF drainage to decrease tension in infratentorial space. A suboccipital craniotomy is performed to enter the posterior fossa, targeting the trigeminal nerve-pons junction [26]. The infratentorial lateral supracerebellar approach accesses the trigeminal nerve within the superior portion of the cerebello-pontine angle via the lateral aspect of the cerebellar tentorial surface [35]. Once the CSF is aspirated, retraction of the superolateral margin of the cerebellum facilitates contact with the nerve. Most commonly, the superior cerebellar artery (SCA) is responsible for nerve compression at the root entry zone and, less commonly, the anterior inferior cerebellar artery or superior petrosal veins [36]. Thus, the arachnoid membrane must be dissected from the trigeminal nerve all throughout its course through Meckel's cavity in order to expose the compression. The SCA courses medial to the trigeminal nerve, which always compresses the nerve medially. Retraction of the cerebellum should be minimized as injury to the vestibulocochlear nerve is at risk. For transposition of the compressing artery, the sling retraction technique is used [37].

**Complications:** complications associated with MVD are trigeminal nerve deficit, facial weakness, hearing loss, anesthesia dolorosa, aseptic meningitis, hydrocephalus, mortality, and cerebellar infarct or hematoma [24].

**Outcome:** long-term pain relief from MVD has been found to be superior among existing surgical interventions for treatment of trigeminal neuralgia at this time; thus, it is generally considered to be first-line intervention for operative candidates [24]. Between 80.3 and 96% of patients experienced initial pain relief immediately following MVD, 84% at 1 year, 72–85% at 5 years, and 74% at 10 years [24] (Tables 1 and 2).

## 5.5 Other treatment options for trigeminal neuralgia

### 5.5.1 Peripheral neurectomy

#### **Indications:**

- Medically refractory trigeminal neuralgia in patients who are unable to undergo general anesthesia (frail, elderly, or medically unstable patients), as this can be performed as an outpatient procedure under local anesthesia [11]
- Therapeutic for patients reluctant to undergo major neurosurgery or have contraindications for craniotomy when rhizotomies are not possible [49]
- Rural settings where too large surgical facilities may be inaccessible

**Contraindications:** peripheral neurectomy may be contraindicated in those unable to tolerate general anesthesia, as other approaches are more invasive (e.g., maxillary sinus route) [49].

Summary of complications		
Procedure	Complication	Rate (%)
PRR	Decreased corneal sensation; keratitis	5.7–17.3; 0.6–1.9 [38]
	Masseter weakness	4 [39]
	Hyperesthesia	3.3 [40]
	Anesthesia dolorosa	0.6–0.8 [39]
PGR	Hyperesthesia	23.3–72 [41]
	Decreased corneal sensation	6.3–15 [40]
	Facial hematoma	7 [42]
	Aseptic meningitis	0.12–3 [42]
	Hearing loss	1.9 [42]
	Bacterial meningitis	1.5–1.7 [42]
	Buccal mucosa penetration	1.5 [42]
	Carotid puncture	0.77 [42]
PBC	Hyperesthesia; persistent symptoms	89–100; 4.6–40 [41]
	Masseter weakness	1.2–12 [39]
	Facial hematoma	3.5–6.7 [43]
	Hearing loss	2.4–6.3 [44]
	Anesthesia dolorosa	0–3.4 [39]
	Decreased corneal sensation	0–3.1 [40]
	Pseudoaneurysm	1 [44]
	Bacterial meningitis	0.7–1 [43]
	Aseptic meningitis	0.7 [43]
	Trigeminal reflex bradycardia	
	Hypotension	
GKRS	Hyperesthesia	6–42 [33]
	Anesthesia dolorosa	0.2 [33]
MVD	Trigeminal nerve deficit	1.6–22 [45]
	Facial weakness	0.6–10.6 [45]
	Hearing loss	1.2–6.8 [45]
	Anesthesia dolorosa	0–4 [46]
	Aseptic meningitis	2 [47]
	Hydrocephalus	0.15 [48]
	Mortality	0.15–0.8 [24]
	Cerebellar infarct or hematoma	0.075–0.68 [45]

**Table 1.**  
Summary of complications and rates associated with PRR, PGR, PBC, GKRS, and MVD [24].

Summary of outcomes					
Procedure	Initial response (%) rate	1-year	5-year	10-year	20-year
PRR	97.6–99	61.8	57.7	52.3	41
PGR	71–97.9	53–63	43.5		
PBC	82–93.8	74.6	69.8	30–51.5	
GKRS	79–91.8 (Delayed 10 days–3.4 months)	75–90	44–65	30–51.5	
MVD	80.3–96	84	72–85	74	

**Table 2.**  
*Summary of success rates of PRR, PGR, PBC, GKRS, and MVD immediately following procedure, 1-, 5-, 10-, and 20-year time points [24].*

**Approach:** for procedures done under local anesthesia, a diagnostic nerve block with 2% lidocaine HCl plus adrenaline 1:200,000 concentration must completely resolve symptoms prior to neurectomy [14]. Infraorbital, inferior alveolar, and mental neurectomies usually require the following incisions: vestibular, Ginwalla’s, and crevicular incision, respectively. Clamping and avulsion of the mental nerve require an additional Y-shaped incision along the anterior border of the ascending ramus. After further blunt and sharp dissection on its medial aspect, the temporalis and medial pterygoid muscles are split, facilitating the clamping and avulsing of the mental nerve at the mental foramen. Sealing the infraorbital foramen with stainless steel screws is the final step [14].

For procedures done under general anesthesia, patients are supine, and an intra-oral mucoperiosteal incision is made between the buccal sulcus of the upper lateral incisor to the first molar on the symptomatic side [49]. Once the infraorbital fossa is exposed, access to the maxillary sinus is gained via bone window with a diameter of 2 cm in the anterior wall of the maxillary sinus. Further dissection completely liberates the entire neurovascular bundle in the maxillary sinus, and the removal of the inferior bone of the infraorbital canal and fissure ensues [49]. Another round bone window with 1.5 cm diameter is made at the upper 1/3 of the posterior wall of the maxillary sinus with extreme care as injury to the maxillary artery may occur. The superior bony wall of the maxillary sinus is removed to expose the pterygopalatine fossa segment of the maxillary nerve. The length of the maxillary nerve from the infraorbital foramen to the pterygopalatine fossa is removed, along with the branches of the infraorbital nerve [49].

**Complications:** anesthesia or paresthesia in the maxillary distribution post-operatively is common and short-lasting. The major complications regarding the pterygoid palatine fossa segment neurectomy of the maxillary nerve under general anesthesia are bleeding, infection, and eye or encephalic injuries.

**Outcome:** pain relief from peripheral neurectomies has been reported to an average of 26.5 months when obturated with fatty tissues [50] and greater than 24 months when obturated with stainless steel screws [14]. One case report from India of a 65-year-old female who underwent a mental neurectomy endorsed pain reduction from 8 to 1 on VAS score from pre-procedure to 2 years postoperatively, respectively [11]. In terms of recurrence rate, a Danish study evaluated patients at a mean follow-up time of 7 years and reported 78% of patients experienced a recurrence, with half of this group becoming symptomatic within the first month [51]. A study that evaluated 40 patients treated with neurectomy, of whom 28 had previously undergone radiofrequency lesions, 5 of these patients had



recurrence after 2 years and were successfully treated with repeat neurectomy [52]. Thus, it can be inferred that mean follow-up time for neurectomy patients in the setting of trigeminal neuralgia is incredibly variable, with sparse reliable data to support findings.

### 5.5.2 Botulinum toxin type-A (BTX-A) injections

#### Indications:

- Medically refractory trigeminal neuralgia in patients who desire minimally invasive procedures or are unable to general anesthesia (frail, elderly, or medically unstable patients)
- Patients with contraindications to major neurosurgery
- Patient preference for minimally invasive procedure, as this can be performed outpatient without anesthesia [12]

**Contraindications:** patients with pre-existing disease that may be exacerbated by exposure to BTX-A (e.g., myasthenia gravis, motor neuron disease, or Lambert-Eaton syndrome), superficial skin infection on treatment site, or the use of drug within 7 days of BTX-A injection that may adversely affect neuromuscular junction (e.g., quinine, aminoglycosides, and penicillamine) [12].

**Approach:** the number of units and sites to be injected varies per patient. One study approach used a 0.5-mL syringe with 5-/16-inch, 30-gauge needle for subcutaneous injection [53]. Other studies describe injection of unstandardized dosages intramuscularly in the region of the zygomatic arch or masseter [54]. A randomized, double-blind study showed no difference between 25 and 75 units, as both had sustained pain relief at 8 weeks postinjection [12]. Whereas, doses as large as 60 and 40 units of BTX-A diluted in 2.5-mL saline, administered to the external nasal trigger zone and right mental nerve region, respectively, showed sustained relief at 5 months [55].

**Complications:** as BTX-A injections are generally considered safe; few complications such as short-term (<6 weeks) asymmetry in the injection area during dynamic movement and transient facial edema (<5 days) have been noted [12]. In patients currently on a pharmacologic regimen for trigeminal neuralgia (either analgesic or prophylactic), no adverse effects were noted when combined with BTX-A injections [53].

**Outcome:** adequate pain control in patients treated with BTX-A has varied between 90 days [15] and 5 months [55]; however, results are largely based on case reports or studies with small sample size. One small, randomized, open-ended study with eight participants underwent BTX-A injections for intractable trigeminal neuralgia found a mean baseline pain score of 4 on VAS, which was reduced to 1.19 at 6 months following treatment [54]. Another study with 13 patients treated with BTX-A and followed at 10-, 20-, 30-, and 60-day postinjection reported pain relief and reduced need for pharmacotherapy in all patients over the course of their study [53]. However, this is often the case where follow-up periods in patients treated with BTX-A and other surgical interventions for their trigeminal neuralgia are not long enough to reliably deduce long-term efficacy.

### 5.5.3 Cryotherapy (cryoanalgesia)

#### **Indications:**

- Medically refractory disease in patients limited to the supraorbital, infraorbital, and mental nerves and potentially the long buccal and lingual nerves
- Elderly or medically compromised patients who are unfit for surgery
- Patient preference for minimally invasive procedure [16]

**Contraindications:** negligible contraindications have been reported.

**Approach:** involved nerve branches are identified with test doses of local anesthesia. Upon complete pain abolition, cryotherapy blockades can proceed in an outpatient setting under local anesthesia and intravenous sedation [56].

The approach to the inferior dental nerve cryoblockade utilizes C-arm radiographic guidance, image intensifier, and nerve stimulator on the cryoprobe. Lateral oblique films confirm accurate needle placement prior to alcohol injection around the inferior dental nerve [16].

The approach of cryoblockade to other nerves such as the infraorbital, mental, and inferior alveolar nerves begins with the following incisions: intraoral Caldwell-Luc, intraoral low buccal in the premolar region, and intraoral Ginwalla, respectively. Exposed nerves are frozen with nitrous oxide via cryoprobe at a temperature of  $-700^{\circ}\text{C}$  for 2-minute freezing cycles followed by 5 minutes of thawing. This is repeated three times [57].

**Complications:** potential complications associated with cryoblockade are infection, swelling, trismus, and paresthesia ranging from complete numbness or altered sensation, up to 3 months postoperatively [56]. In a study with 145 patients treated with cryotherapy, 58 patients experienced symptoms of atypical facial pain (symptoms described as burning, pins and needles, or dull ache) which responded to a short course of tricyclic antidepressants [58].

**Outcome:** duration of pain relief ranges from 6 [56] to 20 months, depending on the treated nerve. A study that looked at 145 patients with paroxysmal trigeminal neuralgia treated with cryotherapy demonstrated a mean relief period of 13 months for long buccal nerve, 17 months for mental, and 20 months for infraorbital nerves [58]. Although well tolerated by patients, multiple sessions of cryotherapy may be needed to achieve durable pain relief, due to regenerative capacity of nerves, albeit subsequent injections are rarely as effective as the first [58]. In a study that looked at 145 patients treated by cryotherapy, 56% of patients needed more than 1 treatment, with a number of patients needing up to 11 procedures. Of the 145 patients, pain relief at 6 months was achieved in half of the group, with only 27% pain-free at 1 year [58].

## 6. Conclusion

As medical treatment with anticonvulsants has been the cornerstone of first-line management of trigeminal neuralgia, surgical interventions have been

developed for more involved cases. Patients who continue to experience pain with three failed drug trials or encounter an intolerable side-effect profile from medications are generally considered for surgical evaluation. However, only patients who are deemed surgically fit per medical status/age shall be recommended for operative procedures.

Diagnostic blocks are fundamental in the surgical evaluation of a patient with medically refractory trigeminal neuralgia. Trigeminal nerve and Gasserian ganglion blocks confirm the clinical diagnosis before the patient can be considered for subsequent intervention. Additional nerve blocks administered to a terminal branch of the trigeminal nerve or at the Gasserian ganglion with therapeutic intent may offer adequate pain control for some patients. Most commonly, patients are treated with percutaneous rhizotomies (radiofrequency, glycerol, and balloon compression), stereotactic radiosurgery, and microvascular decompression for more sustained pain relief with minimal postoperative complications. Other procedures that have fallen out of favor but are still used are peripheral neurectomy include botulinum toxin type-A injections and cryotherapy on a case-by-case basis. It is thought that patients opting for modalities targeting peripheral branches of the trigeminal nerve, rather than the ganglion or nerve root, are more likely to become symptomatic as pain may break through in other nerves not previously treated [59].

Ultimately, all surgical candidates are thoroughly counseled on available interventions and their individual risk-benefit profiles before undergoing further treatment. As all surgical techniques have demonstrated efficacy in the treatment of medically refractory trigeminal neuralgia, patient input on procedure invasiveness, repeatability, accessibility, and cost are all important factors to consider in choosing a treatment. More studies with larger sample size, randomized controlled design, and stricter diagnostic criteria for patients are needed to reliably comment on the prognostic value of each of the aforementioned treatment options. Regardless, it is with a patient-centric, multidisciplinary approach from all physicians involved in a patient's care that the best treatment plan can be implemented for those with intractable trigeminal neuralgia.

IntechOpen

IntechOpen

IntechOpen

### **Author details**

Yashar Eshraghi\*, Sarah J. Vitug and Maged Guirguis  
Department of Anesthesiology and Critical Care, Ochsner Health System University  
of Queensland School of Medicine, Australia

\*Address all correspondence to: [yashar.eshraghi@gmail.com](mailto:yashar.eshraghi@gmail.com)

### **IntechOpen**

© 2019 The Author(s). Licensee IntechOpen. This chapter is distributed under the terms of the Creative Commons Attribution License (<http://creativecommons.org/licenses/by/3.0>), which permits unrestricted use, distribution, and reproduction in any medium, provided the original work is properly cited. 



## References

- [1] Zakrzewska JM, McMillan R. Trigeminal neuralgia: The diagnosis and management of this excruciating and poorly understood facial pain. *Postgraduate Medical Journal*. 2011;**87**(1028):410-416
- [2] Bennetto L, Patel NK, Fuller G. Trigeminal neuralgia and its management. *BMJ*. 2007;**334**(7586):201-205
- [3] Zakrzewska JM, Linskey ME. Trigeminal neuralgia. *BMJ Clinical Evidence*. 2014;**2014**:1207
- [4] Fields HL. Treatment of trigeminal neuralgia. *The New England Journal of Medicine*. 1996;**334**(17):1125-1126
- [5] MacDonald BK, Cockerell OC, Sander JW, Shorvon SD. The incidence and lifetime prevalence of neurological disorders in a prospective community-based study in the UK. *Brain*. 2000;**123**(Pt 4):665-676
- [6] Katusic S, Beard CM, Bergstralh E, Kurland LT. Incidence and clinical features of trigeminal neuralgia, Rochester, Minnesota, 1945-1984. *Annals of Neurology*. 1990;**27**(1):89-95
- [7] Al-Quliti KW. Update on neuropathic pain treatment for trigeminal neuralgia. The pharmacological and surgical options. *Neurosciences (Riyadh)*. 2015;**20**(2):107-114
- [8] Narouze SN. *Interventional Management of Head and Face Pain: Nerve Blocks and Beyond*. New York, NY: Springer; 2014
- [9] Cruccu G. Trigeminal neuralgia. *Continuum (Minneapolis)*. 2017;**23**(2):396-420
- [10] Zakrzewska JM. Surgery for trigeminal neuralgia? *Pain*. 2011;**152**(3):469-470
- [11] Sikkerimath BC, Merchant MI, Patil NS, Mathivanan SM. Peripheral neurectomy for trigeminal neuralgia: Simple technique for a complex disease. *Journal of Clinical and Diagnostic Research*. 2016;**10**(3):ZJ05-ZJ06
- [12] Zhang H, Lian Y, Ma Y, Chen Y, He C, Xie N, et al. Two doses of botulinum toxin type A for the treatment of trigeminal neuralgia: Observation of therapeutic effect from a randomized, double-blind, placebo-controlled trial. *The Journal of Headache and Pain*. 2014;**15**:65
- [13] Zakrzewska JM, Nally FF, Flint SR. Cryotherapy in the management of paroxysmal trigeminal neuralgia. Four year follow up of 39 patients. *Journal of Maxillofacial Surgery*. 1986;**14**(1):5-7
- [14] Ali FM, Prasant M, Pai D, Aher VA, Kar S, Safiya T. Peripheral neurectomies: A treatment option for trigeminal neuralgia in rural practice. *Journal of Neurosciences in Rural Practice*. 2012;**3**(2):152-157
- [15] Allam N, Brasil-Neto JP, Brown G, Tomaz C. Injections of botulinum toxin type a produce pain alleviation in intractable trigeminal neuralgia. *The Clinical Journal of Pain*. 2005;**21**(2):182-184
- [16] Juniper RP. Trigeminal neuralgia—Treatment of the third division by radiologically controlled cryoblockade of the inferior dental nerve at the mandibular lingula: A study of 31 cases. *British Journal of Oral and Maxillofacial Surgery*. 1991;**29**(3):154-158
- [17] Gronseth G, Cruccu G, Alksne J, Argoff C, Brainin M, Burchiel K, et al. Practice parameter: The diagnostic

evaluation and treatment of trigeminal neuralgia (an evidence-based review): Report of the Quality Standards Subcommittee of the American Academy of Neurology and the European Federation of Neurological Societies. *Neurology*. 2008;**71**(15):1183-1190

[18] Vasappa CK, Kapur S, Krovvidi H. Trigeminal neuralgia. *BJA Education*. 2016;**16**(10):353-356

[19] Farag E, Mounir-Soliman L. Brown's Atlas of Regional Anesthesia. Philadelphia: Elsevier; 2016

[20] Waldman SD. Atlas of Interventional Pain Management E-Book. Philadelphia: Elsevier—Health Sciences Division; 2014

[21] Gulur P, Wainger BJ, Young A. Head and Facial Trigeminal Neuralgia. Pain procedures in clinical practice. 2011. 297-304.

[22] McClenahan MF, Hillegass MG. Trigeminal nerve block. In: Yong RJ, Nguyen M, Nelson E, Urman RD, editors. Pain Medicine: An Essential Review. Cham: Springer International Publishing; 2017. pp. 275-277

[23] Peters JG, Nurmikko JT. Peripheral and gasserian ganglion-level procedures for the treatment of trigeminal neuralgia. *The Clinical Journal of Pain*. 2002;**18**(1):28-34

[24] Bick SKB, Eskandar EN. Surgical treatment of trigeminal neuralgia. *Neurosurgery Clinics of North America*. 2017;**28**(3):429-438

[25] Zakrzewska JM, Jassim S, Bulman JS. A prospective, longitudinal study on patients with trigeminal neuralgia who underwent radiofrequency thermocoagulation of the gasserian ganglion. *Pain*. 1999;**79**(1):51-58

[26] Nurmikko TJ, Eldridge PR. Trigeminal neuralgia—Pathophysiology, diagnosis and current treatment. *British Journal of Anaesthesia*. 2001;**87**(1):117-132

[27] Ammori MB, King AT, Siripurapu R, Herwadkar AV, Rutherford SA. Factors influencing decision-making and outcome in the surgical management of trigeminal neuralgia. *Journal of Neurological Surgery. Part B, Skull Base*. 2013;**74**(2):75-81

[28] Chang EF, Cheng JS, Lim DA, Barbaro NM. A review of percutaneous treatments for trigeminal neuralgia. *Operative Neurosurgery*. 2013;**10**(1):25-33

[29] Chen JF, Tu PH, Lee ST. Repeated percutaneous balloon compression for recurrent trigeminal neuralgia: A long-term study. *World Neurosurgery*. 2012;**77**(2):352-356

[30] Mullan S, Lichtor T. Percutaneous microcompression of the trigeminal ganglion for trigeminal neuralgia. *Journal of Neurosurgery*. 1983;**59**(6):1007-1012

[31] Hodaie M, Coello AF. Advances in the management of trigeminal neuralgia. *Journal of Neurosurgical Sciences*. 2013;**57**(1):13-21

[32] Aubuchon AC, Chan MD, Lovato JF, Balamucki CJ, Ellis TL, Tatter SB, et al. Repeat gamma knife radiosurgery for trigeminal neuralgia. *International Journal of Radiation Oncology, Biology, Physics*. 2011;**81**(4):1059-1065

[33] Kondziolka D, Zorro O, Lobato-Polo J, Kano H, Flannery TJ, Flickinger JC, et al. Gamma Knife stereotactic radiosurgery for idiopathic trigeminal neuralgia. *Journal of Neurosurgery*. 2010;**112**(4):758-765

[34] van Kleef M, van Genderen WE, Narouze S, Nurmikko TJ, van Zundert J,

Geurts JW, et al. Trigeminal neuralgia. *Pain Practice*. 2009;**9**(4):252-259

[35] Hitotsumatsu T, Matsushima T, Inoue T. Microvascular decompression for treatment of trigeminal neuralgia, hemifacial spasm, and glossopharyngeal neuralgia: Three surgical approach variations: Technical note. *Neurosurgery*. 2003;**53**(6):1436-1441. Discussion 42-3

[36] Rhoton AL Jr. The cerebellopontine angle and posterior fossa cranial nerves by the retrosigmoid approach. *Neurosurgery*. 2000;**47** (3 Suppl):S93-S129

[37] Matsushima T, Yamaguchi T, Inoue TK, Matsukado K, Fukui M. Recurrent trigeminal neuralgia after microvascular decompression using an interposing technique. Teflon felt adhesion and the sling retraction technique. *Acta Neurochirurgica*. 2000;**142**(5):557-561

[38] Jin HS, Shin JY, Kim YC, Lee SC, Choi EJ, Lee PB, et al. Predictive factors associated with success and failure for radiofrequency thermocoagulation in patients with trigeminal neuralgia. *Pain Physician*. 2015;**18**(6):537-545

[39] Berk C, Kanpolat Y, Savas A, Bekar A. Percutaneous controlled radiofrequency trigeminal rhizotomy for the treatment of idiopathic trigeminal neuralgia: 25-year experience with 1600 patients. *Neurosurgery*. 2001;**48**(3):524-534

[40] Noorani I, Lodge A, Vajramani G, Sparrow O. Comparing percutaneous treatments of trigeminal neuralgia: 19 years of experience in a single centre. *Stereotactic and Functional Neurosurgery*. 2016;**94**(2):75-85

[41] Guidetti B, Fraioli B, Cruccu G, Manfredi M, Esposito V. Treatment of trigeminal neuralgia by

thermocoagulation, glycerolization, and percutaneous compression of the gasserian ganglion and/or retrogasserian rootlets: Long-term results and therapeutic protocol. *Neurosurgery*. 1989;**24**(2):239-245

[42] Blomstedt PC, Bergenheim AT. Technical difficulties and perioperative complications of retrogasserian glycerol rhizotomy for trigeminal neuralgia. *Stereotactic and Functional Neurosurgery*. 2002;**79**(3-4):168-181

[43] Lobato RD, Rivas JJ, Sarabia R, Lamas E. Percutaneous microcompression of the gasserian ganglion for trigeminal neuralgia. *Journal of Neurosurgery*. 1990;**72**(4):546-553

[44] de Siqueira SR, da Nobrega JC, de Siqueira JT, Teixeira MJ. Frequency of postoperative complications after balloon compression for idiopathic trigeminal neuralgia: Prospective study. *Oral Surgery, Oral Medicine, Oral Pathology, Oral Radiology, and Endodontics*. 2006;**102**(5):e39-e45

[45] Broggi G, Ferroli P, Franzini A, Servello D, Dones I. Microvascular decompression for trigeminal neuralgia: Comments on a series of 250 cases, including 10 patients with multiple sclerosis. *Journal of Neurology, Neurosurgery, and Psychiatry*. 2000;**68**(1):59-64

[46] Barker FG 2nd, Jannetta PJ, Babu RP, Pomonis S, Bissonette DJ, Jho HD. Long-term outcome after operation for trigeminal neuralgia in patients with posterior fossa tumors. *Journal of Neurosurgery*. 1996;**84**(5):818-825

[47] Pollock BE, Stien KJ. Posterior fossa exploration for trigeminal neuralgia patients older than 70 years of age. *Neurosurgery*. 2011;**69**(6):1255-1259, 9-60

[48] Barker FG 2nd, Jannetta PJ, Bissonette DJ, Larkins MV, Jho HD. The

- long-term outcome of microvascular decompression for trigeminal neuralgia. *The New England Journal of Medicine*. 1996;**334**(17):1077-1083
- [49] Zhu S, Rong Q, Chen S, Li X. Pterygopalatine fossa segment neurectomy of maxillary nerve through maxillary sinus route in treating trigeminal neuralgia. *Journal of Cranio-Maxillo-Facial Surgery*. 2013;**41**(7):652-656
- [50] Freemont AJ, Millac P. The place of peripheral neurectomy in the management of trigeminal neuralgia. *Postgraduate Medical Journal*. 1981;**57**(664):75-76
- [51] Oturai AB, Jensen K, Eriksen J, Madsen F. Neurosurgery for trigeminal neuralgia: Comparison of alcohol block, neurectomy, and radiofrequency coagulation. *The Clinical Journal of Pain*. 1996;**12**(4):311-315
- [52] Murali R, Rovit RL. Are peripheral neurectomies of value in the treatment of trigeminal neuralgia? An analysis of new cases and cases involving previous radiofrequency gasserian thermocoagulation. *Journal of Neurosurgery*. 1996;**85**(3):435-437
- [53] Piovesan EJ, Teive HG, Kowacs PA, Della Coletta MV, Werneck LC, Silberstein SD. An open study of botulinum-A toxin treatment of trigeminal neuralgia. *Neurology*. 2005;**65**(8):1306-1308
- [54] Turk U, Ilhan S, Alp R, Sur H. Botulinum toxin and intractable trigeminal neuralgia. *Clinical Neuropharmacology*. 2005;**28**(4):161-162
- [55] Ngeow WC, Nair R. Injection of botulinum toxin type A (BOTOX) into trigger zone of trigeminal neuralgia as a means to control pain. *Oral Surgery, Oral Medicine, Oral Pathology, Oral Radiology, and Endodontics*. 2010;**109**(3):e47-e50
- [56] Zakrzewska JM. Cryotherapy for trigeminal neuralgia: A 10 year audit. *The British Journal of Oral and Maxillofacial Surgery*. 1991;**29**(1):1-4
- [57] Zakrzewska JM. Cryotherapy in the management of paroxysmal trigeminal neuralgia. *Journal of Neurology, Neurosurgery, and Psychiatry*. 1987;**50**(4):485-487
- [58] Zakrzewska JM, Nally FF. The role of cryotherapy (cryoanalgesia) in the management of paroxysmal trigeminal neuralgia: A six year experience. *The British Journal of Oral and Maxillofacial Surgery*. 1988;**26**(1):18-25
- [59] Nurmikko TJ, Eldridge PR. Trigeminal neuralgia - pathophysiology, diagnosis and current treatment. *British Journal of Anaesthesia*. 2001;**87**(1):117-132