We are IntechOpen, the world's leading publisher of Open Access books
Built by scientists, for scientists

6,900
Open access books available

186,000
International authors and editors

200M
Downloads

Our authors are among the

154
Countries delivered to

TOP 1%
most cited scientists

12.2%
Contributors from top 500 universities

CLARIVATE ANALYTICS
BOOK CITATION INDEX
INDEXED

WEB OF SCIENCE™

Selection of our books indexed in the Book Citation Index in Web of Science™ Core Collection (BKCI)

Interested in publishing with us?
Contact book.department@intechopen.com

Numbers displayed above are based on latest data collected.
For more information visit www.intechopen.com

Chapter

Orthognathic Surgery in Cleft Lip and Palate Patients

Hakan Yilmaz and Arzu Ari Demirkaya

Abstract

Cleft lip and palate patients often exhibit severe dentofacial deformities that necessitate orthognathic surgery. Orthognathic surgery in these patients generally includes not only maxillary advancement, but also sagittal, horizontal, and vertical movement of both jaws. Surgical planning and execution presents many difficulties, caused by the presence of extensive scar tissues from previous surgeries, tissue deficiencies, the difficulty of aligning multiple segments of bone and soft tissues. Other challenges in cleft patients are complications related to post-surgical airway, speech, velopharyngeal insufficiency, nerve damage, and infections. This review is focused on orthognathic surgery in cleft lip and palate patients, management, techniques, success, and complications.

Keywords: orthognathic surgery, cleft lip and palate, complications

1. Introduction

Deficiency of growth and development in the midfacial complex is a major drawback of primary CLP repair in the neonatal period of growth, well documented in the literature [1–3]. Causes are thought to be formation of scar tissue in the growth centers of the maxilla [4], mouth breathing due to obstruction of the nasal passage [5], deficiency of the alveolar process due to missing teeth [6], and a tense upper lip [7, 8]. Unrepaired bone defects on the other hand result in closer to normal maxillo-facial development [7, 8]. Because of midfacial deficiency, orthognathic surgery becomes often indispensable at the adult ages in CLP management. Treatment of CLP with orthognathic surgery involves maxillary advancement, distraction osteogenesis, and mandibular setback, combined with orthodontic treatment [9].

2. Timing of orthognathic surgery

In the past, CLP-orthognathic surgery in the mixed dentition period has been discussed and discarded. It has been reported that there will usually be a need for revisions after completion of skeletal growth [10]. Risks of early orthognathic surgery include damage to permanent tooth germs and creation of fibrous tissue and calli in the osteotomy regions. Additionally, it was shown that neither Le Fort I osteotomy nor distraction osteogenesis in the mixed dentition period provides additional lateral maxillary growth [11, 12]. Apart from cases with significant psychosocial or functional problems, risks of "early" surgery overweigh its benefits [13].

Orthognathic surgery for treatment of maxillomandibular deformities is usually applied after completion of growth of the maxillomandibular structure [14–16]. Transverse, sagittal, and vertical growth of the maxilla and the mandible ends at different chronological ages, usually at the ages of 14–16 for female patients and 16–18 for male patients [17]. Mandibular growth has a normal pattern in most CLP patients [13]. However, since skeletal growth is variable, hand-wrist or cephalometric radiographs may help in determining the timing of skeletal maturation [17].

3. Preparation for orthognathic surgery

In orthognathic surgery in cleft patients, there are some issues that need to be considered before surgery like velopharyngeal situation, speech problems, hearing problems, the situation of alveolar cleft gap, and dental problems.

Speech pathologists play a critical role in terms of assessing speech and articulation problems and determine velopharyngeal function with nasal endoscopy before the surgery [18, 19]. The velopharyngeal sufficiency rarely remains the same after maxillary advancement surgery; more often, an insufficiency is created [20]. Surgical correction of cross-bites and open-bites and the repair of cleft-dental gaps and residual oronasal fistulae usually alleviate articulation disorders [19, 21].

Prevention and treatment of tympanic infection as well as comprehensive preventive and restorative dental care have been provided during early childhood and adolescence. Oral hygiene maintenance may be more difficult in CLP patients than in routine orthodontic treatment patients. Soft tissues may have a more retentive morphology due to scarring from previous operations: shallow buccal sulci, sometimes buccal flaps with mucosa or gingivae covering teeth. Furthermore, because of poor dental esthetics, CLP patients do not like their teeth and smile and have low motivation. Long treatment times reduce motivation further. Orthodontic preparation presents various challenges not only in terms of planning but also in terms of implementation. It may be difficult for the orthodontist to work in a narrow space with low visibility, since the elasticity of lips is low, mouth opening is limited, and the upper jaw is small and retrognathic. All surgical management of maxillo-mandibular deformities usually requires prior adjustment of the dental arches over the maxillary and mandibular basal bones via orthodontic treatment. The "surgery-first" protocol rarely applies to CLP patients. A major dilemma during

Figure 1.
Teeth erupting from the palate [25]. (a) UCLP patient, permanent dentition. Missing lateral incisors, 15 and 23 erupting palatally, and 17 erupting excessively buccally. (b) Dental arch development through orthodontic leveling, occult fistula enlarged and became visible during dental leveling, 13 is just starting to erupt after 2.5 years of orthodontic treatment.

alignment is the decision on the management of the cleft alveolar region, where often the lateral teeth are missing [6]. Surgical correction of septal and inferior respiratory pathologies is done only in severe obstructive sleep apnoea cases before orthognathic surgery, but rather scheduled to be performed simultaneously or consecutively [22–24].

In most CLP cases, teeth are either missing, erupt late or ectopically located. Therefore, the alveolar bone base is not sufficiently developed, and this adds to the skeletal (transverse and sagittal) insufficiency. Leveling of teeth erupting in the palate usually takes a long time (**Figure 1**).

4. Residual deformities in CLP patients

Patients with Isolated Cleft Palate (ICP) have a complete alveolar ridge and generally a complete set of teeth [13, 17, 26, 27]. The main deformity in unilateral cleft lip and palate (UCLP) and bilateral cleft lip and palate (BCLP) patients is maxillary hypoplasia, but oronasal fistula, bony defects, intranasal obstruction, soft tissue scarring, and velopharyngeal dysfunctions are also frequently encountered [27]. Additionally, the maxillary lateral incisor and often the second premolars in the cleft region are either congenitally missing, resulting in a cleft-dental gap [6, 28–30].

In addition to the existing deformities in UCLP and BCLP patients, nasal obstruction and sinus blockage and mandibular asymmetry and chin dysplasia are seen frequently as secondary deformities [27, 31]. The prevalence of these deformities varies significantly based on the surgical philosophy and experience of the surgeon who repaired the first cleft [32], the individual's unique biological growth potential, and the level of care of the family/patient.

Published clinical research on individuals who were born with complete UCLP/BCLP and treated at cleft centers showed that, despite the best efforts, the mixed dentition period would not be appropriate for grafting just before the canine tooth is erupted on the cleft side in some children [33, 34]. Additionally, although grafted appropriately, in some individuals, additional reconstruction is needed [33]. For these reasons, repairing residual skeletal and soft tissues and managing dental deformities in patients with CLP strains the proficiency and skills of the orthognathic surgery cleft team [26, 31, 35].

5. Orthognathic approach on UCLP deformities

5.1 Prevalence

Studies have examined the need for orthognathic surgery in UCLP patients who underwent primary lip-palate repair procedures in childhood [3, 8, 36, 37]. Ross [37] stated that the midface is close to normal only in 25% of patients, and there is a need for orthognathic surgery in the remaining patients, with interventions at early stages worsening the situation. In other similar studies, the rate of orthognathic surgery needed in repaired UCLP patients was 48–59.3% [3, 8].

5.2 Orthodontic approach

In adolescent or adult UCLP patients with maxillary hypoplasia and deficient bone grafts, there are two maxillary segments separated by the cleft. Each segment has varying degrees of dysplasia on the sagittal, vertical, and horizontal directions.

Orthodontic treatment is carried out to both position the teeth perpendicular to the alveolar crest and level the alveolar segments using the teeth. Sometimes, it is not possible to achieve leveling of the bony segments, and it may be necessary to level the teeth into two separate segments, instead of a complete arch, and to prepare for leveling these segments by alveolar distraction osteogenesis or segmental orthognathic surgery (**Figure 2**).

In cases that present with sufficient bone grafting during the mixed dentition period, the maxilla is a single segment, and the orthodontist would only adapt the dental arch form to the existing basal bone.

There are substantial variations in the number of upper permanent incisors and the alveolar bone amount in the premaxilla of UCLP patients. The lateral incisor tooth on the cleft side was found normal in only 7% of UCLP cases [6], more frequently, when present, there are shape anomalies. In the presence of a weakly formed lateral incisor tooth, these teeth might need extraction for long-term functioning and better esthetics.

Figure 2.
UCLP patient [25]. A1-3: Before orthodontic preparation. Retrognathic and narrow maxilla, missing teeth (12, 22, 15 and 25), noticeable alveolar cleft, severe transverse and vertical dislocation of the smaller segment. B1-3: Orthodontic leveling of teeth in two separate segments. C1-3: Post-op continuous stainless-steel arch-wires. D1-3: Post-treatment vertical relapse to some extent.

Decision to extract the first premolar, which is another tooth near the cleft, is dependent on volume and height of the alveolar bone to accommodate the root of the canine adjacent to the cleft without irreversibly weakening its periodontal support, as well as the degree of crowding. Although extractions on the mandibular arch are sometimes obligatory due to crowding, extraction is usually not necessary in the mandibular arch. The disadvantage of closing a cleft-dental gap orthodontically or surgically is the shifting of the cleft segment toward the posterior, in a way that is the opposite of what is desired (to shifting forward of the posterior region).

As mentioned above, after leveling and aligning teeth with orthodontic treatment, models prepared by digitally or by using plaster are transferred to computer software/articulators. On these models, the maxillomandibular relation and occlusion are adjusted to an ideal position, and the advancement of the maxilla, rotation/setback of the mandible and vertical and transversal dimension amounts are assessed. As a result of these arrangements, splints are fabricated to use as a guide in orthognathic surgery, and the desired effects almost completely reflected on the surgery.

5.3 Surgical approach

Due to the prevalence of maxillary osteotomy complications in UCLP patients [38], confusing and complicated orthognathic surgery techniques were proposed for these patients [39–41]. Moreover, as in other aspects of orthognathic surgery, Hugo Obwegeser also provided contributions that could be explained as breakthroughs for skeletally cleft reconstruction [35, 42–44]. Toward the end of 1960s, he managed to advance the cleft maxilla by up to 20 mm to a desired position without needing a complicated mandibular setback approach. Then, he noticed that down-fracture and adequate mobilization of the maxilla, regardless of the presence or absence of a cleft, were the key in maxillary advancement [35]. The success of this approach achieved by Obwegeser was confirmed when Bell showed supply blood circulation to the down-fractured maxillae in their animal studies [45].

In the mid-1980s, Posnick used the Le Fort I techniques of Obwegeser for treatment of UCLP deformity and improved them [46]. The main issue was that the circumvestibular incision used by Obwegeser directly allowed dissection, osteotomies, disimpaction, fistula closure, septoplasty, inferior turbinate reduction, pyriform aperture recontouring, bone grafting, and application of plate and screw fixation. This was a reliable approach that did not have a circulation damage risk in smaller or larger flaps and had continuity [35]. Moreover, with the easiness of field of view provided by circumvestibular incision, it became possible to readily close the cleft-dental region by differential maxillary segmental repositioning without bone necrosis or loss of teeth. This method also closes the unoccupied space of the cleft, and at the same time, combines the labial and palatal flaps together without needing a subperiosteal undermining procedure, which allows closure of stubborn oronasal fistulae and establishment of periodontal health in the teeth adjacent to the cleft [35]. Today, although the surgical methods applied on UCLP patients differ depending on the success of grafting performed in the mixed dentition period, the main method are as follows:

5.3.1 Standard Le fort I osteotomy

An adolescent or adult CLP patient who has maxillary deformity but no residual fistula, in addition to an intact alveolar ridge with an adequate height in the cleft region may have been born without an alveolar cleft or had a successful grafting procedure [42]. A standard Le Fort I osteotomy may be applied on individuals who

have sufficient alveolar ridge height and volume, a close palate and sufficient periodontal support. Segmental maxillary osteotomy may also be needed in correction of arch width, repairing vertical dimensions or preventing the need for prosthetic lateral incisors by closing the cleft-dental gap.

Unfortunately, even in the twenty-first century, alveolar defects and oronasal fistulae are encountered in many adults and adolescents who have UCLP with maxillary hypoplasia. For these patients, a modified Le Fort I osteotomy should be considered [17].

5.3.2 Modified Le fort I osteotomy (two-segment)

In UCLP patients, the gap of the missing lateral incisor tooth may be eliminated by advancement of the lateral alveolar bone segment, where the canine tooth is placed adjacent to the central incisor tooth. After this, the canine is formed in a similar appearance to that of the lateral incisor [47]. This method that was described by Obwegeser in cases of unilateral cleft was advanced by Posnick in 1992 and name as the modified Le Fort I osteotomy method [46].

In the technique, first, a maxillary circumvestibular incision is made labially from a zygomatic buttress to another. In the residual oronasal fistula region, vertical incisions are made to separate the mucosa on both sides of the cleft as oral and nasal. These incisions are perpendicular to the horizontal vestibular incision, and they follow the line angles of the teeth adjacent to the cleft (central and canine). If the cleft bone was not previously repaired, the segments are already in two pieces with the down-fractured maxilla. If the maxilla is intact and the arch form needs to be adjusted, by using a reciprocating saw with a short and flat tip, the maxilla is divided into two pieces by cutting from the cleft area. The parts need to be brought closer to close the cleft-dental gap. However, this may be achieved only after shaving in the distal direction of the central incisor and along the mesial part of the canine from the alveola. Attention should be paid to ensure avoiding contact with the lamina dura as it would expose the root of teeth and may result in external root resorption. The maxillary segments are then stabilized with wires and acrylic occlusal splints. Repositioning of the segments closes the cleft-dental gap, gathers the alveolar ridges together, and gets the labial and palatal mucosal tissues closer for oral-fistula closure [17].

The extent of the maxillary advancement that is carried out by the surgeon is based on previously planned occlusion, airway needs, and preoperatively determined facial esthetics. The ideal vertical dimension is achieved based on the preoperative plan, but intraoperative approaches may be considered in some cases [35]. Maxillary osteotomy regions are fixed on all zygomatic buttresses and apertures by using titanium plates and screws based on the principles described by Luhr [48, 49]. If a graft has been used, an extra microplate is additionally applied to stabilize each interpositional cortico-cancellous (iliac) graft. For repairing facial asymmetries and secondary deformities, mandibular and jaw osteotomies are also frequently required in UCLP patients in addition to Le Fort I osteotomy.

6. Orthognathic approach on BCLP deformities

6.1 Prevalence

In the study that was carried out at Boston Pediatrics Hospital, it was stated that there was a need for maxillary advancement by orthognathic surgery in 76.5% adolescents whose BCLP had been repaired [3]. Moreover, the authors explained

that, in addition to the severity of the cleft type, the number of previous operations and extent of cleft area also affect the need for orthognathic surgery. Another study conducted at Toronto Pediatrics Hospital stated that there was a need for orthognathic surgery in 65.1% of their own BCLP patients, while this rate was 70% for patients who were referred by other centers [8]. From the Cleft Craniofacial Unit in Adelaide, Australia, David et al. [50] followed BCLP patient groups from birth to adulthood and determined the need for orthognathic surgery. Accordingly, orthognathic repair was needed in skeletal class III malocclusion among 17 of 19 patients (89.5%) and when they reached 18 years of age. Other previous studies also supported the findings of the aforementioned ones [51, 52].

6.2 Orthodontic approach

Different degrees of dysplasia in the sagittal, vertical, and horizontal directions are observed on the maxilla of patients without an ideal bone graft in the mixed dentition period that is divided into three segments. Before surgical treatment of maxillary segments, each segment is separately treated by an orthodontist. Before orthodontic treatment, cephalometric and panoramic radiography images are taken, and the angles, positions, and morphologies of teeth to soft tissues and bones are examined. In these patients, the volumes of the bones in the cleft region and the detailed position of teeth may be analyzed by additionally taking cone beam computerized tomography (CBCT) images.

BCLP patients have a broad variation in terms of the amount of dentoalveolar bone and the number of permanent teeth. Teeth that resemble lateral incisors are usually observed along the sides of the lateral segments. Due to the usually underdeveloped root structure of these teeth and their deformed crowns, extracting them is reasonable. Because of the deformed crowns and root structures of also the erupted supernumerary teeth found in the premaxilla of BCLP patients, it is usually appropriate to extract these during orthodontic treatment. In addition to this, only 7% of BCLP patients have lateral teeth with regular structure [6], and these are kept in the arch and moved to ideal position by the orthodontist.

Decision to extract the premolar teeth is dependent on the width and height of the present alveolar bone, position of canines, and the degree of crowding on the segments. In cases where inadequate bone and periodontal support remains or this support is substantially weakened after leveling and aligning the canines adjacent to the cleft, decision to extract of premolar teeth may be taken by the orthodontist. Aligning and leveling of the second molar teeth in addition to other maxillary teeth will increase the success of orthognathic surgery by improving the arch form and occlusion [35]. While extractions in the mandibular arch may be required based on the need for space on the arch and during the process of moving the incisors to an ideal angle, extraction is usually not necessary on the mandibular arch.

6.3 Surgical approach

Incomplete, insufficient definitions were presented by previous studies for surgical techniques used for the purpose of warning BCLP patients about possible complications regarding maxillary osteotomy and achieving reliable osteotomy operations [39, 53]. Hugo Obwegeser provided significant contributions which may be considered as milestones about cleft surgery on BCLP patients. However, at the early stages, very few clinicians adopted the methods of Obwegeser. This was because, as one of the eight patients he treated died of airway complications, and the results on the others were not reported in an appropriate manner, relevant studies criticized them [54]. In the mid-1980s, Posnick described a safe method of

the segmental Le Fort I osteotomy technique that considers biological principles in BCLP patients with maxillomandibular deformities [17, 55, 56]. This method, for instance, emphasizes preservation of the labial soft tissue mucosal pedicle in the maxillary of patients. The significance of this flap circulation that is achieved by considering biological principles was confirmed in the study by Bell et al. that was carried out on Rhesus monkeys [38].

Mainly, in BCLP patients, clinicians encounter maxillary deformities including those that are intact on both sides (successfully grafted) with one alveolar ridge, those with two segments with one side intact (successfully grafted), and those with three segments that are failed/non-grafted, and they apply different orthognathic surgery methods for these.

6.3.1 Standard Le fort I osteotomy

Patients in cases of BCLP may have intact alveolar ridges on both sides, one intact alveolar ridge on only one side or alveolar clefts that have been successfully grafted during mixed dentition. In adolescents or adults with maxillomandibular deformity and intact alveolar ridges on both sides, a standard Le Fort I down-fracturing technique performs to advance maxillary hypoplasia.

6.3.2 Modified Le fort I osteotomy (two-segment)

In an individual with BCLP, a unilaterally intact alveolar ridge (with residual alveolar cleft and oronasal fistula on the other side) shows the same anatomy as those in a UCLP patient. The surgical approach for such a patient is the same as that which is applied for a UCLP patient with separated segments. For patients who are born with BCLP and non-grafted alveolar arches, the modified Le Fort I Osteotomy (three-segment) procedure should be applied.

6.3.3 Modified Le fort I osteotomy (three-segment)

Unfortunately, a big part of patients who have BCLP maxillomandibular deformities are still observed to have alveolar clefts, residual oronasal fistulae, and mobile premaxilla. While carrying out a Le Fort I osteotomy procedure on a BCLP patient with non-grafted alveolar arches, accurate incisions has a critical importance for providing all three segments with blood circulation [17].

In the technique, on each side, a buccal (labiolateral) incision is made from the zygomatic buttresses (anterior and gingival levels of the parotid canal) in the depth of the vestibule extending toward the location of the residual oronasal fistula. Then, vertical incision continues according to mesial angle of the canine (or if the canine is missing, the most mesial tooth on each lateral segment). Without completely separating the premaxilla, an intermediate splint is placed to fix the lateral segments. The premaxilla is to be included to the vestibular incisions at the posterior with angular, vertical incisions in its labial direction, and to separate the oral and nasal mucosa of the fistulae even further, the incision continues downward along the distal line angle of the central incisor teeth on both sides. Attention should be paid to prevent deformation or incision of the mucosa in the premaxilla. Shavings are made from the segments to get the hard and soft tissues closer to each other. While doing this, one should be careful not to damage the lamina dura of the existing teeth. After completion of the premaxillary segment and other adjustments, the final splint is placed, and the segments are fixed with titanium plates and screws [17]. If there is grafting, an additional microplate is also needed to stabilize each cortico-cancellous (iliac) graft. To repair facial asymmetries, mandibular deformations, and secondary

deformities, mandibular surgery may also be needed in addition to Le Fort I osteotomy in BCLP patients.

7. Orthognathic approach on ICP deformities

7.1 Prevalence

It was reported that 20% of Caucasians with ICP who receive repairs in the period of infancy would experience maxillary hypoplasia in a way that would lead to malocclusions that do not respond to a conventional or compensatory orthodontic approach by itself [36]. Chen et al. [57] reported on the horizontal maxillary growth of both children and adults with ethnic origins of Eastern China who were operated/not operated. Accordingly, as an interesting finding, the results of the individuals with ICP who were not operated in the mixed dentition period showed an almost normal horizontal growth. In the patients who were operated (repaired cleft palate) in the mixed dentition period, there was a decrease in the clockwise rotation of the maxillomandibular complex. In addition to this, it was stated that, for an individual born with ICP, the prevalence of maxillomandibular deficiency is dependent on a combination of factors such as the internal structure of the primary cleft defect, secondary hypoplasia due to surgical repair at infancy, and functional factors (e.g., muscle effects – mastication, respiratory pattern, and mandibular resting posture) [58].

7.2 Orthodontic approach

The main purpose of orthodontic treatment before surgery in ICP patients is to eliminate all existing dental compensations. This is because, conducting camouflage treatment in these patients threatens periodontal health and may cause to relapse and resorption in teeth. Inclination and angulation of the maxillary and mandibular teeth, crowding, gaps, and rotations are organized throughout the orthodontic treatment process. The targets related to achieving ideal arch forms and ideal occlusion may be detailed after the operation. Extractions may be needed in the maxillary arch to eliminate dental compensations. In comparison to UCLP or BCLP patients, treatment is simpler in ICP patients due to the intact nature of the alveolar bone and because all teeth are usually present.

7.3 Surgical approach

In general, primary maxillomandibular deformity that is seen in ICP patients is maxillary hypoplasia that is caused by the cleft deformity and surgical interventions. The normal reconstructive procedure that needs to be considered in these patients is a Le Fort I maxillary osteotomy. Obwegeser stated that complete mobilization of maxilla that are down fractured is needed to achieve an orthognathic repair during surgery and decrease skeletal relapse [35]. Bell and Levy [45] confirmed that the Obwegeser Le Fort I technique allows sufficient blood diffusion for satisfactory bone recovery without aseptic necrosis or tooth injury.

It would be difficult to close any residual palatal oronasal fistula in an ICP patient at the same time with the Le Fort I procedure during orthognathic surgery. The reason for this is that elevation of the palatal flaps that is usually needed will threaten the blood supply for the down-fractured maxilla. Moreover, it was stated that, if an impermeable closure of the nasal side can be achieved following down-fracturing before fixing the maxilla to its new position, the residual mucosal gap on the palatal side will usually be recovered secondarily by fistula closure [35].

8. Post-surgery clinical management

Management of the process at the hospital and at home during the initial recovery process of the orthognathic patient is highly important for a successful outcome. Cephalometric and dental radiographies and facial and occlusal photographs should be taken at certain intervals after the surgery in order to documentation and check the patient's recovery [17].

Orthodontist should remove the splint and see the patient in the next 24 hours to replace the maxillary segmental arch wires or rigid continuous arch wires. The maxillary teeth are tied to each other to preserve the occlusion, sagittal advancement, and transversal dimension. After 2 months of surgery, active orthodontic treatment and finishing procedures can be continued. A trans-palatal appliance (wire or palatal appliance) is recommended to stabilize the new arch form. The orthodontist should closely monitor the patients throughout the 6 months following the surgery to follow up on skeletal and dental relapse and to maintain orthodontic treatment [17].

In routine and unproblematic cases, splint usage is abandoned in about 5–7 after the surgery. However, in patients with early skeletal relapse, that is, within the first 2–8 weeks, the teeth are forced in the buccolingual direction toward outside of the bone because the teeth are held in place due to splint despite the alveolar relapse, and severe gingival recessions may occur (**Figure 3**). Therefore, CLP patients should be observed every week, unlike other orthognathic surgical patients. It should be kept in mind that the relapse rates given in the literature are averages, and it is possible to see more of these amounts in individual cases.

Speech may be objectively assessed in 3–6 months after the surgery. A nasal endoscopy may be used for this. Exact cleft-soft tissue procedures (e.g., cleft rhinoplasty, revision of the labial scar, pharyngeal flap or flap revision) may be carried out in 6 months after the operation. After removal of orthodontic appliances, pre-planned restorative approaches may be implemented [17].

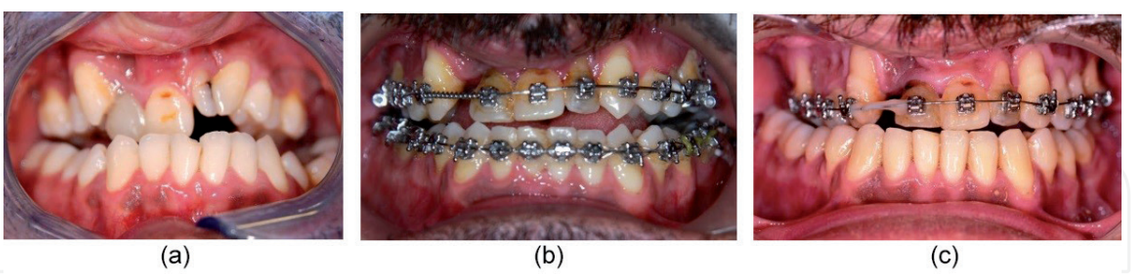

Figure 3.
Periodontal tissue loss due to relapse [25]. (a) Initial: Patient with UCLP, maxillary hypoplasia, severe crowding, missing lateral, and asymmetric arch form. (b) Pre-op: Periodontal problems after expansion and leveling. (c) Post-op: Both transverse and sagittal skeletal relapse occur while teeth are locked within the arch-wire and surgical splint, which deteriorates the periodontal condition. The midline was surgically corrected.

9. Success of orthognathic surgery

After orthognathic surgery, cleft patients have a higher than normal risk of relapse due to factors such as different soft tissue-bone relations and complex mobilization vectors. Fahradyan et al. [59] reported that, in comparison to class III malocclusion patients without clefts, more relapse was encountered in those with

clefts (1.25 mm or more on average), and there was a significant positive correlation between larger clefts and horizontal relapse. In their study, the mean relapse rate was similar among different types of clefts, and in the case of each 1 mm increase in maxillary advancement, horizontal relapse increased by 0.3 mm on average [59].

Richardson et al. [60] examined all relapse cases among individuals where more than 11 mm of maxillary advancement was applied, and they reported a horizontal relapse rate of 18.75%. Nevertheless, Bhatia et al. [61] concluded that relapse rates stayed the same even in maxillary advancement degrees of more than 15 mm (mostly in cleft patients). Yamaguchi et al. [62] reported in their systematic review that the mean values of horizontal and vertical relapse were, respectively, 17.9% and 35.4% in orthodontic surgery for cleft patients. This shows us that vertical stability is lower.

Although most studies focused on horizontal maxillary stability, Park et al. [63] reported that postoperative mandibular relapse in cleft patients had a strong positive correlation with mandibular clockwise rotation and setback amounts. Wong et al. [64] could not find a significant difference between the relapse rates of individuals who received two surgical operations and those who received maxillary advancement surgery only. Some researchers used bone grafts to increase horizontal or vertical stability [61, 63, 64]. It was reported that usage of grafts has a preventive effect on horizontal maxillary stability with an average of 1.72 mm less relapse [61].

10. Complications

10.1 Airway problems

Treatment of cleft patients with class III malocclusion that results out of the combination of maxillary hypoplasia and intermaxillary disorder is usually achieved by maxillary advancement, mandibular setback, and clockwise rotation of the maxillomandibular complex. While maxillary advancement is associated with increased upper airway cavity, in contrast, mandibular setback is associated with reduction of airways with outcomes such as postoperative airway blockage, snoring, hypopnea (slow respiration), and obstructive sleep apnoea [65, 66]. Additionally, a pharyngeal flap may contribute to the airway-related difficulties that are encountered during operation or in the postoperative period. When the three-dimensional (3D) pharyngeal airway cavity of cleft patients in their pre- or post-pubertal periods were compared to a control group, Karia et al. [66] found significantly smaller airway sizes in the cleft group. The total airway volume increased from the pre-pubertal to the post-pubertal periods in both groups, but the reason for this outcome in the cleft group was not anteroposterior growth as in the case of the control group, but in contrast, associated with vertical airway growth. Especially in bilateral cleft patients, significantly reduced pharyngeal airway cavity in comparison to individuals without clefts was also confirmed in a CBCT study [67].

A prospective study by Chang et al. [68] examined the airway changes in cleft patients who received maxillary advancement and mandibular setback treatments by not only CBCT but also polysomnographic examination. Regarding the airway changes after orthognathic surgery, it was found that there was no significant difference in sleep-related respiratory functions, but the snoring index was improved.

10.2 Speech impediment

It is believed that maxillary advancement in cleft patients has a potential to worsen velopharyngeal function (VPF). Nevertheless, there is still no certain evidence on whether or not the amount of advancement affects velopharyngeal disorder and whether or not preoperative VPF is related to the postoperative outcome. It is most likely that improvements are seen in the articulation of patients after surgery due to the correction of dental arches [69]. In a systematic review of the complications that developed as a result of orthognathic surgery on cleft patients, Yamaguchi et al. [62] reported postoperative velopharyngeal deficiency (VPD) as 16.79%.

Moran et al. [70] examined 79 cleft patients who received treatments of conventional orthognathic surgery or distraction osteogenesis, and they reported that, following maxillary advancement rates from 3 to 11 mm, there was VPD in 5 (6.33%) cases. These five patients were also found to have borderline VPD preoperatively. The results of their study supported those of other studies that there is no relationship between maxillary advancement and the amount of postoperative velopharyngeal disorders [71], and when orthognathic surgery and total maxillary distraction are compared in terms of speech and VPD, there is no significant difference [71–73]. Additionally, the finding that there is no correlation between postoperative speech impediment and preoperative borderline VPD was added to the literature which reported similar findings [71–73].

It is a difficult process to estimate soft tissue changes after orthognathic surgery and prevent them. This is because the adaptation of the velopharyngeal region for compensation of other regions is variable, and it is dependent on the personal characteristics of each patient and the capacity of tissues that are present or transplanted to become functional [74].

10.3 Infection

Infection rates following orthognathic surgery are highly variable due to reasons such as antibiotics usage styles and diagnostic differences [75, 76]. Recent studies on orthognathic surgery in individuals without clefts reported an incidence of less than 1–8% [76–78].

Miloro derived a few results by analyzing 15 previous studies on infections following orthognathic surgery: infection incidence may decrease in the case of using oral antibiotics for more than 1 day after surgery. First-generation cephalosporins are used more frequently before surgery. Mandibular osteotomy regions are where infections are seen the most. Extraction of the third molar may have a small effect on infection incidence, but this is under debate. Most infections that occur after orthognathic surgery are small, and removal of fixation plates and screws is rarely necessary [75].

In an analysis of the USA National Inpatient Samples Database (2012–2013), the rate of emergence for any kind of infectious complication following orthognathic surgery was reported as 7.4% in patients with a craniofacial anomaly and 0.6% in those without a craniofacial anomaly [78]. Recent studies reported rates of from 0to 13.92% for infections emerging after orthognathic surgery in cleft patients without any craniofacial anomaly [61, 62, 68, 70]. In the study that obtained a high rate of incidence as 13.92% despite 5 days of routine antibiotics usage, the authors emphasized the importance of oral hygiene, team collaboration, and patient cooperation [70].

10.4 Oronasal fistula

Segmental maxillary osteotomies may have a risk of postoperative oronasal fistulae. In a systematic review in 2017, the postoperative fistula rate was reported as 19.3% in segmental Le Fort I osteotomy [79]. While residual oronasal fistulae in cleft patients increase the difficult of orthognathic surgery, they may be repaired by adjusting the incision patterns during surgery. In addition to this, according to the systematic review in 2016 by Yamaguchi et al. [62], the closure deficiency of a pre-existing fistulae (28.57% for palatal, 10.74% for alveolar fistulae) was the most frequently encountered complication. Another study reported a residual fistulae rate of 10.53% [70]. Nevertheless, residual fistulae rates may be reduced by careful dissection, unstressed closure, delicate tissue management, and compliance with blood circulation [80].

10.5 Nerve damage

The neural disorders that occur as a result of orthognathic surgery mainly affect the infraorbital, inferior alveolar (mandibular), and mental and incisive nerves. Reports on facial nerve paralysis vary in the range of 0.17–0.75% [81].

The incidence of continuation of inferior alveolar nerve disorders varies between 5 and 15% depending on the age of the patient and the technique that is used (piezo-surgery or conventional) [82, 83]. A systematic review in 2017 reported that usage of piezo-surgery in orthognathic operations was associated with significant reductions of loss of blood during surgery and severe nervous disorders [84].

In orthognathic surgery on cleft patients, 70% of the patients may experience paresthesia after surgery, and a permanent sensory disorder may occur in 25% [80]. Bhatia et al. [61] stated that all 25% of patients who experienced cheek paresthesia recovered after a year. Moran et al. [70] reported that the sensory neuropathy of the infraorbital nerve was temporary in 53% of patients and permanent in 1.27%. In addition to this, 3D computer-assisted planning and determination of the inferior alveolar nerve may contribute to the safety of orthognathic surgery [85].

11. Conclusion

Orthognathic surgery, which is the last stage of CLP treatment, is a highly important step in management of the entire process. Therefore, there should be good communication among the patient, the family, and the cleft team. There are effects of factors that are unique to individuals or clefts on the outcomes of surgery, but their extent is still under debate.

Despite the different rates reported in the literature, the rates of complications in cleft surgery are striking. Strategies should be created by focusing on causes and mechanisms to prevent or minimize these complications.

IntechOpen

IntechOpen

Author details

Hakan Yilmaz* and Arzu Ari Demirkaya
Department of Orthodontics, Faculty of Dentistry, Istanbul Okan University, Istanbul, Turkey

*Address all correspondence to: hakanyilmaz90@gmail.com

IntechOpen

© 2019 The Author(s). Licensee IntechOpen. This chapter is distributed under the terms of the Creative Commons Attribution License (http://creativecommons.org/licenses/by/3.0), which permits unrestricted use, distribution, and reproduction in any medium, provided the original work is properly cited. CC BY

References

[1] Broome M, Herzog G, Hohlfeld J, de Buys Roessingh A, Jaques B. Influence of the primary cleft palate closure on the future need for orthognathic surgery in unilateral cleft lip and palate patients. The Journal of Craniofacial Surgery. 2010;**21**(5):1615-1618

[2] Rosenstein SW, Grasseschi M, Dado DV. A long-term retrospective outcome assessment of facial growth, secondary surgical need, and maxillary lateral incisor status in a surgical-orthodontic protocol for complete clefts. Plastic and Reconstructive Surgery. 2003;**111**(1):1-13; discussion 4-6

[3] Good PM, Mulliken JB, Padwa BL. Frequency of Le fort I osteotomy after repaired cleft lip and palate or cleft palate. The Cleft Palate-Craniofacial Journal. 2007;**44**(4):396-401

[4] Filho LC, Normando ADC, Da Silva Filho OG. Isolated influences of lip and palate surgery on facial growth: Comparison of operated and unoperated male adults with UCLP. The Cleft Palate-Craniofacial Journal. 1996;**33**(1):51-56

[5] Astani SA, Yilmaz HN, Nevzatoglu S, Demirkaya AA, Acar ZA. Evaluation of airway volume in cleft lip and palate following nasoalveolar molding. The Journal of Craniofacial Surgery. 2018;**29**(8):2143-2147

[6] Cassolato SF, Ross B, Daskalogiannakis J, Noble J, TompsonB.Treatmentofdentalanomalies in children with complete unilateral cleft lip and palate at SickKids hospital, Toronto. The Cleft Palate-Craniofacial Journal. 2009;**46**(2):166-172

[7] McCance AM, Roberts-Harry D, Sherriff M, Mars M, Houston WJ. A study model analysis of adult unoperated Sri Lankans with unilateral cleft lip and palate. The Cleft Palate Journal. 1990;**27**(2):146-154

[8] Daskalogiannakis J, Mehta M. The need for orthognathic surgery in patients with repaired complete unilateral and complete bilateral cleft lip and palate. The Cleft Palate-Craniofacial Journal. 2009;**46**(5):498-502

[9] Swennen G, Colle F, De AM, Malevez C. Maxillary distraction in cleft lip palate patients: A review of six cases. The Journal of Craniofacial Surgery. 1999;**10**(2):117-122

[10] Wolford LM. Effects of orthognathic surgery on nasal form and function in the cleft patient. The Cleft Palate-Craniofacial Journal. 1992;**29**(6):546-555

[11] Kuo-Ting Chen P, Por Y-C, Jein-Wein Liou E, Chun-Shin Chang F. Maxillary distraction osteogenesis in the adolescent cleft patient: Three-dimensional computed tomography analysis of linear and volumetric changes over five years. The Cleft Palate-Craniofacial Journal. 2011;**48**(4):445-454

[12] Figueroa AA, Polley JW, Ko EW-C. Maxillary distraction for the management of cleft maxillary hypoplasia with a rigid external distraction system. Seminars in Orthodontics. 1999;**5**(1):46-51

[13] Posnick JC, Tiwana PS. Cleft-Orthognathic Surgery. In: Berkowitz S editor. Cleft Lip and Palate. Heidelberg, Berlin: Springer; 2006. pp. 573-585

[14] Harper DC. Children's attitudes to physical differences among youth from Western and non-Western cultures. The Cleft Palate-Craniofacial Journal. 1995;**32**(2):114-119

[15] Jorgenson R, Shapiro S, Odinet K. Studies on facial growth and arch size in cleft lip and palate.

Journal of Craniofacial Genetics and Developmental Biology. 1984;**4**(1):33-38

[16] Mccance AM, Moss JP, Fright WR, Linney AD, James DR. Three-dimensional analysis techniques—Part 1: Three-dimensional soft-tissue analysis of 24 adult cleft palate patients following Le fort I maxillary advancement: A preliminary report. The Cleft Palate-Craniofacial Journal. 1997;**34**(1):36-45

[17] Posnick JC. Principles and Practice of Orthognathic Surgery. London, United Kingdom: Elsevier Health Sciences; 2013

[18] Siegel-Sadewitz V, Shprintzen R. Nasopharyngoscopy of the normal velopharyngeal sphincter: An experiment of biofeedback. The Cleft Palate Journal. 1982;**19**(3):194-200

[19] Vallino LD, Tompson B. Perceptual characteristics of consonant errors associated with malocclusion. Journal of Oral and Maxillofacial Surgery. 1993;**51**(8):850-856

[20] Proffit W, editor. Orthodontic Treatment of Clefts: Yesterday, Today, and Tomorrow. Proceedings of the 48th Annual Meeting. American Cleft Palate-Craniofacial Association Hilton Head; 1991

[21] Warren DW. Perceptual characteristics of consonant errors associated with malocclusion. Journal of Oral and Maxillofacial Surgery. 1993;**51**(8):856

[22] Sandham A, Murray J. Nasal septal deformity in unilateral cleft lip and palate. The Cleft Palate-Craniofacial Journal. 1993;**30**(2):222-226

[23] Kolbenstvedt A, Aaløkken T, Arctander K, Johannessen S. CT appearances of unilateral cleft palate 20 years after bone graft surgery. Acta Radiologica. 2002;**43**(6):567-570

[24] Trindade IE, Yamashita RP, Suguimoto RM, Mazzottini R, Trindade AS Jr. Effects of orthognathic surgery on speech and breathing of subjects with cleft lip and palate: Acoustic and aerodynamic assessment. The Cleft Palate-Craniofacial Journal. 2003;**40**(1):54-64

[25] Yilmaz H, Demirkaya AA. Dudak damak yarığında ortognatik cerrahi. Turkiye Klinikleri Orthodontics-Special Topics. 2019;**5**(1):34-41

[26] Stoelinga PJ, Leenen RJ, Blijdorp PA, Schoenaers JH, Team CP. The prevention of relapse after maxillary osteotomies in cleft palate patients. Journal of Cranio-Maxillofacial Surgery. 1987;**15**:326-331

[27] Posnick JC. The treatment of secondary and residual dentofacial deformities in the cleft patient. Surgical and orthodontic therapy. Clinics in Plastic Surgery. 1997;**24**(3):583-597

[28] Robertsson S, Mohlin B. The congenitally missing upper lateral incisor. A retrospective study of orthodontic space closure versus restorative treatment. The European Journal of Orthodontics. 2000;**22**(6):697-710

[29] Suzuki A, Takahama Y. Maxillary lateral incisor of subjects with cleft lip and/or palate: Part 1. The Cleft Palate-Craniofacial Journal. 1992;**29**(4):376-379

[30] Suzuki A, Watanabe M, Nakano M, Takahama Y. Maxillary lateral incisors of subjects with cleft lip and/or palate: Part 2. The Cleft Palate-Craniofacial Journal. 1992;**29**(4):380-384

[31] Laspos CP, Kyrkanides S, Tallents RH, Moss ME, Subtelny JD. Mandibular and maxillary asymmetry in individuals with unilateral cleft lip and palate. The Cleft Palate-Craniofacial Journal. 1997;**34**(3):232-239

[32] Nordquist GG, McNeill RW. Orthodontic vs. restorative treatment of the congenitally absent lateral incisor—Long term periodontal and occlusal evaluation. Journal of Periodontology. 1975;**46**(3):139-143

[33] Felstead AM, Deacon S, Orth M, Revington PJ. The outcome for secondary alveolar bone grafting in the south West UK region post-CSAG. The Cleft Palate-Craniofacial Journal. 2010;**47**(4):359-362

[34] McIntyre GT, Devlin MF. Secondary alveolar bone grafting (CLEFTSiS) 2000-2004. The Cleft Palate-Craniofacial Journal. 2010;**47**(1):66-72

[35] Posnick JC. Cleft Jaw Deformities and their Management. Cleft Lip and Palate. Heidelberg, Berlin: Springer; 2013. pp. 557-599

[36] Åbyholm FE, Bergland O, Semb G. Secondary bone grafting of alveolar clefts: A surgical/orthodontic treatment enabling a non-prosthodontic rehabilitation in cleft lip and palate patients. Scandinavian Journal of Plastic and Reconstructive Surgery. 1981;**15**(2):127-140

[37] Ross RB. Treatment variables affecting facial growth in complete unilateral cleft lip and palate. Part 7: An overview of treatment and facial growth. The Cleft Palate Journal. 1987;**24**:71-77

[38] Bell WH, You ZH, Finn RA, Fields RT. Wound healing after multisegmental Le fort I osteotomy and transection of the descending palatine vessels. Journal of Oral and Maxillofacial Surgery. 1995;**53**(12):1425-1433

[39] Fitzpatrick B. Mid-face osteotomy in the adolescent cleft palate patient. Australian Dental Journal. 1977;**22**(5):338-350

[40] James DR, Brook K. Maxillary hypoplasia in patients with cleft lip and palate deformity—The alternative surgical approach. The European Journal of Orthodontics. 1985;**7**(4):231-247

[41] Westbrook MT Jr, West RA, McNeill RW. Simultaneous maxillary advancement and closure of bilateral alveolar clefts and oronasal fistulas. Journal of Oral and Maxillofacial Surgery. 1983;**41**(4):257-260

[42] Drommer RB. The history of the "Le fort I osteotomy". Journal of Maxillofacial Surgery. 1986;**14**:119-122

[43] Obwegeser H, editor. Surgical Correction of Deformities of the Jaws in Adult Cleft Cases. First International Conference on Cleft Lip and Palate. Houston; 1969

[44] Obwegeser HL, editor Surgery as an Adjunct Ot Orthodontics in Normal and Cleft Palate Patients. Report of the Congress European Orthodontic Society; 1966

[45] Bell W, Levy B. Revascularization and bone healing after posterior maxillary osteotomy. Journal of Oral Surgery. 1971;**29**(5):313-320

[46] Posnick JC, Tompson B. Modification of the maxillary Le fort I osteotomy in cleft-orthognathic surgery: The unilateral cleft lip and palate deformity. Journal of Oral and Maxillofacial Surgery. 1992;**50**(7):666-675

[47] Obwegeser HL. Orthognathic surgery and a tale of how three procedures came to be: A letter to the next generations of surgeons. Clinics in Plastic Surgery. 2007;**34**(3):331-355

[48] Champy M. Surgical treatment of midface deformities. Head & Neck Surgery. 1980;**2**(6):451-465

[49] Lund TW, Wade M. Use of osseointegrated implants to support

a maxillary denture for a patient with repaired cleft lip and palate. The Cleft Palate-Craniofacial Journal. 1993;**30**(4):418-420

[50] David DJ, Anderson PJ, Schnitt DE, Nugent MA, Sells R. From birth to maturity: A group of patients who have completed their protocol management. Part II. Isolated cleft palate. Plastic and Reconstructive Surgery. 2006;**117**(2):515-526

[51] Friede H, Pruzansky S. Long-term effects of premaxillary setback on facial skeletal profile in complete bilateral cleft lip and palate. The Cleft Palate Journal. 1985;**22**(2):97-105

[52] Lisson JA, Tränkmann J. Comparative survey of osteotomized and nonosteotomized BCLP patients. The Cleft Palate-Craniofacial Journal. 1997;**34**(5):430-437

[53] Poole MD, Robinson PP, Nunn ME. Maxillary advancement in cleft palate patients: A modification of the Le fort I osteotomy and preliminary results. Journal of Maxillofacial Surgery. 1986;**14**:123-127

[54] Willmar K. On Le fort I osteotomy; a follow-up study of 106 operated patients with maxillo-facial deformity. Scandinavian Journal of Plastic and Reconstructive Surgery. 1974;**12** (suppl 12):1

[55] Posnick JC. Orthognathic surgery for the cleft lip and palate patient. Seminars in Orthodontics. 1996;**2**(3):205-214

[56] Posnick JC, Tompson B. Modification of the maxillary Le fort I osteotomy in cleft-orthognathic surgery: The bilateral cleft lip and palate deformity. Journal of Oral and Maxillofacial Surgery. 1993;**51**(1):2-11

[57] Chen Z-Q, Qian Y-F, Wang G-M, Shen G. Sagittal maxillary growth in patients with unoperated isolated cleft palate. The Cleft Palate-Craniofacial Journal. 2009;**46**(6):664-667

[58] Canady JW, Thompson SA, Colburn A. Craniofacial growth after latrogenic cleft palate repair in a fetal ovine model. The Cleft Palate-Craniofacial Journal. 1997;**34**(1):69-72

[59] Fahradyan A, Wolfswinkel EM, Clarke N, Park S, Tsuha M, Urata MM, et al. Impact of the distance of maxillary advancement on horizontal relapse after orthognathic surgery. The Cleft Palate-Craniofacial Journal. 2018;**55**(4):546-553

[60] Richardson S, Krishna S, Khandeparker RV. A comprehensive management protocol to treat cleft maxillary hypoplasia. Journal of Cranio-Maxillofacial Surgery. 2018;**46**(2):356-361

[61] Bhatia S, Bocca A, Jones J, Sugar AW. Le fort I advancement osteotomies of 1 cm or more. How safe or stable? The British Journal of Oral & Maxillofacial Surgery. 2016;**54**(3):346-350

[62] Yamaguchi K, Lonic D, Lo L-J. Complications following orthognathic surgery for patients with cleft lip/palate: A systematic review. Journal of the Formosan Medical Association. 2016;**115**(4):269-277

[63] Park Y-H, Seo J-H, Yang I-H, Choi J-Y, Lee J-H, Kim M-J, et al. What are the contributing factors for postsurgical relapse after two-jaw surgery in patients with cleft lip and palate. The Journal of Craniofacial Surgery. 2017;**28**(4):1071-1077

[64] Wong F, Heggie A, Shand J, Schneider P. Skeletal stability of maxillary advancement with and without a mandibular reduction in the cleft lip and palate patient. International Journal of

Oral and Maxillofacial Surgery. 2016;**45**(12):1501-1507

[65] Gerbino G, Gervasio FC, Blythe J, Bianchi FA. The management of iatrogenic obstructive sleep apnoea syndrome following bimaxillary surgery in a patient with cleft lip and palate. The Journal of Craniofacial Surgery. 2016;**27**(5):1286-1288

[66] Karia H, Shrivastav S, Karia AK. Three-dimensional evaluation of the airway spaces in patients with and without cleft lip and palate: A digital volume tomographic study. American Journal of Orthodontics and Dentofacial Orthopedics. 2017;**152**(3):371-381

[67] Gandedkar NH, Chng CK, Basheer MA, Chen PY, Leng Yeow VK. Comparative evaluation of the pharyngeal airway space in unilateral and bilateral cleft lip and palate individuals with noncleft individuals: A cone beam computed tomography study. The Cleft Palate-Craniofacial Journal. 2017;**54**(5):509-516

[68] Chang C-S, Wallace CG, Hsiao Y-C, Hsieh Y-J, Wang Y-C, Chen N-H, et al. Airway changes after cleft orthognathic surgery evaluated by three-dimensional computed tomography and overnight polysomnographic study. Scientific Reports. 2017;**7**(1):12260

[69] Richardson S, Seelan NS, Selvaraj D, Khandeparker RV, Gnanamony S. Perceptual speech assessment after anterior maxillary distraction in patients with cleft maxillary hypoplasia. Journal of Oral and Maxillofacial Surgery. 2016;**74**(6):1239. e1-e9

[70] Moran I, Virdee S, Sharp I, Sulh J. Postoperative complications following LeFort 1 maxillary advancement surgery in cleft palate patients: A 5-year retrospective study. The Cleft Palate-Craniofacial Journal. 2018;**55**(2):231-237

[71] Chua H, Whitehill T, Samman N, Cheung L. Maxillary distraction versus orthognathic surgery in cleft lip and palate patients: Effects on speech and velopharyngeal function. International Journal of Oral and Maxillofacial Surgery. 2010;**39**(7):633-640

[72] McComb RW, Marrinan EM, Nuss RC, LaBrie RA, Mulliken JB, Padwa BL. Predictors of velopharyngeal insufficiency after Le fort I maxillary advancement in patients with cleft palate. Journal of Oral and Maxillofacial Surgery. 2011;**69**(8):2226-2232

[73] Phillips JH, Klaiman P, Delorey R, MacDonald DB. Predictors of velopharyngeal insufficiency in cleft palate orthognathic surgery. Plastic and Reconstructive Surgery. 2005;**115**(3):681-686

[74] Wu Y, Wang X, Ma L, Li Z. Velopharyngeal configuration changes following Le fort I osteotomy with maxillary advancement in patients with cleft lip and palate: A cephalometric study. The Cleft Palate-Craniofacial Journal. 2015;**52**(6):711-716

[75] Miloro M. Surgical site infections after orthognathic surgery. Journal of Oral and Maxillofacial Surgery. 2017;**75**(6):1101-1103

[76] Posnick JC, Choi E, Chavda A. Surgical site infections following bimaxillary orthognathic, osseous genioplasty, and intranasal surgery: A retrospective cohort study. Journal of Oral and Maxillofacial Surgery. 2017;**75**(3):584-595

[77] Davis CM, Gregoire CE, Steeves TW, Demsey A. Prevalence of surgical site infections following orthognathic surgery: A retrospective cohort analysis. Journal of Oral and Maxillofacial Surgery. 2016;**74**(6):1199-1206

[78] Metalwala Z, Okunseri C, Fletcher S, Allareddy V. Orthognathic surgical outcomes in patients with and without craniofacial anomalies. Journal of Oral and Maxillofacial Surgery. 2018;**76**(2):436. e1-e8

[79] Junior OH, Guijarro-Martínez R, de Sousa Gil A, da Silva Meirelles L, de Oliveira R, Hernandez-Alfaro F. Stability and surgical complications in segmental Le fort I osteotomy: A systematic review. International Journal of Oral and Maxillofacial Surgery. 2017;**46**(9):1071-1087

[80] Ohrmann D, Hoyte-Williams PE, Chen PK-T. Update on complications in cleft orthognathic surgery. Current Opinion in Otolaryngology & Head and Neck Surgery. 2018;**26**(4):260-265

[81] Kim Y-K. Complications associated with orthognathic surgery. Journal of the Korean Association of Oral and Maxillofacial Surgeons. 2017;**43**(1):3-15

[82] Landes CA, Stübinger S, Rieger J, Williger B, Ha TKL, Sader R. Critical evaluation of piezoelectric osteotomy in orthognathic surgery: Operative technique, blood loss, time requirement, nerve and vessel integrity. Journal of Oral and Maxillofacial Surgery. 2008;**66**(4):657-674

[83] Verweij J, Mensink G, Fiocco M, van Merkesteyn J. Incidence and recovery of neurosensory disturbances after bilateral sagittal split osteotomy in different age groups: A retrospective study of 263 patients. International Journal of Oral and Maxillofacial Surgery. 2016;**45**(7):898-903

[84] Pagotto LEC, de Santana Santos T, de Vasconcellos SJA, Santos JS, Martins-Filho PRS. Piezoelectric versus conventional techniques for orthognathic surgery: Systematic review and meta-analysis. Journal of Cranio-Maxillofacial Surgery. 2017;**45**(10):1607-1613

[85] Lonic D, Pai BC-J, Yamaguchi K, Chortrakarnkij P, Lin H-H, Lo L-J. Computer-assisted orthognathic surgery for patients with cleft lip/palate: From traditional planning to three-dimensional surgical simulation. PLoS One. 2016;**11**(3):e0152014