

We are IntechOpen, the world's leading publisher of Open Access books Built by scientists, for scientists

6,900

Open access books available

186,000

International authors and editors

200M

Downloads

Our authors are among the

154

Countries delivered to

TOP 1%

most cited scientists

12.2%

Contributors from top 500 universities



WEB OF SCIENCE™

Selection of our books indexed in the Book Citation Index
in Web of Science™ Core Collection (BKCI)

Interested in publishing with us?
Contact book.department@intechopen.com

Numbers displayed above are based on latest data collected.
For more information visit www.intechopen.com



Poor-Grade Aneurysmal Subarachnoid Hemorrhage: Diagnosis, Therapeutical Management, and Prognosis

*Bing Zhao, Haixia Xing, Shenghao Ding, Yaohua Pan
and Jieqing Wan*

Abstract

Aneurysmal subarachnoid hemorrhage (aSAH) is a devastating neurological condition and these patients often have unfavorable outcomes at the long-term follow-up. Poor-grade aSAH is a severe subtype of aSAH and is defined as World Federation of Neurosurgical Surgeon (WFNS) grade IV or V. All patients should be treated by a multidisciplinary team that consists of vascular neurosurgeons, interventional neuroradiologists, neurologists, and anesthesiologists. Aneurysm rebleeding occurs in the poor-grade aSAH within the first 72 h after ictus. Timing of treatment for aSAH has shifted from delayed to early treatment of ruptured aneurysms, and there will be a trend toward early or ultra-early treatment for poor-grade aSAH. However, there is no consensus regarding the optimal timing of treatment for poor-grade aSAH. Endovascular coiling has provided a viable alternative to surgical clipping. An increasing number of patients have received endovascular treatment. There are limited data on high-level clinical trials focused on the treatment of poor-grade aSAH. An accurate prediction model remains challenging. Predicting long-term outcome is essential to support treatment decision-making. We reviewed the current therapeutical management and prognosis of poor-grade aSAH.

Keywords: intracranial aneurysms, subarachnoid hemorrhage, poor-grade, treatment, prognosis

1. Introduction

Aneurysmal subarachnoid hemorrhage (aSAH) is a devastating neurological condition and is associated with high morbidity and mortality. Poor-grade aSAH accounts for approximately 30% of all aSAH, and it is a severe subtype of aSAH. These patients more often present with acute hydrocephalus, severe intraventricular hemorrhage, microcirculatory disturbances, and even multi-organ failure after ictus [1, 2]. Traditionally, these patients are managed conservatively, and only those who show clinical improvement were selected for aggressive treatment [1, 3, 4]. However, aneurysm rebleeding occurs in patients with poor-grade aSAH, and about 50% of rebleeding is at the early stage after the hemorrhage [5]. Nowadays endovascular coiling, surgical clipping, and intensive neurocritical care have improved outcomes in patients

with poor-grade aSAH [6–11]. However, more than 60% of patients have unfavorable outcomes with severe disability [12]. The treatment decision-making is still challenging. There are limited data on high-level clinical trials focusing on the treatment of poor-grade aSAH. Therefore, we review the current therapeutical management and prognosis of poor-grade aSAH.

2. Diagnosis

Several grading systems, including Glasgow coma score (GCS), WFNS grade (World Federation of Neurological Societies), Hunt & Hess scale, or modified Hunt & Hess scale, have been used for initial clinical assessment of aSAH. Patients with poor-grade aSAH often present with stupor or coma because of the primary brain injury. WFNS grade has better inter- and intraobserver reliability than Hunt & Hess scale and makes it more appropriate [13]. Poor-grade aSAH is defined as WFNS grade IV or V (a GCS score of 7–12 for grade IV and 3–6 for grade V) [14]. It is important to detect ruptured aneurysms in the setting of poor-grade aSAH. These patients are often unstable and require sedation or anesthesia during examination.

Traditionally, digital subtraction angiography (DSA) is the gold standard technique for detecting ruptured aneurysms [15–19]. CT angiography (CTA) is less invasive and less time-consuming in providing information on ruptured intracranial aneurysms as a primary examination tool for aSAH. Current studies have reported the sensitivity and specificity of CTA for detecting intracranial aneurysms [20]. Matsumoto et al. [21] reported that 27 patients underwent successful surgical clipping based on CTA alone. Our previous study reported that more than a third of patients underwent successful surgical treatment on the basis of CTA alone [22]. All ruptured aneurysms were detected and clipped. Complications and clinical outcomes did not significantly differ between CTA alone and DSA group. Therefore, CTA can provide fast and accurate diagnostic and anatomic information on ruptured aneurysms and it can be safely and effectively used in most patients with poor-grade aSAH requiring surgical treatment. Patients with smaller ruptured aneurysms or multiple aneurysms may be considered for additional DSA examination.

3. Aneurysm rebleeding and predictor of the rebleeding

Rebleeding more often occurs in patients with poor-grade aSAH [23–27]. Van Donkelaar et al. [28] reported that 41 (11.0%) of 374 patients experienced rebleeding. Of the 297 patients included in our previous study, 30 (10.1%) patients experienced rebleeding; 14 (46.7%) cases occurred within 24 h after ictus, 11 (36.7%) occurred between 1 and 7 days, and 5 (16.6%) occurred after 7 days [5]. High blood pressure, poor-grade clinical condition, modified Fisher grade, posterior circulation aneurysms, larger aneurysms (>10 mm), intracerebral or intraventricular hemorrhage are reported to be important predictors of rebleeding after aSAH [24, 28–30]. Van Donkelaar et al. [28] reported that a higher modified Fisher grade was a strong risk factor associated with a rebleeding probably because the amount of blood was a marker of stability of the ruptured aneurysm wall.

Many neurosurgeons use preoperative ventricular drainage in all patients with poor-grade aSAH to maintain adequate cerebral perfusion [15, 24, 31–33]; however, there is no guideline for the drainage after poor-grade aSAH. Laidlaw and Siu reported that 2 of 133 patients treated with surgery underwent ventricular drainage because of the concern of rebleeding [34]. On the other hand, several studies

found no increased risk of rebleeding after the drainage [35, 36]. Our previous study showed that a lower Fisher grade, ruptured anterior cerebral artery aneurysms, and preoperative external ventricular drainage were independently associated with rebleeding after poor-grade aSAH [5]. Therefore, these patients may have increased risk of rebleeding after ventricle drainage without aneurysm repair, and early aneurysm treatment may be considered for patients who required emergency ventricle drainage.

4. Therapeutical management

Poor-grade aSAH should be treated with a multidisciplinary team that consists of neurologists, neurosurgeons, interventional neuroradiologists, and anesthesiologists. Emergency treatment should include aggressive resuscitation to keep the basic life support. Central venous catheters are first inserted for fluid and medicine administration and hemodynamic monitoring. Systolic blood pressure should be maintained below 160 mmHg to prevent the rebleeding. Oral or nasotracheal intubation should be performed if the patients require respiratory support.

4.1 Timing of treatment

There is no consensus regarding the optimal timing of treatment for poor-grade aSAH. Traditionally, these patients have been managed medically and only undergo the treatment of the ruptured aneurysm when clinically stabilized and improved. In the past decades, several studies have shown that early surgery (within 72 h of ictus) improved the outcome in selected patients with poor-grade aneurysms [15–17, 33, 37–39]. At more than 6 months of follow-up, 46% of patients had a good outcome after early surgical clipping [40]. Zentner et al. [41] reported that early surgery resulted in a good outcome of 22% of patients with the worst grade. A study of 103 patients with grade V showed a good outcome in 26% of patients at follow-up [42]. Despite the rates of morbidity and death remaining high in patients with WFNS grade V, these findings suggest that early aneurysm repair is feasible and safe for poor-grade aSAH. Early treatment for ruptured aneurysm may help reduce the risk of rebleeding and manage cerebral vasospasm and delayed ischemia. Patients with younger age, WFNS IV after emergency resuscitation, and middle cerebral artery aneurysms are more likely to have a favorable outcome after early surgery [43].

Aneurysm treatment as early as possible is recommended to prevent rebleeding after initial aSAH [44, 45]. Ultra-early treatment (within 24 h) reduces the risk of rebleeding and improves outcomes in most patients with good-grade aSAH [46–48]. However, there is no evidence to support ultra-early treatment of poor-grade aSAH because these patients experience more severe brain swelling than good-grade patients [42, 49]. With development in microsurgical techniques, there has been growing interest in ultra-early treatment of aSAH. A current series of 78 patients with poor-grade treated with surgical treatment showed 44 patients (56%) had a good outcome, including 26% of patients presenting with WFNS grade V, and surgery was performed within 24 h after admission [33]. In a multicenter and contemporary cohort of poor-grade aSAH, 47 (40%) of 118 patients underwent ultra-early surgery, 16 (34%) patients in ultra-early surgery group and 42 (59%) patients in delayed group had a good outcome [50]. Laidlaw et al. [17, 34] reported 40% of patients were independent after 3 months and 45% died. With coiling, there are few technical limitations to ultra-early treatment of aSAH as the limitations related to inflammation and brain swelling do not affect the technical aspects of the procedure [51].

A current meta-analysis and systemic review of poor-grade aSAH evaluated outcomes by timing of treatment modality and found that patients receiving ultra-early treatment (within 48 h of aSAH) had the highest rates of good neurological outcome (61% compared to 40% for early and 47% for delayed) [12]. Park et al. [47] reported that ultra-early surgery did not significantly decrease the incidence of rebleeding of poor-grade aSAH and also that it was not associated with outcomes [18, 47, 48]. Ultra-early aneurysm treatment of poor-grade aSAH still remains controversial.

4.2 Surgical treatment

Surgical treatment includes external ventricular drainage for hydrocephalus or intraventricular hemorrhage, surgical clipping of ruptured aneurysms, and decompressive craniectomy. Surgical selections are based on aneurysm morphology, patient's neurological condition, and treatment relative risk following multidisciplinary consultation. Patients with associated large intracerebral hemorrhage (more than 30 ml) are more often considered for surgical clipping. After surgery, patients are transferred to the intensive care unit, and they are treated with standard management for vasospasm. Illustrative case receiving surgical clipping is shown in **Figure 1**.

The international subarachnoid aneurysm trial (ISAT) demonstrated that for aSAH amenable to both treatments, patients treated with endovascular coiling had better outcomes than patients treated with surgical clipping [52]. Although endovascular treatment has been used as an available alternative to surgery for aSAH, surgical treatment is still an important treatment modality for poor-grade aSAH. In the contemporary multicenter cohorts of poor-grade aSAH, patients receiving clipping more often had a lower GCS score, a WFNS grade of V, a higher Fisher grade and modified Fisher grade, and a ruptured anterior circulation aneurysm than those receiving coiling [53]. Patients with WFNS grade V after emergency resuscitation, a better Fisher grade, brain herniation, the presence of ICH, or the absence of IVH more often underwent early surgical clipping [43]. Patients with brain herniation more commonly are treated with surgery. There are no significant differences in rebleeding, cerebral infarction, symptomatic vasospasm, seizure, pneumonia between coiling and clipping groups. There is also no significant difference in outcomes at 6 and 12 months between the two treatments [53].

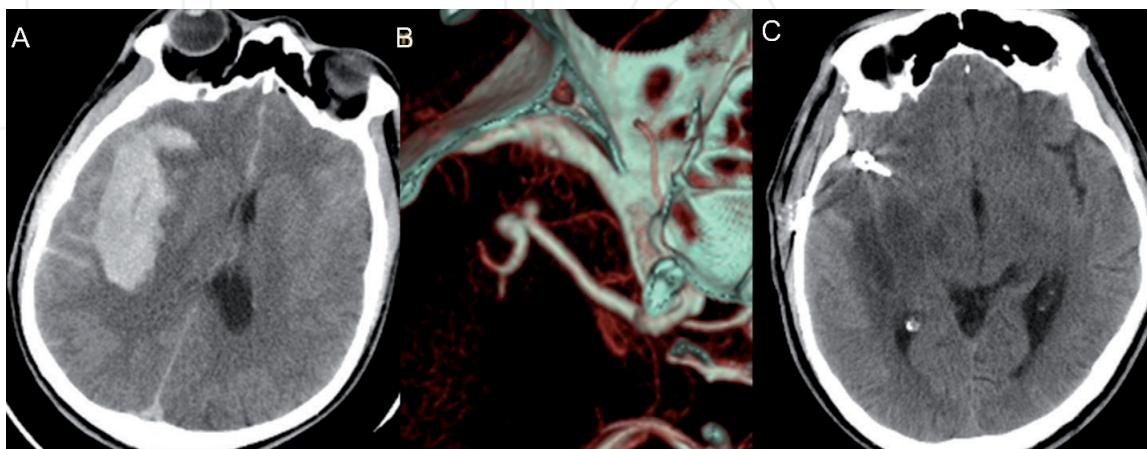


Figure 1.

A 45-year-old male presented with unconsciousness for 2 h and had a Glasgow coma score of 6 and World Federation of Neurosurgical Surgeon grade of V at admission. He was treated with emergency surgical clipping of ruptured aneurysm and hematoma evacuation. He recovered well and had a modified Rankin scale of 1 at 12 months of follow-up. (A) Emergency CT scan shows a large frontotemporal parietal lobe hematoma and midline shift to left side. (B) CT angiography shows a right middle cerebral artery bifurcation aneurysm. (C) CT shows a slight edema of surgical field after 10 days of surgery.

Decompressive craniectomy has been reported in the treatment for severe traumatic brain injury, massive ischemic stroke, and aSAH [54–60]. This procedure can reduce increased intracranial pressure and improve cerebral perfusion and outcomes in selected patients with ruptured aneurysms with associated intracerebral hemorrhage [61]. However, there are no studies focusing on the safety and efficacy of decompressive craniectomy for poor-grade aSAH compared with conventional craniotomy. Our previous study has shown that primary decompressive craniectomy does not increase postoperative complications and can be performed safely in poor-grade sSAH. More than one-half of patients benefit from primary decompressive craniectomy.

4.3 Endovascular treatment

Since the ISAT study, endovascular treatment is more commonly used than clipping for ruptured aneurysm. Aneurysms can be coiled through the minimally invasive endovascular approach to reduce the rate of rebleeding and avoid brain swelling and high intracranial pressure. Endovascular treatment is performed in continuity with the initial angiography and requires less treatment time. The current results at the 3- and 6-year follow-up in the ruptured aneurysm treatment study showed that there was no significant difference in outcome between the two treatments for ruptured aneurysms [62, 63]. A current systematic review of surgical and endovascular treatment of poor-grade aSAH has also shown that the proportion of patients with endovascular coiling increased from 10.0 to 62.0% between 1990 and 2000 and 2010 and 2014 [12]. Therefore, endovascular coiling is a feasible and reasonable option for poor-grade aSAH. Illustrative case receiving coiling is shown in **Figure 2**.

Mocco et al. [31] reported that 35 (35.7%) of 98 patients received coiling, and there was also similar outcome between coiling and clipping for poor-grade aSAH. In our prospective and multicenter registry of 262 patients with poor-grade ruptured aneurysm, 133 (50.8%) patients received endovascular coiling within 21 days after poor-grade aSAH [53]. An unadjusted analysis showed that the rate of outcome (mRS 0–2 or mRS 0–3) at discharge at 6 and 12 months in the coiled patients was higher than that in the clipped patients probably because of selection bias. In our exploratory analysis, there was no significant difference in clinical outcomes between the two groups. Patients receiving coiling had a higher risk of radiological

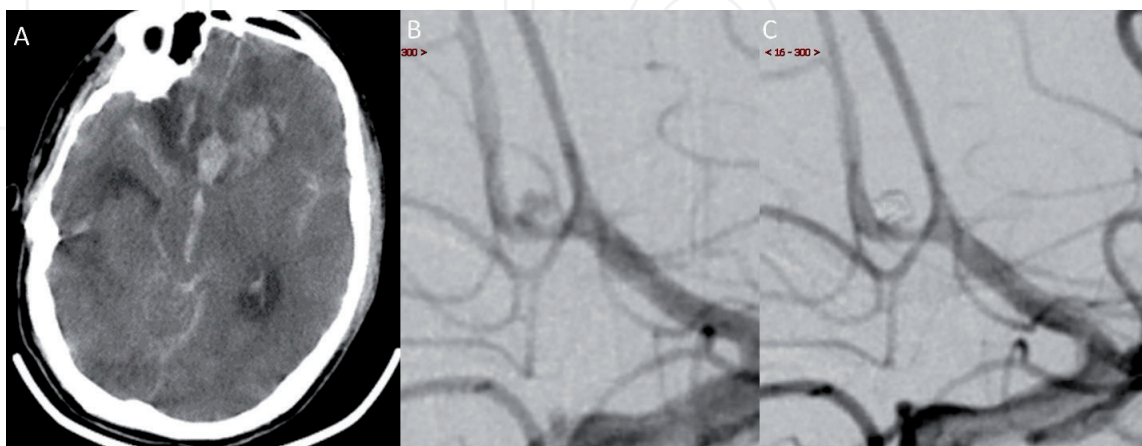


Figure 2.

A 53-year-old male presented with unconsciousness for 1 h and had a Glasgow coma score of 5 and World Federation of Neurosurgical Surgeon grade of V at admission. He was treated with emergency coiling of ruptured aneurysm and external ventricle drainage. He had a modified Rankin scale of 3 at 12 months of follow-up. (A) Emergency CT scan shows severe subarachnoid hemorrhage and frontal lobe hematoma. (B) Preoperative angiography shows a very small anterior communicating artery aneurysm. (C) Immediate angiography shows complete occlusion of aneurysms using coils.

hydrocephalus than clipped patients, and there was a trend toward clinical hydrocephalus after coiling. However, Zaidi et al. [64] found that there was no difference in hydrocephalus among patients treated by coiling or clipping.

With advances of endovascular technology, stent-assisted coiling has been used in the treatment of ruptured aneurysms. There is a main concern about the safety of stent-assisted coiling for poor-grade ruptured aneurysms. A review reported clinical outcomes in the stent-assisted coiling were worse than those in the coiling alone of acutely ruptured aneurysms [65]. Several studies showed that hemorrhagic complications often occurred in patients with acutely ruptured aneurysms after stent-assisted coiling and external ventricular drainage probably because of dual-antiplatelet therapy [66–68]. Using a multicenter poor-grade aneurysm study, we compared perioperative complications, and clinical outcomes between the stent-assisted coiling and the coiling-alone groups [69]. Twenty-three (17.6%) patients were treated with stent-assisted coiling compared with 108 (82.4%) patients treated with coiling alone. There were no statistically significant differences in intraprocedural rupture, procedure-related ischemic complication, ventricle drainage-related hemorrhagic complication, and symptomatic vasospasm between the stent-assisted coiling group and the coiling-alone group. However, there was a trend toward rebleeding after stent-assisted coiling. The hemorrhagic complication should be considered before the treatment decision-making. Therefore, treatment of wide-necked ruptured aneurysms remains challenging and we still require improvement of endovascular treatment of wide-neck ruptured aneurysms. A clinical trial focused on poor-grade ruptured aneurysms may be necessary to assess the efficacy of the treatment.

5. Outcomes and prognosis

The clinical outcomes of patients with aneurysm rebleeding remain very poor probably because of a severe secondary brain injury caused by a large cerebral hematoma or severe intraventricular hemorrhage. The rebleeding is independently associated with poor outcome (odds ratio [OR] 36.37, $p < 0.001$) and associated with mortality (OR 25.03, $p < 0.001$) at 12 months [5]. Tanno et al. [70] reported that 152 (84%) of 181 patients presented with semicoma to coma after rebleeding. Of the 30 patients with rebleeding in our previous study, 22 (73.3%) patients died at discharge. At 12 months, 2 (6.7%) patients had a modified Rankin Score (mRS) of 1, 1 (3.3%) had a mRS of 4, and 26 (86.7%) died [5]. A higher modified Fisher grade before rebleeding, larger aneurysms, and a lower GCS score after rebleeding were independently associated with increased mortality. A lower WFNS grade treated with aggressive treatment is more likely to have a good outcome [71].

Aggressive treatment and successful aneurysm repair can reduce the rebleeding and improve clinical outcomes in selected patients. In a current review of poor-grade aSAH, the rate of good outcome increased from 37.0 to 44.0% over the years. Good outcome was 38% (95% CI = 33–43%) in the endovascular group and 39% (95% CI = 34–44%) in the surgical group at the over 6 months of follow-up [12]. In our multicenter poor-grade aneurysm study [53], 52 (19.8%) patients had a mRS score of 0 or 1, 98 (29.8%) had a mRS score of 0–2, 112 (32.4%) had a mRS score of 0–3, and 51 (19.5%) had died at discharge. Ninety-five (36.3%) patients had a mRS score of 0 or 1, 115 (43.9%) had a mRS of 0–2, 126 (48.1%) had a mRS of 0–3, and 103 (39.3%) had died at 12 months. The outcome is improved after endovascular coiling or clipping over time of the follow-up [53]. In a prospective database of poor-grade aSAH patients, 40% of the 98 patients had a favorable outcome at 12 months [31]. In the 136 patients receiving endovascular coiling, 59 (43.3%) patients had a mRS of 0 or 1, and 64 (47.0%) had a poor outcome (mRS4–6) [72].

Authors	Study design	Mean time of follow-up	Treatments	Predictors of poor outcome
Le Roux et al.	Retrospective	6 months	Clipping	Hunt & Hess Grade V, blood glucose, fibrin degradation products, severity of ventricular hemorrhage, low density on CT, no clinical improvement
Huang et al.	Retrospective	6 months	Clipping	Hunt-Hess grade, aneurysm size, rehemorrhage before surgery, acute hydrocephalus
Mocco et al.	Prospective	12 months	Clipping and coiling	Older than 65 years, hyperglycemia preoperative Hunt & Hess Grade V, and aneurysm size of at least 13 mm
Zhao et al.	Prospective	12 months	Clipping	Older age, WFNS grade V, brain herniation, intraventricular hemorrhage, non-middle cerebral artery aneurysms
Zhao et al.	Prospective	12 months	Coiling	Older age, WFNS grade of V, higher modified Fisher grade, wider neck aneurysm
Zheng et al.	Prospective	12 months	Clipping, coiling, and conservative treatment	Older age, lower Glasgow coma scale score (GCS), the absence of pupillary reactivity, higher modified Fisher grade, and conservative treatment

Table 1.
Summary of predictors of poor outcome at the long-term follow-up.

About one-half of patients achieve a good outcome after the treatment, therefore predicting outcome after poor-grade aSAH is essential to support early treatment [73]. A few prognostic prediction models have been reported [3, 31, 74]. However, these studies are from a single center or have a limited sample size. Older age, lower GCS score, absence of pupil reactivity, higher modified Fisher grade, and conservative treatment are associated with poor outcome in most studies [3, 31, 74, 75]. These predictors of poor outcome are summarized in **Table 1**. We developed an integer-based outcome risk score (WAP) to predict the long-term outcomes [76]. The WAP score consists of three variables: WFNS grade, Age (three categories), and Pupillary reactivity. The sum of the weighted scores was used to assess the overall score and was ranged from 0 to 4. The predicted risk of poor outcome ranged from 25.5% for a WAP score of 0 to 96.2% for a score of 4. The risk score is easily measured and may complement treatment decision-making [76].

6. Conclusions

Poor-grade aSAH is a severe subtype of subarachnoid hemorrhage caused by ruptured aneurysms. Timing of treatment for the aSAH has shifted from delayed to early surgery, and there will be a trend toward ultra-early treatment for poor-grade aSAH. However, there is no consensus regarding the optimal timing of treatment for poor-grade aSAH. Although endovascular treatment has been used as an available alternative to surgical clipping for aSAH, surgical treatment is still an important treatment modality for poor-grade aSAH. Despite advancements in aneurysm

treatment, the morbidity and mortality of poor-grade aSAH remain high. Many retrospective studies have reported the predictors of outcomes, but there is not appropriate prediction model for poor-grade aSAH. The treatment decision-making is still challenging. Further prospective cohort study or clinical trials focused on poor-grade aSAH are required to help guide treatment decisions for this devastating condition.

Acknowledgements

This work was supported by Shanghai Municipal Education Commission—Gaofeng Clinical Medicine Grant Support (20171914), Shanghai Municipal Commission of Health and Family Planning (201740080), Shanghai Science and Technology Project (18411962700), and the Clinical Research Plan of SHDC (16CR3031A, 16CR2045B), the Shanghai Jiaotong University Medical Engineering and translational Cross-cutting Research Foundation (YG2017MS45, ZH2018ZDA07), Shanghai Jiaotong University School of Medicine Research Project (DLY201821).

Author details


Bing Zhao¹, Haixia Xing², Shenghao Ding¹, Yaohua Pan¹ and Jieqing Wan^{1*}

¹ Department of Neurosurgery, Renji Hospital, Shanghai Jiao Tong University School of Medicine, Shanghai, China

² Department of Pathology, Shanghai East Hospital, Tongji University School of Medicine, Shanghai, China

*Address all correspondence to: jieqingwan@126.com

IntechOpen

© 2019 The Author(s). Licensee IntechOpen. This chapter is distributed under the terms of the Creative Commons Attribution License (<http://creativecommons.org/licenses/by/3.0>), which permits unrestricted use, distribution, and reproduction in any medium, provided the original work is properly cited. 

References

- [1] Hutchinson PJ, Power DM, Tripathi P, Kirkpatrick PJ. Outcome from poor grade aneurysmal subarachnoid haemorrhage- which poor grade subarachnoid haemorrhage patients benefit from aneurysm clipping? *British Journal of Neurosurgery*. 2000;**14**:105-109
- [2] Wartenberg KE, Sheth SJ, Michael Schmidt J, Frontera JA, Rincon F, Ostapkovich N, et al. Acute ischemic injury on diffusion-weighted magnetic resonance imaging after poor grade subarachnoid hemorrhage. *Neurocritical Care*. 2011;**14**:407-415
- [3] Le Roux PD, Elliott JP, Newell DW, Grady MS, Winn HR. Predicting outcome in poor-grade patients with subarachnoid hemorrhage: A retrospective review of 159 aggressively managed cases. *Journal of Neurosurgery*. 1996;**85**:39-49
- [4] Mitra D, Gregson B, Jayakrishnan V, Gholkar A, Vincent A, White P, et al. Treatment of poor-grade subarachnoid hemorrhage trial. *AJNR. American Journal of Neuroradiology*. 2015;**36**:116-120
- [5] Zhao B, Fan Y, Xiong Y, Yin R, Zheng K, Li Z, et al. Aneurysm rebleeding after poor-grade aneurysmal subarachnoid hemorrhage: Predictors and impact on clinical outcomes. *Journal of the Neurological Sciences*. 2016;**371**:62-66
- [6] Taylor CJ, Robertson F, Brealey D, O'Shea F, Stephen T, Brew S, et al. Outcome in poor grade subarachnoid hemorrhage patients treated with acute endovascular coiling of aneurysms and aggressive intensive care. *Neurocritical Care*. 2011;**14**:341-347
- [7] Diaz RJ, Wong JH. Clinical outcomes after endovascular coiling in high-grade aneurysmal hemorrhage. *Canadian Journal of Neurological Sciences*. 2011;**38**:30-35
- [8] Pereira AR, Sanchez-Pena P, Biondi A, Sourour N, Boch AL, Colonne C, et al. Predictors of 1-year outcome after coiling for poor-grade subarachnoid aneurysmal hemorrhage. *Neurocritical Care*. 2007;**7**:18-26
- [9] Bracard S, Lebedinsky A, Anxionnat R, Neto JM, Audibert G, Long Y, et al. Endovascular treatment of Hunt and Hess grade IV and V aneurysm. *AJNR - American Journal of Neuroradiology*. 2002;**23**:953-957
- [10] Suzuki S, Jahan R, Duckwiler GR, Frazee J, Martin N, Vinuela F. Contribution of endovascular therapy to the management of poor-grade aneurysmal subarachnoid hemorrhage: Clinical and angiographic outcomes. *Journal of Neurosurgery*. 2006;**105**:664-670
- [11] Bergui M, Bradac GB. Acute endovascular treatment of ruptured aneurysms in poor-grade patients. *Neuroradiology*. 2004;**46**:161-164
- [12] Zhao B, Rabinstein A, Murad MH, Lanzino G, Panni P, Brinjikji W. Surgical and endovascular treatment of poor-grade aneurysmal subarachnoid hemorrhage: A systematic review and meta-analysis. *Journal of Neurosurgical Sciences*. 2017;**61**:403-415
- [13] Shirao S, Yoneda H, Kunitsugu I, Ishihara H, Koizumi H, Suehiro E, et al. Preoperative prediction of outcome in 283 poor-grade patients with subarachnoid hemorrhage: A project of the chugoku-shikoku division of the Japan neurosurgical society. *Cerebrovascular Diseases*. 2010;**30**:105-113
- [14] Report of world federation of neurological surgeons committee on a universal subarachnoid hemorrhage grading scale. *Journal of Neurosurgery*. 1988;**68**:985-986. DOI:10.3171/jns.1988.68.6.0985. PMID: 3131498

- [15] Bailes JE, Spetzler RF, Hadley MN, Baldwin HZ. Management morbidity and mortality of poor-grade aneurysm patients. *Journal of Neurosurgery*. 1990;**72**:559-566
- [16] Oda S, Shimoda M, Sato O. Early aneurysm surgery and dehydration therapy in patients with severe subarachnoid haemorrhage without ich. *Acta Neurochirurgica*. 1996;**138**:1050-1056
- [17] Laidlaw JD, Siu KH. Ultra-early surgery for aneurysmal subarachnoid hemorrhage: Outcomes for a consecutive series of 391 patients not selected by grade or age. *Journal of Neurosurgery*. 2002;**97**:250-258. Discussion 247-259
- [18] Sandstrom N, Yan B, Dowling R, Laidlaw J, Mitchell P. Comparison of microsurgery and endovascular treatment on clinical outcome following poor-grade subarachnoid hemorrhage. *Journal of Clinical Neuroscience*. 2013;**20**:1213-1218
- [19] Gupta SK, Ghanta RK, Chhabra R, Mohindra S, Mathuriya SN, Mukherjee KK, et al. Poor-grade subarachnoid hemorrhage: Is surgical clipping worthwhile? *Neurology India*. 2011;**59**:212-217
- [20] Westerlaan HE, Van Dijk JM, Jansen-van der Weide MC, de Groot JC, Groen RJ, Mooij JJ, et al. Intracranial aneurysms in patients with subarachnoid hemorrhage: Ct angiography as a primary examination tool for diagnosis--systematic review and meta-analysis. *Radiology*. 2011;**258**:134-145
- [21] Matsumoto M, Sato M, Nakano M, Endo Y, Watanabe Y, Sasaki T, et al. Three-dimensional computerized tomography angiography-guided surgery of acutely ruptured cerebral aneurysms. *Journal of Neurosurgery*. 2001;**94**:718-727
- [22] Zhao B, Lin F, Wu J, Zheng K, Tan X, Cao Y, et al. A multicenter analysis of computed tomography angiography alone versus digital subtraction angiography for the surgical treatment of poor-grade aneurysmal subarachnoid hemorrhage. *World Neurosurgery*. 2016;**91**:106-111
- [23] Inagawa T, Kamiya K, Ogasawara H, Yano T. Rebleeding of ruptured intracranial aneurysms in the acute stage. *Surgical Neurology*. 1987;**28**:93-99
- [24] Naidech AM, Janjua N, Kreiter KT, Ostapkovich ND, Fitzsimmons BF, Parra A, et al. Predictors and impact of aneurysm rebleeding after subarachnoid hemorrhage. *Archives of Neurology*. 2005;**62**:410-416
- [25] Rosenorn J, Eskesen V, Schmidt K, Ronde F. The risk of rebleeding from ruptured intracranial aneurysms. *Journal of Neurosurgery*. 1987;**67**:329-332
- [26] Davies BM, Chung KH, Dulhanty L, Galea J, Patel HC. Pre-protection re-haemorrhage following aneurysmal subarachnoid haemorrhage: Where are we now? *Clinical Neurology and Neurosurgery*. 2015;**135**:22-26
- [27] Starke RM, Connolly ES Jr. Rebleeding after aneurysmal subarachnoid hemorrhage. *Neurocritical Care*. 2011;**15**:241-246
- [28] van Donkelaar CE, Bakker NA, Veeger NJ, Uyttenboogaart M, Metzemaekers JD, Luijckx GJ, et al. Predictive factors for rebleeding after aneurysmal subarachnoid hemorrhage: Rebleeding aneurysmal subarachnoid hemorrhage study. *Stroke; a Journal of Cerebral Circulation*. 2015;**46**:2100-2106
- [29] Tang C, Zhang TS, Zhou LF. Risk factors for rebleeding of aneurysmal

subarachnoid hemorrhage: A meta-analysis. *PLoS One*. 2014;**9**:e99536

[30] Boogaarts HD, van Lieshout JH, van Amerongen MJ, de Vries J, Verbeek AL, Grotenhuis JA, et al. Aneurysm diameter as a risk factor for pretreatment rebleeding: A meta-analysis. *Journal of Neurosurgery*. 2015;**122**:921-928

[31] Mocco J, Ransom ER, Komotar RJ, Schmidt JM, Sciacca RR, Mayer SA, et al. Preoperative prediction of long-term outcome in poor-grade aneurysmal subarachnoid hemorrhage. *Neurosurgery*. 2006;**59**:529-538. Discussion 529-538

[32] Ransom ER, Mocco J, Komotar RJ, Sahni D, Chang J, Hahn DK, et al. External ventricular drainage response in poor grade aneurysmal subarachnoid hemorrhage: Effect on preoperative grading and prognosis. *Neurocritical Care*. 2007;**6**:174-180

[33] Huang AP, Arora S, Wintermark M, Ko N, Tu YK, Lawton MT. Perfusion computed tomographic imaging and surgical selection with patients after poor-grade aneurysmal subarachnoid hemorrhage. *Neurosurgery*. 2010;**67**:964-974. Discussion 975

[34] Laidlaw JD, Siu KH. Poor-grade aneurysmal subarachnoid hemorrhage: Outcome after treatment with urgent surgery. *Neurosurgery*. 2003;**53**:1275-1280. discussion 1280-1272

[35] McIver JI, Friedman JA, Wijedicks EF, Piepgras DG, Pichelmann MA, Toussaint LG 3rd, et al. Preoperative ventriculostomy and rebleeding after aneurysmal subarachnoid hemorrhage. *Journal of Neurosurgery*. 2002;**97**:1042-1044

[36] Hellingman CA, van den Bergh WM, Beijer IS, van Dijk GW, Algra A, van Gijn J, et al. Risk of

rebleeding after treatment of acute hydrocephalus in patients with aneurysmal subarachnoid hemorrhage. *Stroke; a Journal of Cerebral Circulation*. 2007;**38**:96-99

[37] Nowak G, Schwachenwald R, Arnold H. Early management in poor grade aneurysm patients. *Acta Neurochirurgica*. 1994;**126**:33-37

[38] Versari PP, Talamonti G, D'Aliberti G, Villa F, Solaini C, Collice M. Surgical treatment of poor-grade aneurysm patients. *Journal of Neurosurgical Sciences*. 1998;**42**:43-46

[39] Chiang VL, Claus EB, Awad IA. Toward more rational prediction of outcome in patients with high-grade subarachnoid hemorrhage. *Neurosurgery*. 2000;**46**:28-35. discussion 35-26

[40] Zhao B, Cao Y, Tan X, Zhao Y, Wu J, Zhong M, et al. Complications and outcomes after early surgical treatment for poor-grade ruptured intracranial aneurysms: A multicenter retrospective cohort. *International Journal of Surgery*. 2015;**23**:57-61

[41] Zentner J, Hoffmann C, Schramm J. Results of early surgery in poor-grade aneurysm patients. *Journal of Neurosurgical Sciences*. 1996;**40**:183-188

[42] Wostrack M, Sandow N, Vajkoczy P, Schatlo B, Bijlenga P, Schaller K, et al. Subarachnoid haemorrhage WFNS grade V: Is maximal treatment worthwhile? *Acta Neurochirurgica*. 2013;**155**:579-586

[43] Zhao B, Tan X, Zhao Y, Cao Y, Wu J, Zhong M, et al. Variation in patient characteristics and outcomes between early and delayed surgery in poor-grade aneurysmal subarachnoid hemorrhage. *Neurosurgery*. 2016;**78**:224-231

- [44] Connolly ES Jr, Rabinstein AA, Carhuapoma JR, Derdeyn CP, Dion J, Higashida RT, et al. Guidelines for the management of aneurysmal subarachnoid hemorrhage: A guideline for healthcare professionals from the American heart association/American stroke association. *Stroke; a Journal of Cerebral Circulation*. 2012;**43**:1711-1737
- [45] Steiner T, Juvela S, Unterberg A, Jung C, Forsting M, Rinkel G. European stroke organization guidelines for the management of intracranial aneurysms and subarachnoid haemorrhage. *Cerebrovascular Diseases*. 2013;**35**:93-112
- [46] Phillips TJ, Dowling RJ, Yan B, Laidlaw JD, Mitchell PJ. Does treatment of ruptured intracranial aneurysms within 24 hours improve clinical outcome? *Stroke; a Journal of Cerebral Circulation*. 2011;**42**:1936-1945
- [47] Park J, Woo H, Kang DH, Kim YS, Kim MY, Shin IH, et al. Formal protocol for emergency treatment of ruptured intracranial aneurysms to reduce in-hospital rebleeding and improve clinical outcomes. *Journal of Neurosurgery*. 2015;**122**:383-391
- [48] Wong GK, Boet R, Ng SC, Chan M, Gin T, Zee B, et al. Ultra-early (within 24 hours) aneurysm treatment after subarachnoid hemorrhage. *World Neurosurgery*. 2012;**77**:311-315
- [49] Wilson DA, Nakaji P, Albuquerque FC, McDougall CG, Zabramski JM, Spetzler RF. Time course of recovery following poor-grade sah: The incidence of delayed improvement and implications for SAH outcome study design. *Journal of Neurosurgery*. 2013;**119**:606-612
- [50] Zhao B, Zhao Y, Tan X, Cao Y, Wu J, Zhong M, et al. Factors and outcomes associated with ultra-early surgery for poor-grade aneurysmal subarachnoid haemorrhage: A multicentre retrospective analysis. *BMJ Open*. 2015;**e007410**:5
- [51] Luo YC, Shen CS, Mao JL, Liang CY, Zhang Q, He ZJ. Ultra-early versus delayed coil treatment for ruptured poor-grade aneurysm. *Neuroradiology*. 2015;**57**:205-210
- [52] Molyneux A, Kerr R, Stratton I, Sandercock P, Clarke M, Shrimpton J, et al. International subarachnoid aneurysm trial (ISAT) of neurosurgical clipping versus endovascular coiling in 2143 patients with ruptured intracranial aneurysms: A randomised trial. *Lancet*. 2002;**360**:1267-1274
- [53] Zhao B, Tan X, Yang H, Li Z, Zheng K, Xiong Y, et al. Endovascular coiling versus surgical clipping for poor-grade ruptured intracranial aneurysms: Postoperative complications and clinical outcome in a multicenter poor-grade aneurysm study. *AJNR. American Journal of Neuroradiology*. 2016;**37**:873-878
- [54] Smith ER, Carter BS, Ogilvy CS. Proposed use of prophylactic decompressive craniectomy in poor-grade aneurysmal subarachnoid hemorrhage patients presenting with associated large sylvian hematomas. *Neurosurgery*. 2002;**51**:117-124. Discussion 124
- [55] Buschmann U, Yonekawa Y, Fortunati M, Cesnulis E, Keller E. Decompressive hemicraniectomy in patients with subarachnoid hemorrhage and intractable intracranial hypertension. *Acta Neurochirurgica*. 2007;**149**:59-65
- [56] Schirmer CM, Hoit DA, Malek AM. Decompressive hemicraniectomy for the treatment of intractable intracranial hypertension after aneurysmal subarachnoid hemorrhage. *Stroke*. 2007;**38**:987-992

- [57] Otani N, Takasato Y, Masaoka H, Hayakawa T, Yoshino Y, Yatsushige H, et al. Surgical outcome following decompressive craniectomy for poor-grade aneurysmal subarachnoid hemorrhage in patients with associated massive intracerebral or sylvian hematomas. *Cerebrovascular Diseases*. 2008;**26**:612-617
- [58] Uozumi Y, Sakowitz O, Orakcioglu B, Santos E, Kentar M, Haux D, et al. Decompressive craniectomy in patients with aneurysmal subarachnoid hemorrhage: A single-center matched-pair analysis. *Cerebrovascular Diseases*. 2014;**37**:109-115
- [59] Guresir E, Schuss P, Vatter H, Raabe A, Seifert V, Beck J. Decompressive craniectomy in subarachnoid hemorrhage. *Neurosurgical Focus*. 2009;**26**:E4
- [60] Dorfer C, Frick A, Knosp E, Gruber A. Decompressive hemicraniectomy after aneurysmal subarachnoid hemorrhage. *World Neurosurgery*. 2010;**74**:465-471
- [61] Zhao B, Zhao Y, Tan X, Cao Y, Wu J, Zhong M, et al. Primary decompressive craniectomy for poor-grade middle cerebral artery aneurysms with associated intracerebral hemorrhage. *Clinical Neurology and Neurosurgery*. 2015;**133**:1-5
- [62] Spetzler RF, McDougall CG, Albuquerque FC, Zabramski JM, Hills NK, Partovi S, et al. The barrow ruptured aneurysm trial: 3-year results. *Journal of Neurosurgery*. 2013;**119**:146-157
- [63] Spetzler RF, McDougall CG, Zabramski JM, Albuquerque FC, Hills NK, Russin JJ, et al. The barrow ruptured aneurysm trial: 6-year results. *Journal of Neurosurgery*. 2015;**123**:609-617
- [64] Zaidi HA, Montoure A, Elhadi A, Nakaji P, McDougall CG, Albuquerque FC, et al. Long-term functional outcomes and predictors of shunt-dependent hydrocephalus after treatment of ruptured intracranial aneurysms in the barrow trial: Revisiting the clip vs coil debate. *Neurosurgery*. 2015;**76**:608-613. Discussion 613-604; quiz 614
- [65] Bodily KD, Cloft HJ, Lanzino G, Fiorella DJ, White PM, Kallmes DF. Stent-assisted coiling in acutely ruptured intracranial aneurysms: A qualitative, systematic review of the literature. *AJNR - American Journal of Neuroradiology*. 2011;**32**:1232-1236
- [66] Chung J, Lim YC, Suh SH, Shim YS, Kim YB, Joo JY, et al. Stent-assisted coil embolization of ruptured wide-necked aneurysms in the acute period: Incidence of and risk factors for periprocedural complications. *Journal of Neurosurgery*. 2014;**121**:4-11
- [67] Amenta PS, Dalyai RT, Kung D, Toporowski A, Chandela S, Hasan D, et al. Stent-assisted coiling of wide-necked aneurysms in the setting of acute subarachnoid hemorrhage: Experience. *Neurosurgery*. 2012;**70**:1415-1429. Discussion 1429
- [68] Kim DJ, Suh SH, Kim BM, Kim DI, Huh SK, Lee JW. Hemorrhagic complications related to the stent-remodeled coil embolization of intracranial aneurysms. *Neurosurgery*. 2010;**67**:73-78. Discussion 78-79
- [69] Zhao B, Tan X, Yang H, Zheng K, Li Z, Xiong Y, et al. Stent-assisted coiling versus coiling alone of poor-grade ruptured intracranial aneurysms: A multicenter study. *Journal of NeuroInterventional Surgery*. 2017;**9**:165-168
- [70] Tanno Y, Homma M, Oinuma M, Kodama N, Yamamoto T. Rebleeding from ruptured intracranial aneurysms in north eastern province of

Japan. A cooperative study. *Journal of the Neurological Sciences*. 2007;**258**:11-16

[71] Zhao B, Yang H, Zheng K, Li Z, Xiong Y, Tan X, et al. Predictors of good functional outcomes and mortality in patients with severe rebleeding after aneurysmal subarachnoid hemorrhage. *Clinical Neurology and Neurosurgery*. 2016;**144**:28-32

[72] Zhao B, Yang H, Zheng K, Li Z, Xiong Y, Tan X, et al. Preoperative and postoperative predictors of long-term outcome after endovascular treatment of poor-grade aneurysmal subarachnoid hemorrhage. *Journal of Neurosurgery*. 2017;**126**:1764-1771

[73] Howard BM, Barrow DL, et al. Outcomes for patients with poor-grade subarachnoid hemorrhage: To treat or not to treat? *World Neurosurgery*. 2015

[74] Schuss P, Hadjiathanasiou A, Borger V, Wispel C, Vatter H, Guresir E. Poor-grade aneurysmal subarachnoid hemorrhage: Factors influencing functional outcome-a single-center series. *World Neurosurgery*. 2016;**85**:125-129

[75] Mack WJ, Hickman ZL, Ducruet AF, Kalyvas JT, Garrett MC, Starke RM, et al. Pupillary reactivity upon hospital admission predicts long-term outcome in poor grade aneurysmal subarachnoid hemorrhage patients. *Neurocritical Care*. 2008;**8**:374-379

[76] Zheng K, Zhong M, Zhao B, Chen SY, Tan XX, Li ZQ, et al. Poor-grade aneurysmal subarachnoid hemorrhage: Risk factors affecting clinical outcomes in intracranial aneurysm patients in a multi-center study. *Frontiers in Neurology*. 2019;**10**:123