

We are IntechOpen, the world's leading publisher of Open Access books Built by scientists, for scientists

6,900

Open access books available

186,000

International authors and editors

200M

Downloads

Our authors are among the

154

Countries delivered to

TOP 1%

most cited scientists

12.2%

Contributors from top 500 universities



WEB OF SCIENCE™

Selection of our books indexed in the Book Citation Index
in Web of Science™ Core Collection (BKCI)

Interested in publishing with us?
Contact book.department@intechopen.com

Numbers displayed above are based on latest data collected.
For more information visit www.intechopen.com



Arteriovenous Fistulas: The Pathological Bridge

*Sara A. AbuSini, Nour A. Tashtush, Abdelwahab J. Aleshawi
and Amer A. Jaradat*

Abstract

An intracranial dural arteriovenous fistula (DAVF) is a type of intracranial vascular malformation in which there is a connection between an intracranial artery and a dural venous sinus. It accounts for 10–15% of all intracranial arteriovenous malformations. This malformation derives its arterial supply primarily from meningeal vessels, and the venous drainage is either via dural venous sinuses or through the cortical veins. DAVFs have a reported association with dural sinus thrombosis, venous hypertension, previous craniotomy, and trauma, though many lesions are idiopathic. Digital subtraction angiography remains the gold standard for diagnosing these fistulas. Endovascular treatment is one of the first line options available for their management. In this chapter, we will discuss and review the etio-pathogenesis, natural history, common classification systems, and various available diagnostic options.

Keywords: angiography, fistula, intervention, pathophysiology

1. Introduction

DAVFs are arteriovenous shunts from a dural arterial supply to a dural venous channel, typically supplied by pachy-meningeal arteries and located near a major venous sinus. The etiology of these lesions is not fully understood; some are congenital, and others are acquired. DAVFs in the pediatric population are associated with structural venous abnormalities [1], but most DAVFs are thought to be acquired. Different etiologies have been implicated in this phenomenon, namely sinus thrombosis, trauma, or surgery [2–6].

Yasargill noted that Rizzoli, in 1881, was the first to describe an arteriovenous malformation (AVM) that involved the dura mater and Sachs reported the first, angiographic description in 1931. Subsequently cranial dural fistulas have been most frequently described at the transverse sinus and cavernous sinus, although they occur at every cranial dural sinus. Dural arteriovenous fistulas (DAVFs) can occur anywhere within the intracranial dura mater. DAVFs are rare vascular abnormalities. They consist of numerous tiny connections between branches of dural arteries and veins or a venous sinus [7]. The true incidence of DAVFs is unknown [8]. However, the reported incidence of intracranial DAVFs is approximately 10–15% of all intracranial vascular abnormalities. A good percentage of DAVFs are asymptomatic or undergo spontaneous involution therefore the true incidence may be much more [9]. DAVFs are acquired lesions; that is why they present later in life than AVMs [10].

2. Pathogenesis

Many factors have been involved in the pathogenesis of DAVFs; however, the exact pathophysiology remains unclear.

Some patients with DAVFs have been found to have venous sinus occlusion, which was proposed to be the direct cause for the development of the fistula. While others were found to have venous sinus thrombosis which resulted in the formation of small dural arteriovenous shunts by the invasion of angiogenic factors, released from the organizing thrombus, to a group of small dural arteries. However, it has been noted that DAVF can precede either venous sinus occlusion or thrombosis, because of its association with venous hypertension [11, 12].

Venous hypertension may lead to chronic focal decrease in both regional cerebral blood flow and cerebral perfusion pressure. The decrease in the cerebral blood flow will cause cerebral ischemia, which increases the expression of vascular endothelial growth factor (VEGF) via hypoxia-inducible factor-1 α (HIF-1 α) upregulation, leading eventually to the formation of DAVF. Also, some theories suggest that if venous hypertension was present, a small arteriovenous anastomosis might open up and generates DAVF when the shunting enlarges [13].

Besides occurring incidentally, the development of DAVFs has been caused by a wide range of events with head trauma, with or without skull fractures, being the most common one. Other preceding events include surgical operations like craniotomy, hormonal alterations like what happens in cases of pregnancy and menopause, infections like cases of otitis and sinusitis, and tumors, particularly meningiomas [14].

3. Classification

The Borden-Shucart and Cognard systems are both known to be the most commonly used systems to classify DAVFs. However, there have been many classification schemes submitted for DAVF [10]. The Borden classification system (**Table 1**) classified DAVFs into three main types according to the presence or absence of cortical venous drainage (CVD) and the location of venous drainage [15]. In type I lesion, the drainage goes to the dural sinus or meningeal vein in an anterograde fashion. In type II lesion, the drainage to dural sinus goes in an anterograde fashion, however, the high pressure within the DAVF causes blood to flow in a retrograde way to subarachnoid veins. In type III lesions, the drainage goes directly and completely to subarachnoid veins [11].

The Cognard grading scale (**Table 2**) classifies DAVFs into five main types based on the direction of the flow whether anterograde or retrograde, presence or absence of a CVD, presence of venous ectasia whether ectatic or nonectatic cortical vein and the location of the fistula [14].

The presence of a CVD (Borden type II and III, Cognard types IIb–V) or absence (Borden type I, Cognard types I, IIa) and the pattern of the venous drainage all are considered major factors by the previous classification systems and were used to assess the risk of hemorrhage or any neurologic deficits [16]. The absence of a CVD

Type 1	Venous drainage into a dural sinus without CVD
Type 2	Venous drainage into a dural sinus with associated CVD
Type 3	Drainage into cortical veins (CVD)

Table 1.
Borden classification of DAVF.

Type I	Venous drainage into dural sinus with antegrade flow
Type II a	Venous drainage into dural sinus with retrograde flow
Type II b	Venous drainage into dural sinus with antegrade flow and CVD
Type II a + b	Venous drainage into dural sinus with retrograde flow & CVD
Type III	Venous drainage into cortical veins (CVD)
Type IV	CVD with associated venous ectasia(s)
Type V	Venous drainage into spinal perimedullary veins

Table 2.
Cognard classification of DAVF.

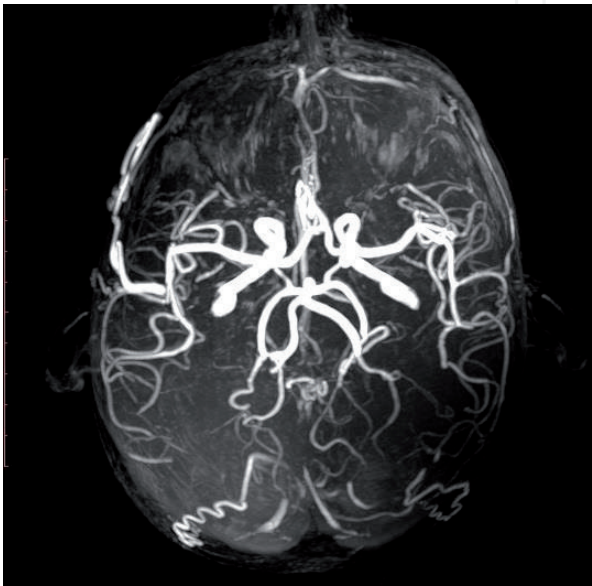

Figure 1.
Magnetic resonance angiography demonstrating the arteriovenous fistula.

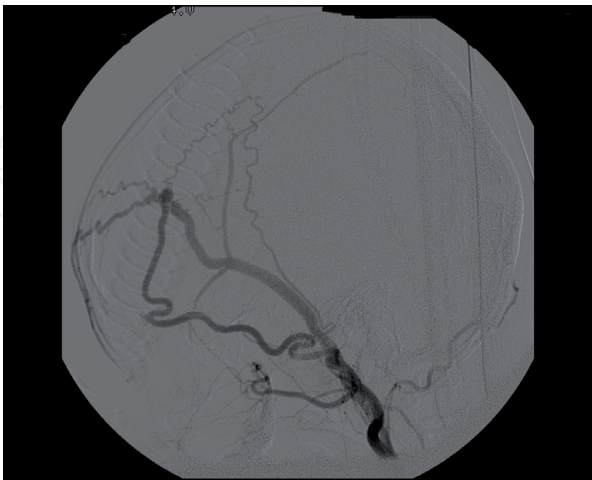


Figure 2.
Digital subtraction angiography showed dural arterio-venous fistula with pseudo aneurysm at the abnormal anastomoses between the right temporal artery and the superior sagittal sinus and the facial vein.

has been recognized as a favorable factor and the patients are usually asymptomatic or have symptoms like pulsatile tinnitus or exophthalmos [15]. On the other hand, presence of a CVD is an unfavorable factor that puts the dural fistula in a higher

risk group. DAVF has a higher chance of being symptomatic if the type of either classification systems was higher. Also, symptomatic lesions have a higher risk of hemorrhage than asymptomatic lesions [16] (**Figures 1** and **2**).

4. Clinical presentation

Patients with DAVFs may be discovered incidentally and be totally asymptomatic. However, if symptoms are present, they can range widely from mild to fatal in severe cases. The site of DAVF and the direction of the venous drainage (anterograde or retrograde) are two of the factors that will determine the nature of symptoms [17].

Benign symptoms like headache and pulsatile tinnitus present when DAVF drains into dural sinus in an anterograde pattern without CVD. Aggressive symptoms of pseudotumor cerebri, papilledema and dementia present when DAVF drains in a retrograde pattern leading to an increase in the intracranial pressure, hence the severe presentation [11].

According to location, ophthalmic symptoms like chemosis, exophthalmos, double vision and low visual acuity occur if the DAVF is located in the cavernous sinus because the ophthalmic venous drainage may get compromised with subsequent increase in the intraocular pressure and periorbital edema [13]. Ear symptoms like pulsatile tinnitus and retroauricular pain present if DAVF involves transverse and sigmoid sinuses. Pulsatile tinnitus can be heard over the mastoid area with auscultation [16].

Tentorial and anterior cranial fossa DAVFs usually present with hemorrhage because both can obtain retrograde CVD. Exophthalmos and chemosis are also present in cases of anterior cranial fossa DAVFs if they obtain cavernous sinus drainage [11].

In severe cases, patients suffer from intracranial hemorrhage and neurological deficits like seizures, parkinsonism, and cerebellar symptoms [15].

Other presentations include brainstem infarction and cervical myelopathy if DAVF is located around the brainstem. Also, these lesions can cause cranial neuropathy because of the compression on cranial nerves [13].

5. Diagnosis

Catheter angiography is the gold standard technique for the diagnosis and classification of DAVFs. Based on the site of DAVF, this method is usually performed by using the four-vessel technique injections with an injection into the external carotid arteries. Several dural arterial feeders with early drainage into a dural sinus or cortical vein are mostly revealed on angiograms. Also, conventional angiograms are used to classify DAVFs based on the venous architecture and the extent of cortical venous reflux.

Among all the used methods for the diagnosis of DAVFs like CT, CT angiography, MRI and MR angiography, CT has been the initial neuroimaging method. Although it can reveal areas of ischemia, edema and ICH, it could not identify DAVF ideally. On the other hand, CTA has been a better method for identifying DAVFs, because it can show a dilated vessel associated with an ICH or calcification with chronically congested veins. Also, MRA has the same ability of CTA of showing dilated vessels.

As both MRA and CTA can show the site of DAVFs in relation to normal brain structures, they are both used as adjuvant methods to catheter angiography, which allows both techniques to be used in intraoperative navigation [14, 15].

6. Rare cases

6.1 Case 1

This is the first case of a DAVF causing isolated intraventricular hemorrhage with radiographic evidence of several cortical venous refluxes into the subependymal venous network. Also, it is the first case of DAVF that was successfully cured using multimodality transvenous and trans-arterial embolization techniques. A hypertensive, diabetic 84-year-old woman whose modified Rankin scale score is 0, presented to the emergency room complaining of headache for 4 days, nausea, vomiting and worsening confusion with episodes of severe drowsiness. Non-contrast CT scan of the head, CT angiogram of the brain, and digital subtraction cerebral angiogram were performed. She was treated by transvenous coil embolization of the right transverse/sigmoid sinus using POD5 and penumbra –400 coils and trans-arterial onyx-18 embolization of the right middle meningeal artery. She had 4- and 6-week follow-up by diagnostic angiogram and 6-week follow-up by clinical examination. The angiogram 6-week follow-up revealed that the DAVF went through complete resolution; the clinical 6-week follow-up showed that the patient mental status returned to normal and her headache resolved [18].

6.2 Case 2

A rare case of dural arteriovenous fistula at the cranio-cervical junction presented as cerebellar hemorrhage, which made physicians struggle with the diagnosis. A 77-year-old woman came to the emergency department complaining of dizziness, she had no history of arterial hypertension. A small cerebellar hemorrhage was revealed on imaging studies. Her diagnosis was hypertensive intracerebral hemorrhage and was treated conservatively. She developed subarachnoid hemorrhage 4 months later, and imaging studies detected dural arteriovenous fistula at the left C1 dural sleeve. Intracerebral hemorrhage and subarachnoid hemorrhage both occurred because of the disruption of a distended cerebellar vein due to venous hypertension caused by the dural arteriovenous fistula. Surgical ligation of a feeding artery and a draining vein was performed which cured the dural arteriovenous fistula [19].

6.3 Case 3

A report of delayed and progressive spontaneous closure of a DAVF after massive intracerebral hemorrhage documented by angiographic studies before and after bleeding. This is the first report to document gradual closure of a DAVF by serial angiographic studies. A 73-year-old woman who had an attack of generalized epileptic seizure was referred to a local hospital. Investigations like MRI and transfemoral cerebral angiography were done and revealed a DAVF Cognard type IIa + b of the left transverse sinus with feeders from the left occipital artery, left pharyngeal artery, left middle meningeal artery, and branches of the meningohypophyseal artery. There was reflux into the cerebral veins and the ipsilateral sigmoid sinus was not filled. She had conservative treatment and was discharged home on antiepileptic medications 3 days after admission. Also, she was planned a future endovascular therapy. She was admitted 1 week later after an episode of severe headache. Her neurological examination showed that her pupils were asymmetric and she was somnolent. A large and disseminated intracerebral hemorrhage in the left temporal, occipital, and parietal lobes was revealed on CT that was done upon admission. Her hematoma was evacuated surgically and she went through

decompressive craniotomy 2 days later to treat her generalized brain edema and increased intracerebral pressure refractory to conservative therapy. The patient was sent for rehabilitation for hemiparesis and her recovery was slow. The DAVF closed completely 8 weeks after the hemorrhage. One year after the bleeding the patient was followed up, she was independent and had recovered but with mild aphasia and a slight hemiparesis on the right side [20].

7. Conclusion

Much has been learned in recent years about the pathoanatomy, pathophysiology, natural history, and therapeutic options for DAVFs. A better understanding of these lesions has allowed more prompt and precise diagnosis, in addition, a realistic assessment of features predisposing to aggressive clinical course. Clinical symptoms other than hemorrhage and progressive neurological deficits rarely warrants aggressive treatment of a DAVF, unless the lesion is particularly accessible or is associated with features predisposing to subsequent aggressive clinical behavior. Patient reassurance, symptomatic treatment, or palliative therapy is frequently sufficient. In DAVFs with features predisposing to an aggressive clinical course, a more definitive treatment strategy should be adopted. It is obvious that the myriad of clinical manifestations of DAVFs and the wide spectrum of possible angiographic and pathophysiologic scenarios call for highly individualized management strategies. The diagnostic investigation should be thorough to identify DAVFs with features predisposing to aggressive clinical behavior such as retrograde and leptomeningeal CVD, associated aneurysms, or venous ectasia.

Conflict of interest

There are no conflicts of interest to declare.

Author details

Sara A. AbuSini, Nour A. Tashtush, Abdelwahab J. Aleshawi and Amer A. Jaradat*
Faculty of Medicine, Jordan University of Science and Technology, Irbid, Jordan

*Address all correspondence to: amerakramjaradat@yahoo.com

IntechOpen

© 2019 The Author(s). Licensee IntechOpen. This chapter is distributed under the terms of the Creative Commons Attribution License (<http://creativecommons.org/licenses/by/3.0>), which permits unrestricted use, distribution, and reproduction in any medium, provided the original work is properly cited. 

References

- [1] Jafar J, Awad I, Huang P. Intracranial vascular malformations: Clinical decisions and multimodality management strategies. In: Jafar J, Awad I, Rosenwasser R, editors. *Vascular Malformations of the Central Nervous System*. Philadelphia: Lippincott Williams & Wilkins; 1999. pp. 219-232
- [2] Awad I. The diagnosis and management of intracranial dural arteriovenous malformations. *Contemporary Neurosurgery*. 1991;**13**:1-6
- [3] Awad I. Dural arteriovenous malformations. In: Carter L, Spetzler R, editors. *Neurovascular Surgery*. New York: McGraw-Hill; 1994. pp. 905-932
- [4] Soderman M, Pavic L, Edner G, Holmin S, Andersson T. Natural history of dural arteriovenous shunts. *Stroke*. 2008;**39**:1735-1739
- [5] Davies MA, Saleh J, Ter Brugge K, Willinsky R, Wallace MC. The natural history and management of intracranial dural arteriovenous fistulae: Part 1: Benign lesions. *Interventional Neuroradiology*. 1997;**3**:295-302
- [6] Davies MA, Ter Brugge K, Willinsky R, Wallace MC. The natural history and management of intracranial dural arteriovenous fistulae: Part 2: Aggressive lesions. *Interventional Neuroradiology*. 1997;**3**:303-311
- [7] Halbach VV, Higashida RT, Hieshima GB, Mehninger CM, Hardin CW. Transvenous embolization of dural fistulas involving the transverse and sigmoid sinuses. *AJNR. American Journal of Neuroradiology*. 1989;**10**:385-392
- [8] Newton TH, Cronqvist S. Involvement of dural arteries in intracranial arteriovenous malformations. *Radiology*. 1969;**93**:1071-1078
- [9] Luciani A, Houdart E, Mounayer C, Saint Maurice JP, Merland JJ. Spontaneous closure of dural arteriovenous fistulas: Report of three cases and review of the literature. *AJNR. American Journal of Neuroradiology*. 2001;**22**:992-996
- [10] Borden JA, Wu JK, Shucart WA. A proposed classification for spinal and cranial dural arteriovenous fistulous malformations and implications for treatment. *Journal of Neurosurgery*. 1995;**82**:166-179
- [11] Elhammady MS, Ambekar S, Heros RC. Epidemiology, clinical presentation, diagnostic evaluation and prognosis of cerebral dural arteriovenous fistulas. *Handbook of Clinical Neurology*. 2017;**143**:99-105
- [12] Miller TR, Gandhi D. Intracranial dural arteriovenous fistulae clinical presentation and management strategies. *Stroke*. 2015;**46**:2017-2025
- [13] Tsai LK, Liu HM, Jeng JS. Diagnosis and management of intracranial dural arteriovenous fistulas. *Expert Review of Neurotherapeutics*. 2016;**16**:307-318
- [14] Chaichana KL, Coon AL, Tamargo RJ, Huang J. Dural arteriovenous fistulas: Epidemiology and clinical presentation. *Neurosurgery Clinics of North America*. 2012;**23**:7-13
- [15] Gandhi D, Chen J, Pearl M, Huang J, Gemmete JJ, Kathuria S. Intracranial dural arteriovenous fistulas: Classification, imaging findings, and treatment. *AJNR. American Journal of Neuroradiology*. 2012;**33**:1007-1013
- [16] Serulle Y, Miller TR, Gandhi D. Dural arteriovenous fistulae imaging and management. *Neuroimaging Clinics of North America*. 2016;**26**:247-258

[17] Gupta A, Periakaruppan A. Intracranial dural arteriovenous fistulas: A review. *Indian Journal of Radiology and Imaging*. 2009;**19**:43-48

[18] Amuluru K, Al-Mufti F, Romero C. Isolated intraventricular hemorrhage secondary to dural arteriovenous fistula. *Journal of NeuroInterventional Surgery*. 2018;**10**:e7

[19] Inamasu J, Tanaka R, Nakahara I, Hirose Y. Dural arteriovenous fistula of the craniocervical junction manifesting as cerebellar hemorrhage. *The Neuroradiology Journal*. 2016;**29**:356-360

[20] Al-Afif S, Nakamura M, Götz F, Krauss JK. Spontaneous closure of a dural arteriovenous fistula. *BML Case Reports*. 2014. pii: bcr2014011255