

We are IntechOpen, the world's leading publisher of Open Access books Built by scientists, for scientists

6,900

Open access books available

185,000

International authors and editors

200M

Downloads

Our authors are among the

154

Countries delivered to

TOP 1%

most cited scientists

12.2%

Contributors from top 500 universities



WEB OF SCIENCE™

Selection of our books indexed in the Book Citation Index
in Web of Science™ Core Collection (BKCI)

Interested in publishing with us?
Contact book.department@intechopen.com

Numbers displayed above are based on latest data collected.
For more information visit www.intechopen.com



Single-Row Versus Double-Row Repair in Rotator Cuff Tears

*Michael E. Hantes, Georgios I. Chalatsis
and Georgios Mpakagiannis*

Abstract

Rotator cuff (RC) tear is a common cause of shoulder pain and disability among adults. Surgical management of RC tears is recommended after conservative treatment failure. Due to the development of arthroscopic repair techniques, the use of the arthroscopic rotator cuff repair has become the gold standard. Single-row (SR) and double-row (DR) suture anchor repairs are the two most popular and commonly used arthroscopic techniques. However, the optimal arthroscopic surgical technique remains controversial in terms of clinical and biomechanical outcomes, healing, and re-tear rates. This chapter will focus on differences between these two techniques regarding biomechanics, clinical results, healing rate, and cost effectiveness.

Keywords: rotator, cuff, repair, single-row, double-row, versus, shoulder, arthroscopy

1. Introduction

The rotator cuff is a group of muscles and their tendons which is consisted by supraspinatus, infraspinatus, teres minor and subscapularis muscles (**Figures 1** and **2**). Rotator cuff tears can hinder the daily activities and the quality of life significantly in adult population. There is a high correlation between rotator cuff tears incidence and advancing age [1]. The overall prevalence of rotator cuff tears range from 20 to 30% for patients older than 60 years old and raises even more to 62%, in patients older than 80 years (regardless of symptoms), among the general population and in patients with a history of shoulder dislocation [1–4]. Partial thickness rotator cuff tears range from 15 to 32% in the general population and rises to 40% in dominant arm of asymptomatic elite overhead athletes [1]. The tear progression is correlated with the initial tear presentation. Patients with partial thickness rotator cuff tear can heal (10%) or become smaller (10%), but 53% progress and 28% become full-thickness tears [60]. On the other hand, patients with more than 50% initial tear had 55% chance the tear to progress [5]. Keener in his study of survivorship of asymptomatic degenerative rotator cuff tears, reported that full-thickness tears were 4.2 and 1.5 times more likely to enlarge than controls and partial tears respectively. Accordingly, tear progression was a risk factor for pain development and muscle degeneration [6]. Sex does not seem to play a significant role to the development of rotator cuff tears [6, 7], although there is a correlation between postmenopausal women, and an increase prevalence in asymptomatic rotator cuff tears [8]. Patients who have been operated in one shoulder for partial or full thickness

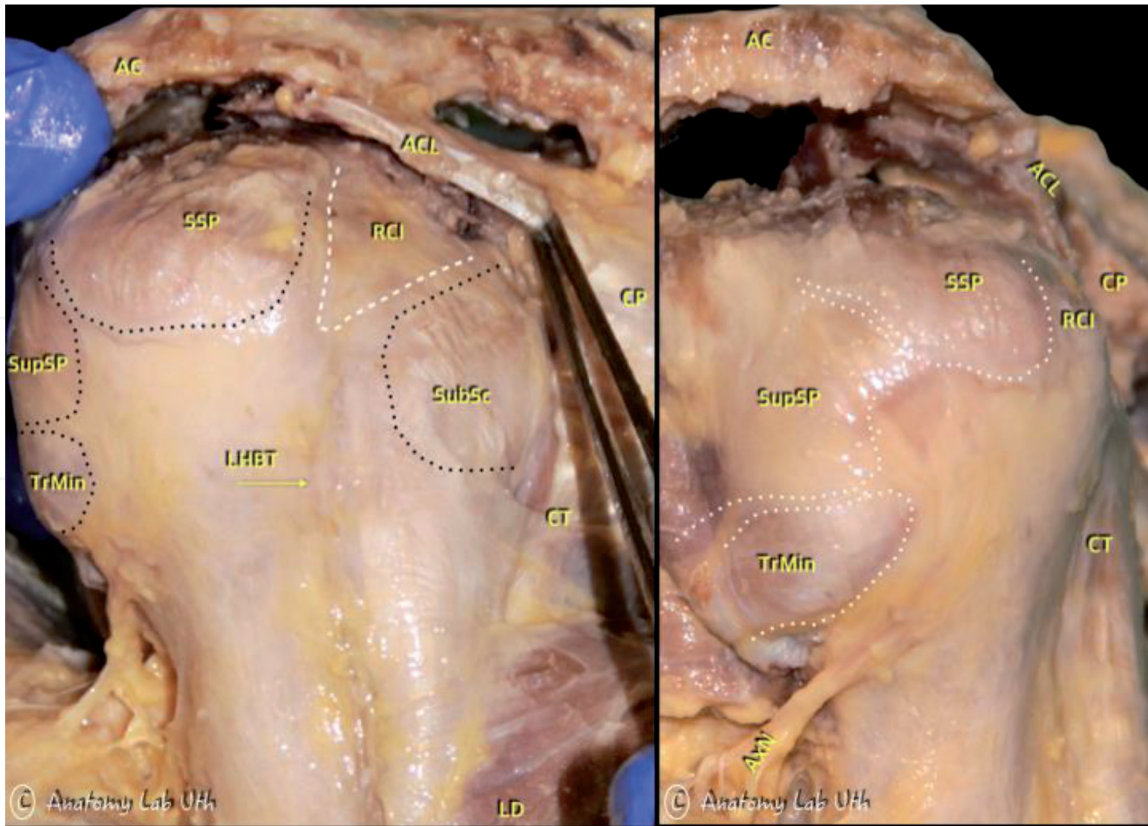


Figure 1. Frontal plane cross section of fresh frozen cadaveric shoulder specimen. SSPT, supraspinatus tendon; Arcap, articular capsule and the junction of the Arcap and SSPT is marked with the *; Rotcab, rotator cuff cable; RC, rotator cuff; TLHB, tendon of long head of humerus biceps; HH, humerus head (courtesy of A.H. Zibis Associate Professor of Anatomy, Department of Anatomy, Faculty of Medicine University of Thessaly).

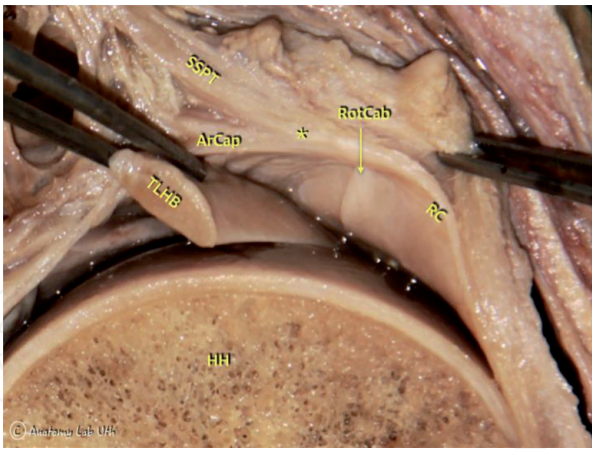


Figure 2. Lateral and oblique posterolateral view of a fresh frozen cadaveric specimen of a right shoulder. AC, acromion; ACL, coracoacromial ligament; CP, coracoid process; TrMin, Teres Minor; SupSP, Infraspinatus; SSP, Supraspinatus; RCI, rotator cuff interval; SubSc, subscapularis; LD, latissimus dorsi; AxN, axillary nerve (courtesy of A.H. Zibis associate professor of anatomy, Department of Anatomy, Faculty of Medicine University of Thessaly).

tendon tear are in increased risk of developing the same on the opposite shoulder [9]. The possibility of a bilateral tear is nearly 50% in patients over 60 years old [1]. Other important predisposing factors are history of trauma, hypercholesterolemia, occupational demands [10], smoking [11], a positive family history [12] and the body posture with higher prevalence in individuals with kyphotic-lordotic, flat back and sway-back posture than people with ideal alignment [13, 14].

Grade	
I	<3 mm (<25% thickness)
II	3–6 mm (25–50%)
III	>6 mm (>50%)
Location	
A	Articular sided
B	Bursal sided
C	Intratendinous

Table 1.
Ellman’s classification of partial thickness rotator cuff tars.

The classification of the rotator cuff tears is based on Ellman’s classification of partial-thickness rotator cuff tears [15] and is categorized based on the grade of the tear and the location (**Table 1**). Snyder [16] classified the size of the defect by its superficial extension. Grade I tears represent a synovial irritation or capsular fraying in an area less than 1 cm, Grade II tear is a lesion with a fraying and failure of some rotator cuff fibers, and additionally synovial, bursal, or capsular injury in an area smaller than 2 cm. Grade III is a tear of the tendon fibers less than 3 cm. Fraying and fragmentation of the tendon and a tear more than 3 cm, involving more than a single tendon, is assessed as a grade IV lesion. Partial articular supraspinatus tendon avulsion, with a traumatic etiology is described as a special form of a type AIII or AIV.

The International Society of Arthroscopy, Knee Surgery and Ortopaedic Sports Medicine Shoulder Committee in its consensus recommendations for the RC tears classification system advices five important factors to be accounted: location, extension, pattern, fatty atrophy and retraction [17].

Adequate initial fixation plays a key role in achieving successful restoration of the rotator cuff tear. The primary function of the rotator cuff is to keep the head of the humerus centered into the glenoid fossa permitting a single center of rotation while enabling abduction or forward flexion [18, 19]. This is achieved with the balance of force couples around the glenohumeral joint. Two couple forces exist in the shoulder joint, the coronal force couple, with Deltoid versus inferior rotator cuff (Infraspinatus, Scapularis and Teres Minor) which opposes the force created by Deltoid muscle [20] and the transverse force couple [21, 22] which is a balance between Scapularis anteriorly and Infraspinatus and Teres Minor posteriorly. In massive RC tears, with the involvement of Infraspinatus muscle, along with Supraspinatus, the force couples are misbalancing, leading to posterosuperior migration of the head and incapability to maintain a steady fulcrum of motion.

Important anatomic factors for the success of the surgical reconstruction include the restoration of the footprint contact area, and the adequate compression of the tendon on it [23, 24], along with the rotator cuff muscles, tendon and bone quality [13]. Although various techniques like open and mini open surgery have been used in the past, the advance of arthroscopic repair techniques, with the development of the suture anchors, have become more and more popular [25]. Although there was no significant difference between re-tear rates, functional and pain scores, between mini-open and arthroscopic reconstruction, patients who received arthroscopic repair had fewer post-operation complications and returned earlier to work [18, 26]. However, there is still controversy which arthroscopic technique of the two most

commonly used - single-row (SR) and the double-row (DR) – provide better clinical results [19].

2. Operative techniques

According to the geometric tear patterns of the rotator cuff, four different types of repairs have been described [28]. Type 1 is crescent-shaped tears, relatively short and wide. The medial to lateral length of these tears is less than anterior to posterior width and can be fixed directly to the bone bed on the greater humeral tuberosity [29–32]. Type II is longitudinal (U- and L-shaped) tears. The medial-to-lateral length of these tears is greater than the anterior-to-posterior width (**Figure 3**). These types of tears are usually repaired by a side to side convergence technique, reducing the strain of the lateral free margin of the cuff, with suture anchors, without tension [29, 31, 32]. Type III, are large contracted tears, long and wide. The tendon edge is too long and cannot be pulled directly to the bone and additionally too wide for the edges to be closed side to side. Interval slides or partial repairs are necessary for this type of lesions [30, 33–38]. Finally, type IV tears are related with significant glenohumeral arthritis and complete loss of the acromiohumeral interspace. These massive lesions are not repairable by arthroscopic or open surgery and the current treatment concept is arthroplasty.

The suture anchor techniques that are used more often are the single row (SR) and the double row (DR). Both of them have modifications. In the SR repair technique, there is the knotted and knotless repair, and in DR repair technique, there is the simple DR and the transosseous equivalent.

In the SR technique, two (or even more) double-loaded suture anchors are placed in a single row into the greater tuberosity at the lateral edge of the foot-print of the tendon's insertion (**Figures 4 and 5**). Anchor sutures are passed and tied in a simple or horizontal-mattress configuration, in a single anterior–posterior row in the knotted repair. The sutures are passed through the tendon, evenly spaced and 5 mm from the torn edge and then secured with knots and repair is achieved with a minimal tension. For the knotless repair the mattress suture are driven through the torn tendon with the help of an implant. A hole for the anchor is created into the corresponding position on the footprint. Both limbs of the suture are passing through the implant and the anchor and suture construct implanted together into the prepared hole. The anchor is reducing and locking the tendon to the bone [39] (**Figures 6–8**).

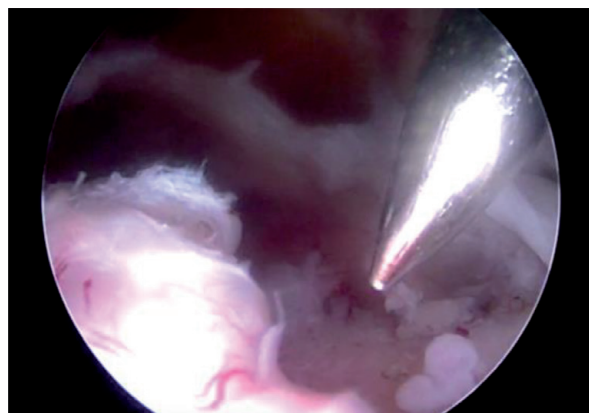


Figure 3.
Type II rotator cuff tear. Placement of guide for suture anchor.

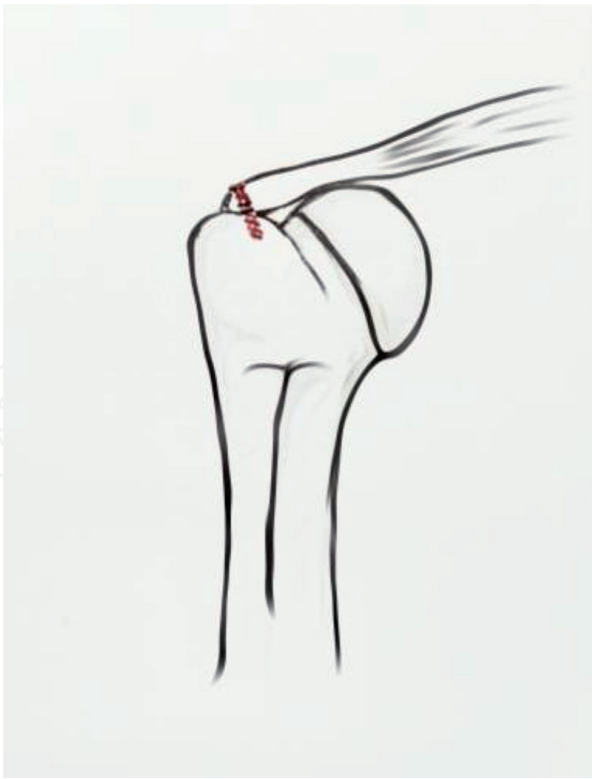


Figure 4.
Coronal view of Single Row suture anchors.

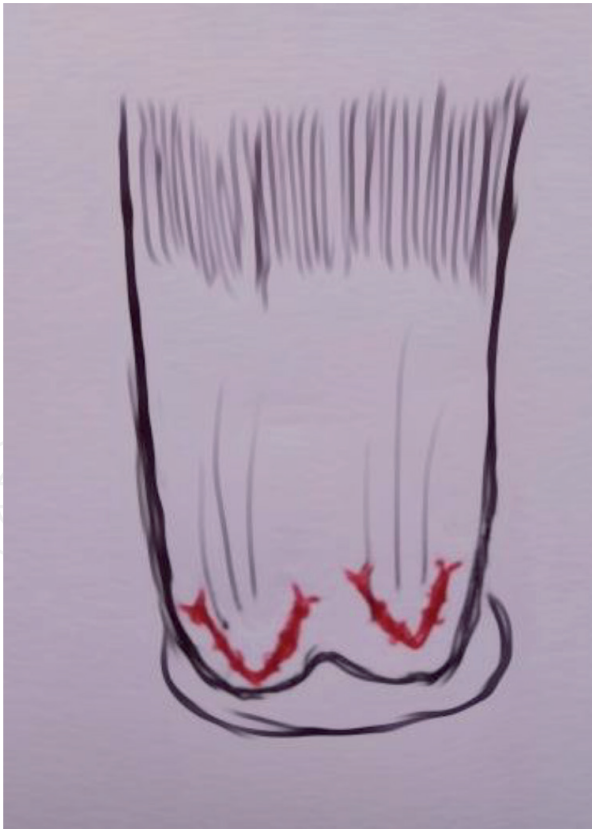

Figure 5.
Axial view of Single Row suture anchors.

In the DR repair technique two rows of anchors are placed, one medial, adjacent to the articular cartilage in the anatomical neck and the other lateral, in the greater tuberosity, in order to provide better anatomical footprint restoration [40, 41] (**Figures 9 and 10**). In order for the repair structure not to lead to excessive tension,

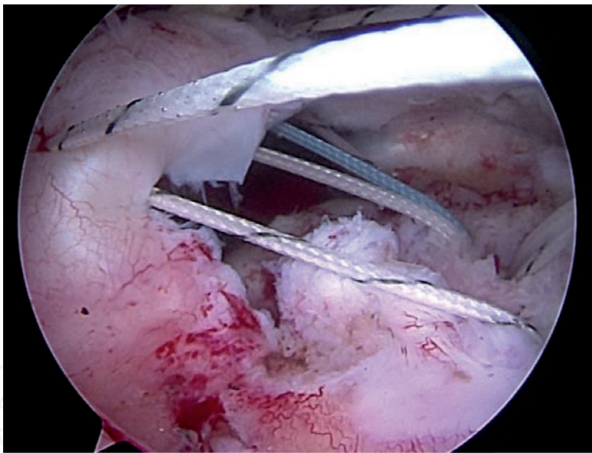


Figure 6.
Sutures through the tendon in a SR repair.

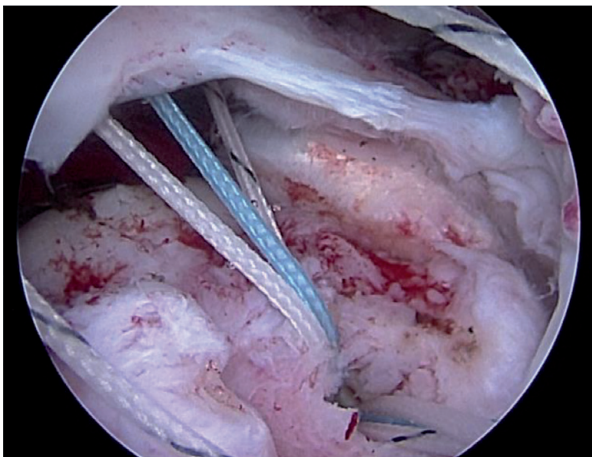


Figure 7.
A triple suture loaded anchor with sutures passed through the tendon in a SR repair.

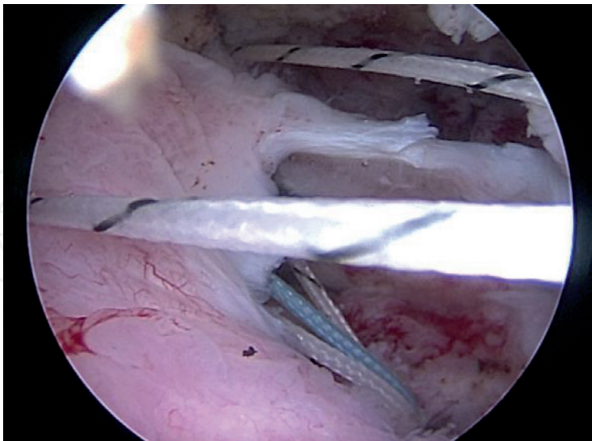


Figure 8.
All sutures anchors passed through the tendon.

the torn tendon should be mobilized to ensure that it can reach the lateral side of greater tubercle. Firstly, the medial row suture anchors are placed through at least 10–12 mm apart from each other and 12–15 mm medially from the lateral edge of the torn rotator cuff tendon in a horizontal mattress fashion [42]. Subsequently, the lateral row suture anchors are placed along the lateral side of greater tubercle. The lateral row suture anchors are passed through the lateral side of the tendon by simple suture configuration and tied in way that it will create a suture bridge construct.

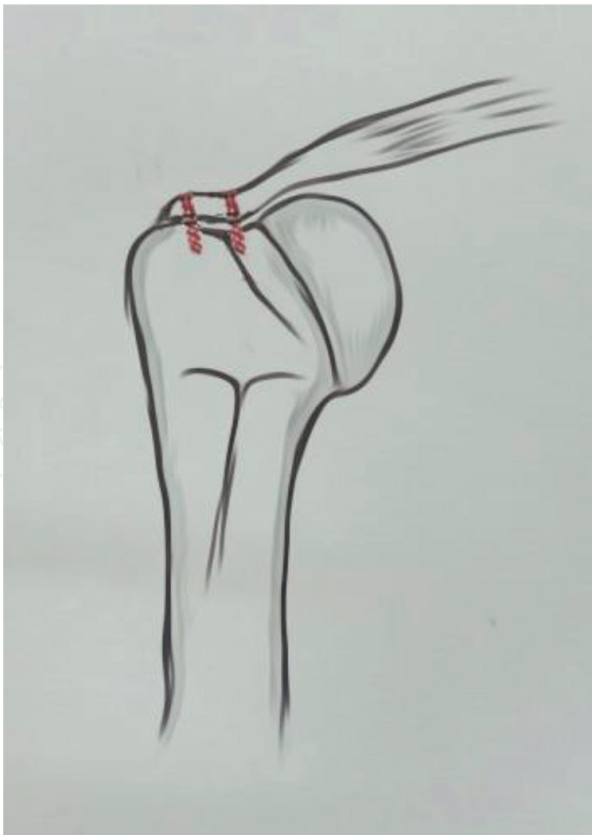


Figure 9.
Coronal view of Double Row suture anchors.

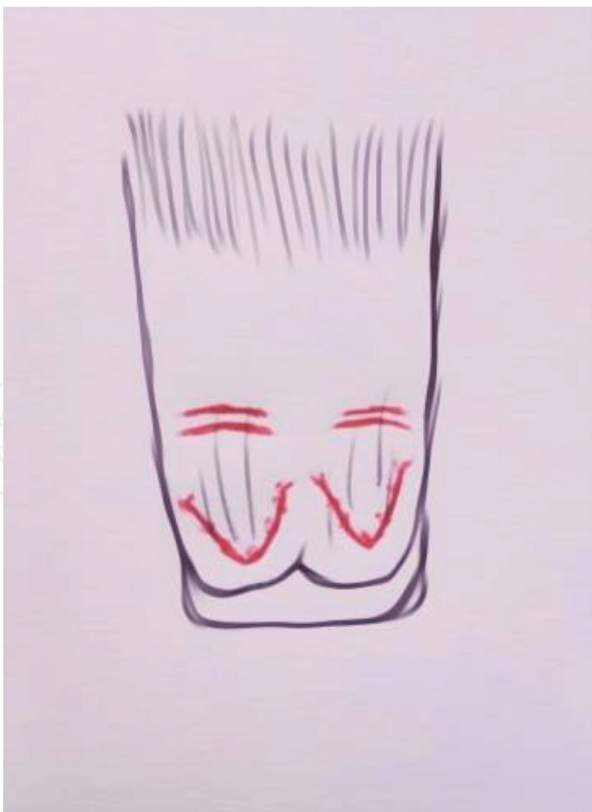

Figure 10.
Axial view of Double Row suture anchors.

After that, the medial row sutures are tied with proper tension. Depending on the size of the tear, the preference about the number of the anchors may vary. Throughout, the most important point is the assurance that remains adequate

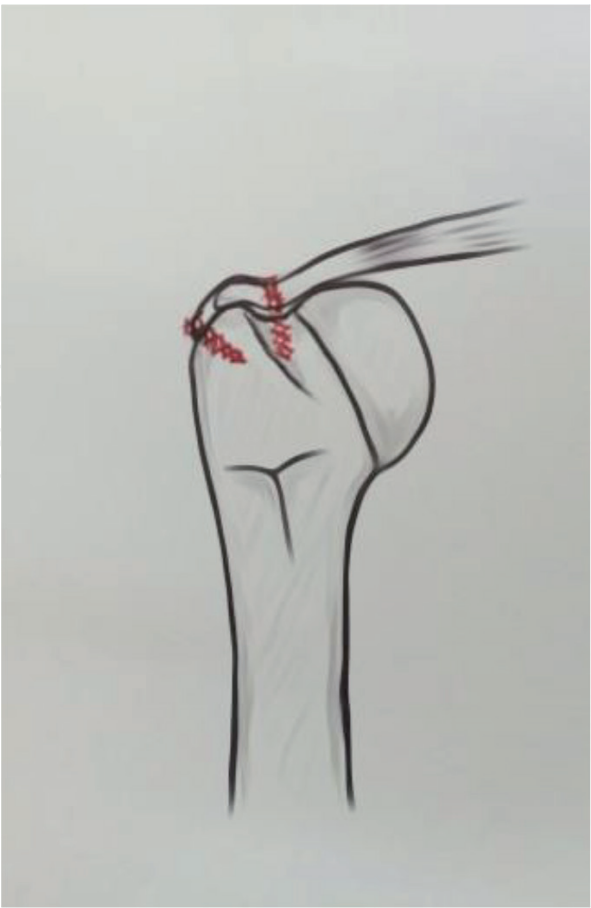

Figure 11.
Coronal view of Transosseous equivalent repair.

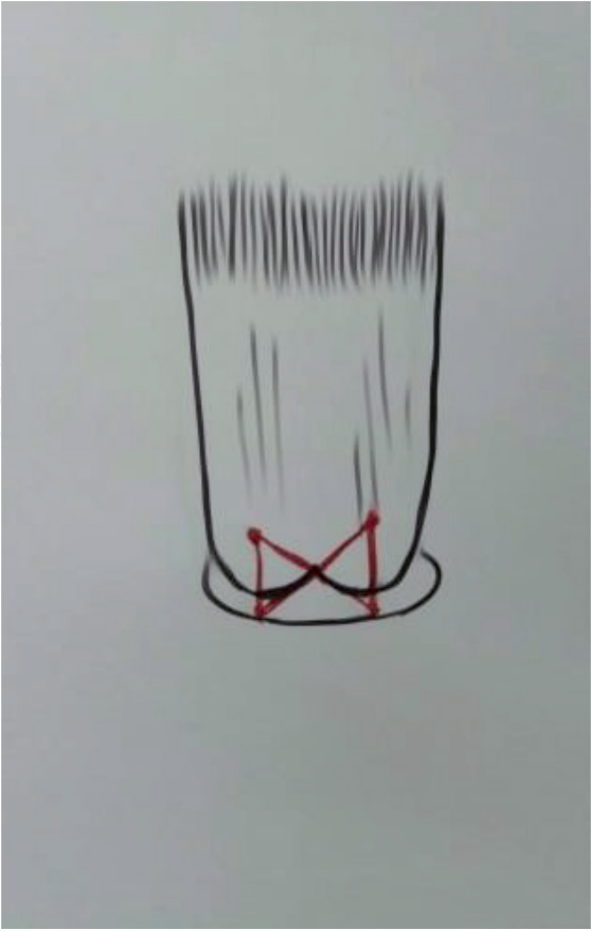


Figure 12.
Axial view of Transosseous equivalent repair.

block of bone between the anchors in order to prevent the risk of overcrowding and anchor failure.

Transosseous equivalent repair with knotless anchors is a modification of traditional double row technique. After the medial row sutures have been placed 12–15 mm medial to the torn edge, they are tied in a mattress fashion. Both limbs of each suture from the medial anchors are then crossed over and brought laterally down to the lateral aspect of greater tuberosity, compressing the tendon to the anatomical footprint. In this way, tissue strangulation by the knots is decreased and tendon vascularity is better preserved (**Figures 11 and 12**).

3. Biomechanics

Biomechanics analysis holds an important place in comparing those two techniques. A lot of cadaveric and animal model has been demonstrated over the times but none of them can foretell the healing potential but surely can answer about the failure strength (especially at day one) each technique provides, footprint restoration, gap formation and the pros and cons of each method. So, each technique must be biomechanically adequate in order to provide a good healing environment and provide adequate fixation until the healing is done.

The mandatory biomechanical features that should be provided are high initial fixation strength, minimal gap formation and the continuation of mechanical stability until the durable bone-tendon repair is completed [43]. In matter of biomechanics, DR repair seems to be far more superior to SR technique. Several studies have shown that DR has the capacity to restore the anatomical footprint almost to 100% something that it cannot be achieved while using SR repair technique and can lead to substantial morbidity. Also, it is shown that DR is a sturdier technique and can reduce the tendon-bone interface mobility and that can lead to better healing environment [44–46].

Although there are some data suggesting that there may be no difference in biomechanical features between those two techniques, most studies support that DR repair has a stronger structure in RC repair due to better restoration of the footprint, higher initial and failure strength, increased footprint contact pressure and lesser gap formation risk and all that can lead to better healing environment and enable more aggressive postoperative rehabilitation [47, 48].

4. Healing and re-tear rate

Healing of a torn rotator cuff is a formation of a continuous layer of tissue from the rotator cuff muscle to its insertion on the greater tuberosity [49]. The rotator cuff healing without surgical repair has been shown to be lower and inadequate in quality as demonstrated in animal models. A significant problem after RC repair is the re-tear on non-healing of the tendon [50, 51]. There are several factors that influence the re-tear rates such as age, preoperative tear size, degree of muscular atrophy, degree of fatty infiltration, surgical technique and inappropriate post-operative rehabilitation [52]. There are numerous studies in the literature that investigate the structural integrity and re-tear rates of these surgical techniques. The retrospective study of Sugaya et al. one of the longest follow up studies which compares the re-tear rates of SR and DR technique, they found 56% re-tear rate in patients treated with SR and 27% re-tear rate in patients who underwent DR repair after 3 years of follow up [53]. Several studies in the literature showed that patients who underwent RC repair and have re-rupture of the rotator cuff tendon are in better condition in terms of pain than they were pre-operative [54], but other

studies directly contradict that and suggest that re-ruptures are associated with loss of strength [55]. Charousset et al. investigated re-tear rates of the patients using CT arthrography and demonstrated that anatomic healing was better in DR repair than SR [56]. The radiological outcomes of SR and DR repair in medium size rotator cuff tears using MR arthrography was examined by Tudisco et al. and detected a lower re-tear rate in DR technique [57]. A systematic review by Duquin et al. [58] also showed that in RC tears more than 10 mm in size, SR repair has significantly larger re-tear rates than DR repair, also in a meta-analysis which compared SR re-tear rates with DR rates revealed bigger re-tear rate in SR repair especially in partial thickness re-tears [27]. Finally, in patients who are in high risk of shoulder stiffness after the operation and are in need for accelerated rehabilitation protocol Franceschi et al. proved that DR repair had significant lower rates of re-tear than SR [59]. In a meta-analysis by Millet et al. in which they concluded only level of evidence I studies they found higher rates of re-tear in SR 25.9% compared to DR repair 14.2% [60]. Finally, a prospective comparative study by Hantes et al. [61] proved that double-row repair provides superior tendon healing compared to single-row and also DR must be considered in patients <55 years with medium to large RC tears.

However, RC healing has questionable association with outcomes. Tear and patient age, comorbidities, Nonsteroidal Anti-Inflammatory Drugs (NSAIDs), smoking status, osteoporosis and tendon shortening and retraction, affects negatively the outcomes. Surgical repair techniques and rehabilitation play important role but have varying degrees of impact on the final result [62–64].

The general consensus in the literature is because of the biomechanical superiorities of DR repair, which are demonstrated in experimental environments carry over healing capacity and lead to lower re-tear rates.

5. Cost

The DR technique has some obvious disadvantages such as time consuming, higher difficulty and it's more expensive. These factors are more significant if the final outcome is not associated with better clinical results than SR repair. In their study, Bisson et al. [65] tried to calculate the costs of the US healthcare system of transition from SR to DR rotator cuff repair and to calculate the decrease in re-operations for re-tear that DR rotator cuff repair would need to accomplish in order to render the transition cost-neutral. The calculated cost for SR repair technique was \$7572 while for DR repair technique was \$12,979. They concluded that DR repair would require a large decrease in revision surgery rates to justify this difference in cost.

Genuario et al. [66] in their study evaluated two different group of patients. One with >3 cm rotator cuff tear and another one with <3 cm and created a decision-analytic model to measure the cost-effect of DR repair compared to SR repair. It was found that DR rotator cuff repair was not cost-effective in any size of tear.

On the other hand, a later cost-utility analysis by Huang et al. [67], indicated that even though there were no significant differences in functional or quality-of-life measures between single row and double row repair technique, double row repair was more cost effective than SR. There was also noted that DR fixation was more economically friendly for tear larger than 3 cm.

According to all this and in conjunction to the absence of studies that correlate the cost of each repair technique with healing, re-tear rate, clinical outcomes and additional cost during follow up (failure of treatment, necessity for extra conservative treatment), there is no consensus with regards to the financial viability of one technique over the other one.

6. Functional and clinical outcomes

In both SR and DR techniques the functional shoulder scores, after rotator cuff repair, improve significantly. The clinical evaluation among several studies is based on many important aspects in patient's daily life, such as range of motion, function, strength, pain and general satisfaction. Some often-used scores are ASES (American Shoulder and Elbow Surgeons) shoulder scale [68], which is a subjective measurement that assess pain and level of function and it is scaled from 0 to 100, the Constant shoulder score [69], which combines subjective and objective data into a functional score on a scale also from 0 to 100, and the UCLA (University of California, Los Angeles) shoulder rating scale [70] that uses subjective and objective measurements that evaluate shoulder function on a scale of 0–35.

Several randomized controlled trials (RCTs) have been conducted comparing the two techniques. Many authors concluded that there is no statistically significant clinical difference between the two surgical methods. In 2009, Burks et al. [71] split evenly 40 patients in two repair groups (single versus double row) and evaluated their functional improvement without finding any difference. Aydin et al. [72] divided 64 patients evenly in two groups with a minimal 2 year follow up, with no significant difference in clinical outcome (Constant score) between them. Koh et al. [73] studied 62 patients (31 in each group) through clinical scores and patient satisfaction with no statistically important difference. Lapner et al. [74] did not find any significant difference in functional or quality of life outcomes in a heterogenous group of patients with tears of all sizes. Nicholas et al. [75] looking 49 patients in a prospective RCT found no differences between DR and SR repair for medium, large and massive rotator cuff tears in terms of outcome scores, clinical tests of shoulder function, shoulder range of movement (ROM) or shoulder strength.

Similar results were found also and in a systematic review and meta-analysis of 7 level I RCTs by Millet et al. [36], concluding that there were no detectable differences in improvement in outcomes scores (ASES, UCLA and Constant) between single row and double row repairs. The same result was found by Spiegl et al. [27], in a summary of eight meta-analysis comparing clinical differences between repairs for small and medium rotator cuff tears, in short and medium follow up.

On the other hand, Park et al. [77] whilst did not find significant functional difference in tears less than 3 cm, noted better results for the double row repair in tears larger than 3 cm. In a larger multicenter RCT by Carbonel et al. [78], with a minimum 2 year follow up and patients with large full thickness rotator cuff tears, DR repairs showed a significant difference in clinical outcomes (UCLA, Constant and ASES) compared with single row repair. A prospective RCT by Ma et al. [79] pointed that DR reconstruction showed better shoulder strength in patients with larger tear size (>3 cm) in comparison with SR.

In a more recent study, Hantes et al. [61] studied 66 individuals younger than 55 years old. Although there was no significant difference in outcomes scores observed between the two groups, they noted that patients in the DR group had a higher tendon healing rate ($p < 0.05$) and patients with healed tendon demonstrated superior clinical outcomes compared with patients who had return tendon ($p < 0.05$).

Saridakis et al. [80], despite the fact that in six studies found no significant differences, within their data, there was some evidence to support the use of DR repair in patients with large (>3 cm) tears.

Tasjian et al. [81] compared healing and function after single-row repair versus double row repair with a suture bridge technique for RC tears of size 1–3 cm and similar improvements in pain and function for a follow up period of 12 months.

In terms of re-tear rate, Franceschi [82] compared partial and full thickness re-tear after SR and DR rotator cuff repair. From the 52 patients equally distributed in two groups, there was no statistically significant difference neither in partial nor in full-thickness re-tears of RC. The same results have been observed by Carbonel et al. [78] and Barber [83] with no difference in both groups of partial or full thickness re-tear, no matter the technique. Park et al. [77] studied patients in groups according to the tear size also. They found lower re-tear rates with DR technique in large tears only. Koh et al. [73] in his RCT found no significant difference for full thickness re-tears in 6 out of 23 patients undergoing DR repair and 4 out of 24 patients undergoing SR repair. On the other hand, there was a significant difference for partial thickness re-tears with 1 patient out of 23 in DR group and 11 patients out of 24 in SR group. Franceschi et al. [59] detected a difference in overall re-tear rates in DR and SR repair groups but when examined each size of tear separately found no significant difference for partial and full thickness tears between the two groups.

In his recent meta-analysis, Sobhy et al. [84] noted that there was a statistically significant difference between groups only for partial thickness re-tears and not for full thickness re-tears. He also found that DR repair showed improved UCLA scores and a correlation between cuff integrity and functional outcomes. The authors also noted that long-term level III studies showed a direct correlation of both functional and cuff structural integrity, with DR repair technique being superior than SR. This seems to be in a contrast compared with previous studies [76, 85] which concluded that there is no correlation between cuff integrity and shoulder function. The reason probably is that they depended on short- or mid-term results which did not give enough time to the two repair techniques to demonstrate significant functional and structural results and also the sample size, the patient population and the inherent study to study variability.

Yang et al. [86] in their meta-analysis of the clinical effect of the rotator cuff repair in single and double row repairs in 29 studies noted that full-thickness re-tear had considerable effect on clinical outcome.

Despite the biomechanical privilege, footprint coverage and tendon-to-bone contact than could lead to better healing of DR and Suture bridge techniques [87–91], excessive contact pressure, that can lead to reduced blood flow to rotator cuff tendon [92], can be the reason for high rates of re-tear. Stress concentration around the medial anchors has been observed to lead to an increased risk of medial cuff failure [93–97]. Two types of tears have been described [95], type 1 is a failure at the tendon-bone interface and type 2 is medial cuff failure with remnant cuff attached to the greater tuberosity. Therefore, there is a necessity for technical modifications of the DR and Suture bridge techniques, minimizing the stress on medial anchors and decreasing the risk of medial strangulation and necrosis.

7. Conclusions

The increasing likelihood of occurrence RC tears with advancing age and longevity makes adequate RC repair a very challenging matter due to results in activity restriction and severe pain. Regarding the functional and clinical outcome, although there is no consensus between studies which repair technique is superior in general, it is well documented that studies with homogenous groups (regarding the size of the tear) indicate a slight superiority of the DR technique. The biomechanical evidence support the supremacy of the DR repair and the same result is applicable for re-rupture and healing rate, comparing with the SR technique. However, DR repair is more demanding for the surgeon technique. The learning

curve is much higher than SR. Although that DR is a more expensive technique than SR, there is a necessity for more studies to be conducted to justify and correlate cost with healing, re-tear rate and clinical outcomes. Considering the existing evidence, the type of repair must be individualized according to the tear size. DR repair should be performed to patients with larger tears and in patients who are in need for accelerated rehabilitation, while patients with small tears can have the same clinical outcome with SR repair.

Acknowledgements

A.H. Zibis, Associate Professor of Anatomy, Department of Anatomy, Faculty of Medicine University of Thessaly.

Conflict of interest

The authors declare no conflict of interest.

Notes/thanks/other declarations

Special thanks to Christos Chalatsis for the drawings.

Abbreviations

RC	rotator cuff
SR	single row
DR	double row
SB	suture bridge
ROM	range of movement
RCT	randomized control trial
ASES	American shoulder and elbow surgeons
UCLA	University of California, Los Angeles
NSAIDs	nonsteroidal anti-inflammatory drugs

Author details

Michael E. Hantes*, Georgios I. Chalatsis and Georgios Mpakagiannis
Faculty of Medicine, Department of Orthopaedic Surgery, School of Health Sciences, University of Thessaly, Larisa, Greece

*Address all correspondence to: hantesmi@otenet.gr

IntechOpen

© 2019 The Author(s). Licensee IntechOpen. This chapter is distributed under the terms of the Creative Commons Attribution License (<http://creativecommons.org/licenses/by/3.0>), which permits unrestricted use, distribution, and reproduction in any medium, provided the original work is properly cited. 

References

- [1] Yamaguchi K, Ditsios K, Middleton WD, Hildebolt CF, Galatz LM, Teefey SA. The demographic and morphological features of rotator cuff disease. A comparison of asymptomatic and symptomatic shoulders. *The Journal of Bone and Joint Surgery. American Volume*. 2006;**88**:1699-1704. PMID: 16882890
- [2] Teunis T, Lubberts B, Reilly BT, Ring D. A systematic review and pooled analysis of the prevalence of rotator cuff disease with increasing age. *Journal of Shoulder and Elbow Surgery*. 2014;**23**:1913-1921. PMID: 25441568
- [3] Fehring EV, Sun J, VanOeveren LS, Keller BK, Matsen FA. Full-thickness rotator cuff tear prevalence and correlation with function and co-morbidities in patients sixty-five years and older. *Journal of Shoulder and Elbow Surgery*. 2008;**17**:881-885
- [4] Moosmayer S, Smith HJ, Tariq R, Larmo A. Prevalence and characteristics of asymptomatic tears of the rotator cuff: An ultrasonographic and clinical study. *Journal of Bone and Joint Surgery. British Volume (London)*. 2009;**91**:196-200
- [5] Mall NA, Kim HM, Keener JD, et al. Symptomatic progression of asymptomatic rotator cuff tears: A prospective study of clinical and sonographic variables. *The Journal of Bone and Joint Surgery*. 2010;**92**(16):2623-2633
- [6] Keener JD, Galatz LM, Teefey SA, et al. A prospective evaluation of survivorship of asymptomatic degenerative rotator cuff tears. *The Journal of Bone and Joint Surgery*. 2015;**97**(2):89-98. DOI: 10.2106/JBJS.N.00099. PMID: 25609434
- [7] Pauly S, Stahnke K, Klatte-Schulz F, Wildemann B, Scheibel M, Greiner S. Do patient age and sex influence tendon cell biology and clinical/radiographic outcomes after rotator cuff repair? *The American Journal of Sports Medicine*. 2015;**43**:549-556
- [8] Milgrom C, Schaffler M, Gilbert S, van Holsbeeck M. Rotator-cuff changes in asymptomatic adults. The effect of age, hand dominance and gender. *Journal of Bone and Joint Surgery. British Volume (London)*. 1995;**77**:296-298
- [9] Abate M, Schiavone C, Di Carlo L, Salini V. Prevalence of and risk factors for asymptomatic rotator cuff tears in postmenopausal women. *Menopause*. 2014;**21**:275-280
- [10] Liem D, Buschmann VE, Schmidt C, Gosheger G, Vogler T, Schulte TL, et al. The prevalence of rotator cuff tears: Is the contralateral shoulder at risk? *The American Journal of Sports Medicine*. 2014;**42**:826-830
- [11] Yamamoto A, Takagishi K, Osawa T, Yanagawa T, Nakajima D, Shitara H, et al. Prevalence and risk factors of a rotator cuff tear in the general population. *Journal of Shoulder and Elbow Surgery*. 2010;**19**:116-120
- [12] Kim KC, Shin HD, Cha SM, Park JY. Repair integrity and functional outcome after arthroscopic conversion to a full-thickness rotator cuff tear: Articular- versus bursal-side partial tears. *The American Journal of Sports Medicine*. 2014;**42**:451-456
- [13] Lee TQ. Current biomechanical concepts for rotator cuff repair. *Clinics in Orthopedic Surgery*. 2013;**5**(2):89-97
- [14] Lindley K, Jones GL. Outcomes of arthroscopic versus open rotator cuff repair: A systematic review of the literature. *American Journal of Orthopedics (Belle Mead, N.J.)*. 2010;**39**:592-600

- [15] Ellman H. Diagnosis and treatment of incomplete rotator cuff tears. *Clinical Orthopaedics and Related Research*. 1 May 1990;(254):64-74
- [16] Snyder SJ. Arthroscopic classification of rotator cuff lesions and surgical decision making. In: *Shoulder Arthroscopy*. 2nd ed. Philadelphia: Lippincott Williams & Wilkins; 2003. pp. 201-207
- [17] Arce G, Bak K, Bain G, et al. Management of disorders of the rotator cuff: Proceedings of the ISAKOS Upper Extremity Committee Consensus Meeting. *Arthroscopy*. 2013;**29**:1840-1850
- [18] Saha AK. Dynamic stability of the glenohumeral joint. *Acta Orthopaedica Scandinavica*. 1972;**42**:476-483
- [19] Basmajian JV, Bazant FJ. Factors preventing downward dislocation of the adducted shoulder joint. An electromyographic and morphological study. *The Journal of Bone and Joint Surgery*. 1959;**41A**:1182-1186
- [20] Inman VT, Saunders JB, Abbott LC. Observations of the function of the shoulder joint. 1944. *Clinical Orthopaedics and Related Research*. Sept 1996;(330):3-12
- [21] Burkhart SS. Partial repair of massive rotator cuff tears: The evolution of a concept. *The Orthopedic Clinics of North America*. 1997;**28**:125-132
- [22] Burkhart SS. A stepwise approach to arthroscopic rotator cuff repair based on biomechanical principles. *Arthroscopy*. 2000;**16**:82-90
- [23] Roth KM, Warth RJ, Lee JT, Millett PJ, ElAttrache NS. Arthroscopic single-row versus double-row repair for full thickness posterosuperior rotator cuff tears: A critical analysis review. *JBJS Reviews*. 22 Jul 2014;**2**(7). DOI: 10.2106/JBJS.RVW.M.00081
- [24] Park MC, Cadet ER, Levine WN, Bigliani LU, Ahmad CS. Tendon-to-bone pressure distributions at a repaired rotator cuff footprint using transosseous suture and suture anchor fixation techniques. *The American Journal of Sports Medicine*. 2005;**33**(8):1154-1159
- [25] Colvin AC, Egorova N, Harrison AK, Moskowitz A, Flatow EL. National trends in rotator cuff repair. *The Journal of Bone and Joint Surgery. American Volume*. 2012;**94**(3):227-233
- [26] Agrawal V, Stinson M. Ability and length of time to return to work after RCR in workers' compensation patient. *Indiana Orthopaedic Journal*. 2008;**2**:49
- [27] Spiegl UJ, Euler SA, Millett PJ, Hepp P. Summary of meta-analyses dealing with single-row double-row repair techniques for rotator cuff tears. *The Open Orthopaedics Journal*. 2016;**10**(Suppl 1):330-338. DOI: 10.2174/1874325001610010330
- [28] Davidson J, Burkhart SS. The geometric classification of rotator cuff tears: A system linking tear pattern to treatment and prognosis. *Arthroscopy*. 2010;**26**(3):417-424
- [29] Burkhart SS, Danaceau SM, Pearce CE. Arthroscopic rotator cuff repair: Analysis of results by tear size and by repair technique-margin convergence versus direct tendon-to-bone repair. *Arthroscopy*. 2001;**17**:905-912
- [30] Davidson JF, Burkhart SS, Richards DP, Campbell SE. Use of preoperative magnetic resonance imaging to predict rotator cuff tear pattern and method of repair. *Arthroscopy*. 2005;**21**:1428.e1-1428.e10
- [31] Burkhart SS. Current concepts: A stepwise approach to arthroscopic rotator cuff repair based on biomechanical principles. *Arthroscopy*. 2000;**16**:82-90

- [32] Lo IK, Burkhart SS. Biomechanical principles of arthroscopic repair of the rotator cuff. *Operative Techniques in Orthopaedics*. 2002;**12**:140-155
- [33] Lo IK, Burkhart SS. Arthroscopic repair of massive, contracted, immobile rotator cuff tears using single and double interval slides: Technique and preliminary results. *Arthroscopy*. 2004;**20**:22-33
- [34] Burkhart SS, Nottage WM, Ogilvie-Harris DJ, Kohn HS, Pachelli A. Partial repair of irreparable rotator cuff tears. *Arthroscopy*. 1994;**10**:363-370
- [35] Tauro JC. Arthroscopic rotator cuff repair: Analysis of technique and results at 2- and 3-year follow-up. *Arthroscopy*. 1998;**14**:45-51
- [36] Tauro JC. Arthroscopic “interval slide” in the repair of large rotator cuff tears. *Arthroscopy*. 1999;**15**:527-530
- [37] Cordasco FA, Bigliani LU. The rotator cuff: Large and massive tears. Techniques of open repair. *Orthopedic Clinics of North America*. 1997;**28**:179-193
- [38] Codd TP, Flatow EL. Anterior acromioplasty, tendon mobilization and direct repair of massive rotator cuff tears. In: Burkhart SS, editor. *Rotator Cuff Disorders*. Vol. 330. Baltimore: Williams & Wilkins; 1996
- [39] Gartsman GM, Hammerman SM. Full-thickness tears: Arthroscopic repair. *The Orthopedic Clinics of North America*. 1997;**28**:83-98
- [40] Lo KYI, Burkhart SS. Double-row arthroscopic rotator cuff repair: Re-establishing the footprint of the rotator cuff. *Arthroscopy*. 2003;**19**(9):1035-1042
- [41] Snyder SJ. *Shoulder Arthroscopy*. 2nd ed. Philadelphia: Lippincott Williams & Wilkins; 2002
- [42] Aydin N KB, Gurcan M, Ozsahin MK. Arthroscopic double-row rotator cuff repair: A comprehensive review of the literature. *SICOT Journal*;4:57. DOI: 10.1051/sicotj/2018048
- [43] Gerber C, Schneeberger AG, Perren SM, Nyffeler RW. Experimental rotator cuff repair. A preliminary study. *The Journal of Bone and Joint Surgery*. 1999;**81**:1281-1290
- [44] Brady PC, Arrigoni P, Burkhart SS. Evaluation of residual rotator cuff defects after in vivo single- versus double-row rotator cuff repairs. *Arthroscopy*. 2006;**22**:1070-1075
- [45] Meier SW, Meier JD. Rotator cuff repair: The effect of double-row fixation on three-dimensional repair site. *Journal of Shoulder and Elbow Surgery*. 2006;**15**:691-696
- [46] Milano G, Grasso A, Zarelli D, et al. Comparison between single-row and double-row rotator cuff repair: A biomechanical study. *The Knee Surgery, Sports Traumatology, Arthroscopy*. Jan 2008;**16**(1):75-80. DOI: 10.1007/s00167-007-0382-0. [Epub 8 Aug 2007]
- [47] Mahar A, Tamborlane J, Oka R, et al. Single-row suture anchor repair of the rotator cuff is biomechanically equivalent to double-row repair in a bovine model. *Arthroscopy*. 2007;**23**:1265-1270
- [48] Nelson CO, Sileo MJ, Grossman MG, Serra-Hsu F. Single-row modified mason-allen versus double-row arthroscopic rotator cuff repair: A biomechanical and surface area comparison. *Arthroscopy*. 2008;**24**:941-948
- [49] Mall NA, Tanaka MJ, Choi LS, Paletta GA. Factors affecting rotator cuff healing. *The Journal of Bone and Joint Surgery. American Volume*. 2014;**96**:778-788. DOI: 10.2106/JBJS.M.00583

- [50] Harryman DT, Mack LA, Wang KY, Jackins SE, Richardson ML, Matsen FA. Repairs of the rotator cuff. Correlation of functional results with integrity of the cuff. *Journal of Bone and Joint Surgery*. 1991;**73**(7):982-989. DOI: 10.2106/00004623-199173070-00004
- [51] Lafosse L, Brzoska R, Toussaint B, Gobeze R. The outcome and structural integrity of arthroscopic rotator cuff repair with use of the double-row suture anchor technique. *Surgical technique. The Journal of Bone and Joint Surgery*. 2008;**90**(Suppl 2 Pt 2):275-286. DOI: 10.2106/JBJS.H.00388
- [52] Galanopoulos I, Ilias A, Karliaftis K, Papadopoulos D, Ashwood N. The impact of re-tear on the clinical outcome after rotator cuff repair using open or arthroscopic techniques: A systematic review. *The Open Orthopaedics Journal*. 2017;**11**(Suppl 1):95-107. DOI: 10.2174/1874325001711010095.M4
- [53] Sugaya H, Maeda K, Matsuki K, Moriishi J. Repair integrity and functional outcome after arthroscopic double row rotator cuff repair: A prospective outcome study. *The Journal of Bone and Joint Surgery*. 2007;**89**:953-960
- [54] Galatz LM, Ball CM, Teefey SA, Middleton WD, Yamaguchi K. The outcome and repair integrity of completely arthroscopically repaired large and massive rotator cuff tears. *The Journal of Bone and Joint Surgery. American Volume*. 2004;**86-A**(2):219-224
- [55] Boileau P, Brassart N, Watkinson DJ, Carles M, Hatzidakis AM, Krishnan SG. Arthroscopic repair of full-thickness tears of the supraspinatus: Does the tendon really heal? *The Journal of Bone and Joint Surgery. American Volume*. 2005;**87**(6):1229-1240. DOI: 10.2106/JBJS.D.02035
- [56] Charousset C, Grimberg J, Duranthon LD. The time for functional recovery after arthroscopic rotator cuff repair: Correlation with tendon healing controlled by computed tomography arthrography. *Arthroscopy*. 2008;**24**:25-33
- [57] Tudisco C, Bisicchia S, Savarese E. Single-row vs double-row arthroscopic rotator cuff repair: Clinical and 3 Tesla MR arthrography results. *BMC Musculoskeletal Disorders*. 2013;**14**:43
- [58] Duquin TR, Buyea C, Bisson LJ. Which method of rotator cuff repair leads to the highest rate of structural healing? A systematic review. *The American Journal of Sports Medicine*. 2010;**38**(4):835-841. DOI: 10.1177/0363546509359679
- [59] Franceschi F, Papalia R, Franceschetti E, et al. Double-row repair lowers the re-tear risk after accelerated rehabilitation, double-row repair lowers the re-tear risk after accelerated rehabilitation. *American Journal of Sports Medicine*. 2016;**44**(4):948-956. DOI: 10.1177/0363546515623031
- [60] Millett PJ, Warth RJ, Dornan GJ. Clinical and structural outcomes after arthroscopic single-row versus double-row rotator cuff repair: A systematic review and meta-analysis of level I randomized clinical trials. *Journal of Shoulder and Elbow Surgery*. 2014;**23**:586-597
- [61] Hantes ME, Ono Y, Raoulis VA, Doxariotis N, Venouziou A, Zibis A, et al. Arthroscopic single-row versus double-row suture bridge technique for rotator cuff tears in patients younger than 55 years: A prospective comparative study. *The American Journal of Sports Medicine*. 2018;**46**(1):116-121. DOI: 10.1177/0363546517728718
- [62] Cho NS, Rhee YG. The factors affecting the clinical outcome and

integrity of arthroscopically repaired rotator cuff tears of the shoulder. *Clinics in Orthopedic Surgery*. 2009;**1**:96-104. DOI: 10.4055/cios.2009.1.2.96

[63] Abtahi AM, Granger EK, Tashjian RZ. Factors affecting healing after arthroscopic rotator cuff repair. *World Journal of Orthopedics*. 2015;**6**:211-220. DOI: 10.5312/wjo.v6.i2.211

[64] Chung SW, Oh JH, Gong HS, Kim JY, Kim SH. Factors affecting rotator cuff healing after arthroscopic repair: Osteoporosis as one of the independent risk factors. *The American Journal of Sports Medicine*. 2011;**39**:2099-2107. DOI: 10.1177/0363546511415659

[65] Bisson L, Zivaljevic N, Sanders S. A cost analysis of single-row versus double-row and suture bridge rotator cuff repair methods. *Knee Surgery Sports Traumatology, Arthroscopy*. 2015;**23**:487-493. DOI: 10.1007/s00167-012-2338-2

[66] Genuario JW, Donegan RP, Hamman D. The cost-effectiveness of single-row compared with double-row arthroscopic rotator cuff repair. *The Journal of Bone and Joint Surgery*. 2012;**94**(15):1369-1377. DOI: 10.2106/JBJS.J.01876

[67] Huang AL, Thavorn K, van Katwyk S, MacDonald P, Lapner P. Double-row arthroscopic rotator cuff repair is more cost-effective than single-row repair. *Journal of Bone and Joint Surgery*. 2017;**99**(20):1730-1736. DOI: 10.2106/JBJS.16. 01044

[68] Richards RR, An KN, Bigliani LU, et al. A standardized method for the assessment of shoulder function. *Journal of Shoulder and Elbow Surgery*. 1994;**3**:347-352

[69] Apreleva M, Ozbaydar M, Fitzgibbons PG, Warner JJ. Rotator cuff

tears: The effect of the reconstruction method on three-dimensional repair site area. *Arthroscopy*. 2002;**18**:519-526

[70] Ellman H, Hanker G, Bayer M. Repair of the rotator cuff: End-result study of factors influencing reconstruction. *The Journal of Bone and Joint Surgery. American Volume*. 1986;**68**:1136-1144

[71] Burks RT, Crim J, Brown N, Fink B, Greis PE. A prospective randomized clinical trial comparing arthroscopic single- and double-row rotator cuff repair: Magnetic resonance imaging and early clinical evaluation. *The American Journal of Sports Medicine*. 2009;**37**:674-682

[72] Aydin N, Kocaoglu B, Guven O. Single-row versus double-row arthroscopic rotator cuff repair in small- to medium-sized tears. *Journal of Shoulder and Elbow Surgery*. 2010;**19**(5):722-725. DOI: 10.1016/j.jse.2009.11.053

[73] Koh KH, Kang KC, Lim TK, Shon MS, Yoo JC. Prospective randomized clinical trial of single-versus double-row suture anchor repair in 2- to 4-cm rotator cuff tears: Clinical and magnetic resonance imaging results. *Arthroscopy*. 2011;**27**:453-462

[74] Lapner PLC, Sabri E, Rakhra K, et al. A multicenter randomized controlled trial comparing single-row with double-row fixation in arthroscopic rotator cuff repair. *The Journal of Bone and Joint Surgery. American Volume*. 2012;**94**(14): 1249-1257. DOI: 10.2106/JBJS.K.00999

[75] Nicholas SJ, Lee SJ, Mullaney MJ, et al. Functional outcomes after double-row versus single-row rotator cuff repair: A prospective randomized trial. *Orthopaedic Journal of Sports Medicine*. 2016;**4**(10). DOI: 10.1177/2325967116667398

- [76] Millett PJ, Warth RJ, Dornan GJ, Lee JT, Spiegl UJ. Clinical and structural outcomes after arthroscopic single-row versus double-row rotator cuff repair: A systematic review and meta-analysis of level I randomized clinical trials. *The Journal of Shoulder and Elbow Surgery*. 2014;**23**(4):586-597. DOI: 10.1016/j.jse.2013.10.006
- [77] Park JY, Lhee SH, Choi JH, Park HK, Yu JW, Seo JB. Comparison of the clinical outcomes of single- and double-row repairs in rotator cuff tears. *The American Journal of Sports Medicine*. 2008;**36**:1310-1316
- [78] Carbonel I, Martinez AA, Calvo A, Ripalda J, Herrera A. Single-row versus double-row arthroscopic repair in the treatment of rotator cuff tears: A prospective randomized clinical study. *International Orthopaedics*. 2012;**36**(9):1877-1883. DOI: 10.1007/s00264-012-1559-9
- [79] Ma H-L, Chiang E-R, H-TH W, et al. Clinical outcome and imaging of arthroscopic single-row and double-row rotator cuff repair: A prospective randomized trial. *Arthroscopy*. 2012;**28**(1):16-24. DOI: 10.1016/j.arthro.2011.07.003
- [80] Saridakis P, Jones G. Outcomes of single-row and double-row arthroscopic rotator cuff repair: A systematic review. *The Journal of Bone and Joint Surgery. American Volume*. 2010;**92**(3):732-742. DOI: 10.2106/JBJS.I.01295
- [81] Tashjian RZ, Granger EK, Chalmers PN. Healing rates and functional outcomes after triple-loaded single-row versus transosseous-equivalent double-row rotator cuff tendon repair. *Orthopaedic Journal of Sports Medicine*. 2018;**6**(11):2325967118805365
- [82] Franceschi F, Ruzzini L, Longo UG, Martina FM, Zobel BB, Maffulli N, et al. Equivalent clinical results of arthroscopic single-row and double-row suture anchor repair for rotator cuff tears: A randomized controlled trial. *American Journal of Sports Medicine*. 2007;**35**(8):1254-1260. DOI: 10.1177/0363546507302218
- [83] Barber FA. Triple-loaded single-row versus suture-bridge double-row rotator cuff tendon repair with platelet-rich plasma fibrin membrane: A randomized controlled trial. *Orthopaedic Journal of Sports Medicine*. 2016;**32**(5):753-761. DOI: 10.1016/j.arthro.2015.11.020
- [84] Sobhy MH, Khater AH, Hassan MR, El Shazly O. Do functional outcomes and cuff integrity correlate after single- versus double-row rotator cuff repair? A systematic review and meta-analysis study. *European Journal of Orthopaedic Surgery and Traumatology*. 2018;**28**(4):593-605. DOI: 10.1007/s00590-018-2145-7
- [85] Chen M, Xu W, Dong Q, Huang Q, Xie Z, Mao Y. Outcomes of single-row versus double-row arthroscopic rotator cuff repair: A systematic review and meta-analysis of current evidence. *Orthopedics*. 2013;**29**(8):1437-1449. DOI: 10.1016/j.arthro.2013.03.076
- [86] Yang J, Robbins M, Reilly J, Maerz T, Anderson K. The clinical effect of a rotator cuff retear: A meta-analysis of arthroscopic single-row and double-row repairs. *The American Journal of Sports Medicine*. 2017;**45**(3):733-741
- [87] Mazzocca AD, Millett PJ, Guanche CA, Santangelo SA, Arciero RA. Arthroscopic single-row versus double-row suture anchor rotator cuff repair. *The American Journal of Sports Medicine*. 2005;**33**(12):1861-1868
- [88] Kim DH, ElAttrache NS, Tibone JE, et al. Biomechanical comparison of a single-row versus double-row suture anchor technique for rotator cuff repair. *The American Journal of Sports Medicine*. 2006;**34**(3):407-414

- [89] Baums MH, Spahn G, Buchhorn GH, Schultz W, Hofmann L, Klinger H-M. Biomechanical and magnetic resonance imaging evaluation of a single- and double-row rotator cuff repair in an in vivo sheep model. *Arthroscopy*. 2012;**28**(6):769-777
- [90] Burkhart SS, Adams CR, Burkhart SS, Schoolfield JD. A biomechanical comparison of 2 techniques of footprint reconstruction for rotator cuff repair: The SwiveLock-FiberChain construct versus standard double-row repair. *Arthroscopy*. 2009;**25**(3):274-281
- [91] Ma CB, Comerford L, Wilson J, Puttlitz CM. Biomechanical evaluation of arthroscopic rotator cuff repairs: Double-row compared with single-row fixation. *The Journal of Bone and Joint Surgery. American Volume*. 2006;**88**(2):403
- [92] Christoforetti JJ, Krupp RJ, Singleton SB, Kissenberth MJ, Cook C, Hawkins RJ. Arthroscopic suture bridge transosseus equivalent fixation of rotator cuff tendon preserves intratendinous blood flow at the time of initial fixation. *Journal of Shoulder and Elbow Surgery*. 2012;**21**(4):523-530
- [93] Cho NS, Lee BG, Rhee YG. Arthroscopic rotator cuff repair using a suture bridge technique: Is the repair integrity actually maintained. *The American Journal of Sports Medicine*. 2011;**39**(10):2108-2116
- [94] Hayashida K, Tanaka M, Koizumi K, Kakiuchi M. Characteristic retear patterns assessed by magnetic resonance imaging after arthroscopic double-row rotator cuff repair. *Arthroscopy*. 2012;**28**(4):458-464
- [95] Cho NS, Yi JW, Lee BG, Rhee YG. Retear patterns after arthroscopic rotator cuff repair: Single-row versus suture bridge technique. *The American Journal of Sports Medicine*. 2010;**38**(4):664-671
- [96] Lee KW, Seo DW, Bae KW, Choy WS. Clinical and radiological evaluation after arthroscopic rotator cuff repair using suture bridge technique. *Clinics in Orthopedic Surgery*. 2013;**5**(4):306
- [97] Kim KC, Shin HD, Cha SM, Park JY. Comparisons of retear patterns for 3 arthroscopic rotator cuff repair methods. *The American Journal of Sports Medicine*. 2014;**42**(3):558-565