

# We are IntechOpen, the world's leading publisher of Open Access books Built by scientists, for scientists

6,900

Open access books available

186,000

International authors and editors

200M

Downloads

Our authors are among the

154

Countries delivered to

TOP 1%

most cited scientists

12.2%

Contributors from top 500 universities



WEB OF SCIENCE™

Selection of our books indexed in the Book Citation Index  
in Web of Science™ Core Collection (BKCI)

Interested in publishing with us?  
Contact [book.department@intechopen.com](mailto:book.department@intechopen.com)

Numbers displayed above are based on latest data collected.  
For more information visit [www.intechopen.com](http://www.intechopen.com)



# Peripheral Nerve Imaging: Focus on Sonography

*Mohamed A. Bedewi, Daniele Coraci and Sherine Swify*

## Abstract

The diagnosis of different peripheral nerve disorders is basically established by electrodiagnostic tests; the assessment of the function of peripheral nerve disorders is estimated by nerve conduction tests (NCT) and electromyography (EMG). The need for more information about nerve morphology mandated the usage of more diagnostic tools. This role is now achieved by means of peripheral nerve imaging consisting mainly of magnetic resonance imaging (MRI) and ultrasonography. In this chapter we will clarify the role of imaging in the diagnosis of peripheral nerve disorders, concentrating more on the role of modern high-resolution ultrasound, considering its advantages like cheap price, dynamic ability, and possibility of comparison with the contralateral side at the same setting.

**Keywords:** peripheral, ultrasound, imaging, peripheral nerves

## 1. Introduction

Diseases of the peripheral nerves are common in the setting of clinical practice. The traditional way of the diagnosis of peripheral nerve disorders is made by neurophysiology and clinical assessment. These tools give information about the functional status of the involved nerve, the presence of nerve damage, and the degree of demyelination [1]; however, the need for more information about nerve morphology mandated the usage of more diagnostic tools. This role is now enhanced by means of peripheral nerve imaging consisting mainly of magnetic resonance imaging (MRI) and ultrasonography, with special ability to assess small-sized and difficult nerves [2].

## 2. Magnetic resonance imaging

Magnetic resonance imaging is a noninvasive imaging technique that has the ability to differentiate pathological peripheral nerves from healthy ones. MRI is also useful in the demonstration of the topographic anatomy of the peripheral nerves. MRI uses a strong magnetic field to create a net magnetization in the involved tissues, then disruption of this magnetization with pulse, and change of direction resulting in T1- and T2-weighted images. Basic MRI study of the peripheral nerves uses T2-weighted images (with fat suppression) detecting the site of injury as sharp hyperintense (as a result of local edema), in comparison to the nearby healthy nerves which appear as isointense. As nerve regeneration resumes, the degree of hyperintensity will gradually return to isointensity. Fat suppression is used for

better visualization. Typically a 1.5 Tesla machine is used, with better results if a stronger magnet is utilized (3 Tesla). As a result of research, a newer MRI technique was developed, which is diffuse tensor imaging (DTI), tracking the diffusion of water molecules, depending on the fact that there is a difference in diffusion pattern between the healthy and injured nerves. The healthy nerves appear as linear structures which maintain diffusion in an anisotropic pattern restricting the movement linearly. If there is structural damage, the water molecules diffuse in an orthogonal pattern [3–5]. Among the disadvantages of MRI are the high-cost and long examination time. Also MRI is not tolerated by claustrophobic patients, and the examination is not suitable for patients with pacemakers and many types of surgical implants.

### **3. Ultrasound**

The first report of nerve ultrasound was by Bruno Fornage in the year 1988, who used a linear transducer with a 5–7.5 MHz frequency. Ultrasound is a cheap modality, which allows examination of the whole nerve at the same setting, plus the contralateral side [2]. This modality is also dynamic, with excellent spatial resolution and nonionizing radiation and good patient compliance. Among the disadvantages of ultrasound is that the procedure is operator dependent, limited ability to visualize deep nerves and long learning curve [3]. Initially ultrasound was mainly used to assess the cross-sectional area (CSA). Among the additional parameters assessed by peripheral nerve ultrasound is the so called “nerve density,” representing hypoechoic/hyperechoic ratio [6]. The use extended field of view is sometimes needed.

### **4. Ultrasound exam and findings**

In order to perform an accurate examination, a good knowledge of the anatomical landmark of each nerve is essential. A linear high-frequency transducer 5–18 MHz (**Figure 1**) is used for ultrasound examination. Another transducer (Hockey stick) is occasionally referred to (**Figure 2**). Peripheral nerves should be imaged in both short and long axes; they appear in short axis as hypoechoic structures with peculiar fascicular pattern “honeycomb appearance.” We recommend beginning the examination in short-axis scan, as differentiation of the nerves is difficult from the surrounding longitudinally oriented structures like tendons.

Topographic anatomy is always helpful in identifying specific nerves. The probe position must be placed perpendicular to scanned nerve in order to avoid anisotropy phenomenon. The simplest measurement of nerve caliber is made by estimating the cross-sectional area (CSA). Two known methods are used for this purpose, the older of which is the ellipse technique, and the newer and most recommended one is the tracer method, by which the nerve is measured inside the hyperechoic epineurium. Each nerve has a reference value, which when exceeded is a sign of disease. Loss of the fascicular pattern could be a sign of disease, as a result of edema/congestion. The cause is variable, the most important of which is compression neuropathy. Other types of neuropathies also exist like immune-mediated neuropathies. The role of ultrasound in traumatic injuries is quite important. The most important issue in trauma is to make sure of nerve continuity, and if there is an injury, it is complete or partial [7–12]. New techniques like three-dimensional imaging and compound imaging were developed during the last 10 years. Measurement of stiffness of the nerve is established by elastography [6].



**Figure 1.**  
*Linear transducer.*



**Figure 2.**  
*Hockey stick transducer.*

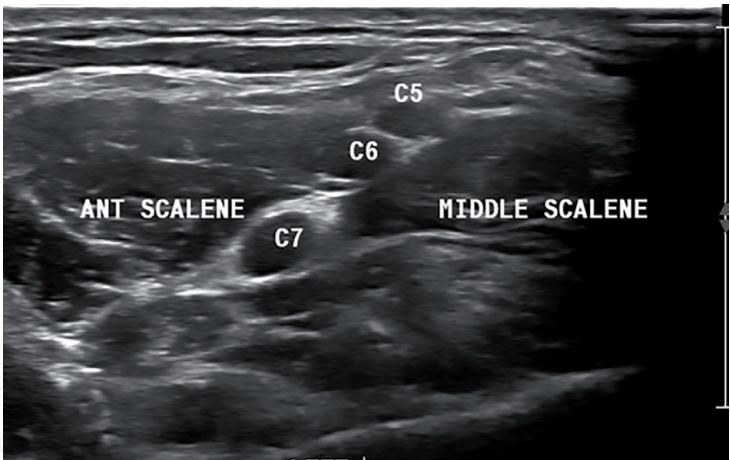
## 5. Brachial plexus

The brachial plexus consists of the network of nerves providing the sensorimotor supply of the upper limb (C5-T1) (**Figure 3**) [6]. Brachial plexus injuries are common in different types of trauma, including car accidents and falls, which could lead to severe impairment. Some lesions are minor, and patients could recover without surgery. The presence of a good diagnostic tool is essential in this manner [13]. Brachial plexus lesions are common, whether traumatic or nontraumatic. Traumatic lesions could also be open or closed.

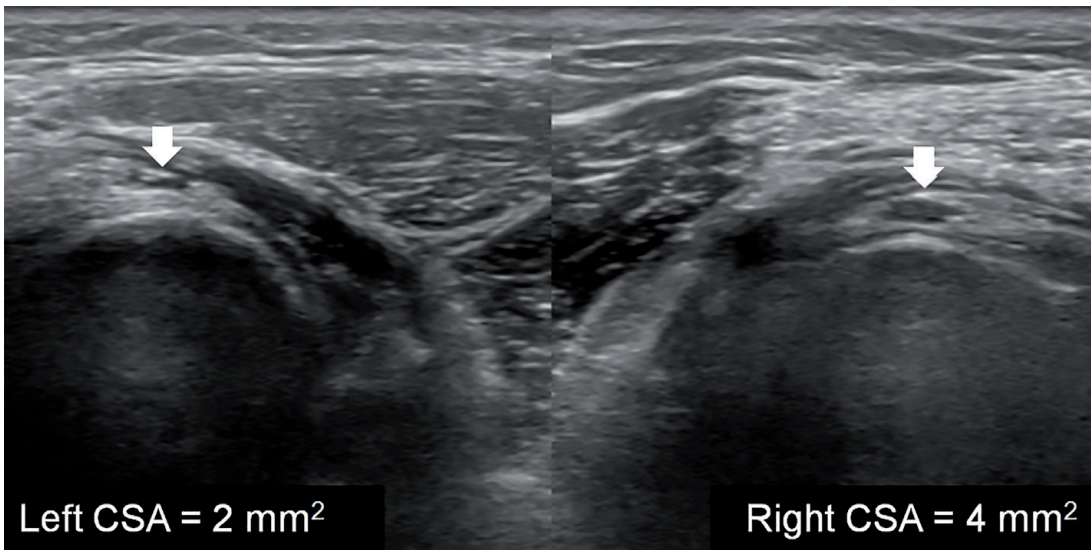
## 6. Upper limb nerves

The radial nerve arises from the C5–C8 nerve roots. This nerve has a peculiar spiral course around the humerus, maintaining direct contact with the humerus, making the nerve highly sustainable to trauma (**Figure 4**). At the distal upper arm, the radial nerve divides into superficial (mainly sensory) and deep (mainly motor) branches (**Figure 5**). The ulnar nerve (**Figure 6**) arises from C8-T1 nerve roots.

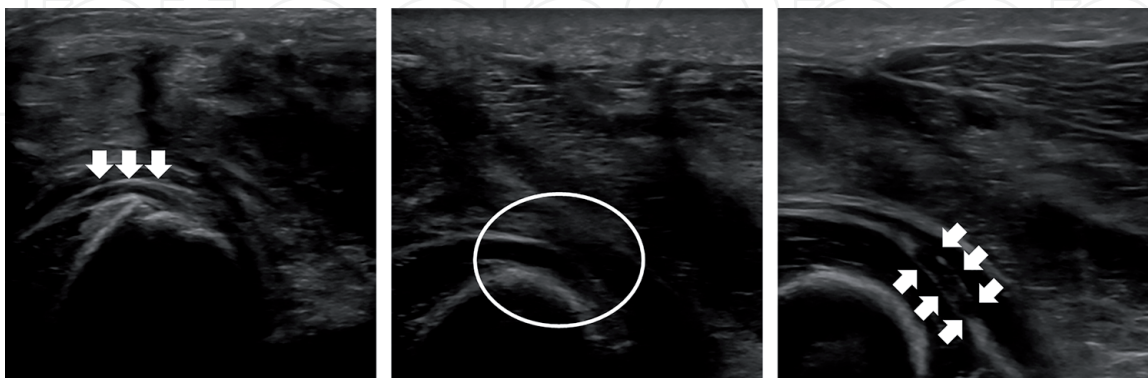




**Figure 3.**  
*Short-axis scan of the C5, C6, and C7 nerve roots, in the interscalene groove, between the middle scalene and anterior scalene muscles. s, scalene muscle.*

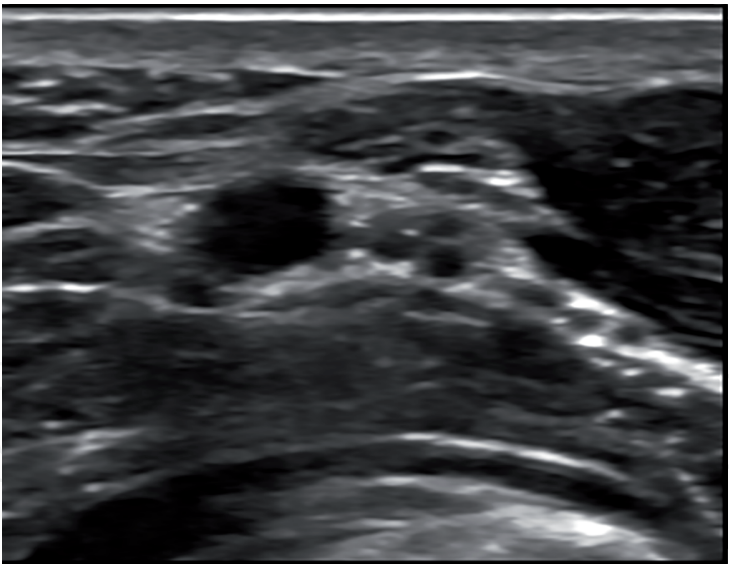


**Figure 4.**  
*A case of upper limb trauma with humeral bone fracture and following deficit in finger extension. The posterior interosseous nerve is larger than the contralateral side.*

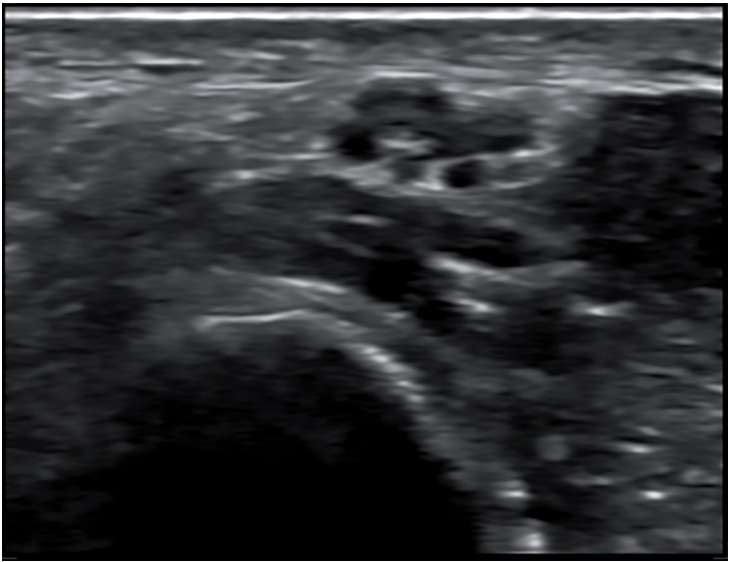


**Figure 5.**  
*A case of blade trauma in the forearm. The patient presents with plegia of the extensor digitorum communis muscle. From right to left, the images show the posterior interosseous nerve course from proximal to distal. In the image at the center, the nerve is not visible (ellipse), while proximally (right) and distally (left), the nerve is depictable (arrows).*

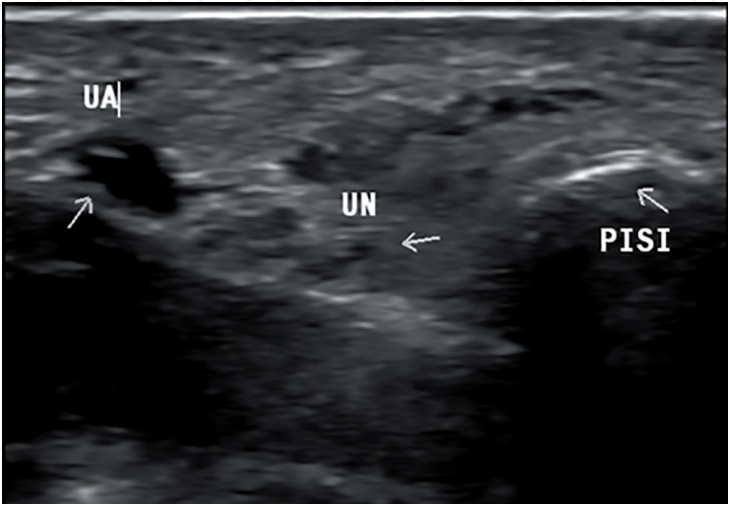
Two common levels of injury/entrapment to the ulnar nerve are the cubital tunnel (Figure 7) at the level of the medial epicondyle of the elbow joint (which represents



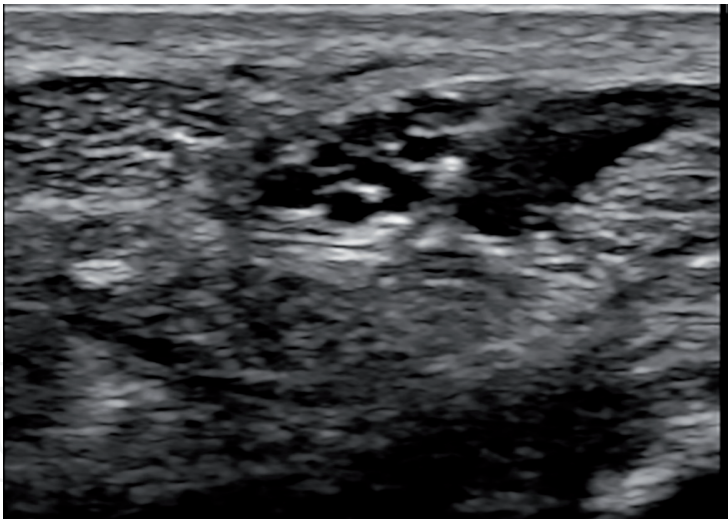
**Figure 6.**  
*Short-axis scan of the ulnar nerve at the forearm.*



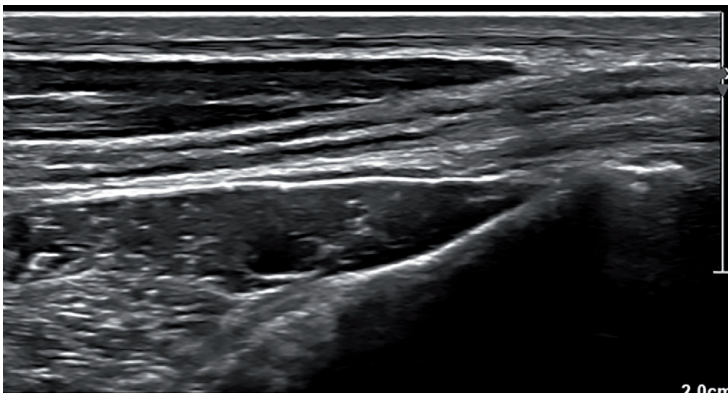
**Figure 7.**  
*Short-axis scan of the ulnar nerve at the cubital tunnel.*



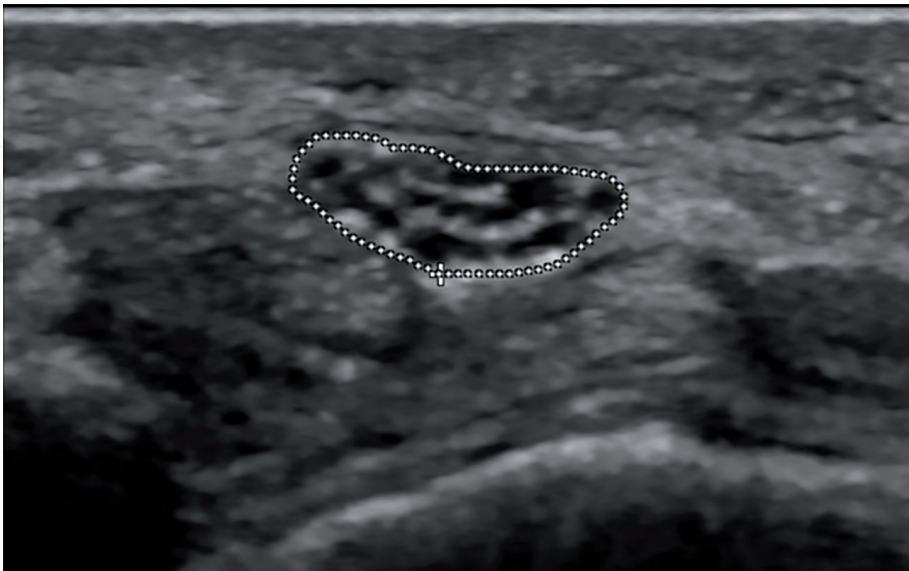**Figure 8.**  
*Short-axis scan of the ulnar nerve (UN) at Guyon's canal. PISI. Pisiform bone; UA, ulnar artery.*



**Figure 9.**  
*Short-axis scan of the median nerve at the carpal tunnel.*



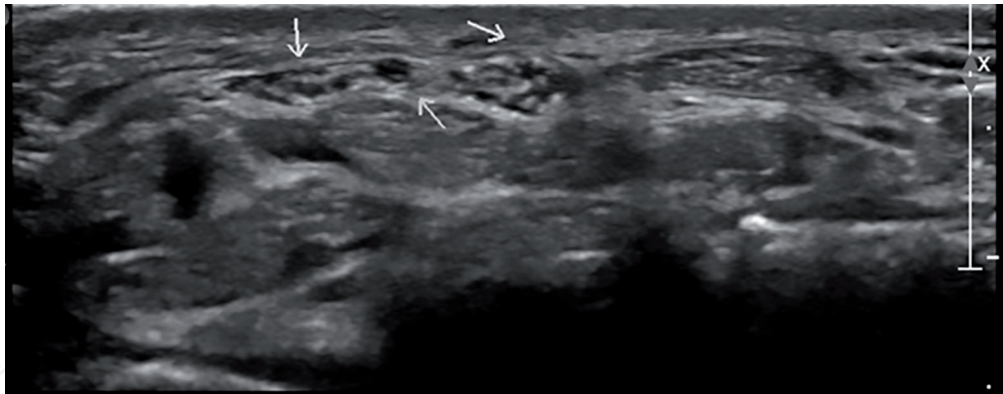
**Figure 10.**  
*Long-axis scan of the median nerve at the carpal tunnel.*



**Figure 11.**  
*Short-axis scan of the median nerve at the carpal tunnel with increased CSA.*

one of the common compressive neuropathies) and at Guyon’s canal at the level of wrist joint (**Figure 8**). The median nerve is the most important nerve of the upper limb. It arises from the C6-T1 nerve roots. The median nerve is also the easiest nerve





**Figure 12.**  
*Bifid median nerve at the level of the carpal tunnel.*

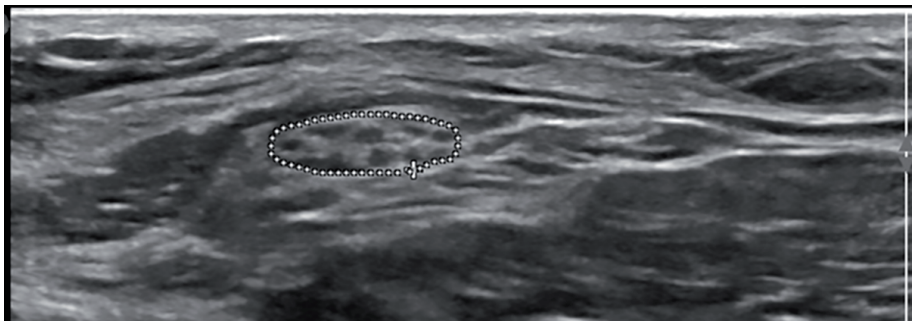
scanned in the body. The commonest entrapment syndrome is related to this nerve when it entraps in the carpal tunnel level, the so called “carpal tunnel syndrome.” Good knowledge about congenital anatomical variation is essential (**Figures 9–12**) [14, 15].

**7. Lower limb nerves**

The sensorimotor supply of the lower limb is derived from the lumbosacral plexus. The most important nerves of the lower limb are the sciatic nerve, the femoral nerve, the common fibular nerve, and the tibial nerve. Two other nerves could be added but are less important which are the saphenous nerve and the sural nerve. The femoral nerve could be injured during surgical/interventional procedures, and it gives branch to the saphenous nerve which also could be injured during varicose vein stripping operations due its close proximity to the long saphenous vein. The sciatic nerve is the largest nerve in the human. This nerve is practically a combination of the two nerves, the tibial and the fibular nerve with one common sheath. Actually the level of true division of the sciatic nerve into these nerves is highly variable in the human population (**Figures 13–15**) [14, 16].

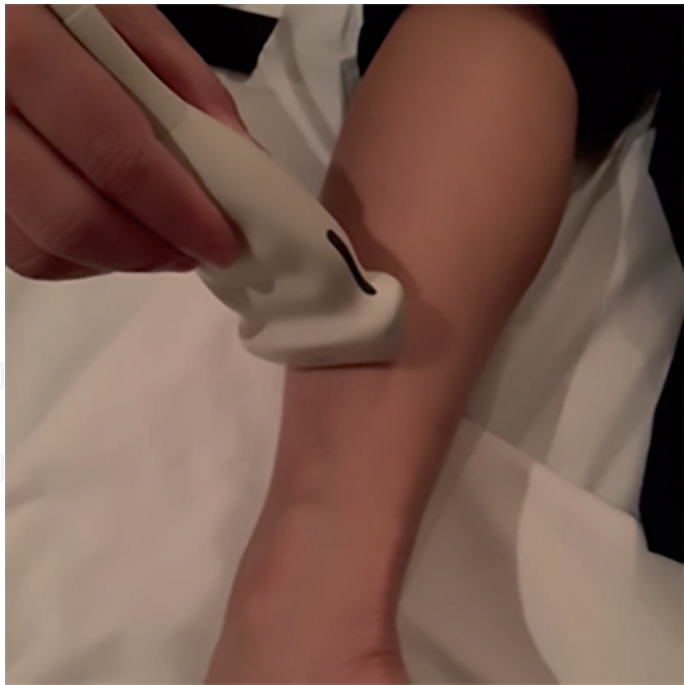**8. Traumatic peripheral nerve injuries**

Trauma to the peripheral nerves could be direct or indirect; one of the following consequences could happen. Structural and morphological changes could occur, resulting in change in the echogenicity or the shape of the nerve. Most of the studies take Sunderland classification as a reference to in dealing with the degree of

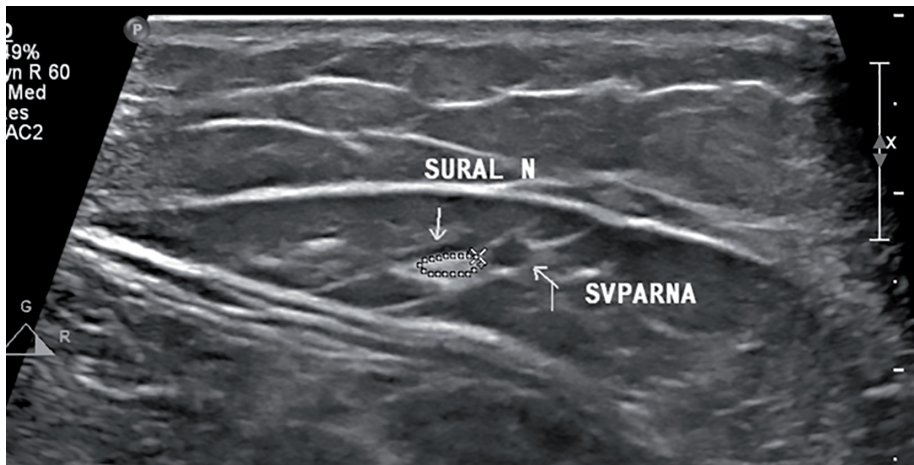


**Figure 13.**  
*Short-axis scan of the common fibular nerve.*





**Figure 14.**  
*Photo of scan of the sural nerve at the lateral aspect of leg.*



**Figure 15.**  
*Short-axis scan of the sural nerve at the lateral aspect of the leg.*

post-traumatic peripheral nerve lesions. Penetrating injuries could lead to partial or complete cut of the nerve (transection), with associated laceration. One of the most important changes is nerve contusion and/or compression. Repetitive insults could lead to stretch along the course of the nerve. Ultrasound does not clearly demonstrate endoneurium but clearly visualize perineurium and epineurium. Also ultrasound could well demonstrate fascicular anatomy but not myelin and axonal anatomy [17]. In conclusion, the main role of ultrasound in the assessment of traumatic nerve lesions is to assess the continuity of the nerve and presence of axonotmesis or neurotmesis and also assessment of other sites of injury and, in some cases, the cause of injury.

### Abbreviations

|     |                       |
|-----|-----------------------|
| NCT | nerve conduction test |
| EMG | electromyography      |

|     |                            |
|-----|----------------------------|
| MRI | magnetic resonance imaging |
| DTI | diffuse tensor imaging     |
| CSA | cross-sectional area       |

### Author details

Mohamed A. Bedewi<sup>1\*</sup>, Daniele Coraci<sup>2</sup> and Sherine Swify<sup>3</sup>

1 Department of Internal Medicine, Prince Sattam Bin Abdulaziz University,  
College of Medicine, Alkharj, Kingdom of Saudi Arabia

2 Fondazione Policlinico A. Gemelli IRCCS, Rome, Italy

3 Ministry of Health and Population, Alexandria, Egypt

\*Address all correspondence to: [mohamedbedewi@yahoo.com](mailto:mohamedbedewi@yahoo.com)

### IntechOpen

© 2019 The Author(s). Licensee IntechOpen. This chapter is distributed under the terms of the Creative Commons Attribution License (<http://creativecommons.org/licenses/by/3.0>), which permits unrestricted use, distribution, and reproduction in any medium, provided the original work is properly cited. 

## References

- [1] Walker FO, Cartwright MS, Alter KE, Visser LH, Hobson-Webb LD, Padua L, et al. Indications for neuromuscular ultrasound: Expert opinion and review of the literature. *Clinical Neurophysiology*. December 2018;**129**(12):2658-2679
- [2] Bedewi MA, Nissman D, Aldossary NM, Maetani TH, El Sharkawy MS, Koura H. Shear wave elastography of the brachial plexus roots at the interscalene groove. *Neurological Research*. September 2018;**40**(9):805-810
- [3] Rangavajla G, Mokarram N, Masoodzadehgan N, Pai SB, Bellamkonda RV. Noninvasive imaging of peripheral nerves. *Cells, Tissues, Organs*. 2014;**200**(1):69-77
- [4] Tagliafico A, Bignotti B, Tagliafico G, Martinoli C. Peripheral nerve MRI: Precision and reproducibility of T2\*-derived measurements at 3.0-T: A feasibility study. *Skeletal Radiology*. May 2015;**44**(5):679-686
- [5] Aggarwal A, Jana M, Srivastava DN, Sharma R, Gamanagatti S, Kumar A, et al. Magnetic resonance neurography and ultrasonogram findings in upper limb peripheral neuropathies. *Neurology India*. January-February 2019;**67**(Supplement):S125-S134
- [6] Tagliafico AS. Peripheral nerve imaging: Not only cross-sectional area. *World Journal of Radiology*. August 2016;**8**(8):726-728
- [7] Visalli C, Cavallaro M, Concerto A, La Torre D, Di Salvo R, Mazziotti S, et al. Ultrasonography of traumatic injuries to limb peripheral nerves: Technical aspects and spectrum of features. *Japanese Journal of Radiology*. October 2018;**36**(10):592-602. [Epub 2018 Aug 13, Review]
- [8] Padua L, Di Pasquale A, Liotta G, Granata G, Pazzaglia C, Erra C, et al. Ultrasound as a useful tool in the diagnosis and management of traumatic nerve lesions. *Clinical Neurophysiology*. June 2013;**124**(6):1237-1243
- [9] Zeidenberg J, Burks SS, Jose J, Subhawong TK, Levi AD. The utility of ultrasound in the assessment of traumatic peripheral nerve lesions: Report of 4 cases. *Neurosurgical Focus*. September 2015;**39**(3):E3
- [10] Cartwright MS, Chloros GD, Walker FO, Wiesler ER, Campbell WW. Diagnostic ultrasound for nerve transection. *Muscle & Nerve*. June 2007;**35**(6):796-799
- [11] Renna R, Coraci D, De Franco P, Erra C, Ceruso M, Padua L. Ultrasound study is useful to discriminate between axonotmesis and neurotmesis also in very small nerves: A case of sensory digital ulnar branch study. *Medical Ultrasonography*. December 2012;**14**(4):352-354 (Erratum in: *Med Ultrason*. 2013 Mar;**15**(1):78. Rosaria, Renna [corrected to Renna, Rosaria]; Daniele, Coraci [corrected to Coraci, Daniele])
- [12] Bianchi ML, Padua L, Granata G, Erra C. Double site nerve lesion: Ultrasound diagnosed musculocutaneous involvement in traumatic brachial plexus injury. *Clinical Neurophysiology*. March 2013;**124**(3):629-630
- [13] Zheng M, Zhu Y, Zhou X, Chen S, Cong R, Chen D. Diagnosis of closed injury and neoplasm of the brachial plexus by ultrasonography. *Journal of Clinical Ultrasound*. September 2014;**42**(7):417-422
- [14] Kerasnoudis A, Pitarokoili K, Behrendt V, et al. Cross sectional area reference values for sonography

of peripheral nerves and brachial plexus. *Clinical Neurophysiology*. 2013;**124**:1881-1888

[15] Bedewi MA, Abodonya A, Kotb M, Mahmoud G, Kamal S, Alqabbani A, et al. Estimation of ultrasound reference values for the upper limb peripheral nerves in adults: A cross-sectional study. *Medicine (Baltimore)*. December 2017;**96**(50):e9306

[16] Bedewi MA, Abodonya A, Kotb M, Kamal S, Mahmoud G, Aldossari K, et al. Estimation of ultrasound reference values for the lower limb peripheral nerves in adults: A cross-sectional study. *Medicine (Baltimore)*. March 2018;**97**(12):e017

[17] Lauretti L, D'Alessandris QG, Granata G, Padua L, Roselli R, Di Bonaventura R, Fernandez E. Ultrasound evaluation in traumatic peripheral nerve lesions: From diagnosis to surgical planning and follow-up *Acta Neurochirurgica (Wien)*. November 2015;**157**(11):1947-1951. discussion 1951