

We are IntechOpen, the world's leading publisher of Open Access books Built by scientists, for scientists

6,900

Open access books available

186,000

International authors and editors

200M

Downloads

Our authors are among the

154

Countries delivered to

TOP 1%

most cited scientists

12.2%

Contributors from top 500 universities



WEB OF SCIENCE™

Selection of our books indexed in the Book Citation Index
in Web of Science™ Core Collection (BKCI)

Interested in publishing with us?
Contact book.department@intechopen.com

Numbers displayed above are based on latest data collected.
For more information visit www.intechopen.com



“Stealth Cranioplasty” for Adult Chiari Malformation Type 1: A Philosophical Journey of Innovation, Adaptation, and Evolution

Asifur Rahman

Abstract

Chiari malformation (CM) and its management are long debated enigmas for neurosurgeons. Many surgical procedures have been innovated and are in practice for this perplexing and daunting entity to give the patients a satisfactory remedy. But, a unanimously accepted surgical procedure is still lacking to achieve gratifying result. We tried to develop a novel technique, which we call the “stealth cranioplasty (SCP),” to help the adult Chiari malformation type 1 (CM1) patients. In this chapter, the philosophy behind developing the technique of “stealth cranioplasty” by reconstruction of posterior fossa (PF) by cranioplasty with pre-shaped titanium mesh is described. Different stages, difficulties, and modifications of the journey toward the present day status are also elaborated graphically.

Keywords: Chiari malformation, Chiari malformation type 1, arachnoid-preserving duraplasty, stealth cranioplasty, posterior fossa

1. Introduction

The baffling malady of Chiari malformation (CM) is still an enigma for neurosurgeons for its poorly understood pathophysiology, uncertain natural history, and dilemma concerning management options since Hans Chiari described it first in 1891 and detailed with refinements in 1896. Even being a diverse disease in presentation, Chiari malformation is being detected more often than before because of the advent of magnetic resonance imaging (MRI) and its better delineation of soft tissue especially in the posterior fossa (PF) and the craniovertebral junction (CVJ). Owing to its diverse presentations, varied thoughts on pathophysiology, and numerous philosophies in management, a myriad of surgical options are existent for CM. Better understanding of pathophysiology with technical advancements and better availability of imaging facilities have made CM more treatable with encouraging outcomes, and CM no more remains an unfamiliar entity. In this chapter we will present a novel technique that we developed over years to treat only the adult Chiari malformation type 1 (CM1) patients. We will also discuss about the philosophy behind developing this as well as the evolution process of the procedure

focusing on the problems that we faced and how we modified our procedure to solve those and finally reached here. With our procedure we tried to address the two most common pathophysiological aspects of CM1 rationally that play the major roles: the shallow posterior fossa and the difference in pressure gradient of cerebrospinal fluid (CSF) between cranial and spinal compartments. With our procedure we also tried to prevent recurrence and avoid complications in a cost-effective way.

2. Pathophysiology

Any conclusive pathology in development of Chiari malformations is still lacking, and heterogeneity of theories regarding pathogenesis of CM continues to deepen the controversy. The most popular and accepted theory regarding Chiari 1 is that it is a developmental anomaly that causes tonsillar herniation from a discrepancy between the content, the hindbrain and the container, and the posterior fossa [1, 2]. Arguments can be made that this malady entirely is not a malformation. The shallow posterior fossa is an anomaly or deviation from the normal arrangement in its structure, while the herniation of the part of the normal hindbrain is an alteration that the nature makes in an attempt to maintain the homeostasis in the posterior fossa and the CVJ [3]. The origin of shallow PF may have several pathological bases, and our technique is primarily based on the theory of shallow posterior fossa as well as other pathologies that play important role in development of CM.

2.1 Evolution of human skull and brain and CM1

Studies on human evolution have revealed significant changes in the braincase; the skull, especially in the posterior skull base region; and the brain itself. Analysis on evolution demonstrated the gradual increase in cranial capacity from about 800 cm³ in *Homo erectus* to 1000–1200 cm³ in the species of the Middle Pleistocene and further to 1500 cm³ in Neanderthals and modern humans [4–6]. But in the process of evolution from *Homo neanderthalensis* to *Homo sapiens*, both the cranial capacity and basal angle had decreased considerably, while the brain size increased significantly [5]. The posterior cranial fossa of *H. sapiens* has diminished in size, occupying around 26.8% of the available intracranial space, while in CM1 this space is further reduced to around 21.6%, resulting from different factors [7]. Modern human beings may carry some primitive genes of ancient hominins in their genomic code influenced by gene flow interchange, interbreeding, and anatomic reshaping of the skull base during evolution at random in some individuals of CM1 [5]. So, the shallow and small posterior fossa in CM1 may bear an evolutionary imprint.

2.2 Genetics of CM1

The majority of cases of CM1 are considered as sporadic. However, there are clues that suggest a genetic component playing role in development of Chiari in at least a subset of patients. Evidence of manifestation of CM1 in twins, in siblings, in first-degree relatives, in familial clustering among generations, or in conjunction with some known genetic syndromes supports the genetic origin vigorously. From these, it can be presumed that genetic factors, along with other epigenetic and/or environmental factors, prompt development of a small posterior cranial fossa. Familial aggregation is a representative of traits that hints to an underlying genetic basis [8–19]. Studies of families having Chiari among the members suggest posterior fossa volume (PFV) to be highly heritable, and genetic analysis reveals

indicative linkage to regions at chromosomes 1q, 8q, 9q, 12p, 12q, 15q, and 22q. Moreover, disturbance in formation of the basichondrocranium from hyperossification or hypo-ossification has the possibility of having morphometric changes in the posterior cranial fossa in patients with Chiari resulting from the misregulation in genes [13, 20–24].

2.3 Embryological basis of CM1

In the development of a shallow and small posterior fossa, embryological derangement is pivotal. Occipitocervical transition develops during the fourth week of embryological life from bilateral four occipital somites (OS1–OS4) and seven cervical somites (CS1–CS7) that form the axial skeleton [25–27]. Different parts of the occipital bone originate from different somites and grow at different paces. This discrepancy in the rate of growth of different parts of the occipital bone during development leads to the typical developmental disorder of CM1 [28]. The supratentorial part of the squamous occipital derives from membranous origin, while the infratentorial part comes from cartilaginous origin. The shallowness of the posterior fossa may result from an abnormality of the lower part of the occipital squamous bone derived from the cartilaginous origin. The chondrified supraocciput, which is vulnerable to regression, theoretically offers an embryological basis for the shortening of the supraocciput in CM [29].

2.4 Posterior fossa volume and development of CM1

From the thoughtful observations and meticulous analysis, along with his theory of chronically raised intracranial pressure (ICP), Chiari furthermore believed that inadequate bone growth and insufficient enlargement of skull triggered raised ICP which plays a vital role in this condition to force down the hindbrain [30–33]. Cleland in 1883 and Mennicke in 1891 also advocated that the pathology lies in the defective bone around the foramen magnum while describing hindbrain herniation [34, 35]. Many studies in the modern era, with the help of modern technological advancements, have also strongly proven that the posterior fossa is indeed shallow or smaller than the normal hindbrain in Chiari patients. The shallowness of the posterior fossa has been proven in Chiari patients in comparison to controls using X-rays [36, 37]. Ratio of the posterior fossa with supratentorial volumes on MR images between patients with Chiari 1 malformation and controls also demonstrated smaller ratio in Chiari patients who were symptomatic, and most of them improved following posterior fossa decompression (PFD) [38].

Some studies found PFV to be smaller in pediatric CM1 patients also, which matches the studies in adults and aids the theory relating to the pathophysiological mechanism of CM1 resulting from small posterior fossa [7]. Interestingly, in cases of acquired Chiari malformation (ACM), surgical management of only the primary lesion has shown to improve ACM which also supports the discrepancy between the volume of the posterior fossa and its contents [39]. From different studies, it is now proposed that development of Chiari results from multifactorial etiologies, where small PF remains to be the most crucial one [40–52]. The theory of small PF is further strengthened by demonstration of CM by creating smaller basichondrocrania and posterior cranial fossa than controls by producing a state of hypervitaminosis A in experimental models of rodents [53]. Moreover, CM1 has been described in several metabolic disorders also like Paget's disease [54], rickets [55, 56], craniometaphyseal dysplasia [57], acromegaly [58], and growth hormone deficiency [59], where the PFV is rendered smaller than usual.

2.5 Tonsillar descent in CM1

By definition, radiologically, tonsillar herniation more than 5 mm below the foramen magnum is considered to be CM1. Incidental findings of patients having more than 5 mm descent of tonsil without any recognizable symptoms of Chiari are not uncommon. On the other hand, there are patients who have less than 5 mm descent of the tonsils and yet show pronounced symptoms of CM1. Though the cerebellar tonsillar herniation is the most commonly used radiological measurement to determine the diagnosis of CM1, clinical presentations often pose dilemma in decision making. So, this radiological measurement of degree of tonsillar descent alone may not be reliable enough to ascertain the presence and severity of CM1 and should always be tallied with the clinicopathological setting [1, 60–70].

2.6 Cranial and spinal cerebrospinal fluid pressure gradient difference in pathogenesis of CM1

Chiari, while describing the hindbrain herniation first, hypothesized the changes to be related to congenital hydrocephalus [30]. Studies later revealed that the malformation is not always accompanied by hydrocephalus; rather the fetal cerebellar herniation is due to the lowered intraspinal pressure owing to leakage of CSF at the myelocoele, especially in cases of Chiari type 2 [71–74].

In fact, it is recommended that the pressure difference between the cranial and spinal compartments is the force responsible for the herniation. It is very much feasible as the brain tissue is a thick jelly like substance and acts like a viscoelastic medium to be subjected to deformation in response to stress [75]. Thus, any imbalance between the cranial and spinal CSF compartments leading to reduced CSF pressure in the spinal compartment may result in spontaneous occurrence of a CM1 which is also evidenced by tonsillar herniation following spinal shunting procedure. Conversion of a lumbar shunt to a ventricular shunt has shown to eliminate the downward craniospinal pressure gradient, leading to the reversal of the tonsillar descent or at least arresting further migration amplifying the aptness of this theory [74, 76–81]. This theory of disequilibrium of CSF dynamics might explain the reason of the tonsils to go back to their normal position following PFD which relieves the discrepancy of the pressure gradient between the cranial and spinal compartments, and our procedure is partly based on this theory also.

3. Commonly practiced surgical procedures

First attempted surgery for CM was in 1930 by a Dutchman Cornelis Joachimus Van Houweninge Graftdijk, on a patient with myelomeningocele and ventriculogram-proven hindbrain herniation. He tried surgically to relieve CSF obstruction at the CVJ by the redundant cerebellar tissue. His thought was to try to restore better flow of CSF by widening the space through which the brain had herniated [82]. For many years after the first attempt by Van Houweninge Graftdijk, surgery of CM carried grave prognosis. Now, with the better understanding of the pathology and improvements in technology, most patients with CM1 can be benefited by different surgical procedures [83].

Owing to the nature of this disorder and its diversity in clinical presentation and image findings, it is difficult to come to a consensus on which is the best way to manage this. Depending on presentation in milder forms of symptoms, some authors have advocated conservative management. However, according to most

experts, surgical intervention remains the gold standard, both in reduction of tonsillar herniation, resolution of syrinx, and in overall outcome, in most of the cases [61, 66, 67, 84, 85]. The common procedure in almost all surgical approaches comprise of a suboccipital craniectomy with removal of posterior arch of C1 with the aim of posterior fossa decompression. Nevertheless, there are controversies concerning the extent of bone removal and additional measures taken along with it [86, 87]. Management of the dura includes leaving the dura intact with removal of the constricting band only [88], dural scoring [89, 90], resecting the outer layer of the dura [67, 91–94], opening the dura and leaving it open [95–98], and performing a duraplasty [38, 43, 67, 88, 91, 94, 99–104]. The arachnoid manipulation similarly varies from leaving it intact [88, 91, 105] to opening and resecting it [96, 99–103, 106, 107]. The cerebellar tonsils have been addressed in various ways also like not touching them [108], dissecting to separate them [99, 109], shrinking by bipolar coagulation [43, 67, 100, 102, 103, 110, 111], and subpial resection [38, 43, 67, 106, 107, 110, 112]. Recently, minimal invasive endoscopy-assisted decompression at the foramen magnum for CM has also been reported [113, 114].

4. Our technique

Many authors have postulated many factors to be responsible for development of Chiari malformations, and it seems that there actually are various pathologies in play. As the pathophysiology is multifactorial, it is almost impossible to address all the problems at a time with a single procedure. We tried to address the two basic pathologies that we feel to be of paramount importance in the pathophysiological process in the development of Chiari malformation. Accordingly we developed our technique only for the patients of CM1, which are young adults and do not have any other problem related to or complicating the condition like HCP, basilar invagination, and platybasia. Our patient subset also had syringes of different diameters and extensions. But we feel that it was not a big factor on influencing the result of the surgical technique, as the pathologies of both CM and SM seem to be the same. It was of our interest to see if the procedure addressing the Chiari only can solve syrinx as well, and that would provide some explanation that CM and SM share at least some common etiological factors and pathologies, which can be dealt with a single procedure.

Whatever theory regarding the pathophysiology is apt, with time and experience, centering on the two basic pathologies of shallow PF and imbalance of CSF dynamics around the CVJ, now the goal of our procedure is a persistent voluminous PF that would reestablish the CSF flow dynamics and would prevent recurrence and complications cost-effectively.

4.1 Patient positioning

We place the patient prone, in a modified concord position, under general anesthesia (**Figure 1A**). Special attention is given to keep the head in neutral position, and that is not flexed in any way. This gives two benefits. When the head is neutral, it helps the already jeopardized medulla from kinking from flexion as well as keeps it free from further compression by the herniated tonsils, which is already there. During reconstruction of the posterior fossa, neutral position gives better idea about the anatomy of the structures around the foramen magnum. This also gives the additional advantage of facilitation of venous return, by ensuring the jugular veins to be free of compression which helps in avoiding unnecessary oozing. Care of the airway, pressure points, and the vital monitoring are as usual.

4.2 Skin incision, harvesting graft, and exposure of bone

A midline skin incision is made from just above the external occipital protuberance down to a little below the prominence of the C2 vertebra. After opening the skin, a strip of the investing layer of the deep cervical fascia, measuring about 2 × 5 cm, is harvested for the duraplasty (**Figure 1B**). This strip is an advantageous graft material for duraplasty as it is autologous and hence can avoid foreign body reaction, potential risk of infection, and arachnoiditis. This graft is also flexible and durable. Most importantly, we do not need to make any additional wound to harvest it. Then the bones, up to the inion above and the posterior arch of the atlas below, are exposed by subperiosteal dissection maintaining the avascular plane in the midline along the ligamentum nuchae to reduce bleeding and postoperative pain from muscle injury. Subperiosteal dissection of the squamous occipital bone down to the margin of foramen magnum and the posterior arch of atlas is continued to expose the bones to a width of about 2 cm on each side.

4.3 Craniectomy

Two burr holes below the inion just lateral to the midline are made, and a 2.5–3 cm wide posterior fossa craniectomy is done in the midline extending from the foramen magnum to 4–5 cm above with the help of bone and Kerrison's rongeurs. Care is taken not to widen the craniectomy more than 1.5 cm beyond the midline on either side. In Chiari patients, often the bone around the inion is very thick. In those cases, the inner surface is undermined with the help of the Kerrison's rongeurs to make more space there. The posterior arch of the atlas is also removed about 1 cm on both sides of the midline (**Figure 1C**).

4.4 Dural opening and grafting

The dura is opened in the midline with a straight incision, keeping the arachnoid intact. On very rare occasions, there may be dural venous lakes or lacunae,

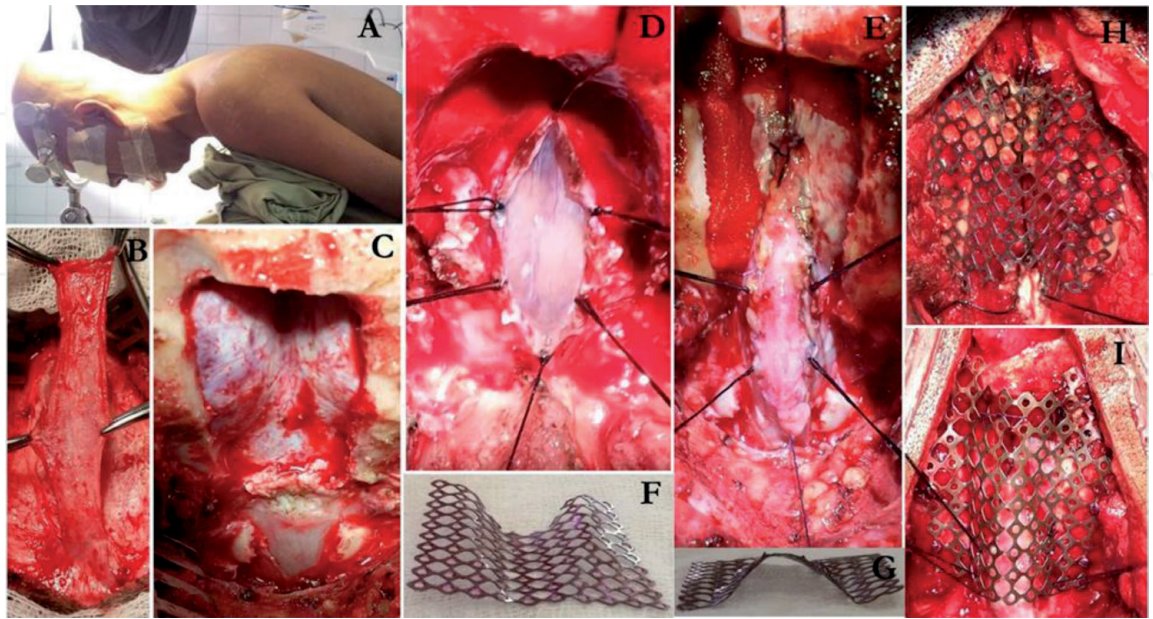


Figure 1. Per-operative picture of different steps of stealth cranioplasty (SCP). Patient is placed prone with head in neutral position. (A) Harvesting of the cervical fascial graft. (B) Posterior fossa craniectomy is in the midline measuring 2.5–3.0 cm in width and 4–5 cm vertically from the foramen magnum. (C) Arachnoid-preserving midline dural opening and hitches for tenting. (D) Duraplasty with cervical fascial graft. (E) Molding of the titanium “stealth cranioplasty.” (F and G) Fixing of the cranioplasty over the craniectomy gap. (H) Tenting of the duraplasty with the cranioplasty mesh (I).

which can be managed by continuous sutures along the cut margins to control the troublesome bleeding. If there is any accidental nick in the arachnoid, that is sealed with a very low bipolar cautery. The dural bands, which are present often, are kept as they are, to facilitate the dural tenting in the later part of the procedure. Two hitches are taken from the topmost and the lowermost points of the dural opening and two each from the free margins on either side. So, a total of six dural hitches are taken from the cut margins to tack those with the cranioplasty mesh later. The dural bands, which are not disturbed, help in strengthening the tenting where we want to pull the dura most, to widen the room in the posterior fossa around the foramen magnum (**Figure 1D**). The deep cervical fascial graft is sewn in the opening of the dura with 5–0 or 6–0 absorbable suture running stitches to complete an arachnoid-preserving duraplasty (APD) in a manner that when the dural tentings are fixed with the cranioplasty mesh, it resembles the roof of a hexagonal tent (**Figure 1E**).

4.5 Crafting of the stealth cranioplasty

The 5 × 5 cm titanium mesh (**Figure 2A**), which is malleable but tough enough to support the craniectomy gap after molding, is shaped to fit in the craniectomy gap in such a way that it covers the opening and at the same time increases the volume of the posterior fossa. The mesh is gradually curved in the middle like a longitudinally half-split cone, and the rest is kept flat (**Figures 1F, G and 2B–F, H, I**). By this the half cone takes the contour of a cockpit, and the flat parts take the contour of the wings of a “stealth” bomber (**Figure 2G**). That’s why we call it a “stealth cranioplasty”. The tapered end of the half cone, which almost merges with the flat of the construct, is placed at the upper part of the craniectomy defect to fit with the curvature of the occipital bone near the occipital protuberance. The lower part of the molded mesh having the wider portion of the half cone is placed inferiorly. The margin of this broader edge of the cone is shaped in a manner of a half circle (**Figure 2E, F**), to create more space around the foramen magnum to provide more range of motion during neck extension postoperatively. The lower border of the wings of the cranioplasty is merged with the margin of the foramen magnum. The




Figure 2. Steps of molding of the titanium mesh to the shape of “stealth cranioplasty”. The titanium mesh before molding. (A) The mesh is bent to make a triangular flat part in the middle. (B) The flat triangular part is curved into a longitudinally half split cone to mimic the cockpit and the sides are bent outwards to give them the contour of the wings of a Stealth bomber. (C & D) The widened part of the cone is cut in a crescent. (E & F) The pre-formed titanium mesh from front mimicking the cockpit of the Stealth bomber. (G) The look of the Stealth cranioplast from the wider part of the cone from rear (H) and below. (I).

rest of the wings is fixed with the bone at the lateral margins of the craniectomy defect to fit with the contour of the bone (**Figure 1H**).

4.6 Tenting and closure

The tentings are tied with the cranioplasty mesh to give the dural graft a final shape of the roof of a hexagonal tent (**Figure 1I**). Hemostasis is secured and the wound is closed in usual fashion in layers without any drain. Initially, there is some potential space between the dural graft and the cranioplasty, even after tenting. But this eventually is filled up with time by the pulsation of the brain as the duraplasty merges with the cranioplasty to create space for the CSF and neural structures.

5. Result

Eleven male and six female symptomatic CM1 adult patients, between age ranges of 22 and 42 years (mean 30.47 years), presented with different neurological symptoms related to CM1 and SM for 6–84 months (mean 27.70 months). The patients had syringes extending from three to more than ten vertebral levels (**Table 1**). All of the patients underwent PFD and arachnoid-preserving duraplasty followed by SCP and dural tenting and were followed up for a period of

Attribute	Number of patients (N = 17)
Gender	
Male	11
Female	6
Mean age in years (range)	30.47 (22–42 Years)
Clinical symptoms	
Sensory disturbance	12
Neck ache	10
Upper limb weakness	9
Lower limb weakness	6
Suboccipital headache	5
Duration of symptoms (months)	
1–12	3
13–24	4
25–36	3
37–48	4
49–60	2
>60	1
Extension of syrinx	
3–6 levels	6
7–10 levels	8
>10 levels	3

Table 1.
Showing distribution of gender, age, clinical symptoms, duration of symptoms, and extent of syrinx.

7–72 months (mean 32.59 months). Of 17 patients, 13 patients improved according to the Chicago Chiari Outcome Scale (CCOS) with score of 13–15, while 4 patients remained unchanged with CCOS of 12, and there was no worsening (**Table 2**). There was no complication related to Chiari surgery in any of the patients. All the patients had reestablishment of cisterna magna to different extents (**Figure 3E, F**). Five patients had marked reduction of syrinx, while 11 patients had moderate to mild reduction, and 1 patient had no change of syrinx. None of the patients needed redo surgery so far.

Parameters	Number of patients (N = 17)
Clinical outcome	
Improved	13
Unchanged	4
Worsened	0
CCOS	
13–16	13
9–12	4
<12	0
Radiological outcome of syrinx	
Marked reduction	5
Moderate reduction	7
Mild reduction	4
No reduction	1
Worsened/enlarged	0

Table 2.
Showing clinical outcome, outcome according to CCOS, and radiological outcome of syrinx.

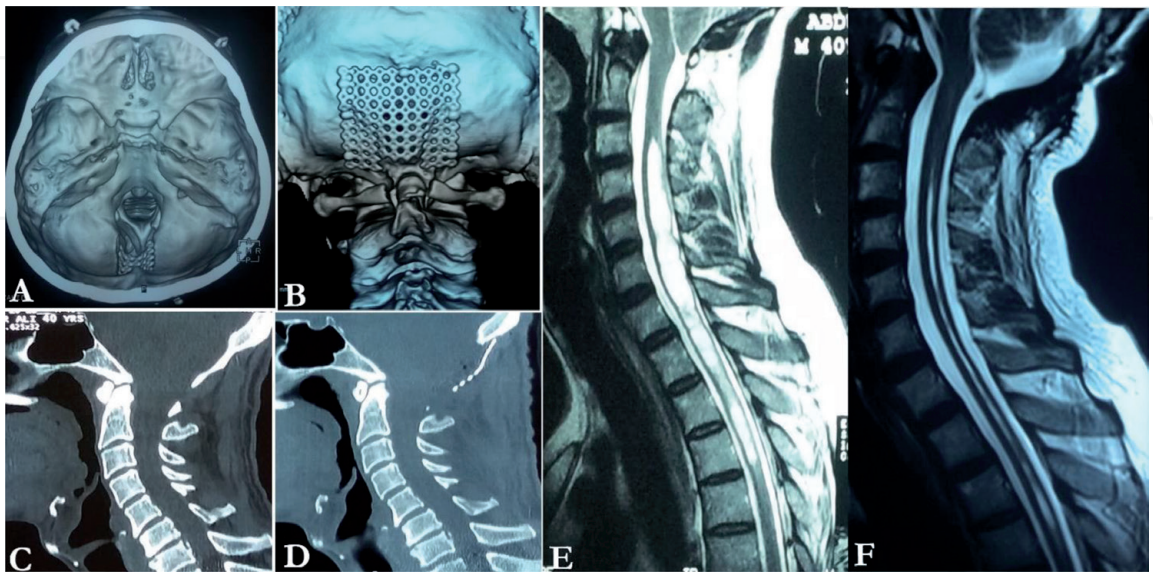


Figure 3.
Postoperative 3D CT scan following “stealth cranioplasty” increase in diameter of foramen magnum (A) and the final contour after fixing the cranioplasty with bone (B). Preoperative and (C) postoperative (D) sagittal reconstruction of bone around the CVJ showing increase in diameter of the foramen magnum and reconstruction of the posterior fossa in a shape of a sphere. Preoperative (E) and postoperative (F) sagittal T2WI ascent of the cerebellar tonsil, reestablishment of cisterna magna, and marked reduction of syrinx.

6. Our philosophy of innovation and evolution

Reconstruction of the posterior fossa by expansive cranioplasty is not practiced routinely following posterior fossa decompression for the CM1. Many authors have tried posterior fossa reconstruction with cranioplasty after PFD in many ways with different objectives. Cranioplasty as an attempt to treat and prevent further cerebellar subsidence during redo surgery has been described. Many techniques have been described in the literature like partial cranioplasty with methyl methacrylate (MMA) [115, 116], with autologous bone [117–122], and cranioplasty with different varieties of titanium prosthesis [48, 123–126]. Tacking of duraplasty with or without cranioplasty has also been described by some authors with intention to keep the cistern patent and to prevent adhesion [48, 120, 122, 123, 127]. We have tried to blend the procedures in an effective and least invasive way to give the utmost benefit to the patients.

Our journey began with the thought of the big concern of recurrence of symptoms in management of CM1. Postoperative recurrence of compression over the cerebellar tonsils around the foramen magnum and obliteration of CSF flow and dynamics around the CVJ may be caused by compression over the dura through the craniectomy gap by repositioned muscle bulk, fibrosis, and cerebellar sag.

We felt that, in conventional procedures, there is no measure to protect the dura from compression by the muscle bulk postoperatively from the back (**Figure 4A–C**). Initially the goal of cranioplasty was to prevent this by covering the craniectomy gap. Eventually, we felt that this cranioplasty can serve as a means to increase the posterior fossa volume as well.

So, we developed the technique based on our observations and thoughts in addition to the initial considerations of merely preventing recurrence and augmenting the posterior fossa volume.

Firstly, many patients come back with recurrences of symptoms from compression of the neuronal elements as well as obliteration of posterior CSF column by muscle bulk and fibrous tissue from posterior aspect around the surgical site as evident in many follow-up MRIs. This seemed to be due to having no protection against

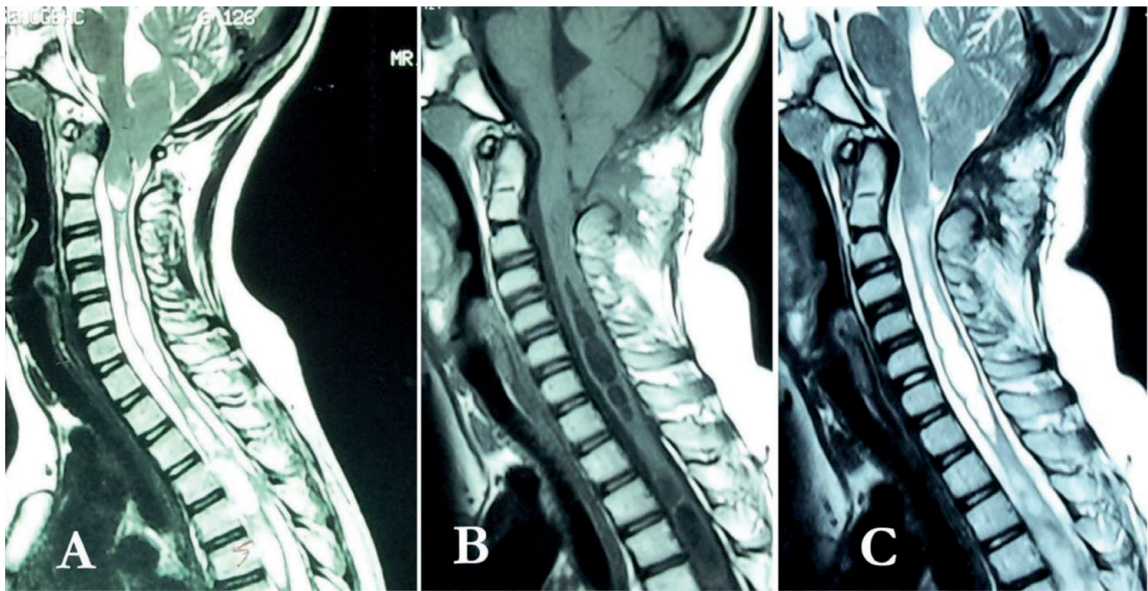


Figure 4. Preoperative sagittal T2WI of a patient with CM1 and syrinx (A) 1 year postoperative sagittal T1WI and T2WI following posterior fossa bony decompression only. Worthy to note the posterior compression on dura by muscle and fibrous tissue and the status of Chiari and syrinx (B and C).

recompression from the posterior aspect. This led us to think about cranioplasty to make a protective safeguard against any compression from posterior aspect to avoid recurrence of symptoms.

Secondly, we wanted to augment the PFV so that the herniated contents can come back, can be accommodated with ease in the newly formed abode, and can relieve the compression around the foramen magnum to get the anatomy and physiology including CSF dynamics back to near normal. Any container which is spherical is more voluminous compared to a flat one. The pathology in case of CM1, is the shallow posterior fossa due to flattening of the lower part. Our endeavor is to make the posterior fossa more spherical and voluminous by performing the APD, SCP, and dural tenting.

Thirdly, cerebellar slump is often encountered when a larger craniectomy is done. This might be due to release of pressure in the posterior fossa creating much space, and the slump can further be aided by gravity. Though we do not make the craniectomy bigger than 2.5 cm wide and 3–4 cm vertically, this cranioplasty helps in preventing the cerebellar ptosis, even if there is any chance at all.

Fourthly, arachnoid-preserving duraplasty has the advantage of preventing postoperative arachnoiditis related to surgery which may result from manipulation of the arachnoid and seepage of blood into the subarachnoid space. APD also has the advantage of avoiding CSF-related complications. As the Pascal's law states, any force in a closed fluid filled container is equally distributed to all directions with the same force. Our hypothesis is that the force of CSF in the new space, aided by brain pulsation, is capable of opening up any adhesion of the arachnoid or creating new pathway naturally if ample space can be created. Some reports are there that sometimes there are arachnoid veils over the foramen of Magendie to block the CSF flow, and we are afraid that in this subset of patients, the SCP might not work to reestablish the CSF flow. Possibly there was no patient like this in our series, as we found all our patients to have better CSF flow around the CVJ. Moreover, as the bigger CSF space is molded and maintained around the CVJ by APD and dural tenting, the CSF makes its way to the spinal subarachnoid space to equilibrate the pressure gradient with the cranial CSF. This CSF equilibrium has the potential to push the tonsils up, back to the newly formed space, and keeps it floating with the buoyancy to prevent it from going down again and castoffs the need to handle the tonsils as well. Initially the new space is enlarged moderately to relieve the symptoms. With time and CSF pulsation, the space expands more and takes the contour of the cranioplasty and is maintained very well, making the PFV and CSF dynamics adequate to sustain relief of symptoms. Following PFD, APD, dural tenting, and SCP, with reversal of CSF dynamics to normalcy, the syrinx usually reduces without taking any additional measure. However, in a good number of cases, the syrinx takes a long time to resolve or does not resolve appreciably, and the symptoms related to syrinx resolve markedly.

Fifthly, with the APD with autologous fascia and hexagonal tacking of that with the "stealth" cranioplasty, some complications can be prevented effectively. The CSF-related complications like CSF leak, meningitis or pseudomeningocele, inflammation, scarring and adhesion of dural graft, cerebellar sag, and compression from behind can be avoided and prevented efficiently with this combined technique. The dural tacking can help in enhancing and maintaining the CSF space also.

Finally, financial and psychological burden other than physical disability takes a heavy toll on the patients of CM1 and their families. These financial and psychological burdens can be avoided as this is well affordable by the patients of a low socioeconomic condition like ours since it costs no more than USD \$50 for the implant. At the same time, with this minimal expense, patients can avoid further extra expenses from re-surgery and rehabilitation program.

But all these adaptations did not take place straightway. We had to develop it step by step after facing different problems at different stages. Initially we had the considerations in mind that we have mentioned already. We started cranioplasty first with autologous bone with a titanium mesh buttress across the bone margins (**Figure 5A, B**). After few cases, we wanted to make it convenient for us by doing the cranioplasty with bone cement (MMA) with a buttress like the one as in cranioplasty with autologous bone (**Figure 5C, D**). We thought that the procedure can be made easier if we do the cranioplasty straight forward with a titanium mesh (**Figure 5E, F**). We expected that the gap created between the dura and the mesh by removing the bone at the craniectomy would be specious enough to serve the purpose of creating space for the cerebellum and reestablishment of CSF flow. That far we used to remove the dural bands only and did the cranioplasty with mesh and did so with satisfactory results in the next few cases until we faced problem with one patient 3 months postoperatively. This male patient was doing well postoperatively with marked improvement till he sneezed one morning and suddenly became quadriparetic. MRI showed greater herniation of the tonsils again (**Figure 6A, C**), while the immediate postop CT after the first surgery showed some ascent of the tonsil (**Figure 6A, B**). Preoperatively at the second surgery, we found that the dura was severely compressed along the lower margin of the mesh, and it seemed that the mesh margin has trapped the tonsil which was also evident in the MRI (**Figure 6C, D**). We only cut the inferior margin of the mesh in a crescentic shape and resected some fibrous tissue over the dura longitudinally to relieve the tonsils (**Figure 6E, F**), and the patient improved gradually. However the improvement was slow and was never as good as the first postoperative status.

After this, we routinely put the mesh by cutting the lower margin to make more space around the foramen magnum (**Figure 7A, B**). Then we thought that we can make some more space in the midline if we bend the mesh in the middle like a longitudinally half-split tube in the middle (**Figure 7C, D**). At this part of the advance of our journey, we started arachnoid-preserving duraplasty and dural tenting as well, and

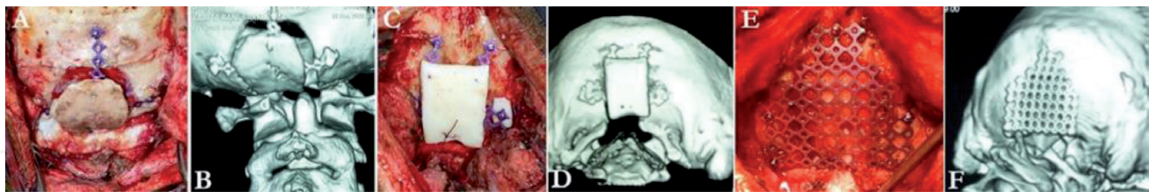


Figure 5. Preoperative picture and postoperative 3D CT scan of cranioplasties using different materials. Cranioplasty with autologous bone (A and B), bone cement (MMA) (C and D), and flat titanium mesh (E and F).

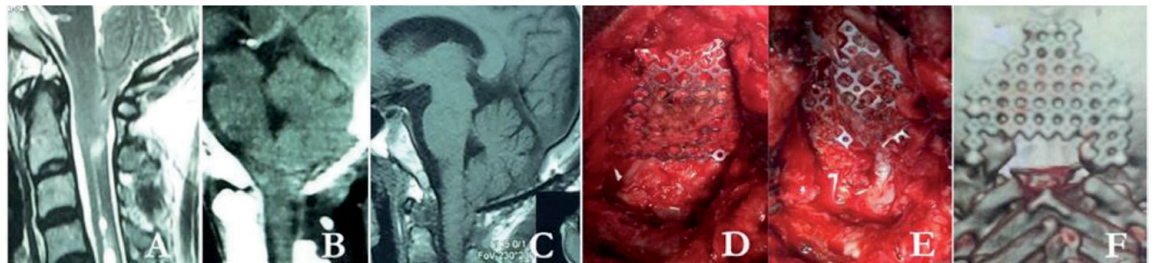


Figure 6. MRI before first surgery of the patient that gave us the impetus to develop this technique, showing tonsillar herniation (A), CT scan after first surgery showing appreciable ascent of the tonsil (B), MRI before second surgery (after clinical deterioration) showing entrapped tonsil by the lower margin of the titanium mesh (C), preoperative picture at second surgery showing the dural compression by the lower margin of the titanium mesh (D), decompressed dura following cutting the lower margin of the titanium mesh and lysis of fibrosis (E), post of 3D CT scan to showing the lower cut margin of the titanium mesh to relieve the compression around the CVJ.

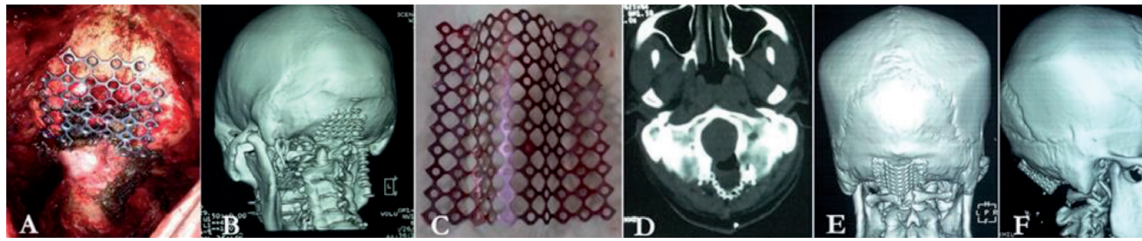


Figure 7.

Preoperative picture (A) and postoperative 3D CT scan (B) showing the placement of flat titanium mesh by cutting the lower margin to make more space around the foramen magnum. Molding of the titanium mesh in a longitudinally split half tube (C) which gives ample space around the foramen magnum as seen in postoperative CT scan (D). Postoperative 3D CT scan showing the protrusion around the external occipital protuberance (E and F).

that produced good results. We had to rethink of the shape of the mesh while molding, when some patients complained of some uneasiness from the little swelling under the skin from the bend at the upper part. Though we tried to merge the upper part of the tube-like bending with the external occipital protuberance, in some patients it was little more protruded than the external occipital protuberance (**Figure 7E, F**). We were afraid of skin excoriation in these patients after we were noticed about this problem. However, practically it did not produce any complication in any of the patients. We then changed the molding a little to come to the present day shape to merge the upper part with the bone near the external occipital protuberance by bending it like a longitudinally half split cone instead of a half split tube, which when fixed with the bone becomes flattened to merge with the contour of the occipital bone. Actually that gave us an additional benefit of preventing cerebellar sag also; as the upper part is flatter, this has more chance of supporting the cerebellum from sagging, if there is any chance at all through the narrow craniectomy gap (**Figure 3B**). This also gives the scope to increase the diameter of the foramen magnum (**Figure 3A, C, D**).

Treatment for CM1 is surgical and success of surgery depends on appropriate patient selection. We consider it a factor of paramount importance while selecting patients for stealth cranioplasty. Our patients are all adults, having no associated complex pathologies like hydrocephalus, platybasia, or basilar invagination, which gives us satisfactory result.

7. Conclusion

The journey to develop “stealth cranioplasty” was not a smooth one. After a lot of trial and error, now it seems to be an effective, fruitful, and cost-effective technique for management of symptomatic adult Chiari malformation type 1 with syringomyelia. This technique has the advantages of preventing complications and recurrences in addition to improvement of symptoms by addressing the basic pathology.

Acknowledgements

I am deeply indebted to the members of the team and sincerely thank them all for helping me in developing this technique with their valuable technical advices.

Conflict of interest

None.

Abbreviations

ACM	Acquired Chiari Malformation
APD	Arachnoid-preserving duraplasty
CCOS	Chicago Chiari Outcome Scale
CM	Chiari malformation
CM1	Chiari malformation type 1
CSF	Cerebrospinal fluid
CVJ	Craniovertebral junction
ICP	Intracranial pressure
MMA	Methyl methacrylate
MRI	Magnetic resonance imaging
PF	Posterior fossa
PFD	Posterior fossa decompression
PFV	Posterior fossa volume
SCP	Stealth cranioplasty
SM	Syringomyelia

Author details

Asifur Rahman
Department of Neurosurgery, Bangabandhu Sheikh Mujib Medical University,
Shahbag, Dhaka, Bangladesh

*Address all correspondence to: bijoun14@yahoo.com

IntechOpen

© 2019 The Author(s). Licensee IntechOpen. This chapter is distributed under the terms of the Creative Commons Attribution License (<http://creativecommons.org/licenses/by/3.0>), which permits unrestricted use, distribution, and reproduction in any medium, provided the original work is properly cited. 

References

- [1] Bejjani GK. Definition of the adult Chiari malformation: A brief historical overview. *Neurosurgical Focus*. 2001;**11**(1):1-8
- [2] Poretti A, Ashmawy R, Garzon-Muvdi T, Jallo GI, Huisman TA, Raybaud C. Chiari type 1 deformity in children: Pathogenetic, clinical, neuroimaging, and management aspects. *Neuropediatrics*. 2016;**47**(05):293-307
- [3] Rahman A. "Formation" of Chiari "malformation." Nature's philosophical way of adaptation. *Journal of Craniovertebral Junction and Spine*. 2017;**8**(3):291
- [4] Bruner E. Cranial shape and size variation in human evolution: Structural and functional perspectives. *Child's Nervous System*. 2007;**23**(12):1357-1365
- [5] Fernandes YB, Ramina R, Campos-Herrera CR, Borges G. Evolutionary hypothesis for Chiari type I malformation. *Medical Hypotheses*. 2013;**81**(4):715-719
- [6] Rightmire GP. Brain size and encephalization in early to mid-Pleistocene homo. *American Journal of Physical Anthropology*. 2004;**124**(2):109-123
- [7] Furtado SV, Reddy K, Hegde A. Posterior fossa morphometry in symptomatic pediatric and adult Chiari I malformation. *Journal of Clinical Neuroscience*. 2009;**16**(11):1449-1454
- [8] Atkinson JL, Kokmen E, Miller GM. Evidence of posterior fossa hypoplasia in the familial variant of adult Chiari I malformation: Case report. *Neurosurgery*. 1998;**42**(2):401-404
- [9] Markunas CA, Tubbs RS, Moftakhar R, Ashley-Koch AE, Gregory SG, Oakes WJ, et al. Clinical, radiological, and genetic similarities between patients with Chiari type I and type 0 malformations. *Journal of Neurosurgery: Pediatrics*. 2012;**9**(4):372-378
- [10] Mavinkurve GG, Sciubba D, Amundson E, Jallo GI. Familial Chiari type I malformation with syringomyelia in two siblings: Case report and review of the literature. *Child's Nervous System*. 2005;**21**(11):955-959
- [11] Milhorat TH, Chou MW, Trinidad EM, Kula RW, Mandell M, Wolpert C, et al. Chiari I malformation redefined: Clinical and radiographic findings for 364 symptomatic patients. *Neurosurgery*. 1999;**44**(5):1005-1017
- [12] Nagy L, Mobley J, Ray C. Familial aggregation of chiari malformation: Presentation, pedigree, and review of the literature. *Turkish Neurosurgery*. 2016;**26**(2):315-320
- [13] Schanker BD, Walcott BP, Nahed BV, Kahle KT, Li YM, Coumans J-VC. Familial Chiari malformation: Case series. *Neurosurgical Focus*. 2011;**31**(3):E1
- [14] Speer MC, George TM, Enterline DS, Franklin A, Wolpert CM, Milhorat TH. A genetic hypothesis for Chiari I malformation with or without syringomyelia. *Neurosurgical Focus*. 2000;**8**(3):1-4
- [15] Stovner LJ, Cappelen J, Nilsen G, Sjaastad O. The Chiari type I malformation in two monozygotic twins and first-degree relatives. *Annals of Neurology*. 1992;**31**(2):220-222
- [16] Szewka AJ, Walsh LE, Boaz JC, Carvalho KS, Golomb MR. Chiari in the family: Inheritance of the Chiari I malformation. *Pediatric Neurology*. 2006;**34**(6):481-485

- [17] Tubbs RS, Hill M, Loukas M, Shoja MM, Oakes WJ. Volumetric analysis of the posterior cranial fossa in a family with four generations of the Chiari malformation type I. *Journal of Neurosurgery: Pediatrics*. 2008;**1**(1):21-24
- [18] Turgut M. Chiari type I malformation in two monozygotic twins. *British Journal of Neurosurgery*. 2001;**15**(3):279-280
- [19] Weisfeld-Adams JD, Carter MR, Likeman MJ, Rankin J. Three sisters with Chiari I malformation with and without associated syringomyelia. *Pediatric Neurosurgery*. 2007;**43**(6):533-538
- [20] Boyles AL, Enterline DS, Hammock PH, Siegel DG, Slifer SH, Mehlretter L, et al. Phenotypic definition of Chiari type I malformation coupled with high-density SNP genome screen shows significant evidence for linkage to regions on chromosomes 9 and 15. *American Journal of Medical Genetics Part A*. 2006;**140**(24):2776-2785
- [21] Markunas CA, Enterline DS, Dunlap K, Soldano K, Cope H, Stajich J, et al. Genetic evaluation and application of posterior cranial fossa traits as endophenotypes for Chiari type I malformation. *Annals of Human Genetics*. 2014;**78**(1):1-12
- [22] Musolf AM, Ho WS, Long KA, Zhuang Z, Argersinger DP, Sun H, et al. Small posterior fossa in Chiari I malformation affected families is significantly linked to 1q43-44 and 12q23-24.11 using whole exome sequencing. *European Journal of Human Genetics*. 2019;**27**(10):1599-1610
- [23] Sekula RF, Arnone GD, Crocker C, Aziz KM, Alperin N. The pathogenesis of Chiari I malformation and syringomyelia. *Neurological Research*. 2011;**33**(3):232-239
- [24] Speer MC, Enterline DS, Mehlretter L, Hammock P, Joseph J, Dickerson M, et al. Chiari type I malformation with or without syringomyelia: Prevalence and genetics. *Journal of Genetic Counseling*. 2003;**12**(4):297-311
- [25] Cambronero F, Puelles L. Rostrocaudal nuclear relationships in the avian medulla oblongata: A fate map with quail chick chimeras. *The Journal of Comparative Neurology*. 2000;**427**(4):522-545
- [26] Carstens MH. Neural tube programming and the pathogenesis of craniofacial clefts, part I: The neuromeric organization of the head and neck. *Handbook of Clinical Neurology*. 2007;**87**:247-276
- [27] Pang D, Thompson DN. Embryology and bony malformations of the craniovertebral junction. *Child's Nervous System*. 2011;**27**(4):523-564
- [28] Raybaud C, Jallo GI. Chiari 1 deformity in children: Etiopathogenesis and radiologic diagnosis. *Handbook of Clinical Neurology*. 2018;**155**:25-48. Elsevier
- [29] Shoja MM, Ramdhan R, Jensen CJ, Chern JJ, Oakes WJ, Tubbs RS. Embryology of the craniocervical junction and posterior cranial fossa, part I: Development of the upper vertebrae and skull. *Clinical Anatomy*. 2018;**31**(4):466-487
- [30] Chiari H. Concerning alterations in the cerebellum resulting from cerebral hydrocephalus. *Pediatric Neurosurgery*. 1987;**13**(1):3-8
- [31] Koehler P. Chiari's description of cerebellar ectopy (1891): With a summary of Cleland's and Arnold's contributions and some early observations on neural-tube

defects. *Journal of Neurosurgery*. 1991;**75**(5):823-826

[32] Massimi L, Peppucci E, Peraio S, Di Rocco C. History of Chiari type I malformation. *Neurological Sciences*. 2011;**32**(3):263-265

[33] Pearce J. Arnold Chiari, or "Cruveilhier cleland Chiari" malformation. *Journal of Neurology, Neurosurgery & Psychiatry*. 2000;**68**(1):13

[34] Carmel P, Markesbery W. Early descriptions of the Arnold-Chiari malformation. The contribution of John Cleland. *Journal of Neurosurgery*. 1972;**37**(5):543-547

[35] Fries FN, Hendrix P, Brinker TJ, Loukas M, Tubbs RS. Otto Mennicke (1876–) and the first description of skull base anomalies causing cerebellar tonsillar ectopia: One of the first mentions of the Chiari I malformation. *Child's Nervous System*. 2017;**33**(5):825-827

[36] Nyland H, Krogness K. Size of posterior fossa in Chiari type 1 malformation in adults. *Acta Neurochirurgica*. 1978;**40**(3-4): 233-242

[37] Stovner L, Bergan U, Nilsen G, Sjaastad O. Posterior cranial fossa dimensions in the Chiari I malformation: Relation to pathogenesis and clinical presentation. *Neuroradiology*. 1993;**35**(2):113-118

[38] Badie B, Mendoza D, Batzdorf U. Posterior fossa volume and response to suboccipital decompression in patients with Chiari I malformation. *Neurosurgery*. 1995;**37**(2):214-218

[39] Wang J, Alotaibi NM, Samuel N, Ibrahim GM, Fallah A, Cusimano MD. Acquired Chiari malformation and syringomyelia

secondary to space-occupying lesions: A systematic review. *World Neurosurgery*. 2017;**98**:800-808.e2

[40] Alkoç OA, Songur A, Eser O, Toktas M, Gönül Y, Esi E, et al. Stereological and morphometric analysis of MRI Chiari malformation type-1. *Journal of Korean Neurosurgical Society*. 2015;**58**(5):454

[41] Alperin N, Loftus JR, Oliu CJ, Bagci AM, Lee SH, Ertl-Wagner B, et al. Magnetic resonance imaging measures of posterior cranial fossa morphology and cerebrospinal fluid physiology in Chiari malformation type I. *Neurosurgery*. 2014;**75**(5):515-522

[42] Aydin S, Hanimoglu H, Tanriverdi T, Yentur E, Kaynar MY. Chiari type I malformations in adults: A morphometric analysis of the posterior cranial fossa. *Surgical Neurology*. 2005;**64**(3):237-241

[43] Batzdorf U, McArthur DL, Bentson JR. Surgical treatment of Chiari malformation with and without syringomyelia: Experience with 177 adult patients. *Journal of Neurosurgery*. 2013;**118**(2):232-242

[44] Biswas D, Eppelheimer MS, Houston JR, Ibrahimy A, Bapuraj JR, Labuda R, et al. Quantification of cerebellar crowding in type I Chiari malformation. *Annals of Biomedical Engineering*. 2019;**47**(3):731-743

[45] Dagtekin A, Avci E, Kara E, Uzmansel D, Dagtekin O, Koseoglu A, et al. Posterior cranial fossa morphometry in symptomatic adult Chiari I malformation patients: Comparative clinical and anatomical study. *Clinical Neurology and Neurosurgery*. 2011;**113**(5):399-403

[46] Greitz D, Wirestam R, Franck A, Nordell B, Thomsen C, Ståhlberg F. Pulsatile brain movement and associated

hydrodynamics studied by magnetic resonance phase imaging. *Neuroradiology*. 1992;**34**(5):370-380

[47] Karagöz F, Izgi N, Sencer SK. Morphometric measurements of the cranium in patients with Chiari type I malformation and comparison with the normal population. *Acta Neurochirurgica*. 2002;**144**(2):165-171

[48] Leung V, Magnussen JS, Stoodley MA, Bilston LE. Cerebellar and hindbrain motion in Chiari malformation with and without syringomyelia. *Journal of Neurosurgery: Spine*. 2016;**24**(4):546-555

[49] Noudel R, Jovenin N, Eap C, Scherpereel B, Pierot L, Rousseaux P. Incidence of basioccipital hypoplasia in Chiari malformation type I: Comparative morphometric study of the posterior cranial fossa. *Journal of Neurosurgery*. 2009;**111**(5):1046-1052

[50] Sgouros S, Kountouri M, Natarajan K. Posterior fossa volume in children with Chiari malformation type I. *Journal of Neurosurgery: Pediatrics*. 2006;**105**(2):101-106

[51] Shoja MM, Johal J, Oakes WJ, Tubbs RS. Embryology and pathophysiology of the Chiari I and II malformations: A comprehensive review. *Clinical Anatomy*. 2018;**31**(2):202-215

[52] Vega A, Quintana F, Berciano J. Basichondrocranium anomalies in adult Chiari type I malformation: A morphometric study. *Journal of the Neurological Sciences*. 1990;**99**(2-3):137-145

[53] Marin-Padilla M, Marin-Padilla TM. Morphogenesis of experimentally induced Arnold-Chiari malformation. *Journal of the Neurological Sciences*. 1981;**50**(1):29-55

[54] Richards PS, Bargiota A, Corral RJ. Paget's disease causing an Arnold-Chiari

type 1 malformation: Radiographic findings. *American Journal of Roentgenology*. 2001;**176**(3):816-817

[55] Caldemeyer KS, Boaz JC, Wappner RS, Moran CC, Smith RR, Quets JP. Chiari I malformation: Association with hypophosphatemic rickets and MR imaging appearance. *Radiology*. 1995;**195**(3):733-738

[56] Kuether TA, Piatt JH. Chiari malformation associated with vitamin D-resistant rickets: Case report. *Neurosurgery*. 1998;**42**(5):1168-1171

[57] Day RA, Park TS, Ojemann JG, Kaufman BA. Foramen magnum decompression for cervicomedullary encroachment in craniometaphyseal dysplasia: Case report. *Neurosurgery*. 1997;**41**(4):960-964

[58] Lemar JH, Perloff J, Merenich J. Symptomatic Chiari-I malformation in a patient with acromegaly. *Southern Medical Journal*. 1994;**87**(2):284-285

[59] Tubbs RS, Wellons JC III, Smyth MD, Bartolucci AA, Blount JP, Oakes WJ, et al. Children with growth hormone deficiency and Chiari I malformation: A morphometric analysis of the posterior cranial fossa. *Pediatric Neurosurgery*. 2003;**38**(6):324-328

[60] Aboulezz AO, Sartor K, Geyer CA, Gado MH. Position of cerebellar tonsils in the normal population and in patients with Chiari malformation: A quantitative approach with MR imaging. *Journal of Computer Assisted Tomography*. 1985;**9**(6):1033-1036

[61] Benglis D, Covington D, Bhatia R, Bhatia S, Elhammady MS, Ragheb J, et al. Outcomes in pediatric patients with Chiari malformation type I followed up without surgery. *Journal of Neurosurgery: Pediatrics*. 2011;**7**(4):375-379

[62] Elster AD, Chen M. Chiari I malformations: clinical and

radiologic reappraisal. *Radiology*. 1992;**183**(2):347-353

Chiari malformation. *Journal of Neurosurgery*. 2013;**119**(3):812-819

[63] Işık N, Elmaci I, Silav G, Celik M, Kalelioğlu M. Chiari malformation type III and results of surgery: A clinical study. *Pediatric Neurosurgery*. 2009;**45**(1):19-28

[71] Cameron A. The Arnold-Chiari and other neuro-anatomical malformations associated with spina bifida. *The Journal of Pathology and Bacteriology*. 1957;**73**(1):195-211

[64] Khalsa SSS, Geh N, Martin BA, Allen PA, Strahle J, Loth F, et al. Morphometric and volumetric comparison of 102 children with symptomatic and asymptomatic Chiari malformation type I. *Journal of Neurosurgery: Pediatrics*. 2018;**21**(1):65-71

[72] Emery JL, MacKenzie N. Medullo-cervical dislocation deformity (Chiari II deformity) related to neurospinal dysraphism (meningomyelocele). *Brain*. 1973;**96**(1):155-162

[65] Meadows J, Kraut M, Guarnieri M, Haroun RI, Carson BS. Asymptomatic Chiari type I malformations identified on magnetic resonance imaging. *Journal of Neurosurgery*. 2000;**92**(6):920-926

[73] van Hoy tenia G, Van den Berg R. Embryological studies of the posterior fossa in connection with Arnold-Chiari malformation. *Developmental Medicine and Child Neurology*. 1966;**8**:61-76

[66] Novegno F, Caldarelli M, Massa A, Chieffo D, Massimi L, Pettorini B, et al. The natural history of the Chiari type I anomaly. *Journal of Neurosurgery: Pediatrics*. 2008;**2**(3):179-187

[74] Welch K, Shillito J, Strand R, Fischer EG, Winston KR. Chiari I "malformation"—An acquired disorder? *Journal of Neurosurgery*. 1981;**55**(4):604-609

[67] Pomeranec IJ, Ksendzovsky A, Awad AJ, Fezeu F, Jane JA. Natural and surgical history of Chiari malformation type I in the pediatric population. *Journal of Neurosurgery: Pediatrics*. 2016;**17**(3):343-352

[75] Fischer EG, Welch K, Shillito J. Syringomyelia following lumboureteral shunting for communicating hydrocephalus: Report of three cases. *Journal of Neurosurgery*. 1977;**47**(1):96-100

[68] Sekula RF, Jannetta PJ, Casey KF, Marchan EM, Sekula LK, McCrady CS. Dimensions of the posterior fossa in patients symptomatic for Chiari I malformation but without cerebellar tonsillar descent. *Cerebrospinal Fluid Research*. 2005;**2**(1):11

[76] Brierley J, Field E. The connexions of the spinal sub-arachnoid space with the lymphatic system. *Journal of Anatomy*. 1948;**82**(Pt 3):153-166

[69] Shehu B, Ismail N, Mahmu M, Hassan I. Chiari I malformation: A missed diagnosis. *Annals of African Medicine*. 2006;**5**(4):206-208

[77] Elman R. Spinal arachnoid granulations with especial reference to the cerebrospinal fluid. *Johns Hopkins Hospital Bulletin*. 1923;**34**:99-104

[70] Smith BW, Strahle J, Bapuraj JR, Muraszko KM, Garton HJ, Maher CO. Distribution of cerebellar tonsil position: Implications for understanding

[78] Hammerstad JP, Lorenzo AV, Cutler R. Iodide transport from the spinal subarachnoid fluid in the cat. *American Journal of Physiology-Legacy Content*. 1969;**216**(2):353-358

[79] Lorenzo A, Hammerstad J, Cutler R. Cerebrospinal fluid formation

and absorption and transport of iodide and sulfate from the spinal subarachnoid space. *Journal of the Neurological Sciences*. 1970;**10**(3):247-258

[80] Payner TD, Prenger E, Berger TS, Crone KR. Acquired Chiari malformations: Incidence, diagnosis, and management. *Neurosurgery*. 1994;**34**(3):429-434

[81] Milhorat TH, Nishikawa M, Kula RW, Dlugacz YD. Mechanisms of cerebellar tonsil herniation in patients with Chiari malformations as guide to clinical management. *Acta Neurochirurgica*. 2010;**152**(7):1117-1127

[82] Tubbs RS, Oakes WJ. The Chiari malformations: A historical context. In: Shane Tubbs R, Jerry Oakes W, editors. *The Chiari Malformations*. New York: Springer; 2013. pp. 5-11

[83] Wilkins RH, Brody IA. The Arnold-Chiari malformation. *Archives of Neurology*. 1971;**25**(4):376-377

[84] Killeen A, Roguski M, Chavez A, Heilman C, Hwang S. Non-operative outcomes in Chiari I malformation patients. *Journal of Clinical Neuroscience*. 2015;**22**(1):133-138

[85] Nishizawa S, Yokoyama T, Yokota N, Tokuyama T, Ohta S. Incidentally identified syringomyelia associated with Chiari I malformations: Is early interventional surgery necessary? *Neurosurgery*. 2001;**49**(3):637-641

[86] Massimi L, Frassanito P, Bianchi F, Tamburrini G, Caldarelli M. Bony decompression vs duraplasty for Chiari I malformation: Does the eternal dilemma matter? *Child's Nervous System*. 2019;**35**(10):1-12

[87] Abd-El-Barr M, Groff MW. Less is more: Limiting the size of posterior fossa decompressions in Chiari I

malformations. *World Neurosurgery*. 2014;**81**(5-6):706

[88] Lee HS, Lee S-H, Kim ES, Kim J-S, Lee J-I, Shin HJ, et al. Surgical results of arachnoid-preserving posterior fossa decompression for Chiari I malformation with associated syringomyelia. *Journal of Clinical Neuroscience*. 2012;**19**(4):557-560

[89] Kennedy BC, Kelly KM, Phan MQ, Bruce SS, McDowell MM, Anderson RC, et al. Outcomes after suboccipital decompression without dural opening in children with Chiari malformation type I. *Journal of Neurosurgery: Pediatrics*. 2015;**16**(2):150-158

[90] Navarro R, Olavarria G, Seshadri R, Gonzales-Portillo G, McLone DG, Tomita T. Surgical results of posterior fossa decompression for patients with Chiari I malformation. *Child's Nervous System*. 2004;**20**(5):349-356

[91] Hida K, Iwasaki Y, Koyanagi I, Sawamura Y, Abe H. Surgical indication and results of foramen magnum decompression versus syringosubarachnoid shunting for syringomyelia associated with Chiari I malformation. *Neurosurgery*. 1995;**37**(4):673-679

[92] Munshi I, Frim D, Stine-Reyes R, Weir BK, Hekmatpanah J, Brown F. Effects of posterior fossa decompression with and without duraplasty on Chiari malformation-associated hydromyelia. *Neurosurgery*. 2000;**46**(6):1384-1390

[93] Quon JL, Grant RA, DiLuna ML. Multimodal evaluation of CSF dynamics following extradural decompression for Chiari malformation type I. *Journal of Neurosurgery: Spine*. 2015;**22**(6):622-630

[94] Oral S, Yilmaz A, Kucuk A, Tumturk A, Menku A. Comparison of dural splitting and duraplasty in patients with Chiari type I malformation: Relationship between

tonsillo-dural distance and syrinx cavity. *Turkish Neurosurgery*. 2019;**29**(2):229-236

[95] Gardner WJ, Goodall RJ. The surgical treatment of Arnold-Chiari malformation in adults: An explanation of its mechanism and importance of encephalography in diagnosis. *Journal of Neurosurgery*. 1950;**7**(3):199-206

[96] Krieger MD, McComb JG, Levy ML. Toward a simpler surgical management of Chiari I malformation in a pediatric population. *Pediatric Neurosurgery*. 1999;**30**(3):113-121

[97] Logue V, Edwards MR. Syringomyelia and its surgical treatment--an analysis of 75 patients. *Journal of Neurology, Neurosurgery, and Psychiatry*. 1981;**44**(4):273-284

[98] Kurzbuch AR, Jayamohan J, Magdum S. Decompressive surgery for Chiari I malformation in children without dural repair: A still effective and safe procedure? *Child's Nervous System*. 2019;**35**(10):1-8

[99] Aghakhani N, Parker F, David P, Morar S, Lacroix C, Benoudiba F, et al. Long-term follow-up of Chiari-related syringomyelia in adults: Analysis of 157 surgically treated cases. *Neurosurgery*. 2009;**64**(2):308-315

[100] Alfieri A, Pinna G. Long-term results after posterior fossa decompression in syringomyelia with adult Chiari type I malformation. *Journal of Neurosurgery: Spine*. 2012;**17**(5):381-387

[101] Armonda RA, Citrin CM, Foley KT, Ellenbogen RG. Quantitative cine-mode magnetic resonance imaging of Chiari I malformations: An analysis of cerebrospinal fluid dynamics. *Neurosurgery*. 1994;**35**(2):214-224

[102] Bonney PA, Maurer AJ, Cheema AA, Duong Q, Glenn CA,

Safavi-Abbasi S, et al. Clinical significance of changes in pB-C2 distance in patients with Chiari type I malformations following posterior fossa decompression: A single-institution experience. *Journal of Neurosurgery: Pediatrics*. 2016;**17**(3):336-342

[103] Radmanesh A, Greenberg JK, Chatterjee A, Smyth MD, Limbrick DD, Sharma A. Tonsillar pulsatility before and after surgical decompression for children with Chiari malformation type 1: An application for true fast imaging with steady state precession. *Neuroradiology*. 2015;**57**(4):387-393

[104] Singhal GD, Singhal S, Agrawal G, Singhal D, Arora V. Surgical experience in pediatric patients with Chiari-I malformations aged ≤ 18 years. *Journal of Neurosciences in Rural Practice*. 2019;**10**(1):85

[105] Zhang L, Yi Z, Duan H, Li L. A novel autologous duraplasty in situ technique for the treatment of Chiari malformation type I. *Journal of Neurosurgery*. 2017;**126**(1):91-97

[106] Alden TD, Ojemann JG, Park T. Surgical treatment of Chiari I malformation: Indications and approaches. *Neurosurgical Focus*. 2001;**11**(1):1-5

[107] Milhorat TH, Johnson WD, Miller JI, Bergland RM, Hollenberg-Sher J. Surgical treatment of syringomyelia based on magnetic resonance imaging criteria. *Neurosurgery*. 1992;**31**(2):231-245

[108] Ladner TR, Dewan MC, Day MA, Shannon CN, Tomycz L, Tulipan N, et al. Evaluating the relationship of the pB-C2 line to clinical outcomes in a 15-year single-center cohort of pediatric Chiari I malformation. *Journal of Neurosurgery: Pediatrics*. 2015;**15**(2):178-188

[109] Batzdorf U. Chiari I malformation with syringomyelia: Evaluation of

surgical therapy by magnetic resonance imaging. *Journal of Neurosurgery*. 1988;**68**(5):726-730

[110] Alzate JC, Kothbauer KF, Jallo GI, Epstein FJ. Treatment of Chiari type I malformation in patients with and without syringomyelia: A consecutive series of 66 cases. *Neurosurgical Focus*. 2001;**11**(1):1-9

[111] Stanko KM, Lee YM, Rios J, Wu A, Sobrinho GW, Weingart JD, et al. Improvement of syrinx resolution after tonsillar cauterization in pediatric patients with Chiari type I malformation. *Journal of Neurosurgery: Pediatrics*. 2016;**17**(2):174-181

[112] Rocque BG, Oakes WJ. Surgical treatment of Chiari I malformation. *Neurosurgery Clinics*. 2015;**26**(4):527-531

[113] Ratre S, Yadav N, Yadav YR, Parihar VS, Bajaj J, Kher Y. Endoscopic management of Arnold-Chiari malformation type I with or without syringomyelia. *Journal of Neurological Surgery Part A: Central European Neurosurgery*. 2018;**79**(01):045-051

[114] Zagzoog N, Reddy KK. Use of minimally invasive tubular retractors for foramen magnum decompression of Chiari malformation: A technical note and case series. *World Neurosurgery*. 2019;**128**:248-253

[115] Di X, Luciano MG, Benzel EC. Acute respiratory arrest following partial suboccipital cranioplasty for cerebellar ptosis from Chiari malformation decompression: Report of 2 cases. *Neurosurgical Focus*. 2008;**25**(6):E12

[116] Holly LT, Batzdorf U. Management of cerebellar ptosis following craniovertebral decompression for Chiari I malformation. *Journal of Neurosurgery*. 2001;**94**(1):21-26

[117] Chou Y-C, Sarkar R, Osuagwu FC, Lazareff JA. Suboccipital craniotomy in the surgical treatment of Chiari I malformation. *Child's Nervous System*. 2009;**25**(9):1111-1114

[118] Dewaele F, Kalmar AF, Baert E, Van Haver A, Hallaert G, De Mets F, et al. The use of the trendelenburg position in the surgical treatment of extreme cerebellar slump. *British Journal of Neurosurgery*. 2016;**30**(1):115-119

[119] Heller JB, Lazareff J, Gabbay JS, Lam S, Kawamoto HK, Bradley JP. Posterior cranial fossa box expansion leads to resolution of symptomatic cerebellar ptosis following Chiari I malformation repair. *The Journal of Craniofacial Surgery*. 2007;**18**(2):274-280

[120] Nishikawa M, Ohata K, Baba M, Terakawa Y, Hara M. Chiari I malformation associated with ventral compression and instability: One-stage posterior decompression and fusion with a new instrumentation technique. *Neurosurgery*. 2004;**54**(6):1430-1435

[121] Sakamoto H, Nishikawa M, Hakuba A, Yasui T, Kitano S, Nakanishi N, et al. Expansive suboccipital cranioplasty for the treatment of syringomyelia associated with Chiari malformation. *Acta Neurochirurgica*. 1999;**141**(9):949-961

[122] Takayasu M, Takagi T, Hara M, Anzai M. A simple technique for expansive suboccipital cranioplasty following foramen magnum decompression for the treatment of syringomyelia associated with Chiari I malformation. *Neurosurgical Review*. 2004;**27**(3):173-177

[123] Assina R, Meleis AM, Cohen MA, Iqbal MO, Liu JK. Titanium mesh-assisted dural tenting for an expansile suboccipital cranioplasty in the

treatment of Chiari 1 malformation.
Journal of Clinical Neuroscience.
2014;**21**(9):1641-1646

[124] Oró JJ, Mueller DM. Posterior fossa decompression and reconstruction in adolescents and adults with the Chiari I malformation. Neurological Research. 2011;**33**(3):261-271

[125] Udani V, Holly LT, Chow D, Batzdorf U. Posterior fossa reconstruction using titanium plate for the treatment of cerebellar ptosis after decompression for Chiari malformation. World Neurosurgery. 2014;**81**(5-6):836-841

[126] Rahman A, Rana MS, Bhandari PB, Asif DS, Uddin ANW, Obaida ASMA, et al. "Stealth cranioplasty:" a novel endeavor for symptomatic adult Chiari I patients with syringomyelia: Technical note, appraisal, and philosophical considerations. Journal of Craniovertebral Junction and Spine. 2017;**8**(3):243

[127] Sahuquillo J, Rubio E, Poca M-A, Rovira A, Rodriguez-Baeza A, Cervera C. Posterior fossa reconstruction: A surgical technique for the treatment of Chiari I malformation and Chiari I/syringomyelia complex—preliminary results and magnetic resonance imaging quantitative assessment of hindbrain migration. Neurosurgery. 1994;**35**(5):874-885