

We are IntechOpen, the world's leading publisher of Open Access books Built by scientists, for scientists

6,900

Open access books available

185,000

International authors and editors

200M

Downloads

Our authors are among the

154

Countries delivered to

TOP 1%

most cited scientists

12.2%

Contributors from top 500 universities



WEB OF SCIENCE™

Selection of our books indexed in the Book Citation Index
in Web of Science™ Core Collection (BKCI)

Interested in publishing with us?
Contact book.department@intechopen.com

Numbers displayed above are based on latest data collected.
For more information visit www.intechopen.com



Neuronavigated and Laparoscopic-Assisted Ventriculoperitoneal Shunt Placement

Sarah Wilson, Michael Crozier and Antonios El Helou

Abstract

Hydrocephalus is an abnormal accumulation of excess cerebrospinal fluid (CSF) in the brain causing increased intracranial pressure, which can arise from a variety of causes, including congenital, acquired, or idiopathic pathologies. Ventriculoperitoneal (VP) shunting is most commonly used to treat hydrocephalic patients, relieving the increased intracranial pressure by draining excess CSF from the ventricles to the peritoneal cavity. VP shunts are primarily completed using either an open or a more minimally invasive neuronavigated laparoscopic-assisted surgical technique. There is a high level of surgical complications, shunt failures and revision rates following VP shunting. It is suggested that different surgical techniques are associated with varying degrees of patient outcomes, surgical complications, and revision rates, with the less invasive laparoscopic-assisted approach producing improved results. We present our results on 14 consecutive hydrocephalic patients, analyzed retrospectively between 2017 and 2019, investigating the benefits offered by the neuronavigated laparoscopic-assisted insertion of VP shunts. Additionally, we explain our workflow and procedural technique. By investigating these differences, changes can be implemented in current routine procedures to ameliorate patient safety, surgical complications, and revision rates.

Keywords: hydrocephalus, ventriculoperitoneal shunt, laparoscopy, neuronavigation, complications, shunt failure, revision rates

1. Introduction

Hydrocephalus is a pathological accumulation of cerebrospinal fluid (CSF) in the ventricular system due to abnormal production, flow, or absorption of CSF [1]. The buildup of CSF increases the intracranial pressure (ICP), producing a variety of neurological defects concurrent with ventriculomegaly [2]. Arising from multiple congenital, acquired and idiopathic pathologies, hydrocephalus can ultimately lead to brain damage in the compressed tissues if left untreated [3, 4].

Hydrocephalus is primarily treated using a shunt system, draining the excess CSF from the cerebral ventricles into another region of the body where it can be absorbed. The peritoneal cavity remains the preferred drainage site in both pediatric and adult populations, accessed using a ventriculoperitoneal (VP) shunt [5].

Other surgical treatment options include third ventriculostomies and alternative shunt types [6] such as ventriculoatrial (VA), ventriculopleural, ventriculocisternal, and lumboperitoneal [7].

2. Ventriculoperitoneal shunt

VP shunts are comprised of a proximal inflow catheter, reservoir, valve mechanism, and a distal outflow catheter. The proximal catheter generally lies in the trigone of the lateral ventricle; however it can be inserted in the frontal horn if it follows an internalization of an external ventricular drain. The proximal catheter leads into the reservoir, which contains a small collection of CSF used for samples or to obtain pressure measurements. A retro-auricular unidirectional valve follows the reservoir and is responsible for controlling the flow of CSF into the distal catheter. The distal catheter then travels subcutaneously from the valve into the right upper abdominal quadrant where the excess CSF can freely drain into the peritoneal cavity [4, 8].

Although a commonly relied upon procedure to treat hydrocephalus, VP shunts are not without complications and failures. VP shunts are subject to a variety of complications of mechanical, functional, and infectious nature [6]. Mechanical complications consist of complications inhibiting the shunt from functioning, including shunt migration, obstruction, malpositioning, disconnection, and fracture. Contrarily, functional complications involve improperly functioning shunts such as overdrainage or underdrainage [6]. Finally, shunts are subject to various infections, the majority arising from normal skin flora and occurring within 30 days of surgery [3]. Current studies suggest an overall infection rate of 8.4% and a shunt failure rate, defined as a catheter-related problem necessitating surgical intervention [9], of 51.4% [10]. It has been shown that patients require 2–3 surgical revisions on average due to shunt failures in the 20 years after the original shunt placement [8], with the majority of shunt revisions occurring in the first 6–12 months [4, 8]. Specifically, 25–30% of all shunt revisions result from distal peritoneal catheter failure [5, 11, 12], such as preperitoneal placement, obstruction due to adhesions or pseudocysts, and malabsorption with secondary ascites [12].

3. Ventriculoperitoneal shunt: challenges

With time, the frequent revision rates and complications have provoked multiple changes and advancements in both VP shunt equipment, including the catheters and valve mechanisms [9, 13], as well as the surgical procedure itself [9]. Traditionally, VP shunts have been inserted using mini-laparotomy, although recently, a neuronavigated laparoscopically assisted approach has become a more commonly accepted surgical technique [9, 14]. Multiple studies have demonstrated that relative to the mini-laparotomy technique, a laparoscopically assisted approach has a shorter operative time and length of stay in the hospital, a decreased distal shunt failure rate [4, 9, 14], and a decreased risk of visceral injury [10]. Laparoscopy has also been shown to offer favorable outcomes with smaller incisions leading to reduced post-operative pain [11], faster mobilization and a preferred cosmetic appearance [5]. Many of the proposed benefits associated with laparoscopic-assisted VP shunts are a direct result of the increased visualization offered by laparoscopy. Laparoscopy allows for the verification of accurate peritoneal placement of the distal catheter as well as the proper functioning of the shunt by observing CSF outflow [5]. Laparoscopy can also be used to perform adhesiolysis, useful in the presence of excess adhesions, often found in patients who have undergone previous

abdominal surgeries [11]. As shunt obstruction can commonly result from the distal catheter becoming lodged in a collection of adhesions, adhesiolysis offers a potential solution to prevent this from occurring, reducing complications and future shunts failures. Additionally, the mini-laparotomy approach has been associated with increased risks of post-operative hernia formation and adhesion formation [4]. Neuronavigation has also been shown to increase the accuracy of ventricular placement of the proximal catheter resulting in a decrease in proximal shunt revisions [15, 16]. However, as most neurosurgeons do not possess the necessary laparoscopy skill, collaboration with a general surgeon is required for the laparoscopic-assisted approach [4]. Incorporating a second surgeon may elicit difficulties in scheduling, requiring that both surgeons be available at given times [17].

Due to the high revision rates for VP shunts as well as the personal and medical burden of the complications and associated revisions, current practices must be assessed for alterations to improve these outcomes. Neuronavigated laparoscopic-assisted VP shunt placement is being regarded as a minimally invasive alternative to an open technique to improve surgical complications and patient outcomes.

4. Surgical technique

The procedure is done under general anesthesia, in the supine position with the head turned 30–45° toward the left, as right trigone is favored for the insertion of the ventricular catheter. The left upper limb is in abduction with the shoulder at 90°, and the right upper limb is tucked against the body. First generation cephalosporin is administered 30–60 minutes before incision. The neuronavigation magnetic system (Axiem, on Stealth by Medtronic) is used with 3D reconstruction of preoperative brain CT scan. Entry point, trajectory and length of insertion are defined on the navigation system. A Foley catheter is not used, as the risk of bladder injury is lowered by laparoscopic approach, which in turn reduces the post-operative UTI risk. A retro-auricular shaving for horizontal 2 cm incision or question mark incision is done. Scrubbing with chlorhexedine 2% is done at the cranial level and over the neck, chest and abdomen. Draping from the scalp to the pubic level is done in sterile fashion.

4.1 Tunneling of the peritoneal catheter

Starting at the scalp, an incision is made, dissection of the galea until reaching the entry point. Dissection of the subcutaneous cranio-cervical tissue is done.

A 60–90 cm passer is used from the scalp to the right upper quadrant (RUQ). The peritoneal catheter is tunneled through the passer and 5 mm incision is done at the RUQ. An anti-siphon programmable or pre-fixed pressure valve is connected to the peritoneal catheter.

4.2 Placement of ventricular catheter

The ventricular catheter is inserted using the navigation stylet until reaching the body of the right lateral ventricle. CSF is drained and a sample for culture is routinely sent. Ventricular catheter is connected to the valve and CSF flow through the valve to the peritoneal catheter is observed before peritoneal insertion of the catheter.

4.3 Placement of abdominal catheter

Laparoscopic approach to the peritoneum is done by the general surgeon. A supra-umbilical, longitudinal incision is incised through skin with the scalpel blade.

The incision may be altered due to previous surgery and concern for adhesions. Generally, we will go through old incisions using the supra-umbilical technique, but an infra-umbilical or epigastric open technique can be used as well. The fascia is elevated between two Kocher instruments and divided with scalpel blade. The peritoneum is divided between two snap instruments with scalpel blade. A finger is inserted into the abdomen to ensure adhesions are clear of the undersurface of the abdominal wall. Previous surgery and/or adhesions are not a contra-indication to this technique. Adhesions may be taken down carefully from the undersurface of the abdominal wall to allow placement of the laparoscopic balloon port. A 5–10 mm laparoscopic balloon port is placed intra-abdominally and the abdomen insufflated.

We maintain medium flow (20–30 L/min) and pressures (15 mmHg) for all cases. A 5 mm, 30-degree camera is inserted into the abdomen and used to visualize the undersurface of the abdominal wall. Placement of the catheter was generally in the RUQ but was also placed in left upper quadrant (LUQ) depending on adhesions from previous surgeries or due to the presence of previously placed shunts. At times we did navigate through heavy adhesions to guide the catheter placement but did not ever need to take down adhesions laparoscopically or add additional trocars for the catheter placement.

After the laparoscopic approach to the peritoneum is done, we approach the abdomen by a puncture using an introducer sheath and dilator (Arrow®). The catheter and CSF flow is observed in the peritoneal cavity. Once the shunt is placed the sheath is removed and skin closed with 4-0 subcuticular monocryl stitch.

After final satisfactory inspection of the abdomen is desufflated and the camera and laparoscopic balloon port removed. Fascia is closed with a purse-string 0-PDS suture. Skin is closed with a 4-0 subcuticular monocryl stitch. Incisions are infiltrated with 0.5% Marcaine with epinephrine. Steristrips and dry dressings are applied.

Following the completion of the laparoscopic portion of the procedure, the scalp closure is done in 2 layers and the entry point to the abdomen is closed in 1 layer.

Patient is awakened extubated and transferred to recovery room. Once fully awake, patient is transferred to the floor; diet is started at 6 hours post operatively in addition to increasing activity.

5. Methods

Fourteen consecutive hydrocephalic patients were treated with neuronavigated laparoscopically assisted VP shunts to explore the benefits offered by this surgical technique. Patient charts were collected retrospectively from February 2017 to March 2019. Collected charts were analyzed to obtain sex, age, BMI, indication for surgery, and whether the patient had a prior shunt placement or previous abdominal surgeries. Additionally, to assess the advantages of the neuronavigated laparoscopically assisted technique the variables collected were length of stay in hospital after surgery, operative time, intra- and post-operative complications, infection, and whether the shunt failed. No patients were excluded from this study. All surgeries were performed at the same institution by the same neurosurgeon and general surgeon. Clinical and radiological follow-up is done at 6-weeks post-operatively. The shunt series is used to evaluate the position of the shunt system and a brain CT is done to rule out over drainage (**Figure 1**).

The shunt series X-rays includes skull with an antero-posterior and lateral view, an antero-posterior chest x-ray and an antero-posterior abdominal x-ray.

The abdominal x-ray is repeated at 60 minutes to evaluate the peritoneal part of the shunt and its mobility (**Figure 2**).

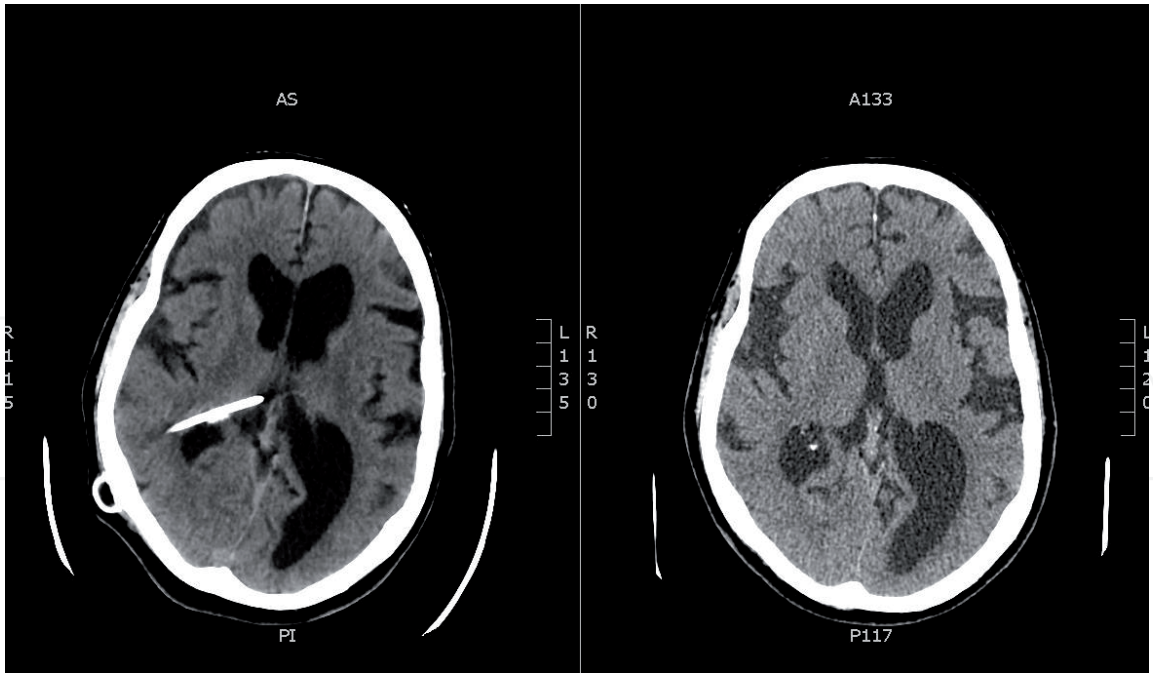


Figure 1.
Pre (left) and post (right) operative brain Ct scan with ventricular catheter in the body of the right lateral ventricle.

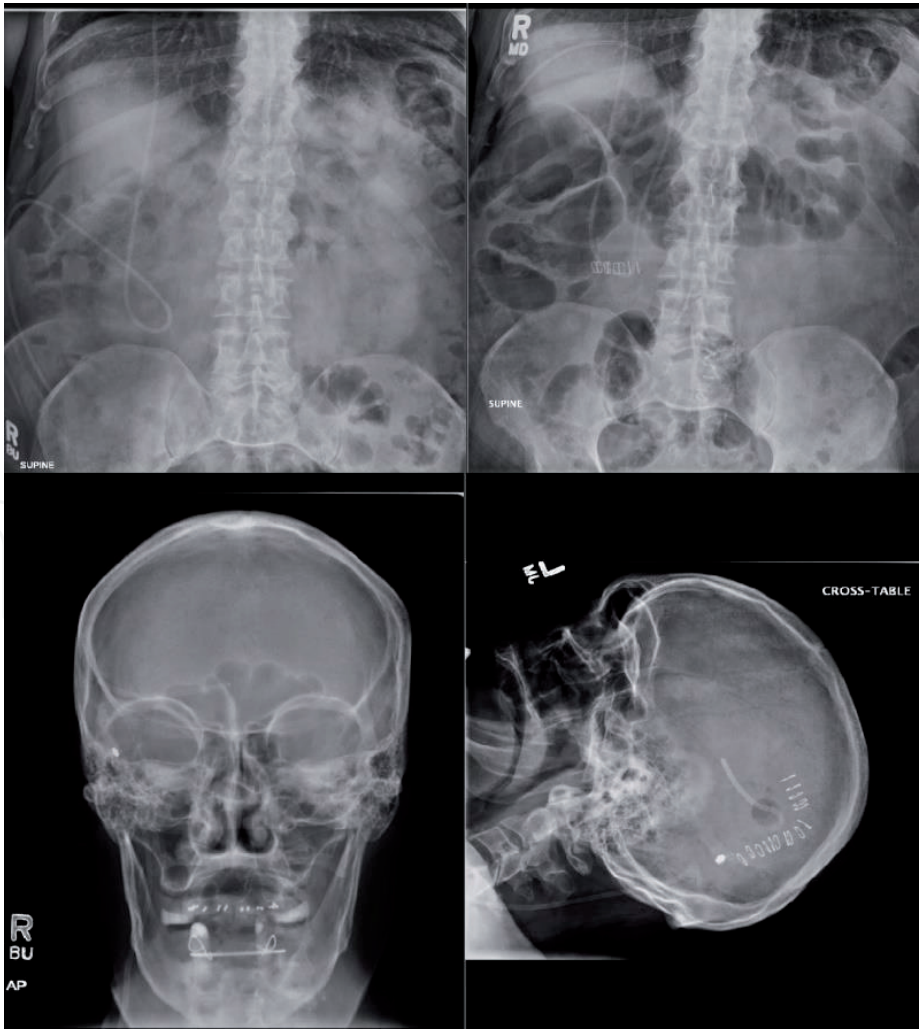


Figure 2.
Top Abdominal X-ray at day 1 (left) and at 3 months follow up (right) showing good peritoneal catheter mobility. Bottom Lateral skull X-ray (left) and Antero-posterior view (right) showing the ventricular catheter and programmable valve.

6. Results

There were 14 patients in total who received a ventriculoperitoneal shunt placement using a neuronavigated laparoscopic-assisted approach. The mean age of patients at the time of surgery was 56.8 years, although ranged from 31 to 78. There were 11 females and three males in the group. Eleven patients received a new VP shunt placement, whereas three patients were undergoing shunt revision. All patients except for one had undergone at least one previous abdominal surgery, with many of the patients having experienced multiple abdominal surgeries. Of note is the average BMI of the group being 31.2. Only one patient was within the normal range with a BMI of 24.6, one patient was classified as underweight at 14.6, four patients were considered overweight, and the remaining eight patients were obese with a BMI above 30.

Patients required a VP shunt for a variety of indications, with idiopathic normal pressure hydrocephalus (NPH) being the most common, occurring in half of the patients. Other indications included obstructive hydrocephalus secondary to a ventricular tumor, NPH secondary to subarachnoid hemorrhage (SAH), idiopathic intracranial hypertension, and a revision of the shunt for subependymal hemorrhage at birth. Average operative time for the VP shunt placements was approximately 45 minutes but ranged from 35 to 90 minutes. Patients on average stayed in the hospital for 2.25 days after the surgery, however, over 40% of patients were discharged after a single day in the hospital, 2/3 had left by 2 days, and all but one patient had left the hospital at 3 days. Two patients were not discharged from the hospital due to other medical conditions unrelated to the VP shunt placement and were therefore excluded from this calculation. There were no intraoperative complications that occurred, however it is worth noting that there were many patients with extensive abdominal adhesions due to previous abdominal surgeries, as well as the extra difficulty presented by the increased rate of obesity in the patient group.

Three patients experienced post-operative complications. One patient's shunt became infected with *Staph epidermis*, another patient experienced a functional complication of overdrainage with symptomatic bilateral subdural hematomas, requiring the removal of the shunt and drainage of the subdural hematomas. The remaining patient experienced mechanical dysfunction of the shunt. Each patient with a post-operative complication led to a shunt failure necessitating a shunt revision. The latter patient first underwent a proximal revision to replace both the ventricular catheter and the valve, due to valve malfunction. This same patient eventually experienced peritoneal complications requiring two distal shunt revisions on separate occasions. Following the second peritoneal complication, the patient decided to obtain a VA shunt insertion, which continues to offer successful treatment.

7. Discussion

VP shunts are one of the most common neurosurgical procedures performed [3]. Despite its widespread use and successes in the treatment of hydrocephalus, there are often complications and failures. This has encouraged the ongoing development of alternative procedural techniques producing better outcomes [5]. The cost associated with VP shunts produces a significant medical burden, which is only furthered by the numerous complications and shunts revisions following the initial surgery. Shunt revisions account for approximately 50% of all shunt-related costs and admissions [5, 12]. By decreasing the amount of shunt revisions and complications, both the medical and personal burden of VP shunts will greatly improve. The

neuronavigated laparoscopic-assisted VP shunt placement performed in this study offers a safe and effective technique, bringing numerous benefits not seen with the traditional mini-laparotomy method.

The length of stay in the hospital followed a similar trend to other studies with most patients being discharged in the first 24 hours [18]. The more minimally invasive technique decreases the length of stay in the hospital as well as prompts a faster recovery rate [9, 14]. This allows for less resource use by individual patients and increased patient satisfaction by leaving the hospital soon after surgery and returning to regular activities faster than with the mini-laparotomy technique [9, 11, 14].

Of the most noteworthy benefits of a laparoscopic-assisted neuronavigated technique is the decreased proximal and distal revision rates. The decreased revision rates are largely due to the avoidance of catheter malposition during placement. The accuracy of ventricular [16, 17] and peritoneal [4, 14, 17] catheter placement has increased as a result of clear visualization of the placement in the proper anatomical locations. Once properly positioned, the laparoscopic approach helps prevent migration of the distal catheter because of the fewer abdominal incisions and the smaller peritoneal wall defect [10]. The decreased revision rates can be seen in our patient population, as only a single patient required a distal revision for shunt malposition as a result of peritoneal adhesions, as well as a ventricular repositioning due to a valve dysfunction. Additionally, the increased visualization offered by this technique can be used to confirm CSF outflow through the VP shunt, indicating a properly functioning shunt, before finishing surgery.

This technique should also be heavily considered for obese individuals as well as those who have undergone previous abdominal surgeries [12], the two patient populations demonstrating the highest number of distal complications with VP shunt placements [5]. Both obesity and peritoneal adhesions resulting from abdominal surgeries pose difficulties with visualization during surgery, which leads to improper placement of shunts and increased complications and shunt failures. Further advantages come with adhesiolysis that can be performed during laparoscopy, creating a clearer visualization for those with previous abdominal surgeries as well as preventing obstruction of the distal catheter by placing it within the peritoneal adhesions [4, 9].

There have been concerns over the laparoscopic-assisted approach to VP shunts in that they require two surgical teams and specific instrumentation, increasing the cost of the surgery [5, 9] as well as the difficulty of scheduling, especially for emergent cases [17]. However, with the countless benefits being demonstrated by laparoscopy and neuronavigation, it should be considered that the mentioned concerns are outweighed.

Our study has limitations, specifically in the small sample size and the surgeries all being performed by the same surgeons. It is possible that results could differ based on the level of expertise of a surgeon. General surgeons performing laparoscopy often will have more experience with adhesions and distorted anatomy as well as neurosurgeons using neuronavigation more often will gain more expertise. It has been suggested that neurosurgeons should be trained on laparoscopy in the future to both avoid the influence of the general surgeon's expertise and to prevent potential scheduling conflicts when organizing two surgical teams [9].

Advancements are continuing to be made in VP shunts technology and procedures. All advancements are aimed at continuing the improvement of patient outcomes and lifting the imposed medical and personal burden of VP shunts. Recently, there have been some new advancements in techniques including a percutaneous minimal access insertion without the use of laparoscopy, as well as a single-port laparoscopic surgery that show further promise in optimizing patient care and routine practices [19, 20].

8. Conclusion

Surgical management of hydrocephalus using neuronavigated laparoscopic-assisted VP shunt placements is becoming a widely accepted alternative to the traditional mini-laparotomy approach. This technique offers a safe, effective, and minimally invasive approach for VP placements in hydrocephalic patients. It provides accurate insertion of both the ventricular and peritoneal catheter, resulting in decreased complications of mechanical, functional, and infectious origin, as well as revision rates. As much of VP shunt-related costs result from shunt revisions, any technical advancements made to reduce revision rates will help alleviate the medical and financial burden associated with this common neurosurgical procedure. This technique should also be considered in more difficult patient cases involving obesity and extensive peritoneal adhesions from previous abdominal surgeries. The benefits offered by the neuronavigated laparoscopic-assisted approach are numerous and seem to outweigh any concerns surrounding this technique. This particular surgical approach should be considered in adjusting current routine practices, resulting in optimal care for hydrocephalic patients and decreasing VP shunt-related medical costs.

Acknowledgements

We would like to acknowledge the Dalhousie Medical Research Foundation (DMRF) Lalia B. Chase Studentship that allowed for the medical student to participate in this research.

Conflict of interest

All authors have no conflict of interest.

Author details

Sarah Wilson¹, Michael Crozier² and Antonios El Helou^{3*}

¹ Dalhousie Medical School, New Brunswick, Canada

² Department of General Surgery, The Moncton Hospital, Horizon Health Network, Moncton, New Brunswick, Canada

³ Department of Neurosurgery, The Moncton Hospital, Horizon Health Network, Moncton, New Brunswick, Canada

*Address all correspondence to: dr.antonios.elhelou@horizonnb.ca

IntechOpen

© 2019 The Author(s). Licensee IntechOpen. This chapter is distributed under the terms of the Creative Commons Attribution License (<http://creativecommons.org/licenses/by/3.0>), which permits unrestricted use, distribution, and reproduction in any medium, provided the original work is properly cited. 

References

- [1] Rekate HL. A contemporary definition and classification of hydrocephalus. *Seminars in Pediatric Neurology*. 2009;**16**(1):9-15
- [2] Shaw R, Everingham E, Mahant N, Jacobson E, Owler B. Clinical outcomes in the surgical treatment of idiopathic normal pressure hydrocephalus. *Journal of Clinical Neuroscience*. 2016;**29**:81-86
- [3] Gutierrez-Murgas Y, Snowden JN. Ventricular shunt infections: Immunopathogenesis and clinical management. *Journal of Neuroimmunology*. 2014;**276**(1-2):1-8
- [4] Phan S, Liao J, Jia F, Maharaj M, Reddy R, Mobbs RJ, et al. Laparotomy vs minimally invasive laparoscopic ventriculoperitoneal shunt placement for hydrocephalus: A systematic review and meta-analysis. *Clinical Neurology and Neurosurgery*. 2016;**140**:26-32
- [5] Dehcordi SR, De Tommasi C, Ricci A, Marzi S, Ruscitti C, Amicucci G, et al. Laparoscopy-assisted ventriculoperitoneal shunt surgery: Personal experience and review of the literature. *Neurosurgical Review*. 2011;**34**(3):363-371
- [6] Nguyen TA, Cohen PR. Scalp necrosis overlying a ventriculoperitoneal shunt: a case report and literature review. *Dermatology Online Journal*. 2015;**21**(10). Retrieved from: <https://escholarship.org/uc/item/2rs544f9>
- [7] Hung CC, Chuang HY, Lin HL, Chu YT, Cheng CH. Intramuscular migration of venous catheter as a rare complication of Ventriculoatrial shunt: Case report and literature review. *Journal of Neurological Surgery Part A: Central European Neurosurgery*. 2017;**78**(04):412-416
- [8] Bates P, Rajderkar D. Common and uncommon causes of ventriculoperitoneal shunt malfunction diagnosed on plain radiographs. *Current Problems in Diagnostic Radiology*. 2018;**47**(5):317-323
- [9] He M, Ouyang L, Wang S, Zheng M, Liu A. Laparoscopy versus mini-laparotomy peritoneal catheter insertion of ventriculoperitoneal shunts: A systematic review and meta-analysis. *Neurosurgical Focus*. 2016;**41**(3):E7
- [10] Rigante L, Navarro R, Roser F. Minimal exposure maximal precision ventriculoperitoneal shunt: How I do it. *Acta Neurochirurgica*. 2019;**161**(8):1619-1622
- [11] Hanna RS, Essa AA, Makhoulf GA, Helmy AA. Comparative study between laparoscopic and open techniques for insertion of Ventriculoperitoneal shunt for treatment of congenital hydrocephalus. *Journal of Laparoendoscopic & Advanced Surgical Techniques*. 2019;**29**(1):109-113
- [12] Roth J, Sagie B, Szold A, Elran H. Laparoscopic versus non-laparoscopic-assisted ventriculoperitoneal shunt placement in adults. A retrospective analysis. *Surgical Neurology*. 2007;**68**(2):177-184
- [13] Ros B, Iglesias S, Martín Á, Carrasco A, Ibáñez G, Arráez MA. Shunt overdrainage syndrome: Review of the literature. *Neurosurgical Review*. 2018;**41**(4):969-981
- [14] Naftel RP, Argo JL, Shannon CN, Taylor TH, Tubbs RS, Clements RH, et al. Laparoscopic versus open insertion of the peritoneal catheter in ventriculoperitoneal shunt placement: Review of 810 consecutive cases. *Journal of Neurosurgery*. 2011;**115**(1):151-158
- [15] Gilard V, Magne N, Gerardin E, Curey S, Pelletier V, Hannequin P, et al. Comparison of electromagnetic neuronavigation system and free-hand

method for ventricular catheter placement in internal shunt. Clinical Neurology and Neurosurgery. 2017;**158**:93-97

[16] Wilson TJ, McCoy KE, Al-Holou WN, Molina SL, Smyth MD, Sullivan SE. Comparison of the accuracy and proximal shunt failure rate of freehand placement versus intraoperative guidance in parietooccipital ventricular catheter placement. Neurosurgical Focus. 2016;**41**(3):E10

[17] Fahy AS, Tung S, Lamberti-Pasculli M, Drake J, Kulkarni A, Gerstle JT. Laparoscopic revision of Ventriculoperitoneal shunts in pediatric patients may result in fewer subsequent peritoneal revisions. Journal of Laparoendoscopic & Advanced Surgical Techniques. 2019;**29**(1):82-87

[18] Turner RD, Rosenblatt SM, Chand B, Luciano MG. Laparoscopic peritoneal catheter placement: Results of a new method in 111 patients. Operative Neurosurgery. 2007;**61**(3):161-167

[19] Hong WC, Lai PS, Chien YH, Tu YK, Tsai JC. Single-incision laparoscopic surgery (SILS) for ventriculoperitoneal shunt placement. Journal of Neurological Surgery Part A: Central European Neurosurgery. 2013;**74**(06):351-356

[20] Ochalski PG, Horowitz MB, Mintz AH, Hughes SJ, Okonkwo DO, Kassam AB, et al. Minimal-access technique for distal catheter insertion during ventricular peritoneal shunt procedures: A review of 100 cases. Journal of Neurosurgery. 2009;**111**(3):623-627