

We are IntechOpen, the world's leading publisher of Open Access books Built by scientists, for scientists

6,900

Open access books available

186,000

International authors and editors

200M

Downloads

Our authors are among the

154

Countries delivered to

TOP 1%

most cited scientists

12.2%

Contributors from top 500 universities



WEB OF SCIENCE™

Selection of our books indexed in the Book Citation Index
in Web of Science™ Core Collection (BKCI)

Interested in publishing with us?
Contact book.department@intechopen.com

Numbers displayed above are based on latest data collected.
For more information visit www.intechopen.com



Liver Changes in the Course of Cystic Fibrosis

Sabina Wiecek

Abstract

Liver damage observed in cystic fibrosis is a complicated process comprised of fibrogenesis, inflammation, remodeling, apoptosis, and cholestasis. Complexity of processes which take place in the liver and bile ducts in the course of this disease are not clearly defined. Changes in the liver are observed in 5–20% of patients with diagnosed cystic fibrosis; however they can increase mortality, shorten time of life, and deteriorate quality of life. The aim of the chapter was to review the risk factors, clinical symptoms, diagnostic methods, and treatment of liver changes in the course of cystic fibrosis.

Keywords: liver, cystic fibrosis

1. Introduction

Hepatic lesions concern only 5–20% of patients with diagnosed cystic fibrosis. However they increase the level of fatalities, shorten the survival rate, and impair the quality of life. Liver diseases are the most common, non-pulmonary cause of death among patients with cystic fibrosis. They most often occur in the first decade of life. Cirrhosis is detected in about 10% of CF children under the age of 18 compared to 2% of adults with the same condition. The average age of the CF liver disease manifestation is about 10 years [1–7].

1.1 Etiopathogenesis of liver's change in patients with cystic fibrosis

Liver and bile duct diseases are a combination of complex processes of fibrosis, inflammation, remodeling, apoptosis, and cholestasis. They are a consequence of the abnormal functioning of the CFTR protein, immunologic reactions, and response to oxidative stress [5, 8–11].

1.1.1 Pathophysiological changes to the bile acids in the course of cystic fibrosis

The important roles played by the pathophysiological changes of the bile duct include changes to the components of the bile (abnormal water and electrolyte contents and change to the pH of the bile) and changes to the profile of bile acids—to hydrophobic, abnormal transport of the bile, retention of toxic bile acids (taurocholic acid), and induction of pro-inflammatory chemokines which influence on biliary fibrogenesis. Factors contributing to the processes of precipitation of bile acids in the bile ducts include decreased synthesis of the salts of the bile acids, decreased absorption of bile acids from the lumen of the small intestine, and

narrowing of the bile ducts impairing the outflow of the bile from the liver to the lumen of the duodenum [5, 8, 10].

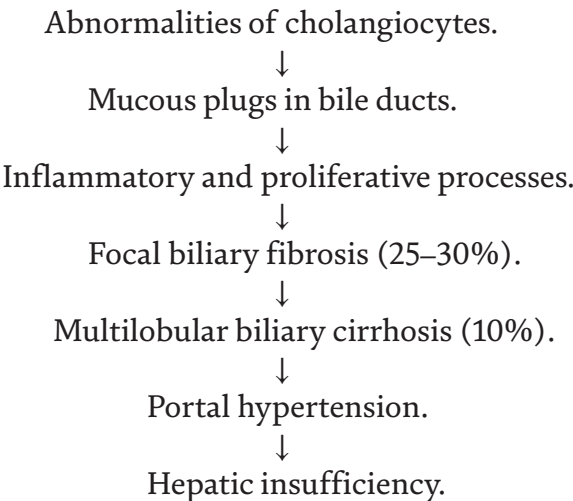
1.1.2 Genetic factors

So far, no specific mutation relating solely to liver damage in the course of cystic fibrosis has been discovered. Most commonly, these are the so-called “serious mutations” of the CFTR gene (delta F508, G524X, N1303K, CFTRdel21kB, 1811 + 1G- > C). The delta F508 mutation plays a particular role in the development of hepatic lesions in the course of cystic fibrosis due to its stimulation of an increased loss of bile acids with stools and the fact that it leads to the formation of more hydrophobic bile acids. Hepatic lesions co-occurring with cystic fibrosis in patients with the 3849 + 10kB C- > T mutation have not yet been the subject of interest. However, the clinical course in patients with diagnosed cystic fibrosis and the same mutation of the CFTR gene tends to vary. There is no strict phenotype-genotype correlation. The role of the SERPINE1 mutation: it occurs in about 2% of the patients with cystic fibrosis and in about 5% of the patients with cystic fibrosis and co-occurring hepatic lesions. Responsible for the synthesis of the inhibitor of serine protease. The protein connected to allele Z is concentrated within the endoplasmic reticulum of hepatocytes leading to their damage, inflammation, and cirrhosis. In about 10% of allele Z homozygotes, the accumulation of the SERPINA gene protein leads to neonatal hepatitis and in 2–3% of cases to fibrosis and cirrhosis. In pathogenesis some genes were suspected as a factor inducing pathological processes in the liver and bile duct in patients with cystic fibrosis (gene of plasminogen activator inhibitor type 1, genes relating to metalloproteinases, P1 glutathion s-transferase gene, transforming growth factor beta gene, uridylyltransferase gene (UGT1A1)). But the role is not strictly confirmed [12–17].

1.1.3 Immunological factors

Chemokines play a role as an activator of stellate cells (source: hepatic macrophages, endothelial cells, bile duct epithelial cells, lymphocytes, blood platelets, and hepatocytes). The main chemokines are monocyte chemoattractant protein-1 (MCP1), macrophage inflammatory protein-1 beta (MIP1B), TGF-beta, TNF-alpha, platelet-derived growth factor (PDGF), and interleukins IL-1, IL-6, and IL-10 [11, 18–23].

Pathogenesis of hepatic lesions the course of cystic fibrosis according to Colombo [1, 2, 8].



1.2 Organ lesions contributing to the manifestation of CFLD

In the examination of Wilchanski et al., the presence of hepatic lesions (cystic fibrosis liver damage (CFLD)) was concluded in 28% (80/288) of CF patients. All patients with hepatic lesions were diagnosed with pancreatic insufficiency. No correlation between the occurrence of hepatic lesions and pulmonary lesions, respiratory insufficiency, the level of malnutrition, meconium ileus, and/or distal intestinal obstruction syndrome (DIOS) was concluded [24]. Lindblad observed meconium ileus in only 12% of CF patients, out of whom only 6/15 patients with meconium ileus had the symptoms of liver damage [6]. Siano did not prove the correlation between the occurrence of hepatic lesions in the course of cystic fibrosis and the pancreatic efficiency and the level of nutrition. In 2–5% of patients, focal biliary cirrhosis develops into multilobular cirrhosis [25].

1.2.1 Nutritional factors

Malnutrition influences on liver function in children with cystic fibrosis. Children with diagnosed cystic fibrosis and liver damage have lower body mass, height, circumference of the upper arm, and BMI. Patients with cystic fibrosis also have significantly lower levels of linoleic (LA), docosahexaenoic (DHA), and docosapentaenoic (DPA) acids. The influence of parenteral nutrition and antioxidant and vitamin deficiency is confirmed [26–29]. Sometimes in children with cystic fibrosis especially with meconium ileus, total parenteral nutrition is necessary. Total parenteral nutrition (TPN) therapy is a well-recognized cause of liver injury. The histologic changes attributed to TPN in the literature vary widely. Total parenteral nutrition-induced liver disease develops in 40–60% of infants who require long-term TPN. The clinical spectrum includes cholestasis, cholelithiasis, hepatic fibrosis with progression to biliary cirrhosis, and the development of portal hypertension and liver failure in a significant number of children who are totally parenterally fed. The pathogenesis is multifactorial and is related to prematurity, low birth weight, and duration of TPN. The degree and severity of the liver disease are related to the recurrent sepsis including catheter sepsis, bacterial translocation, and cholangitis. The lack of enteral feeding leading to reduced gut hormone secretion, reduction of bile flow, and biliary stasis may be important mechanisms in the development of cholestasis, biliary sludge, and cholelithiasis.

1.2.2 The role of medications

In patients with cystic fibrosis, abnormal functions of oxidases and P450, CYP2C8, CYP2C9, and CYP3A4 cytochromes are observed. The dose of beta-lactam should be reduced by 20%. The doses of aminoglycosides should be decided upon depending on the level of the medication in the blood serum. Increased microsomal metabolism relating to theophylline and methylxanthine through the affected first phase of the biotransformation of the medications. Increased hepatic clearance of the second phase, which may be reflected in the abnormal metabolism of furosemide, lorazepam, and ibuprofen [30–32].

1.2.3 Defects of the gall bladder and bile ducts

In about 30% of patients with cystic fibrosis, atrophic gall bladder, or the lack thereof, also its defects and/or of bile ducts is reported. No correlation between cirrhosis and abnormalities in the gall bladder and/or bile ducts has been observed. Gallbladder hydrops and lithiasis are more commonly observed in patients with

cystic fibrosis than the healthy population. The narrowing of the distal regions of the bile ducts is frequent and may occur in even 90% of CF patients and contribute to the formation of gallstones [33, 34].

1.2.4 Cholelithiasis

Cholelithiasis concerns 14–24% of CF patients. The following play a role in the pathogenesis of the formation of gallstones: abnormal bile content, increased excretion of bile acids with stools, and the formation of lithogenic bile where bile acids are interlocked with glycine. No correlation between the formation of gallstones and supplementation with pancreatic enzymes has been confirmed [1, 3, 22].

Risk factors for the development of liver diseases in cystic fibrosis:

1. Male gender—three fourths of patients with CFLD are male. Protective role of estrogens in female.
2. Coexisting meconium ileus (inconsistent data—from a five-time higher risk of developing hepatic lesions to a similar risk). Only 25% of patients with CFLD who had meconium ileus in the medical interview was identified. Meconium ileus is not a prerequisite for CFLD. Probably, parenteral nutrition is an additional factor.
3. Significant undernourishment.
4. Pancreatic insufficiency.
5. Severe genotype (delta F508) [1, 12, 24, 35, 36].

1.3 Clinical picture

In most CF patients, the course of hepatic complications is symptomless. Pruritus sometimes occurs and jaundice in patients whose condition is advanced. Incidental finding of hepatomegaly is usually the first sign. In newborns, steatosis may be incidentally discovered in a routine abdominal ultrasound.

Clinical changes of the liver in patients with cystic fibrosis:

1. Focal hepatic fibrosis (72%)
2. Focal biliary cirrhosis (20–30%)
3. Multilobular biliary cirrhosis (5–15%)
4. Portal hypertension (2–5%)
5. Small atrophic gallbladder and narrowing of bile ducts (15–45%)
6. Cholelithiasis (14–24%)
7. Steatosis (25–60%)
8. Cholestasis in newborns (<10%)
9. Primary sclerosing cholangitis (rarely)

10. Cholangiocarcinoma (rarely)

11. Drug-induced, toxic liver damage [1, 3, 12, 24, 37–40]

1.3.1 Laboratory tests

1.3.1.1 Periodic laboratory tests

The levels of AlAT, AspAT, GGTP, bilirubin and bile acids, the APRI index, and FibroTest are recommended. It is believed that elevated levels of at least two hepatic parameters above the norm within at least 3 months is an indication of advancing hepatic lesions. But they have low sensitivity and specificity. Most patients with multifocal cirrhosis have normal test results. Isolated elevation of aminotransferases with concurrent normal GGTP index may indicate steatosis.

1.3.1.2 Abdominal ultrasound with a Doppler option and elastography

Ultrasound is inexpensive and is a noninvasive test. It allows assessment of the level of steatosis, symptoms of portal hypertension, and cirrhotic transformation of the liver. However, normal imaging of the liver does not exclude the ongoing process of fibrosis.

FibroScan is an effective and noninvasive tool to quantify fibrosis and steatosis in the liver diseases including cystic fibrosis. The stiffness of the liver tissue can be assessed based on shear wave velocity (the stiffness increases with the speed).

1.3.1.3 Liver biopsy with histopathological assessment.

Liver biopsy is an invasive procedure and is prone to side effects and sampling. This is not a routine recommended procedure in patients with CFLD.

1.3.1.4 Noninvasive parameters of liver fibrosis

Fibroindex, aminopeptides of type III procollagen, collagen I, collagen IV, laminine, hyaluronic acid, and/or cytokines and chemokines relating to the process of fibrosis. There are studies on their usefulness in minimally invasive clinical diagnostics [27, 41–48].

1.4 Treatment

1. **Background therapy of cystic fibrosis** include pancreas enzyme supplementation, vitamin supplementation, extensive physiotherapy, and nutritional support,
2. **Diet therapy.** In patients with cystic fibrosis, nutrition and survival are intimately related. Growth failure and body mass deficiency are the prognostic factors in patients with CF. Prevention of undernourishment in cystic fibrosis, sometimes feeding tube or PEG nutrition, is recommended. Hypercaloric diet, which is rich in protein, carbohydrates, and fat, is recommended. The energy needs of patients with CF vary widely and have been stated as 120–150% of those required by healthy individuals of the same age, sex, and size. Reduction of protein only in situation of encephalopathy. Correction of fat-soluble vitamin deficiency is essential. Lower serum levels of vitamin A and E were associated with a higher rate of pulmonary exacerbations and worse liver function.

3. **Ursodeoxycholic acid (UDCA).** UDCA has a cytoprotective effect on the cell membranes of cholangiocytes. It stimulates the secretion of chloride ions through calcium-dependent chloride channel. It reduces the ratio of cholic acid in bile (less than 5%), reduces its synthesis, and lowers its overall volume. It also stimulates cholangiocytes and hepatocytes to secrete. It has antiapoptotic effect and reduces the toxic effects of hydrophobic bile acids.

The dose is 15–20 mg/kg b.m. in two divided doses over 24 hours.

There are only a few clinical trials assessing the effectiveness of ursodeoxycholic acid. There is insufficient evidence to justify its routine use in cystic fibrosis as a preventative measure. Present data suggesting that UDCA should be started before severe liver damage is present as it might be able to prevent the progression of CFLD and has the potential to induce a reversal of fibrosis [1, 2, 4, 40, 49–51].

4. The treatment of portal hypertension should include:

- Beta blockers—mild oesophageal varices in patients without contraindications
- Endoscopic methods for the treatment of severe oesophageal varices [37, 51–53]

5. **Liver transplant.** Advancing dysfunction of the liver, progressing ascites and jaundice, recurrent bleeding from esophageal varices and hepatopulmonary syndrome, and recurring peritonitis and hepatocarcinoma are indications for liver transplantation. MELD/PELD scores are helpful to evaluate the eligibility for liver transplantation. Model for End-Stage Liver Disease (MELD) includes bilirubin level, albumin, and creatinine concentration. Pediatric end-stage liver disease (PELD) consists of age, bilirubin level, INR index, albumin concentration. PELD/MELD score obtained upon admission may be of help to establish the optimal timing for LT evaluation and listing. A higher score correlates with a more critical condition and worse survival.

In patients with cystic fibrosis following isolated liver transplantation, there is an increased risk of pulmonary complications (severe infections). It seems that an FEV1 < 50% was associated with poor outcomes in isolated liver transplantation, and thus patients with poor lung function should be considered for combined lung-liver transplantation. For isolated liver transplantation, if the FEV1 is <40%, patients are listed with their MELD/PELD score plus a 10% mortality equivalence. If listed for a combined liver-lung transplantation with an FEV1 < 40%, the liver listing starts with a MELD of 40 [54, 55]. Simultaneous liver-pancreas transplantation restores exocrine and endocrine pancreatic function in patients with CFLD and enables improved nutritional outcomes concurrent with the potential for discontinuation of insulin and pancreatic enzyme supplementation therapies. Diabetes has been reported to exert a negative effect on the already decreased pulmonary function, observed in CF patients. FEV1 in CF patients with diabetes is markedly reduced in all age groups compared to CF patients without diabetes. Simultaneous liver-pancreas transplantation is associated with an improved BMI in the post-transplant course [56, 57].

The outcome for combined heart/lung/liver grafting in adult people with CF was poor, whereas liver transplantation alone had acceptable waiting times and good survival outcome. High incidence of renal impairment in this group, and in contrast to previous studies, largely in pediatric patients, respiratory function can decline dramatically [55, 58–61].

European recommendations for the treatment of cystic fibrosis and hepatic lesions:

1. Biochemical tests (AlAT, AspAT, GGTP, FA, prothrombin time, blood platelets) every 6 months.
2. Imaging tests—abdominal ultrasound with Doppler option and elastography, alternatively annual CT or MR.
3. Ursodeoxycholic acid at 20 mg/ g daily with divided doses being more effective.
4. Panendoscopy performed every 2–3 years is necessary in patients with cirrhosis and or splenomegaly in order to exclude esophageal varices.
5. Assessment of the hepatopulmonary syndrome—assessment of intrapulmonary shunts as they intensify hypoxemia.
6. In the case of cirrhosis—assessment of the levels of alpha-fetoprotein (AFP) every 6 months.
7. Mild esophageal varices—nonselective beta blockers? Level 2–3 varices—endoscopic treatment or intrahepatic portosystemic shunts.
8. Prevention of undernutrition (via feeding tube or PEG).

2. Summary

1. The etiopathogenesis of hepatic lesions in the course of cystic fibrosis is very complex and not yet fully explained.
2. The clinical symptoms of CFLD are not characteristic, and the clinical picture is often symptomless or limited.
3. Further studies into the causes of hepatic lesions in cystic fibrosis are necessary, which will contribute to the reduction in the number of deaths, extended survival rate, and improvement in patients' quality of life.

IntechOpen

IntechOpen

Author details

Sabina Wiecek

Department of Paediatrics, Medical University of Silesia, Katowice, Poland

*Address all correspondence to: sabinawk@wp.pl

IntechOpen

© 2019 The Author(s). Licensee IntechOpen. This chapter is distributed under the terms of the Creative Commons Attribution License (<http://creativecommons.org/licenses/by/3.0>), which permits unrestricted use, distribution, and reproduction in any medium, provided the original work is properly cited. 

References

- [1] Colombo C. Liver disease in cystic fibrosis. *Current Opinion in Pulmonary Medicine*. 2007;**13**:529-536
- [2] Colombo C, Alicandro G. Liver disease in cystic fibrosis: Illuminating the black box. *Hepatology*. 2019 Apr;**69**(4):1379-1381. DOI: 10.1002/hep.30255
- [3] Herrmann U, Dockter G, Lammert F. Cystic fibrosis-associated liver disease. *Best Practice & Research: Clinical Gastroenterology*. 2010;**24**:585-592
- [4] Kamal N, Surana P, Koh C. Liver disease in patients with cystic fibrosis. *Current Opinion in Gastroenterology*. 2018;**34**(3):146-151
- [5] Guilbault C, Saeed Z, Downey G, et al. Cystic fibrosis mouse model. *American Journal of Respiratory Cell and Molecular Biology*. 2007;**36**:1-7
- [6] Lindblad A, Glaumann H, Strandvik B. Natural history of liver disease in cystic fibrosis. *Hepatology*. 1999;**30**(5):1151-1158
- [7] Lamireau T, Monnerau S, Martin S, et al. Epidemiology of liver disease in cystic fibrosis: A longitudinal study. *Journal of Hepatology*. 2004;**41**:920-925
- [8] Colombo C, Russo M, Zazzeron L, Romano G. Liver disease in cystic fibrosis. *Journal of Pediatric Gastroenterology and Nutrition*. 2006;**43**:49-55
- [9] Elborn J. Cystic fibrosis. *Lancet*. 2016;**388**(10059):2519-2531. DOI: 10.1016/S0140-6736(16)00576-6
- [10] Fiorotto R, Strazzabosco M. Cystic fibrosis-related liver disease: New paradigm for treatment based on pathophysiology. *Clinical Liver Disease*. 2016;**8**(5):113-116. DOI: 10.1002/cld.583
- [11] Pinzani M, Marra F. Cytokine receptors and signaling in hepatic stellate cells. *Seminars in Liver Disease*. 2001;**21**:397-416
- [12] Bartlett J, Friedmann K, Ling S, et al. Genetic modifiers of liver disease in cystic fibrosis. *JAMA*. 2009;**9**:1076-1083
- [13] Boëlle PY, Debray D, Guillot L, Corvol H, et al. SERPINA1 Z allele is associated with cystic fibrosis liver disease. *Genetics in Medicine*. 2019;**21**(9):2151-2155. DOI: 10.1038/s41436-019-0449-6
- [14] Debray D, Corvol H, Housset C. Modifier genes in cystic fibrosis-related liver disease. *Current Opinion in Gastroenterology*. 2019 Mar;**35**(2):88-92. DOI: 10.1097/MOG.0000000000000508
- [15] Freudenberg F, Broderick A, Yu B, et al. Pathophysiological basis of liver disease in cystic fibrosis employing a Delta F508 mouse model. *American Journal of Physiology-Gastrointestinal and Liver Physiology*. 2008;**294**:1411-1420
- [16] Fustik S, Traikovska M, Jakovska T, et al. Screening for liver disease in cystic fibrosis: Analysis of clinical and genetic risk factors for its development. *The Turkish Journal of Pediatrics*. 2008;**50**:526-532
- [17] Khan HH, Mew NA, Kaufman SS, et al. Unusual cystic fibrosis transmembrane conductance regulator mutations and liver disease: A case series and review of the literature. *Transplantation Proceedings*. 2019;**51**(3):790-793. DOI: 10.1016/j
- [18] Bergheim I, Guo L, Davis M, et al. Critical role of plasminogen activator inhibitor – 1 in cholestasis liver injury and fibrosis. *Journal of Pharmacology*

and Experimental Therapeutics. 2006;**316**:592-600

[19] Canbay A, Feldstein A, Baskin-Bey E, et al. The caspase inhibitor IDN-attenuates hepatic injury and fibrosis in the bile duct ligated mouse. *The Journal of Pharmacology and Experimental Therapeutics*. 2004;**308**(3):1191-1196

[20] Weng H, Ciuculan L, Liu Y, et al. Profibrogenetic transforming growth factor- beta/activin receptor like kinase 5 signaling via connective tissue growth factor expression in hepatocytes. *Hepatology*. 2007;**46**:1257-1270

[21] Pereira T, Walsh M, Lewindon P, et al. Paediatric cholestatic liver disease: Diagnosis, assessment of disease progression and mechanisms of fibrogenesis. *World Journal of Gastrointestinal Pathophysiology*. 2010;**15**:69-84

[22] Tanner M, Taylor C. Liver disease in cystic fibrosis. *Archives of Disease in Childhood*. 1995;**72**:281-284

[23] Tsukamoto H. Cytokine regulation of hepatic stellate cells in liver fibrosis. *Alcoholism, Clinical and Experimental Research*. 1999;**23**:911-916

[24] Wilschanski M, Rivlin J, Cohen S, et al. Clinical and genetic risk factors for cystic fibrosis – Related liver disease. *Pediatrics*. 1999;**103**:52-57

[25] Siano M, De Gregorio F, Boggia B, Sepe A, Ferri P, Buonpensiero P, et al. Ursodeoxycholic acid treatment in patients with cystic fibrosis at risk for liver disease. *Digestive and Liver Disease*. 2010;**42**(6):428-431. DOI: 10.1016/j.dld.2009.07.022

[26] Aldamiz-Echevarria L, Prieto J, Andrade F, et al. Persistence of essential fatty acid deficiency in cystic fibrosis despite nutritional therapy. *Pediatric Research*. 2009;**66**:585-589

[27] Ayoub F, Trillo-Alvarez C, Morelli G. Risk factors for hepatic steatosis in adults with cystic fibrosis: Similarities to non-alcoholic fatty liver disease. *World Journal of Hepatology*. 2018;**10**:34-40

[28] Panagopoulou P, Fotoulaki M, Manolitsas A, et al. Adiponectin and body composition in cystic fibrosis. *Journal of Cystic Fibrosis*. 2008;**7**:244-251

[29] Moriconi N, Kraenzlin M, Muller B, et al. Body composition and adiponectin serum concentration in adult patients with cystic fibrosis. *The Journal of Clinical Endocrinology and Metabolism*. 2006;**10**:2005-2135

[30] Kearns G. Hepatic drug metabolism in cystic fibrosis: Recent developments and future directions. *The Annals of Pharmacotherapy*. 1993;**27**:74-79

[31] Rowland M, Gallagher C, O'Laoide R, et al. Outcome in cystic fibrosis liver disease. *The American Journal of Gastroenterology*. 2011;**106**:104-109

[32] Toledano MB, Mukherjee SK, Howell J, Westaby D, et al. The emerging burden of liver disease in cystic fibrosis patients: A UK nationwide study. *PLoS One*. 2019;**14**(4):e0212779. DOI: 10.1371/journal.pone.0212779

[33] Curry M, Hegarty J. The gallbladder and biliary tract in cystic fibrosis. *Current Gastroenterology Reports*. 2005;**7**:147-153

[34] Colombo C, Battezzati P, Crosignani A, et al. Liver disease in cystic fibrosis : A prospective study on incidence, risk factors and outcome. *Hepatology*. 2002;**36**:1374-1382

[35] De Haan W. A marker associated with increased risk for severe liver disease in cystic fibrosis. *Clinical Genetics*. 2010;**77**:434-437

- [36] Debray D, Narkewicz M, Bodewes F, Colombo C, et al. Cystic fibrosis-related liver disease: Research challenges and future perspectives. *Journal of Pediatric Gastroenterology and Nutrition*. 2017;**65**(4):443-448. DOI: 10.1097/MPG.0000000000001676
- [37] Debray D, Kelly D, Houwen R, et al. Best practice guidance for the diagnosis and management of cystic fibrosis-associated liver disease. *Journal of Cystic Fibrosis*. 2011;**10**(Suppl. 2):529-536
- [38] Potter C, Fishbein M, Hammond S, et al. Can the histologic changes of cystic fibrosis-associated hepatobiliary disease be predicted by clinical criteria? *Journal of Pediatric Gastroenterology and Nutrition*. 1997;**25**:32-36
- [39] Rudnick D. Cystic fibrosis – associated liver disease: When will the future be now? *Journal of Pediatric Gastroenterology and Nutrition*. 2012;**54**(3):312-317. DOI: 10.1097/MPG.0b013e3182309fd0
- [40] Sakiani S, Kleiner DE, Heller T, Koh C. Hepatic manifestations of cystic fibrosis. *Clinics in Liver Disease*. 2019;**23**(2):263-277. DOI: 10.1016/j.cld.2018.12.008
- [41] Aqul A, Jonas M, Harney S, et al. Correlation of transient elastography with severity of cystic fibrosis-related liver disease. *Journal of Pediatric Gastroenterology and Nutrition*. 2017;**64**:505-511
- [42] Alexopoulou A, Pouriki S, Vasilieva L, et al. Evaluation of noninvasive markers for the diagnosis of cystic fibrosis liverdisease. *Scandinavian Journal of Gastroenterology*. 2018;**53**(12):1547-1552. DOI: 10.1080/00365521.2018.1534986.
- [43] Friedrich-Rust M, Schlueter N, Smaczny C, et al. Non-invasive measurement of liver and pancreas fibrosis in patients with cystic fibrosis. *Journal of Cystic Fibrosis*. 2013;**12**(5):431-439
- [44] Leung D, Khan M, Minard C, et al. Aspartate aminotransferase to platelet ratio and fibrosis-4 as biomarkers in biopsy-validated pediatric cystic fibrosis liver disease. *Hepatology*. 2015;**62**(5):1576-1583
- [45] Lewindon PJ, Puertolas-Lopez MV, Ramm LE, et al. Accuracy of transient elastography data combined with APRI in detection and staging of liver disease in pediatric patients with cystic fibrosis. *Clinical Gastroenterology and Hepatology*. 2019;**15**. pii: S1542-3565(19)30279-4. DOI: 10.1016/j.cgh.2019.03.015
- [46] Loaeza-del-Castillo A, Paz-Pineda F, Oviedo-Cardenas E, et al. AST to platelet ratio index (APRI) for the noninvasive evaluation of liver fibrosis. *Annals of Hepatology*. 2008;**7**(4):350-357
- [47] Pereira T, Lewindon P, Smith J, et al. Serum markers of hepatic fibrogenesis in cystic fibrosis liver disease. *Journal of Hepatology*. 2004;**41**:576-583
- [48] Sadler M, Crotty P, Fatovich L, et al. Noninvasive methods, including transient elastography, for the detection of liver disease in adults with cystic fibrosis. *Canadian Journal of Gastroenterology and Hepatology*. 2015;**29**(3):139-144
- [49] Lemoine C, Lokar J, McColley S, Alonso E, et al. Cystic fibrosis and portal hypertension: Distal splenorenal shunt can prevent the need for future liver transplant. *Journal of Pediatric Surgery*. May 2019;**54**(5):1076-1082. DOI: 10.1016/j.jpedsurg.2019.01.035 Epub 2019 Feb 2
- [50] Cheng K, Ashby D, Smyth RL. Ursodeoxycholic acid for cystic fibrosis-related liver disease. *Cochrane Database of Systematic Reviews*.

2017;**9**:CD000222. DOI: 10.1002/14651858.CD000222.pub4.

[51] Pereira T, Lewindon P, Greer R, et al. Transcriptional basis for hepatic fibrosis in cystic fibrosis- associated liver disease. *Journal of Pediatric Gastroenterology and Nutrition*. 2012;**54**(3):328-335. DOI: 10.1097/MPG.0b013e3182432034

[52] Efrati O, Barak A, Modan-Moses D, et al. Liver cirrhosis and portal hypertension in cystic fibrosis. *European Journal of Gastroenterology & Hepatology*. 2003;**18**:1073-1078

[53] Stonebraker J, Ooi C, Pace R, et al. Features of severe liver disease with portal hypertension in patients with cystic fibrosis. *Clinical Gastroenterology and Hepatology*. 2016;**14**(8):1207-1215

[54] Arnon R, Annunzjato R, Miloh T, et al. Liver and combined lung and liver transplantation for cystic fibrosis: Analysis of the UNOS database. *Pediatric Transplantation*. 2011;**15**:254-264

[55] Freeman AJ, Sellers ZM, MazariegosG, KellyAA. Multidisciplinary approach to pretransplant and posttransplant management of cystic fibrosis-associated liver disease. *Liver Transplantation*. 2019;**25**(4):640-657. DOI: 10.1002/lt.25421

[56] Frost F, Dyce P, Ochota A, et al. Cystic fibrosis related diabetes: Optimizing care with a multidisciplinary approach. *Diabetes, Metabolic Syndrome and Obesity: Targets and Therapy*. 2019;**12**:545-552. DOI: 10.2147/DMSO.S180597

[57] Gan HW, Bhatt JM, Denvir L, et al. Monogenic diabetes mellitus in cystic fibrosis. *Archives of Disease in Childhood*. 2019;**104**(9):887-889. DOI: 10.1136/archdischild-2018-316141

[58] Arkwright P, Pravica V, Geraghty P, et al. End-organ dysfunction in cystic fibrosis. *American Journal of Respiratory and Critical Care Medicine*. 2003;**167**:384-389

[59] Bandsma R, Bozic M, Fridell J, et al. Simultaneous liver-pancreas transplantation for cystic fibrosis-related liver disease. A multicenter experience. *Journal of Cystic Fibrosis*. 2014;**13**:471-477

[60] Nash K, Collier J, French J, et al. Cystic fibrosis liver disease to transplant or not to transplant? *American Journal of Transplantation*. 2008;**8**:162-169

[61] Young A, Giles C, Mervyn T, et al. A combined liver-pancreas en-bloc transplant in a patient with cystic fibrosis. *Transplantation*. 2005;**5**:605-607