

We are IntechOpen, the world's leading publisher of Open Access books Built by scientists, for scientists

6,900

Open access books available

185,000

International authors and editors

200M

Downloads

Our authors are among the

154

Countries delivered to

TOP 1%

most cited scientists

12.2%

Contributors from top 500 universities



WEB OF SCIENCE™

Selection of our books indexed in the Book Citation Index
in Web of Science™ Core Collection (BKCI)

Interested in publishing with us?
Contact book.department@intechopen.com

Numbers displayed above are based on latest data collected.
For more information visit www.intechopen.com



Immunocheckpoint Blockade in Malignant Pleural Mesothelioma

Nobukazu Fujimoto

Abstract

Targeting immunocheckpoint with immunomodulatory monoclonal antibodies has proven to be an effective antitumor strategy across a variety of cancers. The immunosuppressive tumor microenvironment in malignant pleural mesothelioma (MPM) has suggested that MPM might benefit from this kind of immunotherapy. In recent years, immunocheckpoint inhibitors (ICIs) have shown encouraging results for patients with MPM. Antibodies against programmed death 1 (PD-1) and PD-ligand 1 (PD-L1) have demonstrated favorable response, progression-free survival, and overall survival. The toxicity profiles were similar to those observed with ICIs in other malignancies, like melanoma and non-small cell lung cancer, and they appeared to be manageable. Nivolumab, an anti-PD-1 antibody, was approved in Japan for advanced or metastatic MPM patients resistant or intolerant to other chemotherapies. Important future issues include developing a combination therapy, where ICIs are combined with other agents (including other ICIs), and developing biomarkers for determining which patients might respond well and which might experience unacceptable toxicities.

Keywords: durvalumab, immunocheckpoint, nivolumab, pembrolizumab, PD-1

1. Introduction

Malignant pleural mesothelioma (MPM) is a rare pleural malignancy that is associated with asbestos exposure. Gamba et al. reported that more than 70% of malignant mesothelioma cases in Japan were associated with occupational or environmental asbestos exposure [1]. MPM is a highly aggressive neoplasm with a poor prognosis; the median overall survival (OS) is only about 12 months. Systemic chemotherapy with platinum plus pemetrexed is the recommended first-line systemic therapy for advanced MPM [2]. Some clinical trials have examined the efficacy of new agents to improve the results of the platinum/pemetrexed combination; however, no new agent has demonstrated significant clinical efficacy. Thus, the pemetrexed/platinum combination remains the standard treatment.

Currently, there is no recommended treatment option for MPM after first-line platinum/pemetrexed chemotherapy. Re-treatment with pemetrexed-based chemotherapy is a reasonable option for patients that achieved durable disease control with the first-line chemotherapy [3]. Other treatment options of salvage chemotherapy include vinorelbine and gemcitabine; however, the median OS with these agents only ranges from 5 to 10 months [4, 5]. Other experimental agents, such as angiogenesis inhibitors [6] or tyrosine kinase inhibitors [7], have not demonstrated efficacy.

Targeting immuncheckpoint with immunomodulatory monoclonal antibodies was shown to be an effective antitumor strategy across a variety of cancers [8]. The immunosuppressive tumor microenvironment in MPM has suggested that MPM might benefit from this kind of immunotherapy [9, 10]. In fact, in recent years, immuncheckpoint inhibitors (ICIs) have shown some encouraging results for patients with MPM.

In this chapter, we review recent clinical findings on several ICIs, including anti-cytotoxic T lymphocyte-associated antigen 4 (CTLA-4) antibody, anti-programmed death 1 (PD-1) antibody, and anti-PD-ligand 1 (PD-L1) antibody, for treating patients with MPM.

2. Anti-CTLA-4 antibody

Anti-CTLA-4 antibody was the first ICI described for treating MPM. Phase II studies demonstrated that tremelimumab, a selective human monoclonal antibody against CTLA-4, showed favorable activity as a second-line treatment for MPM [11, 12]. However, a double-blind study that compared tremelimumab to placebo in subjects with previously treated, unresectable malignant mesothelioma (DETERMINE study) failed to demonstrate differences in OS or progression-free survival (PFS) between the treatment and placebo groups [13]. After that, anti-CTLA-4 antibodies were studied in combination with an anti-PD-1 or anti-PD-L1 antibody.

3. Anti-PD-L1 antibody

Avelumab is a human IgG1 monoclonal antibody that targets PD-L1 [14]. A phase 1b open-label study (JAVELIN solid tumor) was conducted in patients with unresectable mesothelioma that progressed after platinum/pemetrexed treatment; patients were enrolled at 25 sites in three countries [15]. Of 53 patients treated, the objective response rate (RR) was 9% (95% confidence interval [95%CI]: 3.1–20.7%); one patient experienced a complete response, and four patients experienced a partial response. Responses were durable (median, 15.2 months; 95%CI: 11.1 to non-estimable) and occurred in patients with PD-L1-positive tumors (RR: 19%; 95%CI: 4.0–45.6) and PD-L1-negative tumors (RR: 7%; 95%CI: 0.9–24.3), based on a 5% or greater cutoff for PD-L1 expression. The median PFS was 4.1 months (95%CI: 1.4–6.2), and the 12-month PFS rate was 17.4% (95%CI: 7.7–30.4). The median OS was 10.7 months (95%CI: 6.4–20.2).

4. Anti-PD-1 antibody

4.1 Pembrolizumab

A nonrandomized, phase Ib trial was conducted to test pembrolizumab in patients with PD-1-positive MPM that had been treated previously. In the preliminary report, 20% of patients experienced an objective response, 72% experienced disease control, and the median OS was 18 months (95%CI: 9.4 to non-estimable) [16]. Then, a phase II trial assessed pembrolizumab activity in 65 unselected patients with MPM [17]. The objective RR was 19% and the disease control rate was 66%. The median PFS was 4.5 months (95%CI: 2.3–6.2), and the median OS was 11.5 months (95%CI: 7.6–14).

After those promising results, pembrolizumab was used off-label in Switzerland and Australia [18]. A total of 93 patients (48 from Switzerland and 45 from Australia) were treated. In those cohorts, the overall RR was 18%, the median PFS was 3.1 months, and the median OS was 7.2 months. Among patients with the non-epithelioid histological subtype, pembrolizumab treatment improved the objective RR (24% vs. 16%; $p = 0.54$) and the median PFS (5.6 vs. 2.8 months; $p = 0.02$).

4.2 Nivolumab

Another anti-PD-1 antibody, nivolumab, was first tested in recurrent MPM in the Netherlands [19]. In that single-center trial, patients with MPM received 3 mg/kg intravenous nivolumab every 2 weeks. Of the 34 patients included, eight patients (24%) displayed a partial response and another eight displayed stable disease, which resulted in a disease control rate of 47%. Japanese investigators also evaluated the efficacy and safety of nivolumab for advanced MPM in patients that were resistant or intolerant to prior chemotherapy [20]. Thirty-four patients were enrolled, and 10 patients (29.4%, 95%CI: 16.8–46.2) showed an objective response in a central assessment. Objective RRs were 25.9, 66.7, and 25.0% for epithelioid, sarcomatous, and biphasic histological subtypes, respectively (**Figure 1**). The median OS and PFS were 17.3 and 6.1 months, respectively (**Figure 2a and b**). Based on these findings,

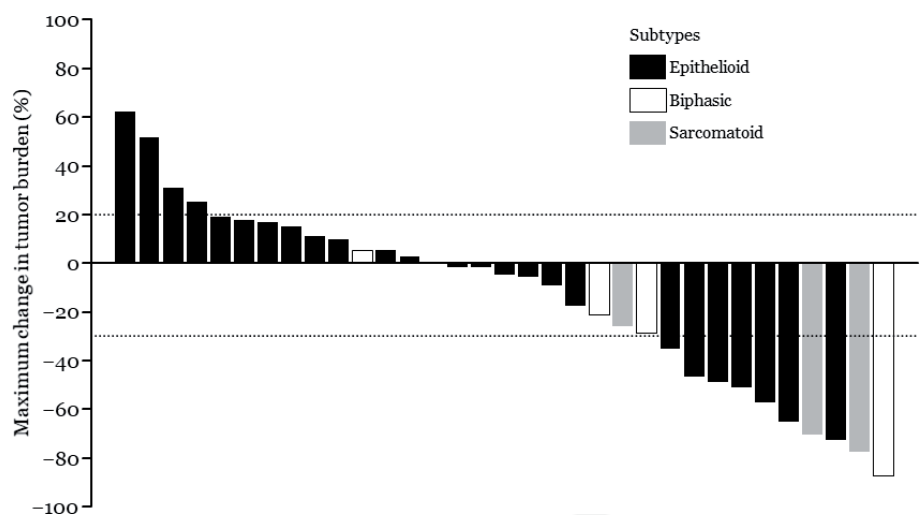


Figure 1. A waterfall plot of the MERIT study results, which demonstrates the maximum percentage changes compared to baseline in target lesions of each patient, according to histological subtype (Ref. [20]).

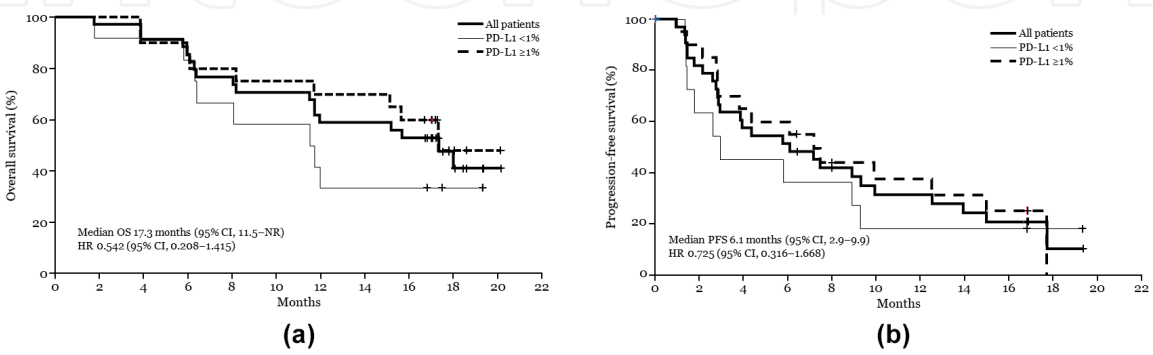


Figure 2. Kaplan-Meier curves show survival for all patients and for patients grouped according to programmed death-ligand 1 (PD-L1) expression in the MERIT study (Ref. [20]). (a) Overall survival (OS); (b) progression-free survival (PFS). HRs compare the PD-L1 ≥1% group to the <1% group. CI, confidence interval; HR, hazard ratio; NR, not reached.

nivolumab was approved in Japan for patients with advanced or metastatic MPM that are resistant or intolerant to previous chemotherapy.

Although the effect requires confirmation in larger clinical trials, nivolumab and pembrolizumab might offer hope for patients with MPM.

5. Toxicity

The toxicity of these ICIs was acceptable in MPM. A study on pembrolizumab toxicity found grade 3 and 4 events, including adrenal insufficiency (3%), pneumonitis (3%), skin rash (3%), colitis (1.6%), confusion (1.6%), hepatitis (1.6%), and hyperglycemia (1.6%), and one grade 5 event of hepatitis (1.6%) [17]. In a study on nivolumab, adverse events of any grade occurred in 26 patients (76%), including fatigue (29%) and pruritus (15%) [19]. In that study, treatment-related grade 3 and 4 adverse events were reported in nine patients (26%); most events were pneumonitis, gastrointestinal disorders, and laboratory disorders. One treatment-related death was due to pneumonitis, but it was probably initiated by concurrent amiodarone therapy. These toxicity profiles were similar to those observed in other malignancies, including melanoma and non-small cell lung cancer (NSCLC), and they appeared to be manageable.

6. Future perspectives

Based on the promising results described above, ICIs could play a primary role in the treatment of MPM. An important issue for the future is whether ICIs can be combined with other agents, including other ICIs. For example, given the synergy between the PD-1/PD-L1 and CTLA-4 pathways in T-cell activation, a combination treatment with antibodies that target PD-1 or PD-L1 and CTLA-4 warrants investigation [22].

NIBIT-MESO-1 was an open-label, nonrandomized, phase II study that investigated the efficacy and safety of first- or second-line tremelimumab, a monoclonal antibody against CTLA-4, combined with durvalumab, a monoclonal antibody against PD-L1 [23]. In that study, patients with unresectable pleural or peritoneal mesothelioma received one dose of intravenous tremelimumab and durvalumab delivered every 4 weeks, for a total of four doses. This was followed by maintenance treatment with intravenous durvalumab. Of 40 patients, 11 (28%) displayed an objective response. The median PFS was 5.7 months (95%CI: 1.7–9.7), and the median OS was 16.6 months (95%CI: 13.1–20.1). Toxicity related to treatment was generally manageable and reversible.

Another multicenter, randomized, phase II study was conducted in France [24]. In that study, patients were randomly allocated to nivolumab or nivolumab plus ipilimumab. In the intention-to-treat population, the primary endpoint, 12-week disease control, was achieved by 25 (40%; 95%CI: 28–52) of 63 patients in the nivolumab group and by 32 (52%; 95%CI: 39–64) of 62 patients in the combination group. The most frequent grade 3 adverse events were asthenia (N = one [2%] with nivolumab vs. three [5%] with the combination), an asymptomatic increase in aspartate aminotransferase or alanine aminotransferase (N = none with nivolumab vs. four [7%] of each with the combination), and an asymptomatic increase in lipase (N = two [3%] with nivolumab vs. one [2%] with the combination). These findings indicated that the combination of anti-CTLA-4 and anti-PD1/PD-L1 antibodies appeared to be active and had a good safety profile in patients with MPM. Currently, there is an ongoing phase III, randomized, open-label trial for testing nivolumab in combination with ipilimumab vs. pemetrexed with cisplatin or carboplatin as a first-line therapy in unresectable MPM. The primary endpoint of the study, OS, will be reported in the near future.

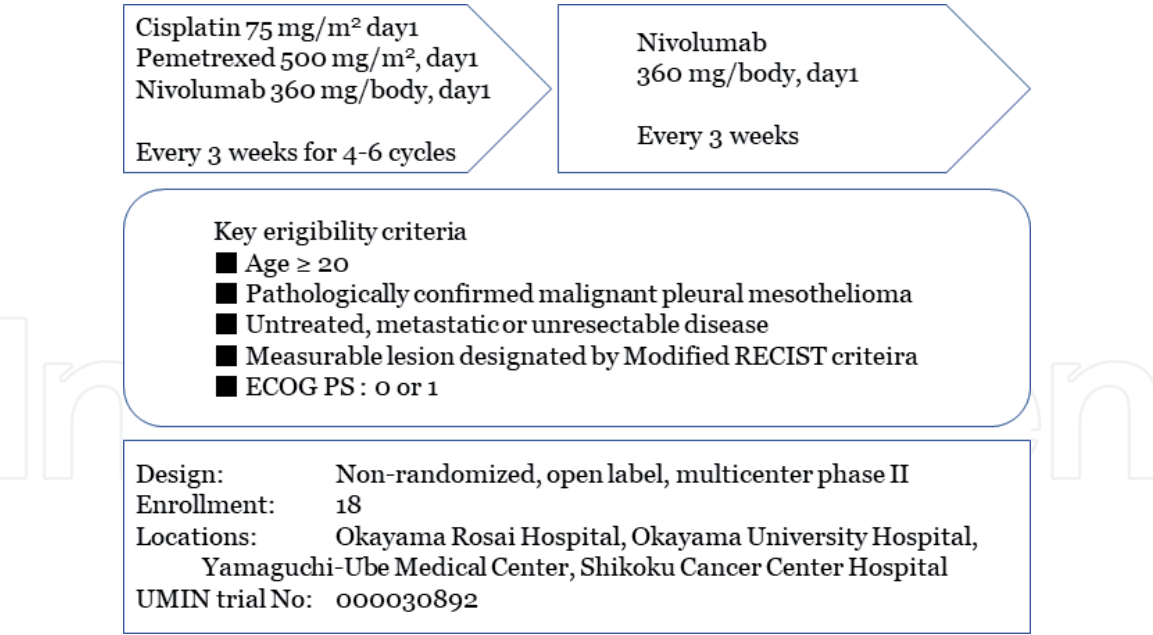


Figure 3.
Overview of a phase II trial for testing a first-line combination chemotherapy with cisplatin/pemetrexed and nivolumab for treating unresectable malignant pleural mesothelioma (Ref. [21]). RECIST, response evaluation criteria in solid tumors; ECOG, eastern cooperative oncology group; PS, performance status.

The combination of an anti-PD-1/PD-L1 antibody and conventional chemotherapy is also under investigation. Nowak et al. presented results from a phase II trial that tested durvalumab combined with cisplatin/pemetrexed in MPM [25]. The primary endpoint, PFS at 6 months, was 57% (N = 31/54; 95%CI: 45–68), the median PFS time was 6.9 months (95%CI: 5.5–9.0), and the objective RR was 48% (95%CI: 35–61). Grade 3–5 adverse events occurred in 36 patients, including neutropenia in 13%, nausea in 11%, anemia in 7%, fatigue in 6%, and any grade of peripheral neuropathy in 35%. The authors have conducted another phase II study to test the combination of nivolumab and cisplatin/pemetrexed, which is currently in progress (**Figure 3**) [21]. A large-scale randomized study for testing the combination of pembrolizumab and cisplatin/pemetrexed is also in progress. Based on whether these combination regimens, which include anti-PD1/PD-L1 antibodies, demonstrate sufficient activity, safety, and tolerability as first-line treatments, the standard regimen of cisplatin/pemetrexed might be replaced.

Another important issue is whether biomarkers can be developed to determine which patients might expect a response and which might expect unacceptable toxicity. Previous studies in patients with MPM have shown that tumors with positive PD-L1 expression were associated with worse survival outcomes compared to those with negative PD-L1 expression [26]. Although an optimal PD-L1 expression threshold could not be identified, a trend was observed, where a higher RR and more durable PFS were associated with increasing PD-L1 expression, in studies on pembrolizumab [17, 18] and nivolumab [20]. In some neoplasms, the tumor mutation burden or the tumor microenvironment was associated with the response to ICIs; however, those associations have not been established as biomarkers in MPM.

7. Conclusion

The prognosis of MPM remains poor. Recent encouraging results have suggested that a PD-1/PD-L1 blockade might be an effective treatment option

for MPM. Although the effect requires confirmation in larger clinical trials, nivolumab and pembrolizumab might offer hope for patients with MPM. Further study is warranted to develop more effective treatment strategies, such as combining ICI with other ICIs or with conventional chemotherapy, and to establish biomarkers for distinguishing patients that might respond to treatment from those likely to develop unacceptable toxicities.

Acknowledgements

This study was supported by grants-in-aid from the Ministry of Health, Labor, and Welfare, Japan.

Conflict of interest

The author received consultancy fees from Boehringer Ingelheim, Ono, Bristol-Myers Squibb, Kyorin, and Kissei, and honoraria or research funding from Hisamitsu, Chugai, Ono, Taiho, Boehringer Ingelheim, Bristol-Myers Squibb, Novartis, GlaxoSmithKline, and MSD.


Author details

Nobukazu Fujimoto

Department of Medical Oncology, Okayama Rosai Hospital, Okayama, Japan

*Address all correspondence to: nobufujimot@gmail.com

IntechOpen

© 2019 The Author(s). Licensee IntechOpen. This chapter is distributed under the terms of the Creative Commons Attribution License (<http://creativecommons.org/licenses/by/3.0>), which permits unrestricted use, distribution, and reproduction in any medium, provided the original work is properly cited. 

References

- [1] Gemba K, Fujimoto N, Kato K, Aoe K, Takeshima Y, Inai K, et al. National survey of malignant mesothelioma and asbestos exposure in Japan. *Cancer Science*. 2012;**103**:483-490. DOI: 10.1111/j.1349-7006.2011.02165.x
- [2] Vogelzang NJ, Rusthoven JJ, Symanowski J, Denham C, Kaukel E, Ruffie P, et al. Phase III study of pemetrexed in combination with cisplatin versus cisplatin alone in patients with malignant pleural mesothelioma. *Journal of Clinical Oncology*. 2003;**21**:2636-2644. DOI: 10.1200/JCO.2003.11.136
- [3] Bearz A, Talamini R, Rossoni G, Santo A, de Pangher V, Fasola G, et al. Re-challenge with pemetrexed in advanced mesothelioma: A multi-institutional experience. *BMC Research Notes*. 2012;**5**:482. DOI: 10.1186/1756-0500-5-482
- [4] Bibby AC, Tsim S, Kanellakis N, Ball H, Talbot DC, Blyth KG, et al. Malignant pleural mesothelioma: An update on investigation, diagnosis and treatment. *European Respiratory Review*. 2016;**25**:472-486. DOI: 10.1183/16000617.0063-2016
- [5] Buikhuisen WA, Hiddinga BI, Baas P, van Meerbeeck JP. Second line therapy in malignant pleural mesothelioma: A systematic review. *Lung Cancer*. 2015;**89**:223-231. DOI: 10.1016/j.lungcan.2015.06.018
- [6] Buikhuisen WA, Burgers JA, Vincent AD, Korse CM, van Klaveren RJ, Schramel FM, et al. Thalidomide versus active supportive care for maintenance in patients with malignant mesothelioma after first-line chemotherapy (NVALT 5): An open-label, multicentre, randomised phase 3 study. *The Lancet Oncology*. 2013;**14**:543-551. DOI: 10.1016/S1470-2045(13)70125-6
- [7] Mathy A, Baas P, Dalesio O, van Zandwijk N. Limited efficacy of imatinib mesylate in malignant mesothelioma: A phase II trial. *Lung Cancer*. 2005;**50**:83-86. DOI: 10.1016/j.lungcan.2005.04.010
- [8] Wilson RAM, Evans TRJ, Fraser AR, Nibbs RJB. Immune checkpoint inhibitors: New strategies to checkmate cancer. *Clinical and Experimental Immunology*. 2018;**191**:133-148. DOI: 10.1111/cei.13081
- [9] Bograd AJ, Suzuki K, Vertes E, Colovos C, Morales EA, Sadelain M, et al. Immune responses and immunotherapeutic interventions in malignant pleural mesothelioma. *Cancer Immunology, Immunotherapy*. 2011;**60**:1509-1527. DOI: 10.1007/s00262-011-1103-6
- [10] Hegmans JP, Hemmes A, Hammad H, Boon L, Hoogsteden HC, Lambrecht BN. Mesothelioma environment comprises cytokines and T-regulatory cells that suppress immune responses. *The European Respiratory Journal*. 2006;**27**:1086-1095. DOI: 10.1183/09031936.06.00135305
- [11] Calabro L, Morra A, Fonsatti E, Cutaia O, Amato G, Giannarelli D, et al. Tremelimumab for patients with chemotherapy-resistant advanced malignant mesothelioma: An open-label, single-arm, phase 2 trial. *The Lancet Oncology*. 2013;**14**:1104-1111. DOI: 10.1016/S1470-2045(13)70381-4
- [12] Calabro L, Morra A, Fonsatti E, Cutaia O, Fazio C, Annesi D, et al. Efficacy and safety of an intensified schedule of tremelimumab for chemotherapy-resistant malignant mesothelioma: An open-label, single-arm, phase 2 study. *The Lancet Respiratory Medicine*. 2015;**3**:301-309. DOI: 10.1016/S2213-2600(15)00092-2

- [13] Maio M, Scherpereel A, Calabro L, Aerts J, Cedres Perez S, Bearz A, et al. Tremelimumab as second-line or third-line treatment in relapsed malignant mesothelioma (DETERMINE): A multicentre, international, randomised, double-blind, placebo-controlled phase 2b trial. *The Lancet Oncology*. 2017;**18**:1261-1273. DOI: 10.1016/S1470-2045(17)30446-1
- [14] Heery CR, O'Sullivan-Coyne G, Madan RA, Cordes L, Rajan A, Rauckhorst M, et al. Avelumab for metastatic or locally advanced previously treated solid tumours (JAVELIN solid tumor): A phase 1a, multicohort, dose-escalation trial. *The Lancet Oncology*. 2017;**18**:587-598. DOI: 10.1016/S1470-2045(17)30239-5
- [15] Hassan R, Thomas A, Nemunaitis JJ, Patel MR, Bennouna J, Chen FL, et al. Efficacy and safety of avelumab treatment in patients with advanced unresectable mesothelioma: Phase 1b results from the JAVELIN solid tumor trial. *JAMA Oncology*. 2019;**5**:351-357. DOI: 10.1001/jamaoncol.2018.5428
- [16] Alley EW, Lopez J, Santoro A, Morosky A, Saraf S, Piperdi B, et al. Clinical safety and activity of pembrolizumab in patients with malignant pleural mesothelioma (KEYNOTE-028): Preliminary results from a non-randomised, open-label, phase 1b trial. *The Lancet Oncology*. 2017;**18**:623-630. DOI: 10.1016/S1470-2045(17)30169-9
- [17] Desai A, Karrison T, Rose B, Tan Y, Hill B, Pemberton E, et al. Phase II trial of pembrolizumab (NCT02399371) in previously-treated malignant mesothelioma: Final analysis. *Journal of Thoracic Oncology*. 2018;**13**:S339
- [18] Metaxas Y, Rivalland G, Mauti LA, Klingbiel D, Kao S, Schmid S, et al. Pembrolizumab as palliative immunotherapy in malignant pleural mesothelioma. *Journal of Thoracic Oncology*. 2018;**13**:1784-1791. DOI: 10.1016/j.jtho.2018.08.007
- [19] Quispel-Janssen J, van der Noort V, de Vries JF, Zimmerman M, Lalezari F, Thunnissen E, et al. Programmed death 1 blockade with nivolumab in patients with recurrent malignant pleural mesothelioma. *Journal of Thoracic Oncology*. 2018;**13**:1569-1576
- [20] Okada M, Kijima T, Aoe K, Kato T, Fujimoto N, Nakagawa K, et al. Clinical efficacy and safety of nivolumab: Results of a multicenter, open-label, single-arm, Japanese phase 2 study in malignant pleural mesothelioma (MERIT). *Clinical Cancer Research*. 2019. DOI: 10.1158/1078-0432.CCR-19-0103. pii: clincanres.0103.2019
- [21] Fujimoto N, Aoe K, Kozuki T, Oze I, Kato K, Kishimoto T, et al. A phase II trial of first-line combination chemotherapy with cisplatin, pemetrexed, and nivolumab for unresectable malignant pleural mesothelioma: A study protocol. *Clinical Lung Cancer*. 2018;**19**:e705-e707. DOI: 10.1016/j.clcc.2018.05.001
- [22] Das R, Verma R, Sznol M, Boddupalli CS, Gettinger SN, Kluger H, et al. Combination therapy with anti-CTLA-4 and anti-PD-1 leads to distinct immunologic changes in vivo. *Journal of Immunology*. 2015;**194**:950-959. DOI: 10.4049/jimmunol.1401686
- [23] Calabro L, Morra A, Giannarelli D, Amato G, D'Incecco A, Covre A, et al. Tremelimumab combined with durvalumab in patients with mesothelioma (NIBIT-MESO-1): An open-label, non-randomised, phase 2 study. *The Lancet Respiratory Medicine*. 2018;**6**:451-460. DOI: 10.1016/S2213-2600(18)30151-6
- [24] Scherpereel A, Mazieres J, Greillier L, Lantuejoul S, Do P, Bylicki O, et al. French Cooperative Thoracic Intergroup. Nivolumab or

nivolumab plus ipilimumab in patients with relapsed malignant pleural mesothelioma (IFCT-1501 MAPS2): A multicentre, open-label, randomised, non-comparative, phase 2 trial. *The Lancet Oncology*. 2019;**20**:239-253. DOI: 10.1016/S1470-2045(18)30765-4

[25] Nowak AKP, Lesterhuis W, Hughes B, Brown C, Kao S, Karikios D, et al. DREAM—A phase 2 trial of durvalumab with first line chemotherapy in mesothelioma: Final result. *Journal of Thoracic Oncology*. 2018;**13**(10, Supplement):S338-S3S9

[26] Cedres S, Ponce-Aix S, Zugazagoitia J, Sansano I, Enguita A, Navarro-Mendivil A, et al. Analysis of expression of programmed cell death 1 ligand 1 (PD-L1) in malignant pleural mesothelioma (MPM). *PLoS One*. 2015;**10**:e0121071. DOI: 10.1371/journal.pone.0121071