

# We are IntechOpen, the world's leading publisher of Open Access books Built by scientists, for scientists

6,900

Open access books available

185,000

International authors and editors

200M

Downloads

Our authors are among the

154

Countries delivered to

TOP 1%

most cited scientists

12.2%

Contributors from top 500 universities



WEB OF SCIENCE™

Selection of our books indexed in the Book Citation Index  
in Web of Science™ Core Collection (BKCI)

Interested in publishing with us?  
Contact [book.department@intechopen.com](mailto:book.department@intechopen.com)

Numbers displayed above are based on latest data collected.  
For more information visit [www.intechopen.com](http://www.intechopen.com)



# New Laparoscopic Surgery in Inguinal Hernia Repair

*Reno Rudiman and Andika August Winata*

## Abstract

Laparoscopic inguinal herniorrhaphy has become widely accepted as an effective alternative to the treatment of hernias with the anterior approach. It has success rates identical to those of the conventional method and quickens recovery by decreasing time until return to work or physical activities. With the introduction of single incision laparoscopic surgery (SILS), there has been an exponential increase in the number of SILS hernia repair. It probably represents the single most exciting innovation in laparoscopic surgery of the last 2 decades. The main premise of SILS is the use of completely blunt ports, which will negate the risks of bowel and vascular injuries, less wound, less postoperative pain, cosmetically more favorable and lower the recurrent rate.

**Keywords:** inguinal hernia, laparoscopic, TAPP, TEP, SILS

## 1. Introduction

Surgery to treat various diseases has been recorded back to middle ages. For two centuries, large incisions were necessary to perform abdominal surgical procedures. Although effective, several known morbidities were related to this method, including postoperative pain, wound infection, incisional hernia, and prolonged hospitalization [1]. The present surgical site infection rate is 15–25%, depending on the level of contamination [2].

Laparoscopic surgery was introduced in 1983 by Lukichev and 1985 by Muhe who performed laparoscopic cholecystectomy. Their cumbersome techniques did not receive the attention they probably deserved. Interests were started to grow after Mouret in 1987 reported the first acknowledged laparoscopic cholecystectomy by means of four trocars [3]. Since then, operative laparoscopy has advanced progressively. Several operative procedures have been performed by this new approach. Due to its minimal invasiveness to abdominal wall, laparoscopic surgery is also called minimally invasive surgery. Laparoscopic procedures can be performed using small incisions of around 0.5–1.5 cm that can be made far away from the surgical site [4].

One of the main advantages of laparoscopic surgery over traditional open surgery is it often requires a shorter hospital stay than traditional open surgery. Procedure such as appendectomy or cholecystectomy is commonly stay at the hospital for only one night after surgery. This is due to patients are experiencing less pain and bleeding after surgery [5].

Another important advantage of laparoscopic surgery is that as the incision wound is so much smaller than open surgery, post-surgical scarring is significantly

reduced. Cosmetically, it is more desirable to most patients. Risks of keloid forming are therefore significantly reduced as well [6].

In conventional laparoscopic surgery, three to four small incisions are made. In a more complex procedure such as large bowel resection or bariatric (obesity) surgery, up to six incisions can be made, allowing more instruments to be used to assist organ resection [4, 7–9]. Obviously, the more wounds are made, the more pain it will eventually be caused to the patients. On the contrary, less wound signifies less pain. This brings about the concept of single incision laparoscopic surgery [10, 11].

## 2. Laparoscopic hernia repair

Transabdominal preperitoneal (TAPP) repair and totally extraperitoneal (TEP) repair are the most common laparoscopic inguinal hernia repair techniques, since the early of 1990s [6]. In TAPP, the peritoneal cavity is explored by the surgeon and then a mesh is placed through a peritoneal incision over possible hernia sites. TEP is different as the peritoneal cavity is not penetrated and mesh is employed to seal the hernia from outside of the peritoneum [8]. Both techniques try to diminish the hernia and hernia sac within the abdomen and then place a 10 × 15 cm mesh just deep to the abdominal wall [12].

The more superior surgical approach and technique for inguinal hernia repair is still widely argued. TAPP laparoscopic inguinal hernia repair improved clinical outcome and associated with a better quality of patient's life in numerous study [13]. The advantages of this approach are capability to inspect abdominal cavity, excellent exposure and enabling bilateral repair if necessary. The disadvantages are the possibility of intraperitoneal structures injury, adhesion formation and possibility of late bowel obstruction [14] (**Figures 1 and 2**).

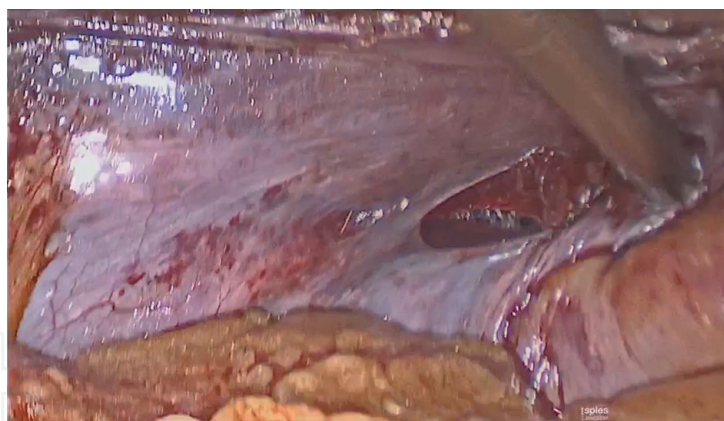
Peritoneal integrity preservation is the main reason for TEP laparoscopic inguinal hernia repair is preferred to the TAPP repair. However, the peculiarity of anatomy and working area restriction in general made it to be more difficult [15]. In TEP, the surgeon is able to create a space just deep to the abdominal muscles without entering the peritoneal cavity and minimizing adhesion formation [14, 16].

It has been more than 20 years since TAPP and TEP were introduced to clinical routine [17]. TEP is considered to be more difficult than TAPP but may have fewer complications [8].

Rhambia et al. in 2016 also conducted a comparative study between these techniques; they found that there is no significant difference between them in the



**Figure 1.**  
*Positioning the mesh in inguinal area.*



**Figure 2.**  
*Peritoneum is closed.*

variable of duration of surgery, serious adverse event, persisting post-operative pain, hematoma, seroma, persisting numbness, hernia recurrence, port site of hernia and length of hospital stay. TEP gave the patients less pain after 24 hours of surgery in this research [18].

Former research by McCormack revealed that TAPP has slightly increased the number of hernias developing close by and injuries to internal organs. TEP has been associated with more conversions to another type of surgery. These are widely consistent results. Comparing these two techniques, the number of vascular injuries and deep and mesh infections is infrequent and there were no overt difference [8].

Apart from that, assuming a comparable patient group, identical indication and adequately experienced surgeons, similar results can be achieved with the TEP and TAPP technique. That is borne out by the comparable reoperation rate for postoperative complications [17].

## **2.1 SILS in hernia repair**

An effective alternative to treat hernias is SILS that was introduced in 2007 after a port by Covidien was released. It is now probably represents the single most exciting innovation in laparoscopic surgery of the last 2 decades [19]. In hernia repair, SILS also accommodates TAPP or TEP to repair the defect. Early outcomes of this novel technique show it to be feasible, safe and with potentially better cosmetic outcome [20].

With this technique, the surgeon operates exclusively through a single entry point, typically at the patient's umbilicus. Unlike a traditional multi-port laparoscopic approach, SILS leaves only a single small scar [10, 21, 22]. During the introduction years on SILS in 1997, enthusiasm was limited because of lack of technical support and poor equipment [3]. In 2005, Hirano et al. reintroduced the technique with some advancements compared to previous technique. Since then, the technology was progressing steadily. Among advancements created were articulating instruments, laparoscope adjustments, several trocars adjacent into each other through a single incision [23].

SILS is gaining popularity due to its advantages in minimizing the invasiveness of surgical incisions. With the reduced number of incisions, the associated possible wound morbidities will also be reduced. This includes the reduced risks of wound infection, pain, bleeding, organ injury, and port site hernia [24]. In addition, one important feature of SILS is since the wound is at umbilicus, it leaves a single small scar that is well-hidden, it is almost unseen when the wound is healed, thereby it is almost "scarless" [10, 21, 25, 26].



In general, SILS techniques take about the same amount of time to do as traditional laparoscopic surgeries. However, SILS is recognized as to be a more complicated procedure because it involves manipulating three articulating instruments through one access port [22, 27, 28]. SILS performed with a similar technique to the conventional laparoscopic through a single umbilical port. The SILS-Port was introduced through a single 2.0–3.0 cm transverse transumbilical skin and facial incision. After creation of pneumoperitoneum at pressure of 12 mmHg, two 5-mm working ports and a 10-mm camera port was inserted. The peritoneal flap was prepared. A mesh was placed, and the peritoneum was closed with standard laparoscopic instruments or tackers. After releasing the pneumoperitoneum, the umbilical fascia was routinely closed with polypropylene loop suture and the skin was sutured with 4-0 absorbable intradermic sutures [29].

From financial point of view, the use of a single-port device and the increased skills needed to perform, SILS is slightly more costly to conventional multi-port laparoscopic surgery [25–27]. Generally, the length of stay in the hospital is shorter and the need of medical assistance is lesser than traditional laparoscopic surgeries [30].

Although SILS offers benefits for patients undergoing abdominal surgery, not everyone is an applicant for the procedure. Obesity, severe adhesions, or scarring from previous surgeries are a few of the factors that would prohibit patients from getting the surgery [26]. Nonetheless, new technologies are evolving continuously [27].

### *2.1.1 SILS versus conventional laparoscopic hernia repair*

A concordant evolution and improvement of the laparoscopic method has occurred when the advantages of minimally invasive surgical techniques are continuing to be defined. The less scar initiative has driven to a reduction in the number of port sites. Consequently, SILS is more popular and widely being used. As the findings show, repair of abdominal wall defects, specifically inguinal hernias, is feasible via SILS as well [31].

There are many studies comparing these two methods now. In Rajapandian et al. study, they assess the potential benefits of SILS without using specialized ports or instruments and compare the same with the conventional laparoscopic surgery in terms of operative time, post-operative pain, complications, cost and scars. They found that the mean duration of surgery was significantly longer in SILS for unilateral as well as bilateral hernia repair than its conventional counterpart. While the mean blood loss was comparable in either groups, various complications like vascular injury, peritoneal tear, cord and nerve injuries had not significant differences. In SILS, two patients were converted to conventional laparoscopy, but without any open conversion [26].

Ece et al. did a research from 148 patients, 88 underwent conventional laparoscopic repair and 60 underwent SILS repair. All SILS procedures were completed successfully without conversion conventional laparoscopic or open repair, and no additional port was required in both groups. There were no differences in operative time, length of hospital stay and VAS scores of patients 24 hours after the operation. No intraoperative major complications were observed such as vessel, intestine, or bladder injury. One patient in each group had a complaint of pain for longer than 3 months. Short-term complication rates were similar in each group. Several small seroma and hematomas were reported in both groups, and all of them were resolved with conservative treatment. Also, three patients treated with oral antibiotics for port site infection. Long-term complications such as mesh infection and recurrence were not detected in both the groups. Three patients in the SILS-TAPP group

experienced port site hernia. All of the port site hernias were confirmed by ultrasound, and elective mesh hernioplasty was performed [29].

Another research by Buckley in 2014 described a slightly different result. SILS for unilateral cases was significantly shorter statistically than for conventional one. For bilateral cases, the average operative times for both were similar. No conversions from SILS to conventional laparoscopic were performed. There were five conversions from SILS (3.88%) and three conversions from other group (3.95%) to open Kugel or Lichtenstein repairs, but the difference was not significant statistically. The recurrence rate during half year period follow up was 2.3% (3 of 129) for SILS and 1.4% (1 of 76) for conventional one. The chronic pain rate was 4.7% for SILS and 5.2% for other group. Both groups reported only one wound infection. Incisional hernia was rare (only one) in the SILS arm of the study, which occurred at the site of an umbilical hernia. There was no widely difference between the two cohorts in complication rate [31].

A systematic review by Sajid et al. analyzed from 15 comparative studies on 1651 patients evaluating the surgical outcomes of inguinal hernia repair using SILS versus conventional laparoscopic techniques. Recovery time after the surgery was significantly more rapid in SILS compared to the other procedure. Nonetheless, from the perspective of length of hospital stay, operative time both for unilateral and bilateral hernias, post-operative pain score, one-week pain score, hernia recurrence conversion and post-operative complications between two approaches showed an equality. The sub-group analysis of four included randomized, controlled trials showed similarities between outcomes following SILS and conventional laparoscopic procedure except slightly higher postoperative pain score in conventional group [27].

SILS inguinal hernia repair offers better cosmetic results with slightly longer operative time compared to conventional laparoscopic inguinal hernia repair. However, this approach is technically demanding and should be reserved for experienced single incision hernia surgeons [32]. The invention of new surgical tools will hopefully overcome the current obstacles in SILS in the future [27].

### **3. Complication of laparoscopic hernia repair**

Even the complications in endoscopic inguinal hernia surgery are more dangerous and more frequent compared to those in open surgery; they could be avoided especially in experienced hands [33]. The complication rate for laparoscopic repair of inguinal hernia ranges from less than 3% to as high as 20% [34].

Complications and the various precautions to be taken in hernia surgery can be divided into:

1. Preoperative
2. Intraoperative
3. Postoperative

#### **3.1 Preoperative precautions**

Patient with large hernias, obese patients and irreducible, obstructed hernias are best avoided. Strangulated hernia is an absolute contraindication. Elderly patients require a detailed work-up to assess cardiorespiratory status to ensure a safe outcome.

### 3.2 Intraoperative complication

#### 3.2.1 Vascular injury

The iliac vessels, inferior epigastric vessels, spermatic vessels, muscular branches, vessels over the pubic arch (including corona mortis vein) or other vessels in the region are susceptible to injury [33].

#### 3.2.2 Visceral injury

The most common injury occurs is bladder injury. Emptying the bladder prior to an inguinal hernia repair is a must to prevent a trocar injury. It is desirable to catheterize the bladder. When urine is seen in the extraperitoneal space then the diagnosis of this bladder injury is evident. Repair with vicryl in two layers and insert a urinary catheter for 7–10 days are recommended [33].

Bowel injuries take place when trocar insertion or while dissecting hernia or utilizing an electrodiathermy. The incidence of bowel injuries is greatly reduced, but sadly not completely eliminated [35].

#### 3.2.3 Pneumoperitoneum

It is a common occurrence in TEP. The patient is placed in Trendelenburg position and escalating the insufflation pressures to 15 mmHg helps. Insertion of a Veress needle at Palmer's point can be used if the problem still persists [33].

#### 3.2.4 Nerve injuries

There are several nerves, viz., ilioinguinal nerve, iliohypogastric nerve, genito-femoral nerve with its medial and lateral branches (external spermatic nerve and lumboinguinal nerve) which are coursing in the myopectineal orifice of Fruchaud. These are prone to injury especially when a lateral dissection or mesh fixation is being performed. Patient might be suffering from a long-term pain and discomfort [36].

#### 3.2.5 Injury to cord structures

The cord structures might be harmed while dissecting the hernial sac from it. It leads to an eventual fibrotic narrowing of the vas. In a young patient, a complete transection of the vas needs to be done. Finding the vas before releasing any structure near the deep ring or floor of the extraperitoneal space can help to avoid this injury. It should be done gentle and direct and not grasping vas deferens with forceps [33].

#### 3.2.6 Bowel obstruction

A water-tight peritoneal closure should reduce the risk of postoperative intestinal obstruction. Laparoscopy is the procedure of choice to diagnose and treat this complication [37].

A risk reduction strategy is required to improve the clinical outcome and this must be adopted during the following surgical steps:

### 1. Placement of the trocar and working port

Identify and repair a pneumoperitoneum as a result of reckless insertion of the first trocar. If there any previous surgical scarring, a surgeon must be more attentive and alert in placing the trocar [33, 38].

The underlying intraperitoneal organs like bowel and bladder should not be damaged in trocar insertion process. In midline area, beware of the inferior epigastric vessels which cause copious bleeding. A laparotomy conversion might be considered if any visceral injury is found [39].

### 2. Dissection of the hernial sac

Identifying the correct anatomical landmarks is the next most decisive step, which is difficult for beginners. The first point is to recognize the pubic bone. After this, the rest of the landmarks can be discovered by putting this as reference point. Keep away the triangle of doom, which contains the iliac vessels and do not place tacks in the triangle of pain laterally [33, 39].

### 3. Mesh placement and fixation

Choose the appropriate size of the mesh to prevent a later recurrence due to an eventual “shrinkage” of the prosthesis [40]. Slashing the mesh is hindered because it can lead to a recurrence [33].

Several studies have recommended no fixation but have been found wanting. Tissue glues are being used to secure the mesh in place [39, 41, 42].

## 3.3 Post-operative complication

### 3.3.1 Seroma/hematoma formation

It is a common complication after laparoscopic hernia surgery and the incidence is within 5–25%. It resolves spontaneously around 4–6 weeks. A drain can be considered if there is an excessive bleeding or after extensive dissection [33].

### 3.3.2 Urinary retention

The reported incidence for this complication is 1.3–5.8%, usually found in elderly patients with prostatism. Put a catheter before the surgery and remove the next day morning [33, 43, 44].

### 3.3.3 Neuralgias

The incidence is reported to be between 0.5 and 4.6% and intra peritoneal onlay mesh had the highest incidence [43]. The most commonly involved nerves are lateral cutaneous nerve of thigh, genitofemoral nerve and intermediate cutaneous nerve of thigh. This complication can be prevented by avoiding fixing the mesh lateral to the deep inguinal ring in the region of the triangle of pain, safe dissection of a large hernial sac and no dissection of fascia over the psoas [33].

### 3.3.4 Testicular pain and swelling

Reported incidence is of 0.9–1.5%. Most are short-term. Orchitis was found occasionally but testicular atrophy was not a complication [33, 43, 44].



3.3.5 Mesh infection and wound infection

Wound infection rates are very low. Mesh infection is a very serious complication and care must be taken to maintain strict aseptic precautions during the entire procedure [33].

3.3.6 Recurrence

The risk of the need for repair for recurrent hernia following these initial hernia operations was lower for patients with open mesh repair and for patients with laparoscopic mesh repair [33, 45].

Laparoscopic has advantages in treating recurrent inguinal hernia including elimination of the missed hernia, identify a complex hernias, covering entire myopectineal orifice with mesh that buttressing the intrinsic collagen deficit so one of the cause of recurrent hernia could be overcome [14].

4. Conclusion

Laparoscopic inguinal hernia repair shows more benefits compared to open hernia repair. SILS inguinal hernia repair offers better cosmetic results; post-operative recovery time was significantly quicker and less painful. However, this approach is technically demanding and should be reserved for experienced single incision hernia surgeons. The invention of new surgical tools will hopefully overcome the current obstacles in SILS in the future.

Acknowledgements

We would also like to show our gratitude to the Grace Ika Yuwono of Western Sydney University for writing assistance and language editing.

Conflict of interest

The authors declare no conflict of interest.

Appendices and nomenclature

SILS	single incision laparoscopic surgery
TAPP	trans-abdominal pre-peritoneal
TEP	totally extra peritoneal
CDC	The Centers for Disease Control

IntechOpen

### **Author details**

Reno Rudiman<sup>1</sup> and Andika August Winata<sup>2\*</sup>

<sup>1</sup> Director of Digestive Surgery Department, Padjadjaran University, Bandung, West Java, Indonesia

<sup>2</sup> General Surgeon in Eka Hospital BSD, Indonesia

\*Address all correspondence to: [andhika.august@gmail.com](mailto:andhika.august@gmail.com)

### **IntechOpen**

© 2019 The Author(s). Licensee IntechOpen. This chapter is distributed under the terms of the Creative Commons Attribution License (<http://creativecommons.org/licenses/by/3.0>), which permits unrestricted use, distribution, and reproduction in any medium, provided the original work is properly cited. 

## References

- [1] Dindo D, Demartines N, Clavien PA. Classification of surgical complications: A new proposal with evaluation in a cohort of 6336 patients and results of a survey. *Annals of Surgery*. 2004;**240**(2):205-213
- [2] Azoury S, Farrow N, Hu Q, Soares K, Hicks C. Postoperative abdominal wound infection - epidemiology, risk factors, identification, and management. *Chronic Wound Care Management and Research*. 2015;**2**:137-148
- [3] Vecchio R, MacFayden BV, Palazzo F. History of laparoscopic surgery. *Panminerva Medica*. 2000;**42**(1):87-90
- [4] Haribhakti SP, Mistry JH. Techniques of laparoscopic cholecystectomy: Nomenclature and selection. *Journal of Minimal Access Surgery*. 2015;**11**(2):113-118
- [5] Bruhat MA, Chapron C, Mage G, Pouly JL, Canis M, Wattiez A, et al. The benefits and risks of laparoscopic surgery. *Revue Française de Gynécologie et d'Obstétrique*. 1993;**88**(2):84-88
- [6] Agha R, Muir G. Does laparoscopic surgery spell the end of the open surgeon? *Journal of the Royal Society of Medicine*. 2003;**96**(11):544-546
- [7] Khwaja HA, Bonanomi G. Bariatric surgery: Techniques, outcomes and complications. *Current Anaesthesia and Critical Care*. 2010;**21**(1):31-38
- [8] McCormack K, Scott NW, Go PM, Ross S, Grant A, Collaboration the EU Hernia Trialists. Laparoscopic techniques versus open techniques for inguinal hernia repair. *Cochrane Database of Systematic Reviews*. 2003;(1):Cd001785. DOI: 10.1002/14651858
- [9] Reichenbach DJ, Tackett AD, Harris J, Camacho D, Graviss EA, Dewan B, et al. Laparoscopic colon resection early in the learning curve: What is the appropriate setting? *Annals of Surgery*. 2006;**243**(6):730-737
- [10] Budzynski A, Matlok M, Pedziwiatr M, Budzynski P, Tusinski M, Zub-Pokrowiecka A, et al. SILS (single incision laparoscopic surgery) - new surgical approach to peritoneal cavity. *Advances in Medical Sciences*. 2011;**56**(1):18-24
- [11] Froghi F, Sodergren MH, Darzi A, Paraskeva P. Single-incision laparoscopic surgery (SILS) in general surgery: A review of current practice. *Surgical Laparoscopy, Endoscopy & Percutaneous Techniques*. 2010;**20**(4):191-204
- [12] Zinner MJ, Ashley SW. *Maingot's Abdominal Operation*. 12th edition. New York: Mc Graw-Hill; 2013
- [13] Bracale U, Melillo P, Pignata G, Di Salvo E, Rovani M, Merola G, et al. Which is the best laparoscopic approach for inguinal hernia repair: TEP or TAPP? A systematic review of the literature with a network meta-analysis. *Surgical Endoscopy*. 2012 Dec;**26**(12):3355-3366
- [14] de Beaux AC. *Abdominal Hernias in Core Topics in General & Emergency Surgery - E-Book: A Companion to Specialist Surgical Practice*. Edisi Ke-6th. London: Elsevier Health Sciences; 2018. pp. 81-93. hlm
- [15] Lal P, Kajla RK, Chander J, Ramteke VK. Laparoscopic total extraperitoneal (TEP) inguinal hernia repair: Overcoming the learning curve. *Surgical Endoscopy*. 2004;**18**(4):642-645
- [16] Loureiro MP, Trauczynski P, Claus C, Carvalho G, Bonin E, Cavazzola L. Totally Extraperitoneal endoscopic inguinal hernia repair using mini instruments:

Pushing the boundaries of minimally invasive hernia surgery. *Journal of Minimally Invasive Surgical Sciences*. 2013;**2**(3):8-12

[17] Köckerling F, Bittner R, Jacob DA, Seidelmann L, Keller T, Adolf D, et al. TEP versus TAPP: Comparison of the perioperative outcome in 17,587 patients with a primary unilateral inguinal. *Hernia. Surgical Endoscopy*. 2015;**29**(12):3750-3760

[18] Rambhia SU, Modi R. A comparative study between totally extraperitoneal and transabdominal preperitoneal laparoscopic inguinal hernia repair techniques. *International Surgery Journal*. 2017;**4**(2):663-670

[19] Tran HM, Tran K, Zajkowska M, Lam V, Hawthorne W. Single-incision laparoscopic intraperitoneal onlay mesh repair for the treatment of multiple recurrent inguinal hernias. *JSLs: Journal of the Society of Laparoendoscopic Surgeons*. 2014;**18**(3):1-8

[20] Yussra Y, Sutton PA, Kosai NR, Razman J, Mishra RK, Harunarashid H, et al. Single incision laparoscopic surgery (SILS) inguinal hernia repair - recent clinical experiences of this novel technique. *La Clinica Terapeutica*. 2013;**164**(5):425-428

[21] Daniel Sánchez López J, Garijo Alvarez J, García-Sancho L, Sánchez-Cabezudo Noguera F, Torres Jiménez J. Single incision laparoscopic surgery (SILS) for incarcerated incisional hernia: A new approach. *Cirugía Española*. 2009;**88**(3):199-200

[22] Yussra Y, A Sutton P, Kosai NR, Jarmin R, K Mishra R, harunarrashid H, et al. Single incision laparoscopic surgery (SILS) inguinal hernia repair- recent clinical experiences of this novel technique. *La Clinica Terapeutica*. 2013;**164**(5):425-428

[23] Hirano D, Minei S, Yamaguchi K, Yoshikawa T, Hachiya T, Yoshida T, et al.

Retroperitoneoscopic adrenalectomy for adrenal tumors via a single large port. *Journal of Endourology*. 2005 Sep;**19**(7):788-792

[24] Greaves N, Nicholson J. Single incision laparoscopic surgery in general surgery: A review. *Annals of the Royal College of Surgeons of England*. 2011;**93**(6):437-440

[25] Petter-Puchner AH, Brunner W, Gruber-Blum S, Glaser KS, Fortelny R. A systematic review of hernia surgery in SIL (single-incision laparoscopy) technique. *European Surgery*. 2014;**46**(3):113-117

[26] Rajapandian S, Bhushan C, Sabnis SC, Jain M, Raj PP, Parathasarthi R, et al. Single incision multiport versus conventional laparoscopic inguinal hernia repair: A matched comparison. *Journal of Minimal Access Surgery*. 2018;**14**(1):44-51

[27] Sajid MS, Khawaja AH, Sayegh M, Baig MK. A systematic review comparing single-incision versus multi-incision laparoscopic surgery for inguinal hernia repair with mesh. *International Journal of Surgery*. 2016;**29**:25-35

[28] Vidal O, Valentini M, Ginesta C, Marti J, Espert JJ, Benarroch G, et al. Laparoendoscopic single-site surgery appendectomy. *Surgical Endoscopy*. 2010 Mar;**24**(3):686-691

[29] Ece I, Yilmaz H, Yormaz S, Shahin M. Clinical outcomes of single incision laparoscopic surgery and conventional laparoscopic transabdominal preperitoneal inguinal hernia repair. *Journal of Minimal Access Surgery*. 2017;**13**:37-41

[30] Tran H. Safety and efficacy of single incision laparoscopic surgery for total extraperitoneal inguinal hernia repair. *JSLs: Journal of the Society of Laparoendoscopic Surgeons*. 2011;**15**(1):47-52



- [31] Buckley FP 3rd, Vassaur H, Monsivais S, Sharp NE, Jupiter D, Watson R, et al. Comparison of outcomes for single-incision laparoscopic inguinal herniorrhaphy and traditional three-port laparoscopic herniorrhaphy at a single institution. *Surgical Endoscopy*. 2014;**28**(1):30-35
- [32] Yang GP, Tung KL. A comparative study of single incision versus conventional laparoscopic inguinal hernia repair. *Hernia: The Journal of Hernias and Abdominal Wall Surgery*. 2015;**19**(3):401-405
- [33] Chowbey PK, Pithawala M, Khullar R, Sharma A, Soni V, Baijal M. Complications in groin hernia surgery and the way out. *Journal of Minimal Access Surgery*. 2006;**2**(3):174-177
- [34] Johansson B, Hallerback B, Glise H, Anesten B, Smedberg S, Roman J. Laparoscopic mesh versus open preperitoneal mesh versus conventional technique for inguinal hernia repair: A randomized multicenter trial (SCUR hernia repair study). *Annals of Surgery*. 1999;**230**(2):225-231
- [35] Felix EL, Harbertson N, Vartanian S. Laparoscopic hernioplasty: Significant complications. *Surgical Endoscopy*. 1999;**13**(4):328-331
- [36] Kraus MA. Nerve injury during laparoscopic inguinal hernia repair. *Surgical Laparoscopy and Endoscopy*. 1993;**3**(4):342-345
- [37] Cueto J, Vázquez JA, Solís MA, Valdéz G, Valencia S, Weber A. Bowel obstruction in the postoperative period of laparoscopic inguinal hernia repair (TAPP): Review of the literature. *JSLs: Journal of the Society of Laparoendoscopic Surgeons*. 1998;**2**(3):277-280
- [38] Dulucq JL, Wintringer P, Mahajna A. Totally extraperitoneal (TEP) hernia repair after radical prostatectomy or previous lower abdominal surgery: Is it safe? A prospective study. *Surgical endoscopy*. 2006;**20**(3):473-476
- [39] Lomanto D, AN K. Managing intra-operative complications during totally extraperitoneal repair of inguinal hernia. *Journal of Minimal Access Surgery*. 2006;**2**:165-170
- [40] Schumpelick V, Klinge U, Welty G, Klosterhalfen B. Meshes within the abdominal wall. *Der Chirurg; Zeitschrift für alle Gebiete der operativen Medizin*. 1999;**70**(8):876-887
- [41] Ferzli GS, Frezza EE, Pecoraro AM Jr, Ahern KD. Prospective randomized study of stapled versus unstapled mesh in a laparoscopic preperitoneal inguinal hernia repair. *Journal of the American College of Surgeons*. 1999;**188**(5):461-465
- [42] Smith AI, Royston CM, Sedman PC. Stapled and nonstapled laparoscopic transabdominal preperitoneal (TAPP) inguinal hernia repair. A prospective randomized trial. *Surgical Endoscopy*. 1999;**13**(8):804-806
- [43] Fitzgibbons RJ Jr, Camps J, Cornet DA, Nguyen NX, Litke BS, Annibali R, et al. Laparoscopic inguinal herniorrhaphy. Results of a multicenter trial. *Annals of Surgery*. 1995;**221**(1):3-13
- [44] Phillips EH, Arregui M, Carroll BJ, Corbitt J, Crafton WB, Fallas MJ, et al. Incidence of complications following laparoscopic hernioplasty. *Surgical Endoscopy*. 1995;**9**(1):16-21
- [45] Kokotovic D, Bisgaard T, Helgstrand F. Long-term recurrence and complications associated with elective incisional hernia repair. *Journal of the American Medical Association*. 2016;**316**(15):1575-1582