

# We are IntechOpen, the world's leading publisher of Open Access books Built by scientists, for scientists

6,900

Open access books available

186,000

International authors and editors

200M

Downloads

Our authors are among the

154

Countries delivered to

TOP 1%

most cited scientists

12.2%

Contributors from top 500 universities



WEB OF SCIENCE™

Selection of our books indexed in the Book Citation Index  
in Web of Science™ Core Collection (BKCI)

Interested in publishing with us?  
Contact [book.department@intechopen.com](mailto:book.department@intechopen.com)

Numbers displayed above are based on latest data collected.  
For more information visit [www.intechopen.com](http://www.intechopen.com)



# Maternal Filovirus Infection and Death from Marburg and Ravn Viruses: Highly Lethal to Pregnant Women and Their Fetuses Similar to Ebola Virus

*David A. Schwartz*

## Abstract

Ebola virus and the marburgviruses are distinct filoviruses that share common clinical presentations and clinical management protocols. However, the marburgviruses are not as well known as is their close relative, Ebola virus, and are a much less frequent cause of human outbreaks. Marburg virus disease (MVD) is caused by two marburgviruses that are clinically indistinguishable—Marburg virus and Ravn virus. There is scant information available concerning MVD in pregnancy, but it appears clear that, similar to Ebola virus, MVD infection is associated with an extremely high maternal and fetal mortality rate. This chapter will examine what is known about Marburg and Ravn virus infections in pregnant women, their clinical outcomes, and the pathogenesis of MVD in experimental animal models of infection. These data will be compared with the more comprehensive information available regarding Ebola virus disease in pregnancy including its effects on pregnant women and the fetus.

**Keywords:** Ebola virus, Marburg virus, Ravn virus, pregnancy, maternal death, fetal death, filovirus, maternal infection, hemorrhagic fever, maternal mortality, maternal morbidity, fetal mortality, West African Ebola epidemic, epidemiology

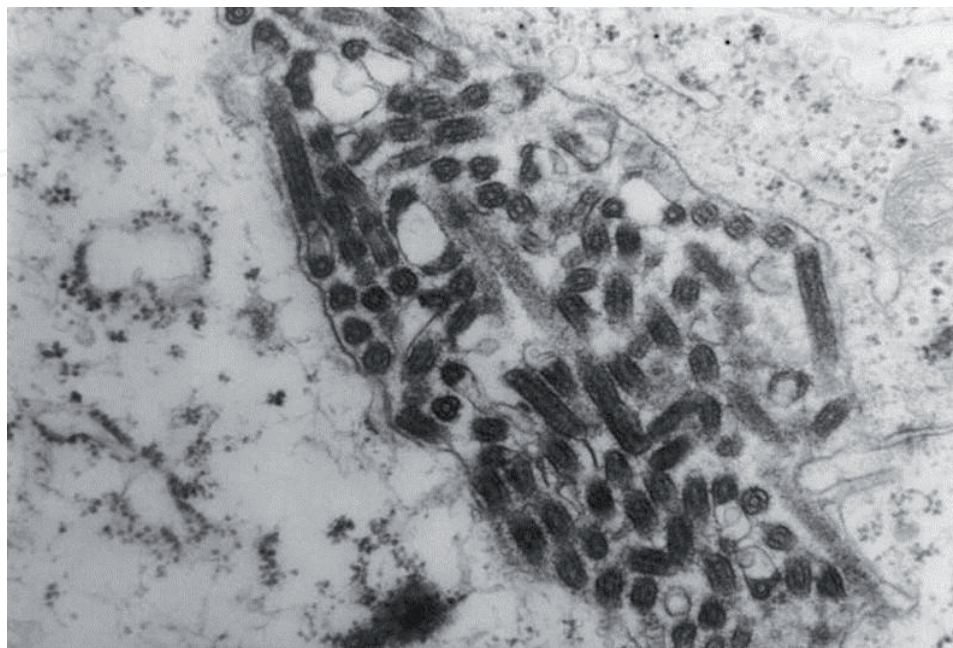
## 1. Introduction

The Ebola and Marburg viruses are distinct filoviruses that share common clinical presentations and clinical management protocols. However, the Marburg virus is not as well-known as its relative, the Ebola virus. The largest Ebola epidemic in history occurred in West Africa from 2013 to 2015 in which 28,616 persons were reported to be infected. Following a small outbreak of 54 probable and confirmed cases in the Équateur Province of the Democratic Republic of the Congo (DRC) from May to June 2018, a second and larger epidemic has occurred in the Kivu and North Ituri Provinces since August 2018 [1]. This epidemic has infected 2592 persons as of July 2019 and is the second largest Ebola epidemic in history. In contrast to the Ebola virus, Marburg virus disease (MVD) occurs much less frequently. MVD is caused by two marburgviruses that are clinically indistinguishable—the Marburg

virus (MARV) and Ravn virus (RAVV). Including occurrences of MVD in less than 5 persons, there have been 13 outbreaks of MVD, with the largest reported from DRC between 1998 and 2000 (154 persons infected) and in Angola between 2004 and 2005 (252 persons infected) [2]. As can be seen, the scale of MVD outbreaks has been much less than those of its filovirus relative Ebola virus.

## 2. The marburgviruses

The marburgviruses are single-stranded RNA viruses belonging to the family *Filoviridae*, which also includes the *Ebolavirus* genus. The genus *Marburgvirus* comprises a single species, *Marburg marburgvirus*, that includes two variants - the Marburg virus (MARV) and the Ravn virus (RAVV) [3, 4]. Similar to other members of the family *Filoviridae*, marburgvirions have a filamentous configuration that appears by electron microscopy to resemble a shepherd's crook, or in the shape of a "U" or a "6"; coiled, toroid, or branched forms can be seen (**Figure 1**). The marburgviruses cause a severe viral illness in humans termed Marburg virus disease, or MVD (formerly termed Marburg hemorrhagic fever). Illness due to the marburgviruses is clinically indistinguishable from Ebola virus disease (EVD). Although Marburg virus disease and Ebola virus disease have historically been labeled as hemorrhagic fevers, hemorrhage is found in less than 50% of patients [5]. According to some authors, they may be considered as gastrointestinal diseases that develop severe systemic organ involvement including hemorrhages [6]. After an incubation period that varies between 4 and 10 days, infected individuals abruptly develop flu-like symptoms characterized by fever, chills, malaise, and myalgia. This is followed by signs and symptoms indicating systemic involvement, including prostration and gastrointestinal symptoms (anorexia, nausea, vomiting, abdominal pain, and diarrhea), respiratory complaints (chest pain, shortness of breath, and cough), vascular findings (conjunctival injection, postural hypotension, and edema), and neurological symptoms (headache, confusion, and coma). The typical hemorrhagic manifestations of



**Figure 1.** Transmission electron micrograph demonstrating the typical filovirus morphology of Marburg virus. This specimen was obtained from an infected person who acquired the infection in 1975 while traveling through Rhodesia (now Zimbabwe). Photograph courtesy of the US Centers for Disease Control and Prevention, Atlanta, USA.

MVD include purpura, ecchymoses, petechiae, maculopapular rash, and hematomas, with death rapidly ensuing as a result of multiple organ dysfunction syndrome (MODS) and disseminated intravascular coagulation (DIC), hypotension, fluid redistribution, and focal tissue necrosis. MVD (and EVD) can be confused with other infectious diseases occurring in Equatorial Africa including other hemorrhagic fevers, falciparum malaria, rickettsial diseases, typhoid fever, and more.

### 3. Epidemiology of Marburg virus disease

The majority of cases of primary MVD acquired in Africa have been associated with persons visiting caves or working in mines, locations where bats are common. Egyptian fruit bats (rousette bats, *Rousettus aegyptiacus*) (**Figure 2**) have been found to represent a major natural reservoir and source of marburgviruses [7]; the bats do not develop illness from the virus. Infected Egyptian rousette bats may shed marburgviruses in their saliva, urine, and feces as they feed on fruit which can then be transmitted to humans. Direct contact with infected bats can also transmit the virus, such as through bites. In December 2018 it was disclosed that five Egyptian rousette bats tested positive for Marburg virus in Sierra Leone—the first time that the virus was identified in West Africa [8]. Two of the four strains identified among the five Marburg-positive bats in Sierra Leone have genetic similarity to the strain of MARV that caused the MVD outbreak in Angola. This was the first time scientists detected these Angolan strains in bats [9]. Another risk factor for acquiring MVD is physical contact with nonhuman primates, although there has been just one outbreak of MVD, in 1967, that resulted from contact with infected monkeys. Transmission of the virus can also occur by handling ill or dead infected wild animals. Mathematical models of the potential geographic distribution of the marburgviruses have indicated that the potential range of the virus includes a broad distribution across the arid woodlands of Equatorial Africa, with possible distribution through eastern and southern Africa as well [10].



**Figure 2.**  
An Egyptian fruit bat (*Rousettus aegyptiacus*) clings to pieces of orange at the Cotswold Wildlife Park, England. Photograph from Adrian Pingstone and Wikipedia.



The marburgviruses are transmitted from person-to-person through direct and unprotected contact with blood, body fluids, and tissues of infected persons. Risk factors for acquiring secondary MVD include close contact with severely ill patients or their body fluids in the acute phase of the disease, either at home or in a hospital, thus placing caregivers at risk for acquiring the infection. In addition, unsafe burial practices are common routes of infection. These are the identical mechanisms for transmission for Ebola virus. MVD has not been reported to be transmitted via the aerosol route. Women who are pregnant and infected with either marburgviruses or Ebola virus can be especially infectious—the placenta has a high viral load, and maternal blood, vaginal secretions, amniotic fluid, urine, sweat, saliva, feces, vomit, and breast milk are all potential sources of virus [11]. Products of conception as occur in miscarriages can also be infectious, as can fetal tissues.

Based upon the history of primary MVD infection occurring in association with exposure to bat-infested caves and mines and additional environmental and occupational risk factors for acquiring the infection, it appears unlikely that Marburg virus infection of a pregnant woman would occur as the index case of an outbreak. Thus, unlike the situation of some viral infections (notably hepatitis E) where infections in pregnant women can represent the index cases of a community-wide outbreak [12], MVD occurring in pregnant women would likely represent secondary infections within the community, prompting an epidemiological investigation to identify the index case(s). During the West Africa Ebola epidemic, pregnant women often became infected through the traditional female roles of caregiver to the sick as well as through preparation of the dead and via unsafe burials [13]. The high rate of transmissibility of filoviral infections was demonstrated in one Liberian village named Joe Blow Town. There, all of the mothers in the town became infected and died after acquiring EVD after caring for a woman who was infected and, following her death, preparing her body and then bathing in the water that had been used to wash her corpse [14].

Following acute infection, both marburgviruses and Ebola virus can persist in a variety of bodily fluids. Ebola virus and Marburg virus have both been found by culture from ocular aqueous humor 2 and 3 months after disease onset, respectively. Ebola virus RNA has been identified in breast milk for up to 21 days after the onset of the disease and in vaginal secretions up to 33 days after its onset. In one report, a 9-month-old infant is believed to have acquired Ebola virus infection through breastfeeding from a mother who did not report having a febrile illness—persistent Ebola virus RNA was identified in both the mother's breast milk and in the father's seminal fluid [15].

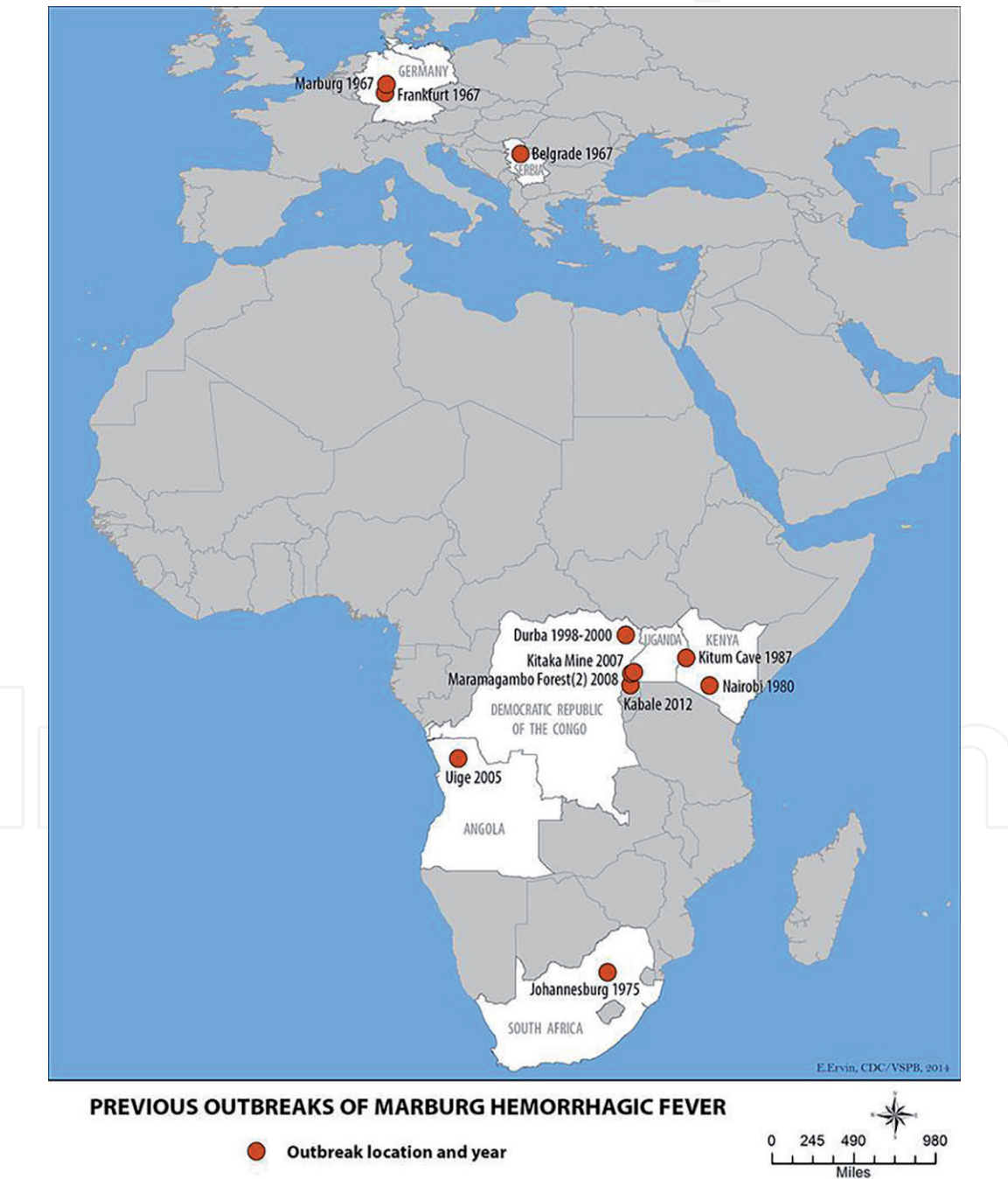
In men, Ebola virus has been identified in the semen of survivors for many months after acute infection, with some having persistence of Ebola RNA for up to 18 months [16]. It is likely that the marburgviruses would also demonstrate persistence in seminal fluid of male survivors. Sexual transmission of marburgviruses was reported in 1968 after the initial outbreak of Marburg virus disease [17]. In a study in crab-eating macaques, it was found by Coffin et al. [18] that experimentally infected males had persistent MARV infection of the seminiferous tubules, an immunologically privileged site. Affecting primarily the Sertoli cells, this viral persistence resulted in severe testicular damage including spermatogenic cell depletion, inflammation, and breakdown of the blood-testis barrier [18].

#### **4. Outbreaks of Marburg virus disease**

Marburg virus disease was initially discovered in 1967 when 31 persons unexplainably became ill in the cities of Marburg and Frankfurt am Main in Germany and Belgrade in the former Yugoslavia. The illness was traced to exposure to tissues or cell cultures obtained from a group of imported African green monkeys (grivets

or *Chlorocebus aethiops*) that were originally from Uganda and had been maintained for making antisera in commercial laboratories. All the patients in Marburg were employees of Behringwerke, which produced sera and vaccines, and the infected persons in Frankfurt were employees of the Paul Ehrlich Institute, a control institute for sera and vaccines. All of the persons who developed a primary infection at the three locations had direct contact with blood, organs, and cell cultures from *Cercopithecus aethiops* monkeys. This initial outbreak resulted in 25 primary MARV infections including 7 deaths and 6 nonfatal secondary cases occurring in the persons and who treated them and their family members [19, 20].

Since this initial recognition of the virus in Europe, there have been at least 12 additional episodes or outbreaks of MVD in humans (**Figure 3**). Numbers of infected individuals have varied, some episodes having only one person involved,



**Figure 3.** Distribution of outbreaks of Marburg virus disease from 1967 to 2012. The 2014 infection of a single individual in Uganda and the 2017 outbreak in Kween, Uganda, are not indicated on this map. Photograph from the US Centers for Disease Control and Prevention, Atlanta, USA.

others involving an infected individual and a care provider, while in one outbreak as many as 252 persons were infected.

In February of 1975, the first outbreak of MVD to occur in Africa was recognized in a young Australian man who acquired the infection while traveling in Rhodesia (now Zimbabwe). He died in a Johannesburg hospital on the 7th day of infection. Two secondary cases developed—a traveling companion and a nurse—and both survived [21].

In 1980 a French electrical engineer working in Nzoia, Kenya, in a sugar factory acquired MVD and died shortly after admission to Nairobi Hospital. His attending physician also contracted MVD but survived [22]. Although it remains unknown how he acquired his infection, he worked at the base of Mount Elgon, where Kitum Cave is located. Kitum cave, 165 meters long and up to 60 meters wide with walls rich in salt, is inhabited by thousands of Egyptian fruit bats as well as by other bat species.

A 15-year-old boy from Denmark developed MVD infection during a visit to Kenya in 1987. He had visited a cave—Kitum Cave—on Mount Elgon and subsequently traveled to Mombasa where he was noted to be ill. He died following transfer to Nairobi Hospital [23]. The causative agent was later found to be a new strain of MVD—the Ravn virus—and thus this was first report of this marburgvirus agent and its causes with human disease.

Two laboratory-acquired infections occurred with MARV occurred in the former Soviet Union in 1988 and 1990. Scant information is available regarding these events, although in one case it is known that the individual became infected after an accidental self-inoculation of MARV with a syringe while working with guinea pigs and which resulted in his death [24, 25].

A major epidemic of MVD occurred in 1998 among gold miners from the Goroubwa mine in the DRC. This was the largest epidemic to have occurred up to that time and continued sporadically in the cities of Durba and Watsa up to 2000. A total of 154 cases occurred (48 confirmed and 106 suspected), with 52% in young male miners. The large majority (94%) of infected miners worked underground, and cessation of the outbreak coincided with the flooding of the mine [26]. Retrospective virologic and epidemiologic analysis revealed evidence for multiple introductions of MARV and RAVV viruses into the population as there were at least nine genetically distinct lineages of virus circulating during the outbreak [26]. This epidemic had a case fatality rate of 83% and importantly was the first MVD outbreak to report infection of pregnant women and their infants (see below). It also significantly affected children and early teens—for the 145 patients for whom demographic data were available, 18 of them (12%) were under the age of 15 years including 15 infants [26].

The largest outbreak of MVD to develop in Africa began in October 2004 in Angola [27, 28]. Centered in the northeastern Uige Province, this epidemic was not identified as being due to MVD until March 2005 following the transmission of the disease to healthcare workers, which alerted the community to the possibility of Marburg or Ebola virus disease. The outbreak persisted until July 2005 [29], and eventually there were 252 persons infected, of whom 227 died—a case fatality rate of approximately 90% [29, 30]. Case finding and follow-up during this outbreak was hampered by several factors. Individuals and patients often resisted medical assistance and epidemiologic studies because of circulating rumors that the foreign teams were responsible for bringing or spreading the virus. Clandestine practices including families hiding ill members, avoiding going to the hospital, immediately burying the deceased, utilizing native healers, and bringing patients to hospitals just before death suggest that the true severity of the outbreak and data on morbidity and lethality might never be known. In addition, patient records were maintained only upon admission and not during hospitalization [31]. Approximately 75% of the reported cases had occurred in children aged 5 years or younger [32]. There were no available data on the number of pregnant women, if any, who



became infected during this large outbreak. However, a report from Jeffs et al. and Médecins Sans Frontières (MSF) [33] working at the Uige Provincial Hospital, the initial epicenter of the outbreak, confirmed that screening for MVD was performed in the maternity ward of the hospital. Assessment of pregnant women was particularly challenging, and many of these women were febrile and fulfilled the suspected case definition for MVD, especially as bleeding during pregnancy is common. The authors [33] stated:

*“It was often difficult to rule out MHF without testing, but, because many women required constant obstetric assistance, it would have been difficult to admit them all to the formal Marburg ward for assessment. Therefore, a well-equipped isolation area was set up in the maternity ward, including a delivery area and a ward area. Maternity staff were trained in infection control, and separate teams were assigned to the isolation area and the normal maternity ward. Any patient testing positive for MHF was admitted to the Marburg ward.”*

Thus, it would appear that there were possible cases of pregnant women with infection during the Uige outbreak, but that cannot be confirmed.

Between 2007 and 2008, there were two outbreaks of MVD in Southwest Uganda—one among miners working in Kitaka Mine in the Kamwenge District [34] and the other in two tourists, one Dutch and the other American, that had separately visited Python Cave in Queen Elizabeth National Park [35, 36]. Both Python Cave and the Kitaka mine are inhabited by Egyptian fruit bats (*Rousettus aegyptiacus*) [37].

An outbreak of MVD was declared in October 2012 in the western Uganda districts of Kabale, Ibanda, and Kamwenge [38] that resulted in 20 confirmed or probable cases and 9 deaths. This outbreak was also linked to mining activity in the Ibanda District.

In September 2014 a 30-year-old male healthcare worker (radiographer) developed symptoms of a viral hemorrhagic fever. Following 1 week of illness, he was admitted to a district health facility in the Mpigi District and later transferred to a hospital in Kampala, Uganda. He expired 2 weeks after the onset of illness, and it was later confirmed that he was infected with MARV. The source of his infection was not identified, and there were no other infected persons identified [37, 39].

In October 2017 an outbreak of MVD occurred in the Kween District of Uganda, near the border with Kenya [40, 41]. The initial three infected persons all belonged to the same family and died. The (probable) initially infected person was a 35-year-old herdsman who frequently hunted near the area of Kaptum, which is known for its bat-infested caves. A healthcare worker also became infected.

## 5. Marburg virus disease in pregnant women, fetuses, and infants

There is very little information available on the effects of MVD on pregnant women, their fetuses, and infants, including clinical obstetrical and neonatal outcomes following MVD infection and the persistence of virus post-infection. Similar to some of the initial outbreaks of Ebola virus disease, the pregnancy status of women suspected or confirmed as having MVD was not generally recorded during outbreaks and may not have even been evaluated at the time of their illness [1].

Based upon the reported cases of filovirus infections occurring in pregnancy, there is no evidence that women who are pregnant are more susceptible to becoming infected with either marburgviruses or the Ebola virus [6]. However, it does appear that once they acquire a filovirus infection, pregnant women are more likely



to have a fatal outcome than are nonpregnant individuals [1, 6]. Pregnant women with EVD and MVD are at high risk of spontaneous abortion and stillbirth. EVD is associated with pregnancy-related hemorrhage, and although it has not been reported, it can probably also complicate MVD infection. Evidence from a number of reports confirms that hematogenous spread of *Filovirus* infection through the placenta is the most common source of fetal infection, as high viral titers have been detected in placental tissue not only for Ebola but also for other hemorrhagic fever viruses [11].

The initial report of MVD occurring in pregnant women and fetuses was derived from the outbreak occurring in the gold mining village of Dursa and district capital of Watsa in the DR Congo in 1998–1999 [6, 26]. During this outbreak, at least three pregnant women with MVD were reported, all of whom died. The infection was also lethal for their infants—one woman had a miscarriage, and another delivered an infant who died 7 h after birth. Thus, the only information available on the clinical effects of MVD occurring in pregnant women indicates a 100% case fatality rate among infected mothers and their infants. This is higher than the mortality rates for pregnant women in the initial 1976 outbreak of Ebola virus in Yambuku, Zaire, in which 9 of 82 Ebola-infected pregnant women survived—a case fatality rate of 89%. During that EVD outbreak, ten live infants were born to mothers who subsequently died of the infection. All of these children also died within 19 days [42].

The 100% maternal and infant case fatality rate that has been reported for MVD is most similar to the Ebola outbreak of 1995 in Kikwit, Zaire, in which only 1 of 15 EVD-infected women survived (case fatality rate of 95.5%). All of the pregnant women during the Kikwit EVD outbreak presented with severe hemorrhage. In addition to the maternal deaths that occurred during the Kikwit outbreak, ten women (66%) had spontaneous abortions, and one woman delivered a premature stillborn infant. Four of the pregnant women died during the third trimester of pregnancy. The single maternal survivor among this group had a curettage because of an incomplete abortion after 8 months of amenorrhea [42, 43].

The first (and only) report of the potential effect of MVD on the post-infection reproductive health of female survivors of the disease was reported from the initial outbreak of MAVN in Marburg, Frankfurt, and Belgrade in 1967 [20]. There were a total 32 persons who became infected at the three geographic locations, of whom 12 were female. Two of the 12 died, and 4 of the survivors had secondary infections that resulted in milder disease symptoms, compared with cases of primary infection. Three women who had been infected and survived became pregnant 1–2 years later. In all three cases, the pregnancy outcomes were normal. The placentas were tested for Marburg virus and were found to be negative. Umbilical cord blood was tested for antibodies to MARV and was positive for IgG but negative for IgM. When the infants were tested for MARV antibodies 1 year after birth, they were negative [20].

Because clinical disease caused by the marburgviruses and Ebola virus is clinically indistinguishable, it is reasonable to postulate that they have a similar, if not close to or even an identical, pathophysiology when affecting pregnant women and their fetuses. The first report of EVD occurring in pregnant women originated in the first reported outbreak of this disease in Zaire (now DRC) in 1976 [44]. This outbreak in the rural town of Yambuku infected a total of 316 persons, causing 280 deaths over a period of 11 weeks. There were 73 deaths among the 82 pregnant women infected with Ebola virus, a case fatality rate (CFR) of 89% [44]. Analysis of all EVD outbreaks prior to the West Africa Ebola epidemic reveals that there were 112 cases of pregnant women reported who had acquired the infection—an aggregate maternal mortality rate of 86% [11].

At the start of the West Africa epidemic and based on prior EVD outbreaks, the prognosis was considered to be so poor for pregnant women and their fetuses that it was predicted that greater than 90% of infected pregnant women and 100% of fetuses would die as a result of EVD. In an interview performed early in the outbreak with a representative from a nongovernmental organization, it was opined that the survival rate for expectant mothers was virtually zero [1]. In a report published in 2015, the probability for maternal and infant survival of EVD was summarized as follows: “Present data suggests that maternal mortality remains high (approximately 95%) and peri-natal mortality virtually 100% for infected pregnant women” [45]. Fortunately, by the close of the epidemic, the maternal mortality rate for EVD, although high, was significantly less than some had originally expected. An accurate assessment of the maternal mortality data resulting from this multinational epidemic has been made difficult by multiple factors—it was not routine practice to test infected women for pregnancy, there were infected pregnant women who did not receive care due to mobility, there were financial or social issues or the inability to reach treatment centers, case surveillance and reporting infrastructure was weakened, and many early pregnancy cases were simply missed. Within these limitations, the combined published direct mortality rates among pregnant women with EVD have been estimated to be 44% [11]. However, in addition to direct deaths caused by Ebola virus infection, many pregnant women probably died during the epidemic from indirect causes resulting from an inability to access maternal health care, diversion of already limited resources to care for persons with EVD, stigmatization and fear of attending health care facilities.

In contrast, the fetal survival rate was close to what had been expected—only one neonate is known to have survived infection. The sole surviving newborn with EVD, Baby Nubia, had received experimental treatments from Médecins Sans Frontières including ZMapp and the broad-spectrum antiviral GS-5734 outside of the clinical trial protocol; her mother had been denied access to potentially protective vaccination due to her pregnant condition and died of Ebola infection shortly after delivery [1].

The West Africa Ebola epidemic of 2013–2015, which officially infected 28,616 persons but almost certainly infected many more, resulted in a significant increase of information about filovirus infections occurring during pregnancy [46–48]. Much of these data are the subject of a multiauthored 2019 book, *Pregnant in the Time of Ebola: Women and Their Children in the 2013–2015 West African Epidemic* [48].

In addition to maternal, fetal, and infant mortalities occurring as a result of acute EVD, information regarding the subsequent effects of EVD on pregnancy and the fetus are still being analyzed, especially among female survivors and the PREVAIL Study. Fallah et al. [49] examined pregnancy outcomes in two locations (Margibi and Montserrado) for 70 female survivors of acute EVD in Liberia. Of these 70 survivors, 15 women miscarried (6 in Montserrado, 9 in Margibi); 4 neonates were stillborn (defined as fetal death  $\geq 28$  weeks’ gestation, 3 in Montserrado, 1 in Margibi); and there were two EVD survivors who decided to terminate their pregnancies (both in Montserrado). Six women became pregnant within 2 months of being discharged from the Ebola treatment unit—three of these resulted in stillbirths. One additional stillbirth occurred in an EVD survivor who had conceived 6 months after recovery. All 15 miscarriages that were identified in this cohort occurred in women who became pregnant 4 months or longer after discharge. Overall the frequency of miscarriage in clinically identified pregnancies for this cohort of Ebola survivors was 22.1% (15/68), a rate slightly higher than that expected for healthy women in developed countries (between 10 and 15%) and women in West Africa (11–13%) [49].

One of the significant findings pertaining to pregnancy arising from the West Africa Ebola epidemic was the potential long-term persistence of filovirus in the tissues of women following clinical recovery from acute infection. The investigation of a family cluster of Ebola virus disease infections that occurred in Liberia provided evidence for long-term persistence of virus in some infected women [50]. Following the infection of a 15-year-old boy in Liberia with EVD in November 2015 and his subsequent death, the evaluation of other family members revealed that his 8-year-old brother had Ebola RNA in his blood, a 5-year-old brother had no evidence of infection, and a 2-month-old brother born in September 2015 had IgG antibodies to Ebola virus that were attributed to maternal transfer. The father had Ebola virus RNA in his blood and an antibody profile that was positive for Ebola-specific IgG and IgM that was consistent with previous EVD infection. The mother/wife had provided care for her adult brother in July 2014—he had died of presumptive EVD after he cared for EVD patients as a nurse's aide. Shortly after her brother died, she developed clinical illness that was compatible with EVD, but did not seek care, and had a miscarriage in August 2014. She was found to have a high titer to IgG and low titer to IgM anti-Ebola antibodies. In addition, with the results of genomic analysis, these findings indicated that the most plausible explanation for this family cluster of Ebola virus infection was that the mother/wife had survived an episode of EVD in 2014 following her acquiring it from providing care for her infected brother. She then developed persistent Ebola infection, transmitting the virus to her three family members 1 year later [16, 50].

## 6. Non-human primate models of Marburg virus disease

Pathological examination of the placenta and fetus and in those cases of maternal death, autopsy of the mother, have proved very helpful in understanding of the mechanisms of maternal-fetal transmission of emerging infectious diseases. This has been most recently demonstrated with the role of placental pathology in helping to understand vertical transmission of the newly emergent TORCH virus infection caused by *Zika virus* [51–54]. However, in the case of filovirus infections such as EVD and MVD, the recommendations from international organizations against pathology examination of placentas, autopsies, and fetal tissues to minimize risk of infection to healthcare workers have diminished our knowledge of the effects on pregnant women, fetuses, and neonates [11].

Experimental studies of laboratory animal infection with infectious agents can be a major source of information on the mechanisms of maternal-fetal transmission of disease, as well as the role of the placenta in vertical infections. There have been many experimental studies of infection with marburgviruses using a variety of non-human primates (NHPs)—these have included cynomolgus macaques (*Macaca fascicularis*), rhesus macaques (*Macaca mulatta*), African green monkeys (*Cercopithecus aethiops*), and squirrel monkeys (*Saimiri* sp.) [31]. Unfortunately, they have not addressed pregnancy or vertical viral transmission. There is, in addition, a paucity of information available on the effects of experimental MVD infection in non-human primates on the pathological effects on the female genital organs in nonpregnant animals, despite the performance of many autopsies.

However, some recent data are available specifically on the pathology of MVD of the female genitalia in NHPs. Four female rhesus macaques were experimentally infected via the intramuscular route with a target dose of 1000 plaque-forming units of Marburg virus/H.sapiens-tc/AGO/2005/Ang-1379v (BioSample identifier SAMN05916381), passage Vero E6p4 [55]. Microscopic



examination of ovaries from three of the four MARV-infected macaques revealed degeneration and necrosis of circumferential stromal cells surrounding secondary and tertiary follicles and rare intracytoplasmic viral inclusions. In all four female macaques, immunohistochemical staining demonstrated that theca interna cells were strongly and diffusely positive for GP (Marburg glycoprotein) and VP40 (Marburg matrix protein) antigens, as well as positivity in scattered clusters of interstitial ovarian stromal cells located between the follicles. In one of the infected female macaques, there was positive staining noted in clusters of granulosa cells in secondary and tertiary follicles. Electron microscopic examination revealed viral nucleocapsids present that formed cytoplasmic tubular and granular inclusions within interstitial stromal cells and theca interna cells and the presence of mature free virus particles and in one macaque confirmed the occurrence of MARV infection in granulosa cells. The virus had also reached the fallopian tubes—all four females had positive findings of immunostaining and in situ hybridization in the epithelial cells (and stroma) of the fimbriae of the oviduct. One macaque had clusters of viral-positive smooth muscle cells in the myosalpinx. In one of the macaques, the uterus demonstrated that low to moderate numbers of vacuolated, apoptotic, and inclusion-bearing macrophages were present in the endometrial stroma; the uteri from the remaining three macaques were histologically normal. Virus was present in the uterine tissues, as evidenced by multifocal to diffuse positive immunostaining and MARV genomic in situ hybridization of the superficial endometrial stroma, and with multifocal positive staining in one of the females. Ultrastructural analysis showed small numbers of viral nucleocapsids present that formed cytoplasmic tubular and granular inclusions in several cell types, including endometrial stromal cells, fibroblasts, and endothelial cells, but not smooth muscle [55].

## 7. Conclusions

*Marburg virus* disease is a life-threatening infection to pregnant women and their infants and has fortunately been much less prevalent than its close filovirus relative, Ebola virus disease. However, mostly as a result of the West Africa Ebola epidemic, there is much more information available regarding the pathophysiology and clinical outcomes of EVD in pregnant women and their fetuses. It is likely that both the marburgviruses and Ebola virus have the same mechanism(s) of maternal-fetal transmission. Both filovirus species can persist in body tissues of survivors and be sexually transmitted. Prior to the West Africa Ebola epidemic, the case fatality rate for EVD in pregnant women varied up to greater than 90%, and all fetuses and neonates from infected women died. Fortunately, the maternal mortality rate for EVD declined during the West Africa epidemic, and as a result of the development of effective forms of therapy, the first neonatal survivor was reported. In contrast, the only reported data for maternal and neonatal survival following MVD shows a 100% mortality rate for pregnant women and their infants. Thus, based upon available, albeit limited, data, MVD has a higher case fatality rate in pregnant women than does EVD. The geographic range of MVD cases has been geographically restricted within Africa to Kenya, Uganda, DR Congo, Angola, Rhodesia, and South Africa. However, the recent announcement that the bat host for marburgviruses (*Rousettus aegyptiacus*) was found to be positive for the virus in Sierra Leone has added a potential new chapter to the risk for additional African outbreaks in a previously uninvolved part of the continent.

IntechOpen

IntechOpen

### **Author details**

David A. Schwartz

Medical College of Georgia, Augusta University, Augusta, Georgia, USA

\*Address all correspondence to: [davidalanschwartz@gmail.com](mailto:davidalanschwartz@gmail.com)

### **IntechOpen**

© 2019 The Author(s). Licensee IntechOpen. This chapter is distributed under the terms of the Creative Commons Attribution License (<http://creativecommons.org/licenses/by/3.0>), which permits unrestricted use, distribution, and reproduction in any medium, provided the original work is properly cited. 

## References

- [1] Schwartz DA. Clinical trials and administration of Zika virus vaccine in pregnant women: Lessons (that should have been) learned from excluding immunization with the Ebola vaccine during pregnancy and lactation. *Vaccines (Basel)*. 2018;**6**(4):E81. DOI: 10.3390/vaccines6040081
- [2] CDC. Outbreaks Chronology: Marburg Hemorrhagic Fever. 2014. Available from: <https://www.cdc.gov/vhf/marburg/outbreaks/chronology.html>. [Accessed: 14 May 2019]
- [3] Spickler A. Ebolavirus and Marburgvirus Infections. 2016. Available from: [http://www.cfsph.iastate.edu/Factsheets/pdfs/viral\\_hemorrhagic\\_fever\\_filovirus.pdf](http://www.cfsph.iastate.edu/Factsheets/pdfs/viral_hemorrhagic_fever_filovirus.pdf). [Accessed: 1 June 2019]
- [4] Schindell BG, Webb AL, Kindrachuk J. Persistence and sexual transmission of filoviruses. *Viruses*. 2018;**10**(12):683. DOI: 10.3390/v10120683
- [5] Feldmann H, Geisbert TW. Ebola haemorrhagic fever. *Lancet*. 2011;**377**:849-862. DOI: 10.1016/S0140-6736(10)60667-8
- [6] Bebell LM, Riley LE. Ebola virus disease and Marburg disease in pregnancy: A review and management considerations for filovirus infection. *Obstetrics and Gynecology*. 2015;**125**(6):1293-1298. DOI: 10.1097/AOG.0000000000000853
- [7] Towner JS, Amman BR, Sealy TK, Carroll SA, Comer JA, Kemp A, et al. Isolation of genetically diverse Marburg viruses from Egyptian fruit bats. *PLoS Pathogens*. 2009;**7**:e1000536. DOI: 10.1371/journal.ppat.1000536
- [8] CDC. Deadly Marburg Virus Found in Sierra Leone bats. First Time this Ebola-Like Virus Identified in West Africa. 2018. Available from: <https://www.cdc.gov/media/releases/2018/p1220-marburg-found-in-bats.html>. [Accessed: 11 May 2019]
- [9] Schnirring L. Marburg-carrying bats found in West Africa for first time. CIDRAP 2018. Available from: <http://www.cidrap.umn.edu/news-perspective/2018/12/marburg-carrying-bats-found-west-africa-first-time>. [Accessed: 11 May 2019]
- [10] Peterson AT, Lash RR, Carroll DS, Johnson KM. Geographic potential for outbreaks of Marburg hemorrhagic fever. *American Journal of Tropical Medicine and Hygiene*. 2006;**75**(1):9-15. Available from: <https://pdfs.semanticscholar.org/4871/a570581b7b9c441dacb68de07e3a01c5913d.pdf>. [Accessed: 26 May 2019]
- [11] Bebell LM. Ebola virus disease and pregnancy: Perinatal disease and transmission. In: *Pregnant in the Time of Ebola: Women and their Children in the 2013-2015 West African Epidemic*. Schwartz DA, Anoko JA, Abramowitz S, editors. Springer Nature, New York and Berlin. 2019. P. 53-65
- [12] Spina A, Lenglet A, Beversluis D de Jong M Vernier L Spencer C, et al. A large outbreak of hepatitis E virus genotype 1 infection in an urban setting in Chad likely linked to household level transmission factors, 2016-2017. *PLoS One*. 2017;**12**(11):e0188240. DOI: 10.1371/journal.pone.0188240
- [13] Strong A, Schwartz DA. Effects of the west African Ebola epidemic on health care of pregnant women - stigmatization with and without infection. In: *Pregnant in the Time of Ebola: Women and their Children in the 2013-2015 West African Epidemic*. Schwartz DA, Anoko JA, Abramowitz S, editors. Springer Nature, New York and Berlin. 2019. P. 11-30. Available from: <https://link.springer.com/>



chapter/10.1007/978-3-319-97637-2\_2. [Accessed: 1 June 2019]

[14] Schwartz DA. All the mothers are dead – Ebola’s chilling effects on the young women of one Liberian town named Joe blow In: *Pregnant in the Time of Ebola: Women and their Children in the 2013-2015 West African Epidemic*. Schwartz DA, Anoko JA, Abramowitz S, editors. Springer Nature, New York and Berlin. 2019. P. 251-260. Available from: [https://link.springer.com/chapter/10.1007/978-3-319-97637-2\\_17](https://link.springer.com/chapter/10.1007/978-3-319-97637-2_17). [Accessed: 1 June 2019]

[15] Sissoko D, Keita M, Diallo B, Aliabadi N, Fitter DL, Dahl BA, et al. Ebola virus persistence in breast milk after no reported illness: A likely source of virus transmission from mother to child. *Clinical Infectious Diseases*. 2017;**64**(4):513-516. Available from: <https://academic.oup.com/cid/article/64/4/513/2666520>. [Accessed: 1 June 2019]

[16] Godwin CL, Schwartz DA. Uncovering more questions: Salome Karwah and the lingering impact of Ebola virus disease on the reproductive health of survivors. In: *Pregnant in the Time of Ebola: Women and their Children in the 2013-2015 West African Epidemic*. Schwartz DA, Anoko JA, Abramowitz S, editors. Springer Nature, New York and Berlin. 2019. P. 243-250

[17] US Army Medical Research Institute of Infectious Diseases. Mechanism of Marburg virus sexual transmission identified in nonhuman primates. *ScienceDaily*. 30 August 2018. Available from: [www.sciencedaily.com/releases/2018/08/180830180111.htm](http://www.sciencedaily.com/releases/2018/08/180830180111.htm). [Accessed: 19 May 2019]

[18] Coffin KM, Liu J, Warren TK, Blancett CD, Kuehl KA, Nichols DK, et al. Persistent Marburg virus infection in the testes of nonhuman primate survivors. *Cell Host & Microbe*.

2018;**24**(3):405-416. DOI: 10.1016/j.chom.2018.08.003

[19] Kissling RE, Murphy FA, Henderson BE. Marburg virus. *Annals of the New York Academy of Sciences*. 1970;**174**(2):932-945. DOI: 10.1111/j.1749-6632.1970.tb45614.x

[20] Slenczka W, Klenk HD. Forty years of Marburg virus. *The Journal of Infectious Diseases*. 2007;**196**(Suppl 2):S131-S135. DOI: 10.1086/520551

[21] Gear JS, Cassel GA, Gear AJ, Trappler B, Clausen L, Meyers AM, et al. Outbreak of Marburg virus disease in Johannesburg. *British Medical Journal*. 1975;**5995**:489-493. Available from: <https://www.ncbi.nlm.nih.gov/pmc/articles/PMC1675587/>. [Accessed: 7 May 2019]

[22] Smith DH, Johnson BK, Isaacson M, Swanapoel R, Johnson KM, Killey M, et al. Marburg-virus disease in Kenya. *Lancet*. 1982;**1**(8276):816-820. DOI: 10.1016/S0140-6736(82)91871-2

[23] Johnson ED, Johnson BK, Silverstein D, Tukei P, Geisbert TW, Sanchez AN, et al. Characterization of a new Marburg virus isolated from a 1987 fatal case in Kenya. *Archives of Virology*. 1996;**11**(Suppl.):101-114

[24] Beer B, Kurth R, Bukreyev A. Characteristics of Filoviridae: Marburg and Ebola viruses. *Die Naturwissenschaften*. 1999;**86**(1):8-17. DOI: 10.1007/s001140050562

[25] Nikiforov VV, Turovskii I, Kalinin PP, Akinfeeva LA, Katkova LR, Barmin VS, et al. A case of a laboratory infection with Marburg fever. *Zhurnal Mikrobiologii, Epidemiologii, i Immunobiologii*. 1994;**(3)**:104-106

[26] Bausch DG, Nichol ST, Muyembe-Tamfum JJ, Borchert M, Rollin PE, Sleurs H, et al. Marburg hemorrhagic fever associated with multiple genetic

lineages of virus. *New England Journal of Medicine*. 2006;**355**(9):909-919. DOI: 10.1056/nejmoa051465

[27] Ligon BL. Outbreak of Marburg hemorrhagic fever in Angola: A review of the history of the disease and its biological aspects. *Seminars in Pediatric Infectious Diseases*. 2005;**16**(3): 219-224. Available from: <https://www.sciencedirect.com/science/article/pii/S1045187005000464>. [Accessed: 9 May 2019]

[28] Roddy P, Thomas SL, Jeffs B, Nascimento Folo P, Pablo Palma P, Moco Henrique B, et al. Factors associated with Marburg hemorrhagic fever: Analysis of patient data from Uige, Angola. *Journal of Infectious Diseases*. 2010;**201**(12):1909-1918. DOI: 10.1086/652748

[29] Towner JS, Khristova ML, Sealy TK, Vincent MJ, Erickson BR, Bawiec DA, et al. Marburgvirus genomics and association with a large hemorrhagic fever outbreak in Angola. *Journal of Virology*. 2006;**80**(13):6497-6516. Available from: <https://www.ncbi.nlm.nih.gov/pmc/articles/PMC1488971/>. [Accessed: 10 May 2019]

[30] CIDRAP. Angola declares worst Marburg outbreak over. 2005. Available from: <http://www.cidrap.umn.edu/news-perspective/2005/11/angola-declares-worst-marburg-outbreak-over>. [Accessed: 9 May 2009]

[31] Glaze ER, Roy MJ, Dalrymple LW, Lanning LL. A comparison of the pathogenesis of Marburg virus disease in humans and nonhuman primates and evaluation of the suitability of these animal models for predicting clinical efficacy under the 'animal rule'. *Comparative Medicine*. 2015;**65**(3): 241-259. Available from: <https://www.ncbi.nlm.nih.gov/pmc/articles/PMC4485633/>. [Accessed: 10 May 2019]

[32] CDC. Brief report outbreak of Marburg virus hemorrhagic fever—Angola, October 1, 2004–march 29, 2005. *MMWR. Morbidity and Mortality Weekly Report*. 2005;**54**(12):308-309. Available from: <https://www.cdc.gov/mmwr/preview/mmwrhtml/mm54d330a1.htm>. [Accessed: 10 May 2019]

[33] Jeffs B, Roddy P, Weatherill D, de la Rosa O, Dorion C, Iscla M, et al. The Medecins sans Frontieres intervention in the Marburg hemorrhagic fever epidemic, Uige, Angola, 2005. I. Lessons learned in the hospital. *Journal of Infectious Diseases*. 2007;**196**(Suppl 2):S154-S161. Available from: [https://academic.oup.com/jid/article/196/Supplement\\_2/S154/858898](https://academic.oup.com/jid/article/196/Supplement_2/S154/858898). [Accessed: 10 May 2019]

[34] Adjemian J, Farnon EC, Tschiko F, Wamala JF, Byaruhanga E, Bwire GS, et al. Outbreak of Marburg hemorrhagic fever among miners in Kamwenge and Ibanda Districts, Uganda, 2007. *The Journal of Infectious Diseases*. 2011;**204**(Suppl 3):S796-S799. DOI: 10.1093/infdis/jir312

[35] Timen A, Koopmans MP, Vossen AC, Van Doornum GJ, Günther S, Van Den Berkmoortel F, et al. Response to imported case of Marburg hemorrhagic fever, the Netherlands. *Emerging Infectious Diseases*. 2009;**15**(8):1171-1175. DOI: 10.3201/eid1508.090015

[36] CDC. Imported case of Marburg hemorrhagic fever - Colorado, 2008. *Morbidity and Mortality Weekly Report*. 2009;**58**(49):1377-1381

[37] Nyakarahuka L, Ojwang J, Tumusiime A, Balinandi S, Whitmer S, Kyazze S, et al. Isolated case of Marburg virus disease, Kampala, Uganda, 2014. *Emerging Infectious Diseases*. 2017;**23**(6):1001-1004. DOI: 10.3201/eid2306.170047

[38] WHO. Marburg Haemorrhagic Fever in Uganda – update. 2012.

Available from: [https://www.who.int/csr/don/2012\\_10\\_31/en/](https://www.who.int/csr/don/2012_10_31/en/). [Accessed: 9 May 2019]

[39] WHO. Marburg Virus Disease – Uganda. 2014. Available from: <https://www.who.int/csr/don/13-november-2014-marburg/en/>. [Accessed: 11 May 2019]

[40] WHO. WHO Supports Containment of Rare Virus on Uganda-Kenya border. 2017. Available from: <https://www.who.int/en/news-room/detail/20-10-2017-who-supports-containment-of-rare-virus-on-uganda-kenya-border>. [Accessed: 10 May 2019]

[41] WHO. Marburg Virus Disease – Uganda and Kenya. 2017. Available from: <https://www.who.int/csr/don/7-november-2017-marburg/en/>. [Accessed: 10 May 2019]

[42] Mupapa K, Mukundu W, Bwaka MA, Kipasa M, De Roo A, Kuvula K, et al. Ebola hemorrhagic fever and pregnancy. *Journal of Infectious Diseases*. 1999;**179**(Suppl. 1):S11-S12

[43] Lyman M, Mpofu JJ, Soud F, Oduyebo T, Ellington S, Schlough GW, et al. Maternal and perinatal outcomes in pregnant women with suspected Ebola virus disease in Sierra Leone, 2014. *International Journal of Gynaecology and Obstetrics*. 2018;**142**(1):71-77. DOI: 10.1002/ijgo.12490

[44] Report of an International Commission. Ebola haemorrhagic fever in Zaire, 1976. *Bulletin of the World Health Organization*. 1978;**56**(2):271-293. Available from: <https://www.ncbi.nlm.nih.gov/pmc/articles/PMC2395567/>. [Accessed: 10 May 2019]

[45] Black B. Principles of Management for Pregnant Women with Ebola: A Western Context. 2015. Available from: [www.rcog.org.uk/globalassets/documents/news/](http://www.rcog.org.uk/globalassets/documents/news/)

ebola-and-pregnancy-western.pdf. [Accessed: 1 June 2019]

[46] Black BO, Caluwaerts S, Achar J. Ebola viral disease and pregnancy. *Obstetric Medicine*. 2015;**8**(3):108-113. DOI: 10.1177/1753495X15597354

[47] Jamieson DJ, Uyeki TM, Callaghan WM, Meaney-Delman D, Rasmussen SA. What obstetrician-gynecologists should know about Ebola: A perspective from the Centers for Disease Control and Prevention. *Obstetrics and Gynecology*. 2014;**124**(5):1005-1010. DOI: 10.1097/AOG.0000000000000533

[48] Schwartz DA, Anoko JN, Abramowitz S. Pregnant in the Time of Ebola: Women and their Children in the 2013-2015 West African Epidemic. New York and Berlin: Springer; 2019

[49] Fallah MP, Skrip LA, Dahn BT, Nyenswah TG, Flumo H, Glayweon M, et al. Pregnancy outcomes in Liberian women who conceived after recovery from Ebola virus disease. *The Lancet Global Health*. 2016;**4**(10):e678-e679. DOI: 10.1016/S2214-109X(16)30147-4

[50] Dokubo EK, Wendland A, Mate SE, Ladner JT, Hamblion EL, Raftery P, et al. Persistence of Ebola virus after the end of widespread transmission in Liberia: An outbreak report. *The Lancet Infectious Diseases*. 2018;**18**(9):1015-1024. DOI: 10.1016/S1473-3099(18)30417-1

[51] Schwartz DA. Viral infection, proliferation and hyperplasia of Hofbauer cells and absence of inflammation characterize the placental pathology of fetuses with congenital Zika virus infection. *Archives of Gynecology and Obstetrics*. 2017;**295**(6):1361-1368. DOI: 10.1007/s00404-017-4361-5

[52] Schwartz DA. Autopsy and postmortem studies are concordant. Pathology of Zika virus infection is



neurotropic in fetuses and infants with microcephaly following transplacental transmission. *Archives of Pathology & Laboratory Medicine*. 2017;**141**(1):68-72. DOI: 10.5858/arpa.2016-0343-OA

[53] Ritter JM, Martines RB, Zaki SR. Zika virus: Pathology from the pandemic. *Archives of Pathology & Laboratory Medicine*. 2017;**141**(1):49-59

[54] Rosenberg AZ, Yu W, Hill DA, Reyes CA, Schwartz DA. Placental pathology of Zika virus and microcephaly – Viral infection of the placenta induces villous stromal macrophage (Hofbauer cell) proliferation and hyperplasia. *Archives of Pathology & Laboratory Medicine*. 2017;**141**(1):43-48. DOI: 10.5858/arpa.2016-0401-OA

[55] Cooper TK, Sword J, Johnson JC, Bonilla A, Hart R, Liu DX, et al. New insights into Marburg virus disease pathogenesis in the rhesus macaque model. *Journal of Infectious Diseases*. 2018;**218**(Suppl\_5):S423-S433. DOI: 10.1093/infdis/jiy367