

We are IntechOpen, the world's leading publisher of Open Access books Built by scientists, for scientists

6,900

Open access books available

185,000

International authors and editors

200M

Downloads

Our authors are among the

154

Countries delivered to

TOP 1%

most cited scientists

12.2%

Contributors from top 500 universities



WEB OF SCIENCE™

Selection of our books indexed in the Book Citation Index
in Web of Science™ Core Collection (BKCI)

Interested in publishing with us?
Contact book.department@intechopen.com

Numbers displayed above are based on latest data collected.
For more information visit www.intechopen.com



Nail Trauma

Rebeca Astorga Veganzones

Abstract

The nails are important elements of the finger, not only aesthetically, but also for its functionality. Not only to protecting the tip of the finger helps us but also to perform meticulously fine dexterity activities. Due to the high incidence of nail injuries seen in a trauma emergency service, it is essential to know, at least, basic aspects of the anatomy and physiology of the nail and what should be the appropriate treatment based on the injury presented by the patient. Injuries such as subungual hematomas are resolved in short time, however, more complex lesions require minor surgical intervention to obtain good results. In this chapter, additionally to reviewing the anatomy-physiological aspects of the nail, the principles of treatment of nail traumas are detailed.

Keywords: nail anatomy, nail physiology, nail trauma, subungual hematoma, nail surgery

1. Introduction

Although commonly said nail, it is a unit and it is an important element in the distal digit. It is a complex structure that is truly vital to daily life and civilized existence. Fingernails have an important role in hand function, to protect the dorsal surface of the distal phalanges and increase sensitive of the fingertip. Furthermore, the nails facilitate the pinch of small objects and have a cosmetic role.

Fingertip injuries account for 15–24% of all hand injuries, particularly affecting the 4–30-year-old age group [1].

To achieve an optimal outcome, a good initial treatment is necessary because an inadequate or insufficient treatment can derivate in aesthetics and functionality sequels. Hence, to know anatomy and physiology, it is fundamental.

2. Anatomy and physiology of the nail unit

The structural and functional features of the nail unit are unique, clinics and surgeons must understand them thoroughly. Although this chapter discusses each component individually, it is important to understand how the basic structural components of the distal digit interrelate. Abnormality of one of these structures has a profound impact on the other components.

The nail anatomy unit compromises the nail plate, the surrounding soft tissues, and their vasculature and innervation based upon the distal phalanx (**Figure 1**).

2.1 Surrounding soft tissues

Hyponychium: it is the distal limit of the adhesion of the nail plate and it is a histologically specialized area making the transition between the nail bed and pulp

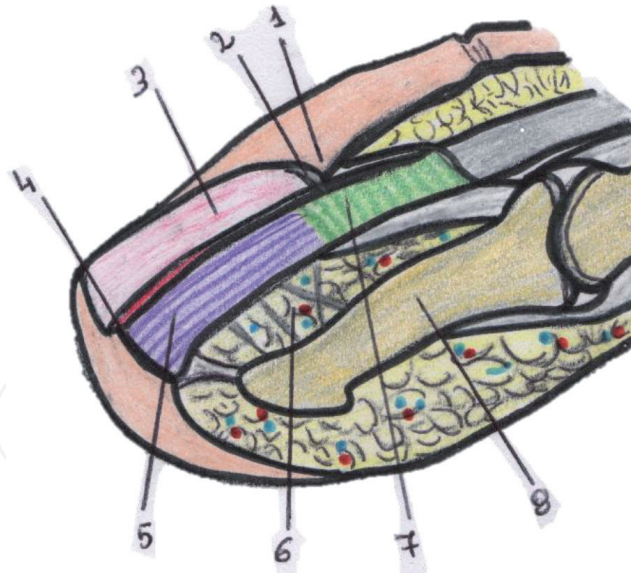


Figure 1.

Nail anatomy: 1. proximal nail fold; 2. eponychium; 3. nail plate; 4. hyponychium; 5. nail bed; 6. subungual subcutaneous; 7. nail matrix; and 8. distal phalanx.

tissue. It has the function as mechanical barrier because prevent accumulation of foreign bodies between the nail plate and the nail bed.

Paronychium: it includes all soft tissues lateral to the nail. The lateral nail folds provide the cushioned cutaneous lateral margins of the nail and is again histologically specialized because protects adjacent nail structures from contamination.

Eponychium: it is a lip of skin that is adherent to the dorsal aspect of the nail plate and conceals all or part of the nail matrix, which is clinically manifest as the “lunula.” It combines with the nail plate to provide protective layer over the matrix. This protection extends to blocking from ultraviolet radiation, diminish risk of malignance. Eponychium also combine with the cuticle to provide a seal against irritants and other agents that might disturb matrix function and hence nail growth. So that, remove the cuticle with manicure should be discouraged.

2.2 Nail plate (nail)

The nail plate is only produced by the nail matrix. It is a modified form of stratum corneum cells arranged in successive layers that overlying the nail bed and matrix. Its deep surface is streaked with longitudinal grooves that contribute to fastening it to the underlying nail bed.

It is curved in both longitudinal and transverse axes. This allows it to be embedded in nail folds at its proximal and lateral margins, which provide strong attachment and make the free edge a useful tool.

The tissues beneath the nail plate are divided into nail matrix (15–25%) and the nail bed (75–85%).

Nail matrix or germinative (dorsal matrix), is where the nail-forming epithelial structure. It extends to the distal edge of the lunula, that is the visible distal portion of the conventional matrix as a pale blue-gray half-moon structure emerging from under the proximal nail fold.

Histologically this area has a multilayered epithelium whose duplication is the basic of nail plate formation. The proximal matrix is more productive than distal matrix near to the nail bed.

Nail bed or sterile matrix (ventral matrix), is the tissue that the nail plate rests on and adheres to. It extends from the distal margin of the lunula to the hyponychium and it has a pattern of longitudinal epidermal ridges stretching to the lunula. This

part has a low rate of proliferation and complement of keratin expression that lacks the keratins of terminal differentiation seen in normal skin, but this is reversible, and when a nail is avulsed, these keratins are expressed as a nail bed develops the more matt surface of cornified epithelium.

2.3 Vascular supply

2.3.1 Arterial supply

The nail unit is vascularized by the terminal branches of the palmar digital arteries that these are connected by dorsal and palmar arches. There are three arches to blood supply the nail unit, so that, it can survive with extensive damage to the blood supply (**Figure 2**).

The small vessels of the nail bed are orientated in the same axis than the ridges.

2.3.2 Venous drainage

It is by deep and superficial systems. The deep system corresponds to the arterial, and the superficial system exist dorsal and palmar digital veins (**Figure 2**).

2.4 Nerve supply

The distal digits have sensory and autonomic nerves. The sensory nerves are to terminal branches are derived from fine oblique branches of the volar collateral nerves to the second, third and fourth fingers. In the first and fifth digit, there are dorsal collateral nerves that supply the innervation. These branches usually run to the nail folds and pass under the nail bed at the level of the lunula, although there are minor variations.

Autonomic nerves end in fine arborizations where there are special receptors that are essentials for vascular control or two-point discrimination. Clearly, loss of the sensory function or the fingertips greatly impairs all function of the entire hand. Tactile sensory perception is the only or the five sense nor confined to the head, so that, loss of the sensory function of the fingertips is “to render the eyes of the finger blind.”

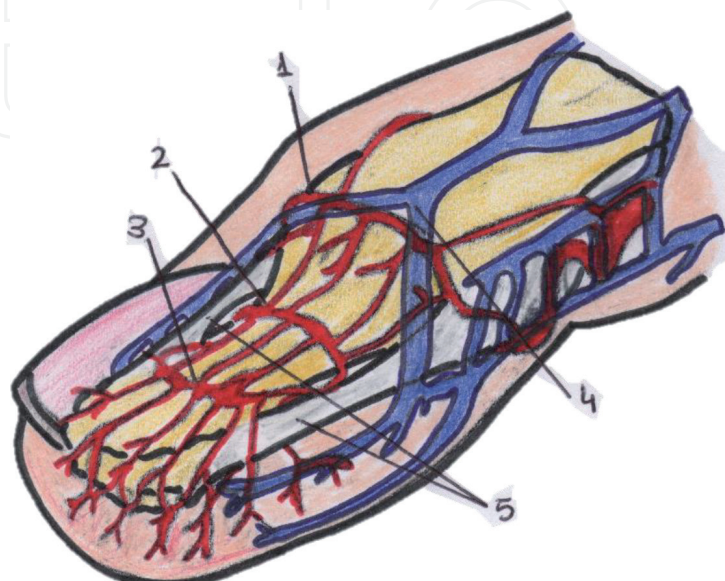


Figure 2.
Vascularity of the nail: 1. superficial arterial arcade; 2. proximal subungual arterial arcade system; 3. distal subungual arterial arcade system; 4. distal venous arch; and 5. lateral ligaments to flint.

3. Aims of nail treatment

Fingernails have an important role in hand function, because they protect the dorsal surface of the distal phalanges and increase sensitive of the fingertip. Furthermore, the nails facilitate the pinch of small objects and a cosmetic role. Hence, the aims of nail treatment are restoring a nail's length, morphology, and a normal appearance.

4. Principles of nail surgery

The nail trauma surgery can be do in the emergency department, but if the patient presents some digits with nail trauma or important lesions with a complex repair, we must think in an operative theater for do the treatment.

The patient should always be lying on a stretcher and good anesthesia is of paramount important. Any local anesthetic can be used (lidocaine, mepivacaine, etc.). We think that ropivacaine 1% is the election choice because have a long duration (8–12 h) and nail surgery usually is appreciated by patient as is often followed by intense pain. Technique of proximal digital anesthesia block make possible to do all types of nail surgery.

Except for subungual hematoma and nail avulsion, sterile prepping is a must for nail operations. Donning a sterile glove and cutting a tiny hole into the corresponding finger, which is then rolled back, not only gives a sterile file but also exsanguinates the finger and is an efficient tourniquet [2]. After realizing the tourniquet, bleeding is usually copious, and a thick padded dressing is necessary.

The major principles of repairs are the following:

- The nail bed is in direct relation to the periosteum of F3, a reduction defect and/or a prominence bone causes a deformation of the bed and, secondary form, of the nail sheet.
- The adhesion of the nail sheet is only possible if the reconstruction of the nail bed is perfect.
- The growth of the nail sheet is only possible from of the matrix, so that any injury of the matrix must be repaired carefully.
- Where possible, keep the nail sheet to replace it after the repair; failing that, a prosthesis can be used [3].

5. Material for nail treatment

It's important a sterile ambient, like any other surgical treatment. But it is almost always ambulatory surgery. Antibiotics are needed in most injuries and the use of magnification is essential for nail bed repair.

Very few special instruments are necessary for nail surgery. The suture material must be absorbable and of a small caliber. We use a Vicryl 6/0 for nail bed repair, and a non-absorbable monofilament for repair the surrounding soft tissue injuries and to fix the nail plate when we must remove it.

6. Nail trauma assessment

Fingertip and nail bed injuries are seen at all ages, with a peak incidence in 4–30 years old patients [4]. In the emergency department is important to detail in the clinical history the mechanism of injuries, the time it occurred, dominant hand, the patient's job and the context in which the trauma occurred to consider the possible contaminants of the wound.

Depending on the injury mechanism we will have to consider possible associated injuries. Fingertip injuries most frequently result from a crush injury, often from the hinge side of a door [5]. Approximately 50% of nail bed injuries presenting to hospital are associated with distal phalangeal fractures [6]. Simple radiographic (anteroposterior and lateral) is mandatory when a nail trauma is.

7. Treatment of nail injuries

7.1 Subungual hematoma

Nail bed is a highly vascular structure. If the nail is not broken with the trauma, blood collects beneath the nail and the pressure of which may cause pain. In these cases, it is a necessary treat. Drainage of the hematoma can be done by a paper clip heated or battery-powered ophthalmic cautery. Touch to nail at 90-degree angle over the central area of hematoma. The key of the treatment is to ensure that the hematoma is not older than 48 h and a round hole completely through the nail, which stay open to drain.

Once a hole is created it is expected that blood will drain out from the hematoma resolving most of the patient's pain. It may take more than one trephination to decompress the hematoma completely. Take care when advancing through the nail to avoid damage to the nail bed. Bandage site with sterile gauze in instruct patient to keep digit clean and dry.

If more than 50% of the nail bed is undermined by hematoma, the nail should be removed and explored the nail bed and the distal phalanx because can be affected.

7.2 Dislocation of the nail plate

These traumas occur when the mechanism of injury has a component of hyperflexion. The nail plate must be replaced in the nail fold. Before this, it is necessary

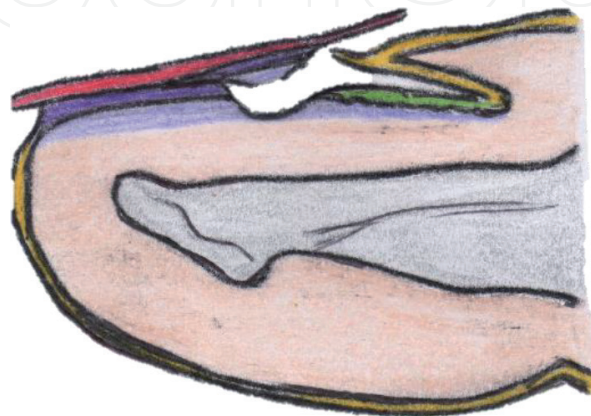


Figure 3.
Dislocation of the nail plate; with the reposition of the proximal nail plate, the nail bed avulsed is holding like a graft.

to verify the absence of any injury to the bed under local anesthesia. When the nail bed is injured, but it is a small fragment and it's adhered to the nail plate, with the reposition of the nail it is enough because it is like holding a graft (**Figure 3**).

A radiography is mandatory to ensure the absence of distal phalanx fracture because is often present. When there is a distal phalanx fracture associated, the nail plate reinstated and it is enough to stabilize the fracture, and no osteosynthesis or additional splinting is required. But generally, a distal phalanx fracture associated a dislocation of the nail base have a nail bed injury.

The nail plate is replaced into the nail fold to prevent scarring between the dorsal roof and the ventral floor. If more exposure of the nail fold is required, incisions are made at the proximal edge like **Figure 4** from the eponychium because are easier to approximate and cause less scarring than an incision made straight proximal.

7.3 Nail bed injuries and distal phalanx fracture

It is an injury similar than anterior apart, but the base of the nail remains in place. Classically, a fingertip crushed by the door. It is a frequent injuries of the nail unit and nail bed injuries are easily overlooked especially in children as they are less cooperative and more difficult to do an adequate inspection of the lesions [7].

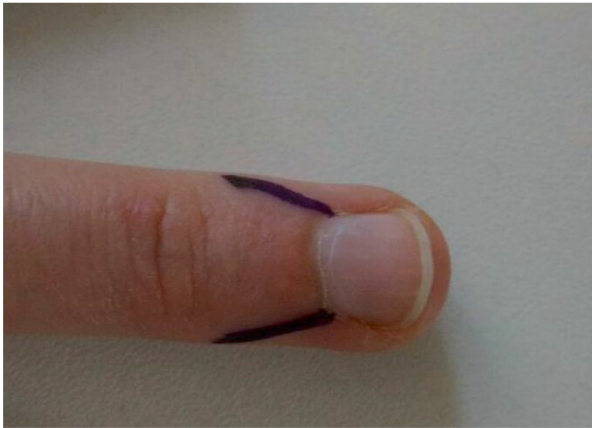


Figure 4.
Kanavel incisions.

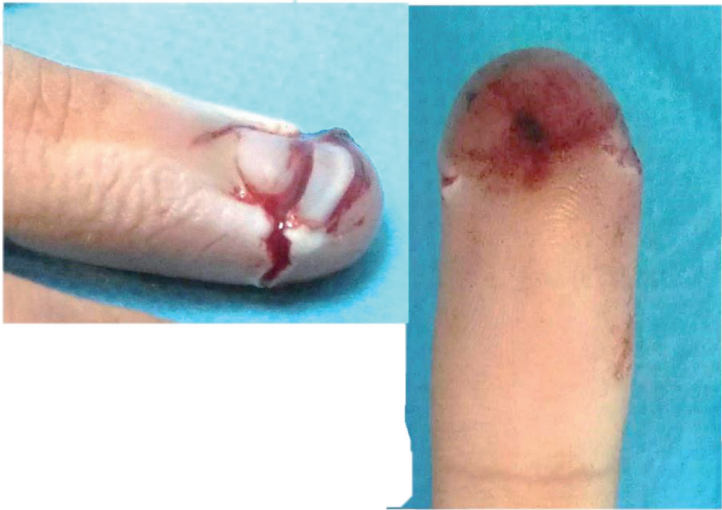

Figure 5.
A 20-year-old man with second finger entrapment of his right hand with a door. The wounds affect paronychia and the lateral edges of the pulp.

The impact of the nail complex results from palmar displacement of the distal fragment (**Figure 5**).

The proximal nail plate is gently elevated. Care should be taken to elevate the nail plate without the nail bed and the other tissue. And the distal nail plate is elevating too. Now, the nail bed is explored, and irregularities of the edges may be trimmed into a straight line if it can be closed without tension. After the nail bed is approximated with an absorbable suture 6/0 or 7/0, the nail plate is replaced into the nail fold and held with 4/0 or 5/0 suture to hyponychium.

Approximately 50% of nail bed injuries have an associated fracture of the distal phalanx [8]. An associated fracture with a wound in the nail indicates a high energy trauma. The nail plate replaced serves as a splint, and usually osteosynthesis is not necessary. But an osteosynthesis by an axial wire is essential when the distal phalanx fragment is big, or the fracture is instable. A proper alignment of the bone fragments must be done because otherwise it may generate future nail deformities.

Figure 6 shows the case of a middle-aged woman with entrapment of the third finger of her left hand with the door of her vehicle. She had an associated fracture

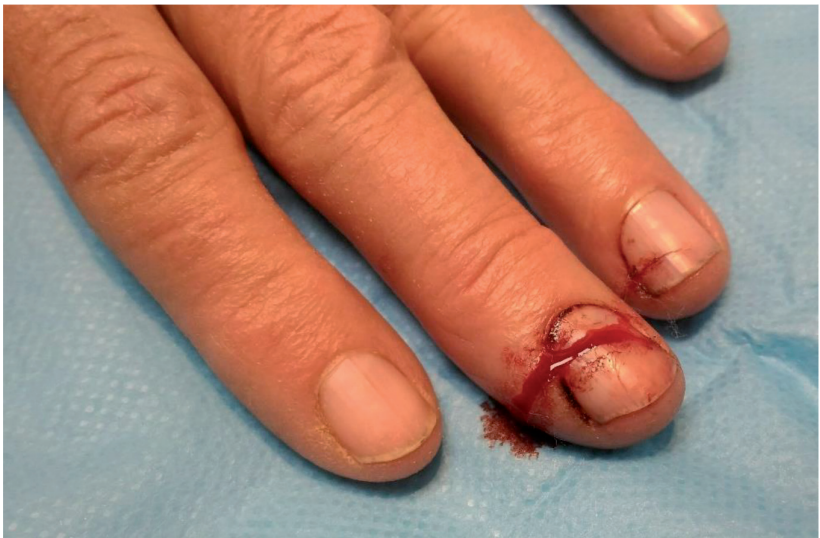

Figure 6.
Example of nail trauma in a woman.

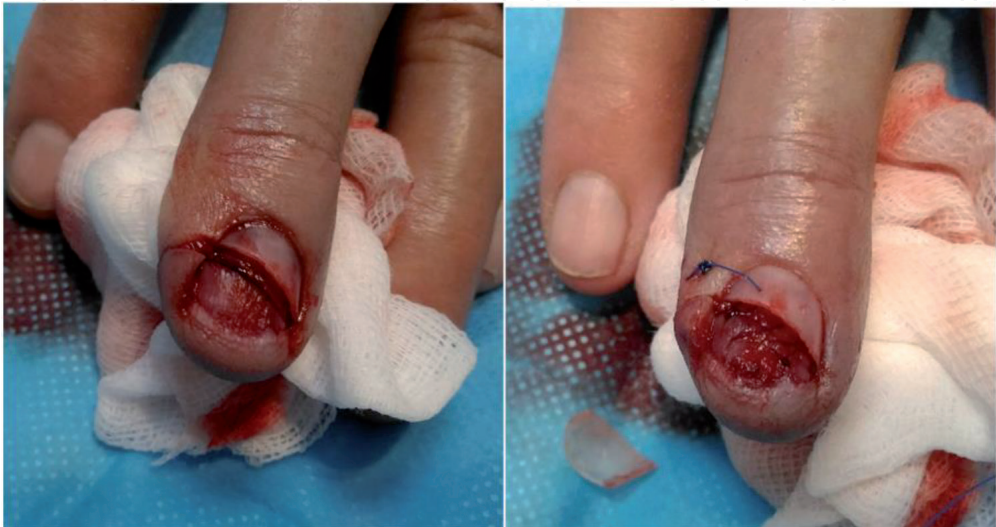

Figure 7.
Left: wound in the nail bed. Right: nail bed sutured.

of the distal phalanx. After elevated the nail plate, we observe a wound in the nail bed, which is approximated with an absorbable suture 6/0 (**Figure 7**). Then, the nail plate is again repositioned and fixed. The nail plate has a double function; protection of the nail bed repaired and like a splint for the fracture (**Figure 8**).

7.4 Crushing injuries

These types of injuries resulting from a wide area of force applied to the nail. This energy causes an explosive type of injury in the nail bed with many fragments (**Figure 9**). In this type of lesion, it is important that all fragments of the nail be attached to the periosteum. So that, when the nail plate is being raised, we must be careful in these. No fragments of nail bed should be debrided and discarded because it is extremely difficult to replace. Like the anterior apart, these fragments are approximated with fine suture, and the nail plate or a synthetic substitute is used to mold the fragments prevent scarring.

7.5 Nail bed avulsions or tissue loss

Tissue lost affecting the distal half of the nail bed are more common than affecting the proximal half, because the distal end of the nail is more exposed to trauma. Many methods or treatment have been described, but still today it continues generating doubts about which is the best method to reposition the lost nail bed.

Depending on the size of the fragment of nail bed avulsed:

- Less than 1–2 mm, it can be replaced as accurately as possible with the nail plate and held in place with Steri-Strips or suture.
- Larger than 2 mm, the nail around the edge is removed of the nail bed and the fragment avulsed is suturing in their place, if it is possible.

Some authors consider the nail bed to have regenerative capacity and recommend, for limited tissue losses, promoting this healing by placement the nail plate or a substitute when the latter has been missed [3].

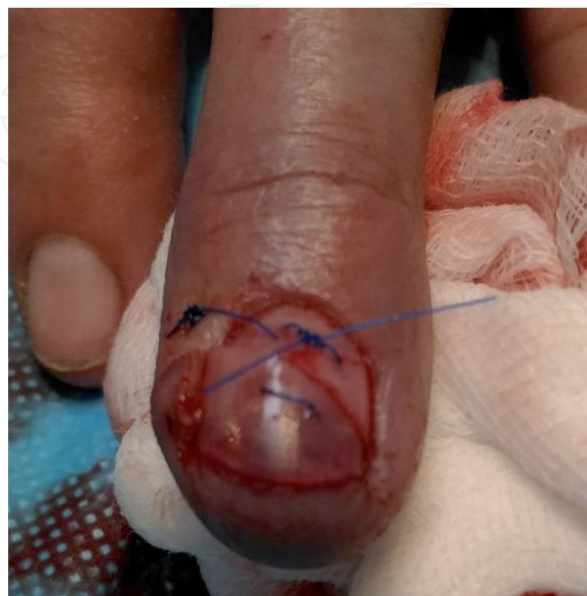

Figure 8.
Nail plate repositioned.

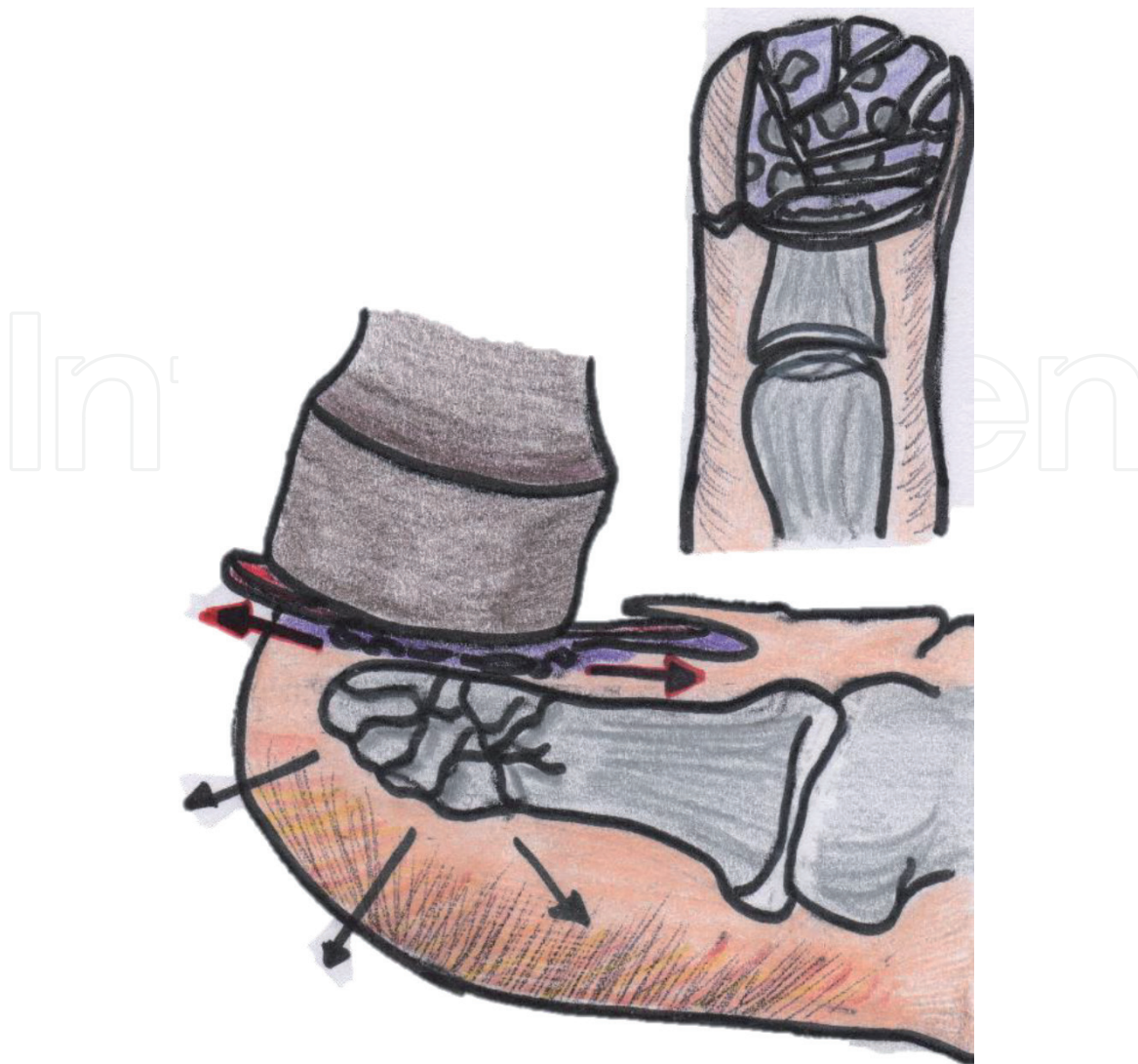


Figure 9.
Crushing injury of the nail.

When the fragment avulsed is missed, diverse treatments have been suggested, like skin grafts [9], reversal dermal grafts [10] or palatal mucosal grafts [11]. Even, porcine xenotransplants has been proposed . But we still have not found a histological tissue that can restore nail plate. So that, nail bed grafts are the best option actually, which can be full thickness grafts [12] or thin nail bed grafts [13, 14]. These techniques are highly specialized that must be performed by expert hand surgeons, so they are not of interest for this chapter.

8. Care after treatment

After performing the appropriate treatment based on the trauma presented by the patient, a cure of the injured finger should be made. The dressing chosen to perform the cure should be non-stick dressing (Vaseline) and must allow to leave free the proximal interphalangeal joint to avoid stiffness.

The first dressing change should be due in 48–72 h, to verify the absence of collection (hematoma, infection) and of pain.

The hand should be carried high with a sling. Analgesics are essential in 24–48 h and antibiotics may be necessary in some situations, especially in highly contaminated traumatism.

9. Conclusion

The pattern of fingernail injury depends in the energy and direction of trauma. Management of a fingernail injury should be selected based on injury type and extent and requires accurate knowledge of nail anatomy and physiology. An effective emergency treatment is mandatory to prevent secondary deformities and reduce the risk of secondary reconstruction of the nail bed, which often gives unpredictable results.

Conflict of interest

The author declares no conflicts of interest.

Author details

Rebeca Astorga Veganzones
University Hospital of Burgos, Burgos, Spain

*Address all correspondence to: rebeaastorga25@gmail.com

IntechOpen

© 2019 The Author(s). Licensee IntechOpen. This chapter is distributed under the terms of the Creative Commons Attribution License (<http://creativecommons.org/licenses/by/3.0>), which permits unrestricted use, distribution, and reproduction in any medium, provided the original work is properly cited. 

References

- [1] Patel L. Management of simple nail bed lacerations and subungual hematomas in the emergency department. *Pediatric Emergency Care*. 2014;**30**:742-745
- [2] Hasegawa K et al. The microvasculature of the nail bed, nail matrix, and nail fold of a normal human fingertip. *The Journal of Hand Surgery*. 2001;**26**(2):283-290
- [3] Ogunro EO. External fixation of injured nail bed with the INRO surgical nail splint. *The Journal of Hand Surgery*. 1989;**14**:236-241
- [4] Nanninga GL et al. Case report of nail bed injury after blunt trauma; what lie beneath the nail? *International Journal of Surgery Case Reports*. 2015;**15**:133-136
- [5] Yildirimer L et al. Experience of nail bed injuries at a tertiary hand trauma unit: A 12-month review and cost analysis. *The Journal of Hand Surgery, European Volume*. 2019;**44**(4):419-423
- [6] Satku M, Puhaindran ME, Chong AK. Characteristics of fingertip injuries in children in Singapore. *Hand Surgery*. 2015;**20**:410-414
- [7] Yorlets RR, Busa K, Eberlin KR, et al. Fingertip injuries in children: Epidemiology, financial burden, and implications for prevention. *Hand (New York, N.Y.)*. 2017;**12**(4):342-347
- [8] Zook EG, Guy RJ, Russell RC. A study of nail bed injuries. Causes, treatment and prognosis. *The Journal of Hand Surgery*. 1984;**9A**:247-252
- [9] Flatt A. Nail bed injuries. *British Journal of Plastic Surgery*. 1956;**8**:38-43
- [10] Clayburgh RH, Wood MB, Cooney WP 3rd. Nail bed repair and reconstruction by reverse dermal grafts. *The Journal of Hand Surgery*. 1983;**8**:594-598
- [11] Fernandez-Mejia S, Dominguez-Cherit J, Pichardo-Velazquez P, Gonzalez-Olvera S. Treatment of nail bed defects with hard palate mucosal grafts. *Journal of Cutaneous Medicine and Surgery*. 2006;**12**:69-72
- [12] Ersek RA, Gadaria U, Denton DR. Nail bed avulsions treated with porcine xenografts. *The Journal of Hand Surgery*. 1985;**10**:152-153
- [13] Lazar A, Abimelec P, Dumontier C. Full thickness skin graft for nail unit reconstruction. *Journal of Hand Surgery (British)*. 2005;**30**:194-198
- [14] Matsuba HM, Spear SL. Delayed primary reconstruction of subtotal nail bed loss using a split-thickness nail bed graft on decorticated bone. *Plastic and Reconstructive Surgery*. 1988;**81**:440-443