

We are IntechOpen, the world's leading publisher of Open Access books Built by scientists, for scientists

6,900

Open access books available

186,000

International authors and editors

200M

Downloads

Our authors are among the

154

Countries delivered to

TOP 1%

most cited scientists

12.2%

Contributors from top 500 universities



WEB OF SCIENCE™

Selection of our books indexed in the Book Citation Index
in Web of Science™ Core Collection (BKCI)

Interested in publishing with us?
Contact book.department@intechopen.com

Numbers displayed above are based on latest data collected.
For more information visit www.intechopen.com



Surgical Treatment of Hepatic Hydatidosis

*Luis Burgos San Juan, Hector Losada Morales,
Jorge Silva Abarca, Cesar Muñoz Castro, Marcelo Klein Diaz
and Pablo Guzmán González*

Abstract

Hepatic hydatid disease has been reported from ancient times. It is a zoonotic infection caused by nine recognized species of tapeworms of the genus *Echinococcus*. Some of them are known to cause human echinococcosis, and there is reasonable doubt regarding the others. Diagnosis is supported by epidemiological history, clinical presentation, radiological imaging, and serological tests. Various pathological forms may become life-threatening, and in those cases, the treatment is extremely complex. The main objective of the treatment is to completely cure the illness in order to avoid further complications and recurrences. Hepatic surgery, using different techniques, achieves best results with acceptable morbidity and mortality rates. In the South of Chile, the geographical location in which we work, this illness is endemic with high incidence and prevalence. The hepatobiliopancreatic units of the regional surgical centers of Temuco have plenty of experience treating liver hydatid disease. In this chapter we shall focus especially on epidemiology, etiopathogenesis, diagnosis, and surgical treatment of hepatic hydatidosis.

Keywords: hepatic hydatidosis, epidemiology, etiopathogeny, diagnosis, surgical treatment

1. Introduction

Human echinococcosis, also called hydatidosis, is a zoonosis which has been known from ancient times. There are mentions about hydatid disease both in humans and animals in documents as old as the Ebers Papyrus and the Babylonian Talmud [1, 2]. Around the mid-nineteenth century, a significant breakthrough happened when the etiology and the life cycles of different *Echinococcus* species were defined, although there are still many related questions pending to resolve [3]. Hydatid disease is caused by nine recognized species of tapeworm of the genus *Echinococcus* (*E.*). Seven of them cause different forms of human echinococcosis, and the remaining two are being studied for a possible human affectation. Some of the life cycles of these tapeworms have domestic animals as hosts, e.g., dogs as definitive hosts and sheep as intermediate hosts. Humans are accidental intermediate hosts. Other species of these parasites have wild life cycles, infecting almost exclusively wild animals and rarely humans. Additionally, more complex cycles

with interaction of wild and domestic animals have been described as well. There are reported variants of these cycles depending on geographical location [4].

Cystic echinococcosis, the most common form of hydatidosis, is an endemic zoonosis caused by the larval stage (metacestodes) of the tapeworm *E. granulosus*. In relation to the geographical distribution, the disease is present in many countries around the world [5]. The diagnosis is supported by epidemiological history, anamnestic data, clinical presentation, radiological imaging, and serological tests. Surgical treatment employs different techniques, aiming for the best outcome for the patient. Partial cystectomy, pericystectomy, and hepatic resection are performed by either open or laparoscopic surgical access, with or without neoadjuvant or adjuvant medical therapy. There are also different procedures for the evacuation of the parasite, using percutaneous or endoscopic access. In selected cases, antiparasitic drug therapy is employed as the only treatment for this illness [6]. The prognosis for these patients will depend on the selection of the most adequate therapy according to several factors mainly related to the physical status of the patient and the larval stage of the parasite and its location [7]. Complicated cases must be treated in reference centers by well-trained and experienced hepatobiliary surgeons. This zoonosis has not yet been completely eradicated, and if affected countries do not apply epidemiological control policies, a great amount of resources will have to be allocated to the treatment of this illness. Cystic echinococcosis of the liver is endemic, especially in the South of Chile [8]. For this reason, the main theme of this chapter will be centered in topics concerning this form of hydatidosis.

2. Epidemiology

The most common form of hydatidosis is cystic echinococcosis caused by *E. granulosus*; it is present in several countries around the world and represents a major public health problem in some regions [9, 10]. It is considered endemic in areas such as Peru, Chile, Argentina, Uruguay, southern Brazil, the Mediterranean region, Central Asia, Western China, and East Africa [11]. Antarctica is the only continent free of this parasitic disease, and it has also been eradicated through efficient epidemiological control programs in Iceland, New Zealand, Tasmania, Falkland Islands, and Cyprus [12]. This pathology affects different organs, although the liver is the most commonly compromised, accounting for 70–75% of the cases. Alveolar echinococcosis caused by *E. multilocularis* is restricted to the Northern Hemisphere and might determine high morbidity and mortality [13]. Polycystic echinococcosis is caused by *E. vogeli* and only reported in Central and South America with low incidence rates [14]. Unicystic echinococcosis, caused by *E. oligarthrus*, is extremely rare in humans, and the only localization in which it has been reported is the orbit of the eye and the myocardium [15]. Other two species of the genus *Echinococcus*, *E. shiquicus* [16] and *E. felidis* [17], are present in the Tibetan Plateau and Africa, respectively, and there are investigations about risks of human affectation. In the South of Chile, cystic echinococcosis is an endemic zoonosis with an average incidence of 1.9/100,000 and a mortality rate of 0.2/100,000 inhabitants. The hospital discharge rate corresponds to 6.3/100,000, and this figure rises to 28.1/100,000 in our Araucanía Region [8].

3. Etiopathogeny

Hydatidosis is caused by the larval stages of taeniid cestodes of the genus *Echinococcus*. There are nine species of this tapeworm currently identified, eight

well-defined species and one genotypic cluster, that in future investigations could be defined as one to three different species. These nine species of *Echinococcus* are as follows: *E. granulosus* sensu stricto, *E. equinus*, *E. ortleppi*, *E. multilocularis*, *E. vogeli*, *E. oligarthrus*, *E. canadensis* cluster, *E. shiquicus*, and *E. felidis*. Each of them has a different life cycle, transmission routes, pathology forms of clinical presentation, possible human affectation, different geographical location, and biological behavior. Some of these species may affect humans, others only animals, and in others this is still unclear [18]. For example, regarding *E. shiquicus* and *E. felidis*, although they were known to infect only animals, there is growing apprehension about an eventual human affectation, and there is an ongoing research to support this with molecular and genomic studies [19, 20]. Other species of these parasites have exclusively wild life cycles. The study of their complex genotypic diversity aims to successfully prevent the transmission of this infection to humans [21]. The life cycle of these parasites starts with adult taeniid cestodes living in the small intestine of canids or felids (definitive host). Next, the adult tapeworms release their eggs, thus contaminating the feces, which are then ingested by rodents, ungulates, other herbivores, and occasionally humans (intermediate hosts). When humans are infected, the eggs reach the small intestine, and larval oncospheres hatch, which adhere and penetrate the intestinal mucosa by using their hooks and then migrate through the portal circulation to reach their first fixed location in the liver (50–70% of the cases). This happens most commonly in the right hepatic lobe due to the anatomical distribution of the portal venous system. The lungs are affected in 20–30% of the cases and much less frequently the spleen, kidneys, heart, muscles, bone, and central nervous system. For example, once located in the liver, the metacestodes begin their development and growth giving place to the formation of the hydatid cyst [22].

The anatomical structure of the cyst has an outer acellular laminated membrane that allows the entry of nutrients from the host. Then there is the inner nucleated germinal membrane, in which the daughter vesicles are produced. In an asexual form, the protoscoleces are formed inside the daughter vesicles. The immunological system of the intermediate host reacts to isolate the parasite, forming a fibrous layer called adventitia, which can calcify with the passage of time (**Figure 1A, B**). The life cycle closes when the animal's definitive host is fed by contaminated viscera, and each protoscolec can develop an adult tapeworm in its small intestine [23] capsules and scolices.

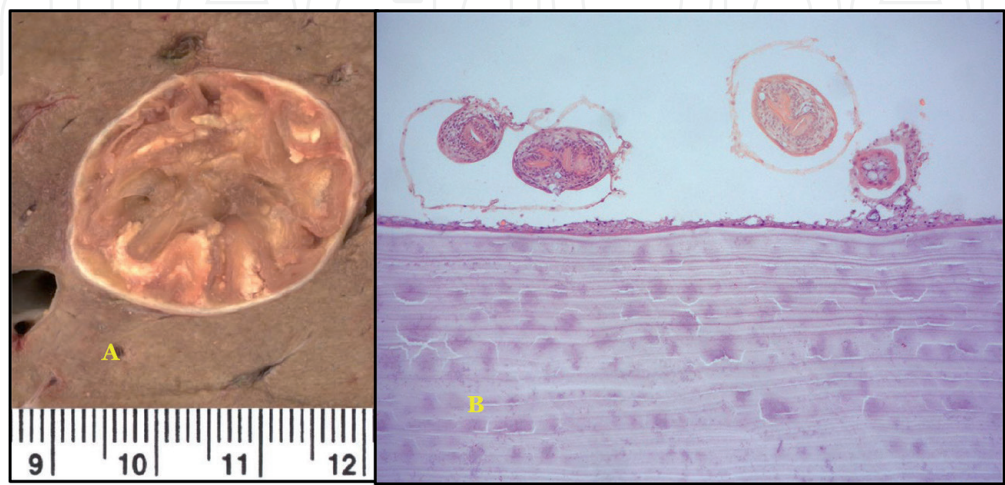


Figure 1.
(a) Hepatic solitary cyst, rounded, whitish external wall of uniform thickness. The cyst contains turbid liquid color upon formalin fixation and whitish yellowish germinal and laminated layer floating within the cyst.
(b) The wall of the hydatid cyst has a laminated acellular membrane and a germinal layer with brood.

4. Diagnosis

Currently, the diagnosis must always consider the epidemiological background. The definitive diagnosis is reached through the use of imaging and in some cases with the additional contribution of serology. In the near future, earlier stages of the parasitosis will be diagnosed by means of advances in immunological tests [24, 25].

4.1 Clinical features

Humans remain asymptomatic for a prolonged period of time after being infected due to the slow growth of the hydatid cyst in the liver (1–5 mm per year). Small and medium cysts of central hepatic location are usually asymptomatic, or a slight pain in the epigastrium and right hypochondrium might be reported by the patient, together with a sensation of abdominal discomfort. Besides, the previous immune status of the patient and the anatomical location of the cyst could determine a late manifestation of the first symptoms [26]. When the cysts grow and reach a significant size, the mass effect on the bile tree and hepatic vasculature determine other clinical manifestations derived from biliary obstruction, portal hypertension, and Budd-Chiari syndrome. The magnitude of this effect will determine different degrees of jaundice and portal hypertension, which may range from a slight increase of bilirubinemia and the appearance of venous collaterals of the abdominal wall to very severe jaundice, ascites, and upper digestive hemorrhage secondary to rupture of the gastroesophageal varices [27].

4.2 Imaging

In 1981, Gharbi reported an ultrasonography classification of the hepatic hydatidosis, describing five categories in relation to the morphological findings of the cysts, according to their stage of evolution [28]. In 2002, based on this classification, the World Health Organization Informal Working Group on Echinococcosis (WHO-IWGE) formulated a new classification adding two more categories, with the aim of guiding in the selection of the best treatment and follow-up of the results obtained (Tables 1 and 2) [29–31]. Current imaging offers several tools to

WHO-IWGE	Radiologic characteristics	Definition of cyst
CL	Unilocular cystic lesion with uniform anechoic content, cyst wall not visible	Cystic lesion
CE1	Unilocular cystic lesion with uniform anechoic content, cyst wall visible, snowflake sign	Active cyst
CE2	Multivesicular, multiseptated cysts, daughter cysts present, honeycomb sign	Active cyst
CE3A	Unilocular cyst containing liquid with a floating membrane inside, water-lily sign	Transitional cyst
CE3B	Cysts with daughter cysts in solid matrix	
CE4	Cysts with heterogeneous hypoechoic or hyperechoic degenerative contents, no daughter cysts	Inactive cyst
CE5	Cysts characterized by a thick calcified wall, which is arch shaped, producing a cone-shaped shadow; degree of calcification varies from partial to complete	Inactive cyst

Table 1.
WHO-IWGE ultrasound classification.

WHO	Surgery	PAIR	Drug therapy	Suggestion	Resource setting
CE1		✓	✓	<5 cm ABZ PAIR PAIR >5 cm PAIR+ALB PAIR	Optimal Minimal Optimal Minimal
CE2	✓	✓	✓	Other PT + ALB Other PT	Optimal Minimal
CE3a		✓	✓	Other PT < 5 cm ABZ PAIR >5cmPAIR+ ABZ PAIR	Optimal Minimal Optimal Minimal
CE3b	✓	✓	✓	Non-PAIR PT + ABZ Non-PAIR PT	Optimal Minimal
CE4				Watch and wait	Optimal
CE5				Watch and wait	Optimal

Table 2.
Suggested stage-specific approach to uncomplicated cystic echinococcosis of the liver.

guide a better management of this disease. Usually, the imaging diagnostic begins with the use of ultrasonography (US), and then other imaging tests could also be used to achieve a better diagnosis of the most complex forms of parasitosis, such as contrast-enhanced ultrasound (CEUS), computed tomography (CT), magnetic resonance imaging (MRI), magnetic resonance cholangiography (MRC), endoscopic retrograde cholangiography (ERC), and conventional X-rays.

4.2.1 Ultrasonography

The US is widely used due to its low cost and high-definition images, which allow to define the pathological characteristics of hepatic hydatid cysts and other locations in the peritoneal cavity (**Figures 2–4**). It is also useful for the differential diagnosis of hydatid cyst with other liver tumors. The use of mobile devices allows having a portable tool for the screening of populations in endemic

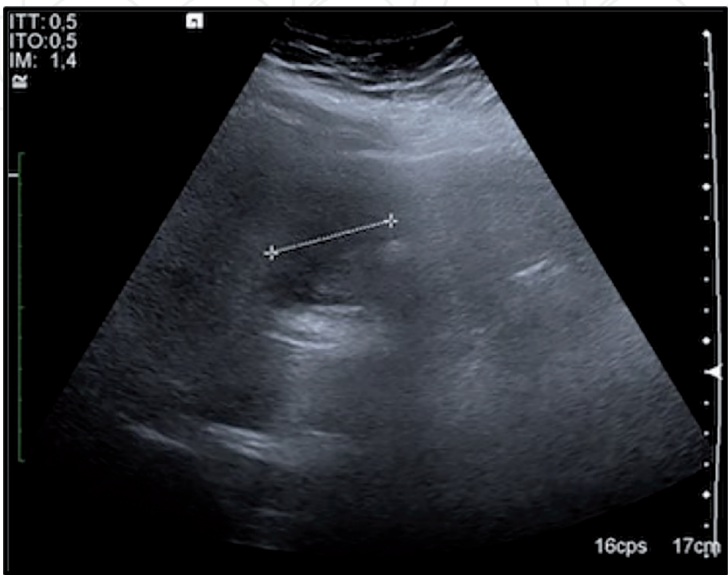


Figure 2.
Cyst of solid appearance (CE4).

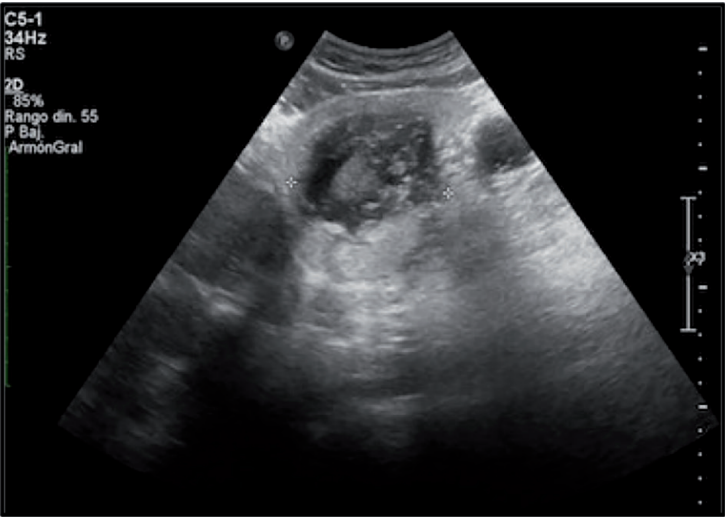

Figure 3.
Heterogeneous matrix. Ball of wool sign (CE4).

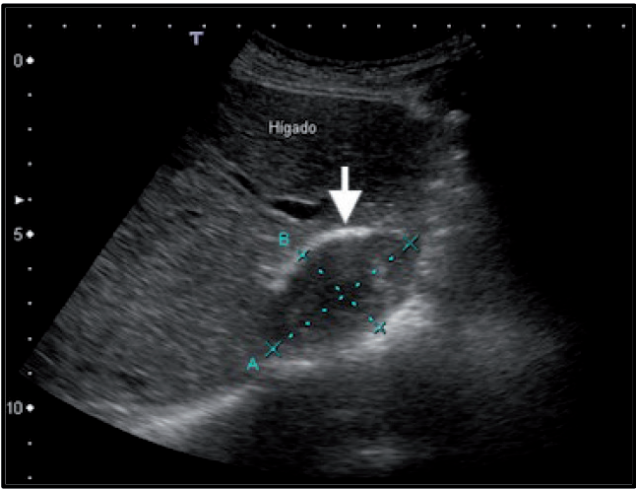


Figure 4.
Calcified anterior wall of cyst. Arciform image (white arrow).

areas with high risk of affection [30, 32, 33]. Due to the difficult differentiation of certain forms of alveolar echinococcosis from other kinds of hepatic tumors, CEUS is being increasingly used in certain regions with endemic affection of this pathology [34].

4.2.2 Computed tomography

Sometimes, the ultrasound does not help much in the diagnosis of liver hydatidosis for different reasons, such as obesity, presence of abundant intestinal gas, hydatid recurrence, or residual cavities secondary to previous surgery. When that is the case, CT is used, taking advantage of its higher sensitivity and specificity. Unenhanced CT allows to have a better radiological diagnosis of the different forms of cyst calcification [33]. The contrast-enhanced CT aids in choosing the best surgical techniques according to the different forms of presentation or complications related to the disease, e.g., by allowing a more accurate appreciation of the involvement of the vasculature and biliary tree. CT also aids in diagnosing the cystic migration to the thorax and the biliary tree [35, 36]. Another advantage of the use of contrast-enhanced CT is to achieve a better differential diagnosis from other focal liver lesions [37] (**Figures 5–11A, B**).

4.2.3 Magnetic resonance imaging

MRI is useful for diagnosis of cases of cholangiohydatidosis. Compared to US and CT, the MRI T2-weighted sequence is better at defining the internal structure of the cyst. In general, it is indicated for patients that present difficulties when performing ultrasound, such as bowel gas excess, previous surgeries, disseminated hydatidosis, and obesity. In addition, MRI is recommended when CT is contraindicated due to comorbidities. MRC is used to determine the existence of cysto-biliary fistula and the presence of hydatid material in the biliary tree. It also visualizes the cysto-biliary fistula both toward the bronchi and to the biliary tree [38, 39] (Figures 11a, b–17).

4.2.4 Endoscopic retrograde cholangiography

The rupture of a hydatid cyst in the intrahepatic bile duct can initiate some complications, which might become serious mainly due to the development of

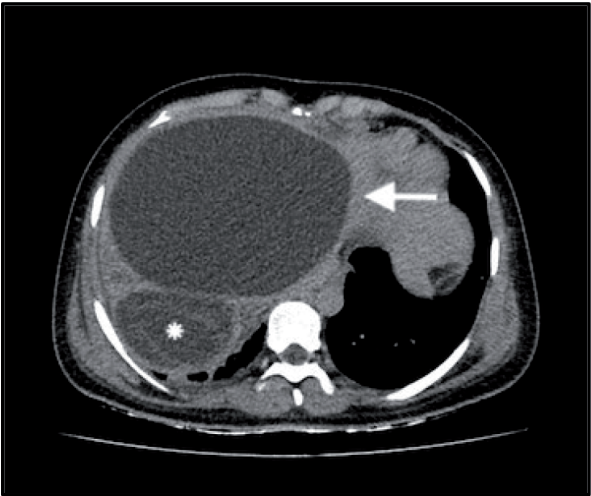


Figure 5.
Unilocular cyst (CE1, white arrow). Detached membrane. Cyst (CE2, white star).

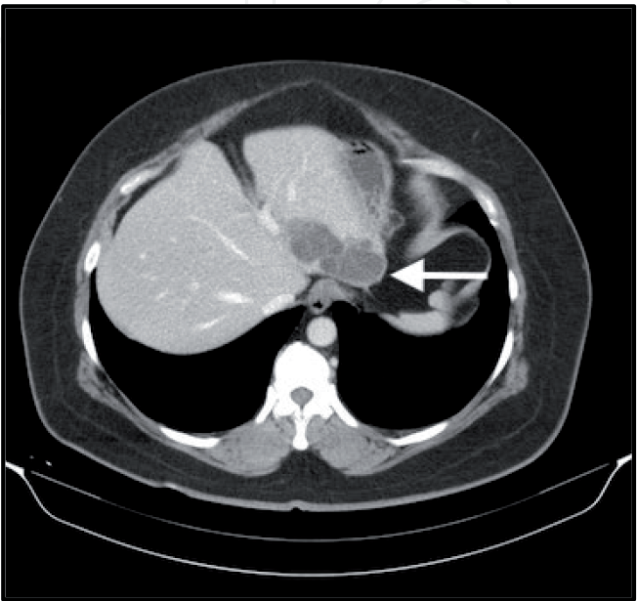


Figure 6.
Contrast-enhanced CT. Septated cyst (white arrow).

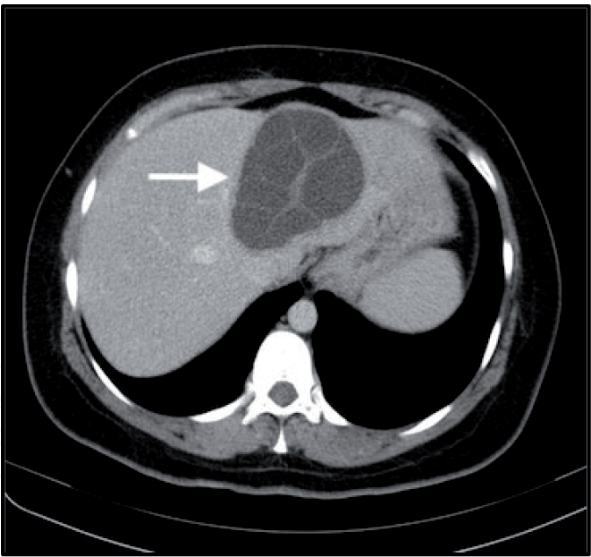


Figure 7.
Daughter vesicles in mother cyst (white arrow).

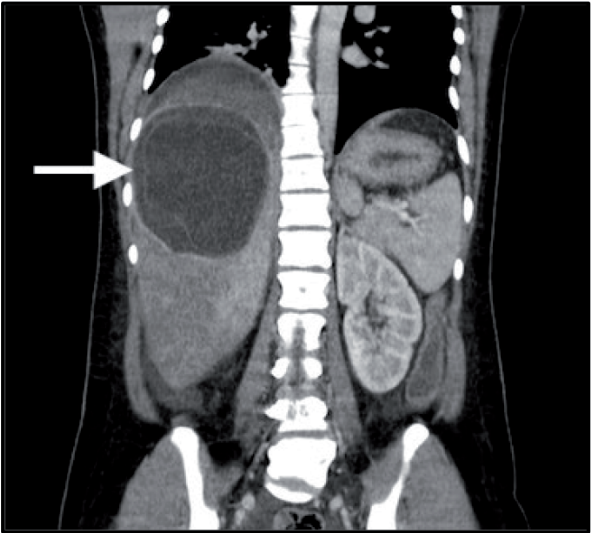


Figure 8.
Coronal contrast-enhanced CT. CE3 A, water-lily sign (white arrow).

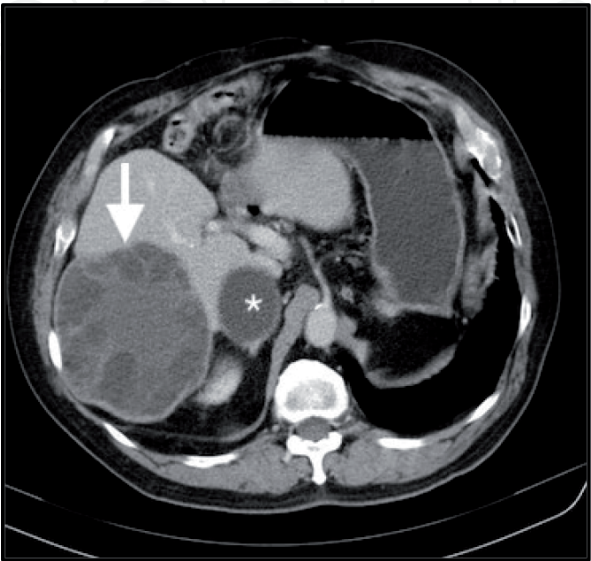


Figure 9.
Central matrix. Daughter vesicles. Cartwheel sign (white arrow).

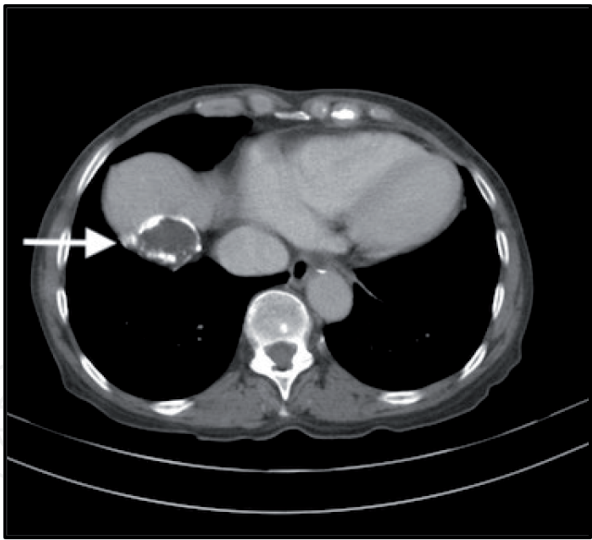


Figure 10.
Dome location with annular calcification (CE 5, white arrow).

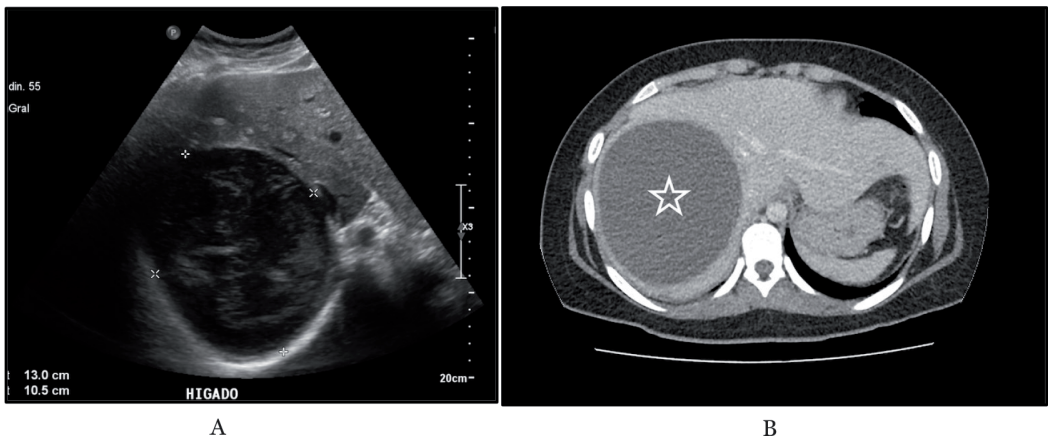


Figure 11.
(A) US content, heterogeneous with a solid appearance (CE4). (B) In the same patient, the contrast-enhanced CT diagnoses a unilocular hydatid cyst (CE1).

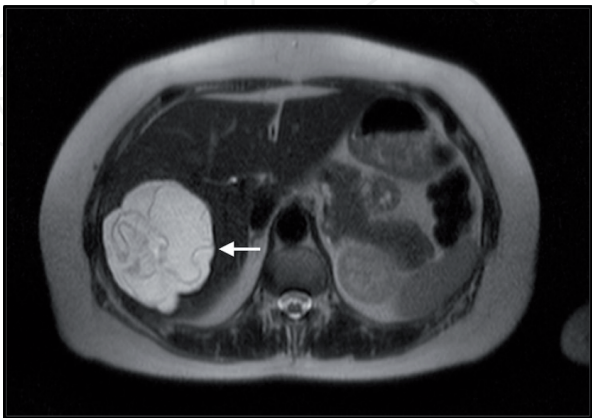


Figure 12.
MRI T2 axial. Detached membranes. Hypointense pericyst (white arrow). Water-lily sign.

cholangitis and septicemia. In these cases, the ERC provides the diagnosis and performs the removal of hydatid material, with the objective of improving the general conditions of the patient before carrying out the definitive surgical treatment [40].

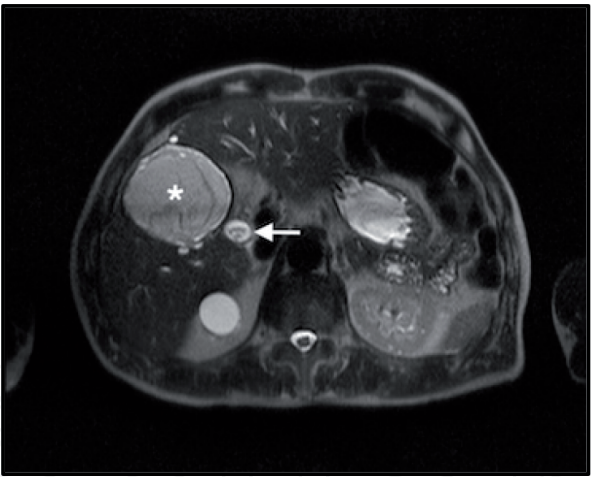


Figure 13.
MRI T2 axial. Detached membranes (white star). Hydatid membranes in bile duct (white arrow).

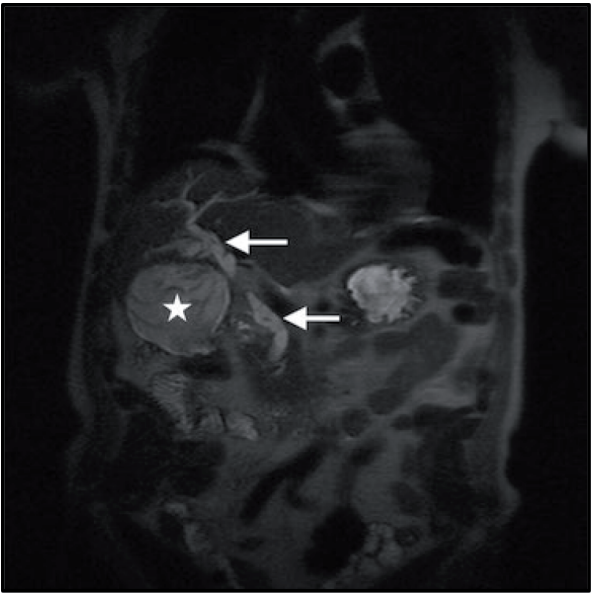


Figure 14.
MRI coronal. Detached membranes. Bile duct with membranes (white arrow).

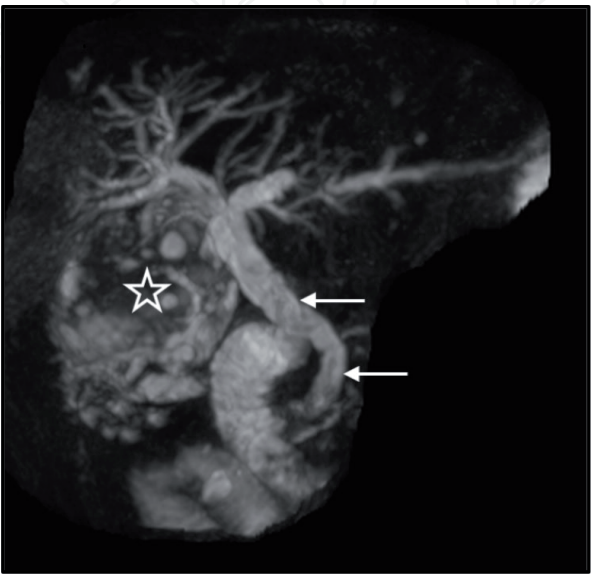


Figure 15.
MR cholangiography. Residual cyst membranes (white star). Cholangiohydatidosis.

4.3 Serology

Currently, diagnosis and follow-up of patients with cystic echinococcosis are achieved especially through imaging. Serology is used for the same purpose, using the detection of IgG-specific antigens. However, low sensitivity and specificity rates have been reported. In addition, false positives appear during follow-up due to the persistence of antibodies over time. There is a lot of research (recombined proteins, isotopic antibodies, subisotopic IgG, synthetic peptides), which seek to develop new antibodies by means of the molecular technique, allowing a better diagnosis of this parasitosis [41, 42].

5. Complications

Frequently, there are complications secondary to the hepatic location of the cyst or by involvement of adjacent organs, in which case symptoms and signs of greater intensity will appear. Among them, the following should be mentioned:

- More intense pain might appear when the Glisson capsule is stressed by larger cysts. In these cases, an abdominal mass mobilizing together with the respiratory movements is visualized during the physical examination. These giant cysts are easily visualized with the ultrasound. CT allows to define in more detail the elevated right hemidiaphragm and the development of secondary pulmonary basal atelectasis.
- Another complication of large cysts occurs when there is an intrahepatic breach or rupture of the cyst to the peritoneum either spontaneously or by trauma. The discharge of fertile hydatid fluid in the liver or peritoneal cavity causes anaphylaxis of a different magnitude and new hydatid implants [43]. These complications are better visualized with the use of CT.
- Cyst rupture and emptying of hydatid fluid or membranes into the biliary tree lead to obstructive jaundice, many times accompanied by severe acute cholangitis [44, 45]. The cysts can become infected as well and determine the formation of liver abscesses, which can sometimes lead to septicemia. In these cases, CT and MRC allow to achieve a better definition of the characteristics of the abscess and whether there is emptying of hydatid material into the biliary tree.
- The chronic inflammatory process of hepatic cysts located in segments of the liver dome determines firm adhesions to the right hemidiaphragm and even transits toward the pleuropulmonary space. As a result of this transphrenic transit, patients may present pleural empyemas or bronchopneumonia [46]. CT and MRC help to achieve a better definition and provide the most appropriate and safe management.
- There are occasions in which large cysts may be more complicated due to the simultaneous rupture and emptying of hydatid material to the biliary tree and bronchi. A bilio-pleuro-bronchial fistula is established with the occurrence of the pathognomonic sign of biliptysis, i.e., the expectoration of the bile. These patients present a fairly severe septic episode with hepatic and respiratory functional compromise [47]. The thorax-abdominal CT and MRC are useful to diagnose this complication [39].

- Rarely, cysts located adjacent to the retrohepatic vena cava can rupture and cause severe cardiorespiratory failure due to bilateral pulmonary arterial embolism with multiple pulmonar hydatid dissemination [48]. In that case, a CT angiography (CTA) is used to better diagnose this serious complication.

6. Surgical treatment

The main objective of the treatment of hepatic hydatidosis is the eradication of the parasite and avoidance of recurrence. There is consensus, in considering surgery as the best option to achieve this purpose. It is currently possible to perform different surgical techniques with acceptable rates of morbidity and mortality, which are applied according to the pathological conditions of cysts. In cases of greater complexity, surgery can be complemented with other therapies such as minimally invasive procedures and chemotherapy. Surgical treatment has indications and contraindications depending on the patient's condition and the forms of disease presentation [6].

At the dawn of the surgery to treat hepatic hydatidosis, only conservative techniques were used. Among them, marsupialization consisted in the opening and extraction of the parasite followed by externalizing the residual cavity toward the abdominal wall, waiting for the closure by secondary intention. Cysto-enteroanastomosis was also performed, anastomosing the hepatic residual cavity into the duodenum or a defunctionalized jejunal loop. Currently, these conservative techniques are not indicated due to the high risk of complications such as recurrences, liver abscesses, intestinal obstruction, biliary fistulas, biliomas, biliary peritonitis, cholangitis, and septicemia. However, there are surgical centers that report good results in cases with large cysts treated by laparoscopic cystojejunostomy [49].

There are various procedures of resective surgery performed in different surgical centers. When indicated, it is necessary to consider age, general condition of the patient, pathological state of the cysts and location in other organs, and the existence of important comorbidities difficult to control. Despite being a benign pathology, its evolution can sometimes be very complicated, requiring multiple surgeries and leading to a poor prognosis. The surgical resections are performed either through open or laparoscopic surgery. The following are the most used techniques from least to greatest complexity.

6.1 Subtotal cystectomy by open surgery

This technique, performed by open surgery, follows the steps below according to the location of the cysts (**Figures 18–21**):

- Right or bilateral subcostal laparotomy.
- In order to obtain a good access to the cyst, the section of the round ligament and the dissection of adhesions to the diaphragm or adjacent organs might be required. The use of intraoperative ultrasound is useful in posterior and central cyst locations, to avoid injuring the retrohepatic cava vein or hepatic veins.
- During puncture and removal of the fluid and hydatid membrane, it is necessary to isolate the surgical field with compresses embedded in scolical agents (20% hypertonic saline solution or diluted povidone iodine).

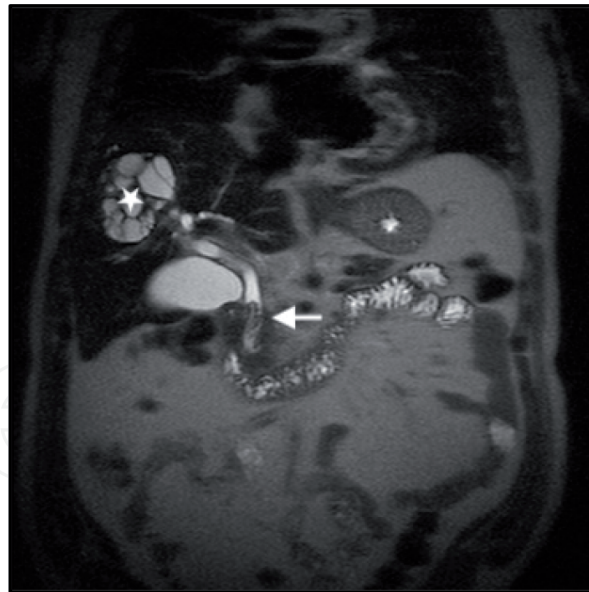


Figure 16.
 MRI T2 coronal septated cysts. Multiple daughter vesicles (white star). Membranes in bile duct (white arrow).

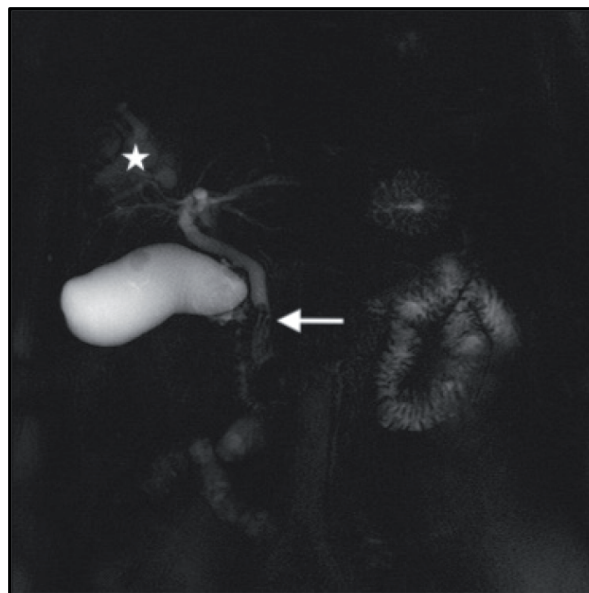


Figure 17.
 MR cholangiography. Same findings as demonstrated in Figure 15.

- Wide resection of the adventitia and further revision to eliminate daughter vesicles in cavities located in the remaining adventitia.
- Identification and suture of biliary communications.
- Closure of the residual cavity by means of capitonage or omentoplasty. In giant cysts, capitonage is not recommended to avoid distortion of the biliary tree and intrahepatic vasculature with subsequent functional sequelae.
- In some cases, to prevent postoperative biliary fistulae, a drain is placed in the residual cavity, or a choledocostomy with a Kehr tube is performed.
- When the cyst is close to the main bile duct or to the subhepatic and cava vein, the adjacent adventitia should be left in situ to prevent biliary fistulae or bleedings.

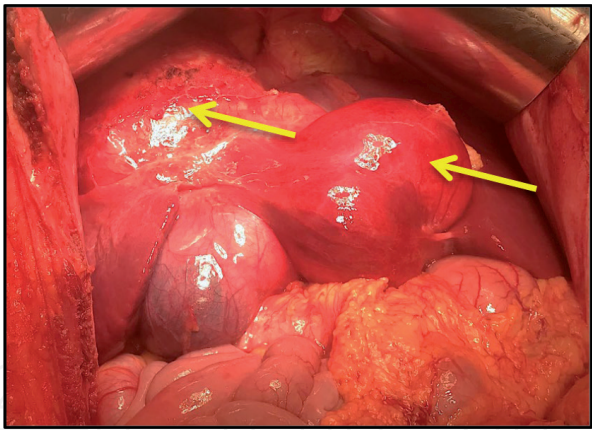


Figure 18.
Open surgery. Multiple cysts (yellow arrow).

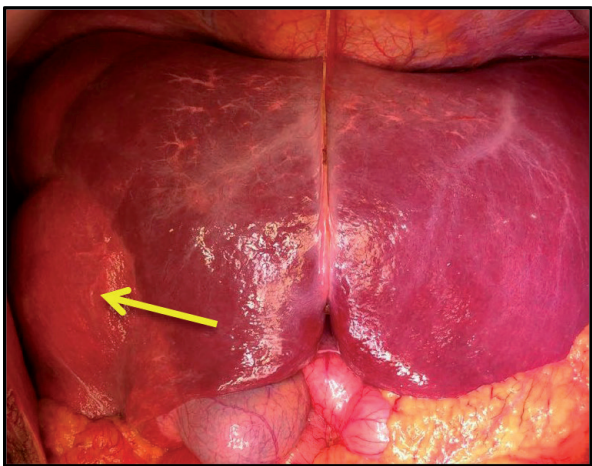


Figure 19.
Hepatic mobilization. Subcostal laparotomy.

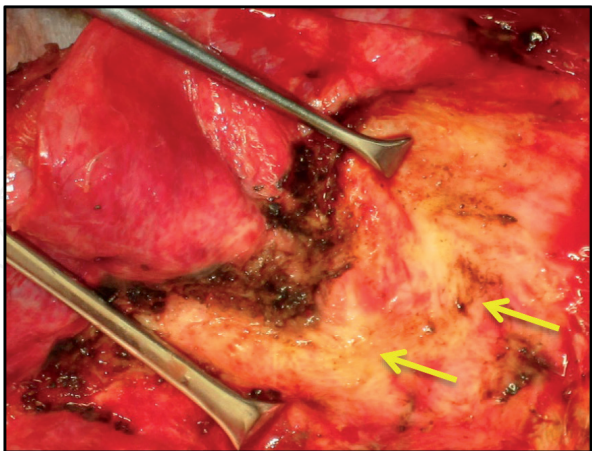


Figure 20.
Open surgery. Subtotal cystectomy biliary communications (yellow arrow).

6.2 Laparoscopic subtotal cystectomy

Laparoscopic subtotal hepatic cystectomy has all the advantages of minimally invasive procedures (**Figures 22–24**). It offers magnified vision with better appreciation of the cyst, residual cavity, and biliary communications. In addition, it presents less postoperative pain and earlier discharge. Comparative studies are reported

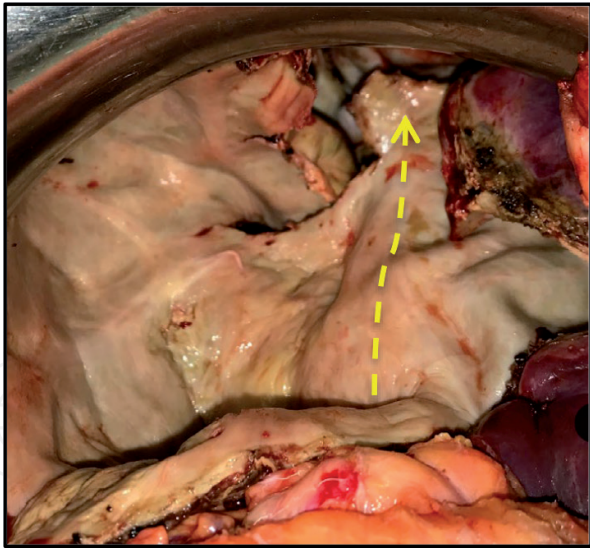


Figure 21.
Subtotal cystectomy. Giant hydatid cyst. Retrohepatic cava vein (yellow-dotted arrow).

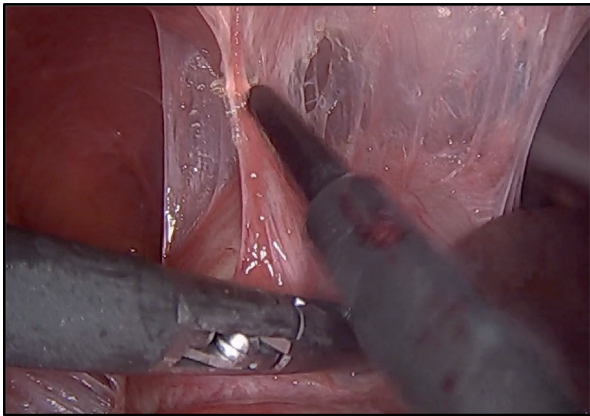


Figure 22.
Laparoscopic subtotal pericystectomy. Dissection of diaphragm adhesion.

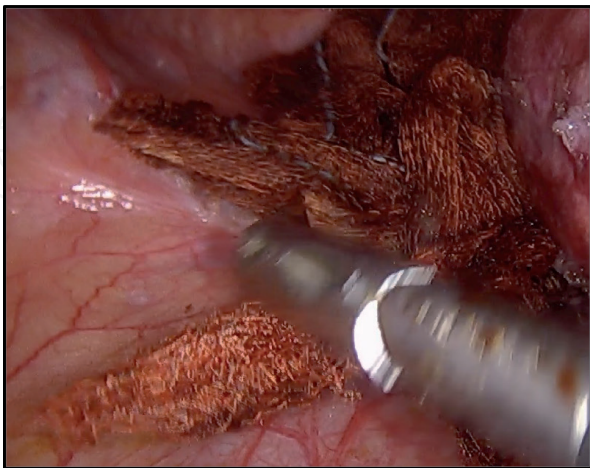


Figure 23.
Protection of the surgical field, iodine povidone.

between the two techniques, and the future trend seems to prefer laparoscopic technique [50]. However, technical difficulties currently persist to avoid the spillage of fertile hydatid material into the peritoneal cavity with anaphylactic reactions and secondary hydatid implants. For this reason, and to prevent this complication and

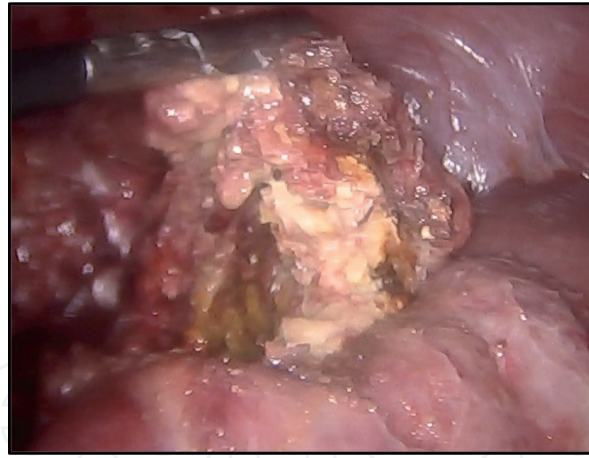


Figure 24.
Partial resection of adventitia.

a possible uncontrollable bleeding, the laparoscopic approach is contraindicated in the following situations:

- Cyst diameter more than 10 cm
- More than three cysts and/or presence of peritoneal cysts or in other organs
- Very thin or calcified adventitia
- Cysts located in the dome and central locations of the liver
- Complicated cysts with rupture and emptying on the biliary tree or peritoneum
- Imaging signs of accentuated pericystic inflammation
- Cysts with fibrous adhesions to the diaphragm on the way to a thoracic migration

Following the rules of laparoscopic liver surgery, the location of the entrance ports depends on the anatomical location of the cysts. To prevent the spillage of hydatid material into the peritoneal cavity, it is necessary to have a good puncture and aspiration system, similar to Perforator-Grinder [51].

6.3 Pericystectomy

Open or laparoscopic pericystectomy is based on the concept of complete parasite removal. This technique consists of resecting the cyst by a plane through the hepatic parenchyma adjacent to the adventitia, thus achieving avoidance of recurrence due to the presence of daughter vesicles in the adventitia or in the surrounding hepatic parenchyma [52]. In cases of complicated cysts, pericystectomy is not recommended due to the risk of further bleeding or bile duct injuries. Previous radiological studies are crucial to determine the relationship of these structures with the cysts. Currently, laparoscopic pericystectomy helps to prevent the aforementioned risks thanks to its magnified vision, more efficient hepatic transection instruments, and widespread access (**Figure 25**). Well-trained surgeons in laparoscopic hepatic surgery have a better chance of successfully performing this technique [53].

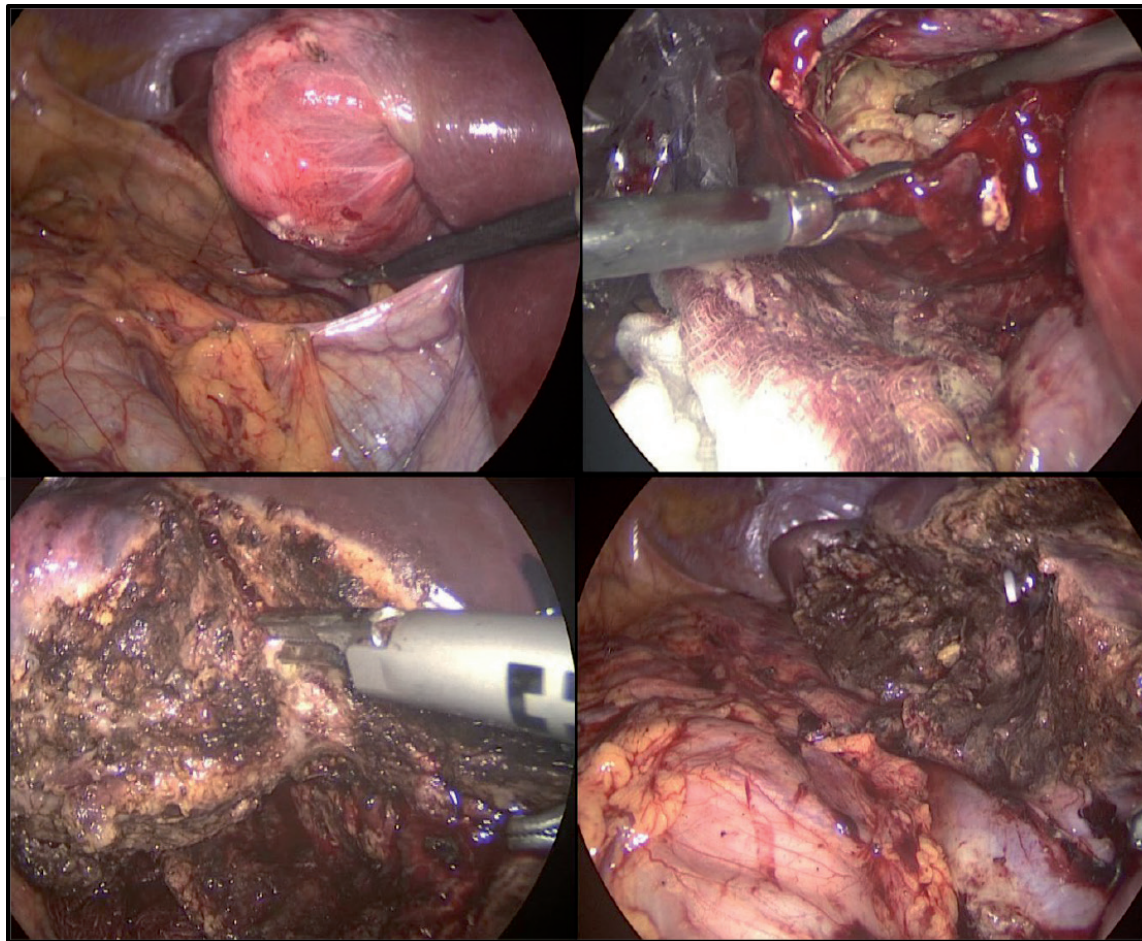


Figure 25.
Steps of laparoscopic pericystectomy.

6.4 Hepatic resection

Sometimes it is necessary to carry out liver resections, e.g., when there are hydatid recurrences in the same lobe previously operated or in residual cavities, which have the risk of subsequent infection with development of liver abscesses and cholangitis. When the infection is controlled by antibiotic therapy or percutaneous drainages, it is recommended to resect the compromised lobe, which is usually more atrophic. This surgery will be consequently more laborious. Nevertheless, the compensatory hypertrophy of the unaffected lobe determines a lower risk of postoperative hepatic failure. With the aim of completely eradicating the parasite and preventing recurrence, several surgical centers perform hepatic resection more frequently by both open and laparoscopic surgeries with acceptable morbidity and very low mortality. Liver resection is more indicated in alveolar echinococcosis by higher frequency of recurrence and infiltrative behavior similar to malignant neoplasms. There are recent reports of liver transplantation and also ex vivo resection surgery with autotransplantation for this type of echinococcosis [54]. Summarizing, hepatic resection, not very used in the past, now appears as a viable alternative for selected cases carried out in specialized reference centers.

The morbidity of resective surgery depends on the complexity of the hydatidosis and the magnitude of the surgery performed. Among the most difficult to treat are biliary fistulas, bleeding, and infections. For example, for patients with fistulization of the cyst toward the bile duct and thorax, it is advisable to work in stages, e.g., treating cholangitis first, and then, when the patient is stabilized, a pleural empyema is drained. Once general conditions have been recovered, the resective surgery is indicated. In relation to morbidity and mortality rates, what has been reported so far shows a great disparity of figures. A surgeon from our university conducted a

study of the risk factors that determine the postoperative morbidity in a significant number of international publications. The results indicate a fairly low level of evidence [55]. The challenge is to perform a prospective series, to achieve consensus on the indications of surgery to treat this complex disease.

7. Percutaneous treatment

This therapy is carried out by means of puncture, aspiration, injection of scolici-
dal agents, and reaspiration of fluid and hydatid membranes (PAIR). The procedure
is performed under ultrasonographic guidance in selected cases. This procedure was
developed by a Tunisian team in 1986. The WHO recommends this procedure
because it is less invasive when compared to surgery, allows a good evacuation of the
parasite, reduces the time of hospitalization, and is less expensive. The following
guidelines contain indications and contraindications for this procedure (**Tables 3**
and **4**) [56]. It is necessary to have anesthesiological support to treat an eventual
anaphylaxis crisis due to hydatid fluid spillage while PAIR is performed [57].

1. Non-echoic lesion 5 cm in diameter
2. Cysts with daughter cysts and/or membrane detachment
3. Multiple cysts if accessible to puncture
4. Infected cysts
5. Patients who fail to respond to chemotherapy alone
6. Patients in whom surgery is contraindicated
7. Patient who refuse surgery
8. Patients who relapse after surgery
9. Children >3 years old
10. Pregnant women

Table 3.
Indications for PAIR.

1. Noncooperative patient
2. Inaccessible or risky location of the liver cyst
3. Cyst in the spine, brain, and/or heart
4. Inactive or calcified lesion
5. Cyst communicating with the biliary tree

Table 4.
Contraindications for PAIR.

8. Chemotherapy

The use of treatments with drugs capable of penetrating and collapsing hepatic
hydatid cysts is reported in numerous publications. These drugs are prescribed alone or
together with surgery and less-invasive therapies such as PAIR. Currently, albendazole
has shown effectiveness in reducing the size or even causing the death of the parasite.
For this reason, it is employed to prevent recurrence after surgery. It is also used as the
only therapy in patients who refuse surgery or who are inoperable due to disseminated

hydatidosis or because of other comorbidities [58]. In Chile, it is indicated preoperatively in doses of 10 mg/kg of weight for one cycle of 14 or 21 days and postoperatively from one to three cycles according to eventual appearance of hepatic dysfunction.

9. Conclusion

Hepatic hydatidosis is still a disease that spreads without epidemiological control in many parts of the world. Also, a continuous biological adaptation of the parasite to subsist in the intermediate host has been demonstrated, which would explain the great difficulties in eradicating this zoonosis. The permanent and even increasing incidence of this disease determines very high health costs necessary to treat patients, sometimes with complex pathological presentations. Efforts are being made to find new alternatives to diagnose early stages of the parasitosis. The creation of new vaccines with the intention of immunizing the intermediate host would determine a better control of human hydatidosis. Surgical advances are allowing for more and more radical surgical procedures with acceptable rates of morbidity and mortality. However, the implementation of minimally invasive surgeries presents significantly higher costs. Logic would dictate that the best path is to minimize the number of new patients affected through successful epidemiological control.

Author details

Luis Burgos San Juan^{1,2,3*}, Hector Losada Morales^{1,2,3}, Jorge Silva Abarca^{1,2,3}, Cesar Muñoz Castro^{4,5}, Marcelo Klein Diaz⁶ and Pablo Guzmán González⁷

1 Hepatobiliopancreatic Surgery Unit, Surgery Service,
Hospital Dr. Hernán Henríquez, Temuco, Chile

2 Surgery Department, Universidad de la Frontera, Temuco, Chile

3 Surgery Department, Clínica Alemana de Temuco, Chile

4 Digestive Surgery and Hepatobiliopancreatic Surgery Unit, Surgery Service,
Hospital Regional, Talca, Chile


5 Department of Surgery, Universidad Católica del Maule, Talca, Chile

6 Interventional Radiology Unit, Imaging Service, Hospital Dr. Hernán Henríquez,
Temuco, Chile

7 Pathological Anatomy Department, Hospital Dr. Hernán Henríquez Aravena,
Temuco, Chile

*Address all correspondence to: luis.burgos.s@ufrontera.cl

IntechOpen

© 2019 The Author(s). Licensee IntechOpen. This chapter is distributed under the terms of the Creative Commons Attribution License (<http://creativecommons.org/licenses/by/3.0>), which permits unrestricted use, distribution, and reproduction in any medium, provided the original work is properly cited. 

References

- [1] Ebell B, Banov L Jr. The Papyrus Ebers: The Greatest Egyptian Medical Document. Copenhagen: Levin & Munksgaard; 1937
- [2] Cordero del Campillo M. Notas históricas de la equinococosis/hidatidosis. In: Jornada científica de la Asociación Española de Hidatidología Parte I. León: Universidad de León. 19-X-2007
- [3] Eckert J, Thompson RC. Historical aspects of Echinococcosis. *Advances in Parasitology*. 2017;**95**:1-64
- [4] Nakao M, Lavikainen A, Yanagida T, Ito A. Phylogenetic systematics of the genus *Echinococcus* (Cestoda: Taeniidae). *International Journal for Parasitology*. 2013;**43**(12-13):1017-1029
- [5] Brunetti E, Garcia HH, Junghanss T, International CE Workshop in Lima, Peru, 2009. Cystic echinococcosis: Chronic, complex, and still neglected. *PLoS Neglected Tropical Diseases*. 2011;**5**(7):e1146
- [6] Sozuer E, Akyuz M, Akbulut S. Open surgery for hepatic hydatid disease. *International Surgery*. 2014;**99**:764-769
- [7] Gomez i Gavara C, López-Andújar R, Belda Ibáñez T, Ramia Angel JM, Moya Herraiz Á, Orbis Castellanos F, et al. Review of the treatment of liver hydatid cysts. *World Journal of Gastroenterology*. 2015;**21**(1):124-131
- [8] Cortes S, Valle C. Human hydatidosis: General aspects and epidemiological situation in Chile according to hospital discharge and mandatory reporting from 2001 to 2005. *Revista Chilena de Infectología*. 2010;**27**:329-335
- [9] Deplazes P, Rinaldi L, Alvarez Rojas CA, Torgerson PR, Harandi MF, Romig T, et al. Global distribution of alveolar and cystic Echinococcosis. *Advances in Parasitology*. 2017;**95**:315-493
- [10] Grosso G, Gruttadauria S, Biondi A, Marventano S, Mistretta A. Worldwide epidemiology of liver hydatidosis including the Mediterranean area. *World Journal of Gastroenterology*. 2012;**18**(13):1425-1437
- [11] Brunetti E, Kern P, Vuitton DA, Writing Panel for the WHO-IWGE. Expert consensus for the diagnosis and treatment of cystic and alveolar echinococcosis in humans. *Acta Tropica*. 2010;**114**:1-16
- [12] Christofi P, Deplazes N, Christofi I, Tanner PE, et al. Screening of dogs for *Echinococcus granulosus* coproantigen in a low endemic situation in Cyprus. *Veterinary Parasitology*. 2002;**104**:299-306
- [13] Chen KF, Tang YY, Wang R, Fang D, Chen JH, Zeng Y, et al. The choose of different surgical therapies of hepatic alveolar echinococcosis: A single-center retrospective case-control study. *Medicine (Baltimore)*. 2018;**97**(8):e0033
- [14] Mayor P, Baquedano LE, Sanchez E, Aramburu J, Gomez-Puerta LA, Mamani VJ, et al. Polycystic echinococcosis in Pacas, Amazon region, Peru. *Emerging Infectious Diseases*. 2015;**21**(3):456-459
- [15] D'Alessandro A, Rausch RL. new aspects of neotropical polycystic (*echinococcus vogeli*) and unicystic (*echinococcus oligarthrus*) echinococcosis. *Clinical Microbiology Reviews*. 2008;**21**(2):380-401
- [16] Boufana B, Qiu J, Chen X, Budke CM, Campos-Ponce M, Craig PS. First report of echinococcus shiquicus in dogs from eastern Qinghai-Tibet plateau region, China. *Acta Tropica*. 2013;**127**(1):21-24
- [17] Hüttner M, Nakao M, Wassermann T, Siefert L, Boomker JD, Dinkel A, et al.

- Genetic characterization and phylogenetic position of *Echinococcus felidis* (Cestoda: Taeniidae) from the African lion. *International Journal for Parasitology*. 2008;**38**(7):861-868
- [18] Romig T, Deplazes P, Jenkins D, Giraudoux P, Massolo A, Craig PS, et al. Ecology and life cycle patterns of *Echinococcus* species. *Advances in Parasitology*. 2017;**95**:213-314
- [19] Xiao N, Qiu J, Nakao M, Li T, Yang W, Chen X, et al. *Echinococcus shiquicus*, a new species from the Qinghai-Tibet plateau region of China: Discovery and epidemiological implications. *Parasitology International*. 2006;**55** Suppl:S233-S236
- [20] Carmena D, Cardona GA. Echinococcosis in wild carnivorous species: Epidemiology, genotypic diversity, and implications for veterinary public health. *Veterinary Parasitology*. 2014;**202**(3-4):69-94. DOI: 10.1016/j.vetpar.2014.03.009. Epub 2014 Mar 15
- [21] Rinaldi F, Brunetti E, Neumayr A, Maestri M, Goblirsch S, Tamarozzi F. Cystic echinococcosis of the liver: A primer for hepatologists. *World Journal of Hepatology*. 2014;**6**:293-305
- [22] Bhutani N, Kajal P. Hepatic echinococcosis: A review. *Annals of Medicine and Surgery (London)*. 2018;**36**:99-105
- [23] Pakala T, Molina M, Wu GY. Hepatic Echinococcal cysts: A review. *Journal of Clinical and Translational Hepatology*. 2016;**4**(1):39-46
- [24] Mihmanli M, Idiz UO, Kaya C, Demir U, Bostanci O, Omeroglu S, et al. Current status of diagnosis and treatment of hepatic echinococcosis. *World Journal of Hepatology*. 2016;**8**(28):1169-1181
- [25] Zhang W, Wen H, Li J, Lin R, McManus DP. Immunology and immunodiagnosis of cystic echinococcosis: An update. *Clinical & Developmental Immunology*. 2012;**2012**:101895
- [26] McManus DP, Gray DJ, Zhang W, Yang Y. Diagnosis, treatment, and management of echinococcosis. *BMJ*. 2012;**344**:e3866
- [27] Eckert J, Deplazes P. Biological, epidemiological, and clinical aspects of echinococcosis, a zoonosis of increasing concern. *Clinical Microbiology Reviews*. 2004;**17**(1):107-135
- [28] Gharbi HA, Hassine W, Brauner MW, Dupuch K. Ultrasound examination of the hydatid liver. *Radiology*. 1981;**139**:459-463
- [29] Group WHOIW. International classification of ultrasound images in cystic echinococcosis for application in clinical and field epidemiological settings. *Acta Tropica*. 2003;**85**:253-261
- [30] Solomon N, Fields PJ, Tamarozzi F, Brunetti E, CNL M. Expert reliability for the World Health Organization standardized ultrasound classification of cystic echinococcosis. *The American Journal of Tropical Medicine and Hygiene*. 2017;**96**(3):686-691
- [31] Kammerer WS, Schantz PM. Echinococcal disease. *Infectious Disease Clinics of North America*. 1993;**7**(3):605-618
- [32] Macpherson CN, Bartholomot B, Frider B. Application of ultrasound in diagnosis, treatment, epidemiology, public health and control of *Echinococcus granulosus* and *E. multilocularis*. *Parasitology*. 2003;**127**(Suppl):S21-S35
- [33] Hosch W, Junghanss T, Werner J, Dux M. Imaging methods in the diagnosis and therapy of cystic echinococcosis. *Röfo*. 2004;**176**:679-687

- [34] Cai D, Li Y, Jiang Y, Wang H, Wang X, Song B. The role of contrast-enhanced ultrasound in the diagnosis of hepatic alveolar echinococcosis. *Medicine (Baltimore)*. 2019;**98**(5):e14325
- [35] Marrone G, Crino' F, Caruso S, Mamone G, Carollo V, Milazzo M, et al. Multidisciplinary imaging of liver hydatidosis. *World Journal of Gastroenterology*. 2012;**18**:1438-1447
- [36] Stojkovic M, Rosenberger K, Kauczor HU, Junghanss T, Hosch W. Diagnosing and staging of cystic echinococcosis: How do CT and MRI perform in comparison to ultrasound? *PLoS Neglected Tropical Diseases*. 2012;**6**:e1880
- [37] Hosch W, Stojkovic M, Janisch T, Heye T, Werner J, Friess H, et al. MR imaging for diagnosing cysto-biliary fistulas in cystic echinococcosis. *European Journal of Radiology*. 2008;**66**:262-267
- [38] Tocchi A, Mazzoni G, Miccini M, Drumo A, Cassini D, Colace L, et al. Treatment of hydatid bronchobiliary fistulas: 30 years of experience. *Liver International*. 2007;**27**(2):209-214
- [39] Muñoz C, Burgos L, Fonseca V. Fístula biliobronquial de origen hidatídico. *Revista Chilena de Cirugía*. 2009;**61**(6):504-506
- [40] Dolay K, Akbulut S. Role of endoscopic retrograde cholangiopancreatography in the management of hepatic hydatid disease. *World Journal of Gastroenterology*. 2014;**20**(41):15253-15261
- [41] Manzano-Román R, Sánchez-Ovejero C, Hernández-González A, Casulli A, Siles-Lucas M. Serological diagnosis and follow-up of human cystic echinococcosis: A new Hope for the future? *BioMed Research International*. 2015;**2015**:428205
- [42] Hernández-González A, Sánchez-Ovejero C, Manzano-Román R, González Sánchez M, Delgado JM, Pardo-García T, et al. Evaluation of the recombinant antigens B2t and 2B2t, compared with hydatid fluid, in IgG-ELISA and immunostrips for the diagnosis and follow up of CE patients. *PLoS Neglected Tropical Diseases*. 2018;**12**(9):e0006741
- [43] Atli M, Kama NA, Yuksek YN, Doganay M, Gozalan U, Kologlu M, et al. Intrabiliary rupture of a hepatic hydatid cyst: Associated clinical factors and proper management. *Archives of Surgery*. 2001;**136**:1249-1255
- [44] Busić Z, Amić E, Servis D, Predrijevac M, Stipanić I, Busić D. Common bile duct obstruction caused by the hydatid daughter cysts. *Collegium Antropologicum*. 2004;**28**(1):325-329
- [45] Nemati Honar B, Hayatollah G, Nikshoar M, Forootan M, Feizi AM. Liver hydatid cyst and acute cholangitis: A case report. *Acta Medica Iranica*. 2016;**54**(4):286-288
- [46] Msaad S, Yangui I, Ketata W, Abid N, Feki W, Abid H, et al. Hydatid cysts of the liver ruptured into the thorax (about five cases). *Revue de Pneumologie Clinique*. 2015;**71**(5):255-263
- [47] Bel Haj Salah R, Triki W, Bourguiba MB, Ben MM, Zaouche A. Rupture aiguë d'un kyste hydatique foie dans la plèvre droite À propos de deux observations. *Chirurgie Thoracique et Cardio-Vasculaire*. 2011;**15**(3):182-184
- [48] Bayaroğullari H, Davran R, Cavuş Y, Yetim TD, Evirgen Ö. Liver hydatid cyst leading to bilateral pulmonary artery embolism and bilateral multiple pulmonar echinococcosis via inferior vena cava: Report of a case. *Clinical Imaging*. 2013;**37**(2):374-378

- [49] Yilmaz H, Sahin M, Ece I, Yormaz S, Alptekin H. A new approach to the complicated liver Hydatid cyst-laparoscopic roux-en-Y Cystojejunostomy. *Prague Medical Report*. 2015;**116**(3):233-238
- [50] Jabbari Nooghabi A, Mehrabi Bahar M, Asadi M, Jabbari Nooghabi M, Jangjoo A. Evaluation and comparison of the early outcomes of open and laparoscopic surgery of liver Hydatid cyst. *Surgical Laparoscopy, Endoscopy & Percutaneous Techniques*. 2015;**25**(5):403-407
- [51] Sormaz IC, Avtan L. Minimally-invasive treatment of hepatic hydatid disease with perforator-grinder-aspirator apparatus and follow-up of 42 patients. *Acta Gastroenterologica Belgica*. 2017;**80**(4):477-480
- [52] Peng X, Zhang S, Niu JH. Total subadventitial cystectomy for the treatment of 30 patients with hepatic hydatid cysts. *Chinese Journal of General Surgery*. 2002;**17**:529-530
- [53] Tai QW, Tuxun T, Zhang JH, Zhao JM, Cao J, Muhetajiang M, et al. The role of laparoscopy in the management of liver hydatid cyst: A single-center experience and world review of the literature. *Surgical Laparoscopy, Endoscopy & Percutaneous Techniques*. 2013;**23**(2):171-175
- [54] Wen H, Vuitton L, Tuxun T, Li J, Vuitton DA, Zhang W, et al. Echinococcosis: Advances in the 21st century. *Clinical Microbiology Reviews*. 2019;**32**(2)
- [55] Manterola C, Otzen T, Muñoz G, Alanis M, Kruuse E, Figueroa G. Surgery for hepatic hidatidosis. Risk factors and variables associated with postoperative morbidity. Overview of the existing evidence. *Cirugía Española*. 2017;**95**(10):566-576
- [56] PAIR: Puncture, Aspiration, Injection, Re-Aspiration- An option for the treatment of Cystic Echinococcosis World Health Organization. WHO/CDS/CSR/APH/2001.6
- [57] Kabaalioğlu A, Ceken K, Alimoglu E, Apaydin A. Percutaneous imaging-guided treatment of hydatid liver cysts: Do long-term results make it a first choice? *European Journal of Radiology*. 2006;**59**(1):65-73
- [58] Dehkordi AB, Sanei B, Yousefi M, Sharafi SM, Safarnezhad F, Jafari R, et al. Albendazole and treatment of hydatid cyst, review of literature. *Infectious Disorders Drug Targets*. 2018. [Epub ahead of print]