

We are IntechOpen, the world's leading publisher of Open Access books Built by scientists, for scientists

6,900

Open access books available

185,000

International authors and editors

200M

Downloads

Our authors are among the

154

Countries delivered to

TOP 1%

most cited scientists

12.2%

Contributors from top 500 universities



WEB OF SCIENCE™

Selection of our books indexed in the Book Citation Index
in Web of Science™ Core Collection (BKCI)

Interested in publishing with us?
Contact book.department@intechopen.com

Numbers displayed above are based on latest data collected.
For more information visit www.intechopen.com



Decision-Making for ALL Reconstruction and Surgical Techniques

Tahsin Gulpinar

Abstract

The anterolateral ligament (ALL), which was first described in 1879, was reintroduced in 2013 by Claes et al. It originates near the lateral epicondyle of the distal femur, runs along the lateral outer aspect of the knee, and inserts on the proximal tibia between Gerdy's tubercle and fibular head. The ALL tightens when the knee is internally rotated (twisted inwards), and in doing so, it is proposed to be a stabilizer to internal tibial rotation. Biomechanical studies showed that the ALL restrains internal rotation of the tibia and thus affects the pivot-shift phenomenon in the anterior cruciate ligament (ACL)-injured knee. Therefore, it is proposed that the deficient ALL can be a reason for persistent rotatory instability after ACL reconstruction. Furthermore, ALL reconstruction techniques have evolved and indications extended. Commonly accepted indications for concomitant ACL and ALL reconstruction are ACL revisions, high-grade pivot-shift test, chronic ACL rupture, and young patients and patients doing pivoting activities. Most surgeons perform an anatomic reconstruction technique with gracilis autograft. However, only few studies published reporting the outcomes of ALL reconstruction and more studies with longer follow-up times are, therefore, needed to provide the compelling clinical evidence for the efficacy of concomitant ACL and ALL procedures.

Keywords: anterolateral ligament, ALL reconstruction, indications for ALL reconstruction, anterior cruciate ligament, pivot shift

1. Introduction

The anterolateral ligament (ALL) is a newly re-introduced ligament on the lateral aspect of the knee, which originates at the lateral epicondyle of the femur, and inserts at the anterolateral aspect of the proximal tibia. It was first described by Paul Segond as "a pearly, resistant, fibrous band" at the anterolateral aspect of the human knee; however, it was not given much importance until Claes et al. identified the ALL in an anatomic study as a distinct structure of the lateral compartment of the knee [1]. Subsequently, many studies have been published regarding the anatomy, biomechanics, and radiology of ALL.

The clinical relevance of ALL mostly comes from its high association with anterior cruciate ligament (ACL) injuries. Studies showed a high incidence of radiological ALL damage (78.7%) in ACL-injured knees [2]. Biomechanically, it is claimed to be a stabilizer in internal rotation of the tibia particularly at high knee flexion

angles; however, the biomechanical role of ALL is still the subject of debate [3, 4]. This chapter reviews the main features related to ALL and focuses on the current indications and techniques of ALL reconstruction.

2. Anatomy

The anatomy of the ALL has been investigated by several authors in order to accurately identify the features of the structure. There has been some debate regarding the exact attachments of the ligament; however, it is generally accepted that the ALL is a distinctive triangular, anterolateral structure under the iliotibial band (ITB). Investigations of the anatomy of the ALL in several cadavers have revealed variability of the structure particularly for the femoral attachment. The femoral origin is located at the lateral femoral epicondyle (LFE) at either the identical position of the origin of the fibular collateral ligament (FCL) or just posterior and proximal to it with the average width at this point 11.85 mm [5]. The ALL then runs distally by overlapping the proximal portion of the lateral collateral ligament, and some fibers of the ALL are attached to the lateral meniscus and the anterolateral capsule at the level of knee joint. The majority of the fibers continue to run distally and attach midway between the tip of the fibular head and GT (**Figure 1**). The tibial attachment is 12.2 ± 3.0 mm width and is centered 21.6 mm posterior to Gerdy's tubercle, and 4–10 mm far from the joint line [1, 6–8]. The mean length of the structure has been measured between 34 and 59 mm from its femoral origin to tibial attachment [7, 8]. The thickness of ALL also varies and has been measured as 2.09 mm in males and 1.09 mm in females [9].

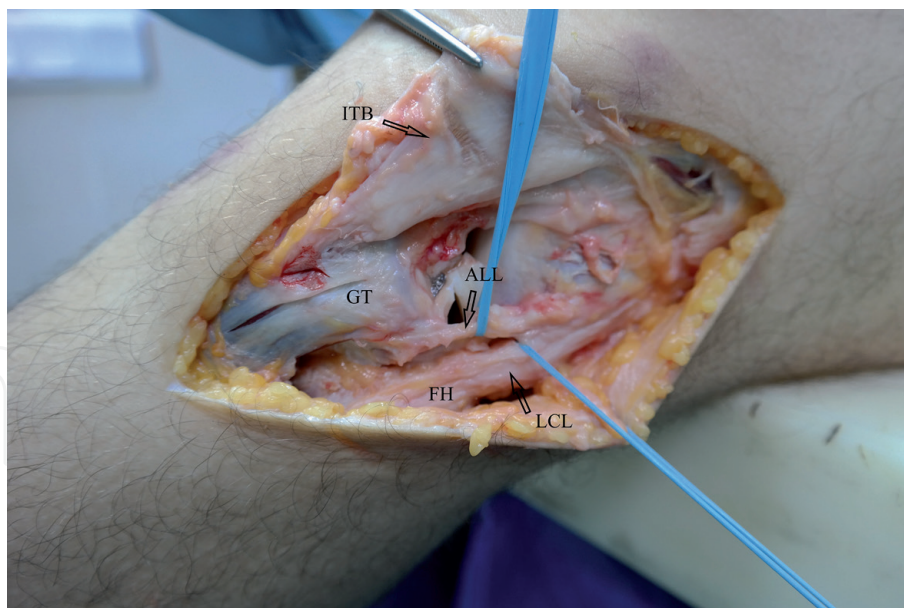


Figure 1. Anterolateral ligament anatomy (ITB: iliotibial band, ALL: anterolateral ligament, FH: fibular head, GT: Gerdy's tubercle, and LCL: lateral collateral ligament).

3. Biomechanics

Zens et al. [10] found that the isolated ALL had an ultimate tensile strength of 50 ± 15 N, at a strain of $36 \pm 4\%$. With a mean cross-sectional area of only 1.54 mm^2 , the ultimate tensile stress was 33 ± 4 MPa and the overall stiffness was 4.2 N/mm extension. However, Kennedy et al. [11] reported that the ALL had a tensile

strength of 175 N (139–211 N 95% CI) and stiffness 20 N/mm [12–21] with a more substantial structure than that shown by Zens et al. [10]. The mean ultimate load to failure and the mean stiffness of ALL have been measured between 50 and 205 N and between 20 and 42 N/mm, respectively, in different studies [11, 22, 23].

In most of the studies, the ALL is described as a secondary stabilizer to internal rotation and to some extent anterior translation [3, 24, 25]. The biomechanical studies demonstrated that in the presence of ACL deficiency, sectioning the ALL in cadaveric specimens significantly effects the anteroposterior (AP) stability as well as results in a significant increase in internal rotation [12, 24]. The contribution of the ALL during internal rotation increases significantly with increasing flexion, whereas that of the ACL decreased significantly. Therefore, it is speculated that the ALL deficiency can be a reason for persistent rotational instability after ACL reconstruction [13].

The isometry of the ALL was measured by Dodds et al. [7], by threading a suture along the ligament fibers, attaching it to the moving tibia and then measuring the changes of the separation distance between the attachments using a transducer. It was shown that the ALL was not isometric, but was close to being isometric from 0 to 60° knee flexion. Internal tibial rotation increased the length between the attachments, and external rotation reduced it. When the knee was in extension, tibial rotations in response to 5 Nm torque were not large enough to cause significant change in the length of the ALL. However, internal tibial rotation increased the mean length between the ALL attachments from 3.6 mm (SD 0.7; 1.5–5.7) at 30° ($p = 0.003$) to 9.9 mm (SD 1.4; 5.7–14.2) at 90° of flexion of the knee. Imbert et al. [14] investigated isometric characteristics of the ALL in a cadaveric navigation study and found that ALL is not isometric at any of the femoral insertion locations but had different length change patterns during knee flexion and internal tibial rotation at 90°. However, they found that the proximal and posterior to epicondyle femoral position is favorable to being isometry.

4. Injury

Injury to the ALL is most commonly associated with a concomitant tear of the ACL. In a retrospective MRI study, Claes et al. [2] analyzed 206 ACL injured knees and found 78.8% radiological ALL abnormalities. Most of the ALL abnormalities were found to be situated in the distal part of the ligament (77.8%), whereas 20.4% of the injuries were proximal and only 1.8% knees were diagnosed with a bony ALL avulsion. Ferretti et al. [15] exposed the lateral knee compartments of 60 patients undergoing ACLR and found several lesion types of the ALL injuries including macroscopic hemorrhage extending to the anterolateral capsule (32%) or to the posterolateral capsule (27%), complete transverse tear of the ALL near its tibial insertion (22%), and a bony tibial avulsion (Segond fracture) (10%). In a retrospective MRI study, Gurpinar et al. found 65.2% ALL injury in patients underwent ACL surgery who were diagnosed with isolated ACL injury previously [13]. In a similar study, van Dyck et al. [16] found ALL abnormalities in 46% of 90 knee MRIs of patients with an acute ACL rupture. Furthermore, they found that these patients were more likely to have a lateral meniscal tear, collateral ligament injury, or osseous injury compared with patients with an intact ALL.

After re-discovery of ALL, Segond fractures, which were previously considered as a diagnostic clue for ACL injury, are classified as ALL equivalent injuries [17]. Porrino et al. [18] evaluated 20 knee MRIs with a Segond fracture and found that the ALL was attached to the fracture fragment in all but one case limited by anatomic distortion. Claes et al. [17] also suggested that the Segond fracture is actually

a bony avulsion of the ALL. However, Shaikh et al. [19] claimed that ITB and lateral capsule attached to the Segond fracture in 94% of the patients and Segond fracture is not merely an ALL avulsion but the avulsion of the anterolateral complex.

On the other hand, anterolateral injuries and instability can also occur in the ACL intact states. Gottsegen et al. [20] and DeLee et al. [21] reported the Segond fracture combined to popliteal tendon avulsion and iliotibial band avulsion. Wharton et al. [26] published a case report in which the Segond fracture was combined to posterolateral ligament injury without ACL rupture. Furthermore, Ferreira reported an absolute isolated Segond fracture.

5. Diagnosis

Diagnosing ALL lesions can be difficult since no specific clinical tests have been validated for the diagnosis of ALL injuries. To achieve an impeccable diagnosis, meticulous clinical examination and appropriate evaluation of the radiographic and MRI imaging are necessary. Since ALL is highly associated with ACL injury, patients subjected to trauma mechanisms similar to an isolated ACL injury such as contact and noncontact injuries involving early flexion, dynamic valgus, and internal rotation should also be suspected for ALL injury. Anterior drawer and Lachman tests can be positive due to the concomitant ACL injury. However, since ALL is primarily responsible for rotational stability, pivot-shift test is considered to be the most reliable test to evaluate ALL integrity. Monaco et al. [27] demonstrated that a grade III pivot shift is only seen in the absence of both the ACL and ALL in vitro. However, the potential confusing factors of a high-grade pivot shift, such as a lateral meniscus or root tear, ITB injury, or general hyperlaxity should be assessed [28, 29].

Segond fracture is also considered to be ALL avulsion, and therefore, it can be assumed that symptoms related to a Segond fracture may be present in ALL injury including provoked pain on palpation of the lateral tibia or increased laxity in varus stress. On examination, the lateral compartment of the knee should be carefully evaluated, and the integrity of the cruciate and collateral ligaments should be examined too. However, in the acute phase, diagnosis can be challenging and evaluation should be repeated in subacute and chronic phases after swelling and pain has decreased.

6. Surgical indications

The optimal ACL reconstruction is still a debate in orthopedic research, and persistent rotatory instability has been reported up to 25% of cases after an isolated ACL reconstruction procedure [30]. Some studies found that an isolated ACL reconstruction can control the translational instability, but is insufficient to restore the normal rotational stability. In addition, the persistent rotatory instability does not only cause difficulties with pivoting sports, but also can cause secondary meniscal and cartilaginous problems [31]. Furthermore, younger and higher-level athletes with rotational instability can be vulnerable to re-ruptures. Therefore, combining a lateral extra-articular procedure with an intra-articular reconstruction for the treatment of ACL injury emerged, with the aim of decreasing rotational instability. However, long-term results of ALL reconstruction are not known and have not been suggested as a standard procedure with ACL reconstruction. Despite this, additional ALL reconstruction has been recommended in patients with grade III pivot shift or Segond fracture and athletes practicing of sports with pivot movements [32–34]. In addition ACL revision, subjective rotational looseness, and Telos

value >10 mm are also considered as indicative of ALL reconstruction associated with ACL reconstruction [35]. Some surgeons also suggested ALL reconstruction in cases of chronic ACL reconstruction, high level of sports activity, and radiographic lateral femoral notch sign [36].

Recently the ALL Expert Group [37] proposed a decision tree for the management of ACL ruptures and recommended ALL reconstruction for patients who present at least: (1) decisive criteria for increased risk of secondary ACL rupture or postoperative residual positive pivot shift or (2) secondary criteria for increased risk of secondary ACL rupture or postoperative residual positive pivot shift including history, clinical or imaging signs, or patient profile. However, literature still lacks good-quality randomized studies and more studies are needed to prove these findings.

7. Reconstruction

7.1 Graft type and preparation

Wytrykowski et al. [38] performed a cadaveric study to compare the biomechanical properties of the ALL, gracilis, and IT band. The gracilis was found to have six times the stiffness of the ALL (131.7 vs. 21 N/mm) and had the highest maximum load to failure (200.7 vs. 141 N). The mechanical properties of the IT band (stiffness, 39.9 N/mm; maximum load to failure, 161.1 N) most closely resembled those of the ALL. However, many authors have published techniques using a gracilis graft for ALL reconstruction and a tripled semitendinosus auto- or allograft or quadrupled semitendinosus autograft with all-inside technique for the reconstruction of ACL [39–41]. The use of polyester tape [42] or a single-bundle semitendinosus auto- or allograft has also been described in the literature [43]. In our clinic, we use gracilis graft for ALL reconstruction, and for the ACL, we use quadriceps autograft, tripled semitendinosus, or allograft.

7.2 Femoral and tibial origins and fixation

On the tibia, the anatomical landmarks are the center of the fibula head, the center of Gerdy's tubercle, and joint line (**Figure 2a**). We use the midpoint between Gerdy's tubercle and the fibula at 5–10 mm below the lateral joint line for the site of tibial fixation. We make a stab incision 5–10 mm below the joint line, halfway between the center of Gerdy's tubercle and the fibula head (**Figure 2b**). Helito et al. [44] have described the radiographic landmarks to determine this location. They choose a point around 7 mm below the tibial plateau on the AP view and around 50% of the plateau length on the lateral view [39]. Similar tibial attachment points have been used by many authors; however, some surgeons used two attachment points, and therefore, they used one point just anterior to the fibular head and second point posterior to the Gerdy's tubercle [45].

Since the origin of the femoral insertion of the ALL varies, the location of femoral fixation during ALLR is a debate. Many authors [40, 46, 47] described a fixation at a point posterior and superior to the lateral femoral epicondyle; however, some [41, 42] described a fixation slightly anterior to the lateral epicondyle. As a radiological reference point, Helito et al. used Blumensaat's line and identified the femoral attachment at approximately halfway along Blumensaat's line from the anterior edge of the femoral condyle [44]. Kennedy et al. used the intersection of two lines: one was the parallel extension of the posterior femoral cortex and the second line was drawn perpendicularly to the first line and intersecting the most

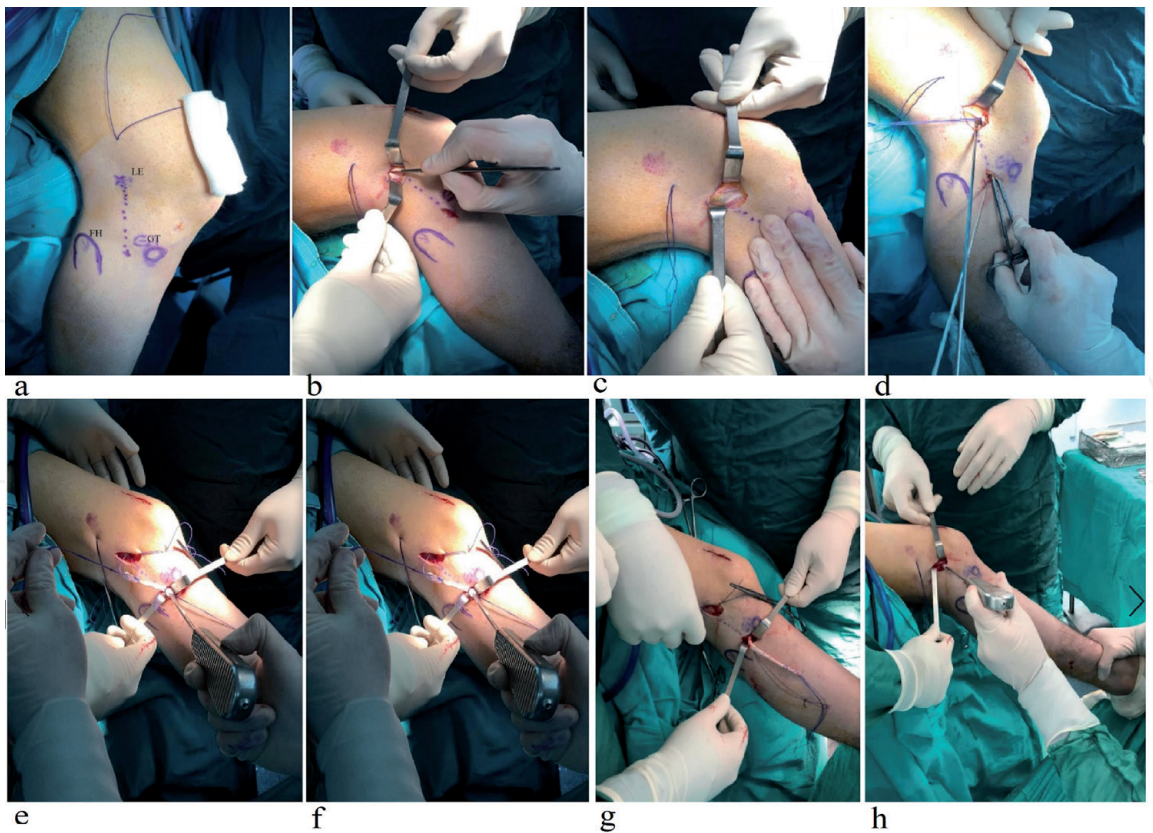


Figure 2.
Step-by-step anterolateral ligament reconstruction.

posterior aspect of Blumensaat's line [11]. In our clinic, we make a 5–10 mm incision just proximal to the epicondyle, and after dividing the ITB, we insert the drill pin slightly proximal and posterior to the lateral epicondyle (**Figure 1c** and **d**).

After inserting femoral and tibial pin guides, the passing suture is placed under the ITB around the femoral wire and tibial wires. The knee is then moved through the full range of motion (**Figure 1d**). The isometry assessment is made to be sure that the graft will not tighten in flexion and will be tight in extension. If the suture tightens in flexion, the femoral socket may be too distal or anterior.

After the isometry test, the graft is passed under the ITB and fixed with interference screws or anchors on both sides, while the knee is 30° flexed and at neutral rotation (**Figure 2**). However, fixation in full extension at 45–60° of flexion or fixation at 60–90° of flexion have also been described in the literature [39, 40, 47]. Different surgical techniques and indications are summarized in **Table 1**.

8. Postoperative rehabilitation

The plaster cast immobilization or bracing were popular in the historical literature when ACL and lateral extra-articular procedures were performed together [49]. However, use of brace is much less common in current practice. Many authors recommend that rehabilitation after an additional ALL reconstruction should be carried out in a similar way compared to isolated ACL rehabilitation. An early aggressive rehabilitation program can be applied. Emphasis should be placed on achieving symmetrical full knee extension, decreasing knee joint effusion, and quadriceps activation early in the rehabilitation process. Passive flexion and patellar mobilization, avoiding eccentric quadriceps contraction, should also be performed. Weight bearing as tolerated is recommended immediately following surgery to promote knee extension and hinder quadriceps inhibition.

Author/ year	Reported indications	Graft types	Femoral fixation point	Tibial fixation point	Fixation types	Fixation angle
Helito et al. [39]	High-grade pivot-shift examination, ACL revision without apparent cause for failure	Gracilis	3–4 mm below the halfway point on the Blumensaat's line in the AP direction	5–10 mm below the lateral tibial plateau	Inference screw 1 size greater than tunnel diameter	60–90° of flexion
Smith et al. [41]	Marked laxity on examination under anesthesia	Gracilis	Anterior to lateral femoral epicondyle	Midway between fibular head and the Gerdy's tubercle, 11 mm distal to joint line	5.5-mm suture anchors	30° of flexion
Sonnery-Cottet et al. [47]	Segond fractures, chronic ACL tears, grade III pivot shift, high-level or pivot sports participation, lateral femoral notch sign	Gracilis	Proximal and posterior to lateral epicondyle	Site of Segond fracture, at tibial footprint of ALL	4.75 or 5.5 mm interference screw	Not reported
Ferreira et al. [40]	Asymmetry of lateral plateau with internal rotation, grade II/III pivot shift, ALL tear on MRI, Segond fractures	Gracilis	8 mm posterosuperiorly from lateral epicondyle	9–13 mm distal to lateral joint line	Interference screw 2 mm larger than tunnel	45–60° flexion
Chahla et al. [43]	Grade III pivot shift, multiple ACL reconstructions with residual laxity, clinically significant instability after ACL reconstruction	Semitendinosus	4.7 mm proximal and posterior to FCL insertion site	Midway between the Gerdy's tubercle and anterior margin fibular head (9.5 mm distal to joint line)	7 × 28-mm interference screw	30° flexion
Wagih and Elguindy [42]	Grade III pivot-shift examination	Polyester tape	Anterior and distal to lateral femoral condyle	Midpoint between the Gerdy's tubercle and the fibular head	Cortical suspension button	30° flexion
Saithna et al. [45]	Young age (<20 years old). Participation in pivoting sports or a high-demand athlete, high-grade pivot shift on examination, lateral femoral notch sign on preoperative imaging, Segond fracture. Revision ACL reconstruction. Chronic (>12 months) ACL injury	Gracilis	Just proximal and posterior to the lateral epicondyle	One point just anterior to the fibular head and second posterior to Gerdy's tubercle	Tibial tunnel no fixation femoral side ACL graft ethibond	Full extension

Author/ year	Reported indications	Graft types	Femoral fixation point	Tibial fixation point	Fixation types	Fixation angle
Delaloye et al. [48]	ACL repair	Gracilis	Posterior and proximal to the lateral epicondyle	One point just anterior to the fibular head and second posterior to Gerdy's tubercle	SwiveLock anchor	Full extension

Table 1.
Indications, femoral and tibial fixation points, and fixation materials and angles reported in the literature.

9. Clinical outcomes

To date, only few studies reported the clinical outcomes of ALL reconstruction since the rediscovery of this ligament [32, 33, 36, 50]. In a retrospective case series, Sonnery-Cottet et al. [36] evaluated 92 patients at a minimum 2-year follow-up after concomitant ACL and ALL reconstruction. Compared with the preoperative assessment, the follow-up showed significant improvements in Lysholm score, subjective IKDC score, and objective IKDC score. Pivot-shift results were also significantly improved; however, this study did not have a control group.

In a prospective comparative study of 502 patients, Sonnery et al. found lower graft rupture rate with combined ALL-ACL reconstruction technique in a high-risk population, compared to the isolated ACL reconstructions that used a bone-patellar tendon-bone graft or a quadrupled hamstring tendon graft [33]. Another randomized study showed an improvement in knee laxity measured using a KT-1000 arthrometer in patients with combined ACL and ALL reconstructions compared to patients with isolated ACL reconstructions; however, the other measured parameters did not differ significantly [32]. Recently, Helito et al. [50] evaluated the results of combined ACL-ALL reconstruction with isolated ACL reconstruction in 101 chronic ACL injuries. Regarding functional outcome scores, they found better results on both the IKDC and the Lysholm evaluations in combined ACL-ALL reconstruction group. In addition, patients in the ACL-ALL reconstruction group had better KT-1000 evaluation and a lower pivot-shift rate at physical examination. Although the results of the recent studies are promising, indications for ALL reconstruction are not identical in these studies and additional studies are needed to confirm these results.

10. Conclusions

In conclusion, it is commonly accepted that the ALL is a distinctive structure that originates from proximal and posterior to the femoral epicondyle, attaches slightly posterior to the Gerdy's tubercle, and functions as a secondary stabilizer to internal rotation. In addition, it has been reported that it has a crucial role in preventing pivot-shift phenomenon. However, there is a lack of evidence supporting that it can be a reason for persistent pivot shift after ACL reconstructions [13]. Although the results of the recent studies reporting the outcomes of ALL reconstruction are promising, the total volume of literature on this topic is limited and composed of low-quality evidence. More studies with longer follow-up times are, therefore, needed to provide the convincing clinical evidence for the favor of concomitant ACL and ALL procedures. In addition, despite the lack of clear evidence for an increase in lateral compartment osteoarthritis after concomitant procedures, compression in the lateral compartment seems to be a concern and was regarded as a reason to abandon concomitant lateral procedures historically [51–53].

Acknowledgements

There is no support funding for the publication.

Conflict of interest

The author declares that no conflict of interest exists.

IntechOpen

IntechOpen

Author details

Tahsin Gurpinar
University of Health Sciences, Istanbul Research and Education Hospital, Istanbul,
Turkey

*Address all correspondence to: tahsingurpinar@msn.com

IntechOpen

© 2019 The Author(s). Licensee IntechOpen. This chapter is distributed under the terms of the Creative Commons Attribution License (<http://creativecommons.org/licenses/by/3.0>), which permits unrestricted use, distribution, and reproduction in any medium, provided the original work is properly cited. 

References

- [1] Claes S, Vereecke E, Maes M, Victor J, Verdonk P, Bellemans J. Anatomy of the anterolateral ligament of the knee. *Journal of Anatomy*. 2013;**223**(4):321-328
- [2] Claes S, Bartholomeeusen S, Bellemans J. High prevalence of anterolateral ligament abnormalities in magnetic resonance images of anterior cruciate ligament-injured knees. *Acta Orthopaedica Belgica*. 2014;**80**(1):45-49
- [3] Parsons EM, Gee AO, Spiekerman C, Cavanagh PR. The biomechanical function of the anterolateral ligament of the knee. *The American Journal of Sports Medicine*. 2015;**43**(3):669-674
- [4] Guenther D, Rahnama-Azar AA, Fu FH, Debski RE. The biomechanical function of the anterolateral ligament of the knee: Letter to the editor. *The American Journal of Sports Medicine*. 2015;**43**(8):NP21-NP22
- [5] Daggett M, Ockuly AC, Cullen M, Busch K, Lutz C, Imbert P, et al. Femoral origin of the anterolateral ligament: An anatomic analysis. *Arthroscopy*. 2016;**32**(5):835-841
- [6] Catherine S, Litchfield R, Johnson M, Chronik B, Getgood A. A cadaveric study of the anterolateral ligament: Re-introducing the lateral capsular ligament. *Knee Surgery, Sports Traumatology, Arthroscopy*. 2015;**23**(11):3186-3195
- [7] Dodds AL, Halewood C, Gupte CM, Williams A, Amis AA. The anterolateral ligament: Anatomy, length changes and association with the Segond fracture. *The Bone & Joint Journal*. 2014;**96-B**(3):325-331
- [8] Vincent JP, Magnussen RA, Gezmez F, Uguen A, Jacobi M, Weppe F, et al. The anterolateral ligament of the human knee: An anatomic and histologic study. *Knee Surgery, Sports Traumatology, Arthroscopy*. 2012;**20**(1):147-152
- [9] Daggett M, Busch K, Sonnery-Cottet B. Surgical dissection of the anterolateral ligament. *Arthroscopy Techniques*. 2016;**5**(1):e185-e188
- [10] Zens M, Feucht MJ, Ruhhammer J, Bernstein A, Mayr HO, Südkamp NP, et al. Mechanical tensile properties of the anterolateral ligament. *Journal of Experimental Orthopaedics*. 2015;**2**(1):7
- [11] Kennedy MI, Claes S, Fuso FA, Williams BT, Goldsmith MT, Turnbull TL, et al. The anterolateral ligament: An anatomic, radiographic, and biomechanical analysis. *The American Journal of Sports Medicine*. 2015;**43**(7):1606-1615
- [12] Ruiz N, Filippi GJ, Gagnière B, Bowen M, Robert HE. The comparative role of the anterior cruciate ligament and anterolateral structures in controlling passive internal rotation of the knee: A biomechanical study. *Arthroscopy*. 2016;**32**(6):1053-1062
- [13] Gürpınar T, Polat B, Polat AE, Mutlu İ, Tüzüner T. Is anterolateral ligament rupture a reason for persistent rotational instability after anterior cruciate ligament reconstruction? *The Knee*. 2018;**25**(6):1033-1039
- [14] Imbert P, Lutz C, Daggett M, Niglis L, Freychet B, Dalmay F, et al. Isometric characteristics of the anterolateral ligament of the knee: A cadaveric navigation study. *Arthroscopy*. 2016;**32**(10):2017-2024
- [15] Ferretti A, Monaco E, Fabbri M, Maestri B, De Carli A. Prevalence and classification of injuries of anterolateral complex in acute anterior cruciate ligament tears. *Arthroscopy*. 2017;**33**(1):147-154

- [16] Van Dyck P, Clockaerts S, Vanhoenacker FM, Lambrecht V, Wouters K, De Smet E, et al. Anterolateral ligament abnormalities in patients with acute anterior cruciate ligament rupture are associated with lateral meniscal and osseous injuries. *European Radiology*. 2016;**26**(10):3383-3391
- [17] Claes S, Luyckx T, Vereecke E, Bellemans J. The Segond fracture: A bony injury of the anterolateral ligament of the knee. *Arthroscopy*. 2014;**30**(11):1475-1482
- [18] Porrino J, Maloney E, Richardson M, Mulcahy H, Ha A, Chew FS. The anterolateral ligament of the knee: MRI appearance, association with the Segond fracture, and historical perspective. *AJR. American Journal of Roentgenology*. 2015;**204**(2):367-373
- [19] Shaikh H, Herbst E, Rahnemai-Azar AA, Bottene Villa Albers M, Naendrup JH, Musahl V, et al. The Segond fracture is an avulsion of the anterolateral complex. *The American Journal of Sports Medicine*. 2017;**45**(10):2247-2252
- [20] Gottsegen CJ, Eyer BA, White EA, Learch TJ, Forrester D. Avulsion fractures of the knee: Imaging findings and clinical significance. *Radiographics*. 2008;**28**(6):1755-1770
- [21] DeLee JC, Riley MB, Rockwood CA. Acute posterolateral rotatory instability of the knee. *The American Journal of Sports Medicine*. 1983;**11**(4):199-207
- [22] Helito CP, Bonadio MB, Rozas JS, Wey JM, Pereira CA, Cardoso TP, et al. Biomechanical study of strength and stiffness of the knee anterolateral ligament. *BMC Musculoskeletal Disorders*. 2016;**17**:193
- [23] Zens M, Niemeyer P, Ruhhammer J, Bernstein A, Woias P, Mayr HO, et al. Length changes of the anterolateral ligament during passive knee motion: A human cadaveric study. *The American Journal of Sports Medicine*. 2015;**43**(10):2545-2552
- [24] Rasmussen MT, Nitri M, Williams BT, Moulton SG, Cruz RS, Dornan GJ, et al. An in vitro robotic assessment of the anterolateral ligament, part 1: Secondary role of the anterolateral ligament in the setting of an anterior cruciate ligament injury. *The American Journal of Sports Medicine*. 2016;**44**(3):585-592
- [25] Schon JM, Moatshe G, Brady AW, Serra Cruz R, Chahla J, Dornan GJ, et al. Anatomic anterolateral ligament reconstruction of the knee leads to overconstraint at any fixation angle. *The American Journal of Sports Medicine*. 2016;**44**(10):2546-2556
- [26] Wharton R, Henckel J, Bhattee G, Ball S, Church S. Segond fracture in an adult is not pathognomonic for ACL injury. *Knee Surgery, Sports Traumatology, Arthroscopy*. 2015;**23**(7):1925-1928
- [27] Monaco E, Ferretti A, Labianca L, Maestri B, Speranza A, Kelly MJ, et al. Navigated knee kinematics after cutting of the ACL and its secondary restraint. *Knee Surgery, Sports Traumatology, Arthroscopy*. 2012;**20**(5):870-877
- [28] Song GY, Zhang H, Liu X, Zhang J, Xue Z, Qian Y, et al. Complete posterolateral meniscal root tear is associated with high-grade pivot-shift phenomenon in noncontact anterior cruciate ligament injuries. *Knee Surgery, Sports Traumatology, Arthroscopy*. 2017;**25**(4):1030-1037
- [29] Tanaka M, Vyas D, Moloney G, Bedi A, Pearle AD, Musahl V. What does it take to have a high-grade pivot shift? *Knee Surgery, Sports Traumatology, Arthroscopy*. 2012;**20**(4):737-742
- [30] Chouliaras V, Ristanis S, Moraiti C, Tzimas V, Stergiou N, Georgoulis AD.

Anterior cruciate ligament reconstruction with a quadrupled hamstrings tendon autograft does not restore tibial rotation to normative levels during landing from a jump and subsequent pivoting. *The Journal of Sports Medicine and Physical Fitness*. 2009;**49**(1):64-70

[31] Stergiou N, Ristanis S, Moraiti C, Georgoulis AD. Tibial rotation in anterior cruciate ligament (ACL)-deficient and ACL-reconstructed knees: A theoretical proposition for the development of osteoarthritis. *Sports Medicine*. 2007;**37**(7):601-613

[32] Ibrahim SA, Shohdy EM, Marwan Y, Ramadan SA, Almisfer AK, Mohammad MW, et al. Anatomic reconstruction of the anterior cruciate ligament of the knee with or without reconstruction of the anterolateral ligament: A randomized clinical trial. *The American Journal of Sports Medicine*. 2017;**45**(7):1558-1566

[33] Sonnery-Cottet B, Saithna A, Cavalier M, Kajetanek C, Temponi EF, Daggett M, et al. Anterolateral ligament reconstruction is associated with significantly reduced ACL graft rupture rates at a minimum follow-up of 2 years: A prospective comparative study of 502 patients from the SANTI study group. *The American Journal of Sports Medicine*. 2017;**45**(7):1547-1557

[34] Zhang H, Qiu M, Zhou A, Zhang J, Jiang D. Anatomic anterolateral ligament reconstruction improves postoperative clinical outcomes combined with anatomic anterior cruciate ligament reconstruction. *Journal of Sports Science and Medicine*. 2016;**15**(4):688-696

[35] Hardy A, Casabianca L, Hardy E, Grimaud O, Meyer A. Combined reconstruction of the anterior cruciate ligament associated with anterolateral tenodesis effectively controls the acceleration of the tibia

during the pivot shift. *Knee Surgery, Sports Traumatology, Arthroscopy*. 2017;**25**(4):1117-1124

[36] Sonnery-Cottet B, Thaunat M, Freychet B, Pupim BH, Murphy CG, Claes S. Outcome of a combined anterior cruciate ligament and anterolateral ligament reconstruction technique with a minimum 2-year follow-up. *The American Journal of Sports Medicine*. 2015;**43**(7):1598-1605

[37] Sonnery-Cottet B, Daggett M, Fayard JM, Ferretti A, Helito CP, Lind M, et al. Anterolateral ligament expert group consensus paper on the management of internal rotation and instability of the anterior cruciate ligament—Deficient knee. *Journal of Orthopaedics and Traumatology*. 2017;**18**(2):91-106

[38] Wytrykowski K, Swider P, Reina N, Murgier J, Laffosse JM, Chiron P, et al. Cadaveric study comparing the biomechanical properties of grafts used for knee anterolateral ligament reconstruction. *Arthroscopy*. 2016;**32**(11):2288-2294

[39] Helito CP, Bonadio MB, Gobbi RG, da Mota E Albuquerque RF, Pécora JR, Camanho GL, et al. Combined intra- and extra-articular reconstruction of the anterior cruciate ligament: The reconstruction of the knee anterolateral ligament. *Arthroscopy Techniques*. 2015;**4**(3):e239-e244

[40] Ferreira MC, Zidan FF, Miduati FB, Fortuna CC, Mizutani BM, Abdalla RJ. Reconstruction of anterior cruciate ligament and anterolateral ligament using interlinked hamstrings—Technical note. *Revista Brasileira de Ortopedia*. 2016;**51**(4):466-470

[41] Smith JO, Yasen SK, Lord B, Wilson AJ. Combined anterolateral ligament and anatomic anterior cruciate ligament reconstruction of the knee.

Knee Surgery, Sports Traumatology, Arthroscopy. 2015;**23**(11):3151-3156

[42] Wagih AM, Elguindy AM. Percutaneous reconstruction of the anterolateral ligament of the knee with a polyester tape. *Arthroscopy Techniques*. 2016;**5**(4):e691-e6e7

[43] Chahla J, Menge TJ, Mitchell JJ, Dean CS, LaPrade RF. Anterolateral ligament reconstruction technique: An anatomic-based approach. *Arthroscopy Techniques*. 2016;**5**(3):e453-e457

[44] Helito CP, Demange MK, Bonadio MB, Tirico LE, Gobbi RG, Pecora JR, et al. Radiographic landmarks for locating the femoral origin and tibial insertion of the knee anterolateral ligament. *The American Journal of Sports Medicine*. 2014;**42**(10):2356-2362

[45] Saithna A, Thaunat M, Delaloye JR, Ouanezar H, Fayard JM, Sonnery-Cottet B. Combined ACL and anterolateral ligament reconstruction. *JBJS Essential Surgical Techniques*. 2018;**8**(1):e2

[46] Lutz C, Sonnery-Cottet B, Imbert P, Barbosa NC, Tuteja S, Jaeger JH. Combined anterior and anterolateral stabilization of the knee with the iliotibial band. *Arthroscopy Techniques*. 2016;**5**(2):e251-e256

[47] Sonnery-Cottet B, Barbosa NC, Tuteja S, Daggett M, Kajetanek C, Thaunat M. Minimally invasive anterolateral ligament reconstruction in the setting of anterior cruciate ligament injury. *Arthroscopy Techniques*. 2016;**5**(1):e211-e215

[48] Delaloye JR, Murar J, Vieira TD, Saithna A, Barth J, Ouanezar H, et al. Combined anterior cruciate ligament repair and anterolateral ligament reconstruction. *Arthroscopy Techniques*. 2019;**8**(1):e23-ee9

[49] Ferretti A, Monaco E, Ponzo A, Basigliani L, Iorio R, Caperna L,

et al. Combined intra-articular and extra-articular reconstruction in anterior cruciate ligament-deficient knee: 25 years later. *Arthroscopy*. 2016;**32**(10):2039-2047

[50] Helito CP, Camargo DB, Sobrado MF, Bonadio MB, Giglio PN, Pécora JR, et al. Combined reconstruction of the anterolateral ligament in chronic ACL injuries leads to better clinical outcomes than isolated ACL reconstruction. *Knee Surgery, Sports Traumatology, Arthroscopy*. 2018;**26**(12):3652-3659

[51] Ferretti A. Extra-articular reconstruction in the anterior cruciate ligament deficient knee: A commentary. *Joints*. 2014;**2**(1):41-47

[52] Ramaniraka NA, Saunier P, Siegrist O, Pioletti DP. Biomechanical evaluation of intra-articular and extra-articular procedures in anterior cruciate ligament reconstruction: A finite element analysis. *Clinical Biomechanics (Bristol, Avon)*. 2007;**22**(3):336-343

[53] Rezende FC, de Moraes VY, Martimbianco AL, Luzo MV, da Silveira Franciozi CE, Belloti JC. Does combined intra- and extraarticular ACL reconstruction improve function and stability? A meta-analysis. *Clinical Orthopaedics and Related Research*. 2015;**473**(8):2609-2618