

We are IntechOpen, the world's leading publisher of Open Access books Built by scientists, for scientists

6,900

Open access books available

186,000

International authors and editors

200M

Downloads

Our authors are among the

154

Countries delivered to

TOP 1%

most cited scientists

12.2%

Contributors from top 500 universities



WEB OF SCIENCE™

Selection of our books indexed in the Book Citation Index
in Web of Science™ Core Collection (BKCI)

Interested in publishing with us?
Contact book.department@intechopen.com

Numbers displayed above are based on latest data collected.
For more information visit www.intechopen.com



External and Internal Root Canal Anatomy of the First and Second Permanent Maxillary Molars

*Said Dhaimy, Lamyae Bedida, Hafsa El Merini
and Imane Benkiran*

Abstract

A successful endodontic treatment depends on a comprehensive knowledge of the morphology of canal and its variations, an appropriate access cavity, cleaning and shaping, and adequate root canal filling. Lack of knowledge in this regard and missing a root canal are among the most common causes of failure of root canal treatments. Most previous studies on maxillary molars have reported that they usually have three roots and four canals since an extra canal is often found in the mesiobuccal root. Other anatomical variations, such as an extra C-shaped canal, have also been reported in distobuccal and palatal roots. Thus, because of having a more complex anatomy compared to other teeth, maxillary molars have the highest rate of endodontic failure. Several studies have assessed the morphology of root canal anatomy in different populations using different techniques such as sectioning, root canal clearing, association of a dental operating microscope and ultrasonic tips, periapical radiography, and computed tomography scanning. Recently, CBCT was suggested to three-dimensionally explore the root canal details before an endodontic treatment. The purpose of this chapter was to highlight the importance of having a thorough knowledge about the root canal morphology of the permanent first and second maxillary molar.

Keywords: permanent maxillary first molars, permanent maxillary second molars, root canal complex, internal morphology, anatomic variation

1. Introduction

The root canal configuration is complex and has many variations depending on the group of teeth. Understanding and mastering this internal anatomy is essential for the planning and executing endodontic therapies [1].

In order to explore root canal anatomy for better understanding, several benchmarks were chosen in combination with appropriate information from the literature, encompassing: general description of teeth, overall length and root's length, chronology of root formation [2–8], the degree of canals curvature [9–11], the number of roots [12], root's curvature and fusion [13], number and

configuration of canals [12], diameter of the canal at 1, 2, and 5 mm from the apex [1, 14], apical foramen position, accessory canals, and lateral and apical ramifications [12].

The divergence of results reported in several studies may be due to the type of the study (clinical/laboratory study); however, different methods have been used in these studies.

Studies done in the laboratory to describe the internal anatomy include various types of methods:

- Decalcification with injection of India's ink [12, 15, 16]
- Injection of sodium fluorescein and microscopy [17]
- In vitro radio-opaque gel infusion and radiography [18]
- In vitro endodontic with radiography and instruments [19] or only with instruments [20]
- In vitro macroscopic examination [13]
- Cone beam computed tomography (CBCT) [21–25, 26]
- Micro-computed tomography [10, 26–29]
- Sectioning and microscopy [11, 14, 18]

While clinical methods include:

- Clinical evaluation during endodontic treatment using enlargement or operating microscope [30]
- In vivo treatment of the root canal and radiography [31]

2. The method of internal anatomy analysis

2.1 Conventional radiography

The retro-alveolar image shows the totality of each X-rayed tooth up to the apex, and provides information on canal anatomy as well as on the integrity of the periodontium [32].

Some studies combined the radiographic technique and radio-opaque sodium iothalamate gel infused in the root canal system [18]. In another use of radiography, Kulild and Peters [19] assessed the internal anatomy of 83 maxillary molars by taking radiography of instruments into the canals (**Figure 1(a)**).

In a retrospective study of 520 completed endodontic treatments of maxillary second molar, radiographs reviewed were useful to detect the anatomical root and canal variations [31].

Unfortunately, the maxillary molar area is often a difficult area to obtain a good radiographic quality because of the superimposition of the maxillary process of the zygomatic bone [34].

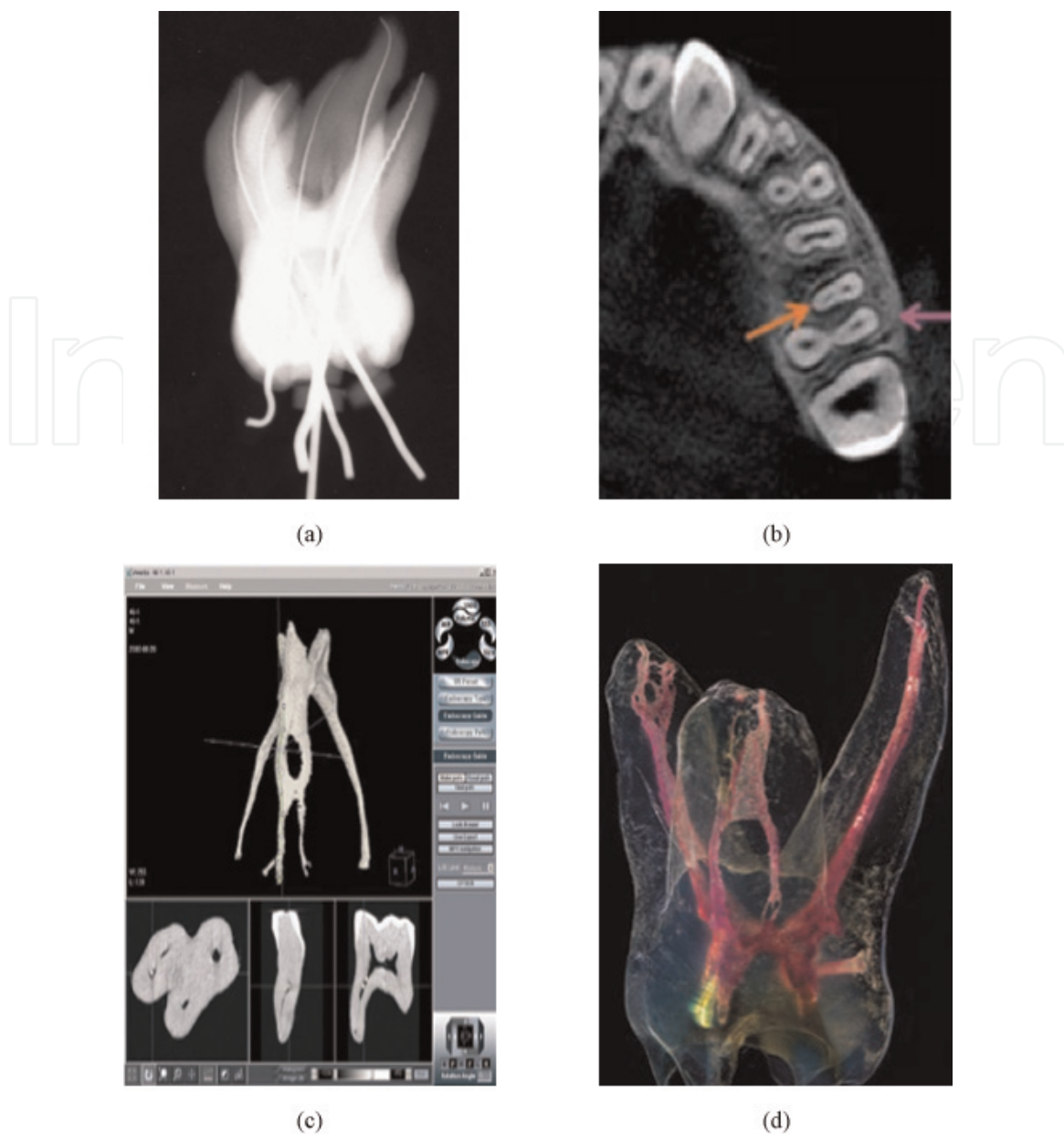

Figure 1.

Methods of study of internal anatomy. (a) Conventional radiography with instruments showing a maxillary first molar with five roots [33]. (b) Cross section, from a CBCT imaging, representing the second mesiobuccal canal of a maxillary first molar [26]. (c) The 3D root canal system of each maxillary first molar was reconstructed with Micro-CT and mathematical modeling [10]. (d) Diaphanization technique showing the complexity of the internal morphology of a maxillary molar [15].

2.2 Cone beam computed tomography (CBCT)

Several studies compared the use of cone beam computed tomography (CBCT) imaging to study root and canal anatomy with some laboratory methods such as histological sectioning and clearing technique and, more recently with the gold standard nondestructive high-resolution micro-computed tomography (Micro-CT) [26].

In order to identify the root canal system, CBCT was used next to charged coupled device (CCD) and photostimulable phosphor (PSP) [22]. For CCD and PSP, the endodontist evaluators correctly identified the number of root canal systems 78 and 80% of the time, respectively, when compared with CBCT 100%.

Numerous *in vivo* studies used CBCT to highlight the second mesiobuccal canal, with prevalence of 42.63 [21] and 70.5% [25] for the first maxillary molar, and between 34.32 [21] and 41.6% [25] for the second maxillary molar (**Figure 1(b)**).

2.3 Micro-computed tomography (Micro-CT)

X-ray micro-computed tomography has also been denominated as micro-computed tomography, microcomputer tomography, high-resolution X-ray tomography, X-ray microtomography, Micro-CT, and similar terminologies. Nowadays, despite the impossibility of employing micro-CT for in vivo human imaging, it has been considered the most important and accurate research tool for the study of fine details of root canal anatomy [26].

In Markvart et al.'s [28] article, he investigated the Micro-CT and segmentation precision of the surface models of molars for the detection of small volumes, such as the reduced pulp cavity, formation of mineral deposits, detection of narrow root canals, and to improve the clinical and morphological understanding of the number of root canals and their configuration. Other study was done by Peters et al. [29] on 12 maxillary molars; Micro-CT was used to detailing root canal geometry.

Bjørndal et al. [35] correlated the shape of the root canals to the corresponding root surface of five maxillary molars. While in 2006, Lee et al. [10] measured the three-dimensional (3D) canal curvature in maxillary first molars using Micro-CT and mathematical modeling (**Figure 1(c)**).

2.4 Diaphanization

Diaphanization is a histological term that refers to the whole body, organ, or structure transparency [15].

Dental diaphanization has been frequently used to observe several anatomical features of the root canal system, including the presence and the type of root canal, number of roots, fusion, lateral canals, transverse anastomoses, position of apical foramen, and apical deltas [12], additional canals such as MB2 in mesiobuccal roots of maxillary molars [16] (**Figure 1(d)**).

To prove the effectiveness of diaphanization technique in the identification of root canal morphology, many authors compared between diaphanization and other techniques. Baratto Filho et al. [36] showed that the incidence of 4 roots in 140 maxillary first molars was high in vivo assessment (67.14%).

3. Permanent maxillary first molar

3.1 The anatomical particularities of the maxillary first molar

3.1.1 General

The maxillary first molars are the first permanent molars to erupt and sometimes referred to as 6-year molar; they erupt distal to the deciduous dentition and they are considered succedaneous, as they do not replace any deciduous teeth; they contact the maxillary second premolar on the mesial and the maxillary second molar on the distal, the maxillary first molars occlude with the mandibular first and second molars; and they are considered the cornerstones in the development of occlusion because of their eruption pattern and location in the arch [37].

Numbering system	Right	Left
Universal	3	14
Palmer	6	6
International	16	26

3.1.2 Development

- Initial calcification: at birth
- Enamel completed: 3–4 years
- Eruption is between: 6–7 years
- Root completed: 9–10 years

3.1.3 Dimensions

See **Table 1**.

3.1.3.1 Crown dimensions

The mesiodistal crown dimension is greater than the cervico-occlusal crown dimension [2, 5, 6]; the average difference is as great as 3.3 mm and as small as 2.5 mm [2, 5] (**Figure 2(a)**).

The buccolingual crown dimension is greater than the cervico-occlusal crown dimension [2, 5, 6], the average difference is as great as 4.1 mm and as small as 3 mm [6] (**Figure 2(b)**).

Overall length	22.0 mm
Crown length	8 mm
Crown width	10.8 mm
Crown buccolingual	11.6 mm
Root length	12.7 mm (DB)
	12.9 mm (MB)
	14.0 mm (P)

Table 1.
Average dimensions (mm) of the maxillary first molar [37].

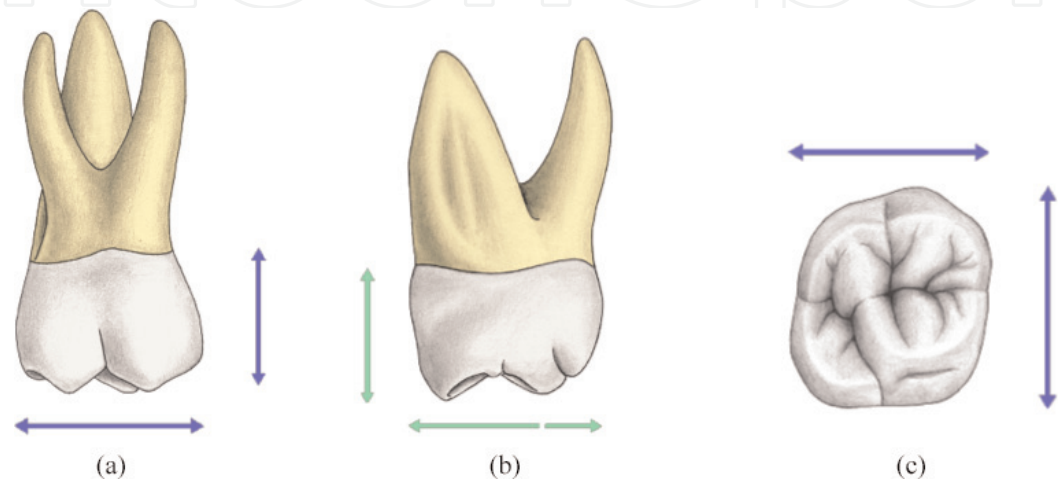


Figure 2.
The crown dimensions (reprinted from 3D tooth atlas version 9) [37]. (a) Crown buccal dimension, (b) crown mesial dimension, and (c) crown occlusal dimension.

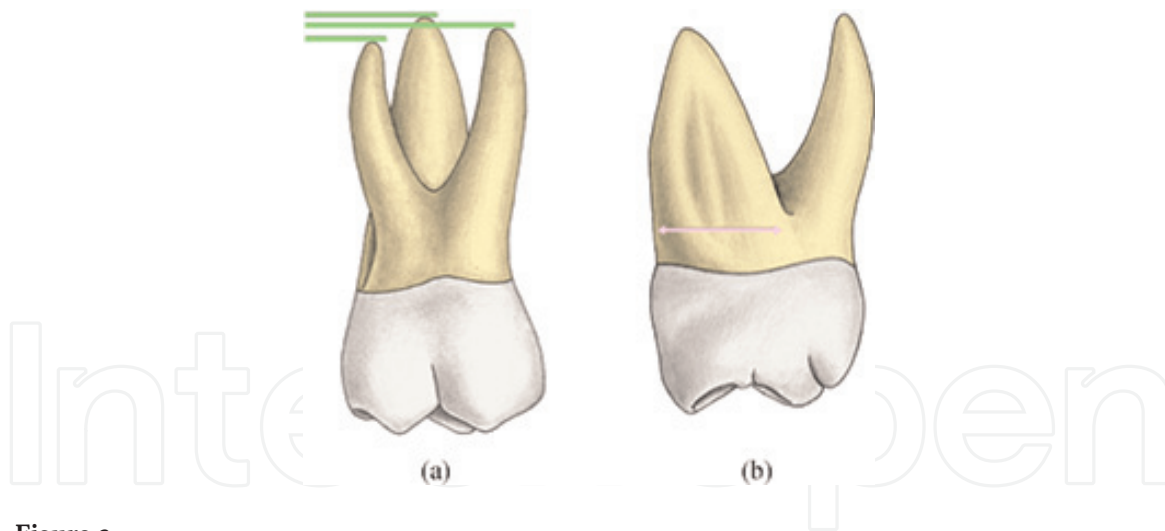


Figure 3. Roots dimensions (reprinted from 3D tooth atlas version 9) [37]. (a) Root length and (b) mesial root dimension.

The buccolingual crown dimension is greater than the mesiodistal dimension [2, 5, 6]. Diamond [6] indicates that the two dimensions are the same. The inequity of the two measurements appears slight from an occlusal view [2] (**Figure 2(c)**).

3.1.3.2 Roots dimensions

The three roots are nearly the same length (within 1.5 mm), but the palatal root is the largest [3]: the mesiobuccal root is slightly longer than the distobuccal root [3]; the two buccal roots are approximately the same length [2]; and the distobuccal root is the shortest root [3] (**Figure 3(a)**).

The buccolingual dimension of the mesiobuccal root at its base equals two-third of the buccolingual dimension of the root trunk [3] (**Figure 3(b)**).

3.2 External root canal anatomy of maxillary first molars

3.2.1 Number of roots

The maxillary first molar root anatomy is predominantly a three-rooted form, as shown in these anatomic studies [12, 13, 18] of this tooth (**Figure 4(a)**).

The single root or conical form of root anatomy in the first maxillary molar is very rarely reported [12, 13] (**Figure 4b**).

The two-rooted form is rarely reported, and may be due to fusion of the distobuccal root to palatal root (5%) [13], fusion of the mesiobuccal root and the palatal root (0%) [13], or fusion of the distobuccal root to the mesiobuccal root (6%) [12] (**Figure 4(c)**).

Over 95% of maxillary first molars had three roots and 3.8% had two roots in four studies that included 416 teeth, according to a literature review [40].

The four-rooted anatomy in its various forms is also very rare in the maxillary first molar and is more likely to occur in the second or third maxillary molars (**Figure 4(d)**).

Review data from two studies that included 2480 teeth show that the maxillary first molars had an incidence of C-shaped canals of 0.12% indicating that this type of anomaly is a rare occurrence in the maxillary first molar [40].

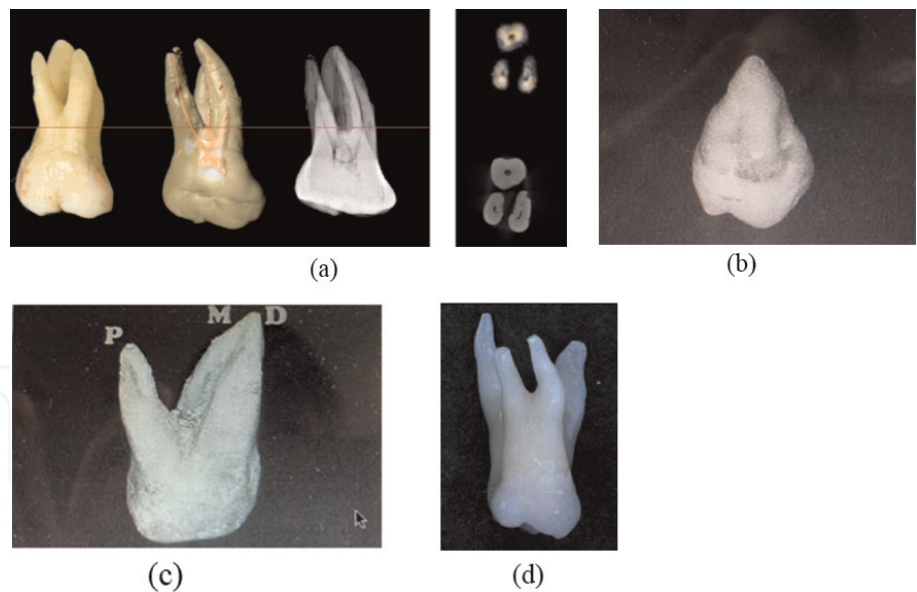


Figure 4.
Variation of root number in maxillary first molar. (a) Buccal view of maxillary right first molar (reprinted from 3D tooth atlas version 9) [37]. (b) First maxillary molar with single root [38]. (c) Fusion of mesiobuccal and distobuccal roots [38]. (d) Maxillary right molar with bifurcated with double palatal root [39].

3.2.2 Shape of roots

3.2.2.1 Buccal aspect

The roots are described as all being roughly ovoid in cross-sectional form at the mid-root area [4] (**Figure 5(a)**).

The buccal furcation is often near the junction of the cervical and middle thirds of the root [3]; the buccal bifurcation is located about 4 mm apical to the cervical line [2] (**Figure 5(b)**).

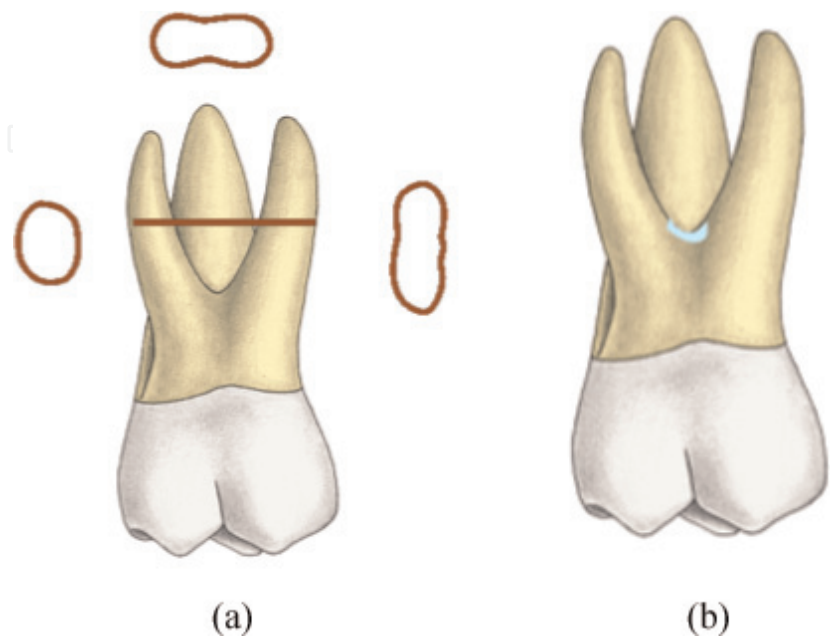


Figure 5.
Buccal aspect of maxillary first molar roots (reprinted from 3D tooth atlas version 9) [37]. (a) Cross-sectional root form and (b) buccal bifurcation.

3.2.2.2 Mesial aspect

The mesial bifurcation is located closer to the cervical line than the buccal bifurcation [2]. There is a smooth concavity extending occlusally and lingually from the furcation almost to the cervical line [2] (**Figure 6(a)**).

The lingual root is the largest; it diverges boldly to the lingual [7], and it is bent like a banana [2, 3]. **Figure 6(b, c)**.

3.2.2.3 Distal aspect

The distal bifurcation is located 5 mm or more apical to the cervical line, thereby being the most apically located furcation [2] (**Figure 7(a)**).

The buccal surface of the distobuccal root is not located as far buccally as the mesiobuccal root; the distal surface on the distobuccal root has no longitudinal depressions [3].

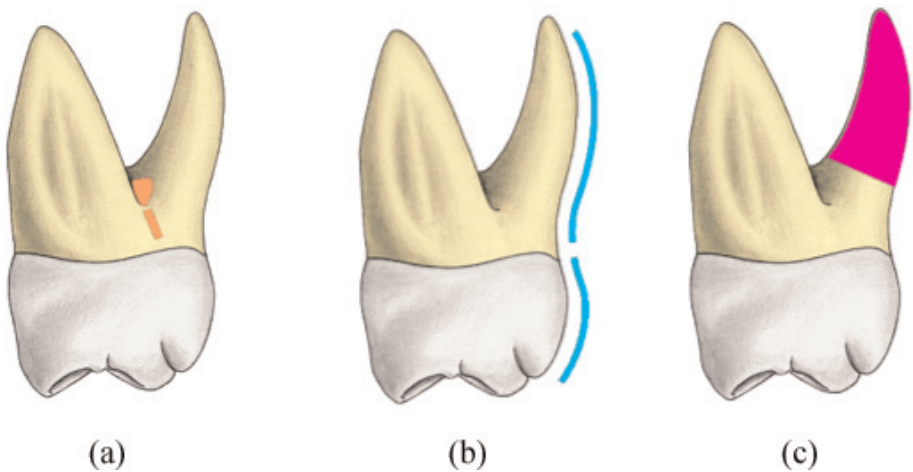


Figure 6. Mesial aspect of maxillary first molar roots (reprinted from 3D tooth atlas version 9) [37]. (a) Mesial furcation, (b) lingual outline form, and (c) palatal root form.

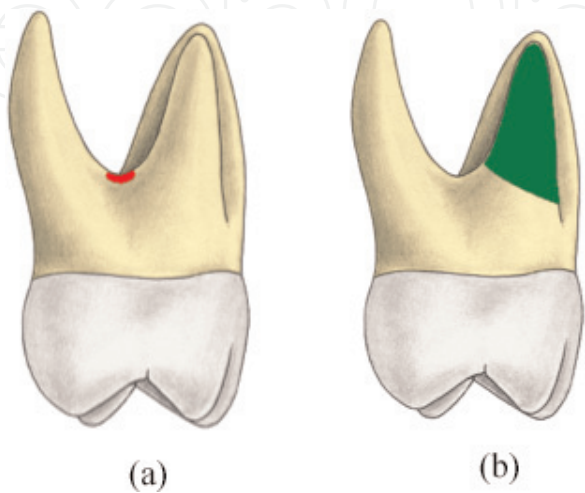


Figure 7. Distal aspect of maxillary first molar roots (reprinted from 3D tooth atlas version 9) [37]. (a) Distal bifurcation and (b) distobuccal root.

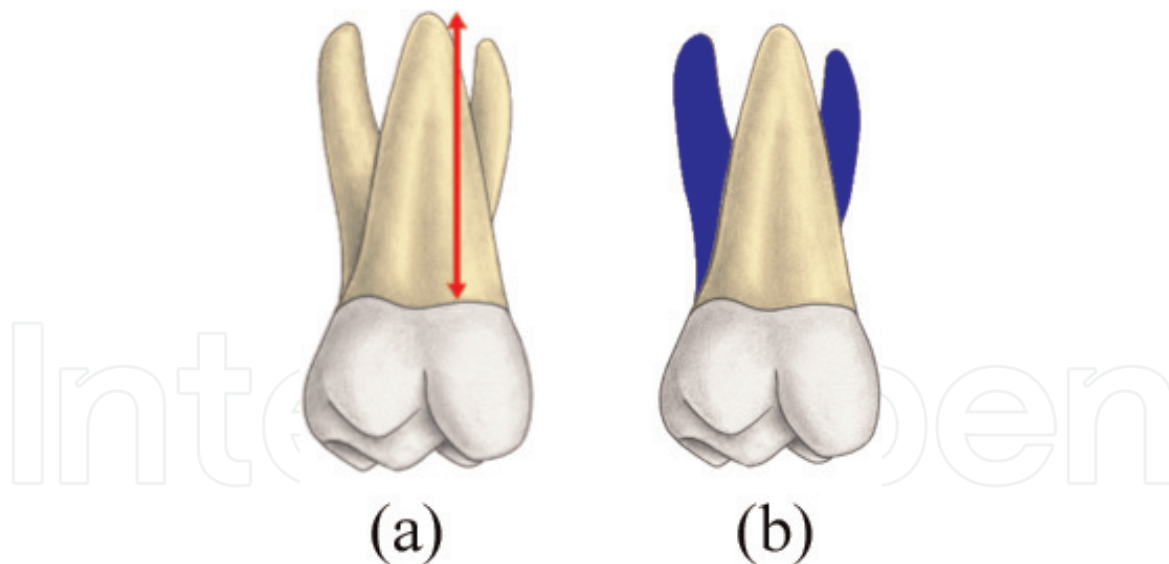


Figure 8.
Palatal aspect of maxillary first molar roots (reprinted from 3D tooth atlas version 9) [37]. (a) Palatal root length and (b) buccal roots visibility.

The distobuccal root is the smallest, shortest, and weakest root and it is a little larger buccolingually than the mesiodistally [4] (**Figure 7(b)**).

3.2.2.4 Lingual aspect

The lingual root of the maxillary first molar has an average length of 13–13.7 mm, depending on the authors [2, 3] (**Figure 8(a)**). It is the third longest root in the maxilla after the canine and the second premolar [3].

The lingual root is the longest, largest, and strongest of the three first molar roots [4].

The lingual root is conical and has a bluntly rounded apex [2]. The buccal roots are visible from a lingual view due to their wide mesiodistal spread [3] (**Figure 8(b)**).

3.3 Internal root canal anatomy of maxillary first molars

3.3.1 Pulp chamber and canal entries

3.3.1.1 Morphology of pulp chamber

The bulk of the pulp chamber is contained within the root trunk, with only the pulp horns extending more coronally. Similar to the outer tooth contour, the pulp chamber is broader buccolingually than mesiodistally. The pulp chamber might undergo calcific metamorphosis, which will reduce its volume considerably [37].

A total of 134 maxillary first molars were studied by Acosta Vigouroux and Trugeda Bosaans [20]; the floor of the pulp chamber was found exactly in the center of the tooth; the most frequent shapes corresponded to trapezoids, rectangles, and inverted trapezoids [20] (**Figure 9**).

The transverse cross-sectional shape of the pulp chamber was trapezoidal in 94 teeth (81.0%); triangular-shaped pulp chambers were found in 13 teeth (11.2%). The shape of the pulp chamber was elliptical in 9 teeth (7.8%) as claimed by Thomas et al. [18].

3.3.1.2 Description and location of canal entries

As stated in Acosta Vigouroux and Trugeda Bosaans' study [20], the largest funnel-shaped entry was that of the lingual canal, which was circular in 45.70% of the cases, and elliptical in 54.30%. The opening to the distobuccal canal was elliptical with a larger buccolingual diameter in 95% of the cases and circular in 5%, the mesiobuccal canal opens at a narrow groove leaning slightly toward the distal aspect and noticeably toward the lingual, which has its origin in the mesiobuccal angle of the floor of the pulp chamber [20].

The average horizontal distance between the MB1 and the MB2 is 1.21 ± 0.5 mm according to Spagnuolo et al. [27], and 1.55 ± 0.56 mm according to Peeters et al. [42] (**Figure 10**).

Spagnuolo et al. [27] also depict a vertical distance between MB1 and MB2 of 1.68 ± 0.83 mm.

The access cavity has a rhomboid shape, due to the presence of four canals with the corners corresponding to the four orifices, as described in "Cohen's Pathways of the Pulp" [41]; the access cavity should not extend into the mesial marginal ridge. From the distal side, the preparation can invade the mesial portion of the oblique ridge; the buccal wall should be parallel to a line connecting the mesiobuccal and distobuccal orifices (**Figure 11**).

In a recent study done by Rover et al. [43] on 30 maxillary first molars, they assess the influence of contracted endodontic cavities (CECs) on root canal detection. The traditional endodontic cavities (TECs) were used as a reference for comparison. The results show that it was possible to locate more root canals in the TEC group in stages 1 and 2 than the CEC group.




Figure 9. The morphology of pulp chamber. (a/b) trapezoid form of the pulp chamber (reprinted from 3D tooth atlas version 9) [37]. (c) pulp chamber shape of maxillary first molar with three canals [41].

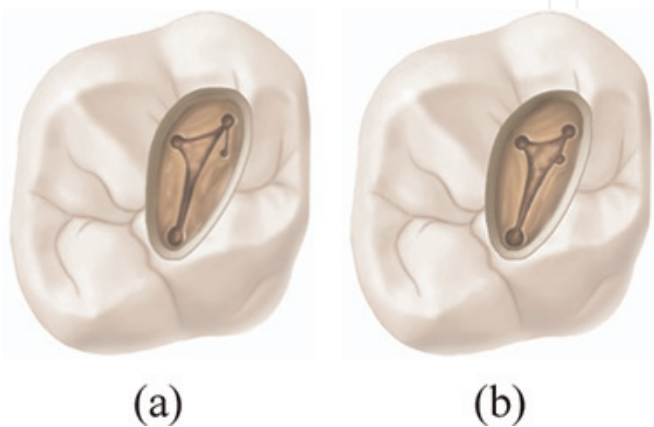


Figure 10. The two locations of the second mesiobuccal (MB-2) canal orifices in a maxillary first molar : (a) first location, (b) second location [41].

3.3.2 Morphology of the canals

3.3.2.1 Mesiobuccal canal

According to a book chapter “Ingle’s Endodontics” [39], a meta-analysis has done by Cleghorn and Goodacre contained the most data of the mesiobuccal canal morphology, a total of 8515 teeth from 37 studies (**Figure 12(a)**).

The incidence of two canals in the mesiobuccal root was 57.1%, and of one canal was 42.9% in a weighted average of all reported studies. The incidence of two canals in the mesiobuccal root was higher in laboratory studies (61.1%) compared to clinical studies (54.7%).

The mesiobuccal canal has a similar volume (2.76 mm³), and considerably larger surface area (up to 24 square mm²) compared to the distobuccal one; canal lengths are similar and can reach up to 24 mm [29] (**Figure 12(b)**).

On 100 maxillary first molar studied by Karaman et al. [11]; the degree of primary curvature in type II, MB (25.63 ± 7.43°) and ML (34.74 ± 8.99°), and in type III, MB (27.33 ± 9.70°) and (ML 36.98 ± 9.41°) in clinical view was not significantly different.

As Vertucci claimed that the median canal diameter at 1, 2, and 5 mm from the apex for **MB1** was 0.19, 0.37, 0.46 mm, respectively, buccally and lingually, and

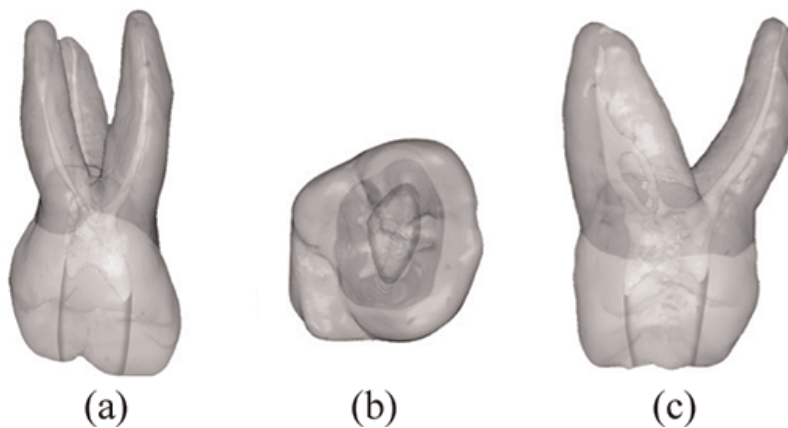


Figure 11.
The shape of the access cavity of maxillary first molars from different views [41]. (a) Buccal view, (b) occlusal view, and (c) mesial view.

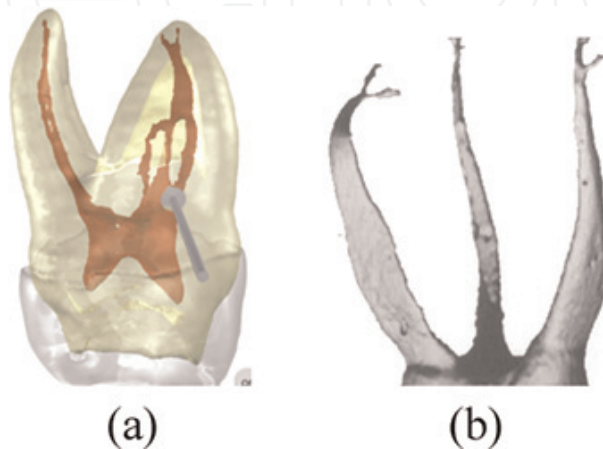


Figure 12.
Three-dimensional configuration of internal anatomy of maxillary first molar. (a) Mesiobuccal canal (reprinted from 3D tooth atlas version 9) [37]. (b) Micro-CT data showing the detailed anatomy of root canal system [29].

0.13, 0.27, 0.32 mm mesially and distally; for **MB2**, the median canal diameter was: 0.19, 0.31, 0.38 mm, respectively, buccally and lingually, 0.16, 0.16, 0.16 mm mesially and distally [1].

3.3.2.2 Distobuccal canal

According to “Ingle’s Endodontics” meta-analysis [39]: 15 studies consisting of 2606 teeth, results show that the distobuccal root had only one canal in 98.3% of teeth studied, two canals were found in 1.7% (**Figure 13**).

It is the smallest of the canals present in terms of volume, length, and surface area with around 2.25 mm^3 , 24 mm, and 18.75 mm^2 , respectively [29].

The distobuccal canal has a clear curvature of $0.29 \pm 0.13 \text{ mm}^{-1}$. However, it is generally less curve that the mesiobuccal root canals [29].

The median canal diameter at 1, 2, and 5 mm from the apex for the distobuccal canal was: 0.22, 0.33, and 0.49 mm, respectively, buccally and lingually, and 0.17, 0.25, 0.31 mm mesially and distally [1].

3.3.2.3 Palatal canal

In a literature review [40] already mentioned included 14 in vivo and in vitro studies based on 2576 maxillary first molars; 99.0% and 98.8% of the palatal roots contained one canal and a single foramen respectively, while the remaining of 1.0% contained 2 canals (**Figure 14**).

Clinical cases reporting the existence of two canals within a palatal root are not uncommon [44], or two distinct palatal roots [45].

The palatal canal is the largest of the root canals present in maxillary molars, with regards to both length and volume; canal length may be up to 25 mm or more, the volume varies $6.96 \pm 1.81 \text{ mm}^3$, and area up to 30.43 mm^2 [29].

The median canal diameter at 1, 2, and 5 mm from the apex for the palatal canal was: 0.29, 0.40, and 0.55 mm, respectively, buccally and lingually, and 0.33, 0.40, 0.74 mm mesially and distally [1].

The palatal canal is unique, wide, and rectilinear except for a slight curvature in order of $0.23\text{--}0.12 \text{ mm}^{-1}$ [29].

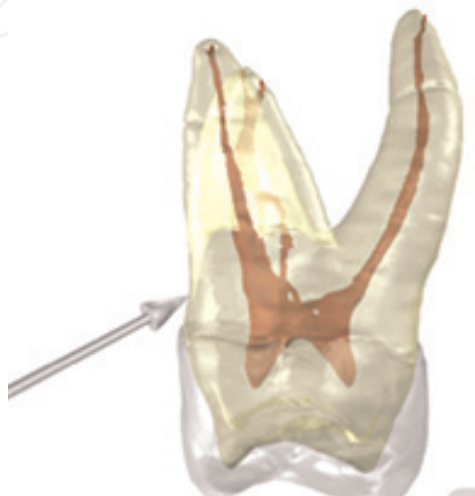

Figure 13.

Distobuccal canal system of maxillary first molar (reprinted from 3D tooth atlas version 9) [37].

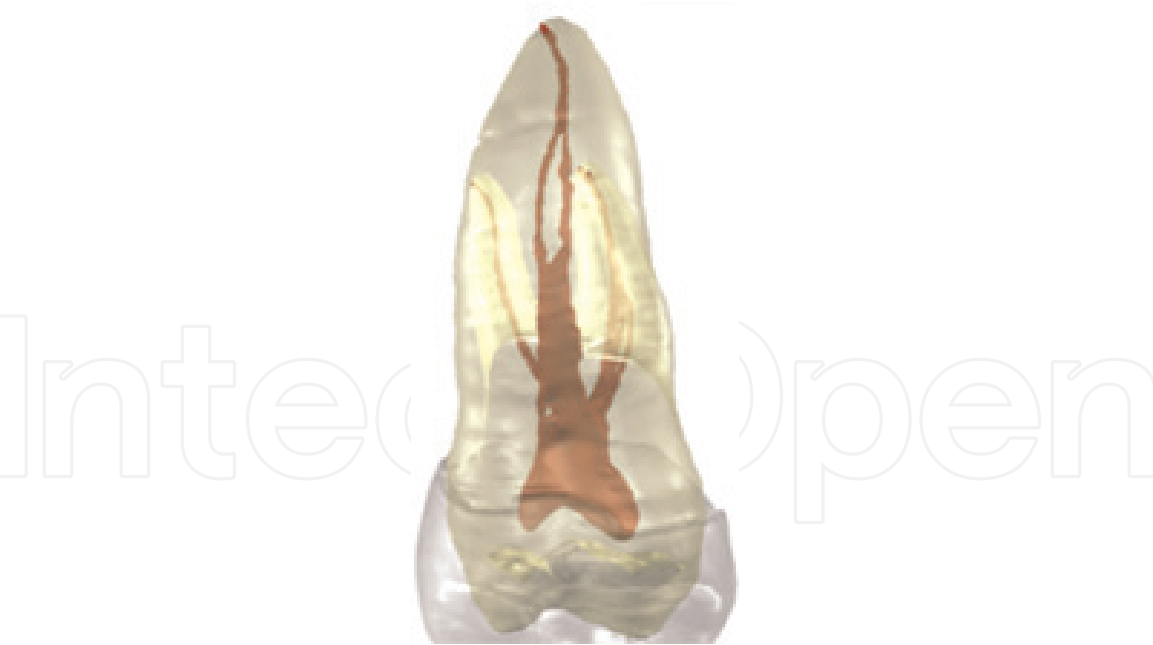

Figure 14.
Palatal canal system of maxillary first molar (reprinted from 3D tooth atlas version 9) [37].

The apical foramen is in the center of the apex in 18.0% of cases, and lateral in 82.0% of cases on the palatal root of the first maxillary molar [1].

4. Permanent maxillary second molar

4.1 The anatomical particularities of the maxillary second molar

4.1.1 General

The maxillary second molars are the seventh teeth from the midline, because they erupt at about age 12, they are occasionally referred to as 12-year molars [37]. They contact the maxillary first molar on the mesial and the maxillary third molar on the distal, and they occlude with the mandibular second and third molar [37].

Numbering system	Right	Left
Universal	2	15
Palmer	7	7
International	17	27

4.1.2 Development

- Initial calcification: 2.5–3 years
- Enamel completed: 7–8 years
- Eruption is between: 12–13 years
- Root completed: 14–16 years

4.1.3 Dimensions

See **Table 2**.

4.1.3.1 Crown dimensions

The mesiodistal crown dimension is greater than the occlusocervical crown dimension [2, 3]. The average difference is as great as 2.2 mm [3] (**Figure 15(a)**).

The buccolingual crown dimension is greater than the occlusocervical crown dimension [2, 3]. The average difference is as great as 4.3 mm [7] (**Figure 15(b)**).

The buccolingual crown is greater than the mesiodistal crown dimension [2, 3]. The average distance is as great as 2.3 mm [7] and as small as 1 mm [6] (**Figure 15(c)**).

The distal half of the crown has a smaller occlusocervical dimension than the mesial half [3] (**Figure 15(d)**).

4.1.3.2 Root's dimensions

The buccal roots are about the same length [2], and the palatal root is the longest root [2, 3] (**Figure 16(a)**).

The mesiobuccal root is wider buccolingually than the distobuccal root [3] (**Figure 16(b)**).

The distobuccal root is shorter and exhibits less buccolingual dimension than the mesiobuccal root [3] (**Figure 16(c)**).

4.2 External root canal anatomy of maxillary second molars

4.2.1 Number of roots

As stated in “Ingle’s Endodontics” [39], a majority of maxillary second molars in three anatomical studies were found to be three-rooted 88.6% (n = 1272); this result is lower than that found in the maxillary first molar, while the incidence of root fusion was 25.8% (n = 1960) as claimed in seven studies (**Figure 17**), and C-shaped canals with (4.9%) when compared to the maxillary first molar.

Other studies show different numbers. Indeed, the periodontologists Ross and Evanchik [46] observed 657 maxillary molars in 170 patients in their dental offices

Overall length	21.4 mm
Crown length	7.7 mm
Crown width	9.7 mm
Crown buccolingual	11.4 mm
Root length	12.5 mm (DB)
	13.1 mm (MB)
	13.7 mm (P)

Table 2.
Average dimensions (mm) of the maxillary second molar [37].

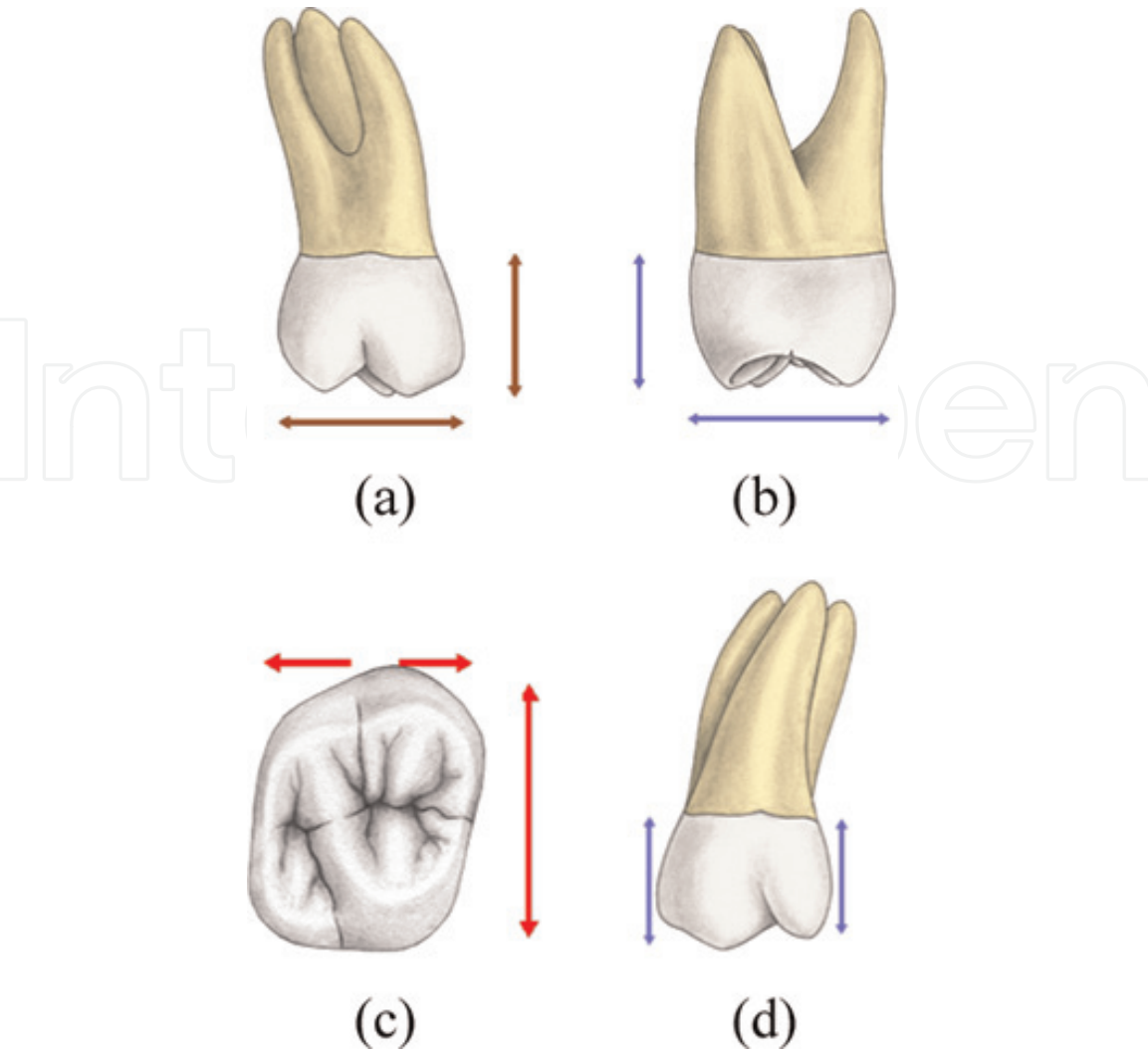


Figure 15.
The crown dimensions (reprinted from 3D tooth atlas version 9) [37]. (a) Crown buccal dimension, (b) crown mesial dimension, (c) crown occlusal dimension, and (d) occlusocervical crown dimension.

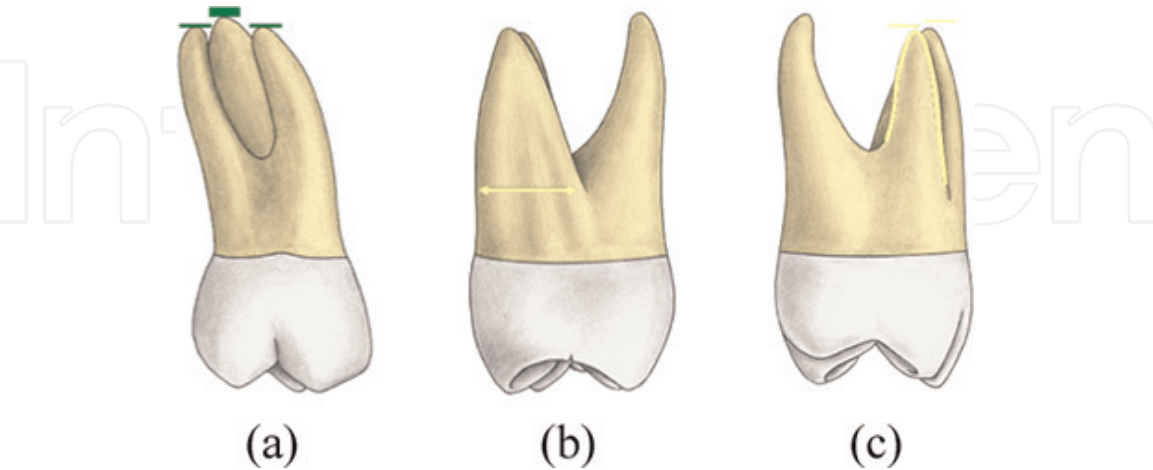


Figure 16.
Roots dimensions (reprinted from 3D tooth atlas version 9) [37]. (a) Root length, (b) mesial root dimension, and (c) distobuccal root dimension.

and concluded that the root fusion in the maxillary second molars percentage is up to 52.9% (n = 157) versus 47.1% (n = 140) without root fusion.

4.2.2 Shape of roots

4.2.2.1 Buccal aspect

The buccal roots are nearly parallel [2, 3]. The roots are relatively straight, and the second molar roots are relatively close together [3] (**Figure 18(a)**).

The roots have a distal inclination [2, 3] (**Figure 18(b)**). The root trunk is relatively long [3] (**Figure 18(c)**).

4.2.2.2 Mesial aspect

The lingual root is relatively straight [3] (**Figure 19(a)**).

The mesiobuccal root has a similar morphology of the maxillary first molar, but the furrow that runs through its mesial face is less marked, or nonexistent [8] (**Figure 19(b)**).

4.2.2.3 Distal aspect

The lingual root apex is frequently aligned with the distolingual cusp tip [2] (**Figure 20(a)**).

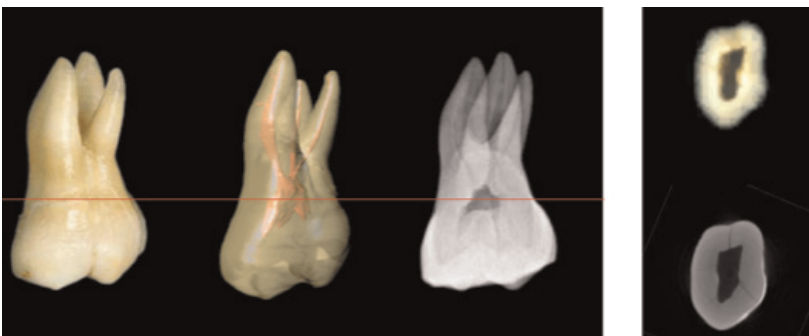


Figure 17.
Buccal view of maxillary right second molar with three roots (reprinted from 3D tooth atlas version 9) [37].

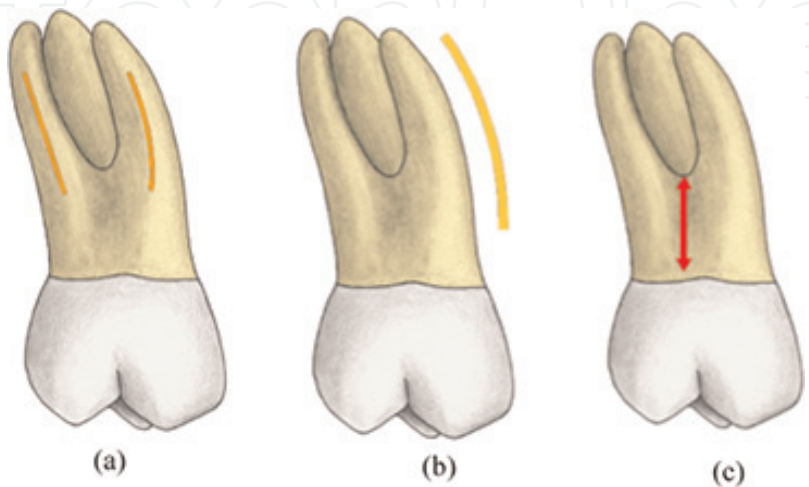


Figure 18.
Buccal aspect of maxillary second molar roots (reprinted from 3D tooth atlas version 9) [37]. (a) Root form/proximity, (b) root curvature, and (c) root trunk.

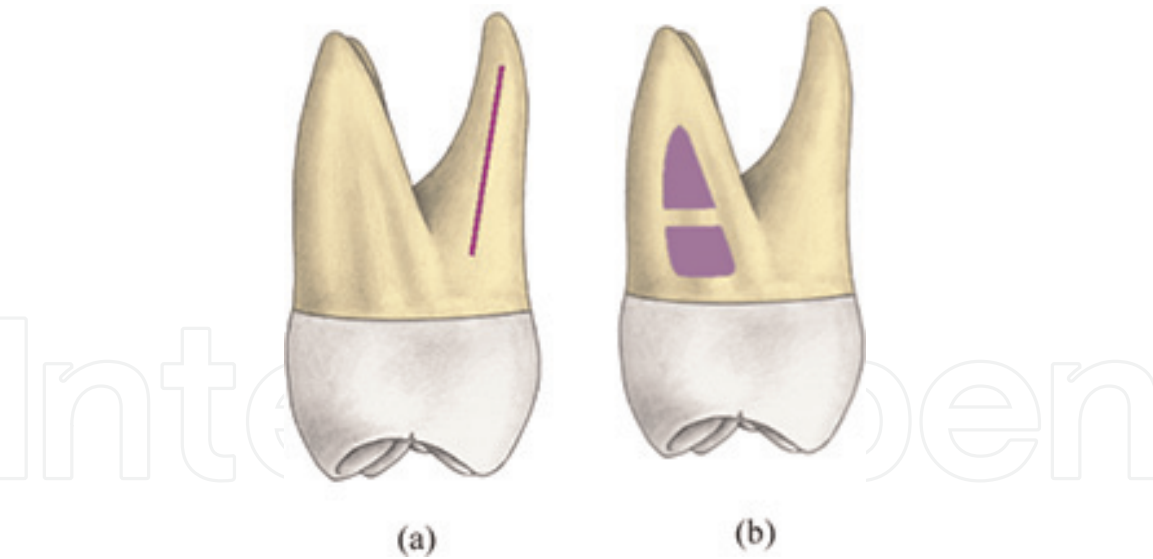


Figure 19.
Mesial aspect of maxillary second molar roots (reprinted from 3D tooth atlas version 9) [37]. (a) Lingual root form and (b) mesiobuccal root surface form.

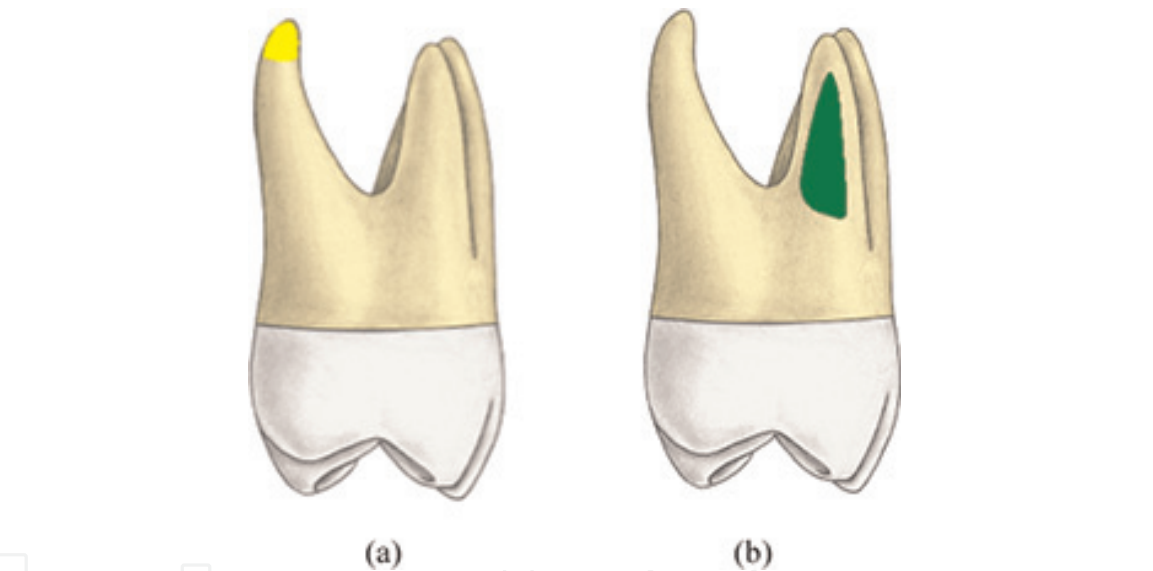


Figure 20.
Distal aspect of maxillary second molar roots (reprinted from 3D tooth atlas version 9) [37]. (a) Lingual root apex location and (b) distobuccal root surface/form.

The distobuccal root of the second maxillary molar differs morphologically. The background the mesiobuccal root on a distal view is visible [8] (**Figure 20(b)**).

4.2.2.4 Lingual aspect

The lingual root is not curved when seen from the lingual view, but it does taper apically to a blunt or rounded apex. The buccal roots are spread out far enough that they are usually visible behind the lingual root from this view (**Figure 21(a)**).

The apex of the lingual root is in line with the distolingual cusp tip instead of the lingual groove, as was found on the first molar [2].

The palatal root curves distally [5] (**Figure 21(b)**).

4.3 Internal root canal anatomy of maxillary second molars

4.3.1 Pulp chamber and canal entries

4.3.1.1 Morphology of pulp chamber

The general outline of the pulp chamber in second maxillary molars resembles first molars; four pulp horns of various sizes are present corresponding to the arrangement of the cusps [37].

The floor of the pulp chamber is markedly convex, which gives the canal orifices a slight funnel shape [41].

In Karaman et al.'s [11] research, among 100 maxillary second molars, the shape of the pulp chamber can be trapezoidal about 74% (n = 74), triangular about 21% (n = 21), or elliptical about 5% (n = 5) (**Figure 22**).

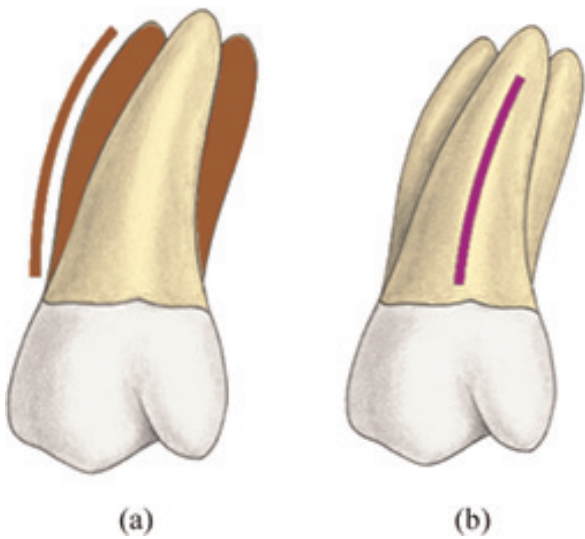


Figure 21.
Palatal aspect of maxillary second molar roots (reprinted from 3D tooth atlas version 9) [37]. (a) Buccal roots visibility and (b) lingual root curvature.

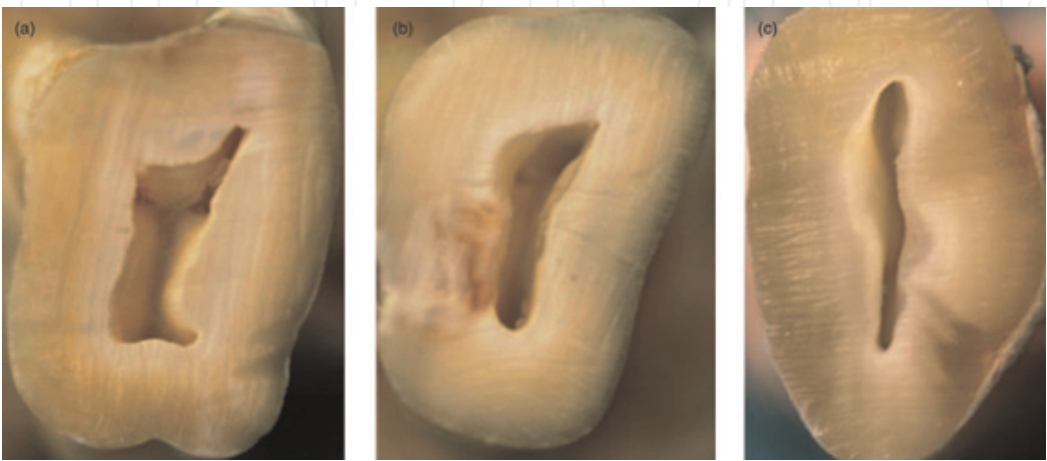


Figure 22.
Photograph of three second maxillary molars with pulp chambers [11]: trapezoidal (a), triangular (b), and elliptical (c).

When four canals are present, the access cavity preparation of the maxillary second molar has a rhomboid shape, if only three canals are present, the access cavity is a rounded triangle, the mesial marginal ridge need not be invaded with the base to the buccal; if only two canals are present, the access outline form is oval and widest in the buccolingual dimension [41] (**Figure 23**).

4.3.1.2 Description and location of canal entries

The canals' orifices in the maxillary second molars are closer mesially to each other than they are in maxillary first molar [41].

The three main orifices (MB, DB, and P) usually form a flat triangle and sometimes almost a straight line [41] (**Figure 24**).

The mesiobuccal canal orifice is located more to the buccal and mesial than in the first molar; the distobuccal orifice approaches the midpoint between mesiobuccal and palatal orifices; and the palatal orifice usually is located at the most palatal aspect of the root [41].

The distance between orifices in pulp chamber floor was claimed as: 3.09 ± 0.22 mm in type II ($n = 20$), and 3.89 ± 0.23 mm in type III ($n = 8$) according to Karaman et al. [11].

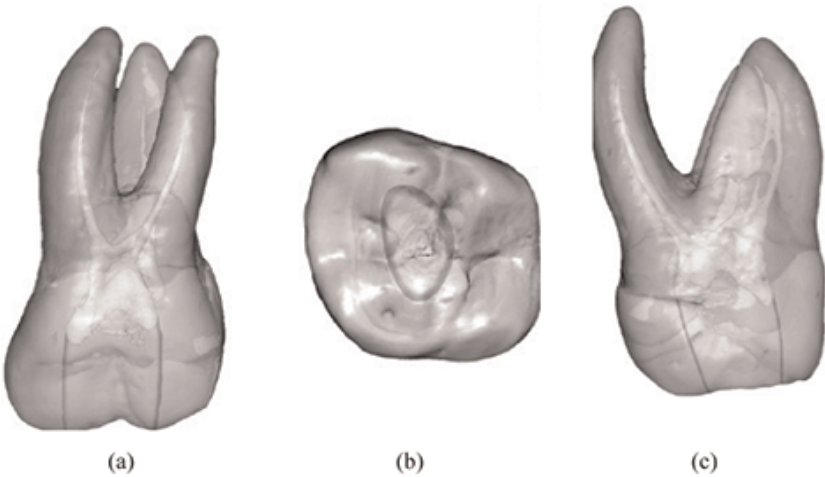


Figure 23.
The shape of the access cavity of maxillary second molars from different views [41]: (a) buccal view, (b) occlusal view, and (c) mesial view.

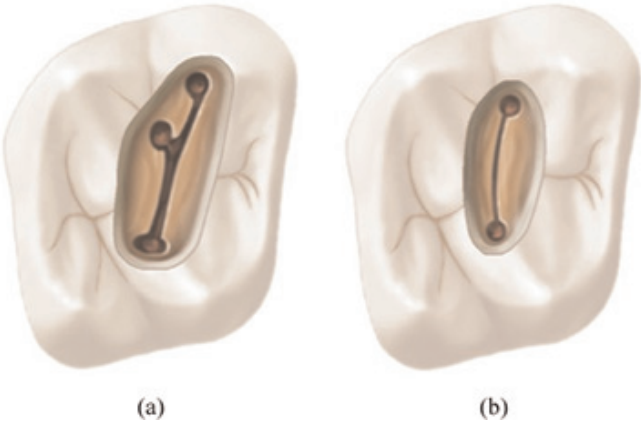


Figure 24.
Canal entries [41]. (a) Three canal orifices in a maxillary second molar. (b) Two canal orifices in a maxillary second molar.

4.3.2 Morphology of the canals

4.3.2.1 Mesiobuccal canal

As mentioned in the fifth chapter of “Cohen’s Pathways of the Pulp” [41]. Seventeen anatomical studies found a wide range of canal incidence in the mesiobuccal root; we calculated the average of one canal’s incidence, the results

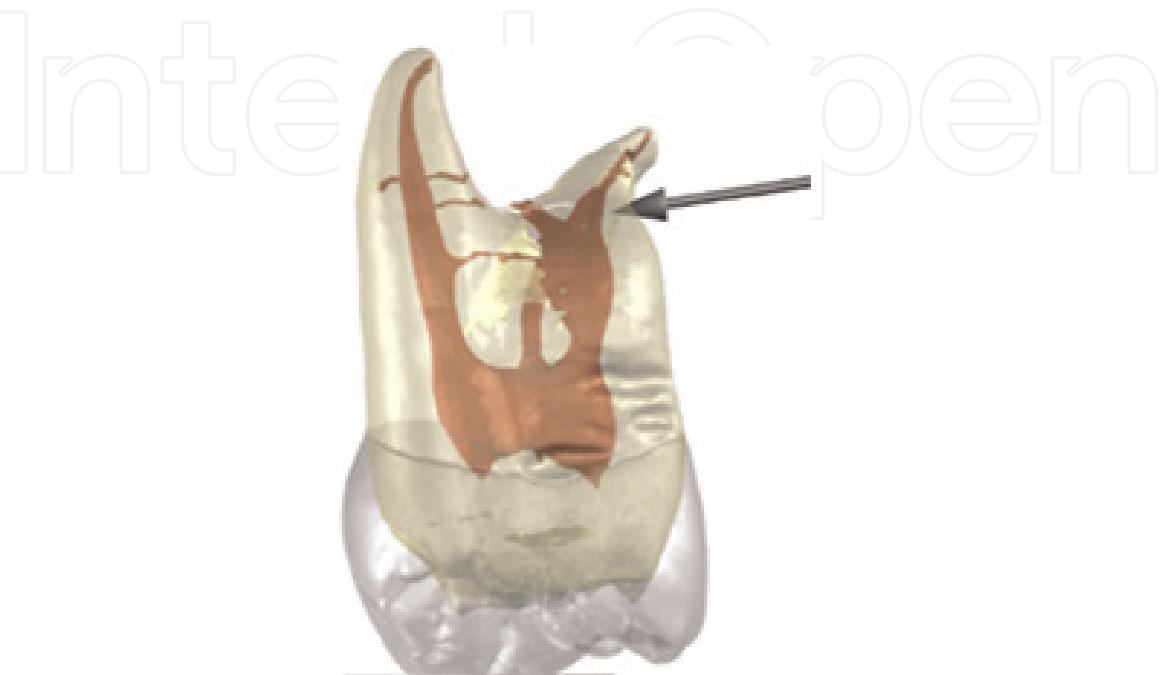

Figure 25.
Mesiobuccal canal system of maxillary second molar (reprinted from 3D tooth atlas version 9) [37].

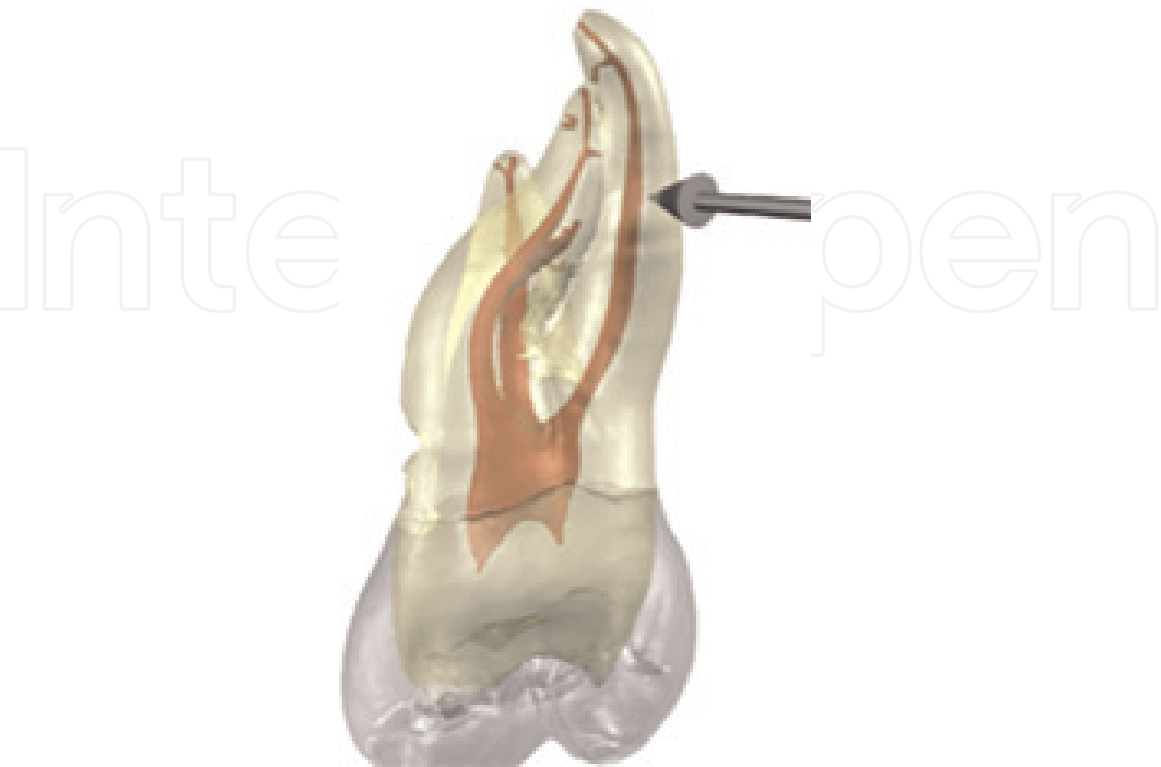

Figure 26.
Distobuccal canal system of maxillary second molar (reprinted from 3D tooth atlas version 9) [37].

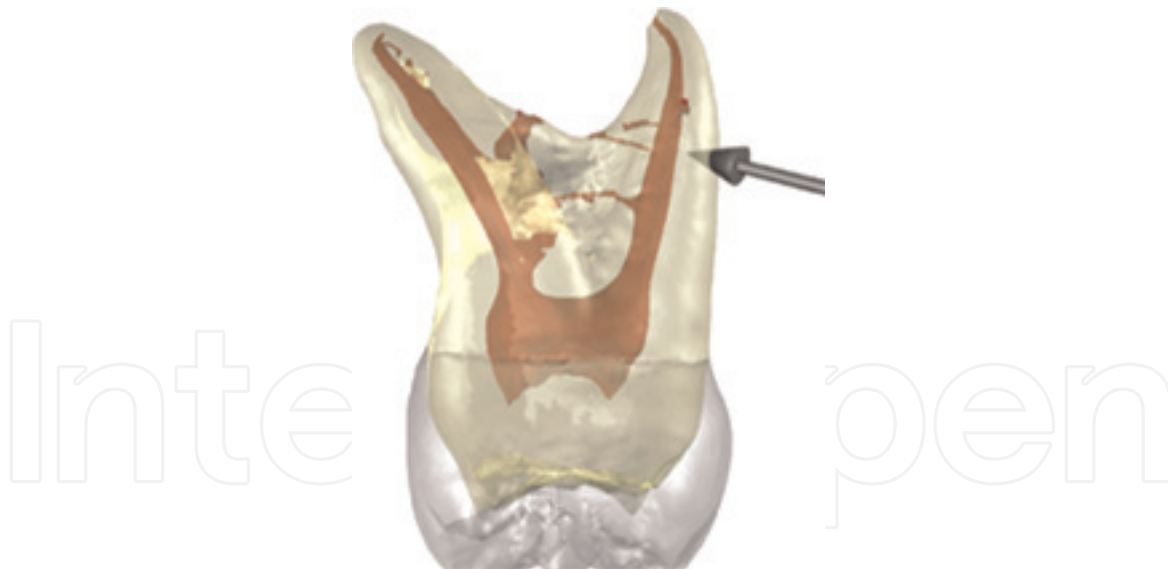


Figure 27.

Palatal canal system of maxillary second molar (reprinted from 3D tooth atlas version 9) [37].

were 69.3%, of two canals was 29%, while the incidence of three and four canals was, respectively, 2.6 and 1% in two studies (**Figure 25**).

There was a single apical foramen found in the mesiobuccal root over 68% in 1352 maxillary second molars studied [39].

The mean degrees of primary canal curvature that obtained for type II and type III configurations in maxillary second molar in clinical view were, respectively, $(26.13 \pm 9.18^\circ)$ and $(18.97 \pm 4.71^\circ)$ [11].

4.3.2.2 Distobuccal canal

These canals can be quite small and smaller at the mid-root and exit the pulp in a relatively straight line, occasionally there may be acute apical curves in mesial as well as distal directions [37] (**Figure 26**).

The distobuccal roots exhibited a single canal over 99% of the time in 10 reported anatomical studies, according to Cleghorn and Goodacre [39].

Otherwise stated in a book chapter: "Tooth Morphology, Isolation, and Access" [41] reporting seven anatomical studies, one single canal was found in the rate of 100%.

4.3.2.3 Palatal canal

In maxillary second molars, palatal canals are mostly straight with an apical curve to the buccal, apical to this marker is a deposition of secondary dentin along the palatal surface of the palatal canal [37] (**Figure 27**).

The internal canal morphology of the palatal root of the maxillary second molar was assessed in seven studies, showing the incidence of one canal over 99% [41]. While one study found that two palatal roots and two palatal canals occur in 1.47% of these teeth [31].

Neelakantan et al. [23] used CBCT to analyze 191 extracted maxillary second molars from an Indian population; the incidence of a single canal in a palatal root was 87.8%, and the presence of two or more canals was approximately 5.3%.

5. Conclusion

The roots’ variation and the canal system’s morphology knowledge constitute for each tooth a daily mission to the dental surgeon, in order to minimize the potential risks that lead to a failure of the therapy, especially in the endodontic.

An accurate diagnosis and a successful therapy could be resulted by highlighting the entire roots and canals network of molars in particular.

The preoperative radiography is the first complementary test to the diagnosis; although the results of the retro-alveolar radiography in ortho-centered incidence are important, they are not as significant as those of the meso-centric in terms of their impact, which appeared to display three roots of maxillary molars distinctly.

The cone beam computed tomography technology offers a high accuracy, when the data collected by the clinic and conventional radiography are not sufficiently contributory to the diagnosis. Unfortunately, the micro-computed tomography is not applicable in vivo human imaging; however, it forms a detailed means to evaluate the root canal anatomy quantitatively and qualitatively.

Respecting the maxillary molars’ axis, the endodontic access cavity in a trapezoidal shape allows: a direct access, and a possible discovery of an additional canal. This incidence appears to be increasing with the use of the surgical operating microscope during the access opening procedure, while a lower magnification of Galilean loupes are limited.

Furthermore, the canal entries could be located by using micro-openers, ultrasound inserts, round burs, or fine taper files. The use of dyes, with or without transillumination, could also be useful.

The working length must ideally be determined through an apex locator, and validated by retro-alveolar radiography. Cleaning and shaping with the k-files remains a prerequisite for Ni-Ti instrumentation.

The techniques that are used to fill a canal network of maxillary molars act according to the principle of vertical warm compaction or thermo-mechanical condensation with Gutta condenser.

Abbreviation

CBCT	cone beam computed tomography
Micro-CT	micro-computed tomography
CCD	charged coupled device
PSP	photostimulable phosphor

IntechOpen

IntechOpen

Author details

Said Dhaimy*, Lamyae Bedida, Hafsa El Merini and Imane Benkiran
Department of Restorative Dentistry and Endodontics, Faculty of Dental Medicine,
University Hassan II, Casablanca, Morocco

*Address all correspondence to: saiddhaimy@gmail.com

IntechOpen

© 2019 The Author(s). Licensee IntechOpen. This chapter is distributed under the terms of the Creative Commons Attribution License (<http://creativecommons.org/licenses/by/3.0>), which permits unrestricted use, distribution, and reproduction in any medium, provided the original work is properly cited. 

References

- [1] Vertucci FJ. Root canal morphology and its relationship to endodontic procedures. *Endodontic Topics*. 2005; **10**(1):3-29
- [2] Nelson SJ. *Wheeler's Dental Anatomy, Physiology, and Occlusion*. 10th ed. St. Louis, Missouri: Elsevier Saunders; 2015
- [3] Scheid RC, Woelfel JB. *Woelfel's Dental Anatomy*. 8th ed. Philadelphia: Wolters Kluwer/Lippincott Williams & Wilkins Health; 2012
- [4] Fuller JL, Denehy GE, Schulein TM. *Concise Dental Anatomy and Morphology*. Iowa City, Iowa: University of Iowa; 2001
- [5] Jordan R, Abrams L, Kraus B. *Kraus' Dental Anatomy and Occlusion*. 2nd ed. St. Louis: Mosby Year Book, Inc; 1992
- [6] Diamond M. *Dental Anatomy*. 2nd ed. Revised and Enlarged. New York: Macmillan; 1929
- [7] Black GV (Greene V. *Descriptive Anatomy of the Human Teeth*. Philadelphia : Wilmington Dental Manufacturing Company; 1890
- [8] Tallec P. *Anatomie Dentaire : Cours de Morphologie et Technologie Appliquées à l'art Dentaire*. Nouvelle éd. Aix-en-Provence: École de Prothèse Dentaire, IFOSUPD; 1983. 352 p
- [9] Bone J, Moule AJ. The nature of curvature of palatal canals in maxillary molar teeth. *International Endodontic Journal*. 1986;**19**(4):178-186
- [10] Lee J-K, Ha B-H, Choi J-H, Heo S-M, Perinpanayagam H. Quantitative three-dimensional analysis of root canal curvature in maxillary first molars using micro-computed tomography. *Journal of Endodontia*. 2006;**32**(10):941-945
- [11] Karaman GT, Onay EO, Ungor M, Colak M. Evaluating the potential key factors in assessing the morphology of mesiobuccal canal in maxillary first and second molars. *Australian Endodontic Journal: The Journal of the Australian Society of Endodontology Inc*. 2011; **37**(3):134-140
- [12] Shalabi RMA, Omer J Glennon OE, Jennings M, Claffey NM. Root canal anatomy of maxillary first and second permanent molars: Rewarming of cooled teeth. *International Endodontic Journal*. 2000;**33**(5):405-414
- [13] Pécora JD, Woelfel JB, Sousa Neto MD. Morphologic study of the maxillary molars. 1. External anatomy. *Brazilian Dental Journal*. 1991;**2**(1):45-50
- [14] Gani O, Visvisian C. Apical canal diameter in the first upper molar at various ages. *Journal of Endodontia*. 1999;**25**(10):689-691
- [15] Barrington C, Balandrano F. Diaphanization techniques in the study of root canal anatomy. In: Versiani MA, Basrani B, Sousa-Neto MD, editors. *The Root Canal Anatomy in Permanent Dentition*. Cham: Springer International Publishing; 2019:57-88
- [16] Pécora JD, Woelfel JB, Sousa Neto MD, Issa EP. Morphologic study of the maxillary molars. Part II: Internal anatomy. *Brazilian Dental Journal*. 1992; **3**(1):53-57
- [17] Pais A, Deo A, Martin A, Cunha R, Fontana C, Bueno C. Sodium fluorescein and cobalt blue filter coupled to a dental operating microscope to optimise root canal location in maxillary first molars. *ENDO*. 2014;**8**(3):193-198
- [18] Thomas RP, Moule AJ, Bryant R. Root canal morphology of maxillary permanent first molar teeth at various

ages. *International Endodontic Journal*. 1993;**26**(5):257-267

[19] Kulild JC, Peters DD. Incidence and configuration of canal systems in the mesiobuccal root of maxillary first and second molars. *Journal of Endodontia*. 1990;**16**(7):311-317

[20] Acosta Vigouroux SA, Trugeda Bosaans SA. Anatomy of the pulp chamber floor of the permanent maxillary first molar. *Journal of Endodontia*. 1978;**4**(7):214-219

[21] Silva EJNL, Nejaim Y, Silva AIV, Haiter-Neto F, Zaia AA, Cohenca N. Evaluation of root canal configuration of maxillary molars in a Brazilian population using cone-beam computed tomographic imaging: An in vivo study. *Journal of Endodontia*. 2014;**40**(2): 173-176

[22] Matherne RP, Angelopoulos C, Kulild JC, Tira D. Use of cone-beam computed tomography to identify root canal systems in vitro. *Journal of Endodontia*. 2008;**34**(1):87-89

[23] Neelakantan P, Subbarao C, Ahuja R, Subbarao CV, Gutmann JL. Cone-beam computed tomography study of root and canal morphology of maxillary first and second molars in an Indian population. *Journal of Endodontia*. 2010;**36**(10):1622-1627

[24] Guo J, Vahidnia A, Sedghizadeh P, Enciso R. Evaluation of root and canal morphology of maxillary permanent first molars in a North American population by cone-beam computed tomography. *Journal of Endodontia*. 2014;**40**(5):635-639

[25] Lee J-H, Kim K-D, Lee J-K, et al. Mesiobuccal root canal anatomy of Korean maxillary first and second molars by cone-beam computed tomography. *Oral Surgery, Oral Medicine, Oral Pathology, Oral*

Radiology, and Endodontics. 2011; **111**(6):785-791

[26] Martins JNR, Versiani MA. CBCT and micro-CT on the study of root canal anatomy. In: Versiani MA, Basrani B, Sousa-Neto MD, editors. *The Root Canal Anatomy in Permanent Dentition*. Cham: Springer International Publishing; 2019:89-180

[27] Spagnuolo G, Ametrano G, D'Antò V, et al. Microcomputed tomography analysis of mesiobuccal orifices and major apical foramen in first maxillary molars. *The Open Dentistry Journal*. 2012;**6**:118-125

[28] Markvart M, Bjørndal L, Darvann TA, Larsen P, Dalstra M, Kreiborg S. Three-dimensional analysis of the pulp cavity on surface models of molar teeth, using X-ray micro-computed tomography. *Acta Odontologica Scandinavica*. 2012;**70**(2):133-139

[29] Peters OA, Laib A, Rügsegger P, Barbakow F. Three-dimensional analysis of root canal geometry by high-resolution computed tomography. *Journal of Dental Research*. 2000;**79**(6): 1405-1409

[30] Stropko JJ. Canal morphology of maxillary molars: Clinical observations of canal configurations. *Journal of Endodontia*. 1999;**25**(6):446-450

[31] Peikoff MD, Christie WH, Fogel HM. The maxillary second molar: Variations in the number of roots and canals. *International Endodontic Journal*. 1996;**29**(6):365-369

[32] Saint-Pierre F, Fanelli G, Mokhbi J, Lombry Y, Pocholle P, Tuil L. *Traitement Endodontique-Rapport d'évaluation*; 2008. Available from: https://www.has-sante.fr/portail/upload/docs/application/pdf/2009-01/rapport_traitement_endodontique.pdf

- [33] Barbizam JVB, Ribeiro RG, Tanomaru Filho M. Unusual anatomy of permanent maxillary molars. *Journal of Endodontia*. 2004;**30**(9):668-671
- [34] Slowey RR. Radiographic aids in the detection of extra root canals. *Oral Surgery, Oral Medicine, and Oral Pathology*. 1974;**37**(5):762-772
- [35] Bjørndal L, Carlsen O, Thuesen G, Darvann T, Kreiborg S. External and internal macromorphology in 3D-reconstructed maxillary molars using computerized X-ray microtomography. *International Endodontic Journal*. 1999;**32**(1):3-9
- [36] Baratto Filho F, Zaitter S, Haragushiku GA, de Campos EA, Abuabara A, Correr GM. Analysis of the internal anatomy of maxillary first molars by using different methods. *Journal of Endodontia*. 2009;**35**(3):337-342
- [37] Montgomery K, Herbranson E. Dental anatomy & 3D tooth atlas version 9.0. 3D Tooth Atlas 9 | eHuman. Illinois: Quintessence; 2018. Available from: <https://ehuman.com/product/3d-tooth-atlas-9/>
- [38] Yang Z-P, Yang S-F, Lee G. The root and root canal anatomy of maxillary molars in a Chinese population. *Dental Traumatology*. 1988;**4**(5):215-218
- [39] Ingle JI, Bakland LK, Baumgartner JC. *Ingle's Endodontics*. Hamilton, ON: BC Decker; 2008
- [40] Cleghorn BM, Christie WH, Dong CCS. Root and root canal morphology of the human permanent maxillary first molar: A literature review. *Journal of Endodontia*. 2006;**32**(9):813-821
- [41] Cohen S. In: Hargreaves KM, Berman LH, Rotstein I, editors. *Cohen's Pathways of the Pulp*. 11th ed. St. Louis, Missouri: Elsevier; 2016
- [42] Peeters HH, Suardita K, Setijanto D. Prevalence of a second canal in the mesiobuccal root of permanent maxillary first molars from an Indonesian population. *Journal of Oral Science*. 2011;**53**(4):489-494
- [43] Rover G, Belladonna FG, Bortoluzzi EA, De-Deus G, Silva EJNL, Teixeira CS. Influence of access cavity design on root canal detection, instrumentation efficacy, and fracture resistance assessed in maxillary molars. *Journal of Endodontia*. 2017;**43**(10):1657-1662
- [44] Hartwell G, Bellizzi R. Clinical investigation of in vivo endodontically treated mandibular and maxillary molars. *Journal of Endodontia*. 1982;**8**(12):555-557
- [45] Baratto-Filho F, Fariniuk LF, Ferreira EL, Pecora JD, Cruz-Filho AM, Sousa-Neto MD. Clinical and macroscopic study of maxillary molars with two palatal roots. *International Endodontic Journal*. 2002;**35**(9):796-801
- [46] Ross IF, Evanchik PA. Root fusion in molars: Incidence and sex linkage. *Journal of Periodontology*. 1981;**52**(11):663-667