We are IntechOpen, the world's leading publisher of Open Access books Built by scientists, for scientists

6,900
Open access books available

186,000
International authors and editors

200M
Downloads

Our authors are among the

154
Countries delivered to

TOP 1%
most cited scientists

12.2%
Contributors from top 500 universities

WEB OF SCIENCE™

Selection of our books indexed in the Book Citation Index in Web of Science™ Core Collection (BKCI)

Interested in publishing with us?
Contact book.department@intechopen.com

Numbers displayed above are based on latest data collected.
For more information visit www.intechopen.com

Chapter

Comprehensive Clinical Approach to Fecal Incontinence

Kasaya Tantiphlachiva

Abstract

Fecal incontinence is a disturbing condition, which reduces the quality of life of patients. Prevalence of this apprehensive problem is usually underestimated. However, it is more common in female, elderly, and institutionalized subjects. Factors that may be associated are urinary incontinence, diabetes mellitus, depression, diarrhea, history of anorectal surgery, anorectal trauma, pelvic organ surgery, and pelvic irradiation. To improve this condition, physicians should have insight into the individual's pathophysiology through the process of careful history taking, severity, and quality of life assessment, thorough physical examination and comprehensive anatomic and neurophysiologic evaluation. These tests include imaging, anorectal manometry, and neural conduction tests. Finally, by these gathered information, individualized treatment for the patient is designed. Patient's education and judicious follow-up are also parts of the plan.

Keywords: fecal incontinence, digital rectal examination, endoanal ultrasound, anorectal manometry, neurophysiologic test

1. Introduction

Fecal incontinence (FI) is defined as recurrent uncontrolled passage of solid or liquid stool at least 3 months in an at least 4-year-old individual [1]. For research, onset should be at least 6 months with the episodes of two times in 4 week-period [1]. Severity of FI has a direct deteriorating effect on the quality of life of the patients, especially on life style and depression [2, 3]. The higher severity was also significantly associated with more direct annual medical (i.e. medical resources used for diagnosis, treatment, and management of related conditions) and nonmedical costs (i.e. nonmedical care such as transportation and use of protective products) [4]. Other indirect cost is associated with loss of productivity [4] and work load of caregivers [5]. Prevalence of FI in general population was 7.7% (range, 2.0–20.7%) [6, 7]. It equally affected both gender in most studies; male 8.1% (range 2.3–16.1%) and female 8.9% (range 2.0–20.7%) [7, 8]. The prevalence increased with age, that is, 5.7% at 15–34 year, 9.9% at 60–90 year, and 15.9% at >90 years [7, 9]. Associated risk factors of FI included increasing age, watery stool, functional diarrhea, urinary incontinence, and polypharmacy (use of five or more medications) [5, 7, 9, 10, 11]. In instituted population, the prevalence of FI was up to 46–57.1% [11, 12]. Significant associated factors of FI were poor general health status (≥4 comorbidities), urinary incontinence, cognitive-function impairment (dementia), decreased mobility, and length of nursing home residency [12]. In elderly female, marriage was another predictive factor of FI [9]. This may be explained by the difference in pathophysiology

IntechOpen

of FI in female where parity, traumatic vaginal delivery, and previous pelvic surgery played roles [13]. In parous female, the incidence of FI was as high as 46% from postal survey [14]. In male with FI, impaired rectal sensation and evacuation disorder are more prominent than female [13]. Thus, pathophysiology of FI is likely to be different between genders and individuals. Careful systematic evaluation should be performed to assess these underlying mechanisms in order to guide a successful management.

2. Pathophysiology of fecal incontinence

Normal control of defecation requires intact neuromuscular structures, including rectum, anal canal, pelvic floor, and neural network. Rectum, as a reservoir; anal canal, with intact sensation and vascular cushion as a checkpoint; pelvic floor and anal sphincter, as controlling gate; and neural network, as a communication system, all play roles in bowel control. For perfect action, colorectal motility, stool volume, and stool consistency should also be normal. Disruption of one or more compositions of the system leads to FI. In clinical practice, most patients with FI were found to have multiple contributing factors [15].

Rectum is the distal part of colon, which extends from the rectosigmoid junction, dilates to form a reservoir, and ends at the tight circular anal canal [16]. It is distensible and acts as a temporary storage of residue of ingested food [17]. Surgical removal of rectum or physical injury to rectum such as radiation predisposes the subject to FI.

Anal canal is the terminal part of the gastrointestinal tract. It is a close tube surrounded by anal sphincter muscle (surgical anal canal). Anal sphincter and pelvic floor muscle act together to close the bowel. Anal sphincter muscles comprise internal anal sphincter (IAS) and external anal sphincter (EAS). ***IAS*** is the inner circular smooth muscle layer, which contributes to most of the anal sphincter pressure at rest [17, 18]. It is a continuation of inner circular muscle of the rectum and ends just proximal to the subcutaneous part of EAS [18]. Its length is 2.5 cm and thickness is 2–5 mm in normal population [18]. IAS is innervated by the autonomic nervous system. Parasympathetic supply is from the first, second, and third sacral nerves via pelvic plexus and sympathetic supply from both thoracolumbar outflow and hypogastric nerves [18]. The enteric nervous system connecting between neurons and glial cells situates in the myenteric (Auerbach's) plexus and the submucosal (Meissner's) plexus is a part of reflex pathways that control bowel [18]. ***EAS*** is the outer striated muscle layer, which voluntarily functions during squeeze. In the literature, it had been described as three parts: subcutaneous, superficial, and deep [19, 20]. However, the findings during surgery and from advance imaging, the current concept accepts that the deep portion of EAS it on continuous circumferential mass with the puborectalis muscle [19]. The upper part of superficial EAS is attached anteriorly with transverse perinei muscle at the perineal body [19]. The subcutaneous portion of EAS is just underneath the skin and is traversed by the conjoined longitudinal muscle, which is the continuation of the outer longitudinal layer of the rectum. EAS is innervated by the perineal branch of pudendal nerve (S2–4), inferior rectal nerve, and perineal branch of the forth sacral nerve [19, 21]. These nerves contribute in various patterns [21]. Mucosa of the upper anal canal is lined by columnar epithelium and the lower anal canal is lined by squamous epithelium [19]. Submucosal tissue and subepithelial tissue contain internal hemorrhoidal plexus and external hemorrhoidal plexus, respectively [19]. This distensible hemorrhoidal cushion plays a protecting role for anus and helps in complete closure of the anal canal. It contributes to 15–20% of resting anal canal pressure in addition to the major 85% contributed by IAS [22].

Pelvic floor muscle, or the levator ani muscle, continues with the uppermost part of the external anal sphincter. It comprises of (1) *puborectalis muscle*, a U-shaped muscular sling from each side of pubic symphysis that joins behind the rectum at the anorectal junction [17]. It is a major muscle that maintains anorectal angle approximately 90° at rest [19, 22]. (2) *Pubococcygeus muscle*: originates from the back of the pubic bone, lateral to the puborectalis muscles, and from the anterior half of the obturator fascia [19, 22]. It runs backward, downward, and medially to decussate with the fibers from the opposite side forming a tendinous center called anococcygeal raphe [19, 22]. (3) Iliococcygeus muscle arises from the ischial spine and posterior part of the obturator fascia and passes downward, backward, and medially to insert on the lower part of sacrum, coccyx, and anococcygeal raphe [19]. In the middle of the anterior part of the levator ani, there is the levator hiatus, which pelvic organs pass through [19]. Pubococcygeus and iliococcygeus contribute to lateral pressure to narrow the levator hiatus, and puborectalis muscle has a role in maintaining continence [22]. Impaired levator ani contraction is strongly correlated with severity of FI [23]. Levator ani is innervated by direct branches from sacral nerves (S3–5) proximal to sacral plexus [19, 24].

Sensory innervation of the anorectal area is responsible for correct afferent information of the luminal content. Anal canal is sensitive to pain, temperature, and touch, and afferent conduction is via pudendal nerve back to S2, S3, and S4 nerve roots [16, 25]. For rectum, parasympathetic fiber transmits the sensation of rectal distension via the nervi erigentes which are derived from the S2, S3, and S4 spinal segment [22]. These fibers join the sympathetic nerve fiber which is derived from L1, L2, and L3 spinal segment [16, 18, 22, 24] to form hypogastric plexus [18, 24].

Sacral reflexes, including rectoanal inhibitory reflex (RAIR), sampling reflex, and cough reflex, are additional mechanisms of sensing and controlling stool [26]. These involve anorectum sensing area, peripheral nerve, spinal cord sensory and motor nuclei, and anorectal musculature, acting in a coordinated circle. ***RAIR***, mediated by intramural myenteric neurons, is an immediate IAS relaxation following rectal distension [26]. Sensation of rectal distention and stretch by nerve fibers in rectal mucosa, submucosa, and myenteric plexus then go along the parasympathetic system to S2, S3, and S4 [27]. When the intrarectal pressure becomes higher than intra-anal canal pressure, bowel content is allowed to reach the anodermal area in the upper anal canal where sensory receptors are abundant [26, 27]. This anorectal sampling reflex provides information for discrimination between solid, liquid, and gas contents [27]. Thus, the person can choose to retain those contents in the bowel or pass it out at an appropriate time.

Cough reflex prevents leakage during a sudden rise in intra-abdominal pressure by immediate contraction of EAS [26]. It is triggered by receptors on the pelvic floor and transferred through a spinal reflex arc [28]. Connection between the central nervous system and the anorectal area contributes to a higher function of bowel control. Intact CNS to percept, process, and produce the efferent action is required for perfect control. Specific sensory areas in the brain are responsible for sensing the rectal distension [29]. Specific motor area in the parasagittal cortex is responsible for controlling anal sphincter [30, 31]. **Figure 1** shows the anatomical and neural pathways of fecal continence control.

FI occurs when one or more of the controlling mechanisms were damaged. Obvious etiology of FI is anal sphincter damage. In females, obstetric anal sphincter injury can occur after vaginal delivery. Postpartum fecal incontinence had been reported in 3–4% of women [32]. Sphincter weakness after delivery may be caused by injury to internal and external sphincter and injury to pudendal nerve or combination [32]. Risk factors include forcep delivery, prolonged second stage of labor (>5 h), shoulder dystocia, ano-vulvar distance <2 cm, perineal scar and third or

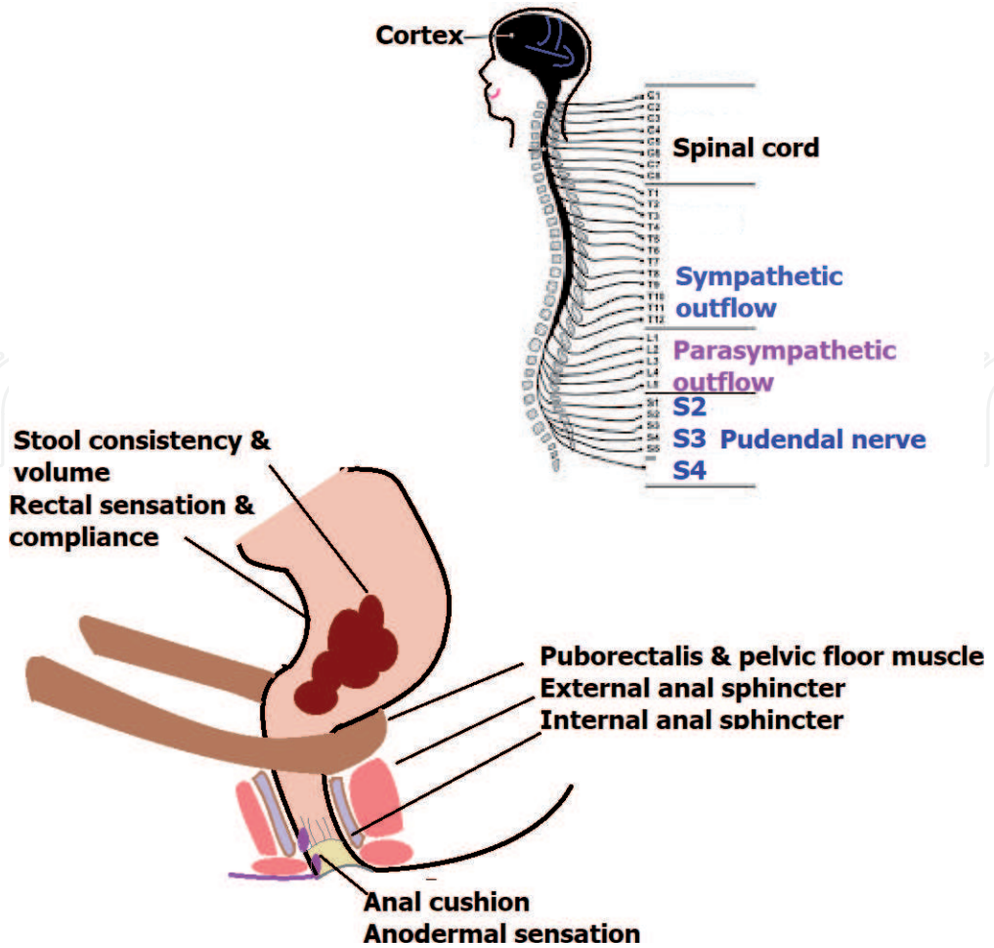

Figure 1.
Fecal continence system.

fourth-degree perineal injury, and infant birth weight >3500 g [32, 33]. Symptoms of continence may occur later in life as there are other compensatory mechanisms to compensate [32]. Symptomatic group was older, had less body mass index, and had more forceps delivery than the asymptomatic group [33]. FI in men was more associated with constipation and previous colon and anorectal surgery compared to women [34]. Anorectal surgery, including hemorrhoidectomy, lateral internal sphincterotomy, and fistulectomy, may affect the anal sphincter and vascular cushion, thus leading to FI [15, 35].

Normal rectum is a low-pressure space acting as a reservoir of fecal material until a coordinated and effective evacuation is appropriate [36]. Decreased rectal compliance, accommodation, or sensation may be found in inflammatory bowel disease and radiation proctitis [15, 36]. Neurological interruption of the central, peripheral, or autonomic nervous system is another cause of FI. These include cerebrovascular accident, spinal cord injury, and pudendal neuropathy. The latter had been reported after radiotherapy for prostatic cancer [37]. FI after multimodality treatment of pelvic malignancy, including prostate, cervical cancer, and rectal cancer, had been reported between 3 and 53% [38].

Other contributing risk factors of FI are stool consistency and transit function of the colon. In the presence of diarrhea and history of previous cholecystectomy, the control of stool becomes more difficult. In obesity, increased body mass index predisposed the subjects to FI due to weakening of pelvic floor musculature and increased intra-abdominal pressure [15, 39]. Shorter anal canal length, lower resting pressure, and higher rectal perception threshold were seen compared to nonobese patients [39]. **Table 1** summarizes the risk factors of fecal incontinence.

Category	Risk factors
Intestinal factors	
	Diarrheal status
	Irritable bowel syndrome
	Inflammatory bowel disease
	Post cholecystectomy
	Malabsorption/food intolerance/enteral tube feeding
	Hypersecretory tumors
Rectal factors	
-Acquired structural abnormalities	Rectal intussusception/rectal prolapse
	Rectal resection
	Trauma/anorectal impalement
	Radiation proctitis
	Ulcerative proctitis
-Overflow	Fecal impaction (overflow incontinence/paradoxical diarrhea)
	Dyssynergic defecation
	Rectal hyposensitivity
Anal sphincter and pelvic floor factors	
-Acquired anatomical defect	Sphincter injury: obstetric, anorectal surgery, accident (e.g. pelvic fracture), and impalement
-Congenital defect	Imperforated anus, cloacal defect, and spina bifida (myelomeningocele and meningocele)
Neurological factors	
-Central nervous system	Cerebrovascular disease
	Trauma brain injury
	Neoplasm of brain and spinal cord
	Cerebral infection
	Multiple sclerosis
	Spinal surgery
	Spina bifida
	Dementia
	Tabes dorsalis
-Peripheral nervous system	Pudendal neuropathy (radiation, diabetes, and chemotherapy)
-Autonomic nervous system	Diabetes mellitus
	Parkinson's disease
	Previous pelvic surgery/radiation
Metabolic and systemic factors	
Endocrine	Diabetic gastroenteropathy and hyperthyroidism
Electrolyte disturbance	Hypercalcemia and hypermagnesemia
Medication	*Causing loose stool:* laxatives/metformin/magnesium-containing antacids/serotonin reuptake inhibitors, and orlistat
	Alter gut flora: cephalosporins, penicillins, and erythromycin
	Alter sphincter tone: nitrate, calcium channel blocker, sildenafil, and bolulinum toxin injection

Category	Risk factors
Psychological factors	
	Psychiatric disorder
	Medication
Individual characteristics	
	Aging
	Female gender
	Smoking
	Obesity
	Institutionalization/physical disabilities

Table 1.
Risk factors of fecal incontinence.

3. Assessment of fecal incontinence

To define the underlying etiology of FI in each patient, the clinician should have stepwise systematic assessment. There are three important steps in evaluation of patients with FI: clinical assessment, anatomical assessment, and neurophysiologic assessment.

3.1 Clinical assessment

Manifestation of FI may be classified into three subtypes: urge incontinence, total incontinence, and seepage [27].

1. *Passive incontinence*: involuntary leakage of fecal material or gas without awareness.

2. *Urge incontinence:* leakage of fecal material or gas in spite of active attempts to retain them.

3. *Fecal seepage*: undesired leakage of fecal material after normal bowel movement without abnormal continence or evacuation.

Careful history taking should detect patients with FI who may not admit this embarrassing condition [40]. By using different terms, such as diarrhea, fecal urgency, accident, etc., and privacy of the clinic environment should allow more patients to discuss about their symptoms. Information retrieved from history taking should include severity, onset duration, clinical subtypes, and associated symptoms, for example, rectal prolapse, pelvic organ prolapse, and urinary incontinence [41]. Stool diary and stool form charts such as the Bristol stool form scale can be used for better communication [15]. Aggravating factors should be elicited. These include detailed obstetric history and abdominal-colon-anorectal surgical history, and coexisting medical condition should be noted [41]. Previous and current treatments and results should be recorded [41]. Severity score should be documented by using one of the available established scores: St. Mark's Fecal Incontinence Severity Score (Vaizey's score), Cleveland Clinic Fecal Incontinence Score (Wexner's score), the American Medical System score, and Pescatori score [42]. From the international survey, the Wexner score is the most commonly used scoring system even though the score does not include fecal urgency [43]. These scores do not have a cut-off point, may not be used to guide treatment, and cannot predict the treatment outcome [44, 45]. However, it reveals the patient's current

Onset, duration, and precipitating event(s)
Severity and timing of symptoms
Clinical subtypes: passive, urge, and fecal seepage
Clinical grading of severity
Previous and current bowel movement activity; frequency, stool consistency, urgency, change in bowel habit, constipation, and fecal impaction
Coexisting problem: urinary incontinence and pelvic organ prolapses
Previous surgery: anorectal surgery, abdominal surgery, and pelvic surgery
Previous pelvic irradiation
Central nervous system problem: cerebrovascular disease and spinal cord injury
Underlying medical problem and current medication
Current medication/caffeine/diet
Obstetric history: previous delivery, instrumentation, baby birth weight, perineal tear, and repair

Table 2.
Information that should be obtained during history taking from patient with fecal incontinence.

burden which can be used to compare during follow-up after treatment. **Table 2** shows the information that should be obtained during history taking [27]. Change in bowel habit, stool character, advanced age, bleeding per rectum, anemia, mucous bloody stool, and family history of cancer should alert the physician to further endoluminal investigation. Multi-compartment involvement of pelvic organ prolapse should be approached by the multidisciplinary team. Quality of life assessment using standardized scores—fecal incontinence quality of life scale (FIQL) [46], SF-36 (short Medical Outcomes Questionnaire), and Gastrointestinal Quality of Life Index—may be used for clinical assessment and should be used routinely in research [44, 45].

Physical examination, especially perineal and anorectal examination, is an important part of assessment. Information of baseline anatomy and function of the subject are obtained [41]. Patients are usually placed on a left lateral position with hip and knee flexion. ***Inspection*** of the perineum, at rest and strain, may be positive for scar from previous surgery or obstetric injury, skin inflammation, thinning or loss of perineal body, anal gaping, soiling fistula, hemorrhoid, mucosal prolapse, rectal prolapse, and perineal descent [41, 47–49]. Following inspection, ***testing for perineal sensation*** and anocutaneous reflex is performed by stroking the perianal skin in a centripetal fashion with a stick with cotton bud, in all four quadrants [47]. The absence of anocutaneous reflex suggests pudendal neuropathy or a cauda equina lesion [48]. ***Digital palpation*** should then be performed gently using a gloved index finger [47]. Anal epithelium and rectal mucosa should be felt for tumor, smoothness, bulging, protruding, and impacted stool. Resting anal sphincter tone and length of anal canal should be noted before asking the patient to squeeze to note voluntary squeeze tone [41, 47]. Then the patient is asked to push and bear down while the examiner places her left hand over the patient's abdomen. The defecation pattern is noted by observing abdominal push effort, anal relaxation, and perineal descent [47]. Patients with suspected pelvic organ prolapse are further examined in a lithotomy position, by asking them to bear down to reveal prolapse of rectum, vaginal, uterus, and/or bladder [41].

By inspection, patients with gaping anus showed lower resting anal sphincter pressure than those without and patients with anal scar had lower incremental squeeze pressure than those without these signs [49]. When comparing squeeze pressure measure by DRE and by high-resolution manometry, there was moderate agreement in the diagnosis of fecal incontinence (ƙ-coefficient = 0.418, p = 0.006).

Sensitivity, specificity, PPV, and NPV were 77.4, 70.0, 88.9, and 50.0%, respectively [50]. Even the agreement is poor if anal resting pressure was used; DRE can be a useful beside test to diagnose FI [50]. Mechanical abnormalities detected during physical examination including palpable mass, mucous bloody stool, and anemia warrant additional investigation such as endoscopy, stool examination, and breath tests [51].

3.2 Anatomical assessment

After secondary FI has been ruled out, investigation to define the underlying mechanism of FI in that patient should be performed. These include endoanal ultrasound or MRI to evaluate anal sphincter and pelvic floor anatomy integrity. For the assessment of anal sphincter defects, DRE is inaccurate for determining external anal sphincter defect <90° (accuracy 36%) [49]. Sensitivity is 90% and specificity is only 27.8% in distinguishing small from extensive anal sphincter defect [52]. Thus, DRE may be able to identify anal sphincter defect but is not sensitive enough to quantify its degree. ***Endoanal ultrasound (EAUS)*** has been recommended as a useful and sensitive tool to detect and define anal sphincter anatomy [44, 45]. It has a firm role in diagnostic work-up of FI [53]. EAUS is the gold standard for morphologic assessment of anal canal [54]. Various kinds of probes are available. Traditional 2D, 360° rotating endoprobe had been used to examine anal canal at multiple levels: (1) uppermost level, U-shaped puborectalis muscle is seen; (2) middle level, complete rings of IAS and EAS were seen and transverse perinei muscle is visualized; and (3) lower level, complete ring of subcutaneous part of EAS was seen without IAS [54, 55]. Normative data using 3D-EAUS had been described in both western and Asian population, and in both genders [56, 57]. Male had longer anal canal length than female by 3D-EAUS [56, 57]; M *vs.* F, 3.9 ± 0.7 *vs.* 3.4 ± 0.43 cm, $p = 0.007$ [57]. Importantly, anterior anal canal length, where puborectalis muscle mass is devoid, is significantly shorter in female [56, 57]; M *vs.* F, 3.6 ± 0.8 vs. 2.8 ± 0.5 cm, $p < 0.001$ [57]. Information which can be obtained included thickness, length, defect, and scar of IAS, EAS components (subcutaneous and superficial parts), and puborectalis muscle. The information of defect and residual anal sphincter remnant can guide anal sphincter repair. **Figure 2** is an example of anal sphincter defect detected by 3D-EAUS. Alternative to EAUS may be transperineal ultrasound (TPUS), which can also detect anal sphincter defect [44]. There was no difference between MRI and EAUS

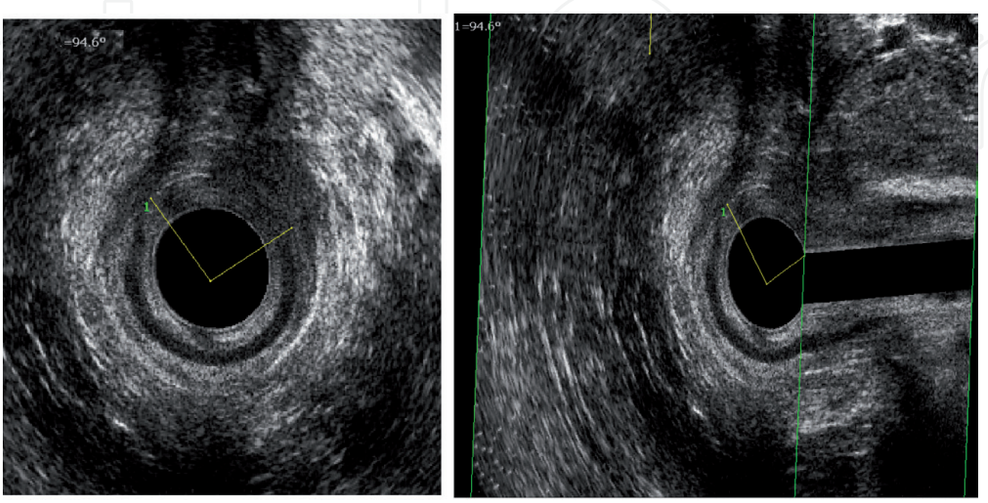

Figure 2.
Anal sphincter defect detected by 3D-endoanal ultrasound.

in depiction of external anal sphincter defect [58]. Sensitivity of MRI vs. EAUS was 81% vs. 90% and the positive predictive value was 89% vs. 85% [58].

In detecting external anal sphincter atrophy, EAUS was also comparable to MRI [59]. External phase-array MRI is comparable to endoanal MRI in detecting EAS atrophy [60]. However, MRI is more expensive and time-consuming than EAUS [45] and is recommended only in the institute with sufficient experience available [60]. Dynamic MRI may be useful in subjects with suspected concomitant pelvic floor disorder, such as rectal prolapse, pelvic organ prolapses, rectocele, enterocele, and perineal descent.

3.3 Functional and neurophysiologic assessment

Anorectal manometry (ARM) has been used to assess global anorectal function. It is used to quantify IAS and EAS function, rectal sensation, rectoanal reflexes, and rectal compliance [51, 61]. Traditional techniques used water-perfused and solid-state probe (6–8 channels). The newer technique uses high-resolution (HRM, 12 channels) and high definition probes (3D-HRM, 256 channels) [51, 61]. From recent international survey, most institutions use a conventional water-perfused system [62]. Solid-state and high-resolution systems are used mostly by specialist center [62]. Techniques and minimum standards of ARM had been described by Rao et al. [63]. These steps can be applied to the new probes. HRM and HDM results were comparable to measurement by water-perfused systems [64, 65]. Important information obtained includes resting anal sphincter pressure which primarily reflects internal anal sphincter function [64, 67]. Resting anal sphincter pressures are varied by gender, age, and testing methodology [28]. Pressure is usually higher in men and younger age [28, 53, 67]. Normal value using classic catheter had been described using solid-state catheter [68]. In our institute, water-perfusion catheter, normative value is shown in **Table 3**. Males had longer high-pressure zone, higher squeeze pressure, and longer squeeze duration than females [68]. **Figure 3** shows manometric findings of a patient with fecal incontinence, in whom, the anal squeeze pressure did not increase as high as normal.

Rectal sensory testing and rectal compliance evaluation can be performed as a part of anorectal manometry or can be performed separately using the barostat technique or electrical stimulus [28]. Incontinent patients may have rectal hyposensitivity or hypersensitivity [51]. Rectal hypersensitivity is commonly found in patients with FI which may be explained by the cognitive precaution of the patients. However, this finding should be studied in detail. Rectal hyposensitivity, found in 10% of subjects with FI, had been reported as a cause of idiopathic FI which may reflect the afferent nerve dysfunction [69, 70]. It may also be due to megarectum and may be associated to fecal retention with overflow FI. Reduced rectal compliance is seen in patients with colitis, low spinal cord lesion, and diabetes mellitus. Increased rectal compliance is seen in high spinal cord lesion [51]. RAIR and cough reflex may be impaired and contribute to FI in some individuals. For example, RAIR may be impaired after low rectal surgery [71] and spinal cord injury below L2 level [72]. Cough reflex is impaired in patients with cauda equina or sacral nerve plexus lesion [28].

Clinical utility of ARM in FI is to assess the weakness of sphincter muscle and abnormal anorectal sensation. For discrimination between normal and incontinent individuals, ARM had reported a sensitivity of 91.4%, an accuracy of 85.8%, and a specificity of 62.5% only [73]. By meta-analysis, ARM is accurate for diagnosis of FI with a sensitivity of 0.80 (95% confidence interval (CI) 0.69–0.88) and a specificity of 0.80 (95%CI 0.65–0.90). The diagnostic likelihood ratio was 16.61 (95%CI 5.52–50.03) [74]. The common parameter used to determine FI was maximal resting pressure [74]. Recent technology of high-definition manometry (HDM) may be able to predict the possibility and to distinguish subjects with FI from healthy subjects [58]. However, further studies are required.

Parameters (mean ± 95%CI)	Male	Female	Total
HPZ rest (cm)	2.4 ± 0.4	2.2 ± 0.2	2.3 ± 0.2
HPZ squeeze (cm)	2.9 ± 0.4	2.8 ± 0.3	2.9 ± 0.3
Resting sphincter pressure (mmHg)	65.3 ± 15.2	58.5 ± 8.3	64.3 ± 8.3
Sustained squeeze pressure (mmHg)	126.9 ± 25.9	102.8 ± 10.3	121.3 ± 14.0
Maximal squeeze pressure (mmHg)	205.8 ± 43.2	169.1 ± 19.1	203.5 ± 23.1
Duration of squeeze (s)	31.8 ± 3.6	29.4 ± 3.1	31.1 ± 2.3
Rectal sensory testing			
Mean first sensation (ml)	15.0 ± 4.3	13.9 ± 3.1	15.1 ± 2.7
Volume at desire to defecate (ml)	35.8 ± 9.5	36.5 ± 6.0	38.7 ± 5.7
Volume at urge to defecate (ml)	61.7 ± 13.8	60.0 ± 8.0	63.8 ± 8.0
Volume at maximal toleration (ml)	120.0 ± 34.1	103.2 ± 16.4	119.1 ± 18.7
Saline continence test			
Saline volume retained (ml)	655.8 ± 72.6	633.2 ± 56.7	638.0 ± 46.0
Mean %volume retained (ml)	90.8 ± 9.3	88.3 ± 7.4	90.0 ± 5.9
Volume at first leak (ml)	313.0 ± 76.4	263.6 ± 52.3	283.1 ± 43.5
Median volume at first leak (ml)	325	280	280
Median retained volume (ml)	750	750	750
Mean % retained volume	100	100	100

**Author's unpublished data.*

Table 3.
*Normative anorectal manometric data.**

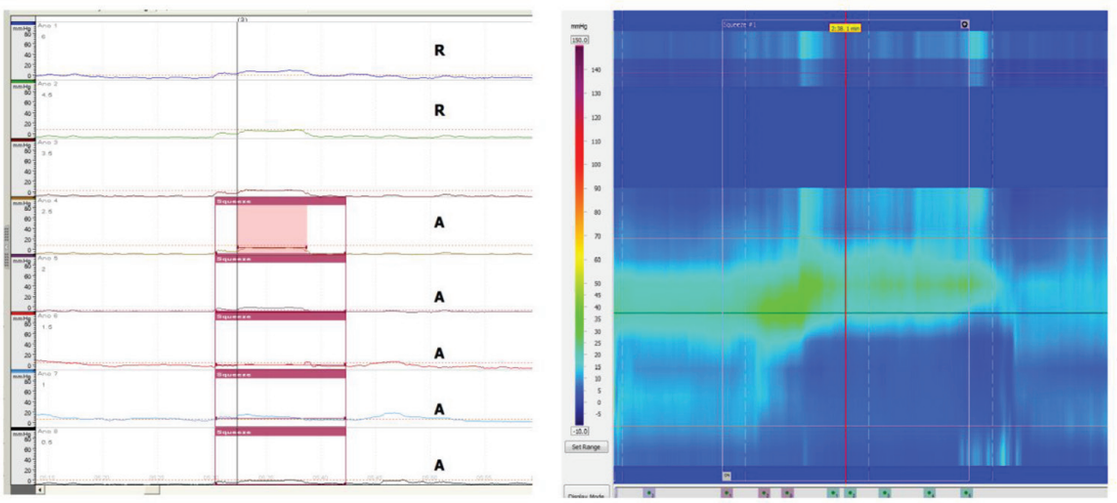

Left: water-perfusion manometric appearance during squeeze; minimal rise in anal sphincter pressure is observed. R-intrarectal pressure, A-intraanal pressure

Right: high-resolution manometric appearance during squeeze; minimal rise of in anal sphincter pressure is observed (note the color reference)

Figure 3.
Anorectal manometric findings in subjects with fecal incontinence during squeeze captured by different techniques; water-perfusion system on the left and high-resolution manometry on the right.

Adjunctive test in FI is the ***saline continence test***, which is performed by infusing 800 ml of 0.9% sodium chloride into the patient's rectum while sitting on a commode at a rate of 60 ml/min [55]. Volume infused at the onset of first leak was about

770 (735–805) ml in male and 530 ml in female (410–650) [68]. The total volume that a male could retain was about 790 (770–810) ml and for a female was 670 (620–750) ml [68]. Subjects with FI had significantly lower volume infused at first leak and total volume retained compared to healthy volunteers [75].

Electromyography (EMG) performed by inserting a needle electrode in the external anal sphincter muscle and levator ani muscle had been used to assess integrity of neuromuscular connection of the muscle [76]. Due to invasiveness, surface EMG had also been used [77]. However, the detection of the EAS defect has been replaced by other imaging techniques such as EAUS and MRI [78], and EMG could not predict the response to biofeedback therapy in FI [79].

Pudendal nerve terminal motor latency test (PNTML) assesses the neuromuscular circuit between the terminal branch of the pudendal nerve and the external anal sphincter by measuring the conduction time between the initial stimulation and the EAS contraction (seen by motor evoked potential curve). Prolonged latency time suggests pudendal neuropathy [76]. However, the test is not sensitive enough to be related with clinical symptoms, manometric findings, and histologic findings [76, 80]. This is because a single intact nerve fiber in a FI patient can give the normal latency time. Thus, it is not routinely recommended [45]. However, in clinical practice, it can be used in conjunction with anorectal manometry and endoanal ultrasound to provide the "missing link" [81] or the possible explanation of underlying pathophysiology of FI in the patient. **Figure 4** demonstrates the abnormal PNTML in a FI patient compared to a normal subject.

Novel neurophysiological investigations can be used to assess the spino-anorectal neuropathy with higher sensitivity. These include ***translumbar and trassacral magnetic neurostimulation*** (***TLMS, TSMS***), which induce motor evoked potential in the anal and rectal areas by using magnetic stimulation at the lumbar and sacral levels [82]. The magnetic stimulation induces the electrical current in the lumbosacral motor nerve roots and then the conduct along the peripheral nerves. The test could detect more anorectal neuropathy than PNTML, is well-tolerated, and can be used to assess the lumbosacral neuropathy in spinal cord injury subjects with anorectal problems [83]. Underlying pathophysiology of fecal incontinence which involves brain-gut axis connection can be tested bi-directionally [84]. For testing efferent pathways, cortical stimulation using transcranial magnetic stimulation over the paramedian motor cortex can be performed [84] and motor-evoked potentials are registered intraluminal at the rectum and anal canal levels. The test has been validated for reproducibility and good interobserver agreement [84]. In one study where both cortico-anorectal and spino-anorectal magnetic stimulations were performed, the peripheral spino-anal and spino-rectal neuropathy was identified to

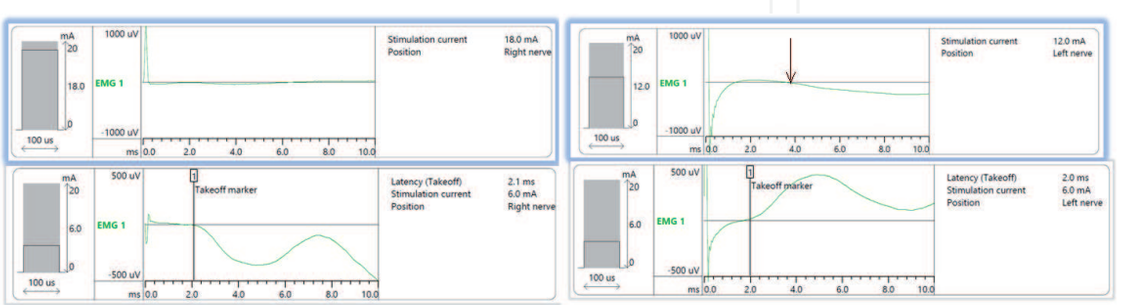

Pudendal Nerve Terminal Motor Latency of subjects with fecal incontinence (upper, blue border) and healthy subjects (lower). In normal subjects latency time was <2.2 msec and in subjects with fecal incontinence the motor evoked potential is not seen on the right and seen with lower amplitude on the left with latency time of about 4.0 msec (arrow)

Figure 4.
Pudendal nerve terminal motor latency testing.

have a possible role in the pathogenesis of FI [85]. For afferent pathways, the cortical sensory perception of anal and rectal stimulation can be detected for cortical evoked potentials (CEPs) using the scalp electrodes [84]. After rectal balloon distension, the prolonged CEP latency was seen in subjects with idiopathic FI [86] suggesting afferent dysfunctions [86]. Brain response to rectal distension can also be detected by functional MRI [28]. Preliminary findings suggested that central cerebral processing of rectal and anal stimuli plays a role in the pathogenesis of FI [29, 86].

3.4 Clinical utility of anorectal anatomical and neurophysiologic tests

FI usually has multiple etiologies including structural and functional defects. Endoanal ultrasound is strongly recommended to detect anal sphincter defects in patients with FI [44, 45]. Three-dimensional ultrasonography is useful to document anal sphincter defects, levator ani muscle avulsion, and tears [44]. Anorectal physiologic tests are used to confirm the diagnosis of FI, to grade the severity, and to determine the underlying pathophysiology. Thus, appropriate management can be planned accordingly. Anorectal manometry provides the baseline resting function of anal sphincter and squeeze function during voluntary contraction. Subjects with FI had shorter high-pressure zone, lower resting, and lower squeeze pressure than normal healthy subjects [75]. In subjects with dyssynergic defecation with overflow continence, the dyssynergic defecation pattern can also be demonstrated [66]. Abnormal anorectal reflex can be demonstrated together with rectal sensation. This information can guide in the biofeedback treatment and planning additional investigation or treatment.

The EMG technique is used to define an underlying neuromuscular dysfunction in selected cases. It is recommended for specialist use in the research study but not in routine clinical practice [28]. PNTML may be useful for assessment of FI especially when considering surgical intervention [28]. The test should be carefully performed and interpreted with caution in conjunction with other investigation results. Other neurophysiologic tests including motor evoked potential after lumbosacral (TLMS, TSMS) and cortical stimulation (TMS) are used to study the efferent brain-gut axis pathways, whereas cortical evoked potential after anorectal stimulation is used to study afferent brain-gut pathways. Functional MRI is a research tool to examine the brain-gut interaction and has not been tested for clinical use [28].

4. Conclusion

Fecal incontinence is a distressing condition of multifactorial etiologies. Detailed clinical evaluation together with selective use of anatomical and neurophysiologic testing is useful for clarification of the underlying pathophysiology. Recent change in bowel habit or stool characters should prompt the attention to rule out secondary FI from organic causes, such as colorectal cancer and inflammatory bowel disease. Severity and quality of life should be assessed. Clinical examination can detect gross, but not minor, defects. 3D-EAUS is recommended to objectively verify anal sphincter integrity. However, anal sphincter scar is better detected with MRI. Dynamic MRI can demonstrate concomitant pelvic floor disorders. TPUS is an alternative to EAUS and dynamic MRI but the accuracy is dependent on the operator's experience. ARM-quantified anal sphincter function measures rectal sensation and compliance. The saline continence test quantifies the severity of FI. EMG has limited clinical utilities and had been replaced by EAUS in detecting the anal sphincter defect. PNTML is insensitive to detect minor neuropathy. TLMS and TSMS are more sensitive to assess the spino-anorectal efferent pathways and TMS assesses the cortico-anorectal efferent pathway. CEP and functional MRI are used

to assess the anorectal-cortical afferent pathways. The latter tests for brain-gut-axis are mostly performed in the tertiary specialized institutes. By integration of the patient's all information, management can be planned accordingly. Further study regarding brain-gut-microbiota interaction is continuing for a better understanding of this group of patients.

Conflict of interest

The author has no conflict of interest.

Abbreviations

FI	fecal incontinence
IAS	internal anal sphincter
EAS	external anal sphincter
RAIR	rectoanal inhibitory reflex
CNS	central nervous system
DRE	digital rectal examination
PPV	positive predictive value
NPV	negative predictive value
EAUS	endoanal ultrasound
TPUS	transperineal ultrasound
MRI	magnetic resonance imaging
ARM	anorectal manometry
HRM	high-resolution manometry
CI	confidence interval
HDM	high-definition manometry
EMG	electromyography
PNTML	pudendal nerve terminal motor latency
TLMS	translumbar magnetic stimulation
TSMS	transsacral magnetic stimulation
CEP	cortical evoked potentials
TMS	transcranial magnetic stimulation

Author details

Kasaya Tantiphlachiva
Department of Surgery, Faculty of Medicine, Chulalongkorn University, Bangkok, Thailand

*Address all correspondence to: kasaya.tan@gmail.com

IntechOpen

© 2019 The Author(s). Licensee IntechOpen. This chapter is distributed under the terms of the Creative Commons Attribution License (http://creativecommons.org/licenses/by/3.0), which permits unrestricted use, distribution, and reproduction in any medium, provided the original work is properly cited.

References

[1] Rao SS, Bharucha AE, Chiarioni G, Felt-Bersma R, Knowles C, Malcolm A, et al. Anorectal disorders. Gastroenterology. 2016;**150**:1430-1442

[2] Bedard K, Heyman S, Palsson OS, Bharucha AE, Whitehead WE. Relationship between symptoms and quality of life in fecal incontinence. Neurogastroenterology and Motility. 2018;**30**:313241

[3] McKenna C, Bartlett L, Ho YH. Fecal incontinence reduces quality of life more than you may think. Diseases of the Colon and Rectum. 2017;**60**:e597-e598

[4] Xu X, Menees SB, Zochowski M, Fenner DE. Economic cost of fecal incontinence. Diseases of the Colon and Rectum. 2012;**55**:586-598

[5] Finne-Soveri H, Sørbye LW, Jonsson PV, Carpenter GI, Bernabei R. Increased work-load associated with faecal incontinence among home care patients in 11 European countries. European Journal of Public Health. 2008;**18**:323-328

[6] Macmillan AK, Merrie AE, Marshall RJ, Parry BR. The prevalence of fecal incontinence in community-dwelling adults: A systematic review of the literature. Diseases of the Colon and Rectum. 2004;**47**:1341-1349

[7] Ng KS, Sivakumaran Y, Nassar N, Gladman MA. Fecal incontinence: Community prevalence and associated factors—A systematic review. Diseases of the Colon and Rectum. 2015;**58**:1194-1209

[8] Walter S, Hallbook O, Gotthard R, Bergmark M, Sjodahl R. A population-based study on bowel habits in Swedish community: Prevalence of faecal incontinence and constipation. Scandinavian Journal of Gastroenterology. 2002;**37**:911-916

[9] Demir N, Yuruyen M, Atay K, Yavuzer H, Hatemi I, Doventas A, et al. Prevalence of fecal incontinence and associated risk factors in elderly outpatients: A cross-sectional study. Aging Clinical and Experimental Research. 2017;**29**:1165-1171

[10] Kang HW, Jung HK, Kwon KJ, Song EM, Choi JY, Kim SE, et al. Prevalence and predictive factors of fecal continence. Journal of Neurogastroenterology and Motility. 2012;**18**:86-93

[11] Borrie MJ, Davidson HA. Incontinence in institutions: Costs and contributing factors. Canadian Medical Association Journal. 1992;**147**:322-328

[12] Ihnat P, Kozakova R, Rudinska LI, Peteja M, Vavra P, Zonca P. Fecal incontinence among nursing home residents: Is it still a problem? Archives of Gerontology and Geriatrics. 2016;**65**:79-84

[13] Townsend DC, Carrington EV, Grssi U, Burgell RE, Wong JY, Knowles CH, et al. Pathophysiology of fecal incontinence differs between men and women: A case-matches study in 200 patients. Neurogastroenterology and Motility. 2016;**28**:1580-1588

[14] Guise JM, Morris C, Osterweil P, Li H, Rosenberg D, Greenlick M. Incidence of fecal incontinence after childbirth. Obstetrics and Gynecology. 2007;**109**:281-288

[15] Guillaume A, Salem AE, Garcia P, Chander Roland B. Pathophysiology and therapeutic options for fecal incontinence. Journal of Clinical Gastroenterology. 2017;**51**:324-330

[16] Barucha AE, Blandon RE. Anatomy and physiology of continence. In: Ratto C, Doglietto G, editors. Fecal Incontinence: Diagnosis and Treatment. Milan: Springer; 2007. pp. 3-12

[17] Karpathiotakis M. Pelvic floor anatomy. In: Mongardini M, Giofre M, editors. Management of Fecal Incontinence. Rome: Springer Nature; 2016. pp. 1-9

[18] Kumar L, Emmanuel A. Internal anal sphincter: Clinical perspective. The Surgeon. 2017;**14**:211-226

[19] Nivatvongs S, Gordon PH, Beck D. Surgical anatomy of the colon, rectum and anus. In: Beck D, Wexner S, Rafferty JF, editors. Gordon and Nivatvongs' Principles and Practice of Surgery for the Colon, Rectum and Anus. New York, USA: Thieme Verlagsgruppe; 2019. pp. 1-25

[20] Shafik A. A concept of the anatomy of the anal sphincter mechanism and the physiology of defecation. Diseases of the Colon and Rectum. 1987;**50**:970-982

[21] Gagnard C, Godlewski G, Prat D, Lan O, Cousineau J, Maklouf Y. The nerve branches to the external anal sphincter: The macroscopic supply and microscopic structure. Surgical and Radiologic Anatomy. 1986;**8**:115-119

[22] Yu SW, Rao SS. Anorectal physiologic and pathophysiology in the elderly. Clinics in Geriatric Medicine. 2014;**30**:95-106

[23] Azpiroz F, Fernandez-Fraga X, Merletti R, Enck P. The puborectalis muscle. Neurogastroenterology and Motility. 2005;**17**(Suppl 1):68-72

[24] Bullard Dunn KM, Rothenberger DA. Colon, rectum, and anus. In: Brunicardi F, Andersen DK, Billiar TR, Dunn DL, Hunter JG, Matthews JB, Pollock RE, editors. Schwartz's Principles of Surgery, 10e. New York, NY: McGraw-Hill; 2015. Available from: http://accessmedicine.mhmedical.com.cuml1.md.chula.ac.th/content.aspx?bookid=980&sectionid=59610871 Accessed January 27, 2019

[25] Van Koughnett JA, da Silva G. Anorectal physiology and testing. Gastroenterology Clinics of North America. 2013;**42**:713-728

[26] Uher EM, Swash M. Sacral reflexes: Physiology and clinical application. Diseases of the Colon and Rectum. 1998;**41**:1165-1177

[27] Rao SS. American College of Gastroenterology Practice Parameters Committee. Diagnosis and management of fecal incontinence. The American Journal of Gastroenterology. 2004;**99**:1585-1604

[28] Remes-Troche JM. Neurophysiological testing in anorectal disorders. Expert Review of Gastroenterology & Hepatology. 2008;**2**:323-335

[29] Mirbagheri N, Hatton S, Ng KS, Lagopoulos J, Gladman MA. Brain responses to mechanical rectal stimulation in patients with faecal incontinence: An fMRI study. Colorectal Disease. 2017;**19**:917-926

[30] Lefaucheur JP. Excitability of the motor cortical representation of the external anal sphincter. Experimental Brain Research. 2005;**160**:268-272

[31] Sultan AH, Nugent K. Pathophysiology and nonsurgical treatment of anal incontinence. BJOG. 2004;**111**(Suppl 1):84-90

[32] Shin GH, Toto EL, Schey R. Pregnancy and postpartum bowel changes: Constipation and fecal incontinence. The American Journal of Gastroenterology. 2015;**110**:521-529

[33] Joris F, Hoesli I, Kind A, Ries JJ, Kavvdias T. Obstetrical and epidemiological factors influence the severity of anal incontinence after obstetric anal sphincter injury. BMC Pregnancy and Childbirth. 2019;**19**:94

[34] Cohan JN, Chou AB, Varma MG. Faecal incontinence in men referred for

specialty care: A cross-sectional study. Colorectal Disease. 2015;**17**:802-809

[35] Pucciani F. Post-surgical fecal incontinence. Updates in Surgery. 2018;**70**:477-484

[36] Ruiz NS, Kaiser AM. Fecal incontinence—Challenges and solutions. World Journal of Gastroenterology. 2017;**23**:11-24

[37] Loganathan A, Schloithe AC, Hutton J, Yeoh EK, Fraser R, Dinning PG, et al. Pudendal nerve injury in men with fecal incontinence after radiotherapy for prostate cancer. Acta Oncologica. 2015;**54**:882-888

[38] Schiano di Visconte M, Santoro GA, Cracco N, Sarzo G, Bellio G, Brunner M, et al. Effective of sacral nerve stimulation in fecal incontinence after multimodal oncologic treatment for pelvic malignancies: A multicenter study with 2-year follow-up. Techniques in Coloproctology. 2018;**22**:97-105

[39] Brochard C, Venara A, Bodere A, Ropert A, Bouguen G, Siproudhis L. Pathophysiology of fecal incontinence in obese patents: A prospective case-matched study of 201 patients. Neurogastroenterology and Motility. 2017;**29**:313051

[40] Ortiz H, De Miguel M, Ciga MA. Clinical assessment of the incontinent patient. In: Ratto C, Doglietto G, editors. Fecal Incontinence: Diagnosis and Treatment. Milan: Springer; 2007. pp. 89-93

[41] Alavi K, Chan S, Wise P, Kaiser AM, Sudan R, Bordeianou L. Fecal incontinence: Etiology, diagnosis and management. Journal of Gastrointestinal Surgery. 2015;**19**:1910-1921

[42] Vaizey CJ, Carapeti E, Cahill JA, Kamm MA. Prospective comparison of faecal incontinence grading systems. Gut. 1999;**44**:77-80

[43] Rusavy Z, Jansova M, Kalis V. Anal incontinence severity assessment tools used worldwide. International Journal of Gynaecology and Obstetrics. 2014;**126**:146-150

[44] Italian Society of Colorectal Surgery (SICCR), Pucciani F, Altomare DF, Dodi G, Falletto E, Frasson A, et al. Diagnosis and treatment of faecal incontinence: Consensus statement of the Italian Society of Colorectal Surgery and the Italian association of hospital gastroenterologists. Digestive and Liver Disease. 2015;**47**:628-645

[45] Paquette IM, Varma MG, Kaiser AM, Steele SR, Rafferty JF. The American Society of Colon and Rectal Surgeons' clinical practice guideline for the treatment of fecal incontinence. Diseases of the Colon and Rectum. 2015;**58**:623-636

[46] Rockwood TH, Church JM, Fleshman JW, Kane RL, Mavran- tonis C, Thorson AG, et al. Fecal incontinence quality of life scale: Quality of life instrument for patients with fecal incontinence. Diseases of the Colon and Rectum. 2000;**43**:9-17

[47] Tantiphlachiva K, Rao P, Attaluri A, Rao SSC. Digital rectal examination is a useful tool for identifying patients with dyssynergia. Clinical Gastroenterology and Hepatology. 2010;**8**:955-960

[48] Andromanakos NP, Filippou DK, Pinis SI, Kostakis AI. Anorectal incontinence: A challenge in diagnostic and therapeutic approach. European Journal of Gastroenterology & Hepatology. 2013;**25**:1247-1256

[49] Dobben AC, Terra MP, Deutekom M, Gerhards MF, Bijnen AB, Felt-Bersma RJ, et al. Anal inspection and digital rectal examination compared to anorectal physiology tests and endoanal ultrasonography in evaluating fecal incontinence. International Journal of Colorectal Disease. 2007;**22**:783-790

[50] Soh JS, Lee HJ, Jung KW, Yoon IJ, Koo HS, Seo SY, et al. The diagnostic value of a digital rectal examination compared with high-resolution anorectal manometry in patients with chronic constipation and fecal incontinence. The American Journal of Gastroenterology. 2015;**110**:1197-1204

[51] Rao SSC. Advances in diagnostic assessment of fecal incontinence and dyssynergic defecation. Clinical Gastroenterology and Hepatology. 2010;**8**:910-919

[52] Coura MM, Silva SM, Almeida RM, Forrest MC, Sousa JB. Is digital rectal exam reliable in grading anal sphincter defectas? Arquivos de Gastroenterologia. 2016;**53**:240-245

[53] Olson CH. Diagnostic testing for fecal incontinence. Clinics in Colon and Rectal Surgery. 2014;**27**:85-90

[54] Abdool Z, Sultan AH, Thakar R. Ultrasound imaging of the anal sphincter complex: A review. The British Journal of Radiology. 2012;**85**:865-875

[55] Stone DE, Quiroz LH. Ultrasound imaging of the pelvic floor. Obstetrics and Gynecology Clinics of North America. 2016;**43**:141-153

[56] Knowles AM, Knowles CH, Scott SM, Lunniss PJ. Effects of age and gender on three-dimensional endoanal ultrasonography measurements: Development of normal ranges. Techniques in Coloproctology. 2008;**12**:323-329

[57] Tantiphlachiva K, Sahakitrungruang C, Pattanaarun J, Rojanasakul A. Normative anatomy of the anal sphincter detected with 3D-endoanal ultrasonography. Asian Biomedicine. 2013;**7**:865-871

[58] Zifan A, Ledgerwooe-Lee M, Mittal RK. A predictive model to identify patients with fecal incontinence based on high-definition manometry. Clinical Gastroenterology and Hepatology. 2016;**14**:178-196

[59] Cazemier M, Terra MP, Stoker J, de Lange-de Klerk ES, Boeckxstaens GE, Mulder CJ, et al. Atrophy and defects detection of the external anal sphincter: Comparison between three-dimensional anal endosonography and endoanal magnetic resonance imaging. Diseases of the Colon and Rectum. 2006;**49**:20-27

[60] Terra MP, Beets-Tan RG, van der Hulst VP, Deutekom M, Dijkgraaf MG, Bossuyt PM, et al. MRI in evaluating atrophy of the external anal sphincter in patients with fecal incontinence. American Journal of Roentgenology. 2006;**187**:99109

[61] Bharucha AE, Rao SS. An update on anorectal disorders for gastroenterologists. Gastroenterology. 2014;**146**:37-45

[62] Carrington EV, Heinrich H, Knowles CH, Rao SS, Fox M, Scott SM. Methods of anorectal manometry vary widely in clinical practice: Results from an international survey. Neurogastroenterology and Motility. 2017;**29**:e13016. DOI: 10.1111/nmo.13016

[63] Rao SSC, Azpiroz F, Diamant N, Enck P, Tougass G, Wald A. Minimum standards of anorectal manometry. Neurogastroenterology and Motility. 2002;**14**:553-559

[64] Kang HR, Lee JE, Lee JS, Lee TH, Hong SJ, Kim JO, et al. Comparison of high-resolution anorectal manometry with water-perfused anorectal manometry. Journal of Neurogastroenterology and Motility. 2015;**21**:126-132

[65] Vitton V, Ben Hadj Amor W, Baumstarch K Grimaud JC, Bouvier M. Water-perfused manometry vs. three-dimensional high-resolution

manometry: A comparative study on a large patient population with anorectal disorders. Colorectal Disease. 2013;**15**:e726-e731. DOI: 10.1111/codi.12397

[66] Staller K. Role of anorectal manometry in clinical practice. Current Treatment Options in Gastroenterology. 2015;**13**:418-431

[67] Lee HR, Lim SB, Park JY. Anorectal manometric parameters are influenced by gender and age in subjects with normal bowel function. International Journal of Colorectal Disease. 2014;**29**:1393-1399

[68] Rao SS, Hatfield R, Soffer E, Rao S, Beaty J, Conklin JL. Manometric tests of anorectal function in healthy adults. The American Journal of Gastroenterology. 1999;**94**:773-783

[69] Burgell RE. Hyposensitivity SSMR. Journal of Neurogastroenterology and Motility. 2012;**18**:373-384

[70] Madbouly KM, Hussein AM. Temporary sacral nerve stimulation in patients with fecal incontinence owing to rectal hyposensitivity: A prospective, double-blind study. Surgery. 2015;**157**:56-63

[71] Kakodkar R, Gupta S, Nundy S. Low anterior resection with total mesorectal excision for rectal cancer: Functional assessment and factors affecting outcome. Colorectal Disease. 2006;**8**:650-656

[72] Thiruppathy K, Mason J, Akbari K, Raeburn A, Emmanuel A. Physiological study of the anorectal reflex in patients with functional anorectal and defecation disorders. Journal of Digestive Diseases. 2017;**18**:222-228

[73] Pehl C, Seidl H, Scalecio N, Gundling F, Schmidt T, Schepp W, et al. Accuracy of anorectal manometry in patients with fecal incontinence. Digestion. 2012;**86**:78-85

[74] Yeap ZH, SImillis C, Qiu S, Ramage L, Kontovounisios C, Tekkis P. Diagnostic accuracy of anorectal manometry for fecal incontinence: A meta-analysis. Acta Chirurgica Belgica. 2017;**117**:347-355

[75] Tantiphlachiva K, Pattana-arun J, Sahakitrungrueng C, Rojanasakul A. Comprehensive evaluation of fecal incontinence: A preliminary report of anatomical neurophysiology study. Journal of the Medical Association of Thailand. 2018;**101**(Suppl 4):S29-S37

[76] Kumar A, Rao SS. Diagnostic testing in fecal incontinence. Current Gastroenterology Reports. 2003;**5**:406-413

[77] Nowakowski M, Tomaszewski KA, Herman RM, Salowka J, Romaniszyn M, Rubinkiewicz M, et al. Developing a new electromyography-based algorithm to diagnose the etiology of fecal incontinence. International Journal of Colorectal Disease. 2014;**29**:747-754

[78] Dobben AC, Terra MP, Deutekom M, Bossuyt PM, Felt-Bersma RJ, Stoker J. Diagnostic Work-up for Faecal Incontinence in Daily Clinical Practice in the Netherlands

[79] Lacima G, Pera M, Gonzalez-Argente X, Torrents A, Valls-Sole J, Espuna-Pons M. Is electromyography a predictive test of patient response to biofeedback in the treatment of fecal incontinence? Neurourology and Urodynamics. 2016;**35**:390-394

[80] Osterberg A, Graf W, Eeg-Olofsson K, Hynninen P, Pahlman L. Results of neurophysiologic evaluation in fecal incontinence. Diseases of the Colon and Rectum. 2000;**43**:1256-1261

[81] Remes-Troche JM, Rao SSC. Neurophysiological testing in anorectal

disorders. Expert Rev Gasroenterol Hepatol. 2008;**2**:323-335

[82] Rao SSC, Coss-Adame E, Tantiphlachiva K, Attaluri A, Remes-Troche J. Translumbar and transsacral magnetic neuro-stimulation for the assessment of neuropathy in fecal incontinence. Diseases of the Colon and Rectum. 2014;**57**:645-652

[83] Tantiphlachiva K, Attaluri A, Valestin J, Yamada T, Rao SSC. Translumabar and transsacral motor-evoked potentials: A novel test for spino-anorectal neuropathy in spinal cord injury. The American Journal of Gastroenterology. 2011;**106**:907-914

[84] Remes-Troche JM, Tantiphlachiva K, Attaluri A, Valestin J, Yamada T, Hamdy S, et al. A bi-directional assessment of the human brain-anorectal axis. Neurogastroenterology and Motility. 2011;**23**:240-e118. DOI: 10.1111/j.1365-2982.2010.01619.x

[85] Xiang X, Patcharatrakul T, Sharma A, Parr R, Hamdy S, Rao SSO. Cortico-anorecatl, spino-anorectal, and cortico-spinal nerve conduction and locus of neuronal injury in patients with fecal incontinence. Clinical Gastroenterology and Hepatology. 2018. DOI: 10.1016/j.cgh.2018.09.007

[86] Haas S, Brock C, Krogh K, Gram M, Lundby L, Drewes AM, et al. Abnormal neuronal response to rectal and anal stimuli in patients with idiopathic fecal incontinence. Neurogastroenterology and Motility. 2015;**27**:954-962