

We are IntechOpen, the world's leading publisher of Open Access books Built by scientists, for scientists

6,900

Open access books available

186,000

International authors and editors

200M

Downloads

Our authors are among the

154

Countries delivered to

TOP 1%

most cited scientists

12.2%

Contributors from top 500 universities



WEB OF SCIENCE™

Selection of our books indexed in the Book Citation Index
in Web of Science™ Core Collection (BKCI)

Interested in publishing with us?
Contact book.department@intechopen.com

Numbers displayed above are based on latest data collected.
For more information visit www.intechopen.com



Introductory Chapter: The Multiple Etiologies of Preeclampsia

Nidhi Sharma

Preeclampsia is an “old” disease. “After more than a century of intensive research, preeclampsia and eclampsia remain an enigmatic set of conditions.”

Roberts JM, Cooper DW. Pathogenesis and genetics of preeclampsia. Lancet. 2001;357:53e6.

1. Introduction

Preeclampsia or “gestosis” or “toxemia of pregnancy” is any condition predisposing to eclampsia or convulsions during pregnancy. The word eclampsia is derived from a Greek word *eklampsis* meaning “lightening” or convulsions. Preeclampsia is speculated to be a heterogeneous group of disorders caused by multiple etiologies. Understanding the pathophysiology of this syndrome is important as different etiologies have different pathological mechanisms and different predictive markers. Though the defect could have arisen in the renin-angiotensin system, cardiovascular system, liver enzyme deficiency, coagulation cascade, oxidative stress, or placental bed, the clinical picture is usually oversimplified as the maternal syndrome of hypertension, edema, and proteinuria.

The third world countries will benefit from the provision of adequate antenatal care after these high-risk women are identified. In the developed world, however, the emphasis is on early detection and prevention of preeclampsia.

During pregnancy, the physiology of cardiovascular system, renin-angiotensin system, pancreas changes, different organ reserves are put to test. Understanding preeclampsia requires the understanding of physiology of pregnancy. The blood flow in multiple organs is increased (**Figure 1**). Numerous studies at the embryo-endometrial interphase have also suggested the association of impaired spiral artery remodeling in preeclampsia, but how exactly is the impaired remodeling mediated and what is the pathogenesis of maternal syndrome are still to be elucidated. Some clinical cases of maternal syndrome of preeclampsia also have normal placental histology, so all cases cannot be attributed to a primary placental defect.

Clinical, biochemical, and biophysical markers are used for prediction depending on the etiology of the maternal syndrome of preeclampsia in the pregnancy (**Figure 2a and b**). These biomarkers can specifically be used to diagnose the etiology of maternal syndrome as renal dysfunction (kallikrein-creatinine ratio, angiotensin sensitivity test), vascular resistance (uterine artery Doppler), coagulation disorders (platelet volume, fibronectin, prostacyclin, thromboxane), oxidative stress (lipid peroxidase, 8-isoprostane, antioxidants, anticardiolipin antibodies, homocysteine), vascular adaptation (placental growth factor, vascular endothelial growth factor, s-flut, sEng), and placental dysfunction and ischemia (placental CRH, CRH bp, activin, inhibin, hCG).

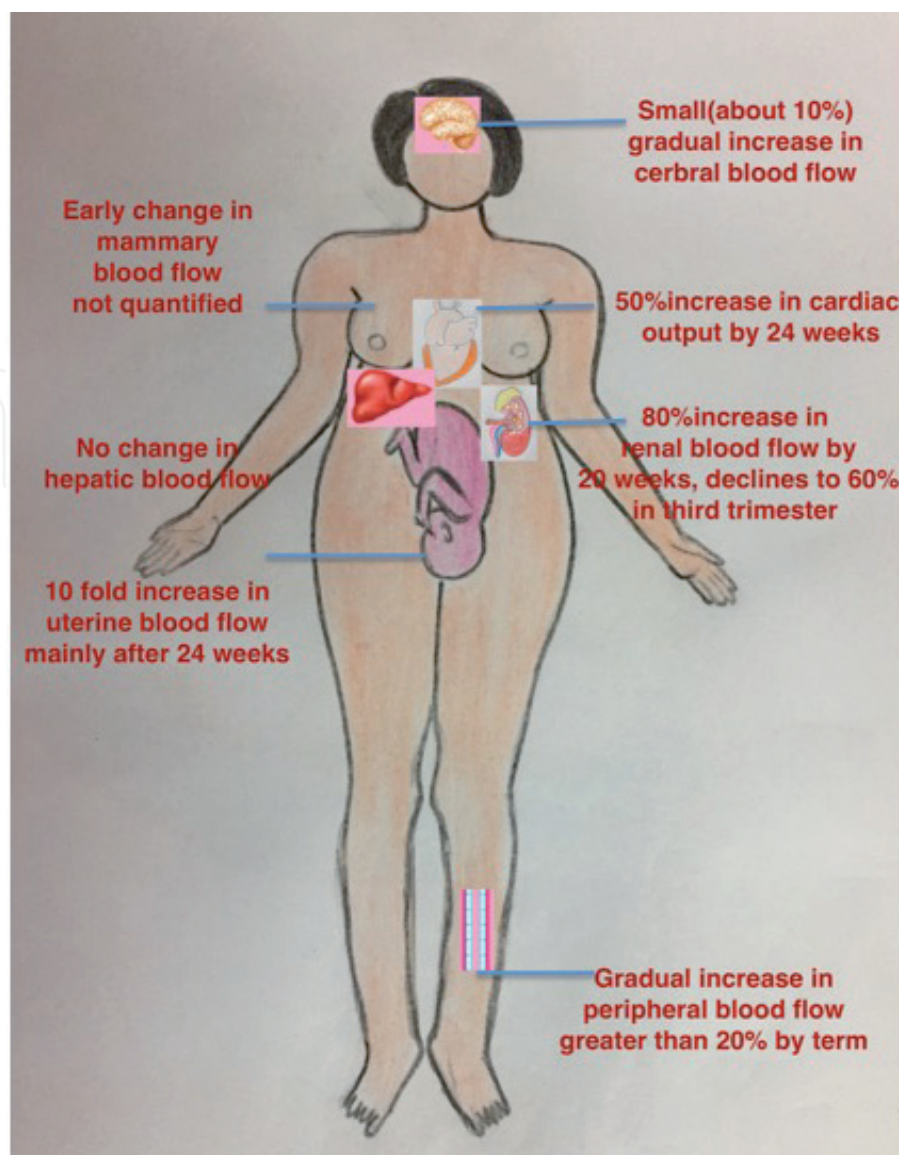


Figure 1.
The distribution of blood flow to maternal organs during pregnancy.

Atypical postpartum preeclampsia has an entirely different pathophysiology; it can be associated with the puerperal defects that prevent the excretion of sodium, puerperal diuresis. It can also be caused by an impaired shift of intravascular fluid into the extravascular compartment (atrial natriuretic peptide in the first week after delivery, natriuresis and inhibition of aldosterone, angiotensin II, vasopressin).

In this chapter the emphasis is on the preclinical pathophysiology of stage 1 of preeclampsia before the development of clinically evident stage 2 of hypertension, edema, and proteinuria.

There are two sides of fetal maternal interface, the maternal and the fetal. At the maternal side, the most important change is the remodeling of the spiral arterioles in the uterine endometrium and myometrium. The spiral arteries supply the intervillous space with blood in which there are floating fetal villi. Decidual veins drain the intervillous space.

At the fetal side, there is the development of fetal villi containing fetal capillaries. The fetal capillaries are covered by mesenchyme and cytotrophoblast. As the cytotrophoblast proliferates, it differentiates into the syncytiotrophoblast that covers the fetal villi. The cytotrophoblast also penetrates into the decidual stroma as interstitial trophoblast and also into maternal spiral arteries as endovascular trophoblast. The changes on both sides of fetomaternal interphase are described *vide infra*.

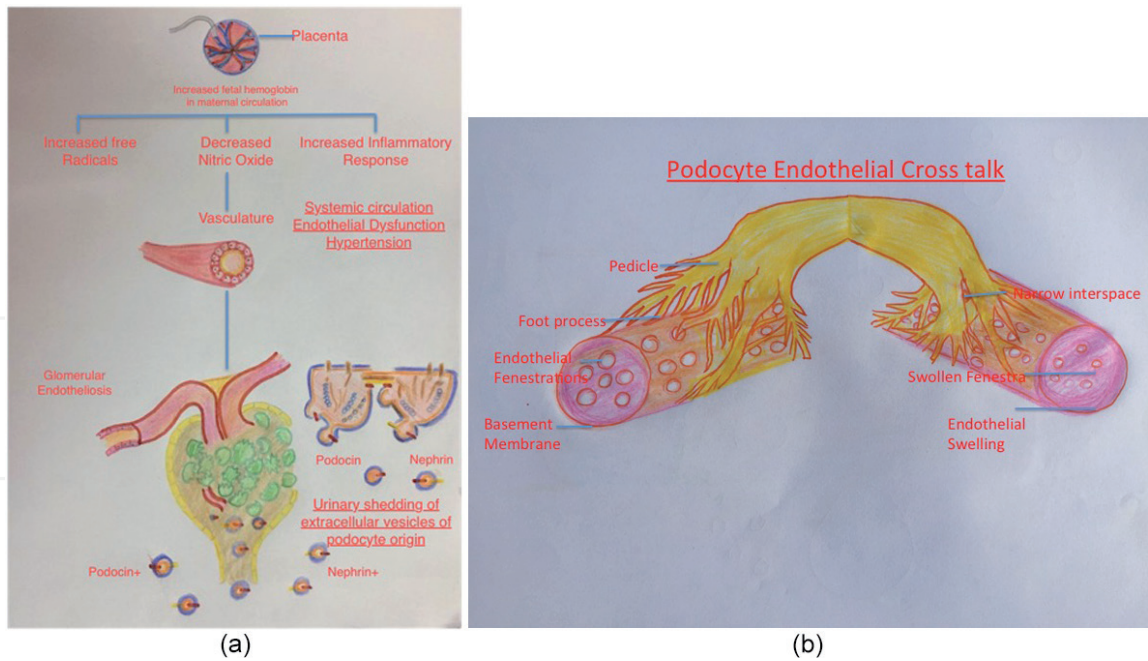


Figure 2.
(a) Maternal syndrome of edema, hypertension, and proteinuria, and (b) podocyte and endothelial relation in normal pregnancy and preeclampsia.

2. The maternal side of fetoplacental interface

In humans' and primates' placental bed, at the embryo-endometrial interface, the extravillous trophoblastic cells of fetal origin penetrate not only the endometrium but also the subendometrial or junctional zone (JZ) myometrium [1–3]. These fetal origin cells also penetrate the interstitium, block the spiral vessel wall, and finally actually get incorporated into the vessel walls resulting in wide channels ensuring constant slow velocity uninterrupted blood flow to the placental sinuses. The fetal tertiary stem villi bathe in these placental sinuses and are gently sprinkled over by maternal blood [4].

It was emphasized by Brosen et al. [5] that this “physiological transformation” of spiral arterioles at the fetomaternal interphase was a result of the phagocytotic action of rapidly dividing and migrating fetal trophoblast that proliferate on vascular smooth muscles and elastic membranes [6]. Some years later a maternal role in spiral arteriolar remodeling was discovered since a few changes in the maternal vessel wall like dilatation of arterioles, immunosuppression, and rheological changes in the vessel wall and uterine decidua actually happen before the antidromic migration and proliferation of fetal trophoblast along the maternal vessel lumen [7].

The four steps of spiral arteriolar remodeling are explained below [8]. In the first step, there is maternal decidua-associated remodeling independent of the trophoblast. Encircling sheaths of edematous decidual cells around the vessels (Streeter's column) appear as early as postovulatory day 11 [3]. These swollen perivascular cells are usually originated from vascular smooth muscles of spiral arterioles.

At 9 weeks of gestational age of the embryo, the maternal natural killer cells in the uterine decidua synthesize and secrete vascular endothelial growth factor (VEGF), placental growth factor (PLGF), and other angiopoietins [9, 10]. This results in vacuolation and disorganization of endothelial cells in the vascular lumen. In junctional zone or subendometrial myometrium, there are no immune-modified natural killer cells of pregnancy, and the penetrating interstitial trophoblast helps the release of VEGF and angiopoietins [9, 10]. This is concluded because the interstitial trophoblast enters the JZ a little later at 8 weeks.

After this there are actual trophoblastic proliferation and intra-arterial migration. Penetration can happen in the stroma (interstitial trophoblast) or inside the vessels (endovascular trophoblast). The endovascular course only takes place antidromically only in spiral arteries but not in veins (**Figure 3**).

The interstitial trophoblast subsequently fuses to form multinuclear giant cells, but endovascular trophoblast remains mononuclear and with phagocytosis tries to become a part of the vessel wall [11]. Though the multinuclear giant cells appear more evident on histology examination, it is the mononuclear cytotrophoblast that is more phagocytotic, and it proliferates widely the uterine endometrium and JZ myometrium within a short time (**Figure 4**). A large quantity of interstitial trophoblastic cells (basophilic mononuclear cells) proliferate in the extracellular space between the smooth muscles of the JZ myometrium. Trophoblast cells are distributed at the center at 8–14 weeks, and at 16–18 weeks, they are more migrated toward the periphery, thus following an enlarging ringlike pattern of centrifugal migration toward the periphery of the placental bed [12]. It is believed that as the trophoblastic cells fuse to form giant cells, they are gradually losing the ability for phagocytosis. During the transformation of the endometrium to decidua, there is a selective breakdown of extracellular matrix of stroma, and this occurs independent of fetal trophoblastic action.

The interstitial migration and proliferation of trophoblast into the decidua and JZ myometrium (extravascular trophoblast) precede the proliferation of trophoblast spiral arteries (endovascular trophoblast) by several weeks. The first thing the proliferating endovascular mononuclear trophoblast does is to plug the outlets of spiral arterioles at the fetomaternal interface and thus create a low-oxygen environment for the developing embryo. The embryo cannot tolerate a high oxygen tension. After 10 weeks the entire span of the spiral arteries in decidua contains trophoblast reaching even up to the superficial vascular JZ myometrium. Deep invasion of myometrial segments of the spiral arteries happens only after 15 weeks (the second wave of proliferation).

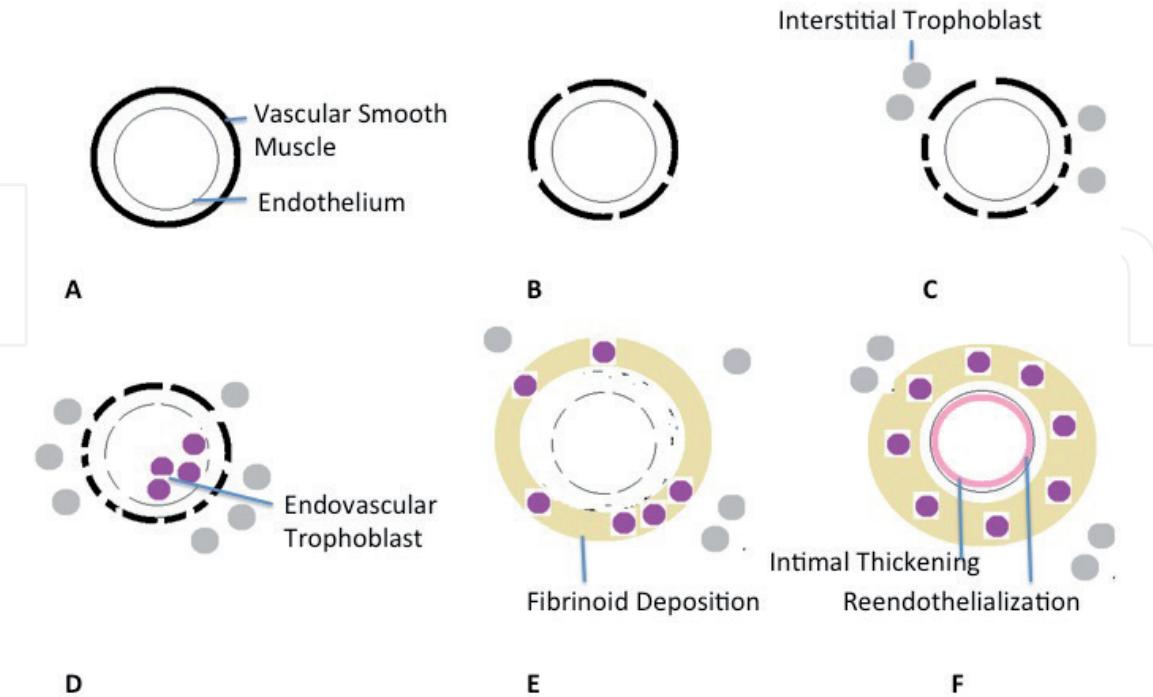
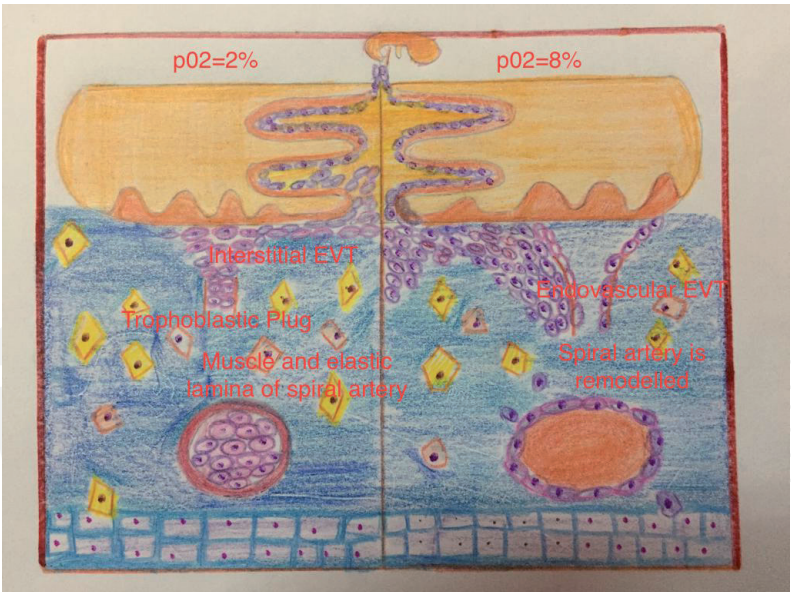
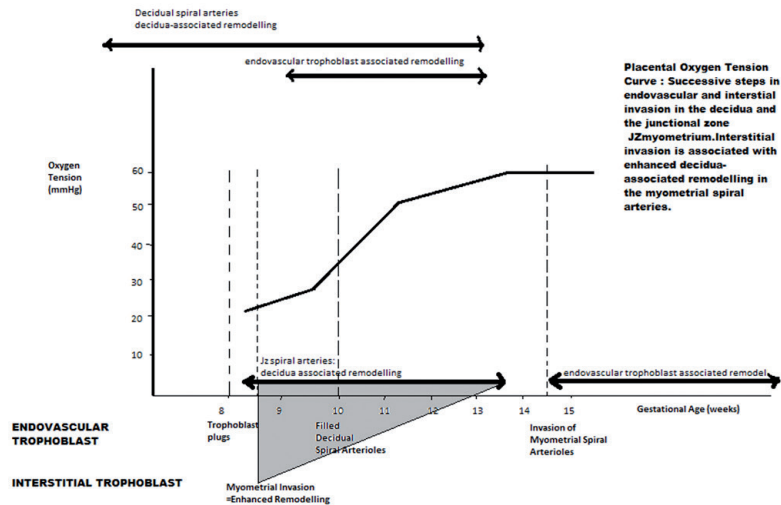


Figure 3. (A) Unmodified spiral artery showing endothelium and vascular smooth muscle, (B) Decidua associated remodeling with disorganization of vascular smooth muscles, (C) Interstitial Trophoblast migration enhances vascular smooth muscle disorganization, (D) Endovascular Trophoblast temporarily replaces to endothelium, (E) Intramural incorporation of endovascular trophoblast and deposition of fibrinoid, replacing the vascular smooth muscle, (F) Reendothelialisation and intimal thickening.



(a)



(b)

Figure 4.
(a) Placental oxygen tension curve, (b) trophoblastic penetration and placental oxygenation at 7–11 and 12–16 weeks.

The third step is called as trophoblast-induced remodeling when the trophoblast cells actually become a part of the arterial wall. This vascular incorporation happens when the fetal trophoblast actually penetrates the maternal endothelium. Electron micrography studies of maternal decidua have revealed that the trophoblast penetrates between the healthy endothelial cells and crosses the underlying basement membrane. The smooth muscle penetration results in replacement of maternal endothelial cells with trophoblast embedded within a fibroid matrix, probably secreted by the trophoblast itself. The intraluminal trophoblastic cells now incorporated into the vessel wall now assume a spiderlike shape because of increasing accumulation of fibrinoid materials around the cell processes. The intraluminal trophoblast always remains mono-nuclear or at the most becomes binuclear. This is opposite to the interstitial trophoblast.

The fourth step of re-endothelialization occurs when the maternal vascular lining is repaired by endothelial remnants, which were still present after the intramural invasion. A new endothelial covering may also be derived from circulating endothelial progenitor cells.

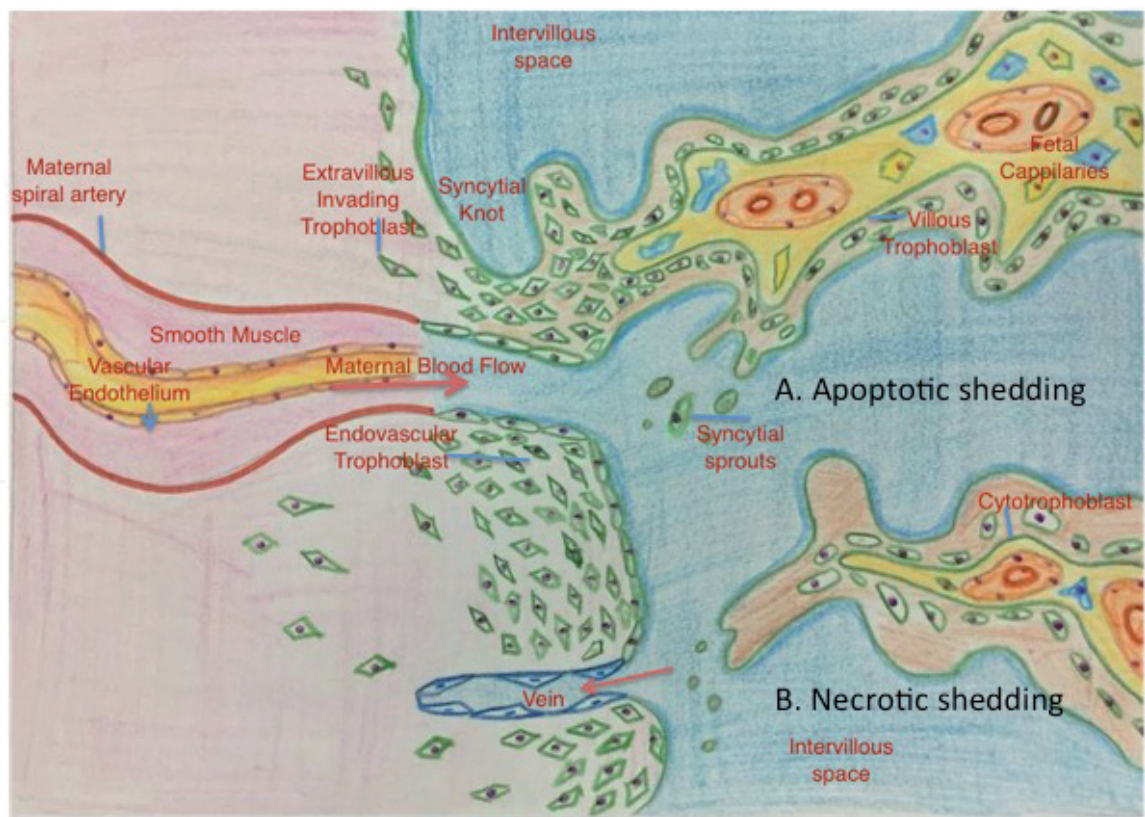


Figure 5.
(a) Syncytial apoptotic shedding in normal pregnancy, (b) trophoblastic penetration and proliferation in preeclampsia.

Investigations of Jauniaux have outlined the different times in gestation at which the decidual spiral arteries and junctional zone spiral arteries get remodeled in decidual association (step 1) and endovascular trophoblast association (step 2). Placental oxygenation increases as gestation advances (**Figure 4a** and **b**). There is no connection between the spiral arteries and the intervillous space at 7 weeks. And they appear at 8 weeks. Even before this communication, the decidual spiral arteries have remodeled (**Figure 5**). At 7–10 weeks, there is first wave of remodeling of decidual spiral arteries and early rise of intervillous flow. The second wave of remodeling, from 15 weeks onward, in which the endovascular trophoblast is observed in the junctional myometrium, is well after the steep rise in placental oxygenation. The decidua-associated spiral remodeling of the myometrium happens at 8–14 weeks, while trophoblastic-associated remodeling of the myometrium happens only after 15 weeks. The early decidua-associated remodeling of the junctional myometrium essentially prepares for the rise in uteroplacental flow, while the subsequent trophoblast-associated remodeling only stabilizes the vessel, and the increased flow is maintained.

2.1 Topology of vascular remodeling

A lateral gradient of diminished invasion has been seen at the periphery of the placental bed as compared to the center of the placental bed. Even in normal pregnancies, the junctional myometrium spiral arteries are remodeled only at the center, and there is an absence of junctional zone myometrial vascular remodeling at the periphery of the placental bed. In preeclampsia the trophoblast-associated remodeling is restricted to the decidual spiral arteries even in the center of the placental bed. One

High risk	Possible explanation	Prediction by	Clinical features
Teenage pregnancy, short interval of pregnancy since menarche, no prior intercourse, and primipaternity	Defective infiltration of decidua by natural killer cells, ligand receptor interaction of leukocyte populations	Maternal history	Maternal syndrome, proteinuria, hypertension, edema
Molar pregnancy	Failed trophoblastic migration and intersignal. Ineffective blocking of spiral vessels and oxidative stress and embryo-endometrial interphase	Early first trimester scan	
Chronic hypertension, high altitude pregnancy, increased maternal age, and diabetes	Impaired apoptosis of hyperplastic arterial smooth muscles of spiral arteries	Maternal history, insulin resistance, glucose intolerance	
Connective tissue disorders, SLE, APLA. Factor 2 and factor 5 Leiden mutations, serpin gene mutations, and protein C and protein S deficiencies	Impaired fibrin deposition by trophoblasts	APLA, ANA, protein essay and genetic screening	
Rh incompatibility, hyperhomocysteinemia	Exaggerated maternal healing tissue response	ABO incompatibility, Rh incompatibility screening	
Vascular resistance	Noncompliant maternal cardiovascular system	Uteroplacental artery flow waveforms, angiotensin II type 1 receptor agonistic antibodies	
Oxidant stress	Lipid peroxidase, 8-isoprostane, antioxidants, hypertriglyceridemia, hemoglobin, iron, transferrin, albumin isoforms	Serum levels, plasma and tissue expression of the long pentraxin 3	
Renal disease	Kallikrein-creatinine	Serum/urine levels	
Coagulation, fibrinolysis system, platelet activation, markers of vascular function	Platelet volume, fibronectin, prostacyclin, thromboxane	Serum levels	
Placental ischemia secondary to any of the above	Placental peptides, CRH, CRH bp, activin, inhibin, HCG	Ratio of angiogenic (placental growth factors, VEGF) and antiangiogenic factors (s-flut and s-endoglin)	

High risk	Possible explanation	Prediction by	Clinical features
Postpartum preeclampsia, inadequate mobilization of liquid from the interstitial and intravascular to extravascular space (6–8 L of the total body water, return of 950 mEq of total body sodium accumulated during pregnancy)	Factors affecting increased urinary sodium excretion between 3 and 5 days after birth (increase of atrial natriuretic peptide in the first week after delivery, natriuresis and inhibition of aldosterone, angiotensin II, vasopressin)	Central venous pressure and pulmonary capillary wedge pressures, colloid osmotic pressure, pulmonary crept, clinical congestive heart failure, cerebral edema	Postpartum convulsions due to posterior reversible encephalopathy syndrome—vasogenic edema in posterior brain due to lack of sympathetic modulation

Table 1.
Possible prediction of various subtypes of preeclampsia.

study demonstrated that even decidual segments might show incomplete remodeling. It is imperative that the placental bed biopsy should be taken from an adequately central space and not lateral. There are less interstitial giant cells in the myometrium and more stacked endometrial glands pushed by the placenta at the periphery of the placental bed.

2.2 Failure of remodeling

2.2.1 Failure of step 1: decidua-associated remodeling is defective

Late luteal phase secretory endometrium decidualization is associated with infiltration of natural killer cells, which are now considered to be major effector cells at trophoblast-uterine interphase interactions. It has also been postulated that repeated cycles of menstrual shedding of decidualizing endometrium may act as preconditioning for successful implantation and deep placentation [13]. This might explain the increased risk of preeclampsia in teenage pregnancy, short interval of pregnancy since menarche, and primipaternity. This may also explain the lowered risk of preeclampsia in women who have intercourse earlier with partner who fathers the current pregnancy. Recent research also suggests that natural killer cells’ associated defects of implantation are due to disturbed ligand receptor interphase. Uterine natural killer cells are absent in the JZ myometrium, but their angiogenic action is mediated by interstitial trophoblast.

2.2.2 Failure of step 2: failed trophoblastic migration

An impaired rise in blood flow, as a result of improper decidualization and improper angiogenesis, leads to a failed integrin shift and a failure of trophoblast to acquire an endothelial phenotype. Disturbed HLA-G expression by trophoblast has also been postulated. This might explain preeclampsia seen in association with molar pregnancy.

2.2.3 Failure of step 3: trophoblast-associated remodeling is defective

Impaired intramural incorporation of endovascular trophoblast and lack of fibrin deposition can be caused by impaired secretion of proteinases. This may be because of improper trophoblast signaling. This might explain the increased risk preeclampsia in connective tissue disorders, SLE, and APLA. The defective laying down of fibrin may explain the preeclampsia in cases of thrombophilia disorders like factor 2 and factor 5 Leiden mutations, serpin gene mutations,

and protein C and protein S deficiencies. This might also explain the association of preeclampsia with placenta accreta and increta where the Nitabuch's layer is absent. Chronic hypertension, renal disease, increased maternal age, and diabetes may lead to hyperplasia of smooth muscles of spiral arterial media; this may lead to impaired maintenance of elastin and vascular smooth muscles [14, 15]. When these conditions are present subclinically before pregnancy, the preexisting Tunica media hyperplasia might interfere with trophoblast-induced apoptosis of elastic smooth muscles.

2.2.4 Failure of step 4: increased maternal inflammatory response

Trophoblast proliferation and apoptosis of maternal intra-arterial smooth muscles invariable incites maternal tissue repair mechanisms, it is easy to understand that if maternal inflammation is marked the proliferating trophoblast may be destroyed by lipophages resulting in "acute atherosclerosis lesions" in the placental bed [16]. This might explain the occurrence of preeclampsia in Rh-incompatible pregnancies and hyperhomocysteinemia (**Table 1**).

3. The fetal side of fetoplacental interface

Syncytial sprouts arise from the syncytiotrophoblast that covers the cytotrophoblast around the fetal stem villi. In early pregnancy large aggregates of trophoblastic cells proliferate and extend into the intervillous space forming drumstick-like syncytial structures. Syncytial sprouts are multinucleated and have large ovoid nuclei with very little heterochromatin. There are a large number of ribosomes with abundant rough endoplasmic reticulum. Larger nuclei are present in the sprouts as compared to other parts of syncytiotrophoblast. True sprouts are produced from the mesenchyme villi and immature intermediate villi (**Figure 5**). There are continuous differentiation and proliferation of cytotrophoblast into syncytiotrophoblast into sprouts. This can be (a) sprout-like apoptotic shedding, (b) knots or Tenny-Parker changes, (c) wavelike apoptotic shedding, (d) arrested apoptotic shedding, (e) aponecrotic shedding, and (e) necrotic shedding.

3.1 Sprout-like apoptotic shedding

This is a normal phenomenon in which villous trophoblast proliferates and differentiates into cytotrophoblast. The cytotrophoblast fuses with the overlying syncytiotrophoblast, and finally the old and aging material is packaged into apoptotic syncytial sprouts and released into the maternal circulation. If apoptotic shedding is blocked, the number of nuclei in the syncytium increases. Since it is a membrane-sealed apoptotic material, it does not induce an inflammatory response. In the maternal lung, the syncytial sprouts get trapped and are phagocytosized by lung macrophages without inflammatory reaction. Approximately 3 g of apoptotically shed trophoblast is destroyed in the lungs daily. This is the balance of 3.6 g of cytotrophoblast that is converted to syncytiotrophoblast each day and 0.6 g that is retained in the syncytium [17, 18].

3.2 Tenny-Parker changes or syncytial knots

The terms syncytial sprouts and syncytial knots are different. True syncytial sprouts happen in first half of pregnancy when they represent early stages of large euchromatic nucleus. Tenny-Parker changes also called as syncytial knots are

bridges between the neighboring villi that look like drumstick or mushroomlike projections containing normally structured nuclei. These are artifacts caused by tangential sectioning of highly branched fetal villi.

3.3 Wavelike apoptotic shedding

In cases of placentas of fetal growth restricted with absent diastolic flow, there is a large decrease in the number of cytotrophoblastic cells, and the thickness of syncytiotrophoblast is also less [19]. The nuclei in syncytiotrophoblast accumulate like a ring around the vertical axis of villi. The underlying pathology is yet to be identified [17, 18].

3.4 Arrested apoptotic shedding

Apoptotic syncytial nuclei accumulate in knot-like structures but do not get extruded into the intervillous space. This is also seen in the cases of fetal growth restriction with absent diastolic flow. At some places the sites with nuclei are even larger than the cross section of villi from which they arise. It is seen that a large number of these giant knots form all over the placenta. In these cases the apoptotic cleavage of syncytial cytoskeleton may be defective [17, 18].

3.5 Aponecrotic shedding

Aponecrosis is a term used when signs of apoptotic trophoblast turnover and shedding are associated with signs of syncytial necrosis. Apoptosis continues with damaged plasma membranes, water influx and secondary hydropic changes of cellular structures, and release of cytoplasmic contents. This process is also called as secondary necrosis. Since apoptosis is a programmed cell death depending on cell energy, lack of cell energy reserves could be the cause of aponecrosis. These villous explants contain cell-free DNA, cell-free actin, and membrane-wrapped nuclei. In some studies in preeclampsia, the villous explants that had the packaged nuclei showed early signs of chromatin condensation, but the cytoplasm was edematous and plasma membrane had local defects.

3.6 Necrotic shedding

In pure necrotic shedding, the villous explants contain edematous nuclei in a hydropic cytoplasm with membrane defects. Placentas from severe preeclampsia and severe Rh incompatibility have shown features of necrotic shedding. The complete absence of chromatin condensation showed that the apoptotic pathway was blocked by inhibitory proteins and never restarted. In an experiment on pregnant guinea pigs, complete blockage of energy metabolism of trophoblast was done by monoiodine acetate or sodium fluoride (inhibitors of glycolysis). Continuous release of necrotic villous explants leads to the features of preeclampsia [17, 18].

If cytotrophoblast keeps growing and accumulating as syncytiotrophoblast and does not shed, it will lead to intrasyncytial accumulation of old and aged trophoblastic components which finally necrose. Cytoplasmic blebbing of syncytium with nuclear and cytoplasmic edema is a hallmark feature of necrotic shedding. Though there are phenotypic similarities among different types of villous explants, there are differences in modes of nuclear chromatin aggregation, nuclear or cytosolic edema. Cracks in the plasma membrane help to differentiate between physiological apoptotic shedding and pathological necrotic shedding.

4. Placenta as a casualty and not the cause

4.1 Liver pathology as a cause of preeclampsia

Preeclampsia is associated with three unique liver lesions described as liver lesions of preeclampsia, HELLP syndrome, and acute fatty liver of pregnancy. HELLP syndrome has classical periportal or focal parenchymal liver necrosis. There is thrombotic microangiopathy with resulting hemolysis and liver damage. Few cases of HELLP are associated with defects in beta-oxidation of fatty acids. There is microangiopathic hemolytic anemia with schistocytes, thrombocytopenia, and elevated levels of ALT/AST/LDH/bilirubin. HELLP may even develop postpartum, so the placenta is an unlikely cause of HELLP syndrome (**Figure 6**).

Acute fatty liver of pregnancy is due to defective oxidation of beta fatty acids. There is mitochondrial deficiency of long-chain 3-hydroxyacyl coenzyme A dehydrogenase in fetus. This leads to accumulation of 3-hydroxyacyl metabolites that are toxic to the liver. Half of the pregnancies with acute fatty liver of pregnancy develop preeclampsia (**Figure 7**).

4.2 Renin-angiotensin system as a cause of preeclampsia

The renin-angiotensin system (RAS) recognizes pregnancy very early. In the luteal phase of menstrual cycle, the RAS is activated under the influence of progesterone, and if pregnancy occurs, this RAS activation is maintained. This activation of RAS may be caused by progesterone that is natriuretic or it could be the “perceived under filling” of circulation by macula densa in early pregnancy. Juxtaglomerular apparatus synthesizes and releases renin, an aspartyl protease. Estrogen simultaneously binds to the promoter region of alpha-2 globulin angiotensinogen (AOGEN) and leads to the synthesis of angiotensinogen. Plasma

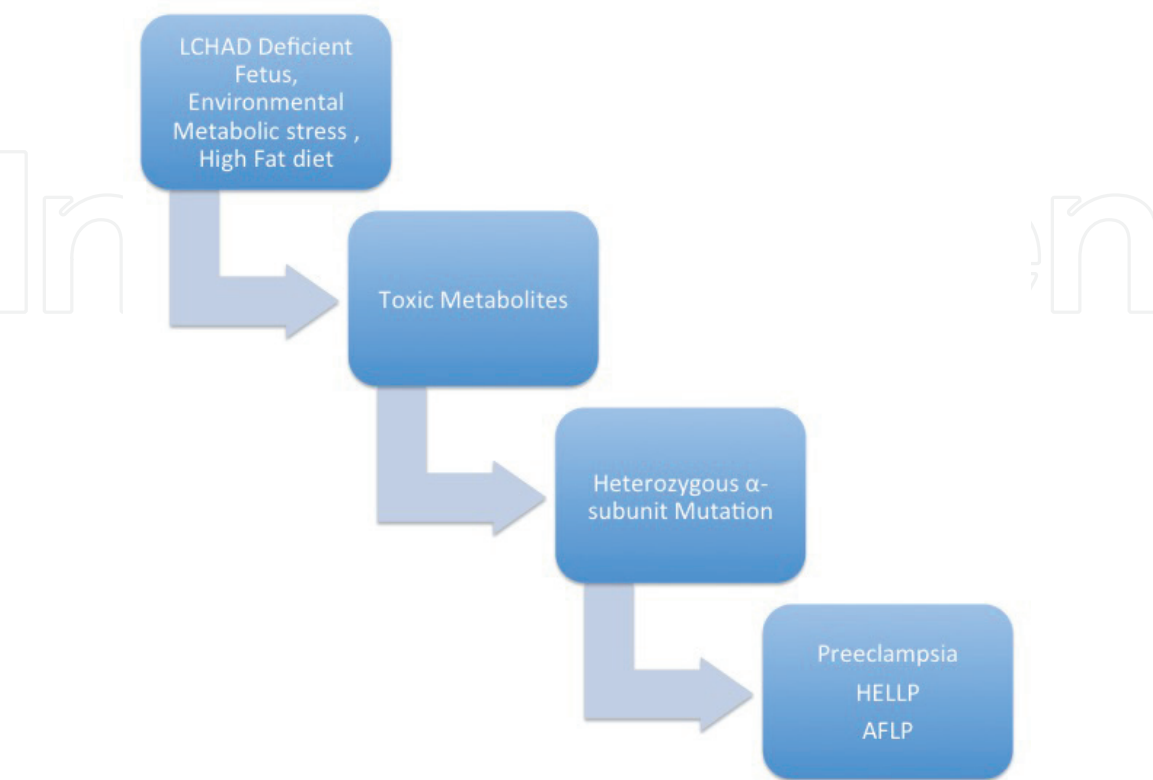


Figure 6.
Pathogenesis of preeclampsia in LACHD deficient fetus.

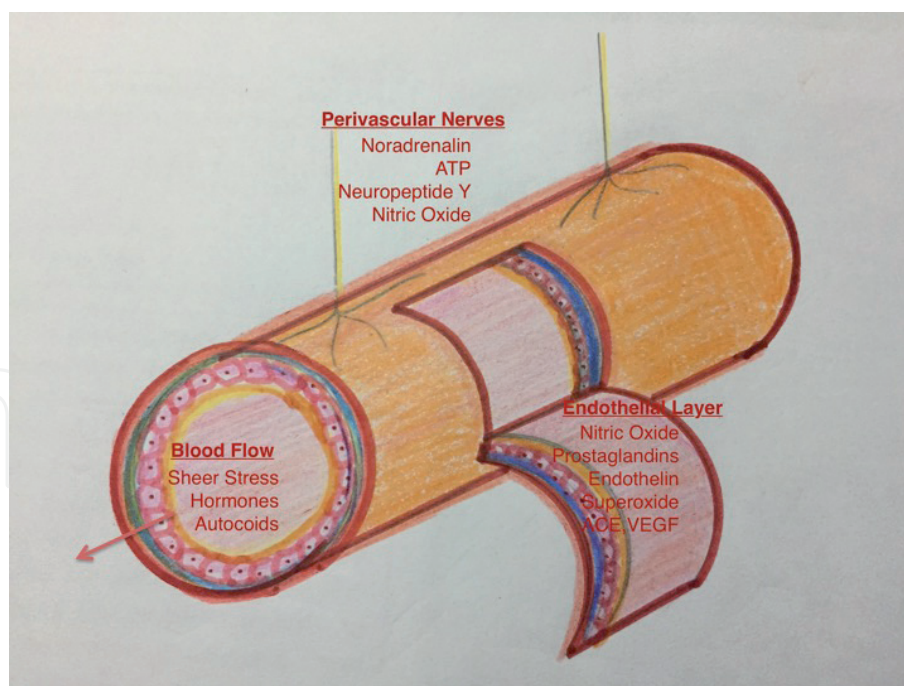


Figure 7.

Pathogenesis of preeclampsia in a nonresilient cardiovascular system. The autonomic nervous system, intrinsic smooth muscle reflexes, and the endothelium influence vascular tone.

angiotensin II (AGII) rises and leads to the synthesis and release of aldosterone from the zona glomerulosa in the adrenal cortex. The pregnant women do not develop hypertension from the presser effects of AGII due to the downregulation of ATR1 receptors. The vessel responsive to adrenal cortisol is usually unaltered in pregnancy [20, 21].

Angiotensin II is very peculiar because its action depends on which of its two receptors it is acting. When AGII binds with AGI receptors, it causes vasoconstriction, but when it binds to AGII receptors, it causes vasodilation. If angiotensin I receptors are downregulated during pregnancy or by angiotensin receptor blockers like telmisartan or if angiotensin II receptors are upregulated during fetal life, it is a vasodilator.

Villous syncytiotrophoblast has high density of angiotensinase A (aminopeptidase A) which converts angiotensin II to angiotensin III [22, 23]. The increase in this angiotensinase activity is also responsible for downregulation of ATR1 receptors in normal pregnancy [24]. It was observed that during cesarean section in normal pregnancy, the uterine venous AGII is lower than the peripheral venous AGII. In preeclampsia pregnancy, uterine venous AGII are higher than peripheral AGII level [25].

In prospective studies it has been demonstrated that aminopeptidase A levels were high before the clinical syndrome of preeclampsia but levels were lower after preeclampsia clinically developed [24]. The initial rise in trophoblastic aminopeptidase could be an initial homeostatic response protecting placenta from the harmful effects of locally generated AGII.

The receptor for angiotensin IV is also called as insulin-regulated aminopeptidase (IRAP). High concentrations of IRAP are present on human placenta [26]. In the second half of pregnancy, the extracellular domain of this receptor is shed off. Angiotensin IV acts as an endogenous inhibitor of angiotensin-converting enzyme. It stimulates both RNA and DNA synthesis in endothelial cells and proliferation of endothelial cells. It can also increase the levels of plasminogen activator inhibitor

mRNA. It is a vasodilator at least in cerebral vessels. These features are important because angiotensin IV can be involved in local apoptosis and remodeling.

4.3 Noncompliant cardiovascular system as a cause of preeclampsia

In preeclampsia there may be an impaired vasodilator response to endothelium-dependent agonists such as acetylcholine and bradykinin (**Figure 7**). Various adaptive mechanisms are employed at the fetomaternal interphase, and subsequently after 20 weeks, a clinically evident maternal syndrome of hypertension, edema, and proteinuria develops. The development of second stage of late vascular dysfunction can also happen independent of first stage. The uterine artery Doppler waveform becomes transformed into a high flow with low resistance at 22–24 weeks in normal gestation. However, in preeclampsia there is a latent preclinical stage with impaired intravascular volume expansion, hyperdynamic circulation, and a decreased cardiac output as clinical disease develops. This decreased cardiac output leads to renal and uteroplacental insufficiency. There may also be leaky capillaries leading to pulmonary and cerebral edema. Severe and early-onset preeclampsia has abnormal uterine artery waveform in preclinical stage and hypertension in clinical stage. Abnormal Doppler of uterine artery may be considered as a local noninvasive imaging of a more generalized systemic vasculopathy. This may mediate further cardiovascular risks. Women with preeclampsia are also two and a half times likely to die from ischemic heart disease in later life [27–29]. Several studies have been conducted showing preeclampsia association with the high pulsatility index of uterine artery.

Raised uterine artery impedance is a marker of early endothelial dysfunction. It is associated with increased aortic pulse wave velocity and augmentation index in the first trimester of pregnancy that is the marker of future cardiovascular risk [30–32]. Increased homocysteine levels have also been implicated in both cardiovascular risks and preeclampsia [33].

5. Conclusion

Preeclampsia is a heterogeneous disease. The late-onset preeclampsia at or near term has low fetal and maternal morbidity. But the early-onset preeclampsia (1%) of all preeclampsia has significant risks. Prediction of risks and identification of subclinical disease are mandatory. The majority of at-risk groups in multigravida are chronic hypertension, pregestational and gestational diabetes, age, and multiple fetuses, whereas in primigravida only 14% have these risks. If there is preeclampsia in a multigravida, a nonplacental cause should be definitely considered. This suggests that there are multiple underlying etiologies of different clinical presentations. **Table 1** summarizes the likely etiopathogenesis in different clinical scenarios. Postpartum eclampsia can be predicted and monitored with central venous pressure and pulmonary capillary wedge pressure [34–36]. The maternal syndrome (proteinuria, edema, and hypertension) also has differences in time of onset, severity, and organ system involvement as highlighted in several studies [37–39]. There is a rising interest in galectin molecules for prediction of these subtypes (**Figure 8**). These clinical subpopulations need to be identified and preeclampsia predicted with rigorous definition of different biomarkers of different clinical phenotypes [40–44]. The future endeavors should be to identify subclinical disease in various clinical phenotypes with these potential biomarkers in prospective longitudinal studies.

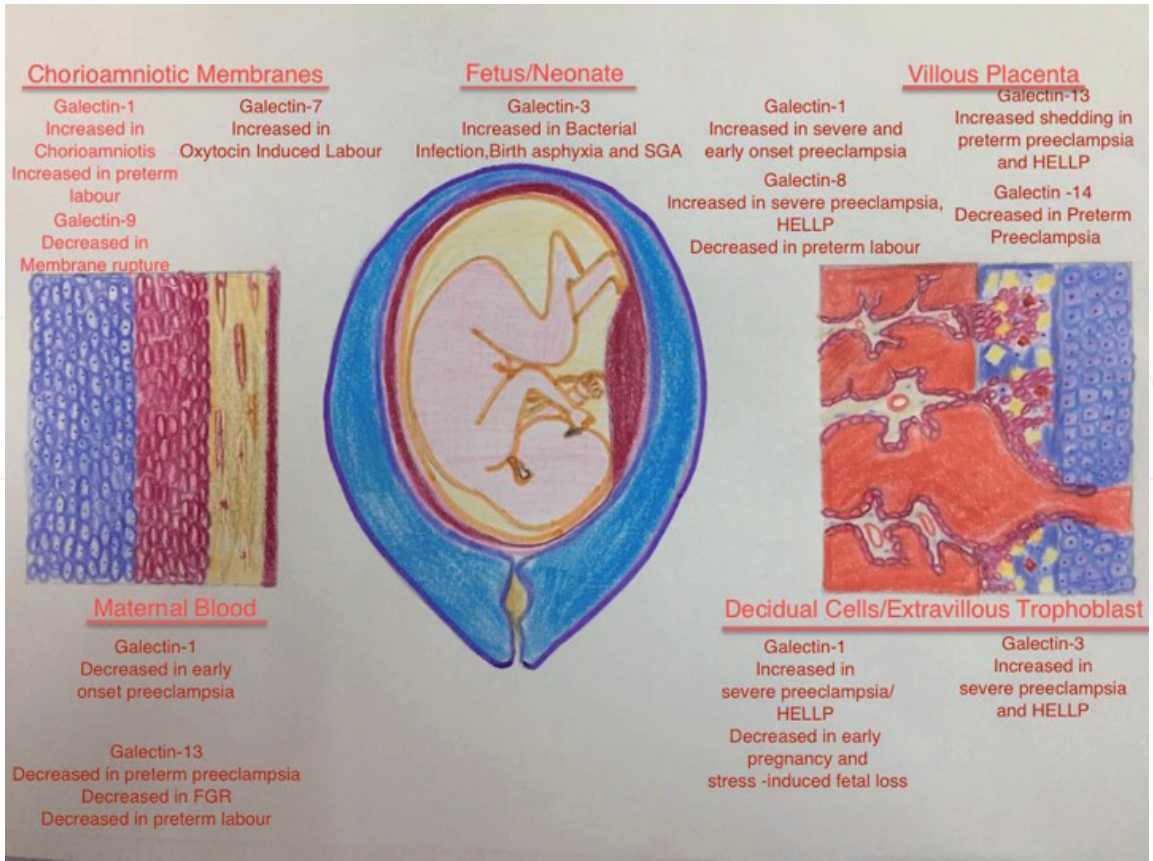


Figure 8.
Galectin subtypes and prediction of preeclampsia.

Author details

Nidhi Sharma
Saveetha University, Chennai, Tamil Nadu, India

*Address all correspondence to: drbonuramkumar@yahoo.co.in

IntechOpen

© 2019 The Author(s). Licensee IntechOpen. This chapter is distributed under the terms of the Creative Commons Attribution License (<http://creativecommons.org/licenses/by/3.0>), which permits unrestricted use, distribution, and reproduction in any medium, provided the original work is properly cited.



References

- [1] Hamilton WJ, Boyd JD. Development of the human placenta in the first three months of gestation. *Journal of Anatomy*. 1960;**94**:297-328
- [2] Hamilton WJ, Boyd JD. Trophoblast in human placental arteries. *Nature*. 1966;**212**:906-908
- [3] Harris JWS, Ramsey EM. The morphology of human uteroplacental vasculature. *Contributions to Embryology*. 1966;**38**:43-58
- [4] Kaufmann P, Black S, Huppertz B. Endovascular trophoblast invasion: Implications for the pathogenesis of intrauterine growth retardation and preeclampsia. *Biology of Reproduction*. 2003;**69**:1-7
- [5] Brosens I, Robertson WB, Dixon HG. The physiological response of the vessels of placental bed to normal pregnancy. *The Journal of Pathology and Bacteriology*. 1967;**93**:569-579
- [6] Pijnenborg R, Vercruysse L, Hanssens M. The uterine spiral arteries in human pregnancy: Facts and controversies. *Placenta*. 1998;**19**:241-252
- [7] Craven CM, Morgan T, Ward K. Decidual spiral artery remodeling begins before cellular interaction with cytotrophoblast. *Placenta*. 1998;**19**:241-252
- [8] Li XF, Charnock-Jones DS, Zhang E, Hiby S, Malik S, Day K, et al. Angiogenic growth factor messenger ribonucleic acids in uterine natural killer cells. *The Journal of Clinical Endocrinology and Metabolism*. 2001;**86**:1823-1834. PubMed PMID: 11297624
- [9] Brosens IA. Uteroplacental Vascular Pathology. *European Journal of Obstetrics, Gynecology, and Reproductive Biology*. 1975;**5**:47-65. Discussion
- [10] Pijnenborg R, Bland JM, Robertson WB, Brosens I. Uteroplacental arterial changes related to interstitial trophoblast migration in early human pregnancy. 1983;**4**:397-414
- [11] Bulmer JN, Lash GE. Human uterine natural killer cells: A reappraisal. *Molecular Immunology*. 2005;**42**:511-521
- [12] Schiessl B, Innes BA, Bulmer JN. Localization of angiogenic growth factors and their receptors in the human placental bed throughout normal human pregnancy. *Placenta*. 2009;**30**:79-87
- [13] Brosens JJ, Parker MG, McIndoe A, Pijnenborg R, Brosens IA. A role for menstruation in preconditioning the uterus for successful pregnancy. *American Journal of Obstetrics and Gynecology*. June 2009;**200**(6):615. e1-5
- [14] Sheppard BL, Bonnar J. An ultrastructural study of utero-placental spiral arteries in hypertensive and normotensive pregnancy and fetal growth retardation. *bjog: An International Journal of Obstetrics & Gynaecology*. 1981;**88**:695-705. DOI: 10.1111/j.1471-0528.1981.tb01268.x
- [15] Robertson WB, Khong TY, Brosens I. The placental bed biopsy: Review from three European centers. *American journal of obstetrics and gynaecology*. Vol. 159:401
- [16] Hanssens M, Pijnenborg R, Keire MJNC. Renin-like immunoreactivity in uterus and placenta from normotensive and hypertensive pregnancies. *European Journal of Obstetrics, Gynecology, and Reproductive Biology*. 1998;**81**:177-184
- [17] Pathology of the Human Placenta. 4th Edn. By Kurt Benirschke and Peter Kaufmann. New York: Springer-Verlag, 2000

- [18] Kaufmann P, Black S, Huppertz B. Endovascular trophoblast invasion: Implications for the pathogenesis of intrauterine growth retardation and preeclampsia. *Biology of Reproduction*. 2003;**69**(1):1-7. Epub 2003 Mar 5. Review. PubMed PMID: 12620937
- [19] Todros T, Sciarrone A, Piccoli E, Guiot C, Kaufman P, Kingdom J. Umbilical Doppler waveform and placental angiogenesis in pregnancy complicated by fetal growth restriction. *Obstetrics and Gynecology*. April 1999;**93**:499-503
- [20] Baker P, Broughton Pipkin F. AII receptor number and screening for PIH. *Clinical and Experimental Pharmacology & Physiology*. 1993;**20**(12):809-810. PubMed PMID: 8306522
- [21] Skinner SL, McCubbin JW, Page IH. Renal baroreceptor control of renin secretion. *Science*. 1963;**141**(3583):814-816. PubMed PMID: 14045137
- [22] Ino K, Uehara C, Kikkawa F, Kajiyama H, Shibata K, Suzuki T, et al. Enhancement of aminopeptidase A expression during angiotensin II-induced choriocarcinoma cell proliferation through AT1 receptor involving protein kinase C- and mitogen-activated protein kinase-dependent signaling pathway. *The Journal of Clinical Endocrinology and Metabolism*. 2003;**88**(8):3973-3982. PubMed PMID: 12915695
- [23] Johnson AR, Skidgel RA, Gafford JT, Erdös EG. Enzymes in placental microvilli: Angiotensin I converting enzyme, angiotensinase A, carboxypeptidase, and neutral endopeptidase ("enkephalinase"). *Peptides*. 1984;**5**(4):789-796. PubMed PMID:6093076
- [24] Mizutani S, Tomoda Y. Effects of placental proteases on maternal and fetal blood pressure in normal pregnancy and preeclampsia. *American Journal of Hypertension*. 1996;**9**(6):591-597. Review. PubMed PMID: 8783784
- [25] Broughton Pipkin F, Baker PN. Angiotensin II has depressor effects in pregnant and nonpregnant women. *Hypertension*. 1997;**30**:1247-1252
- [26] Albiston AL, McDowall SG, Matasacos D, et al. Evidence that angiotensin IV (AT4) receptor is enzyme insulin regulated aminopeptidase. *The Journal of Biological Chemistry*. 2001;**276**(48):623-626
- [27] Rich Edwards JW, Fraser A, Lawler DA, Catov JM. Pregnancy characteristics and women's future cardiovascular health: An underused opportunity to improve women's health? *Epidemiologic Reviews*. 2014;**36**:57-70
- [28] Fraser A, Nelson SM, Macdonald-Wallis C. Associations of pregnancy complications with calculated cardiovascular risk and cardiovascular risk factors in middle age: The Avon longitudinal study of parents and children. *Circulation*. 2012;**125**:1367-1380
- [29] Brown MC, Best K, Pearce MS, Waugh J, Robson SC, Bell R. Cardiovascular disease risk in women with preeclampsia: Systematic review and meta-analysis. *European Journal of Epidemiology*. 2013;**28**:1-19
- [30] Everett TR, Mahendru AA, McEniery CM, Wilkinson IB, Lees CC. Raised uterine artery impedance is associated with increased arterial stiffness in the late second trimester. *Placenta*. 2012;**33**:572-577. DOI: 10.1016/j.placenta.2012.04.001. Epub 2012 Apr 24. PMID: 22538229
- [31] Savvidou MD, Kaihura C, Anderson JM, Nicolaides KH. Maternal arterial stiffness in women who subsequently develop pre-eclampsia. *PLoS One*. 2011;**6**:e18703

- [32] Macedo ML, Luminoso D, Savvidou MD, McEniery CM, Nicolaides KH. Maternal wave reflections and arterial stiffness in normal pregnancy as assessed by applanation tonometry. *Hypertension*. 2008;**51**:1047-1051
- [33] Yu CKH, Lakasing L, Papageorghiou AT, Spencer K, Nicolaides KH. Uterine artery Doppler and mid-trimester maternal plasma homocysteine in subsequent pre-eclampsia. *The Journal of Maternal-Fetal and Neonatal Medicine*. **16**:2134-2139
- [34] Sanctos M. Evolução dos níveis pressóricos no puerpério em mulheres com pré-eclâmpsia grave atendidas em um hospital terciário: Estudo de coorte [dissertação]. Recife: Instituto de Medicina Integral Professor Fernando Figueira-IMIP; 2004
- [35] Pearson JF. Fluid balance in severe preeclampsia. *British Journal of Hospital Medicine*. 1992;**48**:47-45
- [36] Magee Laura, von Dadelszen Peter. Prevention and treatment of postpartum hypertension. *Cochrane Database of Systematic Reviews*. 30 April 2013:4CD004351. DOI: 10.1002/14651858.CD004351.pub3
- [37] Myatt L, Miodovnik M. Prediction of preeclampsia. *Seminars in Perinatology*. 1999;**23**(1):45-57
- [38] Roberts JM, Hubel CA. The two stage model of preeclampsia: Variations on the theme. *Placenta*. 2009;**30** (Suppl A):S32-S37. DOI: 10.1016/j.placenta.2008.11.009
- [39] Roberts J. Pre-eclampsia a two-stage disorder: What is the linkage? Are there directed fetal/placental signals? In: Lyall F, Belfort MA, editors. *Pre-eclampsia: Etiology and Clinical Practice*. New York: Cambridge University Press; 2007. pp. 183-194
- [40] Shibata E, Rajakumar A, Powers RW, Larkin RW, Gilmour C, Bodnar LM, et al. Soluble fms-like tyrosine kinase 1 is increased in preeclampsia but not in normotensive pregnancies with small-for-gestational-age neonates: Relationship to circulating placental growth factor. *The Journal of Clinical Endocrinology and Metabolism*. 2005;**90**:4895-4903
- [41] Walther T, Wallukat G, Jank A, Bartel S, Schultheiss HP, Faber R, et al. Angiotensin II type 1 receptor agonistic antibodies reflect fundamental alterations in the uteroplacental vasculature. *Hypertension*. 2005;**46**:1275-1279
- [42] Vatten LJ, Eskild A, Nilsen TIL, Jeansson S, Jenum PA, Staff AC. Changes in circulating level of angiogenic factors from the first to second trimester as predictors of preeclampsia. *American Journal of Obstetrics and Gynecology*. 2007;**196**:239.e1-239.e6
- [43] Rovere-Querini P, Antonacci S, Dell'Antonio G, Angeli A, Almirante G, Cin ED, et al. Plasma and tissue expression of the long pentraxin 3 during normal pregnancy and preeclampsia. *Obstetrics & Gynecology*. 2006;**108**:148-155
- [44] Ong CY, Liao AW, Spencer K, Munim S, Nicolaides KH. First trimester maternal serum free beta human chorionic gonadotrophin and pregnancy associated plasma protein A as predictors of pregnancy complications. *BJOG: An International Journal of Obstetrics & Gynaecology*. 2000;**107**:1265-1270