

We are IntechOpen, the world's leading publisher of Open Access books Built by scientists, for scientists

6,900

Open access books available

186,000

International authors and editors

200M

Downloads

Our authors are among the

154

Countries delivered to

TOP 1%

most cited scientists

12.2%

Contributors from top 500 universities



WEB OF SCIENCE™

Selection of our books indexed in the Book Citation Index
in Web of Science™ Core Collection (BKCI)

Interested in publishing with us?
Contact book.department@intechopen.com

Numbers displayed above are based on latest data collected.
For more information visit www.intechopen.com



Review on Ascites in Pets

Rosemary Ijeoma Ogechi Nwoha

Abstract

Ascites is one of the major complications seen in various disease conditions in pets. Ascites is characterised by distension of the abdomen with accumulation of fluid of various colours and consistencies depending on the cause. The most common causes of ascites in pets include but not limited to the following health conditions: hypoproteinaemia, left-sided heart failure, congestive heart failure, cirrhosis, hepatic diseases, renal diseases, ancylostomosis and bacterial infection such as tuberculosis. Pathogenesis of ascites often emanate from portal hypertension, cirrhosis, hepatorenal syndrome, etc. Oftentimes the diagnosis of ascites could be cumbersome considering the myriad of diseases implicated in the condition. Standard diagnostic procedures include the following: physical examination, clinical examination, ultrasonography, computed tomography, serum ascites albumin gradient (SAAG), biochemical analysis such as triglyceride, urea and creatinine concentration, total protein, etc. Novel diagnostic procedures with possible clinical relevance include the following: leucocyte esterase reagent strip, platelet indices, tumour markers, etc. Diagnosis is made through standard diagnostic procedure, while special cases of idiopathic origin are detected through diagnostic laparotomy. Novel diagnostic procedures such as platelet indices, leucocyte esterase reagent strip and tumour markers would aid in easy diagnosis of ascites. Treatment of ascites is dependent on identification of the cause of ascites.

Keywords: ascites, SAAG, hepatorenal syndrome, diuretics, portal hypertension, abdominocentesis, hepatic, cardiac, abdominal effusion, abdominal drops

1. Introduction

Ascites is a term used to describe the condition of accumulation of fluid in the peritoneal cavity. The word “ascites” could be used interchangeably with other terms such as abdominal dropsy, abdominal effusion, peritoneal fluid excess, hydroperitoneum and peritoneal cavity fluid. Ascites represents a form of general systemic state which could manifest in diverse disease conditions in animals. This implies that ascites is only a clinical manifestation of an underlying disease condition and not a disease in real sense. It further shows that ascites is not a treatable condition except the cause is properly diagnosed and treated accordingly. Ascites is often diagnosed in dogs between the ages of 5 and 7 years [1]. Cases between the ages of 1 and 4 years have also been recorded. The occurrence of ascites in dogs may be breed dependent with higher incidences in Pomeranian (33.35%) than in Labrador retriever (20%), Boxer (16.66%), Doberman pinscher (13.37%), mongrels (10%) and least in Alsatian (6.66%) [1]. Ascites manifests in several disease

conditions such as hepatic disease, various types of neoplasm, portal hypertension, alteration in serum protein level (hypoproteinaemia), right-sided heart failure, decreased plasma oncotic pressure and increased permeability of capillary endothelium sequel to inflammatory conditions, bacterial infection (tuberculosis), kidney malfunction, pre-hepatic portal hypertension, post-hepatic portal hypertension, trauma (rupture of lymphatic vessels, blood vessels, urinary bladder),

ancylostomosis peritonitis, bleeding disorders and malnutrition [2, 3]. Other conditions may include heartworm infection and pulmonary stenosis [4]. In general, cardiac and hepatic disease conditions ranked highest as the cause of ascites in pets. Other manifesting signs which usually signify an underlying disease condition in ascetic pets may include syncope, vomiting, obtundation, seizure, anaemia which manifests as pale mucous membrane, weakness and rapid panting. The identification and diagnosis of the cause of ascites may not be a straightforward procedure and could be complicated due to the several causative factors. The veterinarian however has to be guided by the medical adage “if you hear the sound of hoof first look for a horse before a zebra”. This only means that diagnosis should start with the basis of thorough physical examination of the entire body and clinical examinations. A well and sequential conduction of physical and clinical examinations serves as a pointer to the underlying cause of ascites. However this may not always be so as diagnosis oftentimes is cumbersome. In such situations diagnosis would include a complete blood count which may reveal evidence of bacterial infection. Abdominal ultrasound/sonography is done to determine the abdominal content and aid in differentiating excess fluid accumulation from abdominal masses and organ enlargement. Knowledge of the blood biochemistry including total protein, albumin, creatinine and urea, liver enzymes and coagulation profile would help in revealing cases of hypoalbuminaemia, hypoproteinaemia and hepatic and kidney diseases [5]. Cardiac diseases may be diagnosed with the aid of electrocardiograph. Cardiac auscultation detects cases of cardiac murmurs and arrhythmia. Abdominal paracentesis is a useful procedure usually carried out to reduce the fluid level and alleviate complications of dyspnea. Paracentesis is a useful procedure in the management of ascites which is instituted in conjunction with appropriate treatment of the underlying cause. Once appropriate diagnosis is made, treatment usually comes easy by alleviating life-threatening conditions such as dyspnea and administering appropriate therapy as the case may be.

2. Classification of ascites

The purpose of this review is primarily focused on the various causes of ascites with emphasis on the hepatic origin. Based on this premise, ascites is classified broadly into hepatic, pre-hepatic and post-hepatic origin:

- i. Pre-hepatic causes emanate from portal vein thrombosis, bacterial infection such as tuberculosis, malnutrition, hypoalbuminaemia and parasitic diseases such as strongyloidosis and entamoeba [6]. Other causes include trauma or rupture of the lymphatic vessels, blood vessels and urinary bladder, renal failure, lymphoma and neoplasm of various kinds including breast, bronchus, ovary, gastric, pancreatic or colonic neoplasms [7]. Up to 20% of neoplastic ascites arise from tumour of unknown origin [7].
- ii. Post-hepatic causes might include congestive heart failure often linked with pulmonary hypertension, left-sided heart failure, right-sided heart failure,

constrictive pericarditis, Budd-Chiari syndrome and stricture web formation in the inferior vena cava [8, 9].

- iii. Hepatic origin emanates from various hepatic diseases including cirrhosis, portal hypertension and hepatitis. Approximately 85% of portal hypertension results in cirrhosis [8–10].

Earlier classification of ascites was centred on two broad categories, transudates and exudates, based on the total protein concentration of ascetic fluid. High total protein (>2.5 g/l) was described as exudates, while low total protein (<2.5 g/l) as transudate [11]. Both transudates and exudates were subcategorised into modified transudates and exudates based on the level of total protein concentration in the ascetic fluid. Transudates with <2.5 g/l of total protein usually occur with portal hypotension or hypoalbuminaemia [6]. Exudates with >2.5 g/l of total protein are associated with inflammatory disease conditions such as bacteria tuberculosis, neoplasm of unknown origin, pancreatitis, myxoedema, etc. Nevertheless, it has been observed that a total protein concentration of <2.5 g/l has an accuracy of only 56% [6] in detecting exudates from various conditions such as cardiac ascites and patients on diuretics and neoplasms [11]. The obvious challenge in the use of total protein concentration paved way to the discovery of serum ascites albumin gradient (SAAG) concentration as a more reliable tool in classification of ascites with efficacy ranging from 80 to 100% [11]. With the advent of SAAG, exudate ascites is replaced with (>1.1 g/l) high serum ascites albumin gradient and transudate with low (<1.1 g/l) serum ascites albumin gradient. The SAAG (>1.1 g/l) shows higher 94% sensitivity and 90% specificity in detecting portal hypertension than ascetic fluid total protein concentration of <2.5 g/dl at percentage sensitivity and specificity of 78 and 50%, respectively [12]. The prognostic index value of SAAG was at 82–97% compared to total protein concentration at 38–85% [12]. Ascites from cardiac origin produces greater (>2.5 g/dl) SAAG compared to cases of cirrhosis [13].

A more recent classification of ascites has endorsed the use of serum ascites albumin gradient (SAAG) in diagnosis of ascites [14]. The SAAG is derived by subtracting the ascetic fluid albumin level from the serum albumin level obtained on the same day [14]. Gradients greater than 1.1 g/dl indicate ascites of portal hypertension with an accuracy of 97–100% [14]. Gradients less than 1.1 g/dl are considered ascites of other sources other than portal hypertension such as neoplasm [15, 16] (**Table 1**).

High gradient (>1.1 g/l) SAAG	Low gradient (<1.1 g/l) SAAG
Portal hypertension	Bacterial infection
Cardiac diseases	Peritoneal tuberculosis
Liver cirrhosis	Pancreatic ascites
Myxoedema	Parasitic disease
Budd-Chiari syndrome	Ancylostomosis
Hepatitis	Nephrotic syndrome
Portal vein thrombosis	Trauma and rupture of lymphatic and blood vessels
Hypoalbuminaemia	Rupture of the urinary bladder, left-sided heart failure, right-sided heart failure, congestive heart failure

Table 1.
Classification of ascites based on SAAG.

3. Pathophysiology of ascites in cirrhosis

Ascites is one of the cardinal complications in liver cirrhosis in most patients [8]. Onset of ascites naturally connotes decompensated underlying liver cirrhosis which also signifies poor prognosis with short life expectancy [10, 17, 18]. Several factors contribute to the development of cirrhosis. The heart, for instance, plays an important role through a complex mechanism in the development of liver disease. The mechanism through which the heart and liver affect each other in the development of ascites is yet to be fully elucidated [14]. Several circulatory abnormalities observed in cirrhotic patients promulgated the peripheral arterial vasodilation hypothesis proposed in the last century [19]. The circulatory abnormalities manifest as increased cardiac output, portal hypertension, peripheral vascular resistance, arterial hypotension and splanchnic vasodilation [6, 20]. Circulatory abnormalities from cardiac disease affect circulatory volume with a resultant decrease in tissue perfusion affecting majorly the kidney functionality [21]. Earlier in the disease, renal dysfunction is less expressed; however, with disease advancement the patient may experience difficulty in sodium excretion and consequent sodium and water retention [22]. Cirrhotic ascites basically develop from failure in renal excretion of sodium [22]. Different mechanisms also play a role in ascites in cirrhosis. Intrinsic factors including arterial vasodilation affect the blood pressure hormones such as the renin-angiotensin-aldosterone system (RAAS) which stimulates sodium reabsorption from the distal nephron [22]. The sympathetic nervous system (SNS) induces renal constriction and sodium reabsorption from the tubules with ascites [23, 24]. The heart, SNS and RAAS play a synergistic role in sodium retention and development of ascites in cirrhosis.

3.1 Pathogenesis of portal hypertension in ascites

The portal vein is a major vein comprising of a group of veins which supply the visceral organs including the abdomen, pancreas, intestine, etc. These veins bifurcate into smaller vessels in the hepatic tissue. Intrinsic factors and disease conditions such as cirrhosis result in blockage of these tiny veins in the hepatic tissue increasing the blood pressure in the veins with resultant portal hypertension. Other causes of portal hypertension include portal vein thrombosis, schistosomiasis, idiopathy, etc. Ascites develops in portal hypertension when the post-sinusoidal gradient is above 12 mmHg [25]. Portal hypertension elevates the hydrostatic pressure within the hepatic sinusoids permitting seepage of transudate into the peritoneal cavity [26, 27]. The extent of ascites' development is dependent on the level of hydrostatic pressure [28] and less on oncotic plasma albumin pressure [26, 29]. Signs and symptoms of portal hypertension include haematuria, dysentery, bloody vomitus due to spontaneous rupture and haemorrhage from varices, encephalopathy due to abnormal liver function and thrombocytopaenia. Factors such as abnormal increase in nitric oxide production and circulation of endogenous vasoconstriction such as catecholamines, leukotrienes and angiotensin II enhance hepatic vascular resistance and portal hypertension [30, 31].

3.1.1 Pathogenesis of hepatorenal syndrome in ascites

One of the complications of activation of RAAS and SNS in cirrhosis is the resultant renal vasoconstriction leading to decrease in renal perfusion and glomerular filtrate rate which progresses to renal impairment [21, 22, 32, 33]. In hepatorenal syndrome, there are no significant morphological changes in renal histology, while the patients largely retain normal tubular function [5, 21]. The kidney analyte and serum creatinine concentration does not increase until the glomerular filtration rate becomes markedly reduced below 40 ml/min [22]. Most patients with cirrhosis have their creatinine level below 1.2 mg/dl, and diagnosis of HRS is only made when the creatinine concentration

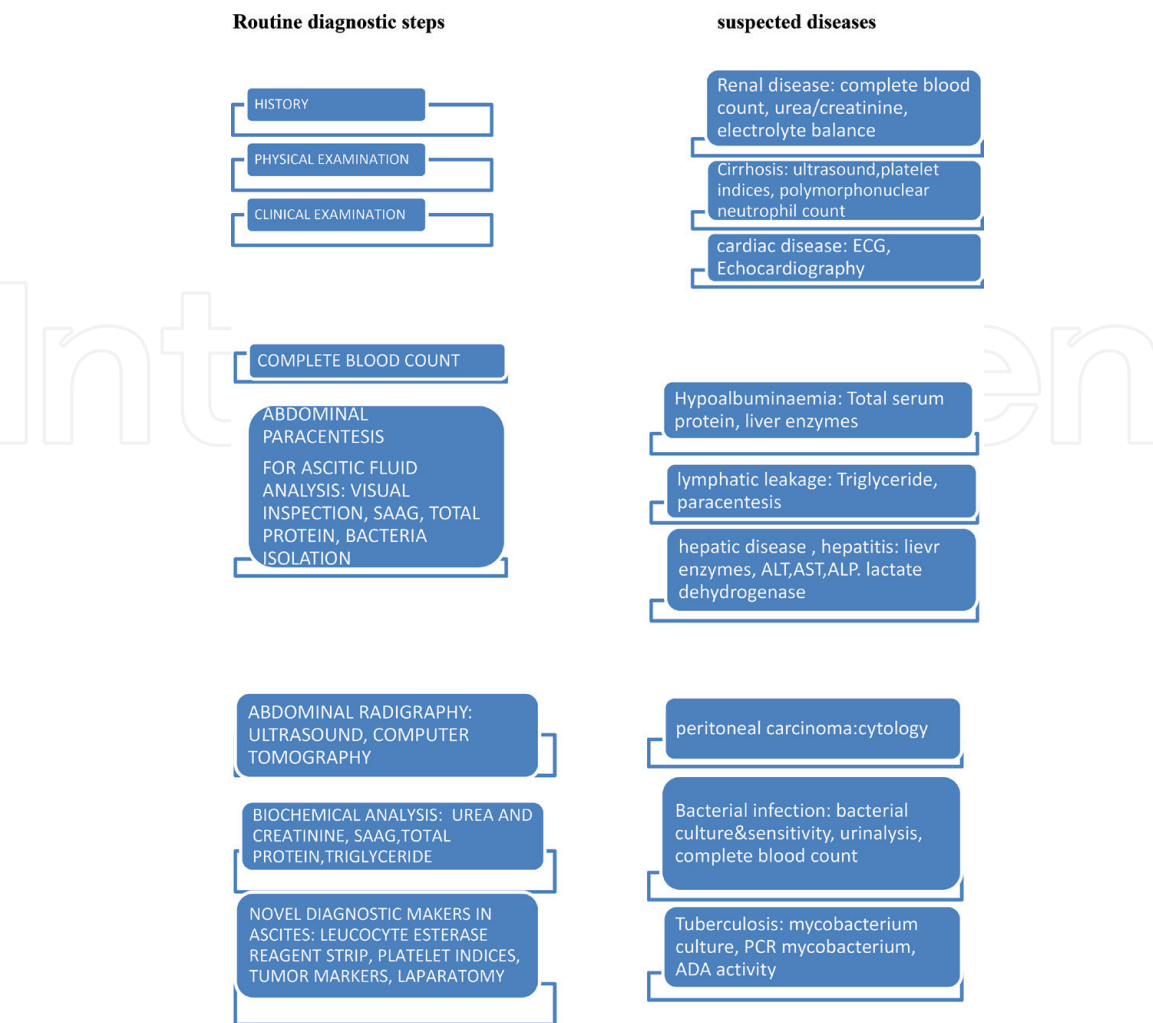
is higher than 1.5 mg/dl in the absence of other complicating aetiologies [22]. Hepatorenal syndrome manifests in two different types in cirrhotic patients. Type I HRS is a fulminating form of the disease rapidly progressing to acute renal failure often precipitated by variceal bleeding, septic infection and spontaneous bacteria peritonitis with poor prognosis of days to weeks [22]. Type 2 is a more chronic form of HRS. Most patients with this form of disease have a more stable creatinine concentration with only signs of refractory ascites due to unresponsive diuretics [34, 35].

With advancement in cirrhosis, there is also progressive increase in sodium and water reabsorption and decrease in renal blood flow and glomerular filtration [36]. Approximately 20% of cirrhotic patients with refractory ascites progress to HRS which results from severe liver and systemic circulatory dysfunction [28]. Hepatorenal syndrome results from marked overactivity of RAAS, SNS, AND and other endogenous vasoconstrictor factors which exceeds renal production of vasodilatory substances [PGE2, prostacyclin, nitric oxide]. The imbalance from renal vasodilatory mechanism and the intrinsic vasoconstrictor enhances vasoconstriction and hypoperfusion and decreases GFR with ultimate result of renal failure [22].

4. Diagnosis of ascites

Usually there is no laid down procedure on the steps to diagnose ascites; however a systematic approach applied in various disease conditions is advantageous in making appropriate diagnosis. A step-by-step approach normally starts with physical examination.

4.1 Algorithm of diagnosis in ascites



4.1.1 Physical examinations

In physical examination, the patient is examined for the presence of ticks and fleas which would contribute in physical discomfort of the pet. Ticks' infestation contributes in depletion of blood volume and anaemia. Anaemia is detected by the appearance of pale mucous membrane of the eye and the gum. Ectoparasitism from ticks' infestation may result in malnutrition due to competition with the host for essential nutrients necessary for the synthesis of protein and albumin. This could result in hypoalbuminaemia/hypoproteinaemia and a decrease in plasma oncotic pressure enhancing vascular permeability and seepage of fluid in the abdominal cavity. A distended or pulsating jugular vein in the neck region may indicate cardiovascular abnormality. Yellowish discoloration of the eye indicates jaundice and hepatic disease. Generalised lymphadenopathy may suggest lymphosarcoma and other inflammatory disease conditions. A "standback" observation reveals cases of dyspnea due to abdominal displacement of the diaphragm into the thoracic cavity compromising respiration. Respiratory distress could manifest in the form of rapid panting. Such condition presents a deviation from the normal respiratory pattern, from coastal to costo-abdominal or abdominal pattern. Black tarry-coloured faeces from gastrointestinal bleeding may signify ancylostomosis and portal hypertension. Physical examination of the trunk reveals a distended abdomen. The content of the abdomen could either be by pregnancy, abdominal masses, fluid of various consistencies or organ enlargement. The diagnosis of ascites starts from differentiating these possibilities through various procedures. First is to carry out abdominal ballottement using clinched fist. This technique can be used to differentiate abdominal masses from fluid. It can be used with other laboratory tests such as pregnancy test to rule out pregnancy. It however has some limitations in differentiating abdominal masses from organ enlargement. Abdominal ultrasound is a better option in differentiating abdominal contents. It has been proven effective in the detection of ascetic fluid, its site of production and differentiation of ascetic nature from transudates and exudates [11]. A recent research has shown the possibility of the use of echotexture of ascetic fluid in the detection of the cause of ascites in patients [11]. Abdominal paracentesis however is a very useful technique in differentiation of ascetic fluid [28].

4.1.2 Guidelines for paracentesis in a dog (author's personal experience)

A well-applied paracentesis without contamination of abdominal content is essential in differentiation of ascetic fluid. To achieve this, the following steps should be strictly applied:

1. First apply caution by the use of proper restrain technique on the dog.
2. Gently place the dog on a lateral decumbency exposing the larger part of the ventral abdomen.
3. Swab the ventral abdomen less covered with haircoat, along the linea alba down to the ventral abdomen between the left and right hindlimbs. (Linea alba is the preferred site of paracentesis due to its less vascularisation and less chance of contamination of the fluid with blood from puncture vessels and abdominal organs when approached through a different site on the abdomen.)
4. Puncture the linea alba using a 21 gauge needle and 10 mL gauge syringe, and aspirate the fluid.

5. Decant the content of the syringe into a clean and well-labelled tube for laboratory investigation.
6. Request for cytology of the fluid (**Figure 1**).

4.1.3 Diagnostic fluid markers in ascites

The colour of ascetic fluid is a very essential marker in the diagnosis of the cause of ascites. The colour ranges from clear fluid to yellowish, reddish and opaque with flakes of fibrin and debris depending on the aetiology. It is therefore important to observe the above guidelines in paracentesis in order to avoid false discolouration of the fluid, thus affecting correct diagnosis. Various colours of ascetic fluid signify a different aetiology as shown below [37]:

1. Pinkish discolouration of the fluid: This is often seen in cases of exudation of fluid from bacterial infection which may become purulent. The exudates are often turbid in consistency and contains more than 2.0 gm of protein and greater than 6000 cells/ μ L composed mostly of neutrophils with evidence of +++ bacterial infection. This type of fluid is considered a medical emergency to prevent development of sepsis.
2. Clear straw-coloured fluid: This type of fluid is described as modified transudate often characterised by the presence of fibrin cells and white blood cells such as neutrophils and lymphocytes. It is often seen in cases of long-standing ascites from various conditions including right-sided heart failure, cancerous growth and hepatic disease giving chance to invasion of fibrinogens.
3. Clear opaque fluid: This fluid is described as collection of pure transudate into the peritoneal cavity free from contamination except with few invasions of mesothelial cells and tissue macrophages. This ascites may be seen in cases of portal hypertension, hepatic diseases, osmotic gradient deficit (hypoalbuminaemia), protein losing enteropathy, kidney impairment and albuminuria.
4. Reddish discolouration of fluid: This is seen in cases of haemorrhages and collection of frank blood in the peritoneal cavity due to conditions of trauma, coagulopathies and blood and blood vessel neoplasm. The fluid contains high levels of cells mainly red blood cells with PCV being above 20%.
5. Greenish discolouration of fluid: This is seen in cases of rupture and seepage of bile into the peritoneal cavity.
6. Milky/slightly yellowish discolouration: This describes a condition of collection of lymph in the peritoneal cavity due to trauma, infection, cancer or right-sided heart failure. This type of exudates is turbid and opaque and is often described as chyle. It gives a positive result in Sudan III stain test for lipids due to the high level of lipid in the fluid.

4.1.4 Clinical examination (author's personal experience)

Clinical examination is considered a useful tool in the identification of the cause of ascites. An elevated temperature would signify an underlying infectious or inflammatory condition such as bacterial tuberculosis. An elevated capillary refill time would signify a decreased circulatory volume as a result of cancerous or infectious

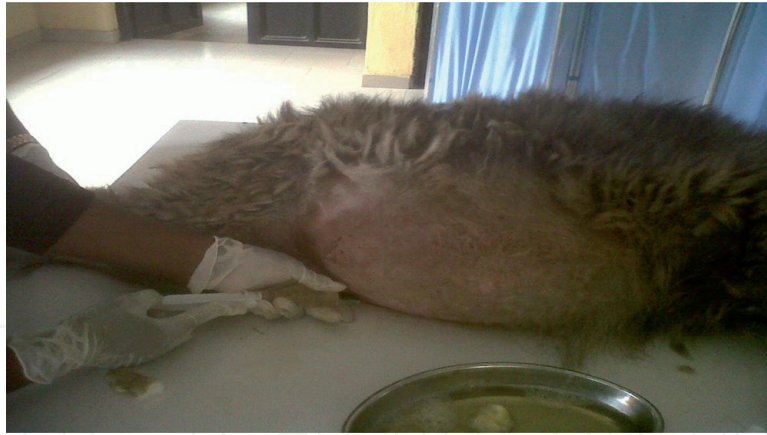

Figure 1.
Removal of ascites through the linea alba in an Alsatian breed of dog.

condition. Auscultation of the heart reveals various cardiovascular diseases such as muffled heart sound which is consistent with pericardial effusion and cardiac tamponade. Heart murmurs or irregular heartbeats are suggestive of right-sided heart failure. An elevated heartbeat or tachypnoea may result from dyspnea due to cranial displacement of the diaphragm into the thoracic cavity. Cardiovascular abnormalities are confirmed through the use of electrocardiograph and echocardiography.

4.1.5 Biochemical investigation in ascites (author's personal experience)

The determination of biochemical profile such as the liver enzymes, total protein level, SAAG, albumin concentration, total bilirubin and kidney analytes such as creatinine and urea levels is useful in the diagnosis of the cause of ascites.

4.1.6 Serum ascites albumin gradient (SAAG)

Serum ascites albumin gradient is presently the best tool in diagnosis of the cause of ascites especially that from portal hypertension [38]. A SAAG value of <1.1 g/dl or 11 g/l indicates causes of non-portal origin such as malignancy, etc. [5]. Gradients >1.1 g/dl or 11 g/l indicate ascites of portal hypertension.

4.1.7 Total protein

Although the traditional classification of ascites according to the transudate and exudate concept has almost phased out following the introduction of SAAG, it however still has relevance in clinical practice for comparison and prognostic value. Concentrations below 15 g/l are often associated with risk of spontaneous bacteria peritonitis in cirrhosis [5, 39].

4.1.8 Triglycerides

An elevated triglyceride concentration in ascetic fluid above 2.2 mmol/l indicates chylous ascites [38]. Chylous ascites is common in neoplastic cases although it may occur in 6% of cirrhosis [40].

4.1.9 Urea and creatinine

Elevated levels in urea and creatinine concentrations in ascetic fluid indicate prerenal failure due to peritoneal absorption of urea [41]. Urinary ascites is often associated with bladder changes and urethra obstruction [41, 42].

4.1.10 Cytology

Cytology of ascetic fluid is often indicated in suspected malignancy and idiopathic cases. Positive cytology is highly indicated in suspected cases of peritoneal carcinomatosis. The sensitivity of cytology can be enhanced by examination of three samples from separate paracenteses [38]. The sensitivity is also enhanced by prompt analysis of ascetic fluid and obtaining large volume of up to 50–1000 ml in patients with initial negative result.

4.1.11 Diagnostic laparotomy

Diagnostic laparotomy is indicated in cases of difficulty in identification of the aetiology of ascites. Often laparotomy presents adequate visual inspection of the peritoneal cavity and avenue for biopsy collection for histological and microbiological studies [38]. Diagnostic laparotomy provides ground for effective diagnosis of peritoneal carcinomatosis, tuberculous peritonitis, etc. [43, 44].

4.1.12 Leucocyte esterase reagent strip

Several studies have shown the usefulness in the use of leucocyte esterase reagent strip in diagnosing spontaneous bacteria peritonitis and in urinary analysis with sensitivity ranging from 80 to 93% and specificity 93–98% [45]. The negative predictive value is markedly high from 97 to 99%, a good measure for an ideal tool to rule out SBP [45]. Recent development has discovered an ascite-specific reagent strip with a cut-off value of 250 cells/mm³ which would further enhance diagnostic accuracy [46].

4.1.13 Platelet indices

Increased platelet indices such as mean platelet volume and platelet distribution width have been observed to increase in cirrhosis. The usefulness of the platelet indices is yet to be fully elucidated but has shown propensity as a potential diagnostic tool [47].

4.1.14 Tumour markers

The use of tumour markers such as alpha - feto protein, des-gamma-carboxy prothrombin, cancer antigen 125, etc. in the diagnosis of cancer in ascetic fluid is presently a subject of controversy among several researchers. Although the increased level of these markers is associated with underlying malignancies, elevated levels are also observed in other conditions such as pancreatitis, gastritis, etc. [48].

4.1.15 Imaging tools

Radiographical imaging is useful in detailing small amounts of ascetic fluid as well as diagnosis of aetiology of ascites [49]. Abdominal ultrasonography can detect as little as 100 ml of intraperitoneal fluid [50]. The sensitivity of radiography is enhanced through the use of computed tomography which detects minute quantities of ascetic fluid. Radiography enhances the picture of internal organs and aids in detection of cirrhosis, intra-abdominal tumour and organ enlargements. Thickening of mesentery and bowel wall, matting of bowel loops and enlargement of mesenteric lymph nodes may provide a guide in the diagnosis of tuberculosis

peritonitis in affected patients. A contrast computed tomography (CT) may be used to demonstrate enhancement of peritoneal lining. Cases of cirrhosis and large hydrothorax can be diagnosed with the aid of scintigraphy with technetium sulphur colloid or radiolabelled albumin [6].

4.1.16 Bacterial culture

Spontaneous bacterial peritonitis may arise due to decreased level of complements which serve as antibacterial factors in ascetic fluid. Suspected cases of SBP are cultured in both aerobic and anaerobic blood media for isolation of organisms [51]. Cultured ascetic fluid should be subjected to sensitivity test to identify effective antimicrobiological agent in treatment.

The DNA of *Mycobacterium tuberculosis* in ascetic fluid can be detected using polymerase chain reaction in suspected cases. PCR for *Mycobacterium tuberculosis* offers a high sensitivity (94%) test compared to microscopic acid-fast bacilli smear (–0%) and mycobacterial culture (–50) [38].

5. General treatment options in ascites

Ascites is treated symptomatically while addressing the primary cause of the condition. Efforts are geared towards relieving manifesting symptoms and preventing progression of ascites. The main goal in congestive heart failure is to improve cardiac contractility, normalise cardiac arrhythmias and enhance cardiac output. Cardiac drugs such as dopamine and digoxin can be used at recommended dosages in cases of congestive heart failure in dogs. Dogs with right-sided heart failure should be placed on cage rest and on sodium-restricted diet [52]. Paracentesis is applied to relieve abdominal tension on the diaphragm and enhance normal respiration. Repeated paracentesis is not required except in cases of failing treatment [52]. Paracentesis should not exceed 1.0 kg weight per day for dogs with both ascites and peripheral oedema and less than 0.5 kg weight per day for patients with only ascites. Serum albumin sometimes is depleted during paracentesis and therefore should be monitored and replaced intravenously in case of depletion at the same quantity of fluid removed. The administration of albumin dosed at 1.5 g/kg on the first day and 1.0 g/kg on the third day ensured renal preservation and reduced mortality [53]. In cases of syncope, a balanced isotonic crystalloid fluid replacement such as Plasma-Lyte A, Normosol R and 0.9% saline may be used in resuscitation and other conditions such as hypernatraemia, hyponatraemia, hypercalcemia, metabolic alkalosis or oliguria renal failure. Diuretics are used in addition to paracentesis to relieve ascites. Diuretics may be dosed once daily. Spironolactone has a half life of 24 hours and is given at the dose of 100 mg/day max 400 mg/day for response [54]. The dose may be spread out every 2 hours stat in dogs under hospitalisation and close monitoring at 2 mg/kg \times im and at 3 mg/kg \times per os at night. Spironolactone could be substituted with either triamterene or amiloride since both drugs have good antagonistic effect on aldosterone action on the collecting tubules [55]. Furosemide is often the first line of treatment in cases of ascites with a half life of 1.5 hours and given at the dose of 40 mg/day and max 160 mg/ day in case of nonresponders to furosemide [39]. The dose may also be spread in divided doses of 3 mg/kg \times IV every 2 hours and at 4 mg/kg per os at night. Bumetanide and spironolactone could be used in combination with furosemide at the ratio of 100:40 to reduce chances of furosemide resistance. The dose ratio ensures efficient natriuresis and flow of water and also reduces the risk of potassium deficit from the use of furosemide [39, 56]. Other diuretics such as torsemide and bumetanide have shown better efficacy than most diuretics [57].

Torsemide has a longer half life than both furosemide and bumetanide [57]. Patient with cirrhotic ascites often presents with complications of SBP, portal hypertension and HRS [28]. Cases without such complications are described as “uncomplicated ascites” [58]. The standard treatment for SBP in humans involves immediate administration of third-generation cephalosporin such as intravenous ceftriaxone 1 to 2 g daily for 5 days [52]. The dose could be given at 1 g daily in dogs. The use of oral fluoroquinolones is equally effective in the treatment of SBP [59, 60]; alternatively piperacillin and tazobactam could be considered [61]. The choice of antibacterial agent depends on culture and sensitivity test to reduce problems of drug resistance. Antibiotic treatment is usually given for an extended period to ensure complete cure of the bacterial infection.

Portal hypertension is managed by the use of antihypertensive medications. A drug such as metolazone (Mykron, Zaroxolyn) aids in the elimination of oedema in congestive heart failure. It enhances sodium excretion by inhibition of sodium reabsorption from the distal tubules, a function which is beneficial in renal conditions [55]. Mannitol (Osmitol) inhibits tubular reabsorption of electrolyte by increasing the osmotic pressure of glomerular filtrate and urine output [55]. Cases of recurrent ascites in humans from portal hypertension may require the use of TIPS [28]. TIPS functions as a side-to-side portacaval anastomosis between the high portal pressure end and low hepatic vein pressure end, thereby effectively decongesting the portal system which may be useful in pets. A reduction in the portal hypertension brings a secondary decrease in RAAS activation and consequent increase in sodium excretion [62]. Persistent ascites from cirrhosis may be managed through liver transplant and removal of the damaged liver. The hepatic cells naturally possess high regenerative capacity and can regenerate after undergoing severe degenerative condition. The hepatocytes in addition can perform at full capacity even with few viable cells, and therefore liver transplant is only required as a last resort after application of all remedial medications.

Renal failure is managed by controlling blood pressure with drugs; avoid the use of hepatotoxic medications in treatment of ascites and the use of non-steroidal anti-inflammatory agents (NSAIDs) such as acetaminophen. Kidney dialysis is recommended in severe kidney damage. A continuous venovenous haemodialysis (CVVHD) is recommended compared to intermittent renal dialysis.

Cases of complications of encephalopathies from hepatic failure are best managed in intensive care units (ICU) [18]. Cases of early complication of encephalopathy may be treated as outpatient; nevertheless such a patient is closely monitored for further deterioration to grade II encephalopathy which would require prompt transfer to an intensive care unit. Such a patient is placed on routine check on mental balance, and signs of restlessness could be slightly sedated with low dose of short-acting benzodiazepines. Patients under sedation are placed on undisturbed bed rest avoiding extensive movement which may enhance chances of intracranial pressure/hypertension. Dyspnea is prevented in late encephalopathy through placement of intratracheal intubation to avoid further complications of aspiration pneumonia. The conditions of cerebral oedema and intracranial hypertension manifest at the late phase of encephalopathy and are prevented through routine checks on the patient's renal parameters; biochemical profile including liver enzymes, total protein, glucose, electrolytes and acid/balance; and neurological evaluations for signs of elevated levels [4]. Cases of severe bleeding result from problems of coagulopathies which can be treated by addressing the coagulopathy through transfusion of coagulation products such as fresh frozen plasma and platelets and administration of vitamin K. Severe conditions may be boosted by transfusion of packed red blood cells. Continuous bleeding after massive replacement infusions may indicate possible retroperitoneal bleeding [18]. A good number of herbal and

antioxidant medications have shown to be beneficial in the treatment of ascites of hepatic origin. The use of these drugs remains controversial, but despite this the drug N-acetylcysteine and *Silybum marianum* still remain the drug of choice in the treatment of hepatic damage from acetaminophen toxicity and hepatic dysfunction, respectively [63].

Conclusion: Ascites is a disease condition commonly seen in pets of various age brackets with high incidences occurring in middle-aged dogs. Ascites is a common manifestation of a decompensate cirrhosis, cardiac diseases and several other aetiologies and is best diagnosed through established standard procedures of physical and clinical examinations, complete blood picture, cytology and various biochemical analyses. Recent novel techniques such as platelet indices, leucocyte esterase reagent strip, tumour markers, bacterial DNA, cytokines and other proteins are available for the advancement of biochemical laboratory techniques and efficient diagnosis of ascites. Treatment is centred on effective diagnosis of the aetiology.

Acknowledgements

I sincerely acknowledge the God Almighty for His enablement bestowed upon me during the course of this write-up.

Appendix

dyspnea	difficulty in breathing
encephalopathies	degenerative condition in the brain
cholestasis	obstruction of the bile duct
haemolysis	red blood cell destruction
gastroenterology	study of both the stomach and intestines
haematology	study of the blood
neurology	study of the nervous tissues
ascites	accumulation of fluid in the abdominal cavity
effusion	accumulation of fluid in the abdominal cavity
arrhythmia	irregular heartbeat
tamponade	closure or blockage especially to stop bleeding
coagulopathy	problem with blood clotting mechanism
conjugated	reversibly combined with a compound
unconjugated	compound in its natural form
opaque	not transparent, cloudy, filmy
aetiology	the cause of a disease condition
vascularisation	area supplied with blood vessels
transudate	fluid produced from increased pressure in the hepatic, portal vein (>8 mmHg) usually around 20 mmHg, low in protein (<30 g/L), low in LDH, high pH, normal glucose and fewer cells
exudate	fluid actively secreted from inflammation or malignancy, rich in protein, lactate dehydrogenase, low pH (<7.30), low glucose level and large numbers of white blood cells
renal	pertains to the kidney
hepatorenal syndrome	condition that affects both the liver and kidney
<i>Silybum marianum</i>	active compound in milk thistle herbal preparation
<i>Amanita phalloides</i>	a poisonous species of mushroom
idiopathic	unknown origin

IntechOpen

IntechOpen

Author details

Rosemary Ijeoma Ogechi Nwoha
Michael Okpara University of Agriculture, Umudike, Abia State, Nigeria

*Address all correspondence to: rosemarynwoha@yahoo.com

IntechOpen

© 2019 The Author(s). Licensee IntechOpen. This chapter is distributed under the terms of the Creative Commons Attribution License (<http://creativecommons.org/licenses/by/3.0>), which permits unrestricted use, distribution, and reproduction in any medium, provided the original work is properly cited. 

References

- [1] Saravanan M, Sarma K, Kumar M, Mahendran K, Mondal DB. Therapeutic management of ascites in dogs. *The Indian Veterinary Journal*. 2013;**90**(2):110-111
- [2] Michael PW, Zenoble RD. Canine ascites. *Digital Repository Iowa State University*. 1982;**44**(1):3
- [3] Pradhan MS, Dakshinkar NP, Naghaye UG, Bodkhe AM. Successful treatment of ascites of hepatic origin in dog. *Veterinary World*. 2008;**1**(1):23
- [4] Chalasani NP, Hayashi PH, Bonkovsky HL, Navarro VJ, Lee WM, Fontana RJ, et al. ACG clinical guideline: The diagnosis and management of idiosyncratic drug-induced liver injury. *American Journal of Gastroenterology*. 2014;**109**(7):950-966
- [5] European Association for the study of the liver. EASL clinical practice guideline on the management of ascites, spontaneous bacterial peritonitis and hepatorenal syndrome in cirrhosis. *Journal of Hepatology*. 2010;**53**:397-417
- [6] Sood R. Ascites: Diagnosis and management. *Journal, Indian Academy of Clinical Medicine*. 2000;**5**(1):81-89
- [7] Christopher MM, Van Thiel DH. Cirrhotic ascites review: Pathophysiology, diagnosis and management. *World Journal of Hepatology*. 2013;**5**(5):251-263
- [8] Ginès P, Quintero E, Arroyo V, Terés J, Bruguera M, Rimola A, et al. Compensated cirrhosis: Natural history and prognostic factors. *Hepatology*. 1987;**7**(1):122-128
- [9] Planas R, Montoliu S, Ballesté B, Rivera M, Miquel M, Masnou H, et al. Natural history of patients hospitalized for management of cirrhotic ascites. *Clinical Gastroenterology and Hepatology*. 2006;**4**:1385-1394
- [10] Guevara M, Cárdenas A, Uriz J, Ginès P. Prognosis in patients with cirrhosis and ascites. In: Ginès P, Arroyo V, Rodés J, Schrier R, editors. *Ascites and Renal Dysfunction in Liver Disease: Pathogenesis, Diagnosis, and Treatment*. 2nd ed. Malden, MA: Blackwell Publishing; 2005. Chapter 21
- [11] Mohammed SA, Caroline EA, Boushra HA, Elsafi AA. Radiology, diagnostic imaging and instrumentation. *Global Journal of Medical Research*. 2013;**3**:3. version 1.0
- [12] Shanker S, Divya J, Pramod Kumar A, Bijoykumar B. Clinicopathological correlation of serum ascites albumin gradient with ascetic fluid total protein in patients of ascites with portal hypertension attending a tertiary care hospital in eastern Bihar India. *International Journal of Advances in Medicine*. 2017;**4**(3):842-846
- [13] McNally PR. *Gastrointestinal/Liver Secrets*. 4th ed. Philadelphia, PA: Mosby Elsevier; 2010
- [14] Shailja CS, David AS. "Cardiac Hepatopathy": A review of liver dysfunction in heart failure. *Liver Research Open Journal*. 2015;**1**(1):1-10
- [15] Moitinho E, Escorsell A, Bandi JC, Salmerón JM, García-Pagán JC, Rodés J, et al. Prognostic value of early measurements of portal pressure in acute variceal bleeding. *Gastroenterology*. 1999;**117**:626-631
- [16] Runyon BA. Ascites and spontaneous bacterial peritonitis. In: Feldman M, Friedman LS, Brandt LJ, editors. *Sleisenger and Fordtran's Gastrointestinal and Liver Disease*. 9th ed. Philadelphia, PA: Saunders; 2010
- [17] Fernandez-Esparrach G, Sanchez-Fueyo A, Gines P, Uriz J, Quinto L, Ventura P, et al. A prognostic model

for predicting survival in cirrhosis with ascites. *Journal of Hepatology*. 2001;**34**:46-52

[18] Gagen KS. Acute Liver Failure, Treatment and Management. 2017. Available from: <https://emedicine.medscape.com/article/177354-treatment#d1>

[19] Bataller R, Arroyo V, Gines P. Management of ascites in cirrhosis. *Journal of Gastroenterology and Hepatology*. 1997;**12**:723-733

[20] Gentilini P, Vizzutti F, Gentilini A, Zipoli M, Foschi M, Romanelli R. Update on ascites and hepatorenal syndrome. *Digestive and Liver Disease*. 2002;**34**:592-605

[21] Ginès P, Schrier RW. Renal failure in cirrhosis. *The New England Journal of Medicine*. 2009;**361**:1279-1290

[22] Vicente AMD. Pathophysiology, diagnosis and treatment. *Annals of Hepatology*. 2002;**1**(2):72-79

[23] Dudley F. Pathophysiology of ascites formation. *Gastroenterology Clinics of North America*. 1992;**21**:215-235

[24] Gines P, Fernandez-Esparrach G, Arroyo V, Rodes J. Pathogenesis of ascites in cirrhosis. *Seminars in Liver Disease*. 1997;**17**:175-189

[25] Casado M, Bosch J, Garcia-Pagan J, Bru C, Banares R, Bandi J, et al. Clinical events after transjugular intrahepatic portosystemic shunt: Correlation with hemodynamic findings. *Gastroenterology*. 1998;**114**:1296-1303

[26] Henriksen J, Siemssen O, Krintel J, Malchow-Møller A, Bendtsen F, Ring-Larsen H. Dynamics of albumin in plasma and ascitic fluid in patients with cirrhosis. *Journal of Hepatology*. 2001;**34**:53-60

[27] Kravetz D, Bildozola M, Argonz J, Romero G, Korula J, Munoz A, et al.

Patients with ascites have higher variceal pressure and wall tension than patients without ascites. *The American Journal of Gastroenterology*. 2000;**95**:1770-1775

[28] Pedersen JS, Flemming B, Møller S. Management of cirrhotic ascites. *Therapeutic Advances in Chronic Disease*. 2015;**6**(3):124-137

[29] Moore KP, Aithal GP. Guidelines on the management of ascites in cirrhosis. *Gut*. 2006;**55**(Supplement vi):vi1-v12

[30] Iwakiri Y, Groszmann R. The hyperdynamic circulation of chronic liver diseases: From the patient to the molecule. *Hepatology*. 2006;**43**:S121-S131

[31] Møller S, Henriksen J. *The Systemic Circulation in Cirrhosis*. Malden, Ma: Blackwell Publishing; 2005

[32] Henriksen J, Møller S. *Alterations of Hepatic and Splanchnic Microvascular Exchange in Cirrhosis: Local Factors in the Formation of Ascites*. Malden, MA: Blackwell Publishing; 2005

[33] Stadlbauer V, Wright G, Banaji M, Mukhopadhyaya A, Mookerjee R, Moore K, et al. Relationship between activation of the sympathetic nervous system and renal blood flow autoregulation in cirrhosis. *Gastroenterology*. 2008;**134**:111-119

[34] Krag A, Bendtsen F, Henriksen J, Møller S. Low cardiac output predicts development of hepatorenal syndrome and survival in patients with cirrhosis and ascites. *Gut*. 2010;**59**:105-110

[35] Ruiz-Del-Arbol L, Monescillo A, Arocena C, Valer P, Gines P, Moreira V, et al. Circulatory function and hepatorenal syndrome in cirrhosis. *Hepatology*. 2005;**42**:439-447

[36] Wensing G, Lotterer E, Link I, Hahn E, Fleig W. Urinary sodium balance in patients with cirrhosis:

Relationship to quantitative parameters of liver function. *Hepatology*. 1997;**26**:1149-1155

[37] Ettinger SJ, Feldman EC. Textbook of Veterinary Internal Medicine Diseases of the Dog and Cat. 6th ed. Vol. 1. USA: Elsevier Saunders; 2005

[38] Oey RC, van Buuren HR, de Man RA. The diagnostic work-up in patients with ascites: Current guidelines and future prospects. *The Netherlands Journal of Medicine*. 2016;**74**(8):330-338

[39] Runyon BA. Management of adult patients with ascites due to cirrhosis: An update. *Hepatology*. 2009;**49**:2087-2107

[40] Laterre PF, Dugernier T, Reynaert MS. Chylous ascites: Diagnosis, causes and treatment. *Acta Gastroenterologica Belgica*. 2000;**63**:260-263

[41] Peeters P, Colle II, Serinesael J, Verbeelen D. Relapsing ascites and uremia due to urinary bladder leakage. *European Journal of Internal Medicine*. 2001;**12**:60-63

[42] Snauwaert C, Geerts A, Colle I, Van vlierberghe H. Ascites not always the usual suspect. *Acta Gastro-Enterologica Belgica*. 2012;**75**:45-48

[43] Han CM, Lee CL, Huang KG, et al. Diagnostic laparoscopy in ascites of unknown origin. Chang gung memorial hospital 20 years experience. *Chang Gung Medical Journal*. 2008;**31**:378-383

[44] Yoon YJ, Ahn SH, Park JY, et al. What is the role of diagnostic laparoscopy in a gastroenterology unit? *Journal of Gastroenterology*. 2007;**42**:881-886

[45] Rerknimitr R, Limmathurotsakul D, Bhokaisawan N, Kongkam P, Treeprasertsuk S, Kullavainijaya P. A comparison of diagnostic efficacies among different reagent strips and automated cell count in spontaneous

bacterial peritonitis. *Journal of Gastroenterology and Hepatology*. 2010;**25**:946-950

[46] Mendler MH, Agarwal A, Trimzi M, et al. A new highly sensitive point of care screen for spontaneous bacterial peritonitis using the leukocyte esterase method. *Journal of Hepatology*. 2010;**53**:477-483

[47] Abdel-Razik A, Eldars W, Rizk E. Platelet indices and inflammatory markers in diagnostic predictors for ascetic fluid infection. *European Journal of Gastroenterology & Hepatology*. 2014;**26**:1342-1347

[48] Huang LL, Xia HH, Zhu SL. Ascitic fluid analysis in the differential diagnosis of ascites: Focus on cirrhotic ascites. *Journal of Clinical and Translational Hepatology*. 2014;**2**:58-64

[49] Theoni RF. The role of imaging in patients with ascites. *American Journal of Roentgenology*. 1995;**165**:16-18

[50] Goldberg BB, Goodman GA, Clearfield HR. Evaluation of ascites by ultrasound. *Radiology*. 1970;**96**:15-22

[51] Siersema PD, de Marie S, van Zeijl JH, Bac DJ, Wilson JH. Blood culture bottles are superior to lysis-centrifugation tubes for bacteriological diagnosis of spontaneous bacterial peritonitis. *Journal of Clinical Microbiology*. 1992;**30**:667-669

[52] Moore CM, Van Thiel DH. Cirrhotic ascites review: Pathophysiology, diagnosis and management. *World Journal of Hepatology*. 2013;**27**(5):251-263

[53] Sort P, Navasa M, Arroyo V, Aldeguer X, Planas R, Ruiz-del-Arbol L, et al. Effect of intravenous albumin on renal impairment and mortality in patients with cirrhosis and spontaneous bacterial peritonitis. *The New England Journal of Medicine*. 1999;**341**:403-409

- [54] Tsochatzis EA, Gerbes AL. Diagnosis and treatment of ascites. *Journal of Hepatology*. 2017;**67**(1):184-185. DOI: 10.1016/j.jhep.2017.01.011
- [55] Rahil S, Janice MF. Ascite. Drugs and disease. *Gastroenterology*. Medscape. 2017. <https://emedicine.medscape.com/article/170907-overview>
- [56] Santos J, Planas R, Pardo A, Durández R, Cabré E, Morillas RM, et al. Spironolactone alone or in combination with furosemide in the treatment of moderate ascites in nonazotemic cirrhosis. A randomized comparative study of efficacy and safety. *Journal of Hepatology*. 2003;**39**:187-192
- [57] Wargo KA, Banta WM. A comprehensive review of the loop diuretics: Should furosemide be first line? *Annals of Pharmacotherapy*. 2009;**43**(11):1836-1847, 2009
- [58] Salerno F, Angeli P, Bernardi M, Laffi G, Riggio O, Salvagnini M. Clinical practice guidelines for the management of cirrhotic patients with ascites. Committee on ascites of the Italian Association for the Study of the liver. *Italian Journal of Gastroenterology and Hepatology*. 1999;**31**:326-334
- [59] Felisart J, Rimola A, Arroyo V, Perez-Ayuso RM, Quintero E, Gines P, et al. Cefotaxime is more effective than is ampicillin-tobramycin in cirrhotics with severe infections. *Hepatology*. 1985;**5**:457-462
- [60] Navasa M, Follo A, Llovet JM, Clemente G, Vargas V, Rimola A, et al. Randomized, comparative study of oral ofloxacin versus intravenous cefotaxime in spontaneous bacterial peritonitis. *Gastroenterology*. 1996;**111**:1011-1017
- [61] Novovic S, Semb S, Olsen H, Moser C, Knudsen J, Homann C. First-line treatment with cephalosporins in spontaneous bacterial peritonitis provides poor antibiotic coverage. *Scandinavian Journal of Gastroenterology*. 2012;**47**:212-216
- [62] Rossle M, Siegerstetter V, Huber M, Ochs A. The first decade of the transjugular intrahepatic portosystemic shunt (TIPS): State of the art. *Liver*. 1998;**18**:73-89
- [63] Chronic Liver Disease. https://en.wikipedia.org/wiki/chronic_liver_disease