

We are IntechOpen, the world's leading publisher of Open Access books Built by scientists, for scientists

6,900

Open access books available

186,000

International authors and editors

200M

Downloads

Our authors are among the

154

Countries delivered to

TOP 1%

most cited scientists

12.2%

Contributors from top 500 universities



WEB OF SCIENCE™

Selection of our books indexed in the Book Citation Index
in Web of Science™ Core Collection (BKCI)

Interested in publishing with us?
Contact book.department@intechopen.com

Numbers displayed above are based on latest data collected.
For more information visit www.intechopen.com



Human Immunodeficiency Virus Associated Large Artery Disease

Ruchika Meel and Ricardo Gonçalves

Abstract

Advances in human immunodeficiency virus (HIV) therapy with highly active antiretroviral agents has increased the longevity of patients afflicted with this disease. HIV vasculopathy is a unique disease entity presenting as aneurysms, dissections and vascular occlusion amongst others due to HIV related vasculitis. A few studies have investigated the pathogenesis of HIV related vasculopathy. This chapter provides a brief overview of aortic aneurysms in general. Further, the current understanding of the pathogenic mechanisms underlying HIV vasculopathy with an emphasis on inflammatory mediators, histology, clinical presentation and imaging are discussed. Finally, a summary regarding management of HIV associated large vessel disease is presented.

Keywords: HIV, vasculopathy, aneurysms

1. Introduction

Human immunodeficiency virus (HIV) is a global disease. According to global HIV and acquired immunodeficiency syndrome (AIDS) statistics in 2017, there were 36.9

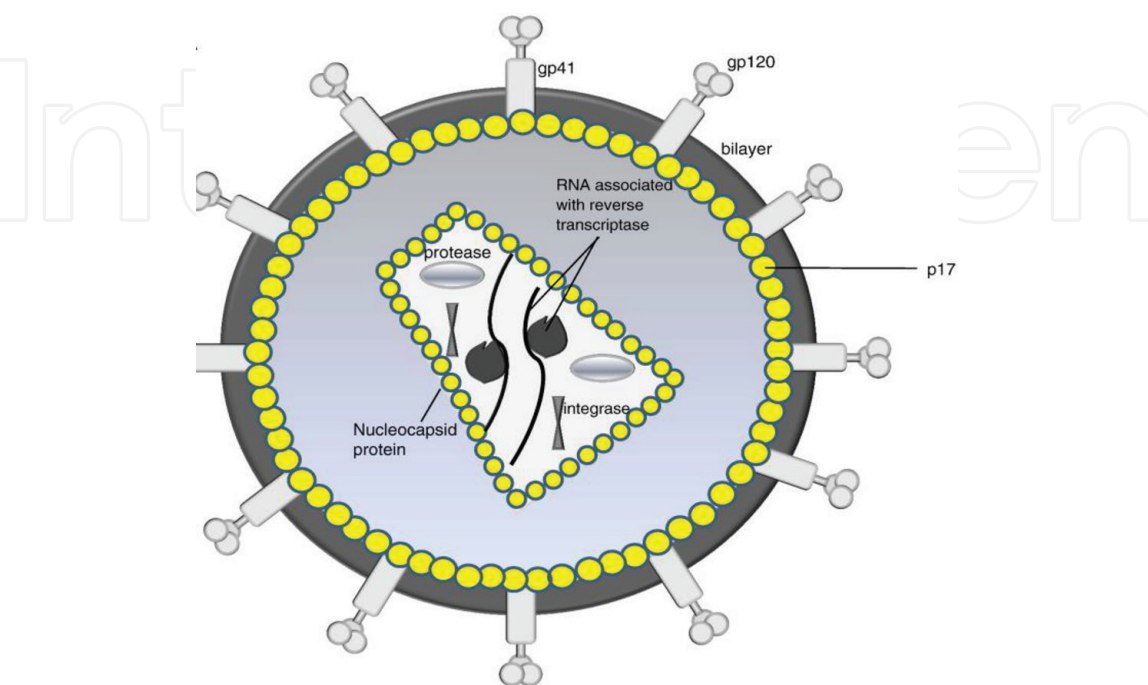


Figure 1.
Structure of the mature HIV virus. (Reproduced from Ref. [2]. Permission obtained from Michael S. Pepper).

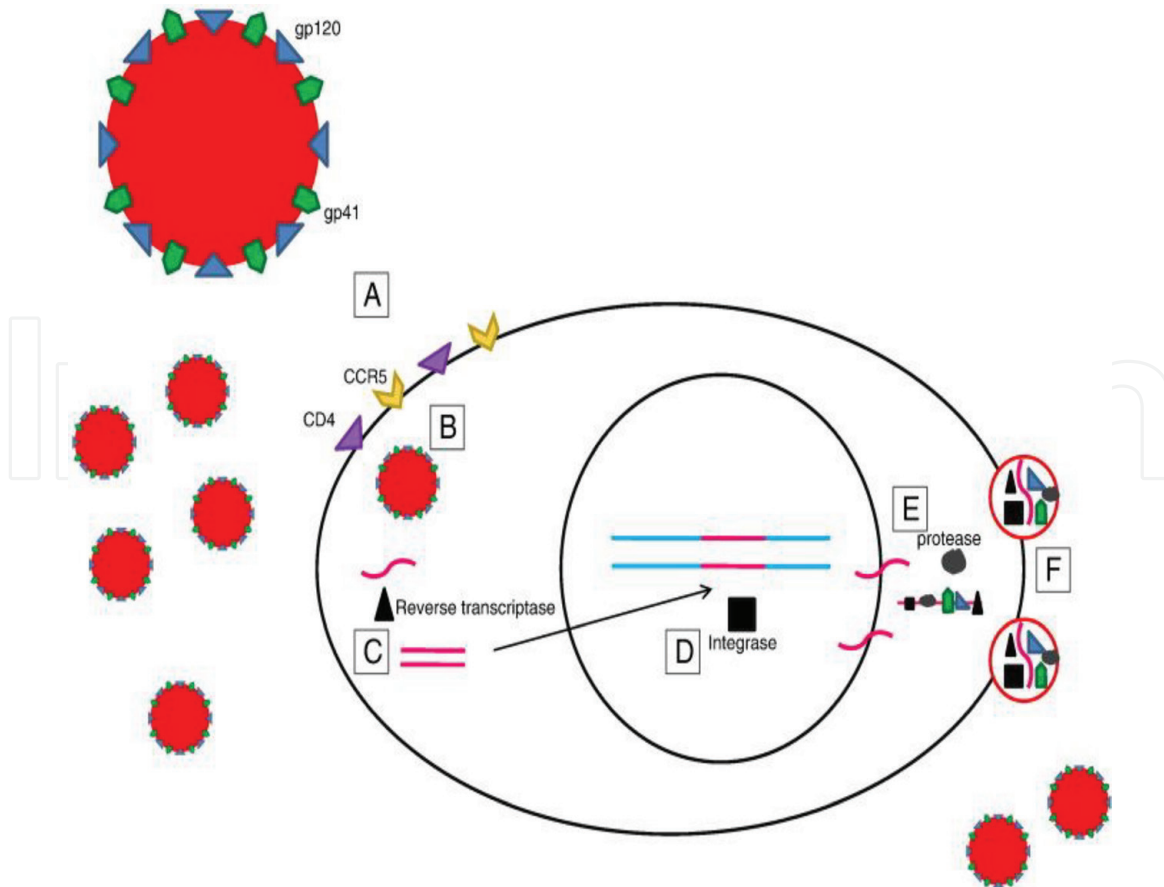


Figure 2.

Diagram illustrating HIV replication. (A) The virus glycoprotein receptors bind to host cell CD4 and a co-receptor CCR5. (B) Fusion of the virus with the host cell membrane results in viral uncoating and the release of the viral nucleocapsid into the cytoplasm. (C) The enzyme reverse transcriptase converts the single stranded RNA into double stranded DNA. (D) The viral DNA is transported to the host nucleus where it is integrated into the host's DNA. (E) Viral DNA is transcribed and translated using host cell machinery and then cleaved by viral protease into functional viral proteins. (F) Viral RNA and proteins assemble at the cell surface and bud off the cellular membrane. (Reproduced from Ref. [2]. Permission obtained from Michael S Pepper).

million [31.1–43.9 million] people living with HIV, of whom 35.1 million [29.6–41.7 million] adults. The majority of these individuals reside in the developing world [1].

HIV infection involves multiple systems including the cardiovascular system. A structure of the HIV virus and its replication in a cell are depicted in **Figures 1** and **2**. A large number of these patients present with vascular pathology [3, 4]. HIV afflicts the vascular system in multiple ways. Patients may present with a diverse array of aneurysms, occlusive disease, spontaneous arteriovenous fistulae and dissections. The precise pathogenesis of HIV related vasculitis remains poorly understood, a few recent studies have tried to address this issue [5].

In this chapter we will review the current knowledge pertaining to the important entity of HIV associated vasculopathy with an emphasis on effects of HIV on the aorta.

2. Definition and broad overview of aortic aneurysms

An aortic aneurysm is a dilation of a segment of the aortic wall, which may undergo further expansion and rupture [6]. It is defined as at least a 50% increase in diameter compared with the expected normal diameter of the vessel. They may occur in the ascending or the descending thoracic or abdominal aorta.

It may be fusiform or saccular in morphology [6]. A fusiform aneurysm is characterised by a uniform symmetric enlargement of the entire circumference of the aortic wall. A saccular aneurysm involves dilation of a localised portion of the aortic wall.

These are true aneurysms as opposed to false aneurysms, as they involve all three layers of the aortic wall.

3. Aetiology

There are multiple aetiologies implicated in the pathogenesis of aortic aneurysms [6]. These include:

1. Degenerative or atherosclerotic diseases.
2. Genetic diseases, such as Marfan syndrome, Loeys-Dietz syndrome, Ehlers-Danlos syndrome, familial thoracic aortic aneurysms, bicuspid aortic valve disease, Turner syndrome and aortopathy associated with congenital heart disease.
3. Inflammatory diseases, such as Takayasu's disease and giant cell arteritis.
4. Infectious diseases, including bacterial infections (the most common organisms implicated are *Staphylococcus aureus*, *Salmonella* species, *Escherichia coli*, *Streptococcus* species, *Neisseria* species and gram-negative bacilli) and fungi. Recently, HIV has been implicated in the pathogenesis of aortic aneurysms. Infected aortic aneurysms have a high mortality.

4. Epidemiology

The true incidence and prevalence of aortic aneurysms is difficult to ascertain due to the silent nature of this disease [7]. In a computed chest tomography (CT) study the prevalence of asymptomatic thoracic ascending aneurysm was 0.16% [8]. In a different study the prevalence was noted to be 0.34% [9]. The incidence and prevalence of aneurysms tend to differ between studies due to different aortic dimension cut-offs. The majority of studies did not include aortas between 4 and 5 cm [7]. The annual incidence according to two studies was estimated to be in the range of 5.6 and 10.4 cases per 100,000 patient-years [10, 11]. Thoracic aneurysms are more common in men greater than 60 years of age [7].

Abdominal aortic aneurysm is predominantly a disease of men [12–15]. The incidence rises with age. In screening studies its prevalence is estimated at 4–8%. The incidence of new cases of abdominal aortic aneurysms in the western population is estimated at 0.4–0.67% [7].

The true incidence and prevalence of HIV associated aneurysms remains understudied. The incidence of symptomatic vasculitis in HIV-infected patients is reported to be 1% [16].

5. Pathogenesis of HIV associated vasculopathy

The pathogenesis of HIV associated vasculopathy is multifactorial (**Figure 3**) [5]. Three pathophysiological processes have been implicated:

- Inflammation and endothelial injury
- Smooth muscle cell proliferation and migration
- Molecular mimicry

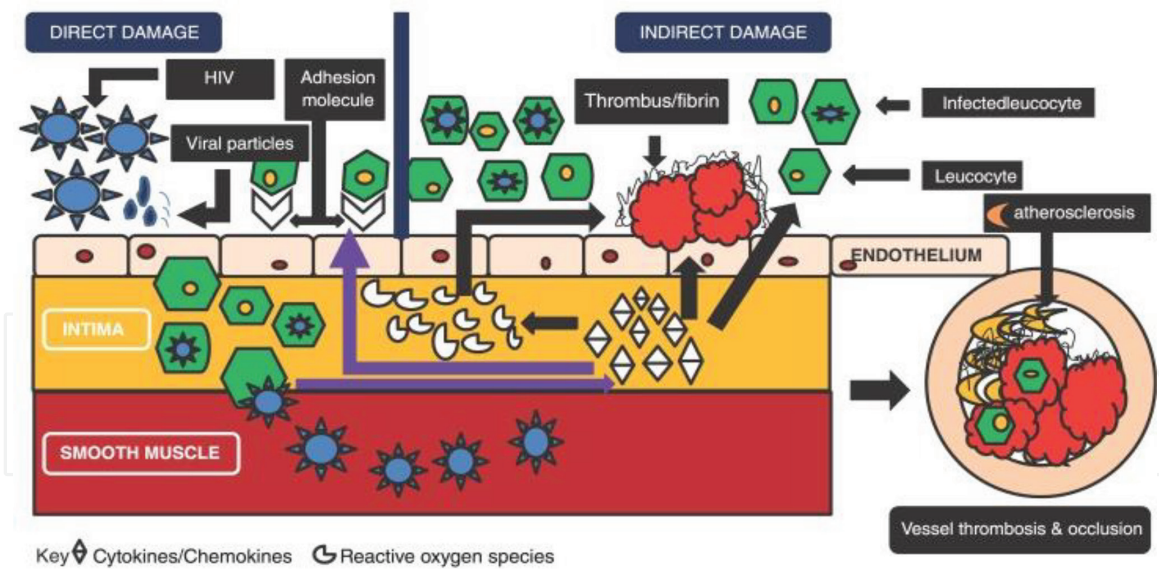


Figure 3.
Pathogenesis of HIV associated vasculopathy. (Reproduced from Ref. [5]. Permission obtained from B Pillay).

5.1 Inflammation and endothelial injury

Endothelial cell dysfunction as a result of increase in inflammatory mediators to viral proteins has been implicated in the pathogenesis of HIV related vasculitis [5]. The inflammatory mediators include interleukins 1, 6 and 8, and tumour necrosis factor- α . The aforementioned argument is supported by a study by Nieuwhof et al., in the setting of cerebral vasculitis, whereby, they found an increased CD25-positive receptor positive T-cells. HIV envelope surface glycoprotein 120 and a transactivator transcription protein that have been implicated in the stimulation of pro-inflammatory pathways in HIV related vasculitis.

Increased oxidative stress in HIV in animal studies has been proposed as an additional mechanism of endothelial dysfunction [17].

5.2 Smooth muscle cell proliferation and migration

Smooth muscle cells, an important component of the muscularis media, possess important surface receptors such as CD4, CCR5 and CXCR4 [5]. These receptors mediate the entry of HIV virus into the cell resulting in invasion and disruption of tunica media, and activation of tissue factor 2 with resultant stimulation of pro-coagulant pathways.

5.3 Molecular mimicry

It is theorised that the arterial wall possesses receptors known as matrix adhesion molecule-1 which may share ligands with similar deoxyribonucleic acid sequences to those present in the viral envelope glycoprotein, GP41 and GP120 [5]. This may result in an autoimmune response within the host and cell damage.

5.4 Other postulated mechanisms involved in the pathogenesis of HIV related vasculopathy

Direct invasion by HIV of vascular endothelium and toxicities related to highly active antiretroviral therapy (HAART) have been postulated as possible additional mechanisms resulting in endothelial injury [17].

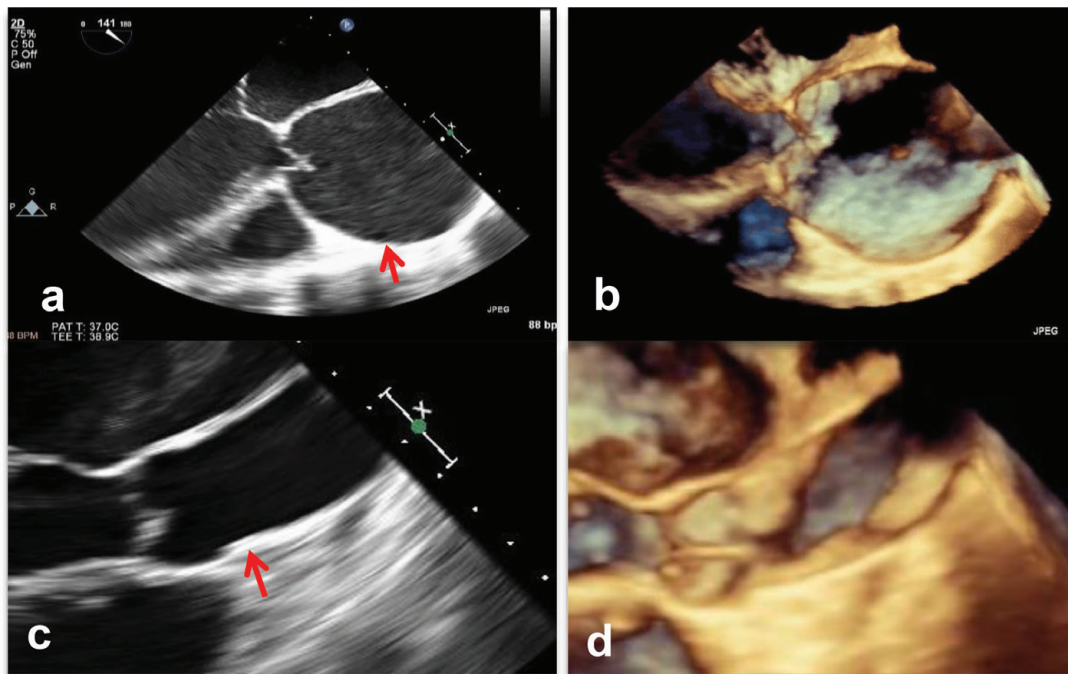


Figure 4.
 Two and three dimensional long axis trans-oesophageal images of an enlarged ascending aorta in a patient with HIV associated aortopathy (arrow) (a, b) and a normal aorta in a control (arrow) (c, d).

5.5 HIV-associated aortopathy

HIV-associated aortopathy may present as aneurysmal disease of the ascending and the descending aorta (**Figure 4a–d**). Bacterial infections have been implicated in the pathogenesis of aortic aneurysms [5, 6]. A few case reports have reported the presence of *Salmonella*-related mycotic aneurysmal disease in HIV-positive patients. These aneurysms have been reported in immunosuppressed patients with advanced HIV disease [5].

5.6 Other forms of HIV related vasculopathy

HIV may affect femoral, carotid and popliteal arteries [5]. It may manifest as aneurysmal or occlusive disease as well as present as arterio-venous fistula and as arterial dissection. Since the advent of HAART, atherosclerotic disease is also a possible manifestation of HIV vasculopathy.

6. Histopathological features of HIV associated large vessel vasculopathy

Large vessel vasculopathy related to HIV is characterised by involvement of all three layers of the vessel wall [5]. There is infiltration of the vasa vasorum, periaortic vessels and the adventitia by leucocytes. The media demonstrates fibrosis, muscle damage and elastin fragmentation. The intima also is characterised by disrupted internal elastic lamina and calcification.

Intracranial aneurysms due to HIV have been reported in children [5]. Overall histopathological studies have shown similar microscopic characteristics as previously described. Some studies, however, have shown distinct tissue characteristics in arteries of patients with intracranial aneurysms. These include variable absence of internal elastic lamina fragmentation, medial thickening with sub-intimal SMC deposition, presence of viral protein gp41 within the

macrophages of the arterial wall, as well as identification of agents such as varicella zoster virus in the tissue.

7. Clinical features of HIV-associated large vessel vasculopathy

These patients will usually have stigmata of advanced HIV disease and presence of other opportunistic infections may confound the clinical picture.

The majority of patients with thoracic ascending aortic aneurysms and abdominal aortic aneurysms are asymptomatic [5, 18]. Symptoms usually result from large aneurysms and include chest or upper back pain, or with symptoms related to compression of nearby structures leading to nerve dysfunction, or compression of the artery resulting in limb ischemia or thromboembolism. The initial presentation may be aortic dissection or rupture and is associated with high mortality.

Abdominal aortic aneurysms may present with abdominal, back, or flank pain, thromboembolism or limb ischemia [19].

An enlarging aneurysm of the carotid artery may present with dysphagia, airway compromise, hoarse voice, cranial nerve involvement, cerebrovascular accident and even rupture [5].

Occlusive disease is another manifestation of HIV vasculopathy [5]. It usually involves young males below the age of 40 years. It afflicts lower limbs more commonly than upper limbs. Clinical presentation can be acute or chronic. Acute presentation involves arterial thrombosis or occlusion. Chronic disease may manifest as critical limb ischemia in the form of rest pain or gangrene in more than half of the patients.

8. Imaging in HIV associated vasculopathy

A basic chest radiograph is considered a reasonable initial test in a patient presenting with chest pain. It can exclude an alternative diagnosis and avoid unnecessary additional aortic imaging [18].

A transthoracic echocardiogram or transesophageal echocardiography are useful bedside tests to assess the presence of aortic enlargement and related complications such as aortic regurgitation, dissection and pericardial effusion.

Cardiac computed tomography and magnetic resonance angiography are the imaging modalities of choice and help determine the aortic size, branch vessel anatomy and presence of dissection (**Figure 5**) [18]. In patients with coexisting risk factors for coronary artery disease such as HIV, a cardiac CT is useful to exclude presence of coronary artery disease.

Digital subtraction arteriography provides higher resolution of lumen of the vessel and is better at evaluating branch vessel pathology [18].

The aortic measurements must be made at the aortic annulus, sinuses, sinotubular junction, ascending arch, and specific locations of the descending aorta as per the American society of echocardiography chamber quantification guidelines [20]. The aortic annulus is measured at peak systole whereas all other aortic dimensions are measured at end-diastole. Currently, a leading edge to leading edge method of measurement is recommended.

Large vessel disease has been studied with the aid of multiple imaging modalities. Arterial inflammation in patients with HIV has been demonstrated using ¹⁸F-fluorodeoxyglucose-positron emission tomography [21]. Inflammation is associated with an increased cardiovascular risk amongst HIV patients. Carotid intima-media thickness has been studied in these patients with the aid of ultrasound technology [22]. An increased carotid intima thickness is a marker of adverse cardiovascular disease.

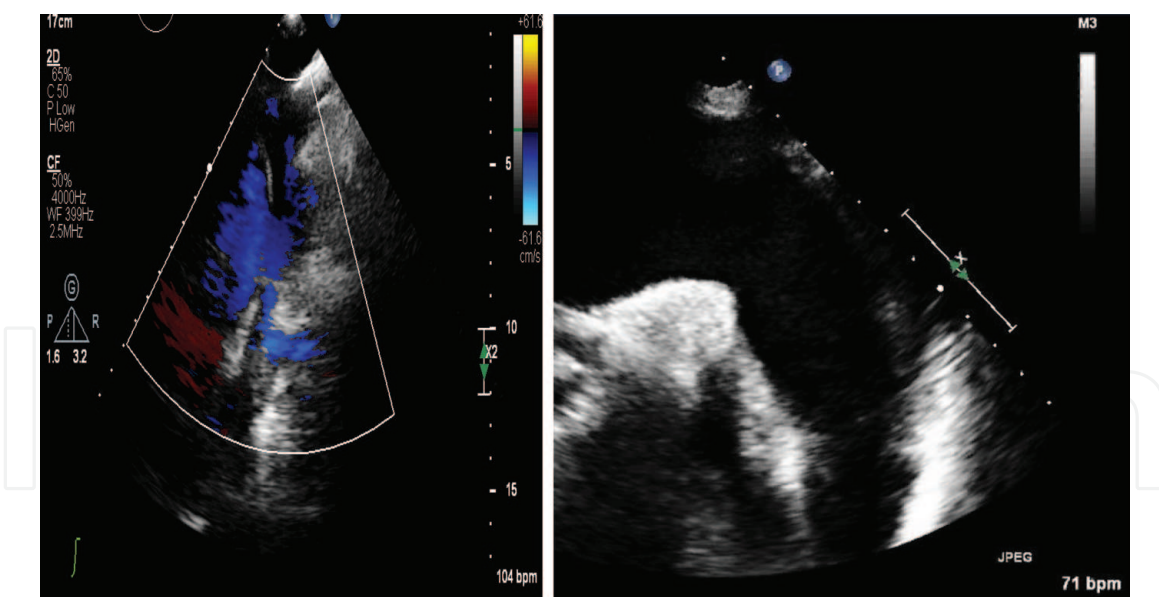


Figure 5.
 Transthoracic echocardiographic suprasternal views of an enlarged aortic arch (right) and descending thoracic aorta dissection (left) in a patient with HIV.

The choice of imaging technique depends on the availability of resources and expertise to interpret the results of the test.

9. Management of patients with HIV vasculopathy

Currently all HIV patients with vascular disease must be managed according to standard guidelines [23]. Conservative management may be considered in a moribund severely immunosuppressed patient with multiple co-morbidities [5]. All patients must be on HAART therapy.

Data regarding management of ascending aortic aneurysm in patients with HIV is limited. Currently the standard guidelines on management of aortopathy are applied to these patients. Patients with ascending thoracic aortic aneurysms with symptoms due to aortic regurgitation, dissection and rupture should undergo emergent surgery as per the standard guidelines [23]. Those without symptoms but an enlarged ascending aorta greater than 55 mm are at high risk of rupture and dissection and therefore urgent surgery is recommended. Asymptomatic patients who display rapid growth of thoraco-abdominal aortic aneurysms, expansion ≥ 1 cm per year for aneurysms less than 50 mm in diameter, must undergo surgery [24]. Aortic diameter is an important risk factor for aneurysm rupture, dissection and mortality [6]. An ascending aorta diameter of 6.0 and 7.0 cm in the descending aorta is associated with increased risk of rupture.

In patients with multiple comorbidities and high risk for surgery conservative management with afterload reducing agents such as angiotensin converting enzyme inhibitors or angiotensin receptor antagonists, can be utilised to reduce the shear stress on the aorta and prevent further expansion and dissection [6, 25]. Beta blockers have been shown to decrease aortic stress and are recommended even in patients without systemic hypertension [6].

In centres where there is a lack of expertise in managing thoracic aortic disease, patients should be referred to an appropriate high volume centre in order to provide the best care and outcomes for such patients [25].

For descending aortic and peripheral artery aneurysms, depending on the site and location of the aneurysm patients can undergo surgical repair of the aneurysm with good success [5]. Patients that are unable to tolerate major surgery due to poor

physiologic reserve can be offered endovascular repair. Data comparing endovascular repair versus surgery are limited in patients with HIV. Descending aortic aneurysms depending on the size and in absence of complications can be managed with medical therapy under close observation and follow-up [6].

The medical management of patients with HIV-related vasculopathy involves a combination of HAART, treatment of hyperlipidaemia and control of traditional risk factors associated with cardiovascular disease [5].

10. Prognosis and outcome

HIV patients with low CD4 counts, hyperglobulinemia, hypoalbuminemia and reversed CD4/CD8 ratios were reported have worse prognosis in a study by Van Marle et al. [26]. For peripheral large vessel surgery the perioperative mortality was reported to be between 9 and 10.6% in South Africa and 33% in Houston [5]. Major challenges related to wound healing and infection. Late graft sepsis rate of 10% has been reported with the use of prosthetic grafts. The follow-up in the aforementioned studies was poor and presents a major challenge in reporting long term outcomes. Further, the results may vary between patients on HAART compared to those without HAART. There are no studies pertaining to surgery in patients with ascending aortic aneurysms and descending thoracic aneurysms in the setting of HIV. No current studies address the natural history of HIV associated ascending or descending aortic aneurysms.

Conflict of interest

The authors have none to declare.

Funding

The first author was the recipient of the Carnegie Post-Doctoral Fellowship award.

Author details


Ruchika Meel^{1*} and Ricardo Gonçalves²

1 Division of Cardiology, Chris Hani Baragwanath Academic Hospital and University of the Witwatersrand, Johannesburg, South Africa

2 Olivedale and Glynnwood Hospitals, Johannesburg, South Africa

*Address all correspondence to: ruchikameel@gmail.com

IntechOpen

© 2019 The Author(s). Licensee IntechOpen. This chapter is distributed under the terms of the Creative Commons Attribution License (<http://creativecommons.org/licenses/by/3.0>), which permits unrestricted use, distribution, and reproduction in any medium, provided the original work is properly cited. 

References

- [1] Global HIV and AIDS statistics. <https://www.hiv.gov/hiv-basics/overview/data-and-trends/global-statistics> [Accessed: 24 November 2018]
- [2] Barmania F, Pepper MS. C-C chemokine receptor type five (CCR5): An emerging target for the control of HIV infection. *Applied & Translational Genomics*. 2013;2:3-16
- [3] Mulaudzi TV. HIV-associated vasculopathy. *CME*. 2009;27(7):320-322
- [4] Robbs JV, Paruk N. Management of HIV vasculopathy: A South African experience. *European Journal of Vascular and Endovascular Surgery*. 2010;39(Suppl 1):S25-S31
- [5] Pillay B, Ramdial PK, Naidoo DP. HIV-associated large-vessel vasculopathy: A review of the current and emerging clinicopathological spectrum in vascular surgical practice. *Cardiovascular Journal of Africa*. 2015;26(2):70
- [6] Zipes DP, Libby P, Bonow RO, Mann DL, Tomaselli GF. Braunwald's Heart Disease: A Textbook of Cardiovascular Medicine. Elsevier Saunders; 2018
- [7] Black JH III, Woo CL. Epidemiology, Risk Factors, Pathogenesis, and Natural History of Thoracic Aortic Aneurysm. Wolters Kluwer; 2017
- [8] Itani Y, Watanabe S, Masuda Y, et al. Measurement of aortic diameters and detection of asymptomatic aortic aneurysms in a mass screening program using a mobile helical computed tomography unit. *Heart Vessels*. 2002;16:42
- [9] Kälisch H, Lehmann N, Möhlenkamp S, et al. Body-surface adjusted aortic reference diameters for improved identification of patients with thoracic aortic aneurysms: Results from the population-based Heinz Nixdorf recall study. *International Journal of Cardiology*. 2013;163:72
- [10] Bickerstaff LK, Pairolero PC, Hollier LH, et al. Thoracic aortic aneurysms: A population-based study. *Surgery*. 1982;92:1103
- [11] Clouse WD, Hallett JW Jr, Schaff HV, et al. Improved prognosis of thoracic aortic aneurysms: A population-based study. *JAMA*. 1998;280:1926
- [12] Ashton HA, Buxton MJ, Day NE, et al. The Multicentre Aneurysm Screening Study (MASS) into the effect of abdominal aortic aneurysm screening on mortality in men: A randomised controlled trial. *Lancet*. 2002;360:1531
- [13] Norman PE, Jamrozik K, Lawrence-Brown MM, et al. Population based randomised controlled trial on impact of screening on mortality from abdominal aortic aneurysm. *BMJ*. 2004;329:1259
- [14] Lindholt JS, Juul S, Fasting H, Henneberg EW. Screening for abdominal aortic aneurysms: Single centre randomised controlled trial. *BMJ*. 2005;330:750
- [15] Ashton HA, Gao L, Kim LG, et al. Fifteen-year follow-up of a randomized clinical trial of ultrasonographic screening for abdominal aortic aneurysms. *The British Journal of Surgery*. 2007;94:696
- [16] Chang JM, Lameen H, Skinner GC. Multiple large vessel aneurysmal formation in HIV-infected patients. *SA Journal of Radiology*. 2017;21(2):a1186
- [17] Baliga RS, Chaves AA, Jing L, Ayers LW, Bauer JA. AIDS-related vasculopathy: Evidence for oxidative and inflammatory pathways in murine

and human AIDS. *American Journal of Physiology—Heart and Circulatory Physiology*. 2005;**289**(4):H1373-H1380

[18] Woo YJ, Greene CL, Hoekstra J, Eidt JF. *Clinical Manifestations and Diagnosis of Thoracic Aortic Aneurysm*. Walthman, MA: UpToDate; 2014. Monografía en Internet

[19] Jim J, Thompson RW, Eidt JF. *Clinical Features and Diagnosis of Abdominal Aortic Aneurysm*. Wolters Kluwer; 2018

[20] Lang RM, Badano LP, Mor-Avi V, Afzalalo J, Armstrong A, Ernande L, et al. Recommendations for cardiac chamber quantification by echocardiography in adults: An update from the American Society of Echocardiography and the European Association of Cardiovascular Imaging. *European Heart Journal Cardiovascular Imaging*. 2015;**16**(3):233-271

[21] Subramanian S, Tawakol A, Burdo TH, Abbara S, Wei J, Vijayakumar J, et al. Arterial inflammation in patients with HIV. *Journal of the American Medical Association*. 2012;**308**(4):379-386

[22] Stein JH, Currier JS, Hsue PY. Arterial disease in patients with human immunodeficiency virus infection: What has imaging taught us? *JACC: Cardiovascular Imaging*. 2014;**7**(5):515-525

[23] Authors/Task Force Members, Erbel R, Aboyans V, Boileau C, Bossone E, Bartolomeo RD, et al. 2014 ESC guidelines on the diagnosis and treatment of aortic diseases: Document covering acute and chronic aortic diseases of the thoracic and abdominal aorta of the adult. The Task Force for the Diagnosis and Treatment of Aortic Diseases of the European Society of Cardiology (ESC). *European Heart Journal*. 2014;**35**(41):2873-2926

[24] Lobato AC, Puech-Leão P. Predictive factors for rupture of thoracoabdominal aortic aneurysm. *Journal of Vascular Surgery*. 1998;**27**:446

[25] Woo J, Greene C, Connolly HM, Aldea FG, Verrier E. *Management of Thoracic Aortic Aneurysm in Adults*. Wolters Kluwer; 2017

[26] Van Marle J, Mistry PP, Botes K. HIV-occlusive vascular disease. *South African Journal of Surgery*. 2009;**47**(2):36-42