

We are IntechOpen, the world's leading publisher of Open Access books Built by scientists, for scientists

6,900

Open access books available

185,000

International authors and editors

200M

Downloads

Our authors are among the

154

Countries delivered to

TOP 1%

most cited scientists

12.2%

Contributors from top 500 universities



WEB OF SCIENCE™

Selection of our books indexed in the Book Citation Index
in Web of Science™ Core Collection (BKCI)

Interested in publishing with us?
Contact book.department@intechopen.com

Numbers displayed above are based on latest data collected.
For more information visit www.intechopen.com



Aneurysmal Bone Cyst in Sino-nasal Region

Zeinab AlQudehy and Lena Telmesani

Abstract

Aneurysmal bone cysts (ABCs) are vascular, rapidly expanding, and locally destructive cystic lesions. It is primarily found in childhood and adolescence. They typically involve the long tubular bones. Approximately 3–6% presented in the head and neck region, with the mandible being the most common site. Involvement of the ethmoid sinuses is extremely rare with only 13 cases reported in English literatures. Here we are presenting as an example an atypical case of an adolescent male patient, which had chief complaint of right-sided nasal blockage and right eye proptosis of 6-month duration. Local examination of the face showed right eye proptosis, with bulging around the right medial canthus and lateral wall of the nose. MRI revealed multiple fluid-fluid levels of varying signal intensities on T2-weighted image suggestive of aneurysmal bone cyst. Endoscopic sinus surgery was carried out to remove the swelling and tissue specimen sent for histopathology, which confirmed the diagnosis. Patient had smooth recovery after. Throughout this chapter, we will discuss aneurysmal bone cyst from its name, origin, and histopathology. Hence, the field of interest here is sino-nasal region, thorough discussion for ABC in sino-nasal region including its clinical presentation, how to reach into diagnosis, treatment method, and finally the prognosis and recurrence.

Keywords: aneurysmal bone cyst, ethmoid sinus, pediatric, fluid-fluid level

1. Introduction

Aneurysmal bone cyst (ABC) is an uncommon cystic vascular lesion [1] that is rapidly expanding and locally destructive. It is found mostly during childhood and adolescence and is more common in females [2]. The ABC lesion typically involves the long tubular bones with approximately 3–12% presented in the head and neck region [3] and the most common site being the mandible [4]. It has been reported to arise from the sino-nasal cavity, but involvement of the ethmoid sinuses is extremely rare [3]. ABC may be found in the presence of other benign bone lesions such as non-ossifying fibroma, giant-cell granuloma, fibrous dysplasia, and fibromyxomas [1]. The rarity of this disease in the head and neck region as well as the high risk of recurrence of the lesion makes it interesting and challenging to the head and neck surgeons to deal with such pathology.

2. Atypical case

A 14-year-old male patient presented with chief complaint of right-sided nasal blockage and bulging of the right eye of 6-month duration. The patient was medically free. He was in his usual state of health till 6 months prior to presentation to our clinic when he started to have nasal obstruction in the right side along with right eye proptosis. Local examination of the face showed right proptosis, with bulging around the right medial canthus and lateral wall of the nose. Nasal endoscopy by 00 rigid telescope showed poorly defined swelling in the right nasal cavity. Magnetic resonance imaging (MRI) of the nose and paranasal sinuses revealed multiple fluid-fluid levels of varying signal intensities ranging from very bright signal to a very low signal on T2-weighted image, suggestive of aneurysmal bone cyst (Figures 1 and 2). The patient was admitted and cleared by the ophthalmologist. Endoscopic sinus surgery

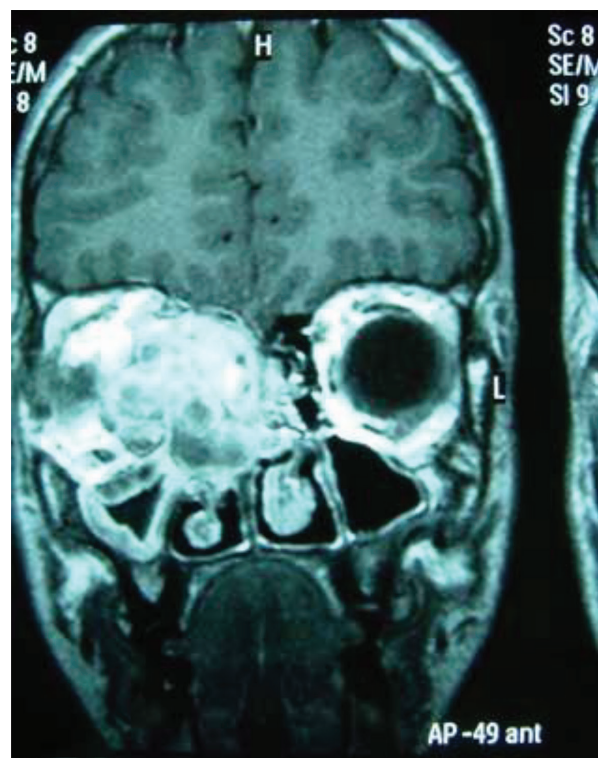


Figure 1.
MRI, coronal view showing multicystic lesion with varying intensity.

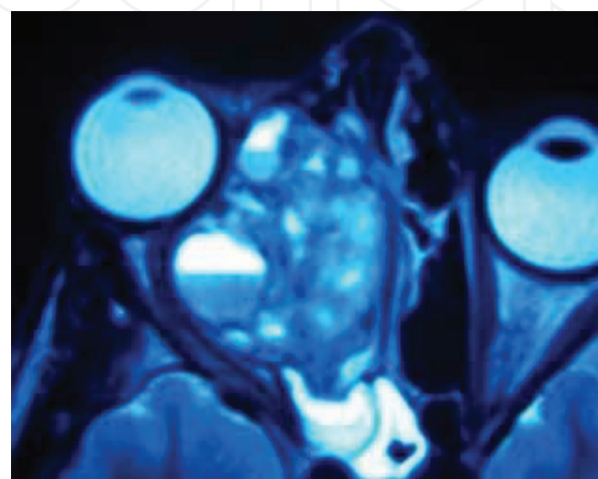


Figure 2.
MRI, axial view showing fluid-fluid levels in the lesion.

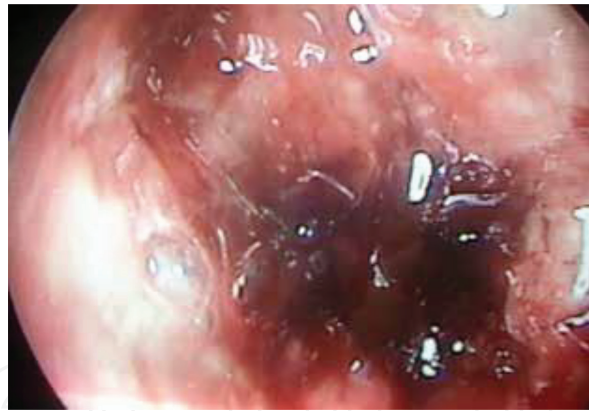

Figure 3.
Endoscopic intraoperative view of static blood inside the lesion.

was carried out to remove the nasal swelling, which showed multiple cystic swellings that were filled with blood (**Figure 3**), and tissue specimens were sent for histopathology. The histopathological specimens, on gross appearance, consist of friable hemorrhagic material that is often gritty. In en bloc resections, cyst and cortical destruction was appreciated. Microscopical results showed stroma composed of fibroblasts, multinucleate giant cells, and bone, as well as cystic spaces often filled with blood with an increased number of giant cells lining the cavity. The final histopathological diagnosis was ABC. The patient had smooth recovery postoperatively and was asymptomatic in 6 months of follow-up but unfortunately lost for subsequent follow-up after.

3. Aneurysmal bone cyst in general

3.1 History

Aneurysmal bone cysts (ABCs) were first described in 1942, by Drs. Jaffe and Lichtenstein. Typically, the described lesion was thin-walled, involving the pelvic and spine region, and they were confronted underneath large hole containing much fluid blood [5].

3.2 Characteristics of aneurysmal bone cyst

ABC is considered as uncommon benign nonneoplastic vascular lesion of the bones characterized by the presence of numerous blood-filled, usually non-epithelized cystic cavities. It is rapidly expanding and locally destructive [6].

3.3 The name of aneurysmal bone cyst

ABC is misnomer, as these lesions are neither aneurysmal in origin nor truly cystic in histopathology, with no endothelial wall. Instead, these are benign expansile lesions, within the bone, forming cavities that are filled with blood and lined by proliferative fibroblasts, giant cells, and trabecular bone [7].

3.4 Demographics of aneurysmal bone cyst

It is found mostly during childhood and adolescence, with median age of 13 years. About 90% of the ABCs lesions are found prior to age of 30. ABCs are more common in female patients, with male to female ratio of 1:1.6 [7, 8].

3.5 The origin of aneurysmal bone cyst

ABC typically originated from the long bones. It represents 1–2% of all primary tumors of the bone, occurring primarily in the metaphysis of long bones and vertebrae [8]. The ABC lesions typically involve long tubular bones. Between 3 and 12% of ABCs are found in the head and neck where they most commonly arise in the mandible or maxilla [3, 4]. Guida et al. [9] report that lesions involving the skull comprise 3–6% of all ABCs. Very few have ever been reported in the paranasal sinuses and are exceptionally rare in the pediatric population. Although they have been reported in the maxilla, mandible, cranium, orbital roof, temporal bone, and sphenoid bone, involvement of ethmoid sinuses as in our case is extremely rare [4]. Only 13 such cases of involvement of ethmoid sinuses were reported in the English literatures.

3.6 The pathogenesis of aneurysmal bone cyst

ABC's pathogenesis is obscure. Historically, it was believed that ABC resulted from increased venous pressure that is causing extravasation of cellular and blood contents into cyst-like voids in the bone [3]. More recent work showed that identification of a genetic driver—a translocation-induced upregulation of the ubiquitin-specific protease USP6 (Tre2) gene—defined at least a subset of ABCs to be a primary neoplasm [10].

3.7 Other associated bone pathologies

ABC is generally solitary and thought to arise as primary neoplasm as a result of translocation. On the other hand, ABCs may be found as secondary lesions, in the presence of other benign bone lesions such as non-ossifying fibroma, giant-cell granuloma, fibrous dysplasia, and fibromyxomas [1, 11, 12].

4. Aneurysmal bone cyst in sino-nasal region

ABC's involvement of ethmoid sinuses is extremely rare [4]. Only 13 such cases of involvement of ethmoid sinuses were reported in the English literatures. The mean age at debut in ethmoid ABCs is around 11.6 years with patient age ranging from 11 months to 20 years [3].

4.1 Clinical presentation

The diagnosis of an ABC from clinical aspect can be challenging with variable clinical presentation. Clinical presentation is highly dependent on the location of the ABC. The most common presentation of ABC in sino-nasal region relates to the presence of the expansile sockets against lamina papyracea [13]. The patient can be presented with nasal obstruction and/or facial heaviness. Epistaxis is a relatively rare presentation, since it has been reported in literatures in only two cases [3]. In the review by Hnenny et al. [14], they report that lesions affecting the skull base are more likely to present with neurological deficits including anosmia, ataxia, otalgia, facial numbness, and hearing loss.

4.2 Radiological diagnosis

Imaging studies, namely, CT scan and MRI, are essential to help with diagnosis and to plan the surgical procedure needed. ABC demonstrates the presence of

expansile, lucent bony lesion surrounded by osseous remodeling and cortical thinning in CT scan [15]. In MRI images, ABC showed as multiple fluid-fluid levels of varying signal intensities. Although the fluid levels seen are nonspecific, the fact that fluid is trapped in multiple separate cavities is suggestive of ABC in both CT scan and MRI [16]. The signal characteristics are also dependent on the age of any blood products within the lesion. Other MRI features include the presence of multiple internal septations and a “soap bubble” appearance due to the presence of small cysts projected from larger cysts [13].

4.3 Definitive diagnosis

Despite all the imaging appearances suggestive of ABC, histological confirmation is essential for diagnosis. Histological evaluation of the suspected lesion is mandatory for diagnosing ABCs accurately. Ultimately, histological evaluation is key, and ABCs typically demonstrate irregular, blood-filled chambers with islands of bone and fibrous tissue [17]. In gross appearance, ABCs are spongy, hemorrhagic masses covered by a thin shell of the reactive bone. Microscopically, ABCs showed abundant red blood cells with pale brown hemosiderin that is filling cyst-like spaces and bounded by septal proliferations of fibroblasts, with mitotically active spindle cells, osteoid, calcifications, and scattered multinucleated giant cells [18]. The principal diagnostic error occurs if the histologist fails to appreciate the lining of the blood-filled spaces [2].

4.4 Treatment

The treatment of choice for ABCs is complete surgical resection, with endoscopic sinus surgery becoming the gold standard of management of aneurysmal bone cyst. Complete clearance of ABC is sometimes impossible especially at the skull base. In difficult extensive cases, further surgical procedures to debulk the lesion may be needed. Radiotherapy has been reported in cranial ABCs for refractory cases in adults. Radiotherapy has a limited success with an accepted risk of sarcomatous degeneration [9]. However, as there is a paucity of information for ethmoidal lesions particularly in children, there exists no clear consensus for radiotherapy [13].

4.5 Prognosis and recurrence

Patients needed to be followed up for quite long time with no specific adequate follow-up time reported in literatures [19]. ABCs are aggressive benign lesions with high rates of recurrence rendering its treatment uniquely challenging [20]. Recurrence can have occurred in up to 26% of cases more in jaws with most of the recurrences seem to occur within 1 year of surgical treatment [3].

5. Conclusion

Aneurysmal bone cyst is a benign, nonneoplastic lesion that presents most frequently under the age of 20 years. The metaphysis of long bones is the usual site of origin. Although the involvement of the skull is rare (2.5–6% of such cases reported in the literature), the skull vault is more often the site than the skull base. Benign ABCs are locally destructive entities which may occasionally present to otolaryngologists, since they can involve the head and neck region. ABC should be suspected, if a cystic mass in nasal cavity that is rapidly growing with fluid-fluid level in CT scan is encountered.

Acknowledgements

I acknowledge the help and support from my colleague Dr. Yasser AlNufaily, who was my assistant in conducting the endoscopic surgical removal of the case. As well as, our institution histopathology department staff who conducted an extensive review at consultant level to discuss the case and reach into the definitive diagnosis. No funding was provided to accomplish this write up for publication.

Conflict of interest

No conflict of interest.

Thanks

Thanks to our trainee resident Dr. Lina Telmsani, who helped in managing the patient’s condition.

Abbreviations

ABC	aneurysmal bone cyst
ABCs	aneurysmal bone cysts

Author details

Zeinab AlQudehy^{1*} and Lena Telmesani²

1 Dammam Medical Complex, Saudi Arabia

2 King Fahd Hospital of University, Dammam University, Saudi Arabia

*Address all correspondence to: drzeinabent@gmail.com

IntechOpen

© 2019 The Author(s). Licensee IntechOpen. This chapter is distributed under the terms of the Creative Commons Attribution License (<http://creativecommons.org/licenses/by/3.0>), which permits unrestricted use, distribution, and reproduction in any medium, provided the original work is properly cited.



References

- [1] Jacob G, Srugo I, Attias D, et al. Giant pediatric aneurysmal bone cysts of the occipital bone: Case report and review of the literature. *Pediatric Neurology*. 2011;**45**:42-44
- [2] Fennessy BG, Vargas SO, Silvera MV, et al. Paediatric aneurysmal bone cysts of the head and neck. *The Journal of Laryngology and Otology*. 2009;**123**:635-641
- [3] Girish B, Veena C, Rashmi D, Vivek CK, Rajat J. Aneurysmal bone cyst of ethmoid sinus: Uncommon manifestation of a rare case. *European Journal of Radiology Extra*. 2009;**70**:49-51
- [4] Sanjib KU, Ashok KJ, Satyendra S, Satrugan PS, Subhash CM. Aneurysmal bone cyst of paranasal sinuses. *Indian Journal of Otolaryngology and Head and Neck Surgery*. 2002;**54**:305-307
- [5] Hl J. Solitary unicameral bone cyst. *Archives of Surgery*. 1942;**44**(6):1004
- [6] Jacob G et al. Giant pediatric aneurysmal bone cysts of the occipital bone: Case report and review of the literature. *Pediatric Neurology*. 2011;**43**(2):42-44
- [7] Copley L, Dormans JP. Benign pediatric bone tumors. Evaluation and treatment. *Pediatric Clinics of North America*. 1996;**43**(4):949-966
- [8] Leithner A et al. Aneurysmal bone cyst. A population based epidemiologic study and literature review. *Clinical Orthopaedics and Related Research*. 1999;**(363)**:176-179
- [9] Guida F, Rapanà A, Conti C, Cagliari E, Civelli F, Trincia G. Cranial aneurysmal bone cyst: A diagnostic problem. With a review of the literature. *Child's Nervous System*. 2001;**17**:297-301
- [10] Ye Y et al. TRE17/USP6 oncogene translocated in aneurysmal bone cyst induces matrix metalloproteinase production via activation of NF kappaB. *Oncogene*. 2010;**29**(25):3619-3629
- [11] Bonakdarpour A, Levy WM, Aegerter E. Primary and secondary aneurysmal bone cyst: A radiological study of 75 cases. *Radiology*. 1978;**126**(1):75-83. DOI: 10.1148/126.1.75
- [12] Martinez V, Sissons HA. Aneurysmal bone cyst. A review of 123 cases including primary lesions and those secondary to other bone pathology. *Cancer*. 1988;**61**(11):2291-2304
- [13] Unadkat S et al. Paediatric aneurysmal bone cyst: Not as easy as ABC. *Journal of Surgical Case Reports*. 2018;**2018**(2):rjy008
- [14] Hnenny L et al. Giant aneurysmal bone cyst of the anterior cranial fossa and paranasal sinuses presenting in pregnancy: Case report and literature review. *Journal of Neurological Surgery Reports*. 2015;**76**:e216-e221
- [15] Hashemi SM et al. A rare case of aneurysmal bone cyst in the paranasal sinus. *Iranian Journal of Otorhinolaryngology*. 2015;**27**:395-399
- [16] Senol U et al. Aneurysmal bone cyst of the orbit. *AJNR. American Journal of Neuroradiology*. 2002;**23**:319-321
- [17] Mankin HJ et al. Aneurysmal bone cyst: A review of 150 patients. *Journal of Clinical Oncology*. 2005;**23**:6756-6762
- [18] Kumar V, Abbas AK, Aster JC. *Robbins and Cotran Pathologic Basis of Disease*. Philadelphia: Elsevier Saunders; 2015

[19] Bassem YS, Imad K, Jehad W, Abdulrahman E, Zoltan P. Aneurysmal bone cyst involving the skull base: A report of three cases. *Skull Base Surgery*. 1999;**9**:145-148

[20] Park HY et al. Current management of aneurysmal bone cysts. *Current Reviews in Musculoskeletal Medicine*. 2016;**9**(4):435-444

IntechOpen

IntechOpen