

We are IntechOpen, the world's leading publisher of Open Access books Built by scientists, for scientists

6,900

Open access books available

186,000

International authors and editors

200M

Downloads

Our authors are among the

154

Countries delivered to

TOP 1%

most cited scientists

12.2%

Contributors from top 500 universities



WEB OF SCIENCE™

Selection of our books indexed in the Book Citation Index
in Web of Science™ Core Collection (BKCI)

Interested in publishing with us?
Contact book.department@intechopen.com

Numbers displayed above are based on latest data collected.
For more information visit www.intechopen.com



Diagnosis of Multiple Sclerosis

Joyce Pauline Joseph

Abstract

Multiple sclerosis (MS) is a chronic inflammatory demyelinating disorder of the central nervous system. Although there are no pathognomonic features to confirm the diagnosis of this immune-mediated disease, a constellation of clinical, radiological, and immune studies can ensure the clinician gets a more definitive diagnosis. Criteria have been made every few years based on research to clinch the diagnosis. The most recent criteria which are the McDonald criteria have been formed in 2001 and revised in 2005, 2010, and 2017. Most criteria are to be used only as a guide to facilitate the diagnosis of multiple sclerosis. Advances in demyelinating disorders will require diagnostic criteria to be revised every few years with scientists hoping for a more definitive and confirmative diagnosis. The cardinal features for diagnosis are dissemination in time and space. There should be no other possible explanation to the clinical features.

Keywords: multiple sclerosis, diagnosis, criteria, dissemination in time, dissemination in space

1. Introduction

Multiple sclerosis is an immune-mediated disease involving the central nervous system predominantly affecting the brain, spinal cord, and optic nerves. There is no gold standard or pathognomonic features that can distinguish MS from other neurological conditions with multiple anatomical site involvement. A comprehensive history obtained from the patient, clinical examination with the support of laboratory investigations with is required to assist in the diagnosis of MS. The key to diagnosis has always been dissemination in time, which translates into different time interval of clinical relapse, and dissemination of space, which is a variable anatomical site in the central nervous system. Hence difference in time and neuro-anatomical site is essential. Several criteria have been created over the last several decades such as Schumacher criteria, [1], Poser criteria [2], and McDonald criteria [3–5]. McDonald criteria has been first established in 2001 and revised in 2005, 2010, and 2017. Revisions are necessary due to evolving research and advances in the field of demyelinating diseases. Researchers in neuroimmunology diseases concurred the diagnosis of MS could be made earlier and can be used for paediatric population and Asian patients [5]. Investigations are done for diagnosis of MS to ensure there are no other possible explanations for the clinical and radiological presentation. As the patient can be subjected to lifelong immune modulators and immunosuppressant, it is highly essential to ensure diagnosis is made accurately and possible differentials are monitored during follow-up. A clinician's job does not end with establishing diagnosis and instituting treatment. Careful surveillance is necessary to ensure we are in the right track as regards to the diagnosis. Misdiagnosis

could still occur, and therefore it must be addressed, and measures should be undertaken to minimise them.

2. Making the diagnosis: symptoms and signs

Awareness about MS is crucial for the patient to seek attention, and to ask for a second opinion when necessary is important both for patients and healthcare providers. A good history with a knowledge of common presentations and bearing in mind neuroanatomical sites involved will be valuable in coming to a conclusion, and focused investigations will be needed. Knowledge of subtypes and classification will be helpful to the clinician.

Four subtypes of multiple sclerosis are used [6].

Active or disease activity is measured by clinical relapses and MRI evidence of contrast-enhanced lesion or new or enlarging lesion on T2-weighted images by annual clinical assessment.

Progression-progressive disability by annual clinical assessment

If no annual assessment is done, it is called indeterminate.

- Clinically isolated syndrome
 - Active
 - Not active
- Relapsing-remitting multiple sclerosis
 - Active
 - Not active
- Primary progressive disease
 - Active with progression
 - Active but without progression
 - Not active but with progression
 - Not active and without progression
- Secondary progressive disease
 - Active with progression
 - Active but without progression

2.1 Optic nerve

Optic nerve involvements are common and often the first presentation in multiple sclerosis [7]. The severity can vary from being asymptomatic to severe visual loss, and recovery could be complete, partial, or no resolution. The symptoms could begin as pain behind the eye and evolve into visual impairment in the centre of the

eye and may worsen till visual acuity is lost. Diminished colour appreciation or dyschromatopsia may be seen. The pain associated with ON tends to progress over days. Visual improvement may occur in 3–8 weeks, and most visual recovery occurs within the first 6 months but can continue for up to 1 year after the acute event [8–12]. However, many patients may experience residual and variable visual complaints and dysfunction after recovery. Examination on optic neuritis could reveal no abnormalities, and deficits are present; there may be disc swelling, fine haemorrhages, impaired visual acuity, central or centrocecal oedema, relative afferent pupillary defect or Marcus Gunn pupil, impaired colour vision, and pale optic discs [11]. Phosphenes, which are an experience of bright flashes of light without light entering the eye, Uhthoff's phenomenon where there is brief blurring of vision during physical exercise [13].

2.2 Spinal cord

Numbness and weakness of upper and or lower limbs are presentations seen in spinal cord lesions in MS [14]. Cord lesions also come with urinary incontinence, frequency, and urinary retention depending on the level and severity involved. Constipation and diarrhoea could relate to bowel dysfunction. The symptoms are of corticospinal tract lesion; a clear sensory level might guide the clinician to focus on a cord lesion rather than a peripheral lesion due to a lower motor neuron lesion. Clinical assessment may reveal increased tone, monoparesis, hemiparesis and quadriparesis, abnormal cutaneous and sensory deficit, and sphincter disturbance [14]. The clinical diagnosis involving the cord is called myelitis.

2.3 Brainstem

Double vision, speech difficulty, swallowing difficulty, nausea, vomiting, hiccups, vertigo, unsteadiness, and weakness of limbs are symptoms seen in brainstem lesions. Examination would reveal nystagmus, ophthalmoplegia, dysarthria, and facial weakness [14]. Cranial nerve deficits involving III–XII may be seen. Cerebellar connection with the brainstem can cause dysdiadochokinesia, dysmetria, and ataxia [15]. Brainstem lesions could also cause respiratory failure and locked-in syndrome. Localization of the neuroanatomical site can be judged based on the symptoms prior to neuroimaging.

2.4 Cerebellum

Unsteadiness involving upper and lower limbs, gait instability, and dysarthria are common symptoms seen in structures involving the cerebellum. Tremors, which are either due to cerebellar or thalamic involvement, could occur, and they result in tremor affecting limbs, trunk, and vocal cord, and head. Types of tremors are intention, postural, rest, and rubral (Alistair [16]). Cerebellar signs will be evident with a significant involvement of the cerebellum. A pure cerebellar syndrome is rare and other causes must be investigated. Tremors in cerebellar involvement affect arms, legs, head, and trunk in descending order of frequency. Face, tongue, and jaw were not affected in a study done by Alusi et al. [17].

2.5 Cerebrum

Symptoms involving the cerebral hemispheres correlate the site of lesion such as the parietal, temporal, frontal, and occipital lobes. Symptoms are right- or left-sided hemianaesthesia, hemiparesis, hemiplegia, or monoplegia and visual

symptoms due to visual field defect. Aphasia or dysphasia and epilepsy are rare symptoms noted in MS [13].

2.6 Symptoms of multiple sclerosis in chronic disease

Spasticity, cognitive dysfunction, fatigue, affective disorders, and sexual dysfunction are normally seen in chronic disease [13]. An in-depth history during the first clinical assessment is a valuable asset to establishing the diagnosis.

3. Investigations in MS

3.1 Blood investigations

There are no blood investigations that are pathognomonic for the diagnosis of multiple sclerosis. However, in order to rule out other neurological conditions that can mimic MS, a complete workout is necessary. Screening for connective tissue diseases such as Systemic Lupus Erythematosus, antiphospholipid antibody, retroviral screen, other autoimmune condition such as thyroid disease, infectious diseases, Lyme disease and angiotensin converting enzyme are necessary [18].

3.2 Lumbar puncture

Lumbar puncture for CSF analysis is required as it can further assist in the diagnosis as its presence reveals a risk of developing MS in patients with clinically isolated syndrome [3, 5, 19]. In 2017, cerebrospinal fluid (CSF) is done to look for oligoclonal band and immunoglobulin G (IgG), and a parallel serum sample need to be taken as no OCB production is noted in the blood in multiple sclerosis. Oligoclonal band and immunoglobulin G are indicative of intrathecal inflammation which is B cell modulated from plasma cells seen in CNS inflammatory disease [20]. Distinctive CSF analysis will disclose slightly raised leucocyte count, B cells, or plasma cells in cytological analysis and raised IgG synthesis [21]. Oligoclonal band will be highly helpful in the event of other clinical features that are not diagnostic, and furthermore it depicts dissemination in space. Lumbar puncture is recommended in the following situations [5]:

- When clinical and MRI evidence is inadequate to make diagnosis of multiple sclerosis, especially if treatment is considered
- When there are atypical features of clinically isolated syndrome and in population where MS is less common such as children, older individuals, or non-white populations

The Panel on Diagnosis of Multiple Sclerosis [5] cautions diagnosis of multiple sclerosis early on in the disease and in children when OCB is negative in atypical clinical, radiological, or OCB findings.

There are two methods of analysing the CSF for oligoclonal band agarose gel electrophoresis/Coomassie Blue Staining and isoelectric focus/silver staining [22]. Oligoclonal bands are positive in up to 95% of patients with clinically definite multiple sclerosis.

3.3 Evoked potentials

Evoked potentials are electrophysiological tests done to look for evidence of silent lesions [23]. Abnormal or slowing of electrical conduction along the central

nervous system pathway can be detected even when there are no obvious clinical features seen. Visual evoked potentials are visual stimulation, which consists high contrast black and white checkerboard where these squares, are changed places and response to this reversal is recorded. Delayed waveform depicts an optic nerve lesion. Brainstem evoked potentials are when auditory stimulations in the form of clicks are given for a response obtained from the brainstem. It assesses lower brainstem auditory pathway. The BAEP are abnormal when demyelination involves brainstem. Somatosensory evoked potentials are obtained when stimulation from the peripheral nerves in the upper limbs produces a response. An abnormal response could translate to demyelination within the central fibres of dorsal column-medial lemniscal pathways. Evoked potentials may not be useful with advances in MRI techniques and oligoclonal band, and they have not been included in McDonald criteria 2017.

3.4 Magnetic resonance imaging

Magnetic resonance imaging (MRI) is a neuroimaging of choice for diagnosis of MS and plays a key role in research, surveillance, and treatment. Although the McDonald criteria denote that two clinical attacks depicting dissemination in time and space are sufficient to make a diagnosis, neurologists and neurologist with interest in MS would require a baseline MRI to confirm diagnosis and for surveillance. White matter lesions in the MRI are characteristic with typical juxtacortical, cortical; periventricular, brainstem and spinal cord lesions are required. MRI protocols used in MS are spin echo T2 weighted, fluid-attenuated inversion recovery. The Consortium of MS Centres revised and updated guidelines for MRI ([24], www.ms-care.org/mri).

3.4.1 MRI protocols adapted from the Consortium of MS Centers

Baseline studies for patients with a clinically isolated syndrome (CIS) and/or suspected MS:

- Brain MRI protocol with gadolinium at baseline and to establish dissemination in time
- Spinal cord MRI if myelitis, insufficient features on brain MRI to support diagnosis, or age > 40 years with nonspecific brain MRI findings
- A cervical cord MRI performed simultaneously with the brain MRI could have prognostic value in the evaluation of CIS patients with or without myelitis and would reduce the number of patients requiring a subsequent MRI appointment
- Orbital MRI if severe optic neuritis with poor recovery

Timing of a follow-up brain MRI protocol for patients with a CIS and/or suspected MS to look for evidence of dissemination in time (i.e. new T2 lesions or gadolinium-enhancing lesions):

- 6–12 months for high-risk CIS (e.g. ≥ 2 ovoid lesions on first MRI)
- 12–24 months for low-risk CIS (i.e. normal brain MRI) and/or uncertain clinical syndrome with suspicious brain MRI features (e.g. radiologic isolated syndrome [RIS])

Timing of brain MRI protocol for patients with an established diagnosis of MS:

- No recent prior imaging available (e.g. patient with established diagnosis of MS and new to your clinical practice)
- Postpartum to establish a new baseline
- Prior to starting or switching disease-modifying therapy
- Approximately 6–12 months after switching disease-modifying therapy to establish a new baseline on the new therapy
- Every 1–2 years while on disease-modifying therapy to assess for subclinical disease activity (i.e. new T2 lesions or gadolinium-enhancing lesions). Less frequent MRI scans required in clinically stable patients after 2–3 years of stable treatment (gadolinium-based contrast optional)
- Unexpected clinical deterioration or reassessment of original diagnosis (gadolinium-based contrast recommended)
- The use of gadolinium-based contrast agents is helpful but not essential for detecting subclinical disease activity because new T2 MS lesions can be identified on well-performed standardized MR imaging unless there is a large T2 lesion burden, which may obscure new T2 lesion activity.

4. Diagnosis of MS with McDonald criteria

The International Panel on Diagnosis of Multiple Sclerosis consists of 30 members of European, American, and Asian representatives who are experts in their field, met in 2016 and 2017 to revise and formulate a new guideline based on advances on MS. The criteria are to be used only in the setting of clinically isolated syndrome to diagnose MS and progressive MS [5].

4.1 Optical coherence tomography

Optical coherence tomography (OCT) is a noninvasive cross-sectional imaging in biological systems [26]. OCT assesses the peripapillary area of the retina. Retinal nerve fibre layer and ganglion cell layer thickness loss affects visual function, disability, and magnetic resonance imaging. OCT angiography is a new technique under study in MS [27]. Retinal nerve fibre thinning is seen in multiple sclerosis, and OCT is able to measure the loss. Fundoscopy is the clinical parallel of OCT.

5. Common differential diagnosis

Clinicians should bear in mind multiple sclerosis mimickers to ensure there is no other possible explanation. Common differentials are connective tissue disease such as systemic lupus erythematosus and antiphospholipid antibody syndrome. Neuromyelitis optical spectrum disorder, which was previously known as Devic's disease, is an immune-mediated disorder that can be distinguished, from MS by typical MRI lesions and/or anti-aquaporin 4 antibody. Other conditions are acute disseminated meningoencephalitis, small vessel disease, and Susac's syndrome.

5.1 Neuromyelitis optica spectrum disorder

Neuromyelitis optica spectrum disorder is often considered as a differential of MS. It was considered as a part and spectrum of Multiple sclerosis, till Aquaporin 4 antibody serum antibodies [28, 29] that target the water channel aquaporin 4 was considered in the pathogenesis of NMOSD. It is essential to differentiate multiple sclerosis and NMOSD as the treatment differs in both, and some treatment could be harmful.

Diagnostic criteria for NMOSD[30].

Diagnostic criteria for NMOSD with AQP4-IgG

1. At least one core clinical characteristic
2. Positive test for AQP4-IgG using best available detection method (cell-based assay strongly recommended)
3. Exclusion of alternative diagnoses

Diagnostic criteria for NMOSD without AQP4-IgG or unknown AQP4-IgG status:

1. At least two core clinical characteristic occurring as a result of one or more clinical attacks and meeting all of the following requirement:
2. At least one core clinical characteristic must be optic neuritis, acute myelitis with LETM, or area postrema syndrome
3. Dissemination in space (two or more core clinical characteristics)
4. Fulfilment of additional MRI requirements, as applicable
5. Negative test for AQP4-IgG using the best available detection method or testing unavailable
6. Exclusion of alternative diagnoses

Core clinical characteristics:

1. Optic neuritis
2. Acute myelitis
3. Area postrema syndrome: episode of otherwise unexplained hiccups or nausea and vomiting
4. Acute brainstem syndrome
5. Symptomatic narcolepsy or acute diencephalic clinical syndrome with NMOSD-typical diencephalic MRI lesions

Symptomatic cerebral syndrome with NMOSD-typical brain lesions

Additional MRI requirements for NMOSD without AQP4-IgG or unknown AQP4-IgG status:

- Acute optic neuritis
 - Requires brain MRI showing
 - Normal findings or only nonspecific white matter lesions, OR
 - Optic nerve MRI with T2-hyperintense lesion, or T1-weighted gadolinium-enhancing lesion extending over 1/2 optic nerve length or involving optic chiasm
- Acute myelitis: requires associated intramedullary MRI lesion extending over three or more contiguous segments (LETM) OR three or more contiguous segments of focal spinal cord atrophy in patients with history compatible with acute myelitis
- Area postrema syndrome: requires associated dorsal medulla/area postrema lesions
- Acute brainstem syndrome: requires associated periependymal brainstem lesions.

5.2 MOG antibody disease

Seronegative NMOSD patients have been associated with MOG antibody disease, which is a myelin oligodendrocyte glycoprotein and which is found only in the central nervous system. Myelin oligodendrocyte glycoprotein is a small part of myelin [31]. MOG can be found in extracellular surface of myelin sheaths and oligodendrocytes. MOG antibodies were seen in several demyelinating diseases of the central nervous system disorders [32, 33]. MOG antibody disease tends to favour women, which is one third of patients (**Figure 1**).

B-cell activation is the strongest element seen in central nervous system of multiple sclerosis patients. Central nervous system-directed antibodies are produced in the periphery in neuromyelitis optica and myelin oligodendrocyte glycoprotein antibody disease. MRZ reaction is antibodies against measles, rubella, and varicella zoster (**Tables 1–3**).

5.3 Acute disseminated encephalomyelitis

Acute disseminated encephalomyelitis (ADEM) is a central nervous system-demyelinating disease predominantly involving children and young adults. It has been noted in adults and elderly; it follows vaccination and postinfectious state. It is commonly monophasic and rarely multiphasic in nature, and it can involve the brain, spinal cord, and optic nerves as in multiple sclerosis. Fever, malaise, myalgias, headache, nausea, and vomiting can precede neurological symptoms of ADEM, which can begin 4–21 days after the antecedent event. Clinical features of ADEM are the development of a focal or multifocal neurological disorder which could be encephalopathy, coma, and focal and multifocal neurological signs like hemiparesis, cranial nerve palsies, paraparesis, meningismus, ataxia, movement disorders, and seizure [36]. The International Paediatric Multiple Sclerosis Study Group (IPMSSG) [37] proposed consensus definitions for paediatric-acquired

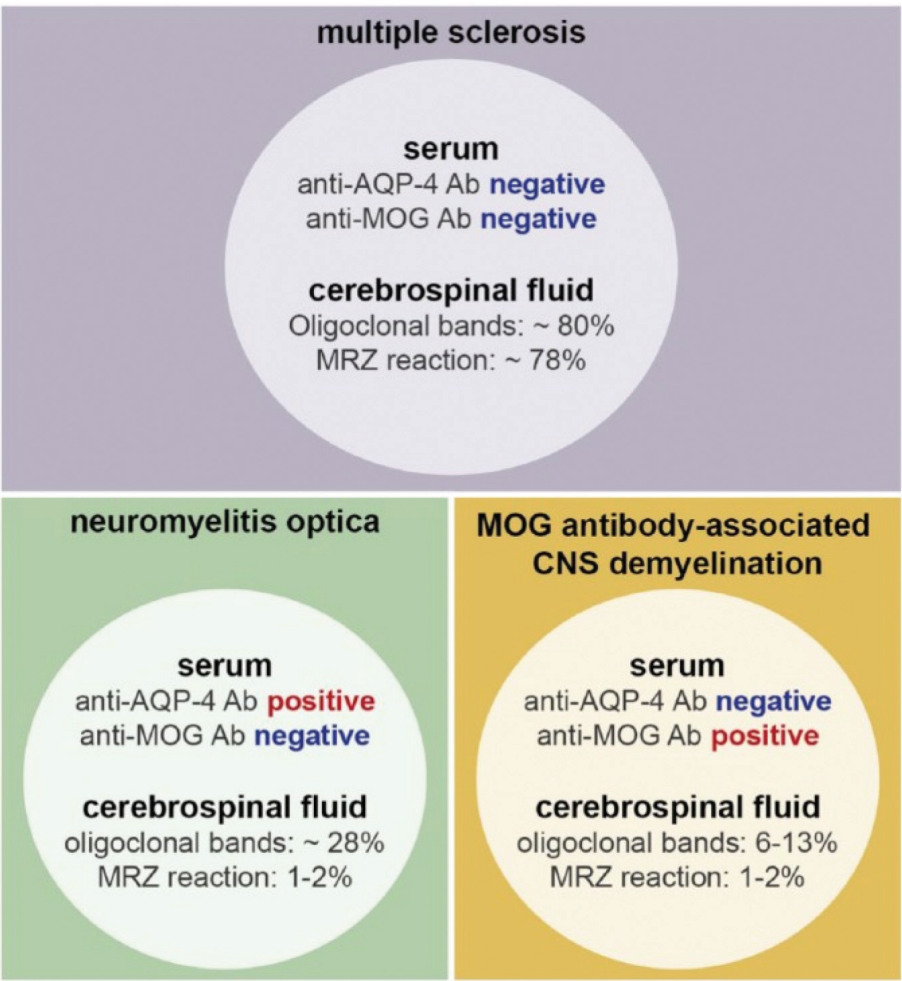


Figure 1.
Biomarkers in Multiple sclerosis, Neuromyelitis Optica Spectrum Disorder and MOG antibody disease. MRZ reaction are antibodies against measles, rubella and varicella zoster. (Adapted from [34]).

demyelinating disorders of the CNS to clarify the terminology for demyelination disease, and this was further updated in 2013 [38]. ADEM criteria require the following:

Monophasic ADEM:

- i. A first polyfocal clinical neurological event with presumed inflammatory cause
- ii. Encephalopathy that cannot be explained by fever is present
- iii. No new clinical or radiological evidence of a new event suggestive of ADEM after 3 months

Multiphasic ADEM



- i. A new onset of ADEM in 3 or more months after the primary event
- ii. A new onset or reappearance of ADEM linked to previous clinical or radiological event involving the central nervous system
- iii. Time of symptom onset in relation to steroids has no relevance

ADEM should be a diagnosis of exclusion and should be differentiated from multiple sclerosis from its clinical and radiological profile.

Protocol 1: Standardised brain MRI protocol (diagnosis and routine follow-up of MS)	
Field strength	Scans should be of good quality, with adequate signal-noise ratio (SNR) and spatial resolution (in-slice pixel resolution of $\leq 1 \times 1$ mm)
Scan prescription	Use the subcallosal plane to prescribe or reformat axial oblique slices
Coverage	Whole brain coverage
Slice thickness and gap	≤ 3 mm, no gap (for 2D acquisition Or 3D1 reconstruction)
Core sequences	2D/3D sagittal and Axial FLAIR1,2. 2D/3D axial T21 Axial 2D DWI3 3D IR-Prep GE4 T1
Gadolinium5 (as required)	Post-gad 2D/3D axial T1
Additional sequences	Susceptibility-weighted imaging (SWI). Pre-gad 2D/3D axial T1
Axial proton density	
<ol style="list-style-type: none">3D acquisition should be isotropic $\leq 1 \times 1 \times 1$ mmFluid attenuated inversion recovery (FLAIR)Diffusion-weighted imaging (DWI)Inversion recovery-prepared gradient echo (IR-Prep GE); magnetization-prepared rapid acquisition gradient echo or MP-RAGE; turbo field echo Or TFESingle dose of gadolinium-based contrast agent as required (note that the FLAIR Or T2 may be performed during the 5-minute minimum delay after gadolinium injection before acquiring the post-gadolinium T1)	
Protocol 2: PML surveillance brain MRI protocol	
Field strength	Scans should be of good quality, with adequate signal-noise ratio (SNR) and resolution (in-slice pixel resolution of $\leq 1 \times 1$ mm)
Scan prescription	Use the subcallosal plane to prescribe or reformat axial oblique slices
Coverage	Whole brain coverage
Core sequences1	2D/3D sagittal and axial FLAIR2 axial 2D DWI3
Gadolinium (can be helpful) 4	Post-gad 2D/3D axial T1
Additional sequences	DWI 2D/3D axial T2 3D IR-Prep GE5 T1 Pre-gad 2D/3D axial T1. Axial proton density
Slice thickness and gap	< 3 mm, no gap (for 2D acquisition or 3D reconstruction)
<ol style="list-style-type: none">Typical PML lesions may appear hyperintense on FLAIR, hypointense on T1, and high signal intensity on DWIFluid attenuated inversion recovery (FLAIR)Diffusion-weighted imaging (DWI)Less than 50% of PML lesions will show contrast enhancementInversion recovery-prepared gradient echo (IR-Prep GE); magnetization-prepared rapid acquisition gradient echo or MP-RAGE; turbo field echo or TFE	
Protocol 3: Spinal cord MRI protocol	
Field strength	Scans should be of good quality, with adequate signal-noise ratio (SNR) and resolution (in-slice pixel resolution of $\leq 1 \times 1$ mm)
Coverage	Cervical cord coverage1
Core sequences	Two of the following: sagittal T2

	Proton density STIR2
	T1-PSIR3
	Axial T2/T2* through lesions
Slice thickness and gap	Sagittal: <3 mm, no gap. Axial: <5 Mm, no gap
Additional sequences	Sagittal T1
	Post-gad T14 (sag, axial)
	Axial T2/T2* entire cervical cord 3D IR-Prep GE5 T1
	1. Thoracic and conus coverage recommended if symptoms localize to this region to rule out an alternate diagnosis
	2. Short tau inversion recovery (STIR)
	3. Phase-sensitive T1 inversion recovery (PSIR)
	4. No additional gadolinium necessary if cord examination immediately follows gadolinium-enhanced brain MRI
	5. IR-Prep GE (inversion recovery-prepared gradient echo); magnetization-prepared rapid acquisition gradient echo or MP-RAGE; turbo field echo or TFE
Protocol 4: Orbit MRI protocol	
	<ul style="list-style-type: none">• May be clinically indicated to confirm optic neuritis and rule out compressive lesions• Recommended sequences include coronal STIR or fat-suppressed T2 and a post-gadolinium fat-suppressed T1 with a section thickness of ≤ 2 Mm, with coverage to include the optic chiasm• Optional sequences may include axial/coronal pre-gadolinium fat-sat T1, axial fat-sat T2 or STIR, and axial post-gad fat-sat T1
	Recommendations for communication
	MRI requisition:
	The clinician should provide on the request for the standardized MRI brain and/or spinal cord protocol:
	<ul style="list-style-type: none">• Clinical questions to be addressed *diagnosis
	*Monitoring for management decision
	<ul style="list-style-type: none">• Relevant clinical history and physical examination findings• Current MS disease-modifying treatment and JC virus status if on natalizumab• If known, date and place of previous examinations
	MRI report:
	Standardised nomenclature/terminology should be used and include:
	1. Description of findings
Scan	<ul style="list-style-type: none">• *Lesion type, location, size, shape, character, number for diagnostic• *CIS diagnostic scan: whether meets current MRI dissemination in space or dissemination in time criteria• *Qualitative assessment of T2 and brain volume/atrophy
	2. MS monitoring or CIS follow-up: comparison with previous studies (new lesions, atrophy)
	3. Interpretation (typical for MS, atypical for MS, not MS) and differential diagnosis, if appropriate
	Note: structured reports can be helpful (Alessandrino et al., <i>Ajr</i> , 2018; Dickerson et al., <i>J Am Coll Radiol</i> 2017).
	Recommendations:
	*Studies should be stored in a DICOM format.
	*Copies of MRI studies should be retained permanently and be available.
	*It is strongly recommended for patients to keep their own studies on Portable digital media

Table 1.
MRI protocols (Adapted from [25]).

<div><div><div>National Multiple Sclerosis Society</div></div><div>2017 McDonald Criteria for the Diagnosis of Multiple Sclerosis</div><div><div>EUROPEAN COMMITTEE FOR TREATMENT AND RESEARCH IN MULTIPLE SCLEROSIS</div></div></div> <div>Diagnosis of MS requires elimination of more likely diagnoses and demonstration of dissemination of lesions in the CNS in space and time. See Lancet Neurology paper* for details.</div> <table><tr><th>CLINICAL PRESENTATION</th><th>ADDITIONAL DATA NEEDED TO MAKE MS DIAGNOSIS</th></tr><tr><td colspan="2">...in a person with a typical attack/CIS at onset (see KEY below for definitions)</td></tr><tr><td>• ≥2 attacks and objective clinical evidence of ≥2 lesions</td><td>None. Dissemination in space (DIS) and dissemination in time (DIT) have been met.</td></tr><tr><td>• ≥2 attacks and objective clinical evidence of 1 lesion with historical evidence of prior attack involving lesion in different location</td><td>One of these criteria: - DIS: additional clinical attack implicating different CNS site - DIS: ≥1 symptomatic or asymptomatic MS-typical T2 lesions in ≥2 areas of CNS: periventricular, juxtacortical/cortical, infratentorial or spinal cord</td></tr><tr><td>• ≥2 attacks and objective clinical evidence of 1 lesion</td><td>One of these criteria: - DIT: additional clinical attack - DIT: simultaneous presence of both enhancing and non-enhancing symptomatic or asymptomatic MS-typical MRI lesions - DIT: new T2 or enhancing MRI lesion compared to baseline scan (without regard to timing of baseline scan) - CSF-specific (i.e. not in serum) oligoclonal bands</td></tr><tr><td>• 1 attack and objective clinical evidence of ≥2 lesions</td><td>One of these criteria: - DIT: additional clinical attack - DIT: simultaneous presence of both enhancing and non-enhancing symptomatic or asymptomatic MS-typical MRI lesions - DIT: new T2 or enhancing MRI lesion compared to baseline scan (without regard to timing of baseline scan) - CSF-specific (i.e. not in serum) oligoclonal bands</td></tr></table> <div>CONTINUED ON REVERSE</div> <div>Colored text = revisions compared to previous McDonald Criteria KEY: CIS: clinically isolated syndrome CNS: central nervous system CSF: cerebrospinal fluid DIS: dissemination in space DIT: dissemination in time T2 lesion: hyperintense lesion on T2-weighted MRI *Thompson AJ, et al. Lancet Neurol 2017; online Dec 21. http://dx.doi.org/10.1016/S1474-4422(17)30470-2.</div>		CLINICAL PRESENTATION	ADDITIONAL DATA NEEDED TO MAKE MS DIAGNOSIS	...in a person with a typical attack/CIS at onset (see KEY below for definitions)		• ≥2 attacks and objective clinical evidence of ≥2 lesions	None. Dissemination in space (DIS) and dissemination in time (DIT) have been met.	• ≥2 attacks and objective clinical evidence of 1 lesion with historical evidence of prior attack involving lesion in different location	One of these criteria: - DIS: additional clinical attack implicating different CNS site - DIS: ≥1 symptomatic or asymptomatic MS-typical T2 lesions in ≥2 areas of CNS: periventricular, juxtacortical/cortical , infratentorial or spinal cord	• ≥2 attacks and objective clinical evidence of 1 lesion	One of these criteria: - DIT: additional clinical attack - DIT: simultaneous presence of both enhancing and non-enhancing symptomatic or asymptomatic MS-typical MRI lesions - DIT: new T2 or enhancing MRI lesion compared to baseline scan (without regard to timing of baseline scan) - CSF-specific (i.e. not in serum) oligoclonal bands	• 1 attack and objective clinical evidence of ≥2 lesions	One of these criteria: - DIT: additional clinical attack - DIT: simultaneous presence of both enhancing and non-enhancing symptomatic or asymptomatic MS-typical MRI lesions - DIT: new T2 or enhancing MRI lesion compared to baseline scan (without regard to timing of baseline scan) - CSF-specific (i.e. not in serum) oligoclonal bands
CLINICAL PRESENTATION	ADDITIONAL DATA NEEDED TO MAKE MS DIAGNOSIS												
...in a person with a typical attack/CIS at onset (see KEY below for definitions)													
• ≥2 attacks and objective clinical evidence of ≥2 lesions	None. Dissemination in space (DIS) and dissemination in time (DIT) have been met.												
• ≥2 attacks and objective clinical evidence of 1 lesion with historical evidence of prior attack involving lesion in different location	One of these criteria: - DIS: additional clinical attack implicating different CNS site - DIS: ≥1 symptomatic or asymptomatic MS-typical T2 lesions in ≥2 areas of CNS: periventricular, juxtacortical/cortical , infratentorial or spinal cord												
• ≥2 attacks and objective clinical evidence of 1 lesion	One of these criteria: - DIT: additional clinical attack - DIT: simultaneous presence of both enhancing and non-enhancing symptomatic or asymptomatic MS-typical MRI lesions - DIT: new T2 or enhancing MRI lesion compared to baseline scan (without regard to timing of baseline scan) - CSF-specific (i.e. not in serum) oligoclonal bands												
• 1 attack and objective clinical evidence of ≥2 lesions	One of these criteria: - DIT: additional clinical attack - DIT: simultaneous presence of both enhancing and non-enhancing symptomatic or asymptomatic MS-typical MRI lesions - DIT: new T2 or enhancing MRI lesion compared to baseline scan (without regard to timing of baseline scan) - CSF-specific (i.e. not in serum) oligoclonal bands												

<div>2017 McDonald Criteria for the Diagnosis of Multiple Sclerosis (continued)</div> <table><tr><th>CLINICAL PRESENTATION</th><th>ADDITIONAL DATA NEEDED TO MAKE MS DIAGNOSIS</th></tr><tr><td colspan="2">...in a person with a typical attack/CIS at onset (continued) (see KEY on reverse for definitions)</td></tr><tr><td>• 1 attack and objective clinical evidence of 1 lesion</td><td>One of these criteria: - DIS: additional attack implicating different CNS site - DIS: ≥1 MS-typical symptomatic or asymptomatic T2 lesions in ≥2 areas of CNS: periventricular, juxtacortical/cortical, infratentorial or spinal cord AND One of these criteria: - DIT: additional clinical attack - DIT: simultaneous presence of both enhancing and non-enhancing symptomatic or asymptomatic MS-typical MRI lesions - DIT: by new T2 or enhancing MRI lesion compared to baseline scan (without regard to timing of baseline scan) - CSF-specific (i.e. not in serum) oligoclonal bands</td></tr><tr><td colspan="2">...in a person with progression of disability from onset</td></tr><tr><td>• progression from onset</td><td>- 1 year of disability progression (retrospective or prospective) AND Two of these criteria: - ≥1 symptomatic or asymptomatic MS-typical T2 lesions (periventricular, juxtacortical/cortical or infratentorial) - ≥2 T2 spinal cord lesions - CSF-specific (i.e. not in serum) oligoclonal bands</td></tr></table> <div>The International Panel on Diagnosis of Multiple Sclerosis was convened under the auspices of the International Advisory Committee on Clinical Trials in MS, sponsored by the National MS Society and the European Committee for Treatment and Research in Multiple Sclerosis. More resources for clinicians: https://www.nationalmssociety.org/For-Professionals/Physicians ©2018 National Multiple Sclerosis Society 733 Third Avenue, New York, NY 10017-3288</div>		CLINICAL PRESENTATION	ADDITIONAL DATA NEEDED TO MAKE MS DIAGNOSIS	...in a person with a typical attack/CIS at onset (continued) (see KEY on reverse for definitions)		• 1 attack and objective clinical evidence of 1 lesion	One of these criteria: - DIS: additional attack implicating different CNS site - DIS: ≥1 MS-typical symptomatic or asymptomatic T2 lesions in ≥2 areas of CNS: periventricular, juxtacortical/cortical , infratentorial or spinal cord AND One of these criteria: - DIT: additional clinical attack - DIT: simultaneous presence of both enhancing and non-enhancing symptomatic or asymptomatic MS-typical MRI lesions - DIT: by new T2 or enhancing MRI lesion compared to baseline scan (without regard to timing of baseline scan) - CSF-specific (i.e. not in serum) oligoclonal bands	...in a person with progression of disability from onset		• progression from onset	- 1 year of disability progression (retrospective or prospective) AND Two of these criteria: - ≥1 symptomatic or asymptomatic MS-typical T2 lesions (periventricular, juxtacortical/cortical or infratentorial) - ≥2 T2 spinal cord lesions - CSF-specific (i.e. not in serum) oligoclonal bands
CLINICAL PRESENTATION	ADDITIONAL DATA NEEDED TO MAKE MS DIAGNOSIS										
...in a person with a typical attack/CIS at onset (continued) (see KEY on reverse for definitions)											
• 1 attack and objective clinical evidence of 1 lesion	One of these criteria: - DIS: additional attack implicating different CNS site - DIS: ≥1 MS-typical symptomatic or asymptomatic T2 lesions in ≥2 areas of CNS: periventricular, juxtacortical/cortical , infratentorial or spinal cord AND One of these criteria: - DIT: additional clinical attack - DIT: simultaneous presence of both enhancing and non-enhancing symptomatic or asymptomatic MS-typical MRI lesions - DIT: by new T2 or enhancing MRI lesion compared to baseline scan (without regard to timing of baseline scan) - CSF-specific (i.e. not in serum) oligoclonal bands										
...in a person with progression of disability from onset											
• progression from onset	- 1 year of disability progression (retrospective or prospective) AND Two of these criteria: - ≥1 symptomatic or asymptomatic MS-typical T2 lesions (periventricular, juxtacortical/cortical or infratentorial) - ≥2 T2 spinal cord lesions - CSF-specific (i.e. not in serum) oligoclonal bands										

Table 2.
McDonald criteria 2017.

5.4 Antiphospholipid antibody syndrome

The antiphospholipid syndrome (APS) is a systemic autoimmune disorder with arterial and venous thromboses; recurrent foetal loss, often accompanied by thrombocytopenia; raised antiphospholipid antibodies, namely, lupus anticoagulant; and anticardiolipin antibodies [39]. Common presentations that can mimic MS are stroke-like presentations such as transient ischemic attack, ischemic stroke, venous thrombosis, epilepsy, headache, movement disorder, transverse myelitis, cognitive impairment, and other neuropsychiatric manifestations.

5.5 Systemic lupus erythematosus

Systemic lupus erythematosus is an autoimmune condition that is frequency associated with neuropsychiatric manifestations and neurological deficit [13].

MRI characteristics	ADEM: Typical	MS: Typical
Deep gray matter and cortical involvement	Yes	No
Bilateral diffuse lesions	Yes	No
Poorly marginated lesions	Yes	No
Large globular lesions	Yes	No
Periventricular pattern of lesions	No	Yes
Lesions perpendicular to long axis of corpus callosum	No	Yes
Ovoid lesions	No	Yes
Lesions confined to corpus callosum	No	Yes
Sole presence of well-defined lesions	No	Yes
Black holes (on T1 sequence)	No	Yes

Table 3.
Features of MOG antibody disease, NMOSD and MS. (Adapted from [34]).

6. Conclusion

Multiple sclerosis can be challenging to make a diagnosis unless a clinician is familiar with the disease. No better explanation for the condition is essential to come to a conclusion regarding the diagnosis. A good history, elaborate and extensive clinical examination, lumbar puncture, magnetic resonance examination, and blood investigations are required. The McDonald criteria have facilitated the diagnosis of multiple sclerosis for precision and allowing earlier diagnosis.

IntechOpen

Author details

Joyce Pauline Joseph
Department of Neurology, Hospital Kuala Lumpur, Malaysia

*Address all correspondence to: jjpmy@yahoo.com

IntechOpen

© 2019 The Author(s). Licensee IntechOpen. This chapter is distributed under the terms of the Creative Commons Attribution License (<http://creativecommons.org/licenses/by/3.0>), which permits unrestricted use, distribution, and reproduction in any medium, provided the original work is properly cited. 

References

- [1] Schumacher GA, Beebe G, Kibler RF, Kurland LT, Kurtzke JF, McDowell F, et al. Problems of experimental trials of therapy In multiple sclerosis: Report by the panel on the evaluation of experimental trials of therapy in multiple sclerosis. *Annals of the New York Academy of Sciences*. 1965;**122**: 552-568
- [2] Poser CM, Paty DW, Scheinberg L, et al. New diagnostic criteria for multiple sclerosis: Guidelines for research protocols. *Annals of Neurology*. Mar 1983;**13**(3):227-231
- [3] Polman CH, Reingold SC, Edan G, Filippi M, Hartung H-P, Kappos L, et al. Diagnostic criteria for multiple sclerosis: 2005 revisions to the 'McDonald criteria'. *Annals of Neurology*. 2005;**58**(6): 840-846. CiteSeerX 10.1.1.604.2677. DOI: 10.1002/ana.20703. PMID 16283615
- [4] Polman CH, Reingold SC, Banwell B, Clanet M, Cohen JA, Filippi M, et al. Diagnostic criteria for multiple sclerosis: 2010 revisions to the McDonald criteria. *Annals of Neurology*. 2011;**69**(2): 292-302. DOI: 10.1002/ana.22366. PMC: 3084507. PMID: 21387374
- [5] Thompson AJ, Banwell BL, Barkhof F, et al. Diagnosis of multiple sclerosis: 2017 revisions of the McDonald criteria. *Lancet Neurology*. 2018;**17**(2):162-173
- [6] Lublin FD, Reingold SC, Cohen JA, et al. Defining the clinical course of multiple sclerosis: The 2013 revisions. *Neurology*. 2014;**83**(3):278-286
- [7] Balcer LJ. Clinical practice. Optic neuritis. *The New England Journal of Medicine*. 2006;**354**(12): 1273-1280
- [8] Hickman SJ, Dalton CM, Miller DH. Management of acute optic neuritis. *Lancet*. 2002;**360**:1953-1962
- [9] Beck RW, Cleary PA, Anderson MM. A randomized controlled trial of corticosteroids in the treatment of acute optic neuritis. *The New England Journal of Medicine*. 1992;**326**:581-588
- [10] Soderstrom M. Optic neuritis and multiple sclerosis. *Acta Ophthalmologica Scandinavica*. 2001; **79**:223-227
- [11] Optic Neuritis Study Group. The clinical profile of optic neuritis: Experience of the Optic Neuritis Treatment Trial. *Archives of Ophthalmology*. 1991;**109**:1673-1678
- [12] Lee AG, Brazis PW. *Clinical Pathways in Neuro-Ophthalmology: An Evidence-Based Approach*. New York: Thieme Medical Publishers; 2003
- [13] Compston A, McDonald I, Noseworthy J, Lassmann H, Miller D, Smith K, et al. *McAlpine's Multiple Sclerosis*. 4th ed 2005
- [14] Swingle RJ, Compston DA. The morbidity of multiple sclerosis. *The Quarterly Journal of Medicine*. 1992; **83**(300):325-337
- [15] Godin D. *Multiple Sclerosis and Related Disorders*, 3rd Series. Vol. 1222014. Copyright: © Elsevier 2014. eBook ISBN: 9780444633095
- [16] Wilkins A. Cerebellar dysfunction in multiple sclerosis. *Frontiers in Neurology*. 2017;**8**:312. DOI: 10.3389/fneur.2017.00312. Recollection 2017
- [17] Alusi SH, Worthington J, Glickman S, Bain PG A study of tremor in multiple sclerosis. *Brain*. 2001;**124**(Pt. 4):720-730
- [18] nationalmssociety.org
- [19] McDonald WI, Compston A, Edan G, Goodkin D, Hartung H-P, Lublin FD,

et al. Recommended diagnostic criteria for multiple sclerosis: Guidelines from the international panel on the diagnosis of multiple sclerosis. *Annals of Neurology*. 2001;**50**(1):121-127

[20] Gastaldi M. Cerebrospinal fluid analysis and the determination of oligoclonal bands. *Neurological Sciences*. 2017;**38**(Supp. 2): 217-224. DOI: 10.1007/s10072-017-3034-2

[21] Stangel M, Fredrikson S, Meinl E, Petzold A, Stüve O, Tumani H. The utility of cerebrospinal fluid analysis in patients with multiple sclerosis. *Nature Reviews. Neurology*. 2013;**9**(5):267-276. DOI: 10.1038/nrneurol.2013.41. Epub 2013 Mar 26

[22] Davenport RD, Keren DF. Oligoclonal bands in cerebrospinal fluids: Significance of corresponding bands in serum for diagnosis of multiple sclerosis. *Clinical Chemistry*. 1988; **34**(4):764-765

[23] Walsh P, Kane N, Butler S. The clinical role of evoked potentials. *Journal of Neurology, Neurosurgery, and Psychiatry*. 2005 Jun;**76**(Supp. 2): ii16-ii22

[24] Traboulsee A, Simon JH, Stone L, et al. Revised recommendations of the consortium of MS centers task force for a standardized MRI protocol and clinical guidelines for the diagnosis and follow-up of multiple sclerosis. *AJNR. American Journal of Neuroradiology*. 2016;**37**(3):394-401

[25] Consortium of MS Centers MRI Protocol and Clinical Guidelines for the Diagnosis and Follow-up of MS. 2018. REVISED GUIDELINES. www.mscares.org/mri

[26] Huang D, Swanson EA, Lin CP, Schuman JS, Stinson WG, Chang W, et al. Optical coherence tomography. *Science*. 1991;**254**(5035):1178-1181

[27] Britze J, Frederiksen JL. Optical coherence tomography in multiple sclerosis. *Eye (Lond)*. 2018;**32**:884-888. DOI: 10.1038/s41433-017-0010-2

[28] Lennon VA, Wingerchuk DM, Kryzer TJ, et al. A serum autoantibody marker of neuromyelitis optica: Distinction from multiple sclerosis. *Lancet*. 2004;**364**:2106-2112

[29] Lennon VA, Kryzer TJ, Pittock SJ, Verkman AS, Hinson SR. IgG marker of optic-spinal multiple sclerosis binds to the aquaporin-4 water channel. *The Journal of Experimental Medicine*. 2005; **202**:473-477

[30] Wingerchuk DM, Banwell B, Bennett JL, Cabre P, Carroll W, Chitnis T, et al. International consensus diagnostic criteria for neuromyelitis optica spectrum disorders. *Neurology*. 2015;**85**(2):177-189. DOI: 10.1212/WNL.0000000000001729. Epub 2015 Jun 19

[31] Johns TG, Bernard CC. The structure and function of myelin oligodendrocyte glycoprotein. *Journal of Neurochemistry*. 1999;**72**(1):1-9

[32] Baumann M, Sahin K, Lechner C, et al. Clinical and neuroradiological differences of paediatric acute disseminating encephalomyelitis with and without antibodies to the myelin oligodendrocyte glycoprotein. *Journal of Neurology, Neurosurgery, and Psychiatry*. 2015;**86**:265-272

[33] Zhou D, Srivastava R, Nessler S, et al. Identification of a pathogenic antibody response to native myelin oligodendrocyte glycoprotein in multiple sclerosis. *Proceedings of the National Academy of Sciences of the United States of America*. 2006;**103**:19057-19062. [PMC free article] [PubMed]

[34] Jarius S, Ruprecht K, Kleiter I, Borisow N, Asgari N, Pitarokoili K, et al. MOG-IgG in NMO and related

disorders: A multicenter study of 50 patients. Part 2: Epidemiology, clinical presentation, radiological and laboratory features, treatment responses, and long-term outcome. *Journal of Neuroinflammation*. 2016; **13**(1):280

[35] Pohl D, Alper G, Van Haren K, Kornberg AJ, Lucchinetti CF, Tenenbaum S, et al. Acute disseminated encephalomyelitis updates on an inflammatory CNS syndrome. *Neurology*. 2016;**87**(Supp. 2):S38-45

[36] Garg RK. Acute disseminated encephalomyelitis. *Postgraduate Medical Journal*. 2003;**79**:11-17

[37] Krupp LB, Banwell B, Tenenbaum S, International Pediatric MS Study Group. Consensus definitions proposed for pediatric multiple sclerosis and related disorders. *Neurology*. 2007;**68** (16, supplement 2):S7-S12

[38] Krupp LB, Tardieu M, Amato MP, et al. International pediatric multiple sclerosis study group criteria for pediatric multiple sclerosis and immune-mediated central nervous system demyelinating disorders: Revisions to the 2007 definitions. *Multiple Sclerosis Journal*. 2013;**19**(10): 1261-1267

[39] Asherson RA, Cervera R, Piette JC, Shoenfeld Y. The antiphospholipid syndrome: History, definition, classification, and differential diagnosis. In: Asherson RA, Cervera R, Piette JC, Shoenfeld Y, editors. *The Antiphospholipid Syndrome*. Boca Raton (FL): CRC Press; 1996. pp. 3-12