

We are IntechOpen, the world's leading publisher of Open Access books Built by scientists, for scientists

6,900

Open access books available

186,000

International authors and editors

200M

Downloads

Our authors are among the

154

Countries delivered to

TOP 1%

most cited scientists

12.2%

Contributors from top 500 universities



WEB OF SCIENCE™

Selection of our books indexed in the Book Citation Index
in Web of Science™ Core Collection (BKCI)

Interested in publishing with us?
Contact book.department@intechopen.com

Numbers displayed above are based on latest data collected.
For more information visit www.intechopen.com



Pathologic Myopia: Complications and Visual Rehabilitation

*Enzo Maria Vingolo, Giuseppe Napolitano
and Lorenzo Casillo*

Abstract

High myopia, defined as refractive error of at least -6.00D or an axial length of 26.5 mm or more, can induce many modifications in eye's anatomy that can lead to complications. When high myopia is able to decrease best corrected visual acuity (BCVA) due to its complications, it is called pathologic myopia. Pathologic myopia is one of the major causes of blindness, and it represents a serious issue, since incidence of myopia and high myopia is constantly rising. For educational purposes, in this chapter, complications of pathologic myopia will be divided into anterior (when structures external to the globe or anterior to the ora serrata are involved, such as motility disturbances and cataract) and posterior (when structures posterior to the ora serrata are involved, such as lacquer cracks, chorioretinal atrophy, Fuchs maculopathy, myopic choroidal neovascularization, and retinal detachment). Many treatments are available for pathologic myopia complications depending on their type, such as vascular endothelial growth factor (anti-VEGF) injections and surgery. We will focus on visual rehabilitation interventions, such as visual biofeedback and visual aids that in many cases are the only chance that the ophthalmologist has in order to help patients suffering from pathologic myopia to use at their maximum their residual vision.

Keywords: visual rehabilitation, low-vision aids, microperimetry, high myopia, pathologic myopia complications

1. Introduction

Many modifications in normal eye anatomy and structure occur in high myopic patients. Sclera is the most external layer of the eye. In normal nonelongated eyes, scleral thickness decreases from the limbus to the equator, then increasing again to the posterior part of the eye. Normal sclera has also well-known tensile and elastic properties. In highly myopic eyes, these properties are altered with tensile strength reduced and augmented elasticity especially at the posterior pole of the globe. The reason can be searched in the alteration of its ultrastructure (which is more layered and lamellar compared to the normal sclera), in thinning and decreased diameter of the collagen fibers, and also in configuration and conformation of the collagen fibrils. In highly myopic eyes, also a remodeling of the extracellular matrix is observed during the extension of the eyeball, even if its mechanisms are not fully understood. These modifications lead to the fact that in highly myopic eyes, sclera is thinner in the part that goes posterior to the equator, while the anterior part does not show any significative difference with normal eyes. This kind of modification can contribute to the development of many

complications that will be discussed in this chapter. Corneal modifications in high myopic patients are still under debate; some studies reported modifications in corneal biomechanical properties in high myopic patients, such as lower hysteresis. According to some studies [1], highly myopic patients had flatter curvature, modifications in corneal thickness, and decreased endothelial density, while other studies did not report any statistical difference in central corneal thickness (CCT) in various ranges of myopia [2]. Choroid's thickness is significantly reduced in highly elongated eyes; its thickness in foveal and parafoveal portions showed to be inversely proportional to parameters such as patient's age, myopic spheric equivalent, and axial length of the globe, with this last parameter showing to be the most consistently related. Also, distribution of choroidal thickness is altered in these eyes, with temporal and superior regions far from the fovea that show to be thicker than foveal region. Another strong predictor for choroidal thinning in high myopic patients is the presence of a posterior scleral staphyloma [3]. Furthermore, this thinning in choroidal tissue has a negative impact on retinal trophism. With regard to choroidal flow in highly myopic eyes, studies are controversial; for some of them, blood flow in choriocapillaris is augmented, while for others not. It is possible to find differences between high myopic patients and emmetropic ones even in retinal blood flow. Density of the superficial and deep plexus is significantly reduced in high myopic subjects, and the magnitude of this phenomenon is negatively related to axial length and myopic refraction. It is possible to postulate that increasing of the axial length on these eyes can lead to mechanical stretching of ocular structures, leading to damage to retinal pigmented epithelium (RPE), retinal microvascular network, and endothelial cells. Furthermore, in highly myopic eyes, excessive elongation of the globe and tilting of the optic disc can lead to posterior staphylomas formation and the tilting of the optic disc could lead to alterations in macular and foveal morphology, leading to a change in foveal position that can be found moved mainly in the vertical direction. High axial length is associated with many morphologic changes in the optic nerve and peripapillary region. The axial elongation is associated with the enlargement of the optic nerve head and of the peripapillary scleral tissue. The scleral flange is strongly adherent to the lamina cribrosa and axial-elongation-induced scleral enlargement during eye movements. This condition may lead to thinning of the lamina cribrosa, and it may also be associated with the formation of peripapillary choroidal cavitation. Thinning of lamina cribrosa leads to an alteration between intraocular pressure (optic nerve tissue pressure and cerebrospinal fluid pressure) with a steepening of the translamina cribrosa pressure gradient; this may play a role in the development of the glaucomatous optic neuropathy.

2. Anterior complications in pathologic myopia

2.1 Cataract and pathologic myopia

Three main studies have investigated the connection between cataract formation and high myopia: the Blue Mountains Eye Study and the Beaver Dam study. In the first one, researchers found that there may be a strong connection between the development of posterior polar cataract and myopia that appeared before 20 years. Furthermore, they found a correlation between the level of myopia and posterior subcapsular cataract. High myopia, however, was linked to the formation of all the three types of cataract known [4]. In the Beaver Dam study, researchers confirmed the connection highlighted in other studies between myopia and nuclear cataract [5]. Unlikely, the connection between myopia and age-related cataract is not fully confirmed, while the incidence of PSC and nuclear cataract in myopic eyes appears well established. Also, the distribution of the type of cataract in relation to the axial length

of the eye has been investigated; some studies found no connection, while others found a significative direct correlation between AL and the severity of the lens opacity [6]. Eventually, the mechanism that underlies this condition is not fully understood.

2.2 Motility and globe position alterations in high and pathologic myopic patients

High myopia is one of the clinical entities that cause a unilateral proptosis [7], leading to poor cosmesis, motility alterations, and pain. Furthermore, chronic exposition of anterior surface may cause exposition keratopathy. The mechanics of the relationship between axial elongation and myopic proptosis is complex; in its elongation process, the eyeball tends to expand backward and proptosis forward [8].

There is also evidence of a linear correlation between spheric equivalent and proptosis grade. It has been observed that in patients that suffer from strabismus related to high myopia, there is a displacement of the globe from the muscle cone in the space that forms between superior and lateral rectus muscles [9]. Lateral rectus is also inferiorly displaced.

Alterations in motility alterations can also be observed in high myopic eyes; the range of these alterations goes from small angle esotropia with mild reduction of abduction to strabismus fixus. Exotropia and hypotropia can also be seen in these patients. Exodeviations due to a lesser accommodative work are relatively common in myopes.

Strabismus fixus is the latest stage of the abovementioned spectrum; the eye appears fixed in esotropic and hypotropic position; even passive movements in other positions of gaze are impossible. Many theories for that phenomenon have been proposed; one of them is that the displacement of the eyeball already described causes a compression of lateral rectus muscle against the orbital wall. According to other authors, not only lateral rectus muscle can experience this compression, but also superior and medial rectus.

To prove this hypothesis, many MRI studies of the orbit have been performed; some found a displacement of the abovementioned muscles, while others demonstrated a superotemporal prolapse of the elongated posterior portion of the globe, which displaces lateral and superior rectus [10]. High myopic patients with time can also develop diplopia, which is due to esotropia, and hypotropia that is accompanied by limitation of abduction and elevation [11].

Patients that suffer from alterations in motility and position of the globe often have an axial length that is more than 30 mm.

3. Posterior complications in pathologic myopia

3.1 Lacquer cracks

Lacquer cracks are linear breaks of the Bruch's membrane-choriocapillaris complex, which can be found in 4% of subjects with high myopia [12]. The main pathogenetic mechanism is the mechanical stretching of the chorioretinal structures due to scleral elongation [12]. However, according to other studies, their formation could be associated with near vessels perforating the sclera causing the expansion of surrounding scleral tissue [13].

The first clinical presentation usually consists in subretinal hemorrhage, which is a potential sight-threatening condition. Fluoro angiography and indocyanine angiography are important for differential diagnosis with myopic choroidal neovascularization. At the fundus examination, lacquer cracks appear as yellowish-white linear lesions, rarely starry or mixed shapes. Usually, they are located at the posterior pole, and their peripheral formation is unusual [14].

In autofluorescence exam, they appear ipoautofluorescent. Spectral domain optical coherence tomography (SD-OCT) allows studying RPE and Bruch's membrane breaks; "en face" OCT angiography shows avascular bands in choriocapillaris segmentation [12].

Break of Bruch's-choriocapillaris complex leads to near RPE atrophy and fibrotic degeneration. Thus, fluoro angiography shows window-effect hyperfluorescence with no leakage; staining can appear during late phases, especially in fibrotic-evolved breaks. In those cases, indocyanine angiography shows linear ipocyanescent lesions, which extension results longer than the one appreciable in fluoro angiography exam. Therefore, indocyanine angiography results in a most accurate examination in lacquer crack detection. Breaks on Bruch's-choriocapillaris complex lead to RPE damage and subsequent retina-epithelial "patchy atrophies" and, in 30% of cases, choroidal neovascularization (CNV) [19].

3.2 Chorioretinal atrophy (tessellation, patchy, diffuse)

Choroid thinning and subsequent retinal involvement are typical findings in pathologic myopia. Retinal remodelling seems to be associated with choroidal hypoperfusion due to vascular axial stretching. There are three main atrophy morphologies.

Tessellated fundus is the most common. It consists in multiple linear choroid-RPE thinning, making fundus appear as tiger streaked. Tessellated fundus is a very early manifestation of myopic retinal changes, and it can evolve in other more severe lesions. In fact, it is associated to lacquer crack formation and myopic chorioretinal atrophies.

Patchy atrophy appears as a gray-white lesion with well-defined edges; they can be found on staphyloma edges, near lacquer cracks, or as CNV evolution [15]. Coalescent patchy atrophies can lead to diffuse atrophy; furthermore, they have been described as very important risk factor in CNV formation (20%).

Diffuse atrophy, instead, is a large yellowish-white lesion with no well-defined edges. Usually, it is located in peripapillary zone and its correlation with CNV formation is rare (3.7%). RPE atrophy, patchy or diffuse, leads to photoreceptor atrophy and their loss of function. Thus, macular or foveal atrophy is responsible of important and irreversible central vision loss. Fluorescein and indocyanine angiographies show hyperfluorescence and hypercyanescence due to window effect. In autofluorescence, atrophy is hypoautofluorescent with mild hyperautofluorescent edges, especially in patchy atrophy.

SD-OCT allows the operator to study the retinal structures involved, measuring progression of lesions over time (**Figure 1**).

The process that can lead to complications due to myopic chorioretinal atrophies is resumed in **Figure 2**.

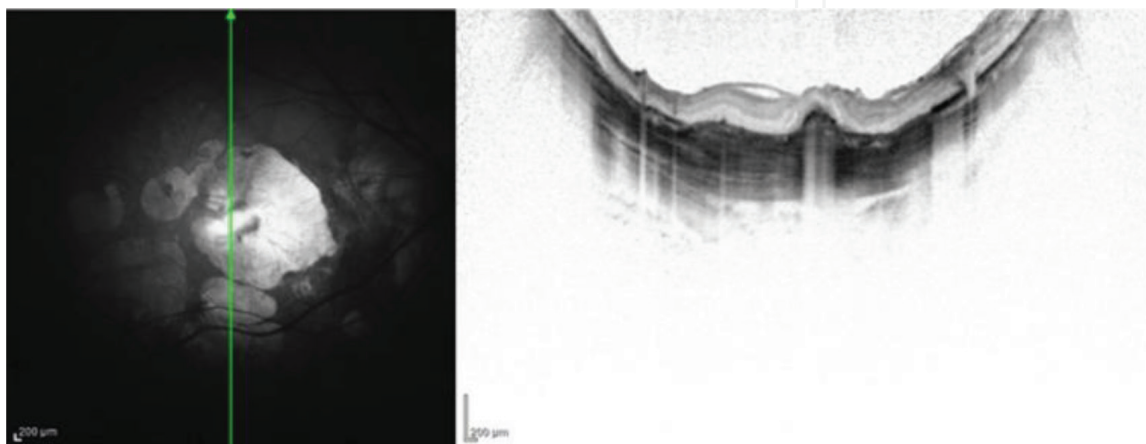


Figure 1.

An OCT scan overlying an area of chorioretinal atrophy: a myopic CNV is also present.

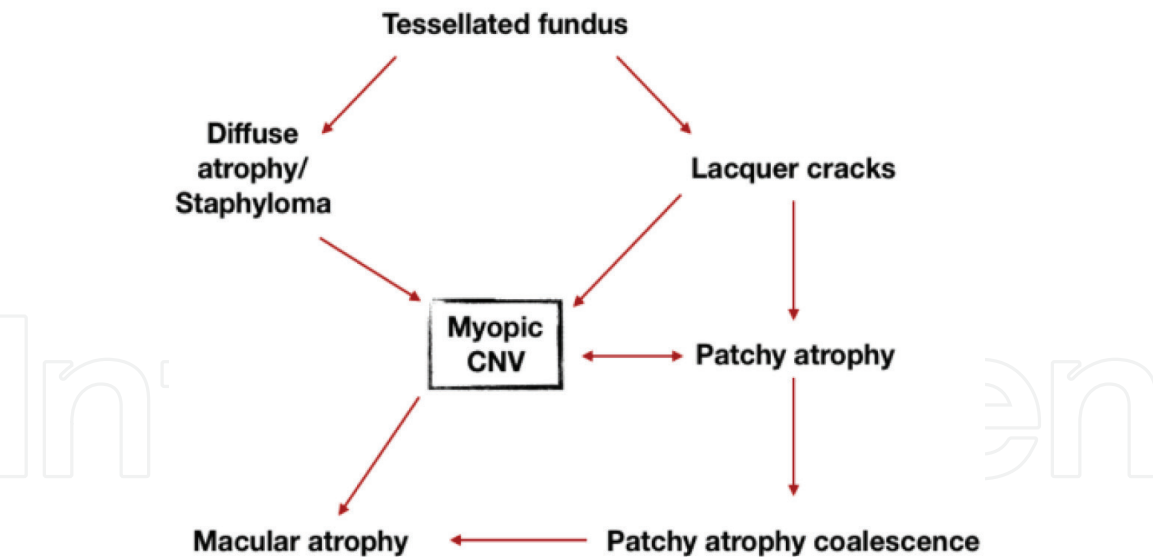


Figure 2.
Myopic chorioretinal atrophies and complications.

3.3 Fuchs' spots

Fuchs' spots are patch-like whitish retinal lesions characterized by a dark pigmented central formation. They are the result of previous myopic CNV and their atrophic evolution with subretinal and intraretinal pigment dispersion. As for patchy atrophies, multiple Fuchs' spots can coalesce forming macular atrophy. Presence of Fuchs' spots in a myopic eye is very important to understand the history of the pathology and its future prognosis [16].

3.4 Myopic CNV

Myopic CNV (mCNV) is found in 5–10% of high myopic eyes. Over time, many environmental and genetic risk factors have been detected. Among the main ones, lacquer cracks (29%), patchy atrophy (20%), female gender, and genetic pro-inflammatory protein expression are important to remember. However, the most important one is history of myopic CNV in the other eye (34%). Very often, mCNVs grow between RPE and neuroepithelium (CNV type 2 or “classic CNV”) [17] in the macular region and precisely: 58% foveal and 23% juxtafoveal. Only 19% of mCNVs have extramacular location on the edges of a peripapillary diffuse atrophy (periconus-CNV).

The pathogenesis of mCNVs is still controversial. Their subretinal growth associated to underlying RPE atrophy (75–94% of mCNVs occur on lacquer cracks), together with strong association of choroidal thinning, suggests that an angiogenic stimulus due to choroidal hypoxia could be a plausible pathogenic mechanism, when RPE barrier breaks are present (patchy atrophies and lacquer cracks). Axial length and refractive error, if considered by themselves, do not represent risk factors for mCNVs development [18]. mCNVs growth is asymptomatic until the activation, which leads to rapid reduction of visual acuity with metamorphopsia and scotoma.

On the funduscopic examination, they appear as small grayish spots with pigmented edges; subretinal hemorrhages' and intraretinal exudation are modest.

Fluoro angiography remains the benchmark test for early diagnosis of myopic CNVs, presenting a higher sensitivity than SD-OCT in the detection of early active forms [19].

These lesions appear as hyperfluorescence in the early phases. When active, they show late fluorescein leakage, which is modest when compared to CNV in

age-related macular degeneration (AMD). Furthermore, fluoro angiography, when a subretinal hemorrhage occurred, is a fundamental tool in the differential diagnosis between mCNV and Lacquer crack, which typically does not show fluorescein leakage. However, factors such as staining of dye in fibrotic tissue and hemorrhagic blocking defect may reduce the reliability of fluoro angiography exam.

Indocyanine angiography has a better penetration through bleeding, pigment, and exudates; it also allows a more accurate visualization of lacquer cracks. However, sensitivity in identifying CNVs is lower than fluoro angiography. Neovascularizations are shown as inconstant hypercyanescent lesions, sometimes surrounded by a hypocyanescent halo. For these reasons, indocyanine angiography is used only in case of extensive macular hemorrhages and in case of doubtful fluoro angiographic results.

SD-OCT exam is a primary, rapid, and noninvasive test in the diagnosis and follow-up of myopic CNV (**Figure 3**). However, modest exudation and bleeding of active mCNVs can sometimes lead to misdiagnosis on OCT examination. They appear as hyperreflective subretinal formations; signs of exudation (such as intraretinal fluid, retinal thickening, and outer limiting membrane interruption) can be detected only in 48% of cases, while fluorescein leakage is found in 82%. A multimodal approach, combining OCT and fluoro angiography, allows reaching high sensitivity in the diagnosis of myopic CNVs [20].

Overmore, implementation with OCT angiography function allowed us to study the retinal flow in the single tomographic segmentation of the retina, managing to identify 94.1% of mCNVs with a specificity of 93.75%. In “en face” visualization, active CNVs appear as vascular organizations in a typical lacy wheel shape or glomerular pattern, with many anastomoses and thin capillaries, in addition to the typical perilesional dark halo. In the quiescent phase, instead, they assumed the typical aspects of mature neovessels: large caliber and linear course, without anastomosis, with a filiform aspect, or dead tree appearance.

The most effective treatments to date are intravitreal injections of anti-VEGF drugs. While bevacizumab and ranibizumab demonstrated a comparable efficacy, aflibercept allowed the resolution of the CNV with a single administration in 55% of cases, resulting in the best medication for the “result/number of injection” ratio [21].

Photodynamic treatment has been shown to be less effective than ranibizumab; therefore, it is considered as a second choice treatment [22]. Natural evolution of mCNVs consists in a remodellation of the neuroepithelial and pigmented epithelial tissues, leading to the formation of typical Fuchs’ spots and patchy atrophies with loss of function of involved retina.

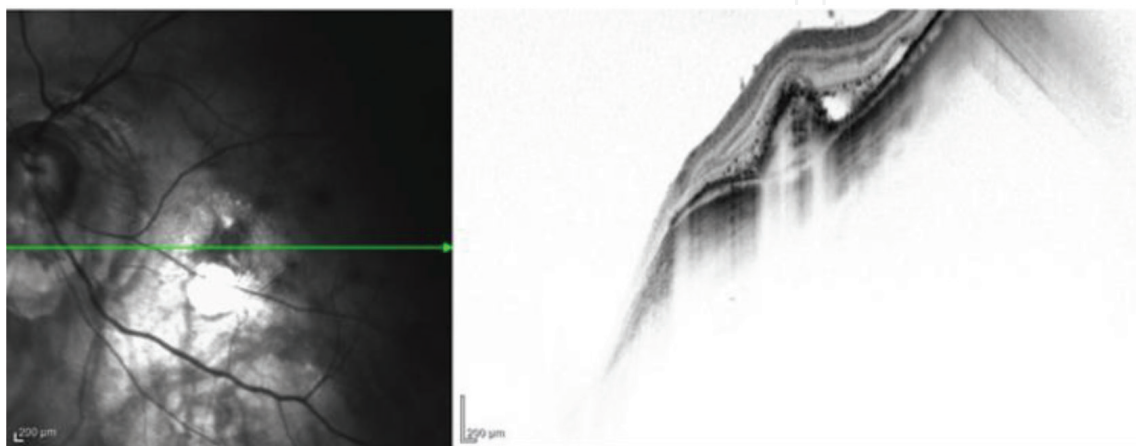


Figure 3.
An OCT scan of a myopic patient showing active myopic CNV.

3.5 Myopic tractional maculopathy (VMT, foveoschisis, macular hole, macular detachment)

The definition of “myopic tractional maculopathy” includes a wide range of pathologies: vitreomacular traction, foveoschisis, and macular hole.

High myopic eyes, with a posterior pole staphyloma, undergo tractional phenomena between stretchable structures and nonelastic structures. To understand the biomechanics underlying these modifications, it is important to consider the physiological adherence of posterior vitreous cortex on the fovea. Furthermore, inner limiting membrane (ILM) and retinal vessels showed a reduced stretching capability compared to choroidal and scleral structures.

The extreme bulbar elongation caused by staphylomas creates axial vitreomacular traction with increased macular thickness; it is usually an asymptomatic condition, or it may lead to metamorphopsia, with preserved or mild altered visual acuity. Axial traction may result in alterations of vitreous body, such as cortical vitreoschisis or posterior vitreous detachment (PVD) (43.2%) with subsequent cellular proliferation and increased risk of epiretinal membrane (ERM) formation.

Progression of staphylomatous bulbar elongation comes up against lower elasticity of retinal internal structures (ILM, retinal vessels, incomplete PVD with vitreoretinal adhesion, ERM), causing an intraretinal cleavage and configuring a foveoschisis (9%) [23]. Cleavage can occur in the inner, outer, or both retinal layers, but more often, it affects the inner limiting membrane. This condition has a variable progression, and some studies demonstrate its stability in 88.4% of cases. However, further progression of axial traction may lead to a detachment of the macular neuroepithelium.

The alteration of posterior pole profile due to the staphyloma, the presence of an ERM, and the incomplete PVD are factors that can lead to the development of tangential traction forces, which, combined with axial traction, can make the foveoschisis evolve into lamellar or full thickness macular holes with important visual acuity impairment. Furthermore, a full-thickness macular hole may cause a rhegmatogenous retinal detachment that can be confined to the macula or also involve the peripheral retina.

Diagnostic strategy of all the clinical presentation analyzed is based on fundus examination and, above all, on the SD-OCT exam. The latter allows a precise characterization of the single vitreoretinal structures involved, through a tomographic study of the bulbar structures. OCT exams also make an accurate, rapid, and noninvasive follow-up possible (Figure 4) [24].

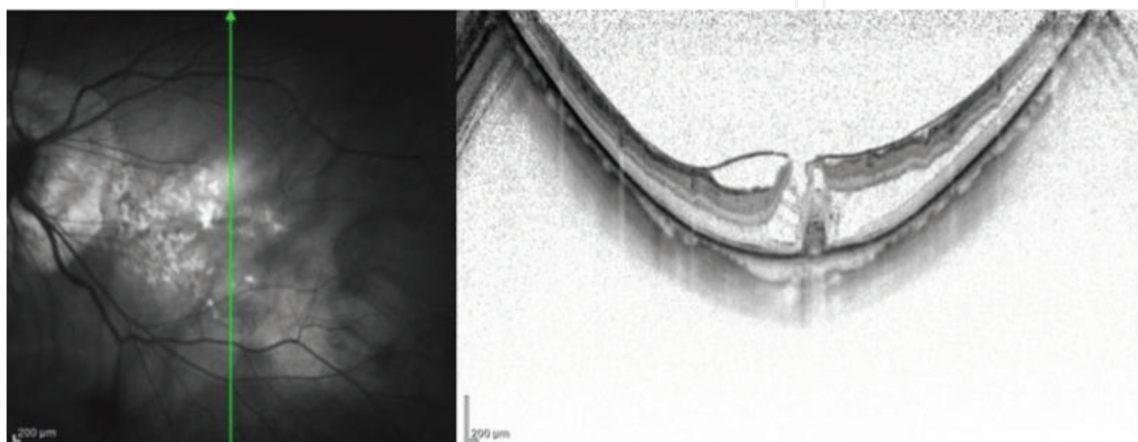


Figure 4.
An OCT of a myopic patient showing a macular pucker and a foveoschisis.

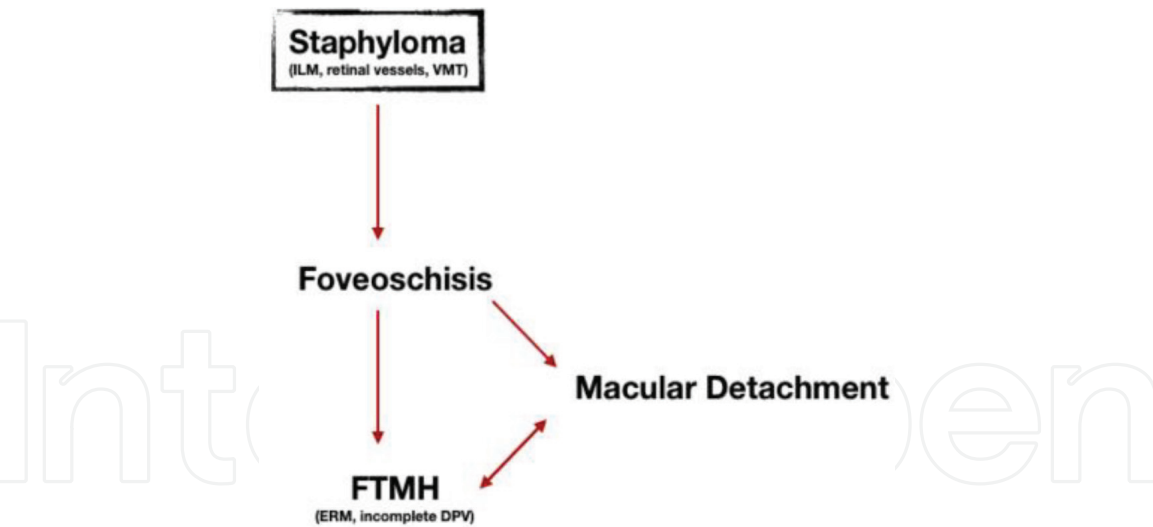


Figure 5.
Myopic tractional maculopathy and complications.

The therapy of myopic tractional maculopathies varies depending on the type of lesion or their combination (foveoschisis, macular hole, macular detachment). Description of surgical procedures is not pertinence of this chapter. In a general way, surgery is the only possible choice and aims at reducing axial and tangential stretching forces. The peeling of ILM and ERM via Pars plana vitrectomy (PPV) is the basis of the resolution of foveoschisis and macular holes [25]. However, sometimes, this approach is not enough, especially if a macular detachment occurred. In these cases, it may be necessary to perform a macular buckle combined or not with PPV.

The pathogenetic process that can lead to the abovementioned complications is resumed in **Figure 5**.

3.6 Retinal detachment

High myopia is the main risk factor for rhegmatogenous retinal detachment; 50% of which, according to some estimates, occurs in myopic patients [26].

Rhegmatogenous retinal detachment is defined as the separation of retinal neuroepithelium from the retinal pigment epithelium following the infiltration of liquefied vitreous material through a full-thickness retinal rupture (tears or holes).

Early vitreal degenerative phenomena leading to syneresis show a peak at young age. Those changes can culminate in a PVD and vitreous liquefaction. This mechanism, typical of myopic eyes, could underlie the higher retinal detachment prevalence. Furthermore, numerous studies have shown a strong association of axial bulbar elongation with various peripheral retinal degenerations, especially with lattice degenerations. These consist in retinal thinning spots with strong vitreous adhesion on the edges, which can exert traction, especially in the presence of PVD. Usually, the vitreous detaches from the retina without causing problems. But, sometimes, the vitreous pulls hard enough to tear the retina in one or more places. Retinal tears can have different shapes and locations. Typically, they are located between equatorial zone and ora-serrata, especially in the upper-temporal quadrant; in over 50% of cases, they appear as circular or oval tears (retinal holes); in the remaining 50%, there are multiple microtears, horseshoe-shaped, and operculated tears [27].

Giant retinal tears are rare and usually associated with bulbar traumas and vitreoretinal proliferation. Overmore, the already mentioned full thickness macular holes can lead to a total retinal detachment in some cases.

Diagnosis of tears and retinal detachment is based on the history and the examination of the fundus oculi. Color peripheral fundus camera and SD-OCT macular scans are often very useful tools. Patients may be asymptomatic or complain of phosphenes and miodesopsias. Standard treatment for retinal tears and lattice degeneration without retinal detachment is argon laser barrage, which has shown to be a very effective prophylactic solution for retinal detachment.

If retinal detachment has already occurred; however, the only therapy is surgery. Ab interno and ab externo approaches are options, but the treatment is delegated to specialistic texts.

3.7 Dome-shaped macula

Features of dome-shaped macula (DMS) are an abnormal profile of the macula that appears convex with an anterior protrusion. Three types of DSM have been described in literature [28]:

- horizontal oval-shaped dome
- vertical oval-shaped dome
- round dome.

DMS can occur in eyes with or without staphyloma and appears related to a localized thinning of the sclera under the dome-shaped macula [29]. This condition can lead to formation of subretinal fluid (SRF) and choroidal neovascularization (CNV). Based on last evidences, the pathologic mechanisms of formation of SRF and CNV could be linked to a similarity of choroid's features between CSCR and only choroid's portion located above the DMS area in high myopic eyes [30]. One of the complications that can occur in eyes with dome-shaped macula is CNV formation, and the types of CNV mostly related to DMS are either typical myopic CNV (i.e., type 2 CNV) or pachychoroid-associated CNV (i.e., type 1 CNV). Another kind of complication related to DMS is the presence of subretinal fluid that causes a chronic serous retinal detachment, which not seems to impair visual function in majority of cases and also shows a certain stability over time. OCT is a crucial technique to observe this condition, because it is almost impossible to detect on standard fundus examination (**Figure 6**). Furthermore, it is crucial to detect the presence of SRF and CNV. Up to date, many treatment approaches such as

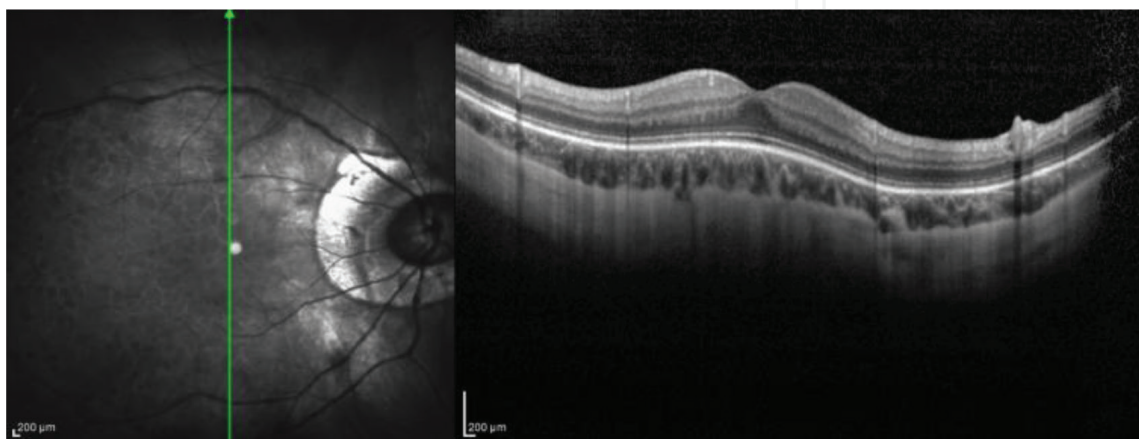


Figure 6.
An OCT of a myopic patient showing a dome-shaped macula.

intravitreal aflibercept, subthreshold laser treatment, PDT, and antimineralocorticoids have been tried to treat SRF associated with DSM, but there is no a definitive one. While representing a potential problem in high myopic eyes, some authors found DMS to be a protective factor for visual function after cataract surgery [31].

3.8 Posterior staphyloma

Posterior staphyloma is defined as “an outpouching of the wall of the eye that has a radius of curvature that is less than the surrounding curvature of the wall of the eye” [32].

Some authors argue that pathologic myopia should not be defined based on axial length but on the presence of staphyloma. An increased presence of staphyloma in eyes exhibits a longer axial length.

According to Curtin, there are many types of staphylomas [33] that can be classified into 10 subcategories. However, also, other classifications have been proposed recently [34]. Methods for detecting staphylomas are OCT, fundus imaging, B mode echography, and 3D magnetic resonance imaging (MRI). Among all, OCT offers the possibility to detect the posterior staphyloma and also to study the morphology of the retinal layers. Interpreting an OCT exam in these cases, it is crucial not to confuse a real staphyloma with a simple scleral backward bowing due to elongation of the eyeball, which is a relatively common finding in high myopic patients. 3D MRI in T2-weighted acquisition perfectly delineates the presence and the type of staphyloma. However, this is not a routine technique and its limits are that it is expensive and that this is not widespread. The presence of a posterior staphyloma can have negative implications on visual outcome, and is also linked to an augmented incidence of other complications such as myopic CNV, myopic macular retinoschisis, and high myopia-associated glaucoma-like defects or glaucomatous optic neuropathy.

4. Low-vision rehabilitation

In many cases, pathologic myopia patients experience an irreversible and deep loss of vision. In such cases, low-vision interventions are useful to allow patients to continue or to improve daily living tasks, independency, and quality of life. Many devices and trainings are available to achieve this goal.

This is an important tool to use in high myopic patients with visual field defects that impair vision, because this is a particularly favorable condition for low-vision correction, mainly because they are used to read at close range of distance.

Low-vision rehabilitation can be approached by many techniques that can be subdivided in two main categories:

- a. stimulation techniques (such as visual biofeedback)
- b. low-vision aids.

4.1 Stimulation techniques

In general terms, biofeedback is a technique that is used to learn how to control a body function that normally is not under patient's control.

Visual biofeedback can be accomplished by many techniques; in our experience, acoustic biofeedback visual training provides to be the most effective. First of all, it is useful to evaluate patient's retinal sensibility and fixation stability by making a microperimetry (**Figure 7**); this exam allows the examiner to evaluate retinal

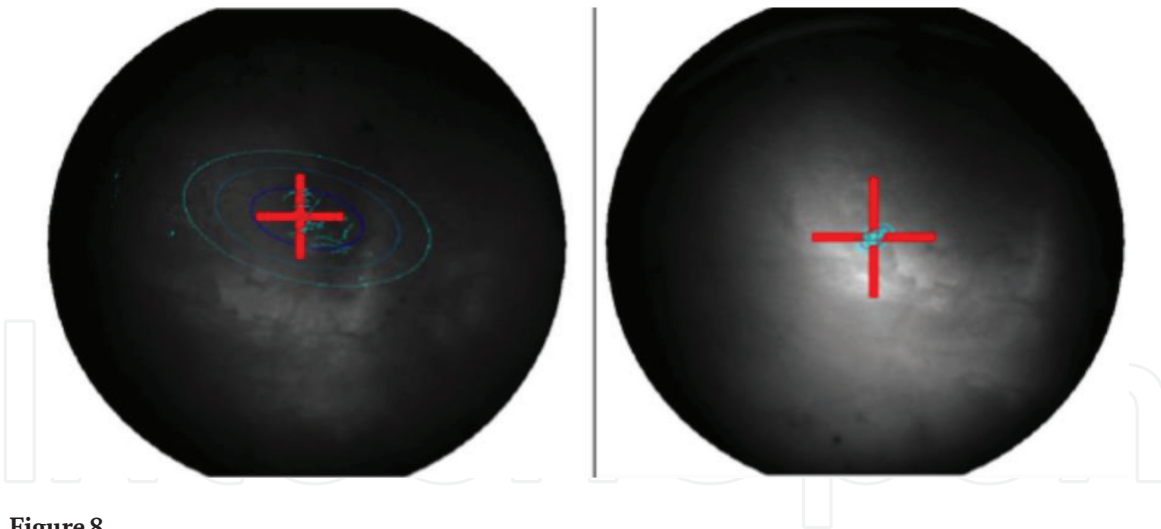


Figure 8.

The fixation stability study (BCEA) of a high myopic patient suffering from a small absolute central scotoma. On the left: before the treatment with acoustic biofeedback; on the right: changes in fixation stability after two treatment of acoustic biofeedback, each of 10 sessions of 10 min. It is possible to appreciate the drastic improvement in fixation stability by means of bivariate contour ellipse analysis.

Regarding last point, it is important to understand that more the distance of the point chosen for stimulation from the natural fovea, the lesser is the outcome to be expected. When the most favorable point to be stimulated is chosen, the patient is asked to firmly look with one eye at a time (in case of rehabilitation of both eyes) to a fixation target inside the microperimeter with the point chosen to be stimulated; during the session, the lesser the distance between the target and the new fixation point chosen, the more continuous the sound emitted by the instrument will be, hence giving the patient a constant control of the retinal point fixing the target. After a training period (usually 10 sessions of 10 min each per eye), the goal is to achieve a constant and stable fixation with the most favorable (in terms of position and residual sensitivity) retinal point other than the fovea previously chosen (**Figure 8**) [35], which is also called pseudofovea, in case of a central scotoma or to achieve a more stable fixation in case of a peripheral defect with a poor fixation stability. All these aspects lead to a better reading performance.

In case of a lesion that leads to a central scotoma, patient's neurovisual system automatically chooses a preferred retinal locus (PRL also known as pseudofovea), which is defined as "one or more circumscribed regions of functioning retina, repeatedly aligned with a visual target for a specified task that may also be used for attention deployment and as the oculomotor reference" [36]. It is also possible to develop two or more PRLs that change accordingly to different tasks. If the ophthalmologist decides to move this PRL using visual biofeedback to a point other than the one automatically set by the patient's brain because he thinks it may be more favorable, it is possible to call it trained retinal locus (TRL). Before starting the treatment, it is absolutely mandatory that the patient has already developed a PRL by itself.

The improvements in fixation stability and PRL relocation observed using acoustic biofeedback technique suggest that a mechanism of cortical reorganization and cortical plasticity may underline those changes [37]. In case of the presence of peripheral visual field defects, a perimetry using 30-2 strategy is useful and can be added to a microperimetry in order to have a more precise evaluation of patient's residual vision.

As already said before, there are two main categories of visual defects that high myopic patients can develop [38]:

- central scotoma (variable in depth, extension, position)
- glaucomatous (if glaucoma develops) or glaucoma-like defects (central and peripheral defects variable in depth, extension, position).

It is well known that patients affected by absolute central scotoma from other kinds of maculopathies may benefit from visual biofeedback training. Highly myopic patients develop macular complications that can lead to this kind of defect, hence making this kind of therapy beneficial also to those patients. Due to the risk of developing glaucoma and/or glaucoma-like defects as mentioned above, acoustic biofeedback can be a useful technique in the visual rehabilitation of those patients. Many studies proved the efficacy of this technique in advanced glaucomatous damage in improving fixation stability and visual performances in patients with glaucoma.

4.2 Visual aids

Visual aids are tools (optical or technological) that may improve visual performances in low-vision patients such as high myopic patient in which visual defects have already developed.

For didactic purposes, we will divide them into three main categories:

- a. for distance and intermediate vision
- b. for near vision and reading
- c. field enhancement.

4.2.1 For distance and intermediate vision

Telescopic systems are the hallmark of this category, and they work by producing magnification. There are two main kinds of telescopes: the Galilean and the Keplerian ones. A Galilean telescope works by coupling a convex lens (object) and a concave lens (ocular) [39]; the image produced is real and erect. A Keplerian telescope is made by the combination of two lenses: a convex lens, which is closest to the object (the ocular lens) and a convex lens (the objective lens), which is closest to the eye and has less dioptric power than the first one. The distance between the two lenses is the result of the sum of their focal length. Since the image produced is inverted, a prism is required in order to reverse it. This kind of telescope has more wide field of view, less aberrations, and a better image quality than Galilean ones, but they are a little bit less comfortable since they are heavier and often more expensive. In contrast, Galilean telescope is lighter, cheaper, and shorter, making them handier for the patient. Telescopes are very effective for distance tasks, but they present some problems. They have a steep learning curve because of the restricted field of view, and the learning process is a struggle because of the distortion provided on space and objects. Telescopes are available in many forms such as hand held, spectacle mounted (**Figure 9**), and clip-on. They may also have fixed or variable focus. Spectacle mounted is obtained by cutting an hole in the spectacle lenses and inserting the telescope; this one can be placed at the center of the lens or higher than the center; this position is particularly useful since the patient uses the center of his lens for most of the time and can look through the telescope placed in the upper part of his spectacles only when he needs to magnify some distant object (such as, for example, traffic signs) [40].

4.2.2 For near vision and reading

Microscopic systems are high dioptric positive power lens that work by reducing focal length. There are many solutions that use this technology. Handheld magnifiers are variable positive power lens with handle, aspheric or biconvex, in various dioptric power and magnification, whether illuminated or not. High positive power lens are



Figure 9.
A patient driving using binocular telescopes mounted on top of the spectacle lenses.

available also as pocket magnifiers. Bar magnifiers are variable length bars able to magnify a text by sliding upon it. They are available in different dioptric powers (hence different magnification) and can be illuminated or not. Another option is high positive dioptric power lens spectacle mounted. However, they pose some struggling: the higher the power, the lesser the distance between the text/object and lens; the higher the power the, higher the convergence required to the patient. Binocular microscopic systems (also known as prismatic hypercorrective) are spectacle-mounted hypercorrective lens, which consist in two positive lenses and two prisms that are calculated based on the power of the positive lens; this kind of glass is found in various amount of magnification and dioptric power (usually from +3.00 to 16.00 dpt). The higher the magnification, the higher the difficulty of the patient to adapt to this kind of low-vision aid. The aim of the use of the prisms is to reduce the amount of the convergence required to the patient due to the use of the reduced working distance, hence reducing discomfort from prolonged tasks as for example reading a book. As we said before, one of the key mechanisms to improve reading performance in low vision is magnification [41]. Many electronical devices exist to accomplish this job; one of them is closed circuit television (CCTV). These systems are often reserved to visually impaired people with severe low vision in which the magnification needed to be able to read or to do it more fluently should be as high that optic systems would not be comfortable and usable [42] to. These are called CCTV to differentiate them from broadcast television. This system can also be useful for writing. Behind the lens of the CCTV camera, there is an image sensor, which is equivalent to a retina. This lens system refracts light beams reflected from an object and focuses them on the plate to become an image.

Based on information sheets of American Foundation for the Blind (AFB), a CCTV (**Figure 10**) must have these characteristics:

- video camera mounted on a fixed stand (some models have optics able to provide zoom while others not; some have autofocus while others not)
- TV or monitor from 5" to 20"
- positive magnification from 2× to 60× (but also even more)
- polarity inversion (from black-white to white-black)




Figure 10.
A CCTV used for writing.

- focus, contrast, and brightness controls
- table that moves on an X-Y direction.

Many kinds of CCTV systems are available in the market; the main difference is between portable CCTV and table-mounted systems. The first one is extremely useful for children with low vision, because they can be used at home and at school, for leisure and for studying. Recently, there has been some evidence that these kinds of devices may be more effective than optical devices in improving reading speed [43].

Portable systems are usually composed by a camera with optics able to provide a variable amount of zoom and hence magnification, an LCD screen (usually small and in most cases within 10"), and an handle to be held by the patient. They are designed to be portable: in most cases, they can be placed in the pocket, or in the case of largest ones in a bag. They are useful in daily activities such as drugs assumption, reading letters, buying products in drugstore, etc. In our experience, however, they are most useful in case of low-vision patients with a nonsevere low vision that allows the patients a certain level of self-sufficiency. Also, portable video magnifiers without screen included exist.

An example of this technology is the mouse video magnifier. It consists in a camera mounted on a mouse that slides above the text, which is projected on a screen. The screen is not included; this device must be connected to a monitor, a PC, or a TV to be used. In some cases, these products are provided with computer software that allows capture of images on the patient's PC.

4.2.3 Other kinds of devices

Many braille systems exist on the market. One of them is the braille printer, which works like a normal printer with the difference that it prints braille text onto a thick paper. Those devices are usually linked to a computer equipped with braille



Figure 11.
A braille display.

translator software that converts a text from a language into a braille text. This text is then embossed into a thick paper with a braille printer [44].

Braille displays (**Figure 11**) are special displays made of special materials (metals or plastics). They instantly translate the text into braille that is appearing on the computer, and they change with the scrolling of the text on the PC screen. They are usually placed under the PC keyboard. Also portable note takers exist, making patients able to take notes via a keyboard in braille; the system is then able to recall and read them via voice activation. A braille writer is very similar to a standard typewriter, with the difference that its keyboard is made in braille. It instantly embosses letters on a thick paper. System based on optical character recognition (OCR) is made of a camera, which scans the text; this is then read by the system itself via a synthesized voice. Many OCR systems offer special features such as storage of the texts acquired, research of words, and chapters of the text. The advantage of these systems is that they are not dependent on a PC for working. Many OCR apps are now available, hence making this technology more widespread [45].

Audiobooks are another useful option in low-vision patients of pathologic myopia. Almost any of the best-known novels can be found in audiobook format, in which a voice reads the texts for the listeners. Many low-vision societies make audiobooks available and also apps for new devices such as that found in tablets.

4.2.4 Household, personal, and other independent living products

In this category, all the devices that improve patient's self-sufficiency, safety, and quality of life are included. As many of them exist, we will cite only the best known: vibrating-, braille and talking watches, talking blood pressure- and glucose meters, talking thermometers, weighted eating utensil fork, talking kitchen scale, cut-resistant gloves, talking microwave, labeling systems, object locators, etc.

4.2.5 Field enhancement

As we already said, pathologic myopic patients are at risk to develop glaucoma and optic neuropathies. Patients can also develop ring-shaped scotomas even if the patient is not affected by glaucoma. However, when this pathology is present, one of the visual field alterations that a patient suffering from glaucoma can experience

is the restriction of the peripheral visual field up to the development of a tubular field of view. In the abovementioned cases, field enhancers are useful. There are many tools that can act as field expanders such as reverse telescopes, minifiers, and prisms. Minifiers act by “miniaturizing the space” in order to maximize the portion of this one that can be seen into a tubular visual field. There are many powers of miniaturization on the market; best known are 0.25× and 0.5×. They can be found as handheld, clip-on, or spectacle mounted. Reverse telescopes are Galilean or Keplerian telescopes used by the object lens and not by the ocular lens; in this way, a minification of the space is obtained in order to fit a restricted visual field and the power of minification is equal to the power of the telescope [46].

Minification devices are a useful help only in static situation, because patient is not able to use them while walking since he perceives many aberrations and a very restricted visual field. Prisms combined in a field expanding channel lens are also an option in such cases [47]. This spectacle lens is made of two lateral prisms of 12 pd and an inferior one of 8 pd; a central nonprismatic lens, which has the dioptric power of the distance vision prescription, is also present. Prisms work only in position of gaze different than the primary. This lens can be built and used for peripheral defects even more than 20°.

5. Conclusions

High myopia, defined as refractive error of at least -6.00D and/or an axial length of 26.5 mm or more, can lead to many morphological changes in the eyeball that can cause development of complications. World is facing a rapid rise in high myopia and pathologic myopia incidence, and some areas of the globe show a more rapid increase in this trend than other ones, such as Asian regions. In such areas, the incidence rate can also reach 80–90% of children and young adults in school age. Major risk factors in myopia progression are intensive education and limited time outdoors. It is estimated that this percentage and the magnitude of myopic shift will rise in the future because of the rising educational pressure and needs especially in developing countries. The constant rising in the amount of time spent using high-tech devices worldwide such as tablets and smartphone and its use by children represents an adjunctive risk factor. These evidences produce a worrying outline for the future, because early onset of myopia in childhood is associated with high myopia in adult life. Prevention in such cases can count on interventions on school system, favoring open air activities if possible, and children's lifestyle modifications [48], spending more time outside and reducing the time spent with electronic devices. Recently, many clinical trials investigated the role of pharmacologic therapy with atropine 0.01% eye drops and orthokeratology [49] in slowing the progression of myopia in children and young individuals with good results.

Studies estimated that by 2050, half of the global population (5 billion people) would be myopic and 25% of those (1 billion) would be considered highly myopic ($>-5\text{D}$), making it a serious problem for healthcare systems and governments facing the rise in healthcare expenditure, because such patients have a greater need of care and assistive devices, low-vision interventions, and a greater impact of the disease on their work productivity, eventually quitting work and hence increasing the costs of this pathology. In our opinion, prevention of high myopia by reducing near work when possible and stimulating open-air activities for children is essential; we also think that atropine drops will be an useful tool for reducing the rising in incidence of myopia in children. For senior individuals affected by high myopia, a comprehensive ophthalmologic assessment with OCT exam, each 6–12 months, depending on the degree of myopia, is in our opinion crucial to be able to act promptly in case of onset of complications related to high myopia.

As above mentioned, when complications due to high myopia occur, we talk about pathologic myopia. Many complications can develop, and their treatment can count mainly on surgery and anti-VEGF therapy. When treatment is not possible or after this in order to boost and maximize the visual recovery, ophthalmologist can recur to visual rehabilitation strategies. These can count into two main categories of tools: visual stimulation and visual aids. Acoustic biofeedback is one of the most effective techniques in order to stimulate visual system. First of all, it is mandatory to analyze the characteristics of the visual field defects that are affecting the patient. Two types of defects can occur in such patients: central scotomas (of various shape, size, and depth) and peripheral defects. The two can also occur simultaneously in various combinations. Then, in case of a central defect, after analyzing patient's retinal sensitivity and fixation stability with a microperimetry, if the patient has already developed a preferred retinal locus (PRL or pseudofovea) by itself, it is possible to stimulate this one if it is in a favorable position in order to boost fixation stability or to choose a new point to relocate the PRL in a position that the physician considers more favorable for the patient because of a better residual retinal sensitivity. A PRL is a point that the patient with a central scotoma uses to fixate object, as a "substitute" of the natural impaired fovea. This point is chosen considering patient's expectations, attitudes, activities and the residual sensitivity microperimetric map of the patient and the distance that the point candidate to be stimulated from the natural fovea. It means that for a better outcome it would be better to choose a point with the best residual retinal sensitivity not too far from the natural fovea if possible. Acoustic biofeedback is a technique that trains the patient relocating the PRL to a more useful position; when a point to become the new PRL is chosen by the examiner, during the acoustic biofeedback session, a beep is produced by the machine (microperimeter), and it becomes more continuous as the point to be stimulated gets closer to the center of the fixation target on the machine, hence training the patient to use the point set by the ophthalmologist. This one guides the patient during the whole session, giving him instructions where to move his gaze to match the trained PRL and the center of the fixation point of the machine. A typical acoustic biofeedback rehabilitation protocol is composed of 10 sessions of 10 min each, typically one session per week. However, it can be repeated if necessary. In case of a peripheral defect alone, acoustic biofeedback can be useful if an unstable fixation is present in order to stimulate the fixation point and make it more stable. Visual aid use can also benefit of a more stable fixation; they are available for distance and intermediate-near vision. For distance vision, the most popular devices are telescopes, Galilean, and Keplerian ones. They ideally "approach" far items to the observer by magnifying them. They can be monocular or binocular, clip-on, spectacle mounted, and handheld. For near vision, microscopic systems are available; they are high dioptric positive power lens that work by reducing focal length. There are many solutions that use this technology: handheld magnifiers, bar magnifiers, positive overcorrection of near prescription, visiolettes, and prismatic hypercorrective are available in various spherical powers and so in various magnification power. Electronic aids for near vision are available, with portable and fixed CCTV being the mainstay of the category. Other solutions are also available such as braille systems (displays, printers, note takers), household, personal and other independent living products (for example, braille and talking watches, talking blood pressure and glucose meters, etc.), OCR systems, and audiobooks. Many recent apps for aided mobility, OCR, etc., have been placed on the market. In patients with peripheral visual field defects, field enhancement systems are very useful. Reversed telescopes and field expanding channel lens represent the mainstay of this category.

Conflict of interest

Enzo Maria Vingolo, Giuseppe Napolitano, and Lorenzo Casillo declare that they have no conflict of interest.

Notes/thanks/other declarations

Authors would like to thank and dedicate this chapter to all the staffs of ophthalmology department in our hospital. You all are great!

Author details

Enzo Maria Vingolo*, Giuseppe Napolitano and Lorenzo Casillo
Department of Medical-Surgical Sciences and Biotechnologies,
U.O.C. Ophthalmology, Sapienza University of Rome, Terracina, Italy

*Address all correspondence to: enzomaria.vingolo@uniroma1.it

IntechOpen

© 2019 The Author(s). Licensee IntechOpen. This chapter is distributed under the terms of the Creative Commons Attribution License (<http://creativecommons.org/licenses/by/3.0>), which permits unrestricted use, distribution, and reproduction in any medium, provided the original work is properly cited. 

References

- [1] Chang SW, Tsai IL, Hu FR, et al. The cornea in young myopic adults. *The British Journal of Ophthalmology*. 2001;**85**:916-920
- [2] Ortiz S et al. Relationships between central and peripheral corneal thickness in different degrees of myopia. *Journal of Optometry*. 2014;**7**(1):44-50
- [3] Ikuno Y, Tano Y. Retinal and choroidal biometry in highly myopic eyes with spectral-domain optical coherence tomography. *Investigative Ophthalmology & Visual Science*. 2009;**50**:3876-3880
- [4] Lim R, Mitchell P, Cumming RG. Refractive associations with cataract: The Blue Mountains Eye Study. *Investigative Ophthalmology & Visual Science*. 1999;**40**(12):3021-3026
- [5] Lee KE, Klein BE, Klein R, et al. Changes in refraction over 10 years in an adult population: The Beaver Dam Eye study. *Investigative Ophthalmology & Visual Science*. 2002;**43**:2566-2571
- [6] Pan C-W, Boey PY, Cheng C-Y, et al. Myopia, axial length, and age-related cataract: The Singapore Malay Eye Study. *Investigative Ophthalmology & Visual Science*. 2013;**54**(7):4498-4502. DOI: 10.1167/iovs.13-12271
- [7] Satchi K, McNab AA. Orbital decompression in the treatment of proptosis due to high axial myopia. *Ophthalmic Plastic & Reconstructive Surgery*. 2010;**26**(6):420-425
- [8] Chen M, Zhou XT, Xue AQ, Wang QM, et al. Myopic proptosis and the associated changes in axial components of the eye. *Zhonghua Yan Ke Za Zhi*. 2007;**43**(6):525-529
- [9] Yamaguchi M, Yokoyama T, Shiraki K. Surgical procedure for correcting globe dislocation in highly myopic strabismus. *American Journal of Ophthalmology*. 2010;**149**:341-346
- [10] Yokoyama T. Ocular motility abnormalities. In: Spaide R, Ohno-Matsui K, Yannuzzi L, editors. *Pathologic Myopia*. New York, NY: Springer; 2014
- [11] Taylor R, Whale K, Raines M. The Heavy Eye Phenomenon: Orthoptic and ophthalmic characteristics. *German Journal of Ophthalmology*. 1995;**4**:252-255
- [12] Liu C-F, Liu L, Lai C-C, et al. Multimodal imaging including spectral-domain optical coherence tomography and confocal near-infrared reflectance for characterization of lacquer cracks in highly myopic eyes. *Eye (London, England)*. 2014;**28**(12):1437-1445. DOI: 10.1038/eye.2014.221. Epub 2014 Sep 19
- [13] Querques G, Corvi F, Balaratnasingam C, et al. Lacquer cracks and perforating scleral vessels in pathologic myopia: A possible causal relationship. *American Journal of Ophthalmology*. 2015;**160**(4):759-766
- [14] Suga M, Shinohara K, Ohno-Matsui K. Lacquer cracks observed in peripheral fundus of eyes with high myopia. *International Medical Case Reports Journal*. 2017;**10**:127-130. DOI: 10.2147/IMCRJ.S131545
- [15] Ohno-Matsui K, Jonas JB, Spaide RF. Macular Bruch membrane holes in highly myopic patchy chorioretinal atrophy. *American Journal of Ophthalmology*. 2016;**166**:22-28. DOI: 10.1016/j.ajo.2016.03.019. Epub 2016 Mar 24
- [16] Soubrane G. Choroidal neovascularization in pathologic myopia: recent developments in diagnosis and treatment. *Survey of Ophthalmology*. 2008;**53**(2):121-138

- [17] Miyata M et al. Detection of myopic choroidal neovascularization using optical coherence tomography angiography. *American Journal of Ophthalmology*. 2016;**165**:108-114
- [18] Wong TY, Ohno-Matsui K, Leveziel N, et al. Myopic choroidal neovascularisation: Current concepts and update on clinical management. *British Journal of Ophthalmology*. 2015;**99**:289-296
- [19] Leveziel N, Caillaux V, Bastuji-Garin S, et al. Angiographic and optical coherence tomography characteristics of recent myopic choroidal neovascularization. *American Journal of Ophthalmology*. 2013;**155**(5):913-919. DOI: 10.1016/j.ajo.2012.11.021. Epub 2013 Jan 23
- [20] Milani P, Massacesi A, Moschini S, et al. Multimodal imaging and diagnosis of myopic choroidal neovascularization in Caucasians. *Clinical Ophthalmology*. 2016;**10**:1749-1757. DOI: 10.2147/OPTH.S108509
- [21] Ikuno Y, Ohno-Matsui K, Wong TY, et al. Intravitreal aflibercept injection in patients with myopic choroidal neovascularization: The MYRROR study. *Ophthalmology*. Jun 2015;**122**(6):1220-1227. DOI: 10.1016/j.opththa.2015.01.025. Epub 2015 Mar 4
- [22] Wolf S, Balciuniene VJ, Laganovska G, et al. RADIANCE: A randomized controlled study of ranibizumab in patients with choroidal neovascularization secondary to pathologic myopia. *Ophthalmology*. 2014;**121**(3):682-92.e2. DOI: 10.1016/j.opththa.2013.10.023. Epub 2013 Dec 8
- [23] Baba T, Ohno-Matsui K, Futagami S. Prevalence and characteristics of foveal retinal detachment without macular hole in high myopia. *American Journal of Ophthalmology*. 2003;**135**(3):338-342
- [24] Gómez-Resa M, Burés-Jelstrup A, Mateo C. Myopic traction maculopathy. In: *Microincision Vitrectomy Surgery*. Vol. 54. Karger Publishers; 2014. pp. 204-212
- [25] Mii M, Matsuoka M, Matsuyama K, et al. Favorable anatomic and visual outcomes with 25-gauge vitrectomy for myopic foveoschisis. *Clinical Ophthalmology*. 2014;**8**:1837-1844. DOI: 10.2147/OPTH.S67619
- [26] Steel D. Retinal detachment. *BMJ Clinical Evidence*. 2014;**2014**:0710
- [27] Alimanović-Halilović E. Correlation between refraction level and retinal breaks in myopic eye. *Bosnian Journal of Basic Medical Sciences*. 2008;**8**(4):346-349. DOI: 10.17305/bjbms.2008.2895. ISSN 1840-4812
- [28] Caillaux V, Gaucher D, Gualino V, et al. Morphologic characterization of dome-shaped macula in myopic eyes with serous macular detachment. *American Journal of Ophthalmology*. 2013;**156**(5):958-967.e1. DOI: 10.1016/j.ajo.2013.06.032. Epub 2013 Aug 20
- [29] Ng DS, Cheung CY, Luk FO, et al. Advances of optical coherence tomography in myopia and pathologic myopia. *Eye (London, England)*. 2016;**30**(7):901-916. DOI: 10.1038/eye.2016.47. Epub 2016 Apr 8
- [30] Viola F, Dell'Arti L, Benatti E, et al. Choroidal findings in dome-shaped macula in highly myopic eyes: A longitudinal study. *American Journal of Ophthalmology*. 2015;**159**(1):44-52. DOI: 10.1016/j.ajo.2014.09.026. Epub 2014 Sep 22
- [31] Zhu X, He W, Zhang S, et al. Dome-shaped macula: A potential protective factor for visual acuity after cataract surgery in patients with high myopia. *The British Journal of Ophthalmology*. 2019. pii: bjophthalmol-2018-313279. DOI: 10.1136/bjophthalmol-2018-313279. [Epub ahead of print]

- [32] Spaide RF. Staphyloma: Part 1. In: Spaide RF, Ohno-Matsui K, Yannuzzi LA, editors. *Pathologic Myopia*. New York, NY: Springer; 2014. pp. 167-176
- [33] Curtin BJ. The posterior staphyloma of pathologic myopia. *Transactions of the American Ophthalmological Society*. 1977;**75**:67-86
- [34] Ohno-Matsui K. Proposed classification of posterior staphylomas based on analyses of eye shape by three-dimensional magnetic resonance imaging and wide-field fundus imaging. *Ophthalmology*. 2014;**121**:1798-1809
- [35] Vingolo EM, Napolitano G, Fragiotta S. Microperimetric biofeedback training: Fundamentals, strategies and perspectives. *Frontiers in Bioscience (Scholar Edition)*. 2018;**10**(1):48-64
- [36] Crossland MD, Engel SA, Legge GE. The preferred retinal locus in macular disease: Toward a consensus definition. *Retina*. 2011;**31**:2109-2114. DOI: 10.1097/IAE.0b013e31820d3fba
- [37] Dilks DD, Julian JB, Peli E, et al. Reorganization of visual processing in age-related macular degeneration depends on foveal loss. *Optometry and Vision Science*. 2014;**91**(8):e199-e206
- [38] Ohno-Matsui K, Shimada N, Yasuzumi K, et al. Long-term development of significant visual field defects in highly myopic eyes. *American Journal of Ophthalmology* 2011;**152**(2):256-265.e1. DOI: 10.1016/j.ajo.2011.01.052. Epub 2011 Jun 12
- [39] Vasconcelos G, Fernandes LC. Low-Vision Aids. 2015. Retrieved from: <https://www.aao.org/disease-review/low-vision-aids>
- [40] Chun R, Cucuras M, Jay WM. Current perspectives of bioptic driving in low vision. *Neuroophthalmology*. 2016;**40**(2):53-58. DOI: 10.3109/01658107.2015.1134585
- [41] Legge GE. Reading digital with low vision. *Visible Language*. 2016;**50**(2):102-125
- [42] Burggraaff MC, van Nispen RMA, Knol DL, Ringens PJ, van Rens GHMB. Randomized controlled trial on the effects of CCTV training on quality of life, depression, and adaptation to vision loss. *Investigative Ophthalmology & Visual Science*. 2012;**53**(7):3645-3652. DOI: 10.1167/iovs.11-9226
- [43] Virgili G, Acosta R, Bentley SA, et al. Reading aids for adults with low vision. *Cochrane Database of Systematic Reviews*. 2018;**4**:CD003303. DOI: 10.1002/14651858.CD003303.pub4
- [44] Kalia A, Hopkins R, Jin D, et al. Perception of tactile graphics: Embossings versus cutouts. *Multisensory Research*. 2014;**27**(2):111-125
- [45] Cutter M, Manduchi R. Improving the accessibility of mobile OCR apps via interactive modalities. *ACM Transactions on Accessible Computing*. 2017;**10**(4):11
- [46] Krefman RA. Reversed telescopes on visual efficiency scores in field-restricted patients. *American Journal of Optometry and Physiological Optics*. 1981;**58**:159-162
- [47] Apfelbaum H, Peli E. Tunnel vision prismatic field expansion: Challenges and requirements. *Translational Vision Science & Technology*. 2015;**4**(6):8. DOI: 10.1167/tvst.4.6.8
- [48] Morgan IG, French AN, Ashby RS, et al. The epidemics of myopia: Aetiology and prevention. *Progress in Retinal and Eye Research*. 2018;**62**:134-149
- [49] Leo SW. Current approaches to myopia control. *Current Opinion in Ophthalmology*. 2017;**28**(3):267-275