

We are IntechOpen, the world's leading publisher of Open Access books Built by scientists, for scientists

6,900

Open access books available

186,000

International authors and editors

200M

Downloads

Our authors are among the

154

Countries delivered to

TOP 1%

most cited scientists

12.2%

Contributors from top 500 universities



WEB OF SCIENCE™

Selection of our books indexed in the Book Citation Index
in Web of Science™ Core Collection (BKCI)

Interested in publishing with us?
Contact book.department@intechopen.com

Numbers displayed above are based on latest data collected.
For more information visit www.intechopen.com



Dental Traumatology in Pediatric Dentistry

*Asli Topaloglu Ak, Didem Oner Ozdas, Sevgi Zorlu
and Pinar Kiymet Karataban*

Abstract

In this chapter, epidemiology of dental trauma will be discussed in terms of its incidence and prevalence among primary and permanent dentition. Dental trauma causes and its distribution in accordance with age and sex will be highlighted. Classification of dental trauma based on soft and hard tissue injuries will be outlined, and subsequently, clinical examination and diagnosis will be featured. Treatment modalities and variations between permanent and primary dentition will be discussed along with the new treatment era namely regenerative approach and decoronation. Splints, techniques, and follow-up routines will also be discussed. Last but not least, prevention of dental trauma will be discussed.

Keywords: dental trauma, children, splints, classification

1. An epidemiological approach to dental traumatology

Traumatic dental injuries are a public dental health problem worldwide and can occur throughout life. Various interventions and treatment options are available, depending on the specific traumatic injury sustained, but the fact is, every trauma is a unique case, which requires unique diagnosis and treatment.

The International Association of Dental Traumatology reports that one of every two children sustains a dental injury, most often between the ages of 8 and 12 years. The suggestion is in most cases of dental trauma; a rapid and appropriate intervention can lessen its impact from both oral and esthetic standpoint. To that end, the association has developed guidelines for the evaluation and management of traumatic dental injuries.

Although the oral region comprises a small part as 1% of the total body area, 5% of all bodily injuries are oral traumatic injuries. Traumatic dental injuries tend to occur at childhood or an young age during which growth and development take place. In preschool children, with injuries to the head being the most common, oral injuries make up as much as 17% of all bodily injuries, in contrast to later in life when injuries to hands and feet are the most common.

Dental injuries are the most common and are seen in as many as 92% of all patients seeking consultation or treatment for injuries to the oral region. Also, soft-tissue injuries are seen in 28%, simultaneously with dental injuries, and fractures involving the jaw are seen more rarely, in only 6% of all patients presenting with oral injuries [1–8].

Trauma has a multitude of consequences for the traumatized individual, family members, and society. The impact is not only physical but also psychosocial and economic. Every pediatric patient should be given the opportunity to receive a complete dental treatment for traumatic dental injuries, but a complete treatment plan involving participation of specialists in several disciplines can often be complicated and expensive. In contrast to many other traumatic injuries treated on an outpatient basis, traumatic dental injuries are mostly irreversible, and thus, treatment will likely continue for the rest of the patient's life [9–14].

Constructing a complete treatment plan can be challenging because of the diversity of evidence-based interventions and reported outcomes in clinical studies. Besides, there is evidence that clinical researchers may prefer reporting outcomes that enhance results—this is known as outcome reporting bias. International Association for Dental Traumatology suggests that this diversity and reporting bias shall be eliminated by a standardized trauma management guideline in order to make the outcomes relevant to patients, clinicians, and policy makers as findings of research are to influence practice and future research [15].

It has been reported that, anterior teeth, especially the maxillary central and lateral incisors are predominantly affected by traumatic dental injuries for both primary and permanent dentitions. Traumatic dental injuries generally affect a single tooth except certain trauma events, such as traffic accidents, violence, and sports injuries, which result in multiple tooth damage.

Besides its numerous beneficial effects, active participation in sports activities may increase the risk for traumatic injuries to oral and dental tissues. These injuries are most prominent in boxing, basketball, hockey, and soccer.

Traumatic dental injuries in the primary dentition appear to be rather stable at approximately 30% in most studies. It is been reported that one-third of all preschool children have suffered from traumatic injuries to the primary dentition in most of the countries. Although variations were observed within and between countries, one-fourth of all school children and almost one-third of adults have also suffered traumatic injuries to the permanent dentition [16–19].

2. Incidence and prevalence of dental trauma

The prevalence of dental injuries varies within countries regarding the research reports. According to two surveys in US, the prevalence of traumatic dental injuries varies between 18.4 and 16% in 6–20 years old and 27.1 and 28.1% in 21–50 years old age groups. In UK, dental trauma prevalence varies between 23.7 and 44.2% in 11–14-year age groups and mostly observed in schools [20–23]. In other European countries, the prevalence varies between 13.5 and 20.3% in 6–24-year age groups. In Middle East and Asia, the prevalence varies between 16.2 and 32% in 8–16 years old age groups as the 10–11 years age groups revealed the highest score. There is an absolute need for an international standardized trauma registration either being able to detect trends over time or to make reasonable comparisons between and within countries [24–32].

In most studies, it is been reported that the incidence of traumatic dental injuries in children shows a range of 1–3% in the population. The peak incidence for traumatic dental injuries per 1000 individuals is found up to 12 years of age. The incidence is lower in older ages. Boys are more often affected than girls.

The variation of both prevalence and incidence presented in the literature reflects the local differences, environmental variations, behavioral, cultural, and

socioeconomic diversities as well as the lack of standardization in methods and classifications [12, 16, 33].

2.1 Etiologic risk factors

Etiologic factors are very much related to the age, gender, environment, and activity of the patient.

Age is an important factor, as school children and adolescent are the main groups who are mostly prone to traumatic injuries. It is estimated that 71–92% of all traumatic dental injuries occur before the age of 19 years; other studies have reported a decrease after the age of 24–30 years.

While in preschool children, the most common cause of traumatic dental injuries are accidental falls, in school age children, injuries are often caused by sports activities or hits by another person. Traffic accidents and assaults are the predominant etiologic factors in adolescents and young adults, and oral injuries occur most frequently during leisure time and during weekends associated with the western lifestyle today.

Gender is also a risk factor as males experience traumatic dental injuries at least twice more often than females. Yet, recent studies have shown a reduction in this gender difference in sports, which might be due to an increased interest in sports among girls Traebert et al. reported that girls can be exposed to the same risk factors of TDI as boys, which is a characteristic of modern Western society. Thus, environment and the activities of a person are undoubtedly more determining factors of TDIs than gender.

Another factor to be pointed is that in many countries, an increasing number of old people are possessing their own teeth, which, in near future, may lead to the increase in prevalence of dental traumatic injuries due to accidental falls in geriatric population [16, 33–35].

3. Guideline on management of acute dental trauma

3.1 Examination

Before making a treatment in trauma cases, dentist must check the circumstances written in below:

1. Patient's name, age, gender (include weight for young patients), address, and contact numbers
2. Symptoms of central nervous system should be checked after the accident
3. General health of the patient
4. Three W' s must be asked "when, where, and how the injury occurred"
5. Treatment the patient received elsewhere
6. Previous dental injury history
7. Disturbances in the bite

8. Tooth reactions to thermal changes or sensitivity to sweet/sour
9. Soreness of the teeth during eating or by touching
10. If the patient is feeling spontaneous pain in the teeth.

Access for risk of concussion or hemorrhage:

- Symptoms may be delayed for minutes to hours
- It must be asked if there is a loss of consciousness
- Difficulty of speech and /or slurred speech
- Nausea/vomiting
- Fluid from ear/nose
- Confusion of situations
- Blurring in vision or uneven pupils.

3.2 History

- Timing
- Mechanism of injury
- Location
- Bleeding must be checked. Also, previous dental traumas should be asked.

3.3 Examination

Clinical examination consists of visual inspection, palpation, thermal testing, and electric pulp testing. First and foremost, account for all teeth:

- Extent of injury
- Lacerations
- Teeth position
- Appearance of tissue should be tested along with the color of tooth (purple, blue, gray, or yellow) and its mobility
- Pulp testing (percussion, EPT, and thermal): but if the traumatized tooth is immature, EPT may not be accurate
- Palpation of soft tissue must be recorded. Because the recordings will help you for follow-up appointments. Taking photographs may help to make proper

examination and diagnosis. These views are going to help the comparison of preoperative and follow-up of traumatized teeth.

3.4 Radiographs: AAE-recommended guidelines

- Occlusal
- Periapicals radiographs with different lateral angulations
- CBCT if more serious of an injury.

3.4.1 Panorex

- Periapical-radiographs taken from the same angle every time will help to make good treatment decisions. Using a film holder will hold the radiograph in a paralleling technique
- Occlusal
- CBCT.

3.5 Types of dental trauma on hard tissue and pulp

Enamel infraction
Enamel fracture
Enamel-dentin fracture
Enamel-dentin-pulp fracture
Crown-root fracture w/o pulp involvement
Crown-root fracture with pulp involvement.

3.6 Types of dental trauma on periodontal tissue

Concussion
Subluxation (loosening)
Intrusive luxation (central dislocation)
Extrusive luxation (partial avulsion)
Lateral luxation
Retained root fracture.

3.7 Types of dental trauma on supporting bone

Exarticulation (complete avulsion)
Comminution of the alveolar socket
Alveolar socket wall fracture
Alveolar process fracture
Mandible or maxilla fracture.

3.8 Types of dental trauma on gingival or oral mucosa

Gingival or oral mucosal laceration
Gingival or oral mucosal contusion
Gingival or oral mucosal abrasion (**Figures 1–3**) [9, 11–13, 15, 36, 37].

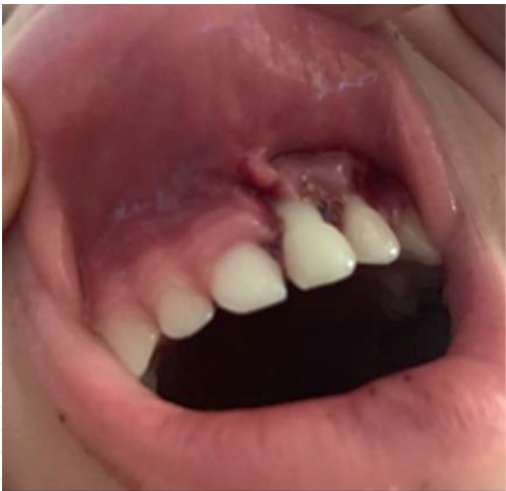

Figure 1.
Types of dental trauma: gingival laceration.

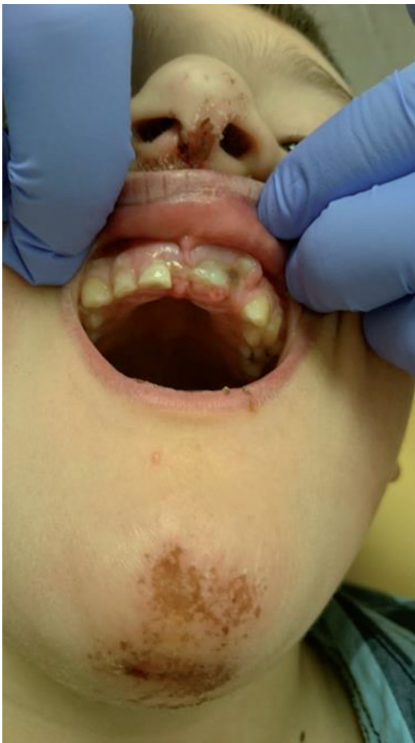

Figure 2.
Types of dental trauma: intrusive luxation (central dislocation).

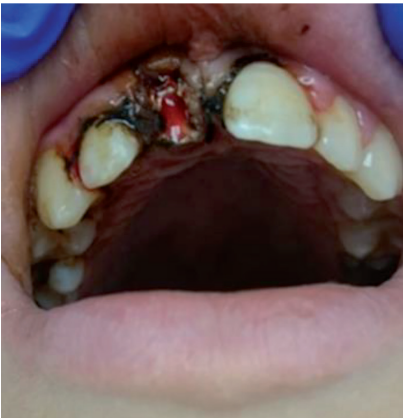

Figure 3.
Types of dental trauma: crown-root fracture with pulp involvement.

4. Dental trauma in primary dentition

Pain treatment and prevention of teeth germs must be our main goal in the treatment strategy of the traumatized primary teeth. Due to behavioral management problems or a severe trauma with a soft tissue bleeding, treatment may be overlooked or limited to extraction. However, in the overall treatment, primary teeth must be followed up clinically and radiographically in the long term.

In this section, treatment of primary dentition will be explained based on IADT treatment guidelines.

Enamel fracture: this type of fracture involves only enamel. There is no radiographic abnormality observed. Sharp edges are recommended to be smoothed. There is no need for follow-up.

Enamel dentin fracture: fracture involves enamel and dentin. Pulp is not exposed. There is no radiographic abnormality observed. The relation between the fracture and the pulp chamber can be revealed. In case behavioral management is succeeded with the patient, involved dentin can be sealed completely with glass ionomer to prevent microleakage. Composite resin restorations are good choices if lost tooth structure is large. Clinical examination is required after 3–4 weeks.

Crown fracture with exposed pulp: fracture involves enamel and dentin and the pulp is exposed. Radiographic findings can reveal the stage of root development. Preservation of pulp vitality can be accomplished by partial pulpotomy. Unless there is an cooperation with the patient, extraction is an alternative treatment approach. Clinical follow-up is required after 1 week, 6–8 weeks, and 1 year. Radiographic follow-up is required after 6–8 weeks and 1 year as well (**Figure 4**).

Crown/root fracture (without pulp exposure): this type of fracture involves enamel, dentin, and root structure. The pulp may or may not be exposed. Tooth displacement may be observed as well. Radiographical evaluation will reveal single/multiple fragments of the traumatized tooth. In case the fracture involves only a small part of the root, only fractured fragment is removed and coronal restoration can be done if the stable fragment is adequate for restoration. Otherwise, extraction is required. Clinical follow-up is required after 1 week, 6–8 weeks, and 1 year. Radiographic follow-up is required after 6–8 weeks and 1 year as well. Monitoring is vital until eruption of the successors.

Crown/root fracture (with pulp exposure): this type of fracture involves enamel and dentin and the pulp is exposed. The stage of development of root can be determined by the radiographic evaluation. Preservation of pulp vitality can be accomplished by partial pulpotomy using calcium hydroxide paste and reinforced

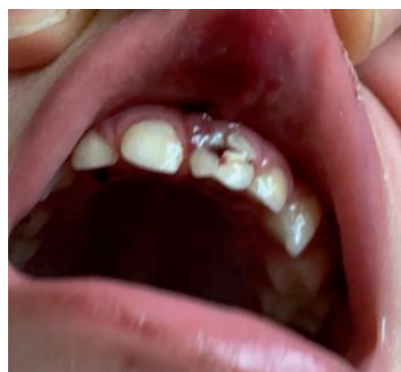

Figure 4.
Crown fracture in primary dentition.

glass ionomer as liner and composite/compomer restorations. Unless there is a co-operation with the patient, extraction is an alternative treatment approach. Clinical follow-up is required after 1 week, 6–8 weeks, and 1 year. Radiographic follow-up is required after 6–8 weeks and 1 year as well.

Root fracture: the fracture involves the alveolar bone and may extend to adjacent bone leading to segment mobility and dislocation. Frequently, an occlusal interference is reported. Radiographic evaluation is required to assess the fracture line position. Treatment should be repositioning the displaced segment and splinting. Stabilization must be for 4 weeks. Monitoring the fracture line is essential. If there is no displacement, 1 week, 6–8 weeks, and 1 year clinical follow-up are required. After 1 year, radiographic evaluation should be repeated until eruption of the successors. If the traumatized tooth/teeth are extracted as treatment choice after 1 year, both clinical and radiographic examination are still required for monitoring successors.

Alveolar fracture: the tooth is displaced, usually in a palatal/lingual or labial direction leading to mobility. Occlusal radiographic findings will reveal increased periodontal ligament space apically at its best. If there is no occlusal interference, the tooth is allowed to reposition spontaneously. If there is minor occlusal interference, slight grinding is indicated. When there is more severe occlusal interference, the tooth can be gently repositioned by combined labial and palatal pressure after the use of local anesthesia. In severe cases, when the crown is dislocated in a labial direction, extraction is indicated. Follow-ups are required as follows: 1 week and 2–3 weeks of clinical examination, and 6–8 weeks and 1 year clinical and radiographic examinations.

Concussion: clinically, tooth is sensitive to touch. There is no mobility or sulcular bleeding observed. Radiographic evaluation discloses no pathology as well. Observation is the only treatment option. Only clinical follow-up is required after 1 and 6–8 weeks.

Subluxation: an increased mobility is observed though the tooth is not displaced. There might be cervical bleeding. There is no abnormality in the radiographic evaluation. Occlusal radiography can screen possible root fracture and displacement. Observation is the only treatment option. Soft brushing and use of antibacterial agents is recommended. Only clinical follow-up is required after 1 and 6–8 weeks. Parents should be informed about an occurrence of possible crown discoloration. Unless a fistula is formed, monitoring is required.

Extrusive luxation: the tooth appears elongated due to its displacement out of its socket. Thus, it can be excessively mobile. Increased apical periodontal ligament space is disclosed in radiographic evaluation. For minor extrusion (<3 mm) in an immature developing tooth, careful repositioning or leaving the tooth for spontaneous alignment can be the treatment options. Extraction is indicated for severe extrusion in a fully formed primary tooth. Clinical follow-up is required after 1 week, 6–8 weeks, and 1 year. Radiographic follow-up is required after 6–8 weeks and 1 year as well. Parents should be informed about the possible occurrence of discoloration.

Lateral luxation: the tooth is displaced, usually in a palatal/lingual or labial direction and will be immobile. If there is no occlusal interference, the tooth is allowed to reposition spontaneously. For minor occlusal interference, slight grinding is indicated. If there is more severe occlusal interference, the tooth can be gently repositioned after the use of local anesthesia. If the crown is dislocated severely in a labial direction, extraction is indicated. Clinical follow-up is required after 1 week, 6–8 weeks, and 1 year. Radiographic follow-up is required after 6–8 weeks and 1 year as well.

Intrusive luxation: when the apex is displaced toward labial bone plate, the apical tip appears shorter than its contra lateral and the tooth is left for spontaneous repositioning. When the apex is displaced toward the permanent tooth germ, tooth appears elongated and must be extracted. Clinical follow-ups are required for 1 week, 3–4 weeks, 6–8 weeks, 6 months, and 1 year after, whereas radiographic

follow-up is 6–8 weeks and 1 year later. Clinical and radiographic monitoring is essential until eruption of the permanent successor.

Avulsion: clinical findings reveal that tooth is not in the socket; however, radiographic examination is required to confirm and not to overlook intrusion. Replantation of the avulsed teeth is not recommended. Clinical follow-ups are required for 1 week, 6 months, and 1 year after, whereas radiographic follow-up is for 6 months and 1 year after to monitor successors' eruption.

5. Classification, definition, examination, and treatment planning in dental traumas

5.1 Hard tissue and pulp in permanent dentition

Enamel infraction: no need to restore.

Enamel-fracture: it is a kind of uncomplicated crown fracture. An enamel fracture is a crown fracture limited to loss of enamel only. Small enamel fractures can be polished. Composite resin restoration may be preferred for more involved enamel fractures (**Figure 5**).

Enamel-dentin fracture: it is a kind of uncomplicated crown fracture. The tooth should be restored with composite resin. If the fragment is available, reattachment of fragment can be attempted (**Figure 6**).

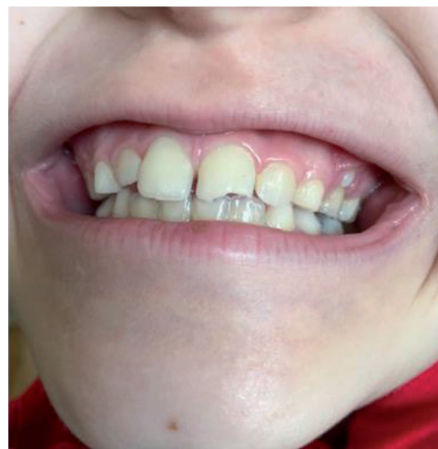

Figure 5.
Enamel fracture.

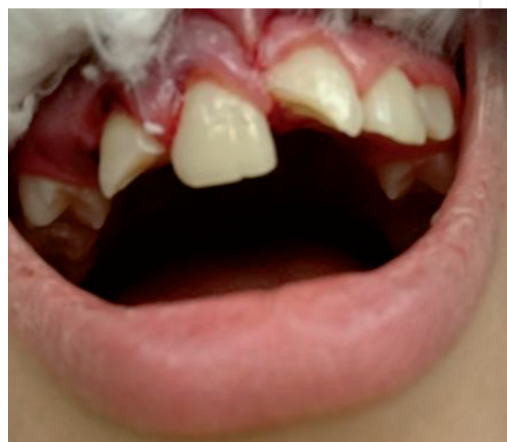

Figure 6.
Enamel-dentin and pulp fracture.

Enamel-dentin-pulp fracture: a complicated crown fracture involves enamel and dentin with pulp exposure. If the pulp exposure is visible, only a pink spot or bluish exposure site is cleaned and pulp-capping agent is applied. For larger pulpal exposures, partial pulpotomy and direct pulp-capping procedures are performed. Crown restoration method is the same as in uncomplicated crown fractures. Pulp capping and restoration should be performed at the same appointment, if possible (**Figures 6–8**).

Crown fracture combined with luxation results in ischemic changes that can lead to pulp necrosis. In these cases, there is no response to vitality tests. It is possible that the tooth has sustained a luxation injury and pulp necrosis (coagulation necrosis) is present. According to Dr. Tsukiboshi, for young patients under 18 years of age, regardless of pulp vitality, the restoration of the tooth should be done. Then, the patient should be followed for 1, 3, and 6 months to determine pulp vitality. After the waiting period, if pulp necrosis occurs, root canal treatment needs to be performed. Adult patients with a traumatized mature tooth with closed apex, after the confirmation of pulp necrosis in the first appointment, root canal treatment should be completed. Otherwise, pulpectomy may be performed (**Figures 9 and 10**).

Crown-root fracture w/o pulp involvement: the treatment is similar to the uncomplicated crown fracture. Firstly, necessity of pulp capping or partial pulpotomy is evaluated and then, rearrangement of the fragment is performed. If no need to pulp capping or partial pulpotomy, flowable composite resin may help to combine the fractured parts of the crown.

Crown-root fracture with pulp involvement: in these cases, the fractured segment accounts for the larger part of the crown and the fracture line has extended to the alveolar crest or below. These teeth may be seen too difficult to restore, but the location of the fracture line may help to decide the treatment procedure. If the location of the fracture line is located within the coronal third of the root, crown restoration is possible after the extrusion of the root. There are two ways for extrusion of the root: orthodontic or surgical.

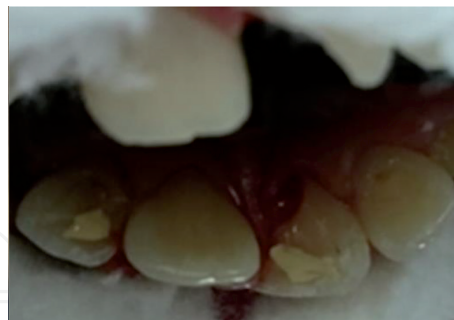

Figure 7.
Pulp capping after dental trauma.

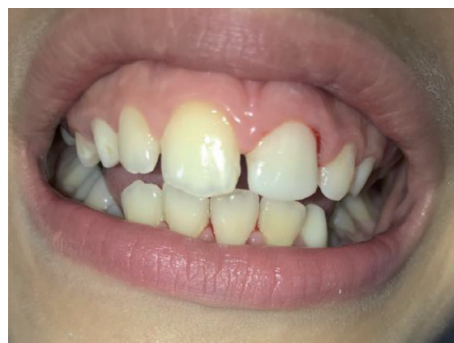

Figure 8.
Restoration during first appointment.

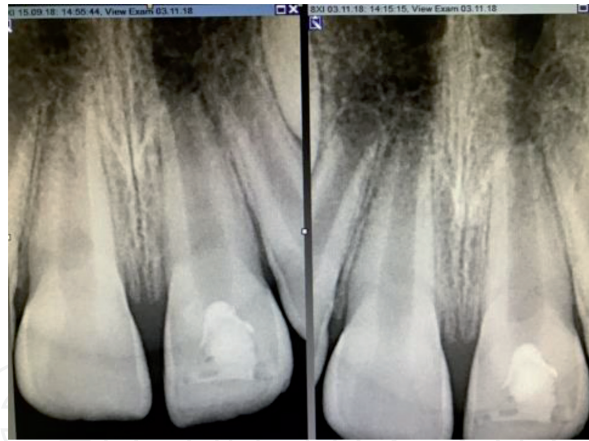


Figure 9.
Young patient's traumatized teeth with open apex.

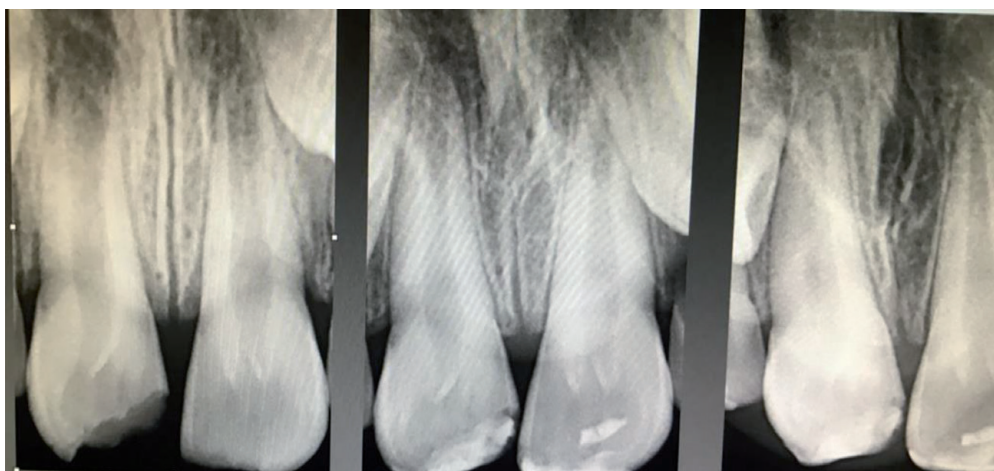

Figure 10.
Closure of apex of traumatized incisor after 1.5 years.

5.2 Root fracture

Root fracture is a fracture that involves cementum, dentin, and pulp. The fracture line may be horizontal, oblique, or vertical. But vertical root fractures may generally occur in endodontically treated teeth. For that reason, in this chapter, horizontally or obliquely fractured teeth will be considered.

Root fractures are classified as shallow or deep according to the location of fracture line. Root fracture is generally diagnosed by radiographs. Sometimes, displacement of the coronal segment is not present. So, the fracture line is easily missed by conventional radiographic techniques. Therefore, it is better to take the radiograph from different angles. Or cone beam computed tomography may be used to diagnose the root fractures. Otherwise, fracture lines may be discovered after several months.

While performing electric pulp testing, tooth may not be responding to it. In that cases, three possibilities may be thought: pulp tissue is severed at the fracture, there is no severance of the pulp, only the subluxation in the apical fragment or the pulp is severed, and the apical fragment is subluxated.

5.2.1 Treatment planning of deep root fractures

The treatment of deep root fracture is simple: repositioning and fixation of coronal segment. Depending on how deep the fracture is and how mobile the coronal

segment is, fixation may be required for up to 3 months. Six months later, if there is no pulp necrosis, there will be no need to root canal treatment. In case of pulp necrosis, root canal treatment is done up to the fracture line [9, 10, 36–39].

5.2.2 Treatment planning of shallow root fractures

Restorative treatment can be very difficult. Sometimes extraction is the best treatment planning. If the extraction is the chosen treatment, the patient's age, oral condition, oral hygiene habits, the tooth's position, and the occlusion should be evaluated and then autotransplantation may be considered as an alternative plan.

5.3 Subluxation

Subluxation is clinically defined as injury to the periodontal tissues accompanied by bleeding from gingival sulcus, an increase in mobility but no dislocation of the tooth. There is sensitivity in percussion, and high mobility and bleeding are important criteria in diagnosis of subluxation. Electric pulp testing is important. In immature tooth, electric pulp testing will not respond, so re-test with electric pulp testing after a week is advised.

5.3.1 Treatment planning

In immature tooth: only follow-up is necessary. Root canal treatment is indicated in the presence of pulp necrosis. When there is a possibility of pulp necrosis, root canal treatment can be initiated without anesthesia.

In mature tooth: follow-up visits without invasive treatment are advised 6–12 months after injury to allow pulp vitality to be recovered. In case of pulp necrosis, root canal treatment is indicated.

5.4 Extrusive luxation

Extrusive luxation results in damage to the periodontal tissues as the tooth is displaced in coronal direction. The periodontal tissue and the root are not completely separated, but the blood supply at the apex is disrupted. There is high mobility, bleeding, and electric pulp testing response is negative. Radiographically, there is widening in periodontal ligament space.

5.4.1 Treatment planning

Repositioning, fixation, and follow-up are the steps of treatment planning. Root canal treatment is avoided until pulp necrosis is confirmed. After confirmation of pulp necrosis, root canal treatment is indicated. In immature tooth, apexification and apexogenesis may be applicable.

5.5 Lateral luxation

Lateral luxation is an injury to the periodontal and alveolar supporting tissues that the tooth displaces laterally. The crown of the tooth is displaced palatally or lingually, and the tooth may be apically displaced with alveolar bone fracture on the labial side. The blood supply is completely disrupted at the apical side, but periodontal tissues have not been separated. Radiographically, the root shape and alveolar socket are not aligned. Sometimes, the traumatized teeth may be locked because of fracture on alveolar bone. This situation may be confused with ankylosis.

5.5.1 Treatment planning

Repositioning, fixation, and regular follow-up are the steps of treatment of lateral luxation. In fixation period, if alveolar fracture occurs, fixation period will take at least 3 months. Root canal treatment may be delayed until pulp necrosis has been confirmed. In young adults, apexification and apexogenesis may be treatment alternatives (**Figures 11 and 12**).

5.6 Intrusive luxation

Intrusion is a luxation injury that results in apical displacement of tooth. In some cases, alveolar bone fracture is also seen. In the diagnosis of intrusion, differential

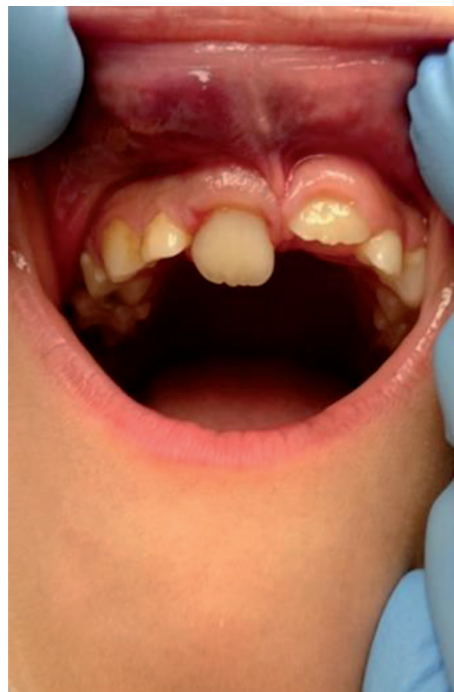

Figure 11.
Lateral luxated central incisor.

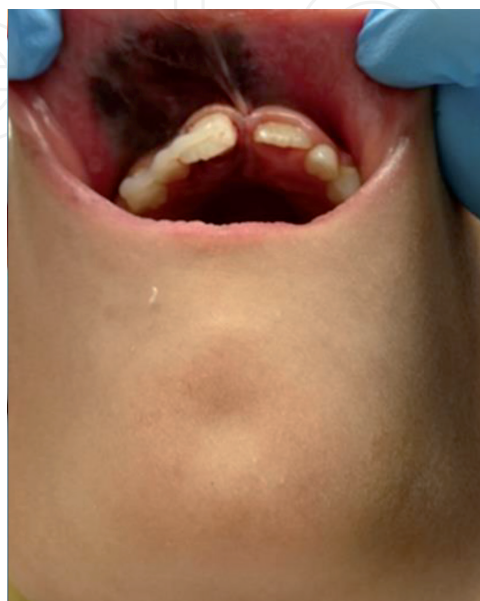


Figure 12.
Splinting after lateral luxation.

diagnostic criteria should be detected. If the tooth is intruded apically compared with adjacent teeth, intrusion should be thought. Reduced mobility may also be seen. Percussion sound is a metallic sound. There is no percussion sensitivity. If there is no clear periodontal ligament in radiograph, the intrusion should be suspected. CBCT images are important to differentiate the diagnosis of lateral or intrusive luxation (**Figure 13**).

5.6.1 Treatment planning

The healing of intruded tooth may be affected by some factors such as patient's age, root development degree, and depth of intrusion.

According to some studies, as age increases, the incidence of pulp necrosis, loss of marginal bone, and root resorption also increase. If intrusion is more than 7 mm, the more complications may be seen compared with those that are intruded less than 3 mm. Time between injury and treatment, type of fixation, and use of antibiotics may also affect the results.

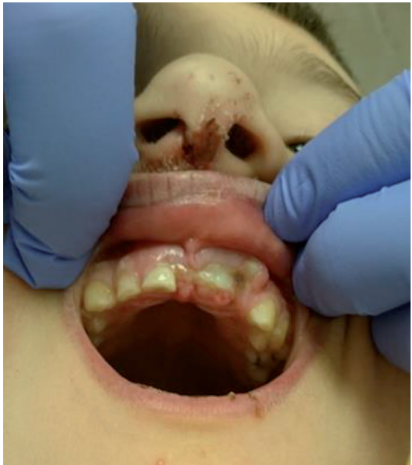


Figure 13.
An intruded central incisor.

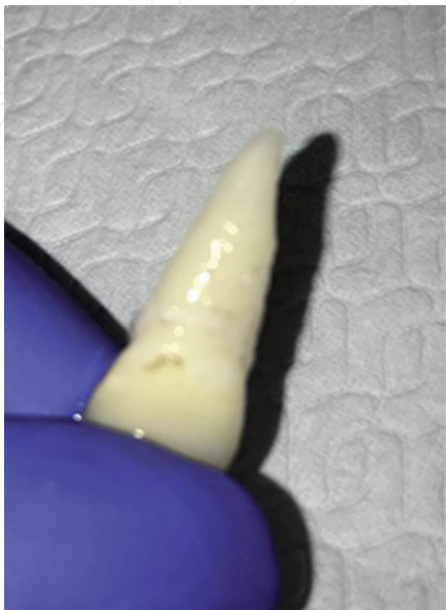

Figure 14.
An avulsed tooth.

Spontaneous re-eruption, orthodontic extrusion, and the surgical extrusion are the main options of intrusive luxation.

Dr. Tsukiboshim suggests spontaneous re-eruption when the depth of intrusion is shallow and the root is immature whereas surgical extrusion is indicated when the depth of intrusion is deep and the root is mature.

5.7 Transient apical breakdown (TAB)

TAB is a phenomenon linked to the repair processes in the traumatized pulp or pulp and periodontium of luxated mature teeth, which returns to normal when repair is completed. This phenomenon is described by Frances Andreasen in 1986.

5.8 Avulsion

Avulsion is defined as the condition that the whole tooth is completely separated from the supporting tissues.

The success rate for an avulsed tooth after replantation depends on the vitality of periodontal ligament and attachment of the tooth (**Figure 14**) [9–12, 15, 24, 26, 27, 31, 36–40].

6. Splinting

6.1 A splint may be necessary to stabilize the traumatized tooth after injury

Dental splint is a rigid or flexible device or compound used to support, protect, or immobilize teeth that have been loosened, replanted, fractured, or subjected to certain endodontic surgical procedures (**Figures 15–17**).

6.1.1 Flexible splinting assists in healing

Characteristics of the ideal splint include:

1. easy to fabricate in the mouth and without extra trauma to the tooth
2. passive if not orthodontic forces are intended
3. allows for physiologic mobility
4. nonirritant to soft tissues, periodontal tissues, and noncarcinogenic
5. does not interfere with occlusion
6. easy to permit endodontic access and vitality testing
7. easy to clean
8. easy to remove
9. allows for pulp testing and endodontic treatments
10. relatively inexpensive

11. provides patient comfort and esthetic appearance
12. easily accessible and easy to maintain oral hygiene.

6.1.2 Types of splints

Rigid splints: are used in cervical root fractures and alveolar bone fractures. Stainless steel wire >0.5 mm, direct composite resin or titanium ring splint (TTS), or direct composite resin reinforced with fiberglass ribbon can be used.

Flexible splints: allow for optimal pulp and periodontal ligament healing. Nylon, stainless steel wire <0.4 mm, nickel titanium wires up to 0.016 with composite resin, and glass ionomer cement splints are used.

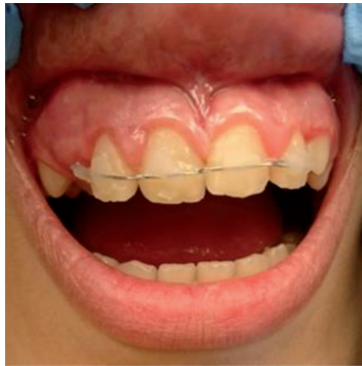

Figure 15.
Splint with ligature wire.

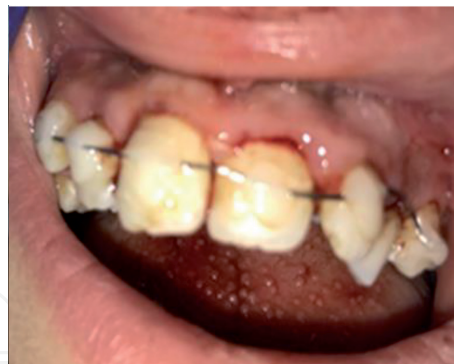

Figure 16.
Arch wire and composite splint.

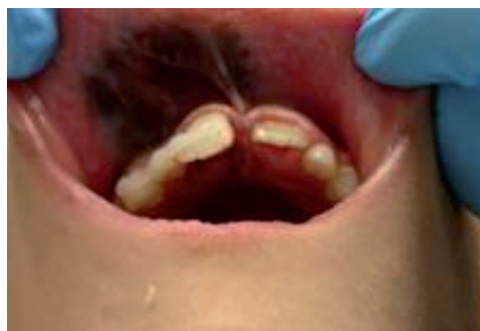

Figure 17.
Composite resin splint.

Compound splints: orthodontic bracket and wire are used as compound splint materials.

Instructions to patients having a splint placed include to:

1. taking a soft diet
2. avoid eating on teeth having splint
3. maintain a detailed oral hygiene
4. use chlorhexidine/antibiotics if prescribed
5. reach the dental office immediately if splint breaks/loosens.

Before beginning or continuing orthodontic treatment, traumatized teeth must be checked carefully.

It is recommended that even if there is a minor trauma to the teeth, one should wait for at least 3 months for orthodontic movement. Any kind of dental traumas to hard or soft dental tissues (e.g., minor concussions, subluxations, and extrusions) also requires a 3-month waiting period. For moderate to severe trauma/damage to the periodontium, at least 6 months of waiting period is recommended.

In root fracture cases, the tooth must not be moved for at least 1 year. If there is radiographic evidence of healing, those teeth may be moved successfully [15, 36–39].

7. Regenerative endodontic treatment of necrotic immature permanent teeth due to dental trauma

An immature permanent tooth is defined by the British Society of Pediatric Dentistry as a tooth that is not fully formed, particularly the root apex. A vital pulp is necessary for the development and maturation of the tooth root [40]. Completion of the root development of the teeth and closure of the root apex takes place 2–3 years after the eruption of the teeth. If pulp necrosis occurs for any reason (trauma, caries, etc.) before root development is complete, the root development undergoes a standstill, so the root remains without closure. In such cases, root canal treatment is both inevitable and difficult to do, because the root canal is very large, and the dentin walls are very thin and fragile [16, 40–43].

As a result of trauma, opening of the pulp tissue into the oral cavity may lead to infection by reaching the pulp tissue of oral microorganisms [44]. However, damage to the vascular nerve pack at the apex of the severely traumatized tooth causes necrosis of pulp tissue [41, 44].

The completion of the root formation of immature teeth that have necrotic pulp, or the induction of a calcified barrier formation at the root apices is defined as apexification [21].

There are various difficulties in the treatment of immature necrosed young permanent teeth:

- the difficulty of cleaning and shaping the canals
- difficulty of canal disinfection
- the risk of breakage of thin fragile dentin walls during mechanical obturation

- short crown/root ratio
- material carried out of the apex
- it is difficult or impossible to perform a possible retreatment in the future due to thin canal walls.

Until now, two apexification procedures for these teeth have been performed successfully. First of these procedures is conventional apexification inducing the formation of a barrier to apical calcification using calcium dihydroxide. Second is a one-step apexification method that provides production of an artificial apical barrier using mineral trioxide aggregate (MTA). In both the methods, constriction of apical foramen of an immature tooth has been shown [16, 38, 42, 43].

Traditional apexification treatment requires a large number of sessions, and problems with patient compliance may occur. Long-term use of calcium hydroxide may lead changing physical properties of dentin.

As a result of requirements of short-term completion of canal treatments, acceleration of healing and reduction of the sessions was sought response to one-step apexification with apex closing by using MTA that has been on the agenda [25].

Advantages of MTA apexification over calcium hydroxide apexification are more such as reliable barrier formation, reduction in treatment time, requirement of lesser visits, hence reducing the root fractures and preventing the changing of physical properties of dentin. In addition, since the MTA is not cytotoxic, its biological properties are advantageous and induce tissue repair.

Despite the popularity among clinicians, there are disadvantages of the apexification technique compared with MTA:

- the inability to control the applied condensation pressure and increased risk of fracture of thin dentin walls at large pressures
- it is difficult to remove after hardening, and surgical methods are needed for removing
- the high alkalinity of the material affects the stiffness of the root dentin over time
- high cost
- short shelf-life
- the challenges of clinical practice.

However, the risk of development of cervical root fractures remains high after apexification treatments [28].

The disadvantages of traditional apexification treatments have led the researchers to quest an alternative treatment approach that restores the function of the pulp dentin complex and persists its development. This quest led to arise of regeneration and regenerative endodontic treatment.

In biology dictionaries, regeneration is defined as the regrowth by an animal or plant of an organ, tissue, or part that has been lost or destroyed [21].

Regenerative endodontics is one of the most exciting new developments in endodontics. The current (2016) American Association of Endodontists' Glossary of Endodontic Terms defines regenerative endodontics as "biologically-based

procedures designed to physiologically replace damaged tooth structures, including dentin and root structures, as well as cells of the pulp-dentin complex” [21].

Regenerative endodontic procedures, a new approach to preventing tooth loss, aim to restore the damaged pulp and dentin structures, create a new pulp tissue in the canal, and provide root maturation [16, 28, 38, 43].

Seeking to find the ideal treatment method within the regenerative endodontics continues. The most studied methods in this area are: root canal revascularization, stem cell therapy, pulp implants, scaffold implants, injectable scaffold applications, three-dimensional cell software, and gene therapy. However, only the root canal revascularization could be used clinically in the treatment of traumatized necrotic young permanent teeth [28].

Revascularization term is used to indicate the restoration of blood flow to the necrotic pulp cavity. Despite the fact that pulpless teeth can sustain their presence in the mouth for a long time after successful endodontic treatment, the viability of the dental pulp offers many advantages, including the formation of reparative dentin, the completion of apical closure, and the development of dentin walls. Via the root canal revascularization, the pulp tissue is regenerated and the permanence of the tooth vitality is ensured [28, 38].

There are also negative aspects such as the fact that some dental pathologies, such as progressive decay, cannot be recognized by patients due to the loss of sensitivity to environmental changes by pulpless teeth.

In addition, the elimination of the negative consequences of traditional root canal treatment procedures is the reason why revascularization is preferred in the treatment of necrotic traumatized young permanent teeth.

At the basis of revascularization lies the rationale that “new cells can develop in the presence of sterile tissue matrix and pulp vitality can be restored,” because when dental canal infection is under control, it becomes a necrotic, avulse tooth condition with sterile pulp cavity. Regeneration in the apical tissues after the avulsion and replantation suggests regeneration may occur in the pulp tissue of a necrotic and infected tooth [16, 43, 45].

In the revascularization method, after the necrotic root canal is totally disinfected, it is aimed to provide a fibrin matrix with the blood clot formed by the bleeding from the tooth apex provided by the over instrumentation. Revascularization is observed through the new cell development via the differentiation of few stem cells preserved vital, in this provided sterile matrix [16, 43].

Hargreaves et al. recommended three major components of pulp regeneration called triad of regenerative endodontics:

- a. a dependable stem cell source that has capability of differentiating into odontoblasts
- b. a suitable scaffold to support cell growth and differentiation, and
- c. signaling molecules that have capability to stimulate cellular proliferation and direct cellular differentiation [28].

Stem cells are nondifferentiated cells that are capable of differentiating themselves into specialized cells, which can be transformed into many different cell types, when appropriate conditions are achieved within the body or in the laboratory. They are self-renewing and thus can generate any tissue for a lifetime unlike other progenitor cells [21].

Stem cell sources that play a role in the regeneration and root development of pulp tissue in the treatment of revascularization include dental pulp cells that

maintain the viability of the root canal, stem cells originating from the apical papilla, and periodontal ligament [16, 19].

Blood clot is a very rich source of growth factors and has an important role in the differentiation, maturation, and regeneration of fibroblast, odontoblast, and cementoblast [23].

7.1 The importance of root canal disinfection in revascularization treatments

Absence of bacteria in the root canal is critical for successful revascularization therapy, because the development of new tissue stops when it encounters bacteria in the canal cavity.

The most effective root canal disinfection method is provided by drugs applied to the root canal in addition to chemical irrigation.

However, a good preparation in open apex tooth and the use of cytotoxic antiseptics may remove pulp cells that are well fed and viable in the apical region. Removal of these tissues means removal of cells with the potential to convert to pulp and dentin [16, 41, 43, 46].

Sato et al., who applied the triple antibiotic paste in vitro for the first time, reported that triple antibiotic paste is effective in the treatment of dentin infected by *Escherichia coli* [46].

7.2 Patient selection criteria for revascularization treatment

The success of the treatment is based on the right case selection. No studies have been conducted on the success of revascularization therapy in individuals with genetic disease, severe medical disease, or poor immune system. Therefore, revascularization therapy procedures should be limited to systemically healthy people.

Revascularization therapy is not suitable for individuals allergic to triple antibiotics used in the canal.

It is not indicated in patients who cannot adapt or participate in the treatment process due to being a long-term and follow-up procedure, and in individuals who are fearful or uncooperative [42, 45, 47].

7.3 Tooth selection criteria for revascularization treatment

First of all, the tooth to be treated should be necrosis. Other regenerative therapies are considered such as pulp capping or partial pulpotomy with regenerative medicaments in teeth with vital pulp and partial pulpitis.

The presence of radiolucency in the periapical region as well as vitality tests has long been used as a determining factor. In both cases, vital pulp cells and apical papilla can still be present in the canal and apex.

Another criterion is the presence of infection. However, as a hypothesis, the presence of long-term infection adversely affects the survival of the pulp tissue and stem cell continuity, and makes it difficult to control the infection.

Since apex opening greater than 1 mm increases success, it should be preferred in immature young permanent teeth. Although a very few researchers recommend to expand the apex with a hand piece in the teeth with closed apex having less than 1 mm apex opening, but in the guidelines, the indication is limited to the open apex teeth.

Furthermore, the loss of coronal tissue in the teeth that will be treated with revascularization should not exceed the size for allowing it to be restored, and tissue damage should not be large, requiring to be made post/core [16, 41–43, 47].

8. Procedures in regenerative endodontics

An informed consent document must be taken before the treatment. This document should include the informations of complications such as tooth coloration or treatment failure, side effects such as pain or infection that may be able to emerge, two (or more) appointments will be needed, and what type of antibiotics will be used. Also, besides the nontreatment option, the patient must be informed about the tooth extraction (when deemed the tooth is nonsalvageable), and calcium hydroxide and MTA apexifications as the alternative treatments of revascularization. Following the consent document signing, treatment can be commenced [16, 18, 19, 25, 28, 38, 41–44, 46–49].

8.1 First appointment

Under local anesthesia and rubber dam isolation, an access cavity is prepared for the treatment. Each root canal opening is expanded to facilitate the placement of the medicament. The remaining root canal is not instrumented.

Copious, passive irrigation is made with 20 ml of 1.5% sodium hypochlorite (NaOCl), for 5 minutes to each canal, followed by a sterile saline solution or EDTA (20 ml for each canal, 5 minutes). It is important to maintain the vitality of stem cells in the apical tissues. Therefore, an irrigation system such as needle with closed end and side vents is used to minimize the odds of extrusion of irrigant agents into the periapical area. Also, the irrigation needle should be positioned approximately 1 mm from the root end to minimize cytotoxicity to stem cells in the apical tissues.

After sufficient irrigation, the canals are gently dried with sterile paper points.

Calcium hydroxide, or low concentration of triple antibiotic paste, can be used to fill the canals.

A triple antibiotic paste is an antibiotic mix made from tablets of ciprofloxacin, metronidazole, and minocycline in a ratio of 1:1:1. For preparation, after removal of the coatings on the tablets, the tablets are pulverized and mixed in a 1:1:1 ratio in a sterile saline to form a paste-like consistency.

Triple antibiotic paste has been associated with tooth discoloration; therefore, if it is used, to minimize risk of staining, pulp chamber is sealed with a dentin bonding agent and ensure that it should remain below cemento-enamel junction (CEJ).

For minimizing the coronal staining, modified triple antibiotic paste obtained by adding another antibiotic (e.g., clindamycin, amoxicillin, and cefaclor) instead of minocycline, or minocycline-free double antibiotic pat, may also be used.

After delivering the paste into the canals via syringe, a sterile cotton pellet is placed into the canal below the CEJ and the cavity is sealed with temporary filling so as not to allow microleakage.

8.2 Second appointment (1–4 weeks after first visit)

In the second appointment, 1–4 weeks after the first visit, the response of the initial treatment is evaluated. If the clinical signs/symptoms persisted, the first appointment treatment procedures are repeated with antimicrobials, or alternative antimicrobials.

If the tooth has become asymptomatic, the second session is started through the anesthesia with 3% mepivacaine free of vasoconstrictor.

After the tooth is isolated with rubber dam, the temporary filling and cotton pellet are removed.

Following the removing of the paste from the canals by irrigation with 20 ml of 17% EDTA, the canals are dried with sterile paper points.

Bleeding into canal system to the level of CEJ is created by 2 mm over-instrumenting through rotating a precurved K-file. The using of platelet-rich plasma (PRP), platelet-rich fibrin (PRF), or autologous fibrin matrix (AFM) has been considered as the alternatives to create a blood clot, especially when bleeding into the canal cannot be achieved.

Bleeding is stopped at a level allowing for 3–4 mm of restorative material. In order to ensure the formation of blood clot, place a sterile cotton pellet for 3–4 minutes upon the bleeding. If it is necessary, placing a resorbable matrix (e.g., CollaPlug™, Collacote™, and CollaTape™) over the blood clot is applicable.

For stabilizing the white MTA that is used as a capping material, 3–4 mm layer of light-curing glass ionomer is flowed gently over it. Because the MTA has been associated with discoloration, it should be placed just below the level of the CEJ, over the blood clot. If there is an esthetic concern, alternative materials of MTA like bioceramics or tricalcium silicate cements should be considered.

Finally, the access cavity is restored with a suitable restorative material [16, 18, 19, 25, 28, 38, 41–44, 46–49].

8.3 MTA as a coating material

MTA, with quite good physical properties in terms of covering and sealing, is one of the most ideal coating materials to be used for the hermeticity of coronary closure.

In addition, the application with glass ionomer resin increases its covering properties and durability.

To allow more root growth, the MTA should be 1–2 mm thick below the CEJ.

Placing the MTA on the formed clot is a technically difficult procedure. Care should be taken during condensation, because the material can be moved from the CEJ to the apical point [16, 43].

8.4 Follow-up, goals, and success in revascularization treatment

Appointments are given to the patient at intervals of 3–6 months, and root formation is monitored clinically and radiographically.

The success of pulp revascularization treatment depends on three elements: root canal disinfection, the presence of a scaffold (blood clot), and hermetic coronary filling [38, 45].

The degree of success of regenerative endodontic procedures is largely measured by the degree to which primary, secondary and tertiary goals are achieved.

Primary goal: elimination of symptoms and healing of bone tissue.

Secondary goal: the increase in the thickness and/or the length of the root walls (although it is a desirable condition).

Tertiary goal: positive response to vitality test (indicates the presence of a more organized vital pulp tissue).

Five different types of responses to revascularization treatments are available:

Type 1—thickening and root development of canal walls

Type 2—the root of the root end is blunt and closed and the root growth is stopped

Type 3—root development continues, but the apex remains open

Type 4—common calcification in canal cavity

Type 5—hard tissue barrier formation between root apex and coronal MTA.

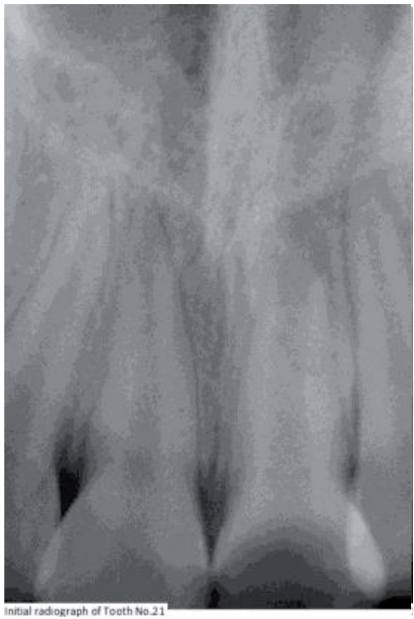


Figure 18.
A necrotic, immature, 21 numbered teeth, due to dental trauma from a year ago.

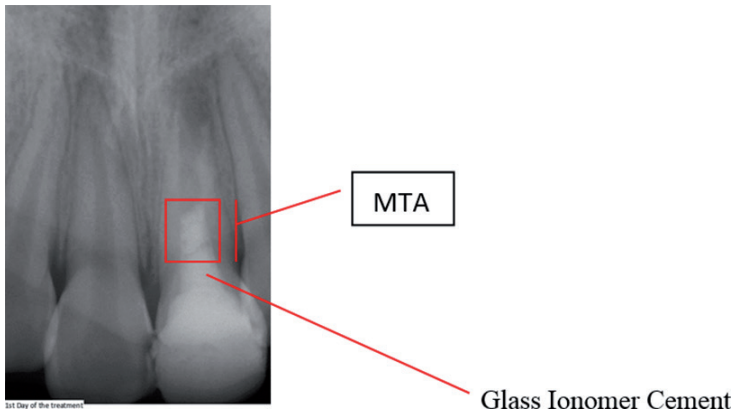


Figure 19.
First day of treatment: it is clearly seen that the root canal is very large, and the dentin walls are very thin.

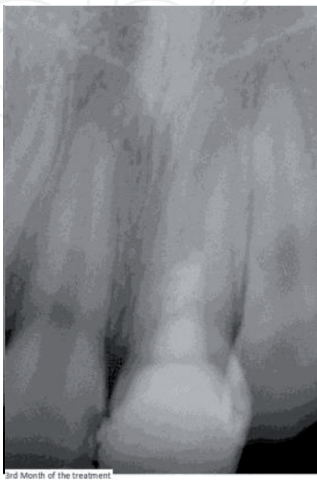


Figure 20.
Third month of the treatment: the lateral walls were thickened by the continued growth of dentin/hard tissue and the root length was increased.

If the treatment becomes success, in clinical and radiographical follow-ups, there should be no pain or swelling, apical radiolucency should be disappeared (usually observed 6–12 months after treatment), the root canal walls should be thickened (observed before the increase of the root length between 12 and 24 months), and the root length should be prolonged. Pulp should respond positively to vitality tests.

If there is no evidence of recovery, if the fistula does not disappear, and pain and swelling persist or no root growth is observed within 3 months, apexification with calcium hydroxide or MTA can be tried.

If pulp necrosis develops afterward, traditional endodontic treatment protocols should be performed [16, 18, 19, 25, 28, 38, 41–44, 46–49].

8.5 The advantages of revascularization treatment

Revascularization can be completed in a single session after the infection is controlled, and there is no need for repeated sessions as in the treatment of calcium hydroxide. This is very economical.

The greatest advantage is that it can regenerate the vitality of the tooth and maintain the root development.

The lateral walls are supported by the continuation of the dentin/hard tissue deposition, and the durability of the root is increased [16, 18, 19, 25, 28, 38, 41–44, 46–49] (**Figures 18–20**).

Author details

Asli Topaloglu Ak*, Didem Oner Ozdas, Sevgi Zorlu and Pinar Kiymet Karataban
Department of Pediatric Dentistry, Dentistry Faculty of Istanbul Aydin University,
Istanbul, Turkey

*Address all correspondence to: asliak@aydin.edu.tr

IntechOpen

© 2019 The Author(s). Licensee IntechOpen. This chapter is distributed under the terms of the Creative Commons Attribution License (<http://creativecommons.org/licenses/by/3.0>), which permits unrestricted use, distribution, and reproduction in any medium, provided the original work is properly cited. 

References

- [1] Marcenes W, Murray S. Social deprivation and traumatic dental injuries among 14-year-old schoolchildren in Newham, London. *Dental Traumatology*. 2001;**17**:17-21
- [2] Oldin A, Lundgren J, Nilsson M, Norén JG, Robertson A. Traumatic dental injuries among children aged 0-17 years in the BITA study—A longitudinal Swedish multicenter study. *Dental Traumatology*. 2015;**31**:9-17
- [3] Pattussi MP, Hardy R, Sheiham A. Neighbourhood social capital and dental injuries in Brazilian adolescents. *American Journal of Public Health*. 2006;**96**:1462-1468
- [4] Petti S, Tarsitani G. Traumatic injuries to anterior teeth in Italian schoolchildren: Prevalence and risk factors. *Endodontics & Dental Traumatology*. 1996;**12**:294-297
- [5] Rocha MJC, Cardoso M. Traumatized permanent teeth in Brazilian children assisted at the Federal University of Santa Catarina, Brazil. *Dental Traumatology*. 2001;**17**:245-249
- [6] Rodd HD, Chesham DJ. Sports-related oral injury and mouthguard use among Sheffield school children. *Community Dental Health*. 1997;**14**:25-30
- [7] Shulman JD, Peterson J. The association between incisor trauma and occlusal characteristics in individuals 8-50 years of age. *Dental Traumatology*. 2004;**20**:67-74
- [8] Traevert J, Peres MA, Blank V, Böoell RD, Pietruza JA. Prevalence of traumatic dental injury and associated factors among 12-year-old school children in Florianópolis, Brazil. *Dental Traumatology*. 2003;**19**:15-18
- [9] Andersson L, Andreasen JO. Important considerations for designing and reporting epidemiologic and clinical studies in dental traumatology. *Dental Traumatology*. 2011;**27**:269-274
- [10] Andersson L, Kahnberg K-E, Oral PMA. *Maxillofacial Surgery*. Oxford: Wiley-Blackwell; 2010
- [11] Andersson L. Epidemiology of traumatic dental injuries. *Pediatric Dentistry*. 2013;**35**(2):102-105
- [12] Andreasen JO, Andreasen FM, Andersson L. *Textbook and Color Atlas of Traumatic Injuries to the Teeth*. 4th ed. Oxford: Blackwell Munksgaard; 2007
- [13] Andreasen JO, Ravn JJ. Epidemiology of traumatic dental injuries to primary and permanent teeth in a Danish population sample. *International Journal of Oral Surgery*. 1972;**1**:235-239
- [14] Chen YL, Tsai TP, See LC. Survey of incisor trauma in second grade students of Central Taiwan. *Chang Gung Medical Journal*. 1999;**22**:212-219
- [15] July 2018. Available from: www.iadt-dentaltrauma.org (Accessed 20 July 2018)
- [16] Banchs F, Trope M. Revascularization of immature permanent teeth with apical periodontitis: New treatment protocol? *Journal of Endodontia*. 2004;**30**(4):196-200
- [17] Borsse'n E, Holm AK. Traumatic dental injuries in a cohort of 16-year-olds in northern Sweden. *Endodontics & Dental Traumatology*. 1997;**13**:276-280
- [18] Chisini LA, Grazioli G, Francia A, San Martin AS, Demarco FF, Conde MCM. Revascularization versus apical barrier technique with mineral trioxide

aggregate plug: A systematic review. *Giornale Italiano di Endodonzia*. 2018;**32**(1):9-16

[19] Cotti E, Mereu M, Lusso D. Regenerative treatment of an immature, traumatized tooth with apical periodontitis: Report of a case. *Journal of Endodontia*. 2008;**34**:611-616

[20] Glendor U. Epidemiology of traumatic dental injuries: A 12 year review of the literature. *Dental Traumatology*. 2008;**24**:603-611

[21] American Association of Endodontists. Glossary of Endodontic Terms, 9th Edn: Chicago. <http://www.nxtbook.com/nxtbooks/aae/endodonticglossary2016/index.php> (Accessed 15 August 2018)

[22] Granville-Garcia AF, de Almeida Vieira IT, da Silva Siqueira MJP, et al. Traumatic dental injuries and associated factors among Brazilian preschool children aged 1-5 years. *Acta Odontológica Latinoamericana*. 2010;**23**:47-52

[23] Gronthos S, Brahim J, Li W, Fisher LW, Cherman N, Boyde A, et al. Stem cell properties of human dental pulp stem cells. *Journal of Dental Research*. 2002;**81**:531-535

[24] Eilert-Petersson E, Andersson L, Sørensen S. Traumatic oral vs. non-oral injuries. An epidemiological study during one year in a Swedish county. *Swedish Dental Journal*. 1997;**21**:55-68

[25] Giuliani V, Baccetti T, Pace R, Pagavino G. The use of MTA in teeth with necrotic pulps and open apices. *Dental Traumatology*. 2002;**18**:217-221

[26] Glendor U, Andersson L, Andreasen JO. Economic aspects of traumatic dental injuries. In: Andreasen JO, Andreasen FM, Andersson L, editors. *Textbook and Color Atlas of Traumatic Injuries to the Teeth*. 4th ed. © 1981,

1994 by Munksgaard, Copenhagen, Denmark © 2007 Blackwell Munksgaard A Blackwell Publishing Company

[27] Hamilton FA, Hill FJ, Holloway PJ. An investigation of dentoalveolar trauma and its treatment in an adolescent population. Part 1: The prevalence and incidence of injuries and the extent and adequacy of treatment received. *British Dental Journal*. 1997;**8**:182

[28] Hargreaves KM, Geisler T, Henry M, Wang Y. Regeneration potential of the young permanent tooth: What does the future hold? *Pediatric Dentistry*. 2008;**30**(3):253-260

[29] Hedegård B, Stålhane I. A study of traumatized permanent teeth in children aged 7-15 years. Part I. *Swedish Dental Journal*. 1973;**66**:431-450

[30] Holland TJ, O'Mullane DM, Whelton HP. Accidental damage to incisors amongst Irish adults. *Endodontics & Dental Traumatology*. 1994;**10**:191-194

[31] Dean JA. McDonald and Avery's Dentistry for the Child and Adolescent-E-Book. 10th ed. St. Louis, Missouri: Elsevier Health Sciences; 2015

[32] Kaste LM, Gift HC, Bhat M, Swango PA. Prevalence of incisor trauma in persons 6 to 50 years of age: United States, 1988-1991. *Journal of Dental Research*. 1996;**75**:696-705

[33] Marcenes W, Murray S. Changes in prevalence and treatment need for traumatic dental injuries among 14-year-old children in Newham, London: A deprived area. *Community Dental Health*. 2002;**19**:104-108

[34] Levin L, Friedlander LD, Geiger SB. Dental and oral trauma and mouthguard use during sports activities in Israel. *Dental Traumatology*. 2003;**19**:237-242

- [35] Malikaew P, Watt RG, Sheiham A. Prevalence and factors associated with traumatic dental injuries (TDI) to anterior teeth of 11-13 year old Thai children. *Community Dental Health*. 2006;**23**:222-227
- [36] Traumatic Dental Injuries AAE (Patient Education Brochure)
- [37] July 2018. Available from: http://www.aapd.org/media/policies_guidelines/g_trauma.pdf (Accessed 20 July 2018)
- [38] Namour M, Theys S. Pulp revascularization of immature permanent teeth: A review of the literature and a proposal of a new clinical protocol. *The Scientific World Journal*. 2014;**2014**:737503. DOI: 10.1155/2014/737503
- [39] Tsukiboshi M. Treatment Planning for Traumatized Teeth. 2nd ed. Chicago: Quintessence Publ. Comp. Inc; 2012
- [40] Koch G, Poulsen S, Espelid I, Haubek D. Pediatric Dentistry: A Clinical Approach. 3rd ed. Copenhagen, Denmark: John Wiley & Sons; 2017
- [41] Vinchurkar S, Patil V. Outcomes of regenerative endodontic procedure In immature permanent teeth with necrotic pulps using different antimicrobial agents and/or Intracanal medicaments using different protocols: A systematic review. *International Journal Of Scientific Research*. 2018;**7**(3):37-43
- [42] Garcia-Godoy F, Murray PE. Recommendations for using regenerative endodontic procedures in permanent immature traumatized teeth. *Dental Traumatology*. 2012;**28**(1):33-41
- [43] Trope M. Regenerative potential of dental pulp. *Pediatric Dentistry*. 2008;**30**(3):206-210
- [44] Theilade E. The microbiology of the necrotic pulp. In: Bergenholtz G, Horsted-Bindslev P, Reit C, editors. *Textbook of Endodontology*. 4th ed. Oxford: Blackwell, Munksgaard; 2007
- [45] Reynolds K, Johnson JD, Cohenca N. Pulp revascularization of necrotic bilateral bicuspid using a modified novel technique to eliminate potential coronal discoloration: A case report. *International Endodontic Journal*. 2009;**42**(1):84-92
- [46] Sato T, Ando-Kurihara N, Kota K, Iwaku M, Hoshino E. Sterilization of infected root-canal dentine by topical application of a mixture of ciprofloxacin, metronidazole and minocycline in situ. *International Endodontic Journal*. 1996;**29**:118-124
- [47] American Association of Endodontists. AAE Clinical Considerations for a Regenerative Procedure [Internet]. Chicago: American Association of Endodontists; 2018. Available from: https://f3f142zs0k2w1kg84k5p9i1o-wpengine.netdna-ssl.com/specialty/wp-content/uploads/sites/2/2018/06/ConsiderationsForRegEndo_AsOfApril2018.pdf [Accessed: Jan 4, 2018]
- [48] Regenerative Endodontics. Endodontics: Colleagues for Excellence. Chicago: American Association of Endodontists; 2013
- [49] Yamauchi N, Yamauchi S, Nagaoka H, Dugan D, Zhong S, Lee SM, et al. Tissue engineering strategies for immature teeth with apical periodontitis. *Journal of Endodontia*. 2011;**37**:390-397