

# We are IntechOpen, the world's leading publisher of Open Access books Built by scientists, for scientists

6,900

Open access books available

186,000

International authors and editors

200M

Downloads

Our authors are among the

154

Countries delivered to

TOP 1%

most cited scientists

12.2%

Contributors from top 500 universities



WEB OF SCIENCE™

Selection of our books indexed in the Book Citation Index  
in Web of Science™ Core Collection (BKCI)

Interested in publishing with us?  
Contact [book.department@intechopen.com](mailto:book.department@intechopen.com)

Numbers displayed above are based on latest data collected.  
For more information visit [www.intechopen.com](http://www.intechopen.com)



# Breast Reconstruction with TRAM Flap

*Ercan Karacaoglu*

## Abstract

Traditional breast conservative therapy (BCT) is lumpectomy, sentinel lymph node biopsy and possible axillary dissection, and radiation therapy. BCT is, as known and considered all over the world, is oncologically equivalent to mastectomy with regard to overall long-term survival rates. BCT is the recommended treatment of choice for women with early stages breast cancer. The main philosophy of BCT is optimizing cosmetic goals and minimizing the psychological morbidity of a mastectomy while ensuring low rates of local recurrence. Achieving an oncologically safe resection is maintained by tumor margin clearance. Ensuring an oncologic clearance with increasing tumor size requires extensive breast parenchyma resection. And this results in large volume resection and this requires volume replacement techniques. Depending on the amount of breast volume resected, an autologous tissue transfer may be required to achieve requirement of breast restoration. Latissimus dorsi flap and TRAM flap are two autologous tissues mostly used to fulfill this restoration. This chapter focuses on the TRAM flap, one of the most commonly used autologous tissue in volume replacement reconstruction of the mastectomy defect.

**Keywords:** TRAM, flap, breast, reconstruction, pediculated, skin sparing, mastectomy, autologous, repair

## 1. Introduction

Breast reconstruction with transverse rectus abdominis myocutaneous (TRAM) flap has its own unique features and requirements. Not all cases require TRAM flap, and TRAM flap is not the best option for every case. That can be analyzed by comparing available treatment options of breast cancer (or breast deformities) and reconstruction.

Traditional breast conservative therapy (BCT) is lumpectomy, sentinel lymph node biopsy, possible axillary dissection, and radiation therapy. BCT, as known and considered all over the world, is oncologically equivalent to mastectomy with regard to overall long-term survival rates. BCT is the recommended treatment of choice for women with early stages of breast cancer [1, 2]. The main philosophy of BCT is optimizing cosmetic goals and minimizing the psychological morbidity of a mastectomy while ensuring low rates of local recurrence.

Achieving an oncologically safe resection is maintained by tumor margin clearance [2]. Ensuring an oncologic clearance with increasing tumor size requires extensive breast parenchyma resection. And this results in large volume resection, and this requires volume replacement techniques. Depending on the amount of

breast volume resected, an autologous tissue transfer may be required to achieve requirement of breast restoration. Latissimus dorsi flap and TRAM flap are two autologous tissues mostly used to fulfill this restoration. Perforator flaps are also available within the last two decades, and some centers and surgeons began to use them as the procedure of choice. This chapter focuses on the TRAM flap, one of the most commonly used autologous tissue in volume replacement reconstruction of the mastectomy defect.

The results of breast reconstruction have improved dramatically over the past 30 years. The main reason for this improvement is the experience that has grown from various techniques of flap surgery. Breast reconstruction entered the modern era with the introduction of the TRAM flap in 1982 by Hartrampf et al. [3]. This ingenious procedure reliably transfers autogenous tissue from the lower abdomen for breast reconstruction. This surgery has also the added benefit of abdominal rejuvenation.

## 2. Pertinent anatomy

The adult female breast lies with its footprint extending from the second to sixth ribs. The medial border is at the edge of the sternum, and the lateral border is at the anterior axillary line. The female breast has a circular shape except the upper outer quadrant, where the axillary tail of Spence extends to the armpit. The breast is a modified cutaneous gland. The mature breast demonstrates both a superficial and a deep fascia support system. From an embryological standpoint, the breast bud develops within the Scarpa's fascia. This fascia splits to form anterior and posterior lamella. Anterior lamella serves as a dissection plane for surgeons when performing a mastectomy, while the posterior lamella separates the breasts from the underlying pectoralis major muscle. Breast duct network often extends more widely than this footprint. In about 15% of cases, breast tissue extends below the costal margin. It is critical when performing breast reconstruction that the inframammary fold (IMF) is maintained or at least identified and reconstructed if surgical removal of additional breast tissue below this fold is required [4–6]. The breast lobule is the basic unit of the breast. Each breast consists of roughly 20 lobules. The breast has its breast duct network starting from acini or alveoli, excretory duct, and lactiferous duct. A total of 15–20 lactiferous ducts drain the entire breast and dilate into the milk sinus beneath the areola. The stroma within the breast consists of connective tissue, nerves, blood vessels, and lymphatic channels.

*Arterial supply:* The blood supply of the breast is diffuse and comes from a variety of potential sources including internal mammary artery, lateral thoracic artery, branches from thoracoacromial artery, and intercostal arteries. *The internal mammary artery system* has both deep and superficial blood supplies and provides more than half of total breast blood flow by anterior and posterior perforating branches. *The lateral thoracic vessels* have both dermal and dermoglandular pedicles with adequate both arterial input and venous drainage [5]. *Minor sources of arterial supply* to the breast are posterior intercostal arteries (third, fourth, and fifth) and branches from the axillary artery, the thoracic artery, the subscapular artery, and the pectoralis branches of the thoracoacromial artery.

*Venous drainage:* The venous drainage of the breast is superficial and deep. The superficial system has transverse and longitudinal veins. The deep system empties into internal mammary vein, axillary vein, and perforating branches of posterior intercostal veins [5].

Arterial inflow is strong enough to support blood supply, but venous return is also a key in designing and avoiding congestion and increasing the security of the

perfusion of both breast parenchyma and skin envelopes. This is one of the key issues for the viable results in breast oncologic surgery and in breast reconstruction.

*Lymphatic drainage:* The lymphatic drainage of the breast is also diffuse and variable. Traditionally recognized lymphatic basins include the axillary nodes as well as nodes along the internal mammary vessels.

*Innervation:* The innervation of the breast is also diffuse and variable. Multiple nerve branches from the lateral and anterior cutaneous branches of the second through the sixth intercostal nerves as well as the supraclavicular nerves enter and branch within the breast. The lateral branches are more significant than the smaller anterior branches.

## 2.1 Basic anatomy for tram flap

*Rectus abdominis muscle:* The rectus abdominis muscles are pairs of long, straight muscles that flex the spine and tighten the intra-abdominal wall. This muscle has its origin from the symphysis pubis and the pubic crest and inserts on the linea alba and the fifth, sixth, and seventh costal cartilages. Each muscle has two to five tendinous inscriptions. The most caudal inscription is at the level of umbilicus. These tendinous inscriptions are not adherent to the posterior sheath but to overlying anterior rectus sheath. Rectus sheath is thick and encloses the rectus abdominis muscle except for the posterior part below the arcuate line. The arcuate line is mostly located halfway between the umbilicus and symphysis pubis. The arcuate line is the transition point where the internal oblique aponeurosis stops to split and the aponeurosis of all three muscles pass ventral to the rectus abdominis muscle. Below the arcuate line, there is only the transversalis fascia where this is the region of weakness and it is the place potential herniation after flap dissection. The linea alba is the decussation of the fused aponeurosis in the midline. The linea alba is wider close to the xiphoid process and narrows to a fine a line below the umbilicus. The lateral border of the rectus muscle with its sheath is referred to as the linea semilunaris.

*Blood supply:* The blood supply to the rectus muscle and TRAM flap comes from the deep superior epigastric artery (DSEA), which arises from the internal thoracic (mammary) artery, and the deep inferior epigastric artery (DIEA), a branch of the external iliac artery. Both the deep superior and inferior epigastric arteries communicate within the rectus abdominis muscle and the overlying muscular and cutaneous tissue of the anterior abdominal wall. The DSEA and DIEA systems connect above the umbilicus through a system of small-caliber vessels that Taylor and Palmer refer to as “choke” vessels [7]. The DIEA originates approximately 1 cm above the inguinal ligament and then pierces the transversalis fascia and enters the rectus sheath just below the arcuate line. The DIEA then ascends obliquely and medially between the rectus abdominis muscle and the posterior wall of the rectus sheath. The DIEA divides into two or three large branches below the level of the umbilicus. It shows certain type of arborization, extensive studies reported by Moon and Taylor. Based on their outcomes, there are three types of anastomosis between DIEA and DSEA. Most patients have two networks (57%), while there are three networks in 14% of the people and only one major anastomosis in 29% of the people [8].

*Perforators* are key for the vascular supply of TRAM flap. These vessels are terminal branches of the DIEA and deep inferior epigastric veins. Perforators extend from the vertical epigastric system and pass through the anterior rectus sheath, supplying the skin and subcutaneous tissue. Taylor and Palmer studies demonstrated a rich connection between the DIEA system and the abdominal wall skin. The majority of perforators are between the umbilicus and the arcuate line, but the highest concentration of perforators is in the periumbilical area. Usually there are two parallel rows of perforators, a medial one and a lateral one. Incorporation of the

periumbilical perforators permits the harvesting of a skin flap with virtually any orientation from the midline [9, 10].

TRAM flap can be planned either unipedicled or bipedicled. The decision about pedicle depends on the requirement of the tissue pad to be transferred. If a surgeon needs almost up to 60% of the lower abdominal tissue, then unipedicle might be the right choice. If the requirement is more than that, then it would be better to go with bipedicled flap.

### 3. TRAM flap

Breast reconstruction with TRAM flap can be accomplished with a variety of lower abdomen flap and techniques such as pedicled TRAM flap (uni- or bipedicled), free TRAM flap, or DIEP flap. The scope of this chapter is pedicled TRAM flap.

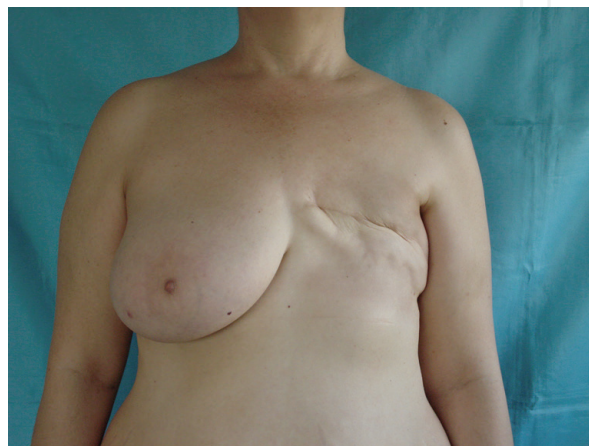*Patient selection:* The very first part of this procedure should be patient selection. The candidate should be evaluated as to the status of her disease and overall health. She should be emotionally stable. She should have a good motivation. All details regarding surgery, hospitalization, and recuperation need to be discussed in detail.

**Who are candidates for TRAM flap breast reconstruction?** In general speaking, mastectomy defect needs to be evaluated before planning (**Figure 1**). The best candidates are as follows:

1. Patients with large and ptotic breasts where the contralateral breast needs to be altered for symmetry purpose.
2. Patients with big mastectomy defect and/or poor skin quality due to excessive dissection, skin slough, radiation effect, etc.

The best candidates for TRAM flap harvesting are the patients with well-padded lower abdominal soft tissue and loose upper abdominal soft tissue. Patient with excessive abdominal fat might not be a good candidate [11].

**Who are not candidates for TRAM flap breast reconstruction?** The scar on the abdomen is also a key to analyze patient eligibility for TRAM flap. A subcostal or transverse incision that divides the rectus abdominis muscle and its superior epigastric blood supply might be a contraindication for the use of a pedicled TRAM flap. Lower abdominal incision such as Pfannenstiel incision is not a contraindication for a TRAM flap, and contrary to fact, such an incision might play a “delay phenomena” effect. Patients ideally should be nonsmoker, or if they are smoker,



**Figure 1.**

*Typical mastectomy defect and best candidates for breast reconstruction with TRAM flap are as seen in the picture.*

they need to stop smoking almost 1–2 months before surgery. If the patient is on chemotherapy, it would be better to wait at least 6 months more after the last cure of chemotherapy. If there is a history of radiation therapy, it would be better to postpone surgery for another 6 months to year after the last cure of radiation therapy. The last condition can be totally excluded based on the recipient area requirement such as radiation-induced soft tissue defect in the mastectomy area or other soft tissue defects due to the mastectomy.

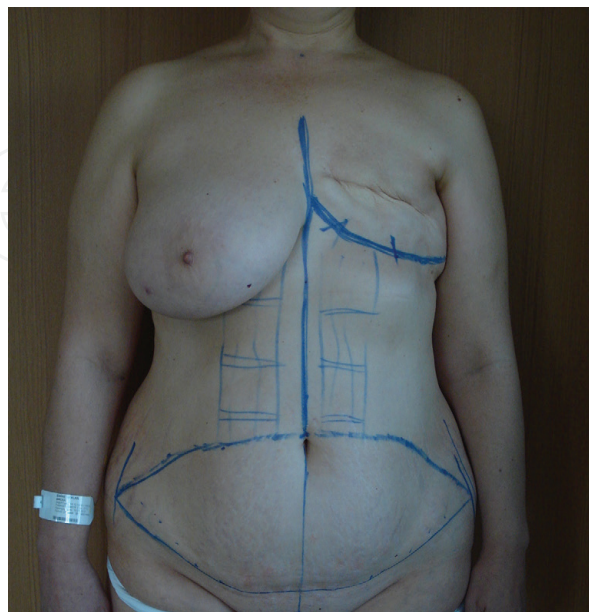
### 3.1 Preoperative marking and patient positioning

All markings are made with the patient in an upright standing position.

*Recipient area:* The inframammary, parasternal, anterior axillary line of the contralateral breast is marked. The template of these lines is reflected to the recipient side on a mirror image. The footprint of the recipient side is also copied from the contralateral breast. The marking are also made for the future inframammary fold and the tunnel that the flap would pass through (**Figure 2**).

*Donor area:* The TRAM flap is marked as a horizontal ellipse on the lower abdomen. Perforators around the umbilicus and below it are marked with the aid of a handheld Doppler US. The whole ellipse is tried to fit with these perforators as much as possible. The inferior incision is placed in the low bikini area. The best inferior incision location would be suprapubic crease, but this might not be possible in each case. The excursion of the lower bikini area should be tested by pinching. The superior incision line is marked 1 cm above or below the umbilicus. A superior incision that is above the umbilicus is preferable as this has a higher chance to include as much periumbilical perforators as possible. But the ease of donor area closure is the key factor to place the superior incision line (**Figure 2**).

A TRAM flap is divided into four zones based on the reliability of perfusion. There are four zones for a unipedicled TRAM flap scenario. Zone 1 refers to the skin overlying each lateral rectus abdominis muscle. Zone 2 refers to the skin overlying contralateral rectus abdominis muscle. The skin territory on each side of the



**Figure 2.**

*Marking for the TRAM flap. All markings are made with the patient in an upright standing position. Recipient area: the inframammary, parasternal, anterior axillary line of the contralateral breast is marked. The template of these lines is reflected to the recipient side on a mirror image. Footprint of the recipient side is also copied from the contralateral breast. The marking are also made for the future inframammary crease and the tunnel that the flap would pass through.*

abdomen lateral to the linea semilunaris is referred to as zone 3, and the skin lateral to the opposite linea semilunaris is zone 4. The perfusion of zones 4 and 3 is less than zones 1 and 2 where zone 4 is the most tenuous.

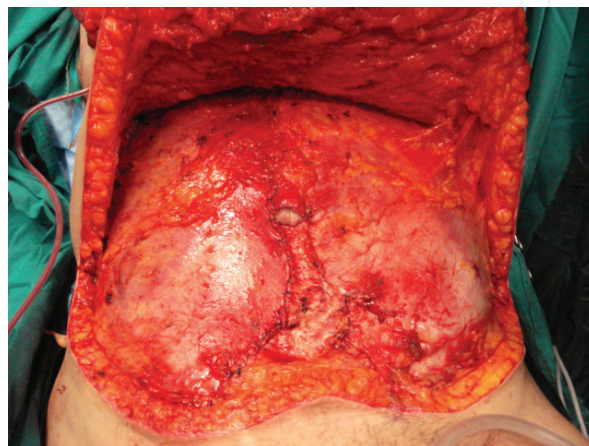
*Surgical technique:* The mastectomy skin flap is elevated off the pectoralis major muscle inferiorly and superiorly based on the preoperative marking. Previous mastectomy scar is excised and sent for pathologic evaluation.

The superior TRAM flap incision is placed till anterior rectus fascia. The upper abdominal skin flap is elevated close to both inframammary folds (IMF). A tunnel is made to the mastectomy area.

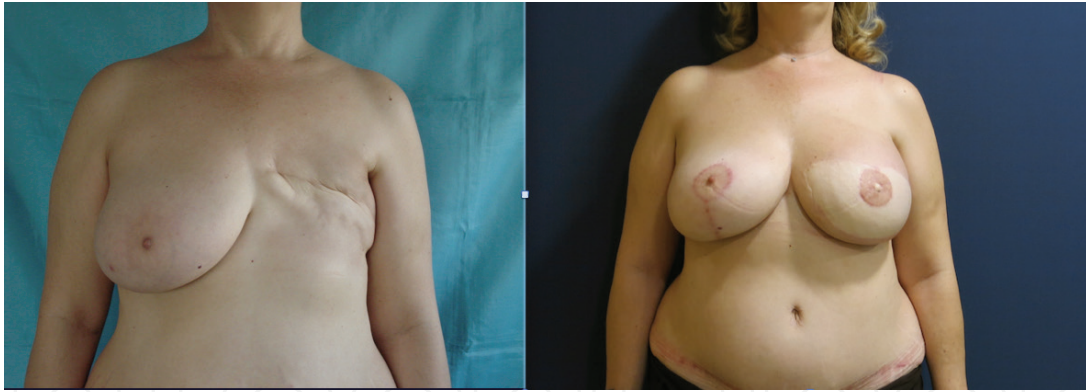
The inferior incision is placed deep to the rectus muscle, and both superficial epigastric vessels are identified and preserved. Zones 3 and 4 are dissected off the external oblique fascia, and dissection continues medially with precaution while approaching the lateral border of the rectus abdominis fascia. At this point, preoperative markings for perforators are followed, and this dissection continues medially, stopping approximately 4–5 mm lateral to these perforators. The largest perforator is mostly found just lateral and inferior to the umbilicus. An incision is made on the rectus fascia just 1 cm lateral to the perforators. The inferior epigastrics are identified easily along the lateral edge of the rectus muscle. The vessels are identified close to the external iliac artery, and the DIEA is ligated. The rectus fascia is divided vertically, and the rectus muscle with TRAM flap attached elevated off the posterior rectus fascia. The umbilicus is circumferentially incised and isolated on its stalk medially. The eight intercostal nerves are identified and transected to help for the atrophy of the muscle pedicle while approaching close to the arcus costarum. TRAM flap is delivered through the tunnel to the mastectomy site.

Anterior rectus fascia is closed with 0 or 1/0 Prolene (or nylon suture). Inferior cuff of rectus muscle is integrated to the weak area below arcuate line (**Figure 3**). Closure is reinforced with an overlay Prolene mesh that lies from epigastric area to symphysis pubis. Care must be taken not to constrict the pedicle. Abdominal skin flap is closed in layers, and the umbilicus is delivered to its new location in the midline.

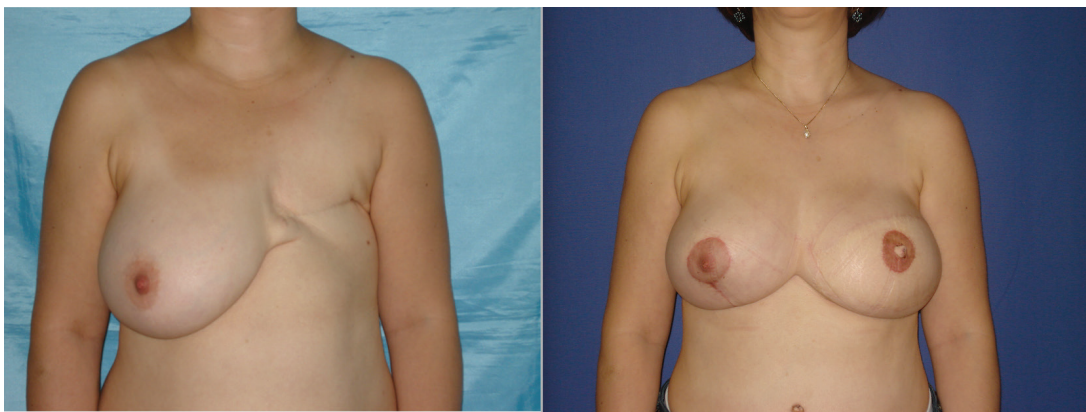
The TRAM flap is provisionally placed into the mastectomy defect, and the mastectomy flap is draped over the TRAM flap. The patient is placed in a sitting position, and the TRAM flap is shaped into a breast mound. Care should be taken to shift breast mound superior and medial area to ensure adequate cleavage volume. Surely, volume distribution is important for each quadrant of breast mound (**Figures 4 and 5**).



**Figure 3.**  
*Anterior rectus fascia is closed after the TRAM flap is transferred to the mastectomy site.*



**Figure 4.**  
*Pre- and postoperative view of a mastectomy patient that is reconstructed with bipedicle TRAM flap. The patient is 56 years old. Follow-up picture was taken 6 month after nipple and areola complex reconstruction.*



**Figure 5.**  
*Pre- and postoperative view of a mastectomy patient that is reconstructed with bipedicle TRAM flap. The patient is 48 years old.*

**Postoperative care:** Wound care is essential, and routine wound care is needed. The flap is kept warm, and a fenestrated dressing might be a better option to observe flap perfusion. A support bra is used to maintain the position of the flap. The patient is placed in a flexed position by keeping head elevated 30° and legs elevated 20°. An abdominal girdle needs to be on at all time for 2 months. Patients are mostly hospitalized for 3 days. Patients are advised for resting for 15 days to a month after surgery.

### 3.2 Complications

**Fat necrosis:** Fat necrosis can be seen, and the reason is inadequate perfusion or limited perfusion to a certain part of the flap. Planning and surgical technique needs to be verified before and during surgery to minimize the possibility of inadequate perfusion. Planning and technique should be optimal perforator areas with limited perfusion, or question might be discarded during surgery. Zone 4 is always an area of question and must be discarded before transposing the flap.

**Partial flap loss:** Partial flap loss is also can be seen due to inadequate perfusion. Likewise, areas with question need to be discarded; planning and technique should be optimal to include as much perforators as possible.

**Abdominal hernia:** Hernia or bulging can be seen as one of the major complication. Fascial closure needs to be dome tension-free, and mesh needs to be used if indicated. Patients should be placed in abdominal girdle and told to avoid strenuous exercise till the sixth month after surgery [12]. The incidence of abdominal bulges

was reported 3.8%, while hernia was reported 2.6% [13]. It is also reported that abdominal strength, as measured by the ability to do sit-ups, is influenced significantly by TRAM flap.

Revisional surgeries for TRAM flap: All complications need to be revised as needed. Partial flap loss should be addressed within the first 2 weeks after surgery. Meticulous wound care is essential meanwhile.

Breast reconstruction with TRAM flap is a two-stage procedure. The goal of the first step is to reconstruct the breast mound as close as to the contralateral breast mound. The goal of the second stage is to get symmetry as much as possible and reconstruction of nipple areola complex (NAC). Surgical intervention might be needed for the contralateral breast (i.e., lifting and reduction) during the second stage. The following procedures might be done during the second stage: removal of fat necrosis, breast mound revision, IMF revision, medial cleavage revision (with flap transposition or fat grafting), donor site liposuction for feathering touch, and NAC reconstruction.

NAC reconstruction: NAC reconstruction can be done with various techniques. Some of the mostly used techniques are CV flap, skate flap, star flap, etc. Areola mostly reconstructed with pigmented full-thickness grafting from inguinal area or tattooing.

## **Author details**

Ercan Karacaoglu

Department of Plastic Surgery, School of Medicine, Bahcesehir University, Istanbul, Turkey

\*Address all correspondence to: [drercanka@yahoo.com](mailto:drercanka@yahoo.com)

## **IntechOpen**

© 2019 The Author(s). Licensee IntechOpen. This chapter is distributed under the terms of the Creative Commons Attribution License (<http://creativecommons.org/licenses/by/3.0>), which permits unrestricted use, distribution, and reproduction in any medium, provided the original work is properly cited. 

## References

- [1] Veronesi U, Salvadori B, Luini A. Breast conserving is a safe method in patients with small cancer of the breast. Long-term results of three randomized trials on 1,973 patients. *European Journal of Cancer*. 1995;**31A**(10): 1574-1579. PMID: 7488404
- [2] Fisher B, Anderson S, Redmond CK, et al. Reanalysis and results after 12 years of follow up in a randomized clinical trial comparing total mastectomy with lumpectomy with or without irradiation in the treatment of breast cancer. *The New England Journal of Medicine*. 1995;**333**:1456-1461. PMID: 7477145
- [3] Hartrampf CR, Scheflan M, Black PW. Breast reconstruction with a transverse abdominal Island flap. *Plastic and Reconstructive Surgery*. 1982;**69**:216-224
- [4] Evans GRD, Hall-Findlay E. History and anatomy. In: Evans GRD, Hall-Findlay E, editors. *Aesthetic and Reconstructive Surgery of the Breast*. China: Elsevier Saunders; 2010. pp. 1-3
- [5] Hamdi M, Wuringer E, Schlenz I, Kuzbari R. Anatomy of the breast: A clinical application. In: Hamdi M, Hammond DC, Nahai F, editors. *Vertical Scar Mammoplasty*. Springer-Berlin Heidelberg; 2005. pp. 2-6
- [6] Hammond DC, editor. Applied anatomy. In: *Atlas of Aesthetic Breast Surgery*. China: Elsevier Saunders; 2009. pp. 1-9
- [7] Taylor G, Palmer J. The vascular territories (angiosomes) of the body: Experimental and clinical applications. *British Journal of Plastic Surgery*. 1987;**40**:113
- [8] Bohmet H, Gabka CJ, editors. Anatomy of the transverse rectus abdominis musculocutaneous flap—The TRAM flap. In: *Plastic and Reconstructive Surgery of the Breast. A Surgical Atlas*. New York: George Thieme; 1997. pp. 251-258
- [9] Duchateau J, Declety A, Lejour M. Innervation of the rectus abdominus muscle: Implications for rectus flaps. *Plastic and Reconstructive Surgery*. 1984;**82**:223
- [10] Boyd JB, Taylor GI, Corlett R. The vascular territories of the superior and deep inferior epigastric systems. *Plastic and Reconstructive Surgery*. 1984;**73**:1
- [11] Kroll SS. Why autologous tissue? *Clinics in Plastic Surgery*. 1998;**25**:135-143
- [12] Padubidri AN, Tetman R, Browne E, Lucas A, Papay F, Larive B, et al. Complications of postmastectomy breast reconstruction in smokers, ex smokers, and nonsmokers. *Plastic and Reconstructive Surgery*. 2001;**107**:350-351
- [13] Kroll SS, Schusterman MA, Reece GP, Miller MJ, Robb G, Evans G. Abdominal wall strength, bulging, and hernia after TRAM flap breast reconstruction. *Plastic and Reconstructive Surgery*. 1995;**96**(3):616-619