

# We are IntechOpen, the world's leading publisher of Open Access books Built by scientists, for scientists

6,900

Open access books available

185,000

International authors and editors

200M

Downloads

Our authors are among the

154

Countries delivered to

TOP 1%

most cited scientists

12.2%

Contributors from top 500 universities



WEB OF SCIENCE™

Selection of our books indexed in the Book Citation Index  
in Web of Science™ Core Collection (BKCI)

Interested in publishing with us?  
Contact [book.department@intechopen.com](mailto:book.department@intechopen.com)

Numbers displayed above are based on latest data collected.  
For more information visit [www.intechopen.com](http://www.intechopen.com)



# Single-Incision Pediatric Endosurgery (SIPES)

*Enaam Raboei, Ameen Alsaggaf, Yazeed Owiwi,  
Syed Salahuddin, Alaa Ghallab and Mazen Zidan*

## Abstract

Most centers advocate laparoscopy in order to minimize the size and the number of skin incisions. Many comparative studies, systematic review, and pooled analysis demonstrate that single-incision laparoscopic surgery (SILS) is comparable to conventional laparoscopic surgery (CLS). However, this review identifies the need for randomized controlled trials to clarify the efficacy of SIPES compared with CLS. SIPES pediatric has gained significant popularity. Longer M OT with SIPES was the main concern in most published series. One study has shown that SIPES in children is safe and feasible when performed by resident doctors in comparison to the fellow. We started SIPES in 2003. It is carried out routinely by trainees and specialists. Interferences and collisions between surgical instruments are worse in SIPES than CLS. These challenges extended the OT. Although the use of flexible laparoscopic instruments instead of straight instruments may overcome these technical difficulties, only straight laparoscopic instruments are currently used in our institution. Our aim is to standardize this approach in pediatric age group. The technique can be imparted satisfactorily to trainees. However, its successful incorporation into surgical training programs will depend on the development of innovative simulation strategies.

**Keywords:** SILS, SIPES, single incision, laparoscopy

## 1. Introduction

There are many nomenclatures and abbreviations found in literatures: SILS, single-incision laparoscopic surgery; LESS, laparo-endoscopic single-site surgery; TUES, trans-umbilical endoscopic single-site surgery; SPA, single portal access; E-NOTES, embryologic natural orifice transluminal endoscopic surgery; SAS, single access surgery; S3, single-site surgery; NOTUS, natural orifice trans-umbilical surgery; SAVES, single access video endoscopic surgery; and SIPES, single-incision pediatric endoscopic surgery. Cultural changes affected the way of managing patients. It has been over 30 years since the first laparoscopic cholecystectomy. Von Ott inspected the abdominal cavity of pregnant women in 1901. Georg Kelling performed “koelioscopie.” Jacobeus published his first report “Laparothorakoskopie.” Lukichev in 1983 and Muhe in 1985 performed laparoscopic cholecystectomy in humans [1]. Kalloo performed trans-gastric peritoneoscopy in 2004 [2]. Multiple centers performed NOTES in humans, trans-gastric appendectomy and transvaginal cholecystectomy. Limitations of NOTES technique lead to make SILS to go in parallel with it [3]. The first published report in general surgery

appeared in 1992 with appendectomies [4]. In the same year, D'Alessio described a technique for appendectomy in pediatric patients in which a special port was used at the umbilicus to allow the surgeon to bring the appendix out through the umbilicus to perform an extracorporeal appendectomy [5]. 19% of 166 patients in their series required additional trocars, and 4% required conversion to an open operation. The MOT (MOT) was 35 min with a 7-day return to normal activity, compared with 10 days for those that required additional trocars. SIPES has been introduced in our institute by 2003. Now SIPES is our standard technique for many procedures like cholecystectomy, splenectomy, appendectomy, assisted Mitrofanoff, SIPES hernia repair percutaneous internal ring suturing (PIRS), ovarian cystectomy, and fundoplication since 2011. We have performed around 400 SIPES cases up-to-date.

## **2. Limitations of SIPES**

SIPES is not a new technique. It is actually a modification of current laparoscopic technique with some modified instruments and approach used successfully for multiple laparoscopic procedures. Almost all cases which could be done by conventional laparoscopy are amenable to be done by SIPES like splenectomy, appendectomy, cholecystectomy, colectomy, anterior resection, hernia repair, splenectomy, Nissen fundoplication, and sleeve gastrectomy. The approach failed to gain momentum for several years, due to technical limitations with conventional instrumentation. These limitations did not prevent surgeons from using SIPES in pediatric age group. Barbaros and Dincag [6] published the first two adult cases of SILS splenectomy in 2009. Later Dutta reported the first SIPES splenectomy in 2012 [7]. Recently still few centers worldwide have advanced pediatric SIPES [7–13].

## **3. Advantage of SIPES**

Fewer incisions, cosmesis, and non-violation of natural orifices are the most attractive reasons for the patient to choose SILS technique; as a surgeon, ease of tissue retrieval and combination procedures are the main reasons. Using standard laparoscopic equipment has facilitate the procedure for the surgeon with less cost.

## **4. Disadvantage of SIPES**

In comparison with CLS, increased postoperative pain and violation of ergonomic principles in SIPES were not proven in the published studies. Hernia might be a problem in adults published series, but we did not encounter any in our patients. In reverse SIPES, it is an opportunity to repair the umbilical hernia when closing the wound in pediatric age group. Wound infection was not different from conventional laparoscopy. Learning curve escalates fast, and the cost-effectiveness was proven to be less costly than conventional laparoscopy [3].

## **5. Public opinion**

Which technique the public choose if NOTES and SIPES were the only options offered to them? [14]

Most people choose SILS over NOTES when asked about this scenario.

- 208 (20.7%) choose NOTES
- 795 (79.0%) choose SILS
- 3 (0.3%) would refuse surgery

1006 individuals completed the questionnaire explained by F1 medical intern, so as not to bias anyone. All individuals were from around London. 458 (45.5%) were males and 548 (54.5%) were females. 129 were < 20 yrs. old, 460 were 20–29 yrs. old, 186 were 30–39 yrs. old, 103 were 40–49 yrs. old, 61 were 50–59 yrs. old, and 67 were ≥ 60 yrs. old. 80 were physician, 88 medical students, 39 were nurses, and 6 were NHS admin [15]. 793 were nonmedical. Taking the choices by gender, profession, and age, the preference order for the four approaches was:

- 1st—SILS
- 2nd—conventional lap
- 3rd—NOTES
- 4th—open

**Summary**

- SIPES is safe and feasible technique for pediatric age group.
- The disadvantages are balanced with the patient satisfaction and excellent cosmetic results.

**6. Port position**

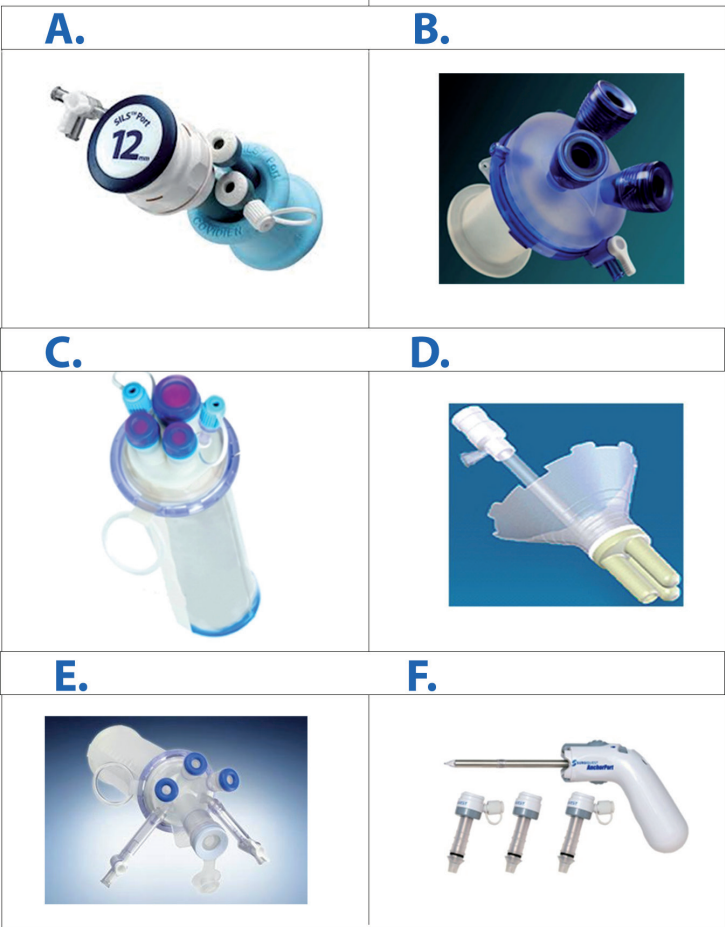The position of SIPES port may be different depending on many factors like choice of surgeon, type of surgery, and the age of the patient. The different locations commonly used are:

1. Omega-shaped incision made around the upper half of umbilicus.
2. Trans-umbilical incision.
3. Incisions are also given above and below umbilicus.
4. Incision maybe placed in the pubic hairline medially.

The author prefers trans-umbilical incision as its ideal to prevent any visible scar, easy access, and quick closure with no port site hernia. In pediatric it gives opportunity to repair the umbilical hernia.

**7. Types of ports**

There are many types of ports with different sizes in the market. The devices are either disposable or reusable: SILS device by Covidien© (Medtronic), GelPOINT system by Applied Medical, R-Port and TriPort by Advanced Surgical Concepts,



**Figure 1.**  
*Types of ports. A) Sils covidien, B) Gel point, C) Triport, D) Uni-X, E) Quadric port. F) Anchorport R by Surgiquest.*

Uni-X by Pnave, Tri or quadric port by Olympus, and AnchorPort R by SurgiQuest. (**Figure 1**) Each port has its own unique feature, so the selection of the port depends on the surgeon, availability, and cost factor. The author has found that Covidien® (Medtronic) port is the most suitable one as it is small in size and it can adopt 15 mm port for introducing GIA stapler and endobag.

## 8. Problems and solutions seen in SIPES

Rivas [16] has given a good list of problems and solutions in SILS. The encountered problems were clashing of instruments, lack of ideal operative ports, interference and deflection of laparoscope's light source by operating instruments, interference of wires or tubing that connect perpendicularly to instruments, difficulty with retraction of organs or structures, lack of time and patience to learn, loss of proprioception due to crossed instrument, and change of surgeon's mindset. The solutions suggested by him were the use of curved, reticulating, or flexible instruments, use of novel multichannel ports, use of an extra-long 5-mm angled laparoscope (50 cm), use of retracting sutures, continuous medical education, implementation of magnetically anchored instruments deployed through a single incision, and use of a 90° adaptor for the light source (for sharp change in its direction parallel to the laparoscope).

Collision of instruments is considered the main limiting factor for popularizing this technique. Other surgeons conquer this problem by using articulating instruments and angled tip fiber-optic camera. The use of articulating instruments was



difficult and almost impossible in small age group due to narrow and small working space, so the author has replaced it by standard straight instruments. The camera-man can stand away from the operating surgeon by using a 50 cm long laparoscope. The articulating and bent instrumentation requires training and experience, and we as other SIPES surgeons are confident that they are not needed in neonates and children. Bent graspers and the 45° rigid endoscope or the deflectable tip laparoscope to minimize instrument collision, both internally and externally, might be of help in obese children and bariatric surgery.

Retraction difficulties is again one of the most important challenges in SIPES; to overcome this problem, there are many tricks being used by surgeons like placing a thin grasper (2-mm Minilap Alligator-Stryker Endoscopy, San Jose, CA), transabdominal sutures, insertion of additional trocarless instrument, and using special laparoscopic magnetic graspers which coupled with external magnets [16, 17]. Transabdominal suturing is useful in small children due to their thin abdominal wall. These sutures are used to encircle the round ligament for liver retraction and seromuscular bites through hollow organs like intestine and gallbladder [16, 19].

Coordination between the surgeon and the camera driver is essential as much or more than it's needed in CLS. In case of intraoperative complication or failure of progression, the introduction of other transabdominal conventional laparoscopic ports to aid completion of the surgical procedure is still there.

Engagement of OR staffs is essential to develop SIPES skills. In the beginning “converting an easy procedure into a harder one” is the sentence which you will hear as a SILS surgeon. Surgeons performing SIPES should have MIS skills and should attend SILS workshops.

In our institute we are providing surgical trainees with advanced laparoscopic and SILS animal workshops. The trainees are doing many SIPES procedures during their rotation, like appendectomies, cholecystectomies, and splenectomies. Although our rotating trainees did not have previous experience in SILS, as we are the only SILS center in the region, by the end of their rotation, they will be able to perform SIPES safely.

**Summary**

- The position of SIPES port is mainly trans-umbilical, but it might be introduced in the left upper quadrant for sleeve gastrectomy.
- Many types of ports are available, but Covidien© (Medtronic) is more suitable for pediatric patients, and Olympus is more suitable for bariatric surgery.
- Many challenges exist with SIPES, but there are always solutions as in conventional laparoscopy.
- Surgeons performing SIPES should have MIS skills and should attend SILS workshops.
- Insertion of extra port is always an option and is considered as conversion to mini laparoscopy (two ports).

**9. SIPES tips and tricks**

**9.1 Tips & Tricks in SIPES appendectomy**

SIPES appendectomy is increasing for its well-known cosmetic benefit. SIPES appendectomy is the most common procedure done in pediatric surgical units. The incision is strategically placed in the umbilicus with a perceived scarless abdomen. The technique is almost the same as in conventional procedure; it is performed

through a 1.5 cm umbilical incision. Single-incision port Medtronic 5–12 mm is placed using the open technique. The mesoappendix is divided by diathermy or sealing device, endo-loops is applied to secure the base of the appendix, and the appendix is then divided and retrieved through the port. Interferences and collisions between surgical instruments are worse than they are when conventional laparoscopic appendectomy (CLA) is performed using three incisions; this may extend the MOT. However, even with these challenges, difficult appendectomy can be completed successfully and safely by SIPES.

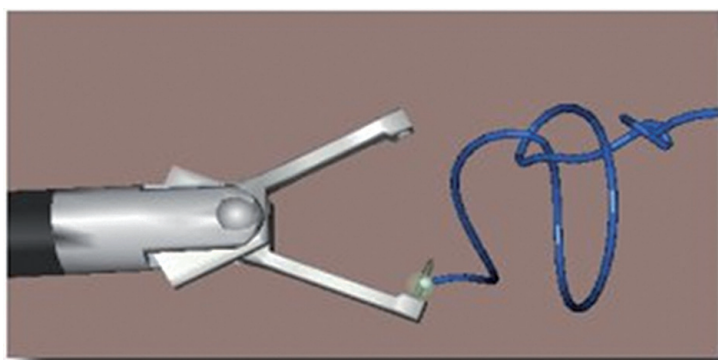
## 9.2 SIPES cholecystectomy

Cholecystectomy is one of the most popular SIPES procedures. Our technique is to place a SILS port Covidien® (Medtronic) 5–12 mm in 1.5 cm trans-umbilical incision by open access. Obtaining the critical view of safety to properly visualize the cystic duct and artery is perhaps of utmost importance. The author modified the placement of straight needle for gallbladder fundus traction by transabdominal suture which is introduced percutaneously by curved needle. Once the gallbladder is properly retracted, the cystic duct and artery are identified, double clipped, and divided. The gallbladder is then dissected off the liver bed with hook cautery, and when completely detached, it is extracted from the abdomen through 12 mm port. No need for endobag.

## 9.3 SIPES splenectomy

SIPES splenectomy gives a good access for retrieving large-sized spleen through the umbilicus, instead of Pfannenstiel-Kerr incision used in conventional laparoscopic splenectomy CLS. Our technique is to place the patient in supine position with left side tilted 30°. Open-access trans-umbilical single-incision of 1.5 cm is used for placement of SILS port, Covidien (Medtronic) 12–15 mm SILS ports. Pneumoperitoneum is created and maintained at a constant pressure of 10–12 mm Hg. We insert 3 mm extra port in left flank for splenic retraction. We use only straight regular instruments. Dissection is performed by sealing device (LigaSure) in four stages: division of spleno-colic ligament at lower pole, dissection of vascular hilum, division of short gastric vessels, and detachment of diaphragmatic ligaments. The spleen is placed in a plastic bag and retrieved after morcellation with Péan forceps.

Insertion of portless extra 3 mm port in the left upper quadrant is necessary for elevation of the spleen to facilitate dissection of the hilum [20]. There is some argument about the use of extra port that it contradicts the concept of SIPES.



**Figure 2.**  
*Endo Stitch device.*

There are some options to replace this port by using tug-exposure or suture suspension techniques [21, 22].

**9.4 SIPES inguinal herniorrhaphy**

Our technique for inguinal herniorrhaphy is percutaneous internal ring suturing (PIRS). The child is placed on supine position, and the surgeon stands on contralateral site of hernia. Laparoscopic camera is inserted through supra umbilical incision. Both sides of deep inguinal ring are explored. Stab wound is placed on the skin crease above deep inguinal ring. Epidural needle inserted in pre-peritoneal area with looped 4/0 nonabsorbable suture. In female the suture surrounds the sac entirely. In boy the needle enters the peritoneum adjacent to vas or vessels for exchange of the suture.

**9.5 SIPES cystectomy/oophorectomy**

We are using bronchoscope with foreign body retrieval forceps to retrieve the cyst and deliver it from the wound in neonate. In older children we use SIPES port and operate as in conventional laparoscopy.

**9.6 SIPES fundoplication**

We insert liver retractor directly through stab wound. The dissection is carried out as in conventional laparoscopy, and traction suture around the esophagus is taken out from the abdominal wall. We performed two cases with large hiatus hernia. Intracorporeal suturing is done by Endo Stitch device (**Figure 2**).

**9.7 SIPES-assisted Mitrofanoff appendicovesicostomy**

We ligate the base of appendix by extracorporeal sutures instead of endo-loop. The urinary bladder filled to come near the umbilical wound. The operation finished through the umbilical incision.

**9.8 Obesity and SIPES**

In the beginning adult surgeons were doing SILS cholecystectomy on patients with BMI less than 34. Later with improvement of instrumentations and development of disposable and reusable SILS trocars, SILS is now is recommended technique for obese, and it is used for sleeve gastrectomy.

**Summary**

- Many procedures have been done in our center
- We found out that appendectomy, cholecystectomy, splenectomy, cystectomy, oophorectomy, orchidectomy, Mitrofanoff, nephrectomy, herniorrhaphy, adhesiolysis, malrotation, and Morgagni hernia are easier to be performed
- Sleeve gastrectomy and fundoplication are less frequently done in our center; the reason in fundoplication is difficulty in suturing.
- This difficulty in older age group could be overcome with Endo Stitch instrument or the use of extracorporeal sliding notes.



10. Outcomes of SIPES at King Fahad Armed Forces Hospital (KFAFH)

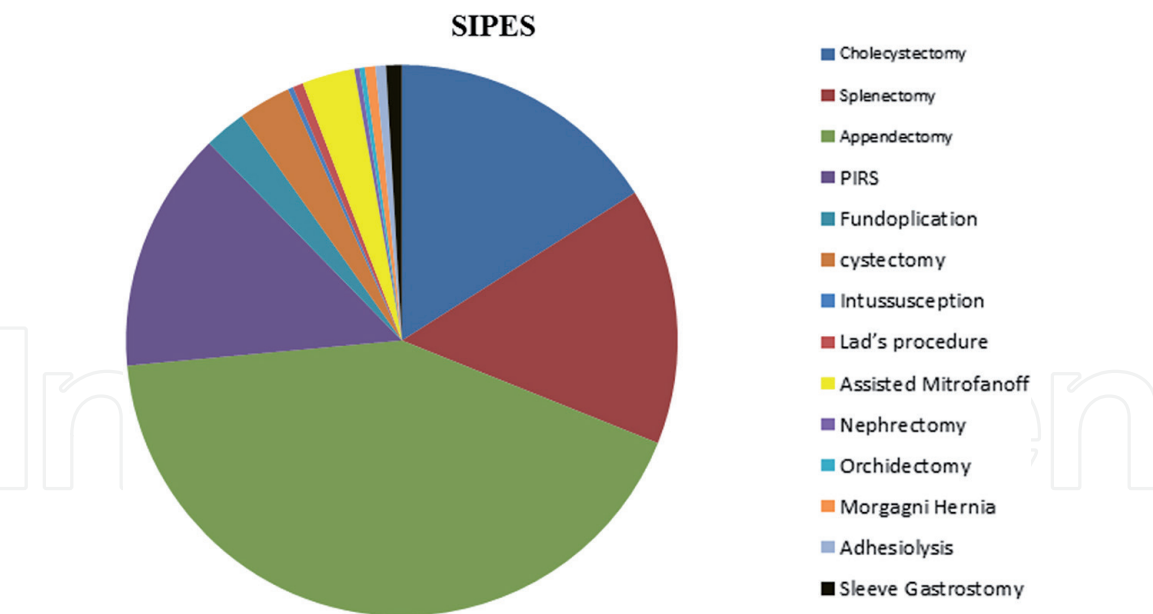
The outcome of our retrospective study of all SIPES cases which was done from 2010 to 2016 is shown in (Table 1 and Figure 3).

10.1 SIPES splenectomy

Few centers worldwide are performing SIPES pediatric splenectomy (Table 2). On extensive review there were only 166 SILS splenectomy cases, out of them only 61 SIPES pediatric splenectomy published in English, German, Greek, French, Italian, or Spanish literatures in all age groups (0.6–90 years) [23–28]. No publications regarding the safety of SIPES splenectomy were performed by trainees. Laparoscopic splenectomy is a demanding technique which needs high level of skills and mainly performed by the most experienced trained surgeon. Our SIPES splenectomy series is the largest one. 49 SIPES splenectomies were performed by 15 trainees. 25 (51%) were male and 24 (49%) were female. Mean age was 6.9 years (2.5–14.8 years). Six cholecystectomies were done simultaneously. 45 patients were having sickle cell disease, two with thalassemia, one spherocytosis, and one Fanconi’s anemia. MOT for splenectomy was 182 min (130–190) and 251 min for splenectomy with cholecystectomy (230–270) min depending on severity of adhesions and size of the spleen

Procedures	Age	OT (min)	#	Conversion
Cholecystectomy (one with inguinal hernia repair+ 1 with appendectomy)	7–16	85 ± 40	52	2 (extra port)
Splenectomy (6 with cholecystectomy)	2.5–14.8	130–270	49	2
Appendectomy (carcinoid, adhesion, 6 perforated, 4 appendix mass)	3–12	70–160	137	0
SIPES hernia repair percutaneous internal ring suturing (PIRS)	2 months–12 years	20–45	46	22 (extra port)
Fundoplication (liver retract, Endo Stitch, 2 hiatal hernia)	18 months–7 years	90–180	8	0
Ovarian cystectomy (oophorectomy) (2 teratomas)	4 days–13 years	30–90	10	0
Intussusception	10 months	90	1	0
Malrotation (Ladd’s procedure)	16 and 17 years	90 and 120	2	0
Assisted Mitrofanoff one with nephrectomy and orchidectomy	1.5–13 years	90–180	10	0
SIPES nephrectomy	18 months	100	1	0
SIPES abdominal orchidectomy	18 months	20	1	0
Morgagni hernia	3 and 5 years	90 and 120	2	0
Adhesiolysis	3 and 6 years	80 and 100	2	0
Sleeve gastrectomy	13–18 years	40–120	3	0
Total				324

Table 1.  
SIPES outcome at KFAFH.



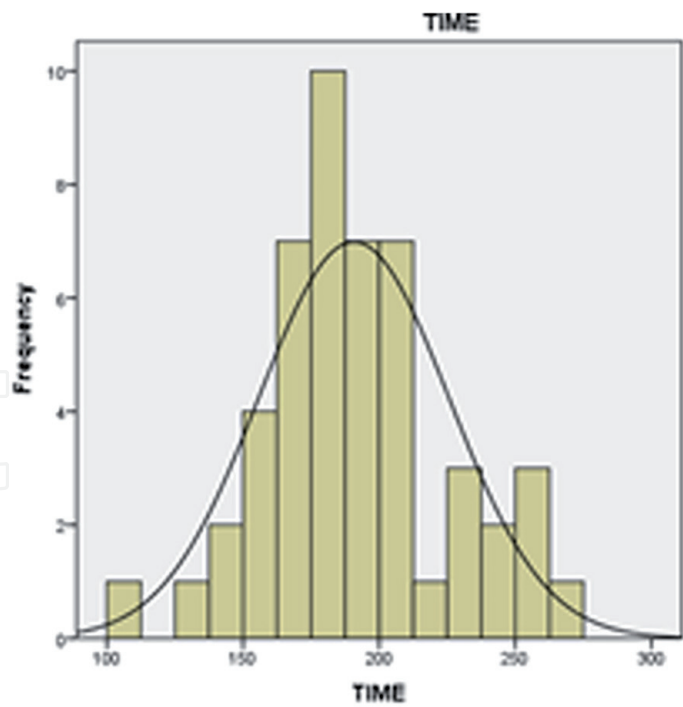
**Figure 3.**  
*KFAFH SIPES outcome.*

Conversion	Time/min	Detail procedures	Age years	Number	Authors
0	90–176	4 splenectomy 2 combined splenectomy/ cholecystectomy	2–17	20 SIPES procedures 8 months	Dutta [18]
2 (excluded)	116	SIPES	7.1 (2.7–9.7)	37 patients (20 with extra port)	Seims et al. [20]
0	125 min (range, 45–420 min)	SILS and SIPES splenectomy	0.6–90	81	Gkegkeset al [23]
		SIPES splenectomy	6 months	1	Joshi et al. [24]
2	130–190	SIPES splenectomy	2.5–14.8	49	Raboei [25]

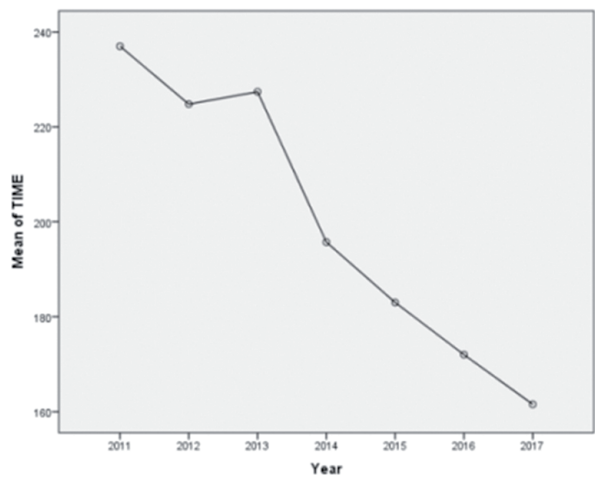
**Table 2.**  
*Comparison of SIPES splenectomy in pediatric age group.*

P value <0.001 (**Figures 4 and 5**). Two were converted to open due to bleeding and were in the beginning of the series. There is neither wound infection nor incisional hernia update. SIPES splenectomy is now the standard of care in our unit, and we highly recommend it as excellent approach for splenectomy.

Summary				
• This is the first series of SIPES splenectomy for hematological diseases done by trainees.				
Procedures	Age	OT (min)	#	Conversion
Splenectomy (six with cholecystectomy)	2.5–14.8	130–270	49	2



**Figure 4.**  
*MOT SIPES splenectomy.*



**Figure 5.**  
*SIPES MOT over years.*

## 10.2 SIPES appendectomy

Most centers advocate laparoscopy for treating acute appendicitis in order to minimize the size and the number of skin incisions even with complicated ones [29]. SIPES pediatric appendectomy has gained significant popularity, as its main advantage is preferable cosmetic result. Previous studies have typically compared SIPES and CLA appendectomy in children and showed heterogeneous results. There was no difference in duration of hospital stay or postoperative complications. Longer MOT with SIPES appendectomy was the main concern [11, 30–41]. One study has shown that SIPES appendectomy in children is safe and feasible when performed by resident doctors and compare it when performed by fellows [42]. Chandler NM et al. studied SIPES versus conventional laparoscopic appendectomy CLA in children. 110 patients underwent appendectomy; 50 SIPES Group 1 and 14 were excluded (perforated) [30, 33]. They concluded that MOT and pain medication are the only significant values between SIPES and conventional. There was no increase in wound infection [43, 44].

Operation	Performing surgeon	MOT	NO.
SIPES appendectomy	Specialist	70.723	47
	Trainee	95.289	90
	Total	86.861	137
CLA	Specialist	64.681	141
	Trainee	88.457	46
	Total	70.529	187

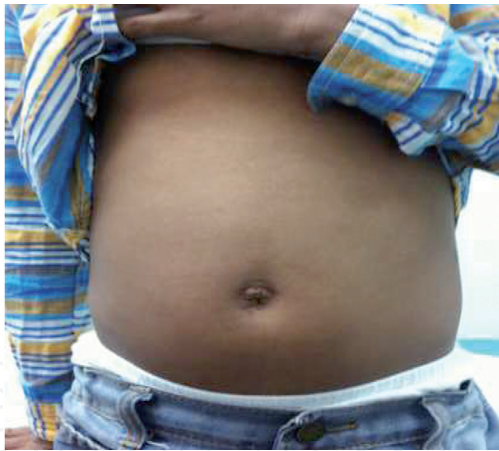**Table 3.**  
*Performing surgeon and MOT.*

We started SIPES appendectomy in 2011, and it became our standard approach for acute appendicitis. It is carried out routinely by trainees and specialist. We compared SIPES appendectomy with CLA between our center and another training center. We conducted retrospective study at two training military institutes, KFAFH and Prince Sultan Medical City PSMC. A total of 322 patients were operated. 187 patients (58%) underwent CLA, and 137 patients (42%) underwent SIPES appendectomy. 120 patients (64%) of CLA and 87 (63%) patients of SIPES appendectomy were males. 67 patients (36%) of CLA and 42 (37%) patients of SIPES appendectomy were females. The mean age of the patients in CLA and SIPES appendectomy was 10 and 9.6 years, respectively. Diagnosis at time of operation was simple appendicitis in 166 patients who underwent CLA and 126 patients who underwent SIPES appendectomy, and complicated appendicitis was in 21 and 11 patients, respectively. 143 CLA (76%) were performed by specialist, and 44 cases (24%) were performed by trainees. 47 SIPES appendectomy (34%) were performed by specialist, and 90 cases (66%) were performed by trainees (**Table 3**) (P value <0.001). The MOT was 70 min for CLA and 86 min for SIPES appendectomy (P value <0.001). The mean length of hospital stay is 2.6 days for CLA and 2.8 days for SIPES appendectomy. Bilateral percutaneous internal ring suturing (PIRS) and right PIRS were performed on 2 patients who underwent SIPES appendectomy. Three cases developed intra-abdominal collection (2.2%), one case had wound infection (0.7%), and two cases had adhesion (1.5%), treated conservatively in SIPES appendectomy. There were five cases of intra-abdominal collection (2.7%), two cases of wound infection (1.1%), and one case of adhesion (0.5%) in CLA. Negative appendectomy rate has been 10%.

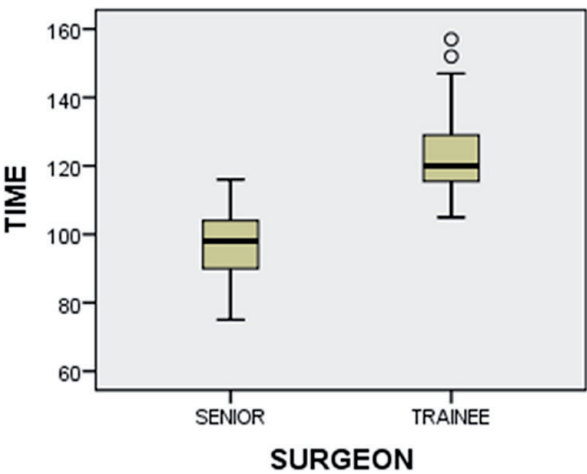
Summary				
<ul style="list-style-type: none"><li>SIPES appendectomy is the commonest procedure done in our center by our trainees.</li></ul>				
Procedures	Age	OT (min)	#	Conversion
Appendectomy (carcinoid, adhesion, six perforated, four appendix mass)	3–12	70–160	137	0

10.3 SIPES cholecystectomy

Minimally invasive techniques have revolutionized surgical treatment. Few centers worldwide have advanced SIPES for pediatric age group. Many papers that were published in English literatures proved the safety and efficacy of SIPES cholecystectomy [44–48]. Up to our knowledge, there is no study regarding MOT of SIPES



**Figure 6.**  
*SIPES cholecystectomy 6 months post-op.*



**Figure 7.**  
*SIPES cholecystectomy MOT.*

cholecystectomy performed by trainees in patients with hematological disease. We conducted a retrospective study to determine the feasibility, safety, and expediency of SIPES cholecystectomy performed by trainees. 45 patients underwent SILS cholecystectomy. Age of the patients ranged from 7 to 16 years. Hematological disease were in >80% of cases. One extra port was needed in 2 patients in the beginning of the series. Eight procedures were done simultaneously, six splenectomy, one appendectomy, and one herniotomy, and were excluded from MOT. No conversion was needed. No wound infection. MOT is  $85 \pm 40$  min. (**Figures 6 and 7**). It is comparable with conventional technique.

Summary				
<ul style="list-style-type: none"><li>SIPES cholecystectomy is the second common operation in our center.</li><li>We made a new technique for gallbladder traction by using a curved needle which visualize Calot's triangle clearly.</li></ul>				
Procedures	Age	OT (min)	#	Conversion
Cholecystectomy (one with inguinal hernia repair + 1 with appendectomy)	7–16	85 ± 40	52	2 (extra port)



10.4 SIPES inguinal herniorrhaphy

The approach to inguinal hernia in the pediatric population has historically been via an open technique. During recent years, laparoscopic surgery has emerged as an alternative in the treatment of pediatric inguinal herniorrhaphy. Different laparoscopic technique has been used, and SIPES is a recommended approach for management of inguinal herniorrhaphy [28]. SIPES inguinal herniorrhaphy gives opportunity to explore the contralateral side. We retrospectively review all SIPES inguinal hernia cases. MOT, intra- and postoperative complications, cosmetic results, and contralateral patencies of processus vaginalis (CPPV) were recorded. Patients were followed up for 4 months postoperatively. A total of 46 patients were operated, 39 (84.8%) were male, and 7 (15.2%) were female. Right side inguinal hernias were 18 (39.1%), left were 12 (26.1%), and bilateral sides were 16 (34.8%). 56.5% were less than 1 year, 19.6% were between 1 and 5 years, and 23.9% were 6–13 years old. Mean age is 2.7 years. For unilateral procedures MOT was 27 min. For bilateral procedures MOT was 40 minutes. Seven (23%) (CPPV) was found in laparoscopic surgery. Stitch granuloma developed in one patient.

Summary				
<ul style="list-style-type: none"><li>PIRS is comparable with OH.</li><li>It needs good ancillary services for babies below 6 months of age.</li></ul>				
Procedures	Age	OT (min)	#	Conversion
SIPES hernia repair percutaneous internal ring suturing (PIRS)	2 months–12 years	20–45	46	22 (extra port)

11. Conclusion

SIPES has excellent cosmesis and almost invisible scar.  
We can do more than one procedure at the same time with SIPES technique.  
SIPES splenectomy is safe and feasible when performed by surgical trainees without adding any morbidity to the patients even those with hematological diseases.  
SIPES appendectomy is feasible and safe in complicated appendicitis.  
SIPES cholecystectomy MOT is comparable with conventional technique.  
SIPES PIRS for inguinal herniorrhaphy is safe and efficient with good learning curve and best cosmetic result.  
SIPES technique can be imparted satisfactorily to trainees. However, its successful incorporation into surgical training programs will depend on the development of innovative simulation strategies.  
Our aim is to standardize this approach and to reassure our colleagues regarding the safety, feasibility, and technical challenges of SIPES.

Acknowledgements

We would like to acknowledge Dr Mohamed Al Onazi and his team from PSMC in Riyadh Saudi Arabia for their contribution.

## **Conflict of interest**

None.

## **Author details**

Enaam Raboei<sup>1\*</sup>, Ameen Alsaggaf<sup>2</sup>, Yazeed Owiwi<sup>2</sup>, Syed Salahuddin<sup>3</sup>,  
Alaa Ghallab<sup>2</sup> and Mazen Zidan<sup>2</sup>

1 Pediatric Surgery Department, King Fahd Armed Forces Hospital, Jeddah,  
Saudi Arabia

2 King Fahd Armed Forces Hospital, Jeddah, Saudi Arabia

3 Leeds, UK

\*Address all correspondence to: enaamraboei@kfah.med.sa

## **IntechOpen**

© 2019 The Author(s). Licensee IntechOpen. This chapter is distributed under the terms of the Creative Commons Attribution License (<http://creativecommons.org/licenses/by/3.0>), which permits unrestricted use, distribution, and reproduction in any medium, provided the original work is properly cited. 

## References

- [1] Vecchio R, MacFayden BV, Palazzo F. History of laparoscopic surgery. *Panminerva Medica*. 2000;**42**(1):87-90
- [2] Kalloo AN, Singh VK, Jagannath SB, Niiyama H, Hill SL, Vaughn CA, et al. Flexible transgastric peritoneoscopy: A novel approach to diagnostic and therapeutic interventions in the peritoneal cavity. *Gastrointestinal Endoscopy*. 2004;**60**(1):114-117
- [3] Li P, Chen Z-H, Li Q-G, Qiao T, Tian Y-Y, Wang D-R. Safety and efficacy of single-incision laparoscopic surgery for appendectomies: A meta-analysis. *World Journal of Gastroenterology*. 2013;**19**(25):4072-4082
- [4] Pelosi MA, Pelosi MA 3rd. Laparoscopic appendectomy using a single umbilical puncture (minilaparoscopy). *The Journal of Reproductive Medicine*. 1992;**37**(7):588-594
- [5] Saidy MN, Tessier M, Tessier D. Single-incision laparoscopic surgery—Hype or reality: A historical control study. *The Permanente Journal*. 2012;**16**(1):47-50
- [6] Barbaros U, Dinççağ A. Single incision laparoscopic splenectomy: The first two cases. *Journal of Gastrointestinal Surgery*. 2009;**13**(8):1520-1523
- [7] Dutta S. Early experience with single incision laparoscopic surgery: Eliminating the scar from abdominal operations. *Journal of Pediatric Surgery*. 2009;**44**(9):1741-1745
- [8] Hansen EN, Muensterer OJ, Georgeson KE, Harmon CM. Single-incision pediatric endosurgery: Lessons learned from our first 224 laparoendoscopic single-site procedures in children. *Pediatric Surgery International*. 2011;**27**(6):643-648
- [9] De Armas IA, Garcia I, Pimpalwar A. Laparoscopic single port surgery in children using Triport: Our early experience. *Pediatric Surgery International*. 2011;**27**(9):985-989
- [10] Kocherov S, Lev G, Shenfeld OZ, Chertin B. Laparoscopic single site surgery: Initial experience and description of techniques in the pediatric population. *The Journal of Urology*. 2011;**186**(4 Suppl):1653-1657
- [11] Oltmann SC, Garcia NM, Ventura B, Mitchell I, Fischer AC. Single-incision laparoscopic surgery: Feasibility for pediatric appendectomies. *Journal of Pediatric Surgery*. 2010;**45**(6):1208-1212
- [12] Gasior AC, Knott EM, Holcomb GW, Ostlie DJ, St Peter SD. Patient and parental scar assessment after single incision versus standard 3-port laparoscopic appendectomy: Longterm follow-up from a prospective randomized trial. *Journal of Pediatric Surgery*. 2014;**49**:120-122. discussion 122
- [13] Jayashingh SC. Comparison of advantages and disadvantages between SILS and NOTES. *World Journal of Laparoscopic Surgery*. 2011;**4**(1):67-72
- [14] Fransen SA, Broeders E, Stassen L, Bouvy N. The voice of Holland: Dutch public and patient's opinion favours single-port laparoscopy. *Journal of Minimal Access Surgery*. 2014;**10**:119-125
- [15] Chow A, Purkayastha S, Dosanjh D, Sarvanandan R, Ahmed I, Paraskeva P. Patient reported outcomes and their importance in the development of novel surgical techniques. *Surgical Innovation*. 2012;**19**(3):327-334. DOI: 10.1177/1553350611426011. Epub 2011 Dec 7
- [16] Rivas H, Varela E, Scott D. Single-incision laparoscopic cholecystectomy:

Initial evaluation of a large series of patients. *Surgical Endoscopy*. 2010;**24**(6):1403-1412

[17] Padilla BE, Dominguez G, Millan C, Martinez-Ferro M. The use of magnets with single-site umbilical laparoscopic surgery. *Seminars in Pediatric Surgery*. 2011;**20**:224-231

[18] Dutta S. Early experience with single incision laparoscopic surgery: Eliminating the scar from abdominal operations. *Journal of Pediatric Surgery*. Sep 2009;**44**(9):1741-1745

[19] Blanco FC, Kane TD. Single-port laparoscopic surgery in children: Concept and controversies of the new technique. *Minimally Invasive Surgery*. 2012;**2012**:232347. Published Online 2012 Jun 12

[20] Seims AD, Russell RT, Beierle EA, Chen MK, Scott AA, Martin CA, et al. Single-incision pediatric endosurgery (SIPES) splenectomy: What dictates the need for additional ports? *Surgical Endoscopy*. 2015;**29**(1):30-33

[21] Misawa T, Sakamoto T, Ito R, Shiba H, Gocho T, Wakiyama S, et al. Single-incision laparoscopic splenectomy using the "tug-exposure technique" in adults: Results of ten initial cases. *Surgical Endoscopy*. 2011;**25**(10):3222-3227

[22] Li S, Li M, Xu W, Sun C, Liu L. Single-incision laparoscopic splenectomy using the suture suspension technique for splenomegaly in children with hereditary spherocytosis. *Journal of Laparoendoscopic & Advanced Surgical Techniques. Part A*. 2015;**25**(9):770-774

[23] Gkegkes D, Mourtarakos S, Iavazzo C. Single-incision laparoscopic splenectomy. *JSLs*. 2014;**18**(3):e2014.00350

[24] Joshi M, Kurhade S, Peethambaram M, Kalghatgi S, Narsimhan M,

Ardhanari R. Single-incision laparoscopic splenectomy. *Journal of Minimal Access Surgery*. 2011;**7**(1):65-67

[25] Raboei E, Owiwi Y, Ghallab A, Zeinelabdeen A, Alsaggaf A, et al. Is It Safe for Trainees to Perform Single-Incision Pediatric Endosurgery Splenectomy?. *Journal of Laparoendoscopic & Advanced Surgical Techniques*. Mar 2019;**29**(3):420-423

[26] Hansen EN, Muensterer OJ. Single incision laparoscopic splenectomy in a 5-year-old with hereditary spherocytosis. *JSLs*. 2010;**14**(2):286-288

[27] Garrett D, Emami C, Anselmo DM, Torres MB, Nguyen N. Single-incision laparoscopic approach to management of splenic pathology in children: An early experience. *Journal of Laparoendoscopic & Advanced Surgical Techniques. Part A*. 2011;**21**:965-967

[28] Saldana LJ, Targarona EM. Single-incision pediatric endosurgery: A systematic review. *Journal of Laparoendoscopic & Advanced Surgical Techniques. Part A*. 2013;**23**:467-480

[29] Muensterer O, Puga Nougues C, Adibe O, Amin S, Georgeson K, Harmon C. Appendectomy using single-incision pediatric endosurgery for acute and perforated appendicitis. *Surgical Endoscopy*. 2010;**24**(12):3201-3204

[30] Chandler NM, Danielson PD. Single-incision laparoscopic appendectomy vs multiport laparoscopic appendectomy in children: A retrospective comparison. *Journal of Pediatric Surgery*. 2010;**45**(11):2186-2190

[31] Chow A1, Aziz O, Purkayastha S, Darzi A, Paraskeva P. Single incision laparoscopic surgery for acute appendicitis: Feasibility in pediatric patients. *Diagnostic and Therapeutic Endoscopy*. 2010;**2010**:294958



- [32] Lacher M, Muensterer OJ, Yannam GR, Aprahamian CJ, Perger L, Megison M, et al. Feasibility of single-incision pediatric endosurgery for treatment of appendicitis in 415 children. *Journal of Laparoendoscopic & Advanced Surgical Techniques. Part A.* 2012;**22**(6):604-608
- [33] Chandler NM, Danielson PD. SILS versus conventional laparoscopic appendectomy CLA in children. *Journal of Pediatric Surgery.* 2010;**45**(11):2186-2190
- [34] Perez EA, Piper H, Burkhalter LS, Fischer AC. Single-incision laparoscopic surgery in children: A randomized control trial of acute appendicitis. *Surgical Endoscopy.* 2013;**27**:1367-1371
- [35] Salö M, Järbur E, Hambræus M, Ohlsson B, Stenström P, Arnbjörnsson E. Two-trocar appendectomy in children—Description of technique and comparison with conventional laparoscopic appendectomy. *BMC Surgery.* 2016;**16**:521-525
- [36] Wu K, Yang L, Wu A, et al. Single-site laparoscopic appendectomy in children using conventional instruments: A prospective, randomized, control trial. *Pediatric Surgery International.* 2015;**31**:167-171
- [37] Duza G, Palermo M, Khiangte E, Azfar M, Rizvi SAA, Trelles N, et al. Single port laparoscopic appendectomy vs conventional laparoscopic appendectomy: Outcomes after multicenter randomized control trial. *Journal of American College of Surgeons.* 2015;**221**(4 Suppl 2):e17
- [38] St. Peter S, Adibe O, Juang D, Sharp S, Garey C, Laituri C, et al. Single incision versus standard 3-port laparoscopic appendectomy. *Annals of Surgery.* 2011;**254**(4):586-590
- [39] Feng J, Cui N, Wang Z, Duan J. Bayesian network meta-analysis of the effects of single-incision laparoscopic surgery, conventional laparoscopic appendectomy and open appendectomy for the treatment of acute appendicitis. *Experimental and Therapeutic Medicine.* Dec 2017;**14**(6):5908-5916
- [40] Park J, Kwak H, Kim SG, Lee S. Single-port laparoscopic appendectomy: Comparison with conventional laparoscopic appendectomy. *Journal of Laparoendoscopic & Advanced Surgical Techniques. Part A.* 2012;**22**:142-145
- [41] Yannam G, Griffin R, Anderson S, Beierle E, Chen M, Harmon C. Single incision pediatric endosurgery (SIPES) appendectomy—Is obesity a contraindication? *Journal of Pediatric Surgery.* 2013;**48**(6):1399-1404
- [42] Wakasugi M, Tsujimura N, Nakahara Y, Matsumoto T, Takemoto H, Takachi K, et al. Single-incision laparoscopically assisted appendectomy performed by residents is safe and feasible: A single institution, retrospective case series. *Annals of Medicine and Surgery.* 2017;**15**:43-46
- [43] Sesia S, Haecker F, Kubiak R, Mayr J. Laparoscopy-assisted single-port appendectomy in children: Is the postoperative infectious complication rate different? *Journal of Laparoendoscopic & Advanced Surgical Techniques.* 2010;**20**(10):867-871
- [44] Stringe G, Zitsman JL, Shehadi I, Kithir S. Laparoscopic Appendectomy in Children. *JSLs.* 1997;**1**(1):37-39
- [45] Navarra G, Pozza E, Occhionorelli S, Carcoforo P, Donini I. One-wound laparoscopic cholecystectomy. *The British Journal of Surgery.* 1997;**84**(5):695
- [46] Podolsky ER, Rottman SJ, Poblete H, King SA, Curcillo PG. Single port access (SPA) cholecystectomy: A completely transumbilical approach.



Journal of Laparoendoscopic &  
Advanced Surgical Techniques. Part  
A. 2009;**19**(4):495-499. DOI: 10.1089/  
lap.2008.0424

[47] Podolsky ER, Curcillo PG 2nd.  
Reduced-port surgery: Preservation of  
the critical view in single-port-access  
cholecystectomy. *Surgical Endoscopy*.  
2010;**24**(12):3038-3043

[48] Podolsky ER, Rottman SJ, Curcillo  
PG 2nd. Single port access (SPA)  
cholecystectomy: Two year follow-up.  
*JSLs*. 2009;**13**(4):528-535