

We are IntechOpen, the world's leading publisher of Open Access books Built by scientists, for scientists

6,900

Open access books available

185,000

International authors and editors

200M

Downloads

Our authors are among the

154

Countries delivered to

TOP 1%

most cited scientists

12.2%

Contributors from top 500 universities



WEB OF SCIENCE™

Selection of our books indexed in the Book Citation Index
in Web of Science™ Core Collection (BKCI)

Interested in publishing with us?
Contact book.department@intechopen.com

Numbers displayed above are based on latest data collected.
For more information visit www.intechopen.com



Surgical Treatment of Distal Common Bile Duct Malignancy

Adrian Bartos, Andrei Herdean and Dana Monica Bartos

Abstract

Distal cholangiocarcinoma is a rare malignant condition arising from the epithelial cells of the biliary tract. Surgical resection is the only curable alternative for patients with this disease. True resectability is often determined by surgical exploration. Duodenopancreatectomy is an extremely high-demanding technique and is the only one that can be potentially curable for patients diagnosed with resectable distal cholangiocarcinoma. Long-term survival may be achieved only in selected patients, undergoing duodenopancreatectomy, especially in patients where R0 margins are achieved. Perineural extension, pancreatic invasion, and lymph nodes involvement are the main risk factors for recurrence. Palliative biliary drainage or endoscopic internal drainage of the biliary tree is alternative for patients with unresectable tumors. Although the prognosis after surgical treatment of distal common bile duct malignancy is better than for other periampullary tumors, the continuous progresses made in the field of surgical therapy and oncological treatment may lead to an improvement in the outcome of this neoplastic pathology.

Keywords: common bile duct tumors, surgical treatment, duodenopancreatectomy, jaundice palliation, laparoscopic pancreatic surgery

1. Introduction: general aspects

Biliary tract cancers are a group of neoplastic lesions originating from the epithelial cells of the biliary tract. This type of cancers are characterized by late diagnosis and also poor outcomes; they represent <1% of all cancers and approximately 3% of all gastrointestinal tumors [1] and affect elderly patients, especially men [2, 3]. Biliary tract cancers are categorized by their anatomical sites in distal, hilar, and intrahepatic cholangiocarcinoma. Intrahepatic cholangiocarcinoma is an entity defined by the fact that it is located proximally than the second-degree bile ducts. Perihilar cholangiocarcinoma represents the bile tract neoplasm characterized by the localization between the second-degree biliary ducts and the confluence between the cystic duct and the common bile duct. Distal cholangiocarcinoma is located from the confluence between the cystic duct and the common bile duct to the ampulla of Vater. Distal common bile duct cancer represents a periampullary neoplasm, which is less common than pancreatic adenocarcinoma, being very difficult to distinguish between them [2]. Most of the biliary tract neoplasms are adenocarcinomas, which can be well, moderately, and poorly differentiated. Other types are considered to be rare [4]. Five-year survival rate is extremely poor, despite the fact that surgery and liver transplantation represent options for selected candidates suffering from perihilar cholangiocarcinoma. Many patients are still

not eligible for surgical treatment because of the advanced locoregional stage at the moment of diagnosis [1]. In order to obtain a higher survival rate, the multimodal treatment (surgery, chemotherapy, radiotherapy) should be considered in all stages of disease [5]. Regarding the chemotherapy, gemcitabine and cisplatin are usually used for treating inoperable cases. For intrahepatic cholangiocarcinoma, locoregional therapies were developed, but there is no conclusive evidence [2]. Perihilar localization is encountered in about 50% of the cases. The distal topography is found in approximately 40% of biliary tract cancers and the intrahepatic disease in less than 10% [6]. The epidemiology of these tumors is still poorly understood. Distal cholangiocarcinoma has a better prognosis and cure rate when compared to the pancreatic adenocarcinoma, but it still remains a high lethal medical condition. It is very important to make sure that a multidisciplinary approach is considered when dealing with distal cholangiocarcinoma [7].

2. Surgical treatment of distal cholangiocarcinoma: indications

2.1 Indications for radical treatment

Only a small number of patients are suitable for surgical treatment. In order to submit a patient for surgery, an assessment is mandatory, and it relies on accurate imaging and endoscopic techniques to assess the localization of the tumor and also the local and metastatic extent. In order to obtain an accurate staging and diagnosis, imaging should be done prior to biopsy. Ultrasound and CT are useful imaging tools for the staging of distal cholangiocarcinoma, but MRI with contrast angiography is the most accurate for assessing the biliary tract and the possible invasion of nearby vascular structures. The use of PET-CT scan is limited because of the presence of cholangitis, which can make the interpretation very difficult. The histological diagnosis is usually obtained by ERCP. The tissue sample can also be obtained by performing an endoscopic ultrasound with fine needle aspiration [8]. The selection of patients for surgery requires preoperative staging and surgical exploration (laparoscopy) in order to exclude the patients with unresectable or metastatic disease. A biopsy is not mandatory in the cases when there is a high index of suspicion [9].

In order to obtain the best long-term outcome, tumor resection with clear margins is mandatory. The main objective is represented by an aggressive resection strategy [10]. Distal cholangiocarcinomas encounter the highest rate of resectability when compared to hilar or intrahepatic cholangiocarcinomas [11]. The overall 5-year survival rate following curative surgery is between 16 and 52% in cases of distal cholangiocarcinoma. The operation generally requires a duodenopancreatectomy with typical reconstruction. In few cases, when the disease is extensively involving the biliary tract, a pancreaticoduodenectomy associated with a hepatic resection might be required. However, if there is a case of distant nodal extent, combined pancreatic and hepatic resections are not recommended due to the high morbidity and mortality rates that this operation presents. The guidelines recommend that a biliary drainage should be considered prior to radical resection in patients with jaundice. However, the need of biliary drainage should be assessed by a multidisciplinary team with high experience in dealing with distal cholangiocarcinomas [12].

2.2 Prognostic factors: operability criteria

There are two main predictors of survival after surgery: the status of surgical margins and lymph node involvement. Lymphadenectomy should be performed in the area of the pancreatic head and it is considered to be a vital part of the surgical

intervention. Performing a frozen section examination of the proximal biliary tract margin should be considered in order to be sure that oncological surgical criteria are fulfilled [13, 14].

Resectability criteria:

- The absence of retropancreatic and paraceliac lymph nodal involvement
- The absence of liver metastases
- The absence of invasion of the main hepatic artery
- The absence of disseminated disease

3. Indications for palliative treatment: unresectable tumors

Locally advanced, unresectable, distal cholangiocarcinomas are divided into three main categories as it follows:

1. Microscopic positive margins (R1) after resection
2. Locally advanced, unresectable, from the moment of presentation
3. Recurrence after intent of curative treatment

The prognosis of unresectable cholangiocarcinomas is extremely poor: 6–12 months. The goal for these patients is to relieve symptoms and obtain a better quality of life. Also, it is well known that tumor debulking does not have a role and should be avoided in advanced cases of cholangiocarcinoma. Recently, chemotherapy combined with local therapies and biological therapies proved to be associated with a significant improvement in the survival rate. However, because of the rarity of the disease, many of these treatment options are assessed only in small studies and require to be validated by large prospective randomized trials [8]. Surgical treatment is contraindicated in cases of metastatic disease of the liver, lung, and peritoneum or in cases that present lymph nodes involvement beyond the head of the pancreas. Patients with unresectable or metastatic disease are considered for the palliation of jaundice. This is made either by a surgical bypass or, most frequently, by ERCP with the placement of a biliary stent. In cases of unresectable disease, a biopsy is mandatory in order to continue with any type of further treatment. Treatment options include the enrollment into a clinical trial, chemotherapy, radiotherapy, or chemoradiation procedures. There are trials that suggest the benefit of chemotherapy over best supportive care alone with reported overall survival rate of 9.5 versus 4.5 months [15, 16]. Another possibility for these patients is represented by chemoradiation. This way of treatment provides control of the symptoms and prolongs the overall survival rate. The most studied chemotherapeutic agent used in combination with radiotherapy was fluorouracil [17].

For patients with microscopically positive margins after surgery, the most recommended way of treatment consists of postoperative systemic chemotherapy combined with adjuvant chemoradiotherapy in conventional doses of radiation.

In cases of locally advanced and recurrent disease, the use of conventional doses of radiations has the role of relieving pain and may have a role in the decompression of the biliary tract [18].

Photodynamic therapy consists of intravenous injecting of a porphyrin photosensitizer combined with the endoscopic application of light on the tumor site.

This innovative technique leads to the death of the tumoral cell by generating free radicals of oxygen. Some studies suggest that photodynamic therapy combined with biliary decompression obtained after stenting provides a benefit in the overall survival rate of these patients [19–21]. Nowadays, photodynamic therapy is studied as a neoadjuvant condition. It is presumed that the rate of postoperative negative margins can be increased by submitting patients to neoadjuvant photodynamic therapy [22].

One of the most important aspects when dealing with locally advanced, unresectable, distal cholangiocarcinomas is represented by the palliation of jaundice. This can be realized by performing a surgical by-pass or by endoscopic placement of a stent. In patients who are found to suffer from an unresectable cholangiocarcinoma during a laparotomy, a surgical bypass is preferred. On the other way, in cases that the unresectable condition is diagnosed by imagining or laparoscopy, the endoscopic placement of a biliary stent is preferred. In most cases, the palliation of jaundice is obtained by an endoscopic approach [23, 24]. The most common relapse pattern is represented by local recurrence. Positive margins and lymph node involvement are predictive risk factors for local recurrence. The typically sites of metastases are the liver and the peritoneum.

4. Surgical technique and approach

4.1 Duodenopancreatectomy

Duodenopancreatectomy represents a very complex surgical intervention. It is performed in cases of resectable periampullary tumors: distal cholangiocarcinoma, tumors of the pancreatic head, tumors of the ampulla of Vater, and tumors of the duodenum [25].

The surgical intervention begins with either a median or bilateral subcostal incision (in thin patients, a median incision is preferred). First important step during a duodenopancreatectomy is to search for distant metastases. Once the surgeon rules out the presence of liver or peritoneal metastases, the Kocher maneuver is performed in order to identify the relation of the tumor with the retroperitoneal structures and especially the superior mesenteric artery. The superior mesenteric artery is dissected beginning from the right side of the Treitz's ligament, in order to exclude the tumoral involvement of the artery. This procedure is known as artery-first approach. Access to the omental bursa is gained by the division of the gastrocolic ligament. In order to mobilize the hepatic flexure of the colon, careful dissection of the avascular plane located between the hepatic flexure and the duodenum must be performed. Once the colonic flexure is mobilized caudally, the Kocher maneuver can be extended in order to allow the access to the D3 portion of the duodenum (**Figure 1**). Now, the gastroepiploic vein is divided and the superior mesenteric vein appears on the inferior margin of the pancreas. In order to complete this step of the surgical intervention, a tunnel is made between the neck of the pancreas and the portal vein (**Figure 2**). Further, the dissection continues in the supraduodenal region as it follows. Cholecystectomy is performed in the classical way. After the dissection of the Callot triangle, the common bile duct is divided just proximal from the origin of the cystic duct. After the cystic artery is identified, it is closed by ligation and divided. A very important step for obtaining best oncological outcome is represented by the lymphadenectomy of the hepatoduodenal ligament continued toward the celiac trunk. During this dissection, the proper hepatic artery, originating from the common hepatic artery and the main branches of the celiac trunk, can be isolated. The gastroduodenal artery is now divided near its origin (**Figure 3**). In order to obtain the preservation of the pylorus (optional step), the right

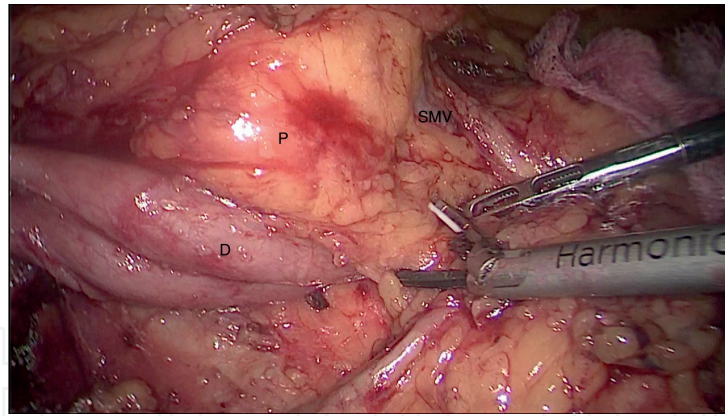


Figure 1.
 Kocher maneuver; laparoscopic approach (from the personal archive of the authors). P = pancreatic head;
 D = duodenum; SMV = superior mesenteric vein.

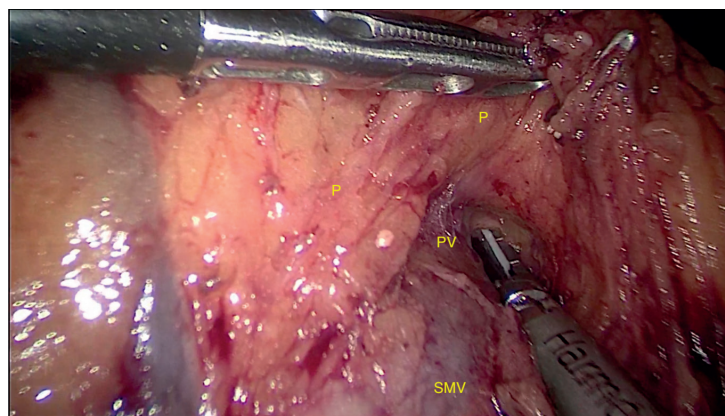


Figure 2.
 Dissection of the SMV and PV from the pancreatic isthmus; laparoscopic approach (from the personal archive of the authors). P = pancreatic head; SMV = superior mesenteric vein; PV = portal vein.

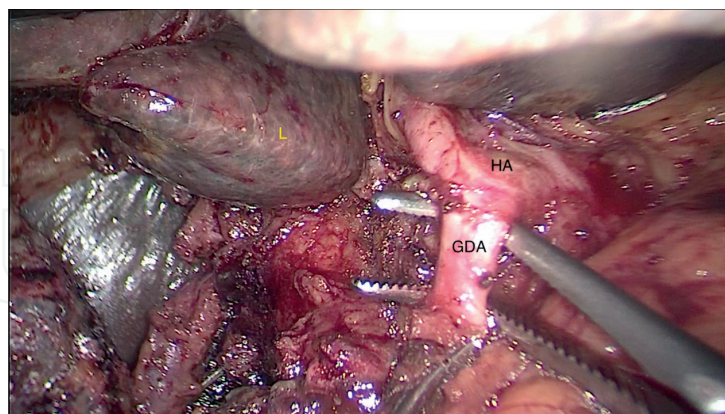


Figure 3.
 Dissection of the gastroduodenal artery; laparoscopic approach (from the personal archive of the authors).
 L = liver; HA = hepatic artery; GDA = gastroduodenal artery.

gastric and right gastroepiploic arteries should be divided. After the mobilization of the first 2 cm of the duodenum is performed, the portal vein is widely exposed. The superior and inferior pancreatic vessels are now ligated by placing two sutures on both the superior and inferior borders of the pancreas. Those two sutures are extremely important for minimizing the bleeding after transection of the pancreas. A tunnel is now fully created between the portomesenteric trunk and the posterior surface of the pancreatic neck. The Treitz angle and the first jejunal loop are now

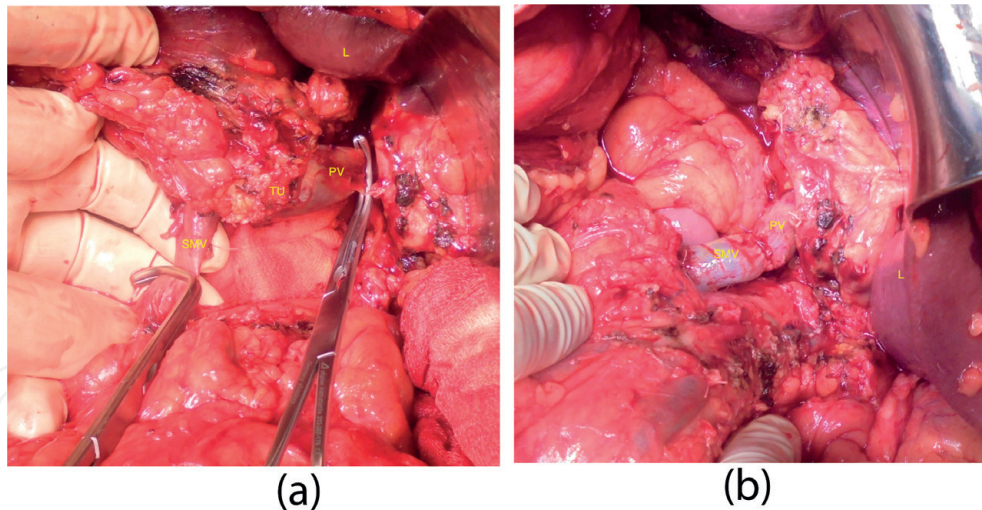


Figure 4. Vascular resection of a tumor with invasion in the portal vein; open approach (from the personal archive of the authors). L = liver; PV = portal vein; SMV = superior mesenteric vein; TU = tumor. (A) Before vascular resection; and (B) after vascular reconstruction.

dissected and divided so that the jejunum can be tractioned into the supramesocolic compartment. The dissection along the superior mesenteric artery and vein is carefully performed using a bipolar electrocautery and clips or ligatures. The venous (portal, superior mesenteric, venous confluent) resection, if required, is performed in the last step (**Figure 4A and B**). By gently retracting the portal vein, in order to expose the retroportal tissue, the venous branches that drain directly into the portal vein are identified, ligated, and divided. The transection of the pancreatic neck is now performed by using a scalpel (classic or harmonic). It is very important to obtain a perfect hemostasis at the level of the pancreatic stump. This is obtained by placing nonabsorbable monofilament sutures. Some authors consider that by using the bipolar or monopolar cautery, an insecure hemostasis is obtained and also the pancreatic tissue can be damaged, the fact that may compromise future anastomosis. As a final step of the extirpative phase, the duodenum (in pylorus preserving technique) is divided using a linear stapler. Now the specimen is removed and sent for histopathological examination. The pancreatic stump is now mobilized in order to obtain a tension-free pancreatic anastomosis (with the stomach or the jejunum). The second main phase of this very complex operation is the reconstructive phase. Now, in order to obtain the continuity of the digestive tract, three anastomoses must be performed. Firstly, the pancreatic stump is anastomosed either with the stomach (posterior surface) or the jejunum. As long as the basic principle of a safe anastomosis is considered, any technique may be successful. The bilioenteric anastomosis is performed usually as an end to side single layer anastomosis (**Figure 5**). Another important aspect is that the bilioenteric anastomosis is performed on the antimesenteric margin of the jejunum. The final reconstruction is represented by the gastrojejunostomy (or duodenojejunostomy if pylorus preserving technique was used). Most authors prefer an antecolic gastrojejunostomy performed at approximately 50 cm downstream from the biliodigestive anastomosis.

Finally, abdominal drains and nasogastric tube are placed. A feeding jejunostomy may now be performed. After a final evaluation of hemostasis, the musculo-aponeurotic plane is closed and the skin is sutured.

4.2 Palliative surgery

There are different surgical approaches in order to obtain jaundice palliation. However, these procedures are rarely performed due to the fact that they were largely replaced by endoscopic placing of stents [26].

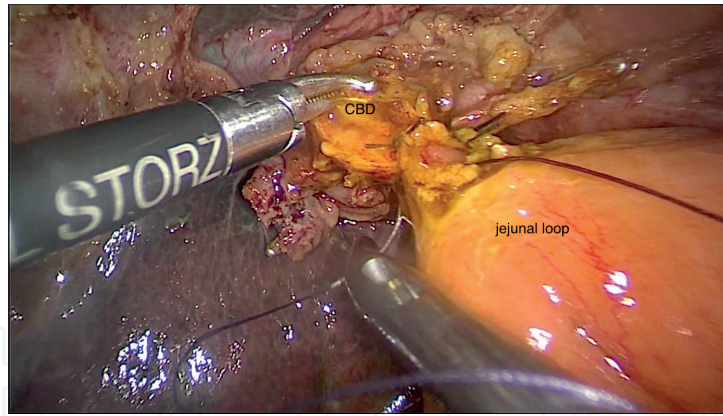


Figure 5.
Biliojeunal anastomosis; laparoscopic approach (from the personal archive of the authors). CBD = common bile duct.

In order to perform a bilioenteric bypass, the *cholecystectomy* is a mandatory step. The most important moment in performing the cholecystectomy is the dissection of Callot triangle, where the elements of the gallbladder pedicle are located. The isolation, ligation, and resection of the cystic duct and artery are performed at this level. The next step of the procedure is the dissection of the gallbladder from its hepatic fossa using the electrocautery or scissors.

4.2.1 Choledochoduodenostomy

Choledochoduodenostomy is a useful operative technique when dealing with unresectable distal cholangiocarcinoma. After performing a cholecystectomy, a supraduodenal longitudinal choledochotomy is performed and the biliary tract is explored. By performing a wide Kocher maneuver, the duodenum can be mobilized in order to obtain a tension-free anastomosis. A longitudinal duodenotomy is performed on the D1 portion of the duodenum. Two corner sutures are placed between the ends of the duodenotomy and the middle parts of the choledochotomy. Another corner suture is placed between the inferior pole of the choledochotomy and the midposterior point of the duodenotomy. Now the posterior row of sutures is applied and tied. Next, the forth corner suture is applied between the superior pole of the choledochotomy and the midanterior point of the duodenotomy. This makes it easier to perform the anterior layer of sutures. Like other biliodigestive anastomosis, single-layer sutures are recommended (**Figure 6**) [26].

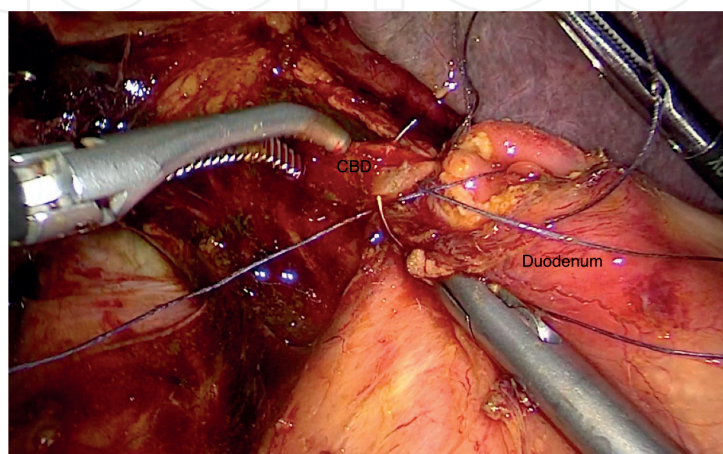


Figure 6.
Side-to-side choledochoduodenostomy for unresectable neoplasia; laparoscopic approach (from the personal archive of the authors). CBD = common bile duct.

4.2.2 Choledochojejunostomy and hepaticojejunostomy

A hepaticojejunostomy can be performed either on the left or the right hepatic ducts. This surgical intervention is performed through a right subcostal incision. Extending the incision toward the xiphoid process or with a left subcostal incision provides a good approach in order to perform the biliary-enteric bypass. By removing the gallbladder, a better access to the extrahepatic biliary ducts is gained.

In order to approach the left hepatic duct, the teres ligament is divided to obtain a better exposure of the left hemiliver. On the visceral surface of the left hemiliver, the left hepatic duct goes together with the left branch of the portal vein and they are found together into a peritoneal reflection. The best way to gain access in this area is by lowering the hilar plate.

On the other hand, the right hepatic duct can be approached by dissecting along the base of IVb segment of the liver. In this way, the biliary confluent is well visualized. As it often happens, the right hepatic duct is too short in length and small hepatic parenchyma incisions may be needed in order to visualize the intrahepatic right portal pedicle.

Once the access is gained, a 60–70 cm Roux en Y jejunal loop is prepared and delivered through a breach in the mesocolon located on the right from the middle colic pedicle. The posterior row of sutures is now performed in order to secure the duct mucosa to the jejunal mucosa. With the anterior sutures retracted upward, the posterior row is now tied up. Further, the anterior row is completed by suturing the jejunal mucosa. Finally, the anterior layer is tied and the anastomosis is complete [26].

In order to perform a choledochojejunostomy, the technique is the same, except the location on the common bile duct where the anastomosis is done.

4.2.3 Endoscopic and percutaneous drainage

If the malignant disease is too advanced and a surgical curative treatment is not suitable, biliary drainage needs to be established in order to lower the effects of hyperbilirubinemia. Percutaneous transhepatic drainage and endoscopic retrograde cholangiopancreatography are widely used for the palliation of jaundice.

Percutaneous transhepatic biliary drainage is a procedure performed under fluoroscopic or ultrasound guidance. With increased expertise and better instrumentation, the technical success rate is of ~90–95% with fewer complications rates [27].

ERCP is accepted as the preferred procedure worldwide as it is a comparably safer procedure with relatively fewer contraindications. Absolute contraindications for ERCP are as follows: pharyngeal or esophageal obstruction and active coagulopathy [28, 29]. This procedure also has some relative contraindications, such as the presence of acute pancreatitis or severe cardiopulmonary disorder. Unlike percutaneous transhepatic drainage, burden of percutaneous drainage catheter and bag is obviated, which further compounds the psychological burden of terminally ill patients. In the current scenario, in cases of distal common bile duct obstruction, ERCP is the preferred technique unless contraindicated, for which the percutaneous approach is performed [27].

5. Results

Despite the fact that biliary tract cancer is associated with a high mortality rate, patients diagnosed with distal cholangiocarcinoma have a better survival rate when compared with other periampullary cancers. The poor prognosis is due to the fact that many patients are suffering from an advanced stage at the time of surgery; this

is proved by the high incidence of lymph node involvement, perineural extension, and lymphatic and vascular invasion [30]. Significant improvement of short-term outcome has been encountered lately due to the development of surgical techniques and perioperative management. Nowadays, it is considered that the mortality rate following surgery is less than 5%, when talking about high-volume centers [30, 31]. The 5-year overall survival rate is now considered to range from 13 to 54%. The poor prognosis is due to the fact that biliary tract cancer encounters two main forms of extension: submucosal spreading and superficial spreading. Those two cause the high rate of positive margins obtained in surgery. This is why an intraoperative frozen examination of the margins is extremely important [30]. If R0 resection is performed, the overall survival rate at 5 years is considerably increased from 0–40% (R1 margins) to 27–60% (R0 margins) [30, 32]. Surgeons worldwide make efforts to improve the prognosis of this disease. Some of them claim that extended lymphadenectomy combined with the dissection of nerve plexus surrounding major blood vessels improves the outcome [30]. However, there are still a lot of controversies around this strategy. A very controversial aspect is represented by postoperative adjuvant chemotherapy. There are studies that show no significant difference in the 5-year overall survival rate between those who receive adjuvant chemotherapy (gemcitabine, paclitaxel, oxaliplatin, fluorouracil) when compared to those who have not [33]. In order to establish significant prognostic factors for distal cholangiocarcinoma, several studies were conducted. They assessed prognostic factors such as perineural extent, lymph node involvement, and the histological differentiation of the tumor. Studies that analyze the prognostic factors for 5-year overall survival rate of patients diagnosed with distal cholangiocarcinoma and submitted to surgery with curative intent conclude that the presence of R1 margins, lymph node involvement, perineural invasion, lymphatic and vascular extension, pancreatic invasion, and the presence of tumors >T3 is associated with poor prognosis. Those studies conclude that obtaining R0 margins substantially improves the outcome and is one of the most important prognostic factors [30]. In order to obtain better outcome, more accurate diagnostic modalities should be developed.

6. Future perspectives

Laparoscopic duodenopancreatectomy represents one of the most advanced abdominal interventions and it still has small widespread so far (**Figures 1–3, 5, 7**). The complexity of this procedure is due to the facts that dissection of the portal vein, lymphadenectomy, and dissection of the uncinate process are extremely high demanding. When comparing to other minimally invasive procedure, the rate of conversion is higher. This is due to the adhesions to large vascular structures and uncontrollable bleeding. Reported rates of conversion are ranging between 0 and 40%. The difference between the reported rates of conversion arises from the liberalization of intraoperative decision to convert [34]. The mean operating time is significantly longer during minimally invasive duodenopancreatectomies when compared to the open procedure. In addition to the complexity of the resection step, performing the reconstructive step is technically high demanding and of course, time-consuming. It is considered that the learning curve extends for several years, in order to obtain good outcome [35, 36]. Hybrid approach might be a solution in order to accumulate experience. In this type of surgical approach, the anastomoses are performed through a small laparotomy [33, 34]. Hybrid approach is considered to provide a safely development to a totally laparoscopic method [37]. The learning curve can be shortened by practicing simple sutures and then gastrointestinal anastomoses on the simulator or animal models. There are studies that

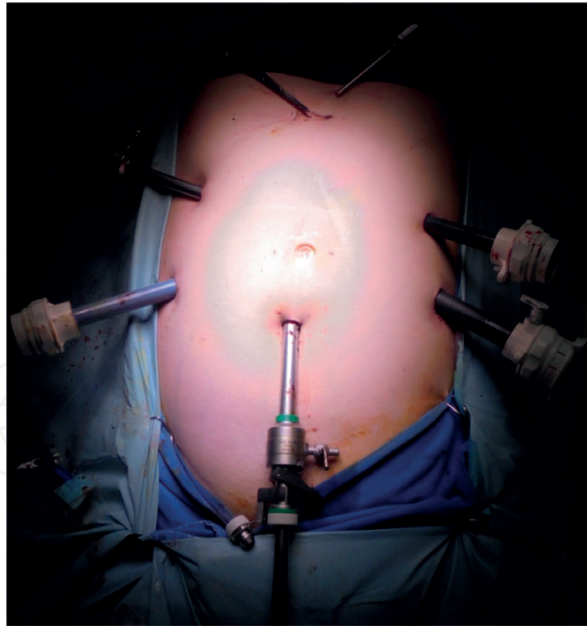


Figure 7.

Port placement for laparoscopic duodenopancreatectomy (from the personal archive of the authors).

demonstrate favorable outcomes in case of using a robotic and laparoscopic hybrid approach. In this case, the resection is performed laparoscopically and then, with robotic assistance, the surgeon performs the reconstructive step [38]. Data showed a lower blood loss in the minimally invasive approach when compared to the open technique. As a consequence, there is a lower need of transfusion, which is an objective outcome. However, there is a high risk of perioperative morbidity and mortality, the fact that limits the development of minimally invasive duodenopancreatectomy. Literature concludes that the open approach has a morbidity rate between 23 and 66% with a mortality of 3–5% in high-volume centers [39, 40]. The minimally invasive technique has a morbidity ranged between 18.2 and 87.5% with a mortality rate of 0–6.9%, comparable to the open approach. The main complication following duodenopancreatectomies is considered to be pancreatic fistula. There are comparable rates of complications (severe pancreatic fistula, delayed gastric emptying, pancreatic stump hemorrhage) when comparing the open technique with minimally invasive [41], the fact that encourages to consider the use of the minimally invasive approach as safe as the open technique. However, it is necessary that large prospective studies to be done, in order to obtain a comparison between these two techniques regarding long-term outcomes such as survival rate and quality of life [42].

The use of robotics may turn useful in promoting the application of a minimally invasive approach in major procedures in the treatment of distal cholangiocarcinoma. Robotic surgery has proven to be feasible, but its oncologic adequacy is yet to be demonstrated by larger studies.

7. Key points

- Jaundice is the most important clinical manifestation of this neoplastic disease.
- Surgical resection is the only curable alternative for patients with distal cholangiocarcinoma.
- The treatment of choice for resectable tumors is duodenopancreatectomy.

- Duodenopancreatectomy can be performed either open or laparoscopically, in high-volume centers.
- The palliation of jaundice is the cornerstone for treatment of the advanced distal cholangiocarcinoma.
- Long-term survival may be achieved only in selected patients, undergoing duodenopancreatectomy, especially in patients where R0 margins are achieved.
- Perineural extension, pancreatic invasion, and lymph nodes involvement are the main risk factors for recurrence.

Acknowledgements

Adrian Bartoş is the coordinator of this chapter.

Author details

Adrian Bartoş^{1*}, Andrei Herdean¹ and Dana Monica Bartoş^{1,2}

1 Surgical Department, “Prof. Dr. Octavian Fodor” Regional Institute of Gastroenterology and Hepatology, Cluj-Napoca, Romania

2 Anatomy Department, “Iuliu Hatieganu” University of Medicine, Cluj-Napoca, Romania

*Address all correspondence to: bartos.adi@gmail.com

IntechOpen

© 2019 The Author(s). Licensee IntechOpen. This chapter is distributed under the terms of the Creative Commons Attribution License (<http://creativecommons.org/licenses/by/3.0>), which permits unrestricted use, distribution, and reproduction in any medium, provided the original work is properly cited. 

References

- [1] Waseem D, Tushar P. Intrahepatic, perihilar and distal cholangiocarcinoma: Management and outcomes. *Annals of Hepatology*. 2017;**16**(1):133-139
- [2] Razumilava N, Gores GJ. Cholangiocarcinoma. *Lancet*. 2014;**383**(9935):2168-2179
- [3] Squadroni M, Tondulli L, Gatta G, Mosconi S, Beretta G, Labianca R. Cholangiocarcinoma. *Critical Reviews in Oncology/Hematology*. 2017;**116**:11-31
- [4] Blechacz B, Gores GJ. Cholangiocarcinoma: Advances in pathogenesis, diagnosis, and treatment. *Hepatology*. 2008;**48**(1):308-321
- [5] Bonet Beltran M, Allal AS, Gich I, Sole JM, Carrio I. Is adjuvant radiotherapy needed after curative resection of extrahepatic biliary tract cancers? A systematic review with a meta-analysis of observational studies. *Cancer Treatment Reviews*. 2012;**38**(2):111-119
- [6] DeOliveira ML, Cunningham SC, Cameron JL, Kamangar F, Winter JM, Lillemoe KD, et al. Cholangiocarcinoma: Thirty-one-year experience with 564 patients at a single institution. *Annals of Surgery*. 2007;**245**(5):755-762
- [7] Dickson PV, Behrman SW. Distal cholangiocarcinoma. *Surgical Clinics of North America*. 2014;**94**(2):325-342
- [8] Skipworth JR, Keane MG, Pereira SP. Update on the management of cholangiocarcinoma. *Digestive Diseases*. 2014;**32**(5):570-578
- [9] Cho A, Yamamoto H, Kainuma O, Muto Y, Yanagibashi H, Tonooka T, et al. Laparoscopy in the management of hilar cholangiocarcinoma. *World Journal of Gastroenterology*. 2014;**20**(41):15153-15157
- [10] Endo I, Gonen M, Yopp AC, Dalal KM, Zhou Q, Klimstra D, et al. Intrahepatic cholangiocarcinoma: Rising frequency, improved survival, and determinants of outcome after resection. *Annals of Surgery*. 2008;**248**(1):84-96
- [11] Miura F, Sano K, Amano H, Toyota N, Wada K, Yoshida M, et al. Evaluation of portal vein invasion of distal cholangiocarcinoma as borderline resectability. *Journal of Hepato-Biliary-Pancreatic Sciences*. 2015;**22**(4):294-300
- [12] Ribero D, Zimmitti G, Aloia TA, Shindoh J, Fabio F, Amisano M, et al. Preoperative cholangitis and future liver remnant volume determine the risk of liver failure in patients undergoing resection for Hilar cholangiocarcinoma. *Journal of the American College of Surgeons*. 2016;**223**(1):87-97
- [13] Qiao QL, Zhang TP, Guo JC, Zhan HX, Zhao JX, Liu YC, et al. Prognostic factors after pancreatoduodenectomy for distal bile duct cancer. *The American Surgeon*. 2011;**77**(11):1445-1448
- [14] Ito K, Ito H, Allen PJ, Gonen M, Klimstra D, D'Angelica MI, et al. Adequate lymph node assessment for extrahepatic bile duct adenocarcinoma. *Annals of Surgery*. 2010;**251**(4):675-681
- [15] Sharma A, Dwary AD, Mohanti BK, Deo SV, Pal S, Sreenivas V, et al. Best supportive care compared with chemotherapy for unresectable gall bladder cancer: A randomized controlled study. *Journal of Clinical Oncology: Official Journal of the American Society of Clinical Oncology*. 2010;**28**(30):4581-4586
- [16] Geynisman DM, Catenacci DV. Toward personalized treatment of advanced biliary tract cancers. *Discovery Medicine*. 2012;**14**(74):41-57

- [17] Czito BG, Anscher MS, Willett CG. Radiation therapy in the treatment of cholangiocarcinoma. *Oncology*. 2006;**20**(8):873-884. Discussion 86-8, 93-5
- [18] Sahai P, Kumar S. External radiotherapy and brachytherapy in the management of extrahepatic and intrahepatic cholangiocarcinoma: Available evidence. *The British Journal of Radiology*. 2017;**90**(1076):20170061
- [19] Moole H, Tathireddy H, Dharmapuri S, Moole V, Boddireddy R, Yedama P, et al. Success of photodynamic therapy in palliating patients with nonresectable cholangiocarcinoma: A systematic review and meta-analysis. *World Journal of Gastroenterology*. 2017;**23**(7):1278-1288
- [20] Lu Y, Liu L, Wu JC, Bie LK, Gong B. Efficacy and safety of photodynamic therapy for unresectable cholangiocarcinoma: A meta-analysis. *Clinics and Research in Hepatology and Gastroenterology*. 2015;**39**(6):718-724
- [21] Fuks D, Bartoli E, Delcenserie R, Yzet T, Celice P, Sabbagh C, et al. Biliary drainage, photodynamic therapy and chemotherapy for unresectable cholangiocarcinoma with jaundice. *Journal of Gastroenterology and Hepatology*. 2009;**24**(11):1745-1752
- [22] Wagner A, Wiedmann M, Tannapfel A, Mayr C, Kiesslich T, Wolkersdorfer GW, et al. Neoadjuvant down-sizing of Hilar cholangiocarcinoma with photodynamic therapy-long-term outcome of a phase II pilot study. *International Journal of Molecular Sciences*. 2015;**16**(11):26619-26628
- [23] Heedman PA, Astradsson E, Blomquist K, Sjodahl R. Palliation of malignant biliary obstruction: Adverse events are common after percutaneous transhepatic biliary drainage. *Scandinavian Journal of Surgery: Official Organ for the Finnish Surgical Society and the Scandinavian Surgical Society*. 2018;**107**(1):48-53
- [24] Shariff MI, Khan SA, Westaby D. The palliation of cholangiocarcinoma. *Current Opinion in Supportive and Palliative Care*. 2013;**7**(2):168-174
- [25] Werner J, Büchler MW. Chapter 62A: Resectional techniques: Pancreaticoduodenectomy, distal pancreatectomy, segmental pancreatectomy, total pancreatectomy, and transduodenal resection of the papilla of Vater. In: Jarnagin WR, Blumgart LH, editors. *Blumgart's Surgery of the Liver, Pancreas and Biliary Tract*. 5th ed. Philadelphia: W.B. Saunders; 2012. pp. 945-966.e3
- [26] Cho CS, MI D'A. Chapter 29: Bile duct exploration and biliary-enteric anastomosis. In: Jarnagin WR, Blumgart LH, editors. *Blumgart's Surgery of the Liver, Pancreas and Biliary Tract*. 5th ed. Philadelphia: W.B. Saunders; 2012. pp. 470-480.e1
- [27] Chandrashekhara SH, Gamanagatti S, Singh A, Bhatnagar S. Current status of percutaneous transhepatic biliary drainage in palliation of malignant obstructive jaundice: A review. *Indian Journal of Palliative Care*. 2016;**22**(4):378-387
- [28] Mohammad Alizadeh AH. Cholangitis: Diagnosis, treatment and prognosis. *Journal of Clinical and Translational Hepatology*. 2017;**5**(4):404-413
- [29] Silviera ML, Seamon MJ, Porshinsky B, Prosciak MP, Doraiswamy VA, Wang CF, et al. Complications related to endoscopic retrograde cholangiopancreatography: A comprehensive clinical review. *Journal of Gastrointestinal and Liver Diseases*. 2009;**18**(1):73-82
- [30] Zhou Y, Liu S, Wu L, Wan T. Survival after surgical resection of distal

cholangiocarcinoma: A systematic review and meta-analysis of prognostic factors. *Asian Journal of Surgery*. 2017;**40**(2):129-138

[31] Hong SM, Pawlik TM, Cho H, Aggarwal B, Goggins M, Hruban RH, et al. Depth of tumor invasion better predicts prognosis than the current American Joint Committee on Cancer T classification for distal bile duct carcinoma. *Surgery*. 2009;**146**(2):250-257

[32] Kwon HJ, Kim SG, Chun JM, Lee WK, Hwang YJ. Prognostic factors in patients with middle and distal bile duct cancers. *World Journal of Gastroenterology*. 2014;**20**(21):6658-6665

[33] Wellner UF, Shen Y, Keck T, Jin W, Xu Z. The survival outcome and prognostic factors for distal cholangiocarcinoma following surgical resection: A meta-analysis for the 5-year survival. *Surgery Today*. 2017;**47**(3):271-279

[34] Wang Y, Bergman S, Piedimonte S, Vanounou T. Bridging the gap between open and minimally invasive pancreaticoduodenectomy: The hybrid approach. *Canadian Journal of Surgery*. 2014;**57**(4):263-270

[35] Shyr B-U, Chen S-C, Shyr Y-M, Wang S-E. Learning curves for robotic pancreatic surgery- from distal pancreatectomy to pancreaticoduodenectomy. *Medicine*. 2018;**97**:45

[36] Rodríguez-Sanjuán JC, Gómez-Ruiz M, Trugeda-Carrera S, Manuel-Palazuelos C, López-Useros A, Gómez-Fleitas M. Laparoscopic and robot-assisted laparoscopic digestive surgery: Present and future directions. *World Journal of Gastroenterology*. 2016;**22**(6):1975-2004

[37] Zureikat AH, Breaux JA, Steel JL, Hughes SJ. Can laparoscopic pancreaticoduodenectomy be

safely implemented? *Journal of Gastrointestinal Surgery: Official Journal of the Society for Surgery of the Alimentary Tract*. 2011;**15**(7):1151-1157

[38] Ji W, Ding K, Kao X, He C, Li N, Li J. Robotic and laparoscopic hybrid pancreaticoduodenectomy: Surgical techniques and early outcomes. *Chinese Medical Journal*. 2014;**127**(16):3027-3029

[39] Elberm H, Ravikumar R, Sabin C, Abu Hilal M, Al-Hilli A, Aroori S, et al. Outcome after pancreaticoduodenectomy for T3 adenocarcinoma: A multivariable analysis from the UK Vascular Resection for Pancreatic Cancer Study Group. *European Journal of Surgical Oncology*. 2015;**41**(11):1500-1507

[40] de Wilde RF, Besselink MG, van der Tweel I, de Hingh IH, van Eijck CH, Dejong CH, et al. Impact of nationwide centralization of pancreaticoduodenectomy on hospital mortality. *British Journal of Surgery*. 2012;**99**(3):404-410

[41] Xiong JJ, Tan CL, Szatmary P, Huang W, Ke NW, Hu WM, et al. Meta-analysis of pancreaticogastrostomy versus pancreaticojejunostomy after pancreaticoduodenectomy. *British Journal of Surgery*. 2014;**101**(10):1196-1208

[42] Chen K, Pan Y, Liu X-L, Jiang G-Y, Wu D, Maher H, et al. Minimally invasive pancreaticoduodenectomy for perampullary disease: A comprehensive review of literature and meta-analysis of outcomes compared with open surgery. *BMC Gastroenterology*. 2017;**17**(1):120