

We are IntechOpen, the world's leading publisher of Open Access books Built by scientists, for scientists

6,900

Open access books available

185,000

International authors and editors

200M

Downloads

Our authors are among the

154

Countries delivered to

TOP 1%

most cited scientists

12.2%

Contributors from top 500 universities



WEB OF SCIENCE™

Selection of our books indexed in the Book Citation Index
in Web of Science™ Core Collection (BKCI)

Interested in publishing with us?
Contact book.department@intechopen.com

Numbers displayed above are based on latest data collected.
For more information visit www.intechopen.com



Endoscopic Management of Pancreatic Fluid Collection in Acute Pancreatitis

*Cosmas Rinaldi Adithya Lesmana,
Laurentius Adrianto Lesmana and Khek Yu Ho*

Abstract

Acute pancreatitis is an acute clinical condition where it can be manifested as mild disease or serious and life-threatening condition. There are several factors that may be responsible for this condition, such as genetic, gallstone disease, alcohol consumption, pancreatic trauma, medication, hypertriglyceridemia, autoimmune disease, and surgery. The most common manifestation of pancreatic parenchymal injury is pancreatic pseudocyst (PPC) formation, where peripancreatic fluid collection (PFCs) usually precedes this condition. Even though most of the pseudocyst can be managed conservatively, however in conditions such as infected pseudocyst or possible wall of necrosis (WON), there should be an early intervention management. Clinical evaluation and imaging studies have to be done in the beginning. Computed tomography (CT) scan or magnetic resonance imaging (MRI) are the main imaging techniques used to evaluate the characteristic of the cyst, the size, surrounding vascularity, and to assess the pancreatic duct itself with possible of fistula formation. Clinical conditions that are usually considered for early intervention management are symptomatic pseudocyst, large size of pseudocyst, presence of gastric outlet obstruction, or biliary obstruction. PFC should be evaluated as it has been classified based on type of pancreatitis, time frame, well-defined wall, and debris contained inside the cyst. Endoscopic management has replaced percutaneous and surgical approach in most of PFC cases. Nowadays, endoscopic ultrasound (EUS) has been widely used as the first-line tool for PFC drainage procedure. Pancreatic pseudocyst stenting is the most common procedure in most of the centers in the world. However, the cost, availability, and expertise are needed to be considered in clinical practice.

Keywords: endoscopic management, pancreatic fluid collections, acute pancreatitis

1. Introduction

Acute pancreatitis is one of the challenging situations in clinical practice where it can lead to a critical condition. This condition also needs to be carefully managed to prevent more complications [1]. One of the major complications is acute peripancreatic fluid collections (APFPC) and pseudocyst development [2, 3]. The clinical

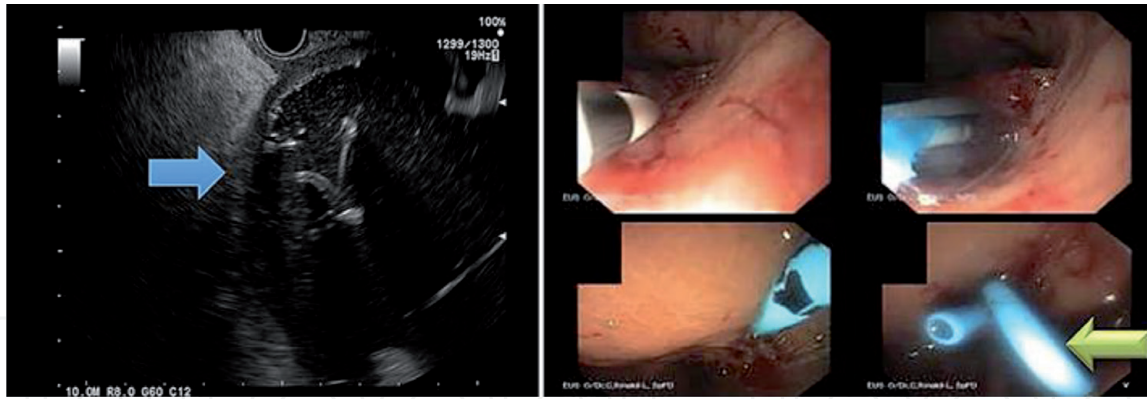


Figure 1.
Patient with infected pancreatic pseudocyst and acute pancreatitis [6].

decision for pancreatic pseudocyst or necrotic infected cyst drainage procedure is very important with regard to the patient's clinical condition and imaging evaluation. There are several well-known routes of drainage procedure of choice such as percutaneous, endoscopic, or surgical drainage [4].

Recently, development of therapeutic endoscopic ultrasound (EUS) procedure has become more popular in most of the highly experienced centers as a first-line management in pancreatic fluid collection drainage [5–7] (**Figure 1**). However, it would need a good comprehensive team work and facilities to perform this kind of procedure.

2. Acute pancreatitis and pancreatic fluid collection

Acute pancreatitis is an acute clinical condition due to sudden inflammation of the pancreas, and it is mostly caused by gallstone disease or alcohol consumption. The other risks of acute pancreatitis are endoscopic retrograde cholangiopancreatography (ERCP) procedure, some medications, trauma of the abdomen, autoimmune disease, hypertriglyceridemia, hereditary factors, abnormalities of the pancreas anatomy, infection, surgical procedure, and pancreatic tumor. Acute pancreatitis consists of two phases of disease: (1) within 1 week, where the systemic inflammation plays an important role and it can be accompanied by organ failure; and (2) more than 1 week, where local complications happened, such as acute peripancreatic fluid collections (APFPC), acute necrotic fluid collection (ANC), pancreatic pseudocyst (PPC), and walled-off necrosis (WON), either can be sterile or infected. This has been classified based on the revised Atlanta criteria. This criteria has been mainly based on time after the onset (whether it is ≤ 4 weeks or > 4 weeks from the onset of pain) and whether there is a necrosis condition through the imaging examination [7, 8]. Acute pancreatitis can be easily diagnosed based on three classic parameters, which are abdominal pain, serum amylase, and/or lipase more than three times upper limit normal, and abdominal imaging study. Abdominal ultrasound should be routinely performed in acute pancreatitis patients as gallstone disease is still the most common etiology. This issue is important to consider early cholecystectomy to prevent more complications in the pancreas [9].

On the other hand, the development of PFC can also be subdivided into early complication (APFPC and ANC) and delayed complication (PPC and WON). APFPC, which contains sterile pancreatic juice, is usually developed within 48 h in almost 50% acute pancreatitis patients, where this condition might be resolved within 2–4 weeks. In the imaging study, homogeneous fluid attenuation conforms to the retroperitoneal structures without any wall which is the hallmark.

Meanwhile, ANC can be located pancreatic, peripancreatic, or mixed. It is usually arising from the necrotic pancreas tissue or glandular and mostly it is connected to the pancreatic duct. Imaging study showed inhomogeneous without any liquefied components and wall. If the fluid collection persists, then usually it can further lead to the development of PPC. PPC is a pancreatic juice collection surrounded by the wall. The location of pseudocyst development usually is at the lesser sac. The cyst wall is formed from the fibrous or granulomatous tissue. Based on imaging studies, it is an oval-round cystic lesion with a thin-walled even though sometimes the wall can be thicker. More than 50% of PPC are usually either resolved or drained spontaneously into the stomach. The larger size of PPC can cause symptoms such as abdominal pain or rupture into the peritoneal cavity. Other related complications are secondary infection, internal bleeding, and bile duct or duodenal obstruction. WON is the transformation of pseudocyst and ANC; it is a thick cavity wall containing semi-liquid collection and necrotic debris. Based on the imaging study, there is an inhomogeneous nonliquefied component encapsulated with wall. Imaging studies are very important to differentiate each of PFC types, as it will have different management and prognosis [10, 11].

3. Endoscopic management of pancreatic fluid collection: history and development

Traditionally, percutaneous and surgical approaches are the old standard methods for PFC (PPC and WON) drainage, where the percutaneous approach can be performed easily for PPC drainage with transabdominal ultrasound-guided or computed tomography (CT) guide. Meanwhile, the surgical approach is the usually preferred method, especially for ANC or WON. It is an open approach and consists of cystogastrostomy, cystoduodenostomy, and cystojejunostomy. Laparoscopic method for PFC drainage was also increasingly reported afterward. However, looking at the high complication rate of surgery approach and possible ineffective drainage result with high recurrence rate in percutaneous approach, recently, endoscopic method has become a new alternative route and the most preference method nowadays [12].

The first report was published by Sahel et al. in 19 patients with chronic pancreatitis [13]. The complications occurred in four patients (bleeding in two patients, and two perforations). Another pioneer study by Cremer et al. also showed high success rate for endoscopic cystoduodenostomy (ECD) and 100% for endoscopic cystogastrostomy (ECG) [14]. However, both studies were performed in small sample size. Study by Weckman et al. in larger study subjects within 6 years period showed 86.1% success rate for endoscopic management in PPC patients with around 13.9% needing surgical intervention due to unsuccessful therapeutic endoscopy [15].

More studies have been conducted regarding endoscopic transpapillary stenting for pancreatic duct (PD) leak or disruption causing PPC or fistula, and also endoscopic management in WON. First, study by Catalano et al. performing endoscopic cystenterostomy in 8 of 21 PPC patients with duct strictures was successful in all cases [16]. In the recent study of transpapillary management route by Brennan et al., where it only included 30 patients with the indications of PD stenting were PPC, pancreatic ascites, pancreatic duct leak, and fistula, the follow-up success rate after PD stenting for pancreatic duct rupture was 88%, while for pseudocyst, it was 63% [17]. In the WON study, endoscopic treatment was performed in 101 patients. The therapeutic success rate was 98.02%; whereas, long-term follow-up success rate was 96.04% in patients with symptomatic WON [18].

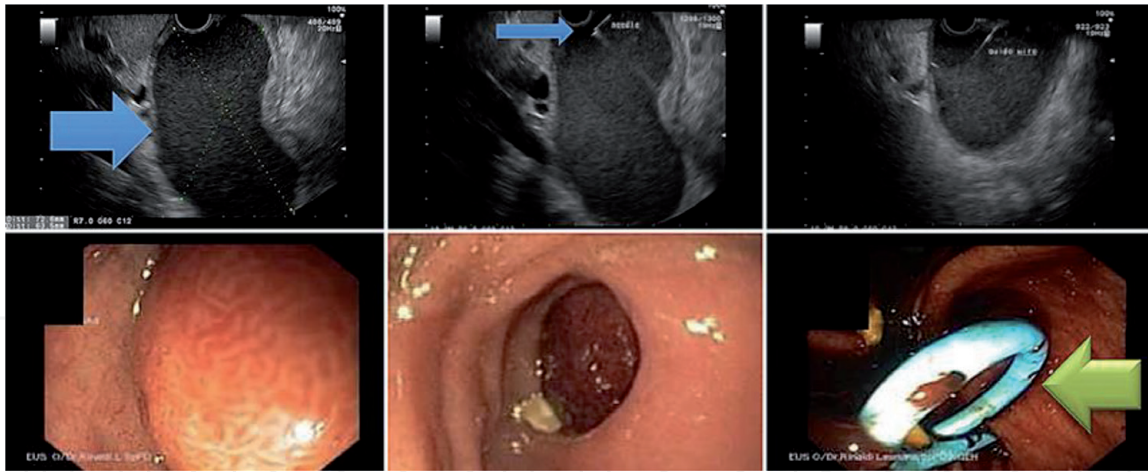


Figure 2.
Patient with pancreatic pseudocyst and gastric outlet obstruction [6].

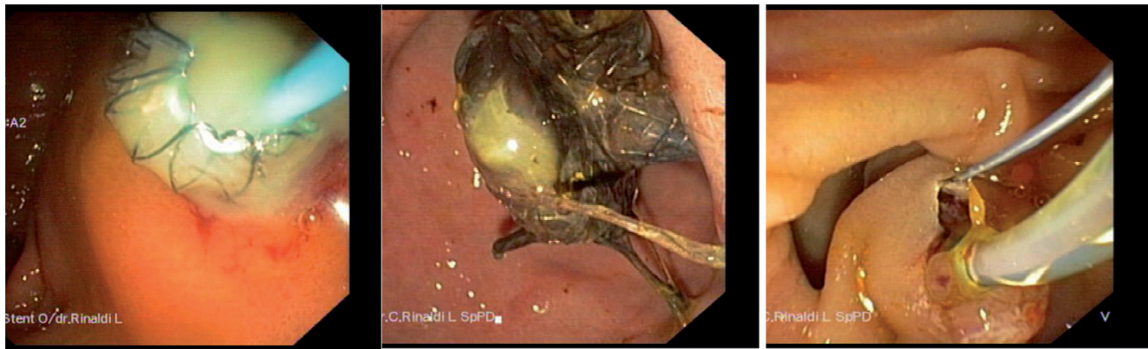

Figure 3.
Patient with infected pancreatic pseudocyst and biliary obstruction (Courtesy: Dr. Cosmas Rinaldi A. Lesmana).

The clinical decision when to intervene the PFC is usually based on comprehensive clinical and imaging evaluation. Gastric outlet obstruction or biliary obstruction needs to be managed as soon as possible (**Figure 2**). It can be recognized early through the clinical symptoms such as abdominal pain, vomiting, weight loss, early satiety, or even jaundice. Infected PPC is one of the absolute indications for drainage procedure (**Figure 3**). Imaging evaluation as well as the fluoroscopy-guided or transabdominal-guided endoscopic management is considered as an important thing, especially in non-bulging PPC [19].

Nowadays, endoscopic ultrasound (EUS) has replaced the traditional way to do the drainage procedure. Through EUS examination, it is easy to evaluate non-bulging PFC as well as other factors, such as the puncture site with large vessels avoidance, accurate fluid aspiration with the wall evaluation, and pancreatic duct connection. Defining the characteristics of each PFC type can also be easily done through EUS examination as the location and the size of the PFC, including the solid material, the wall, and the border, can be scored. It can also evaluate the bile duct under direct visualization [20].

The indication for endoscopic management is usually based on the patient's symptoms, the resolution or severity of infections, and the size of the cyst. Another consideration involves the cyst wall maturity. Usually, the right time to perform endoscopic intervention is after 4 weeks as it allowed better encapsulation. Recent systematic review, comparing percutaneous, surgical, and endoscopic methods in managing PPC, shows that endoscopic management using EUS reduced the length of hospital admission time, cost, and improved patient's quality of life [21, 22].

4. Endoscopic ultrasound-guided pancreatic fluid collection drainage: technical review

There are two options of endoscopic drainage method, which are transmural, transpapillary, or even combining these two techniques. In the pseudocyst case, endoscopic ultrasound (EUS) has been widely used for transmural drainage with previous evaluation where direct visualization of cystic lesions through the gastrointestinal (GI) lumen can be easily performed. It has become the most important tool in the management for pancreatic cyst, especially to differentiate benign from malignant condition. However, other than anatomic factor, the presence of ductal communication is also an important factor to decide which route is better to perform. In the WON case, the principle is the same; however, the fluid collection resolution after 72 h is the main consideration for more aggressive endoscopic intervention, which is known as EUS-guided transmural necrosectomy procedure. The drainage procedure can be done either with transpapillary or transmural approach. The needle puncture is performed using 19-G FNA needle. After the tip of the needle entering the cyst cavity, the needle sheath can be left inside by pulling out the needle and the guide wire was inserted through the needle sheath until it is coiled up. Then, the sheath was pulled out with maintaining the wire inside the cyst cavity. The dilatation process will further be performed either with dilator or 5 or 6-fr cystotome to make a larger fistula. Finally, the stent is inserted through the fistula track (plastic or metallic stent) [23–26].

5. Endoscopic management: metal vs. plastic stent

There are two types of stents that are usually used in the management of PPC: metal stent and double pigtail plastic stent. There have been some concerns about using the plastic stents, which are possible for re-intervention due to ineffective drainage, longer procedure time regarding the need of two plastic stents placement, or even the risk of leakage. However, some studies have shown that plastic stent success rate for PPC drainage ranges from 84 to 94%, but the success rate was found to be lower in few studies when managing WON cases [27–29]. One of the studies by Bang et al. showed that there was no difference for the treatment success between 7 and 10 Fr plastic stents, and even only one plastic stent placement when compared to more than one plastic stents. Another consideration need to be put in clinical practice is the cost, where it would be cheaper to use the plastic stent [30]. Recent meta-analysis study showed that there was a higher clinical success rate (OR 3.39, 95% CI 1.35–21.19) and lower adverse events (OR 0.37, 95% CI 0.21–0.66) in the metal stent studies. The concern is regarding adverse events, such as bleeding, perforation, and stent migration. Fully covered metallic stent (FCMS) might be considered better in bleeding prevention due to the tamponade direct effect from the stent. In the subgroup analysis, even though the success rate in the metal stent group was 98.3%, however, the success rate in the plastic stent group also more than 90%. The success rate in the plastic group was below than 90% only in the WON group, where the metal stent group has still more than 90% success rate [31]. Another development in the stent evolution, lumen apposing metal stent (LAMS) development where this stent is used not only for endoscopic drainage procedure, but also for endoscopic necrosectomy procedure. This stent has also advantage in migration prevention when compared to FCMS [32–35].

Until now, there are still debates and conflicting data with regard to the use of type of the stents. However, even though technically there is no significant difference between placing metal stent versus plastic stent, every type of case need to

be decided individually as the cost issue, stent availability, PFC type, and possible complications are still important things for clinical consideration.

6. Conclusions

Acute pancreatitis with pancreatic fluid collection (PFC) is a challenging condition in the field of gastroenterology as it would need good comprehensive clinical assessment and good timing to decide when to intervene. Transmural approach through endoscopic procedure has replaced percutaneous or surgical approach to manage pancreatic pseudocyst. The use of metal stent seemed to be superior than the plastic stent for PFC drainage, however, it would be depending on the cost, availability, and the type of PFC.

Author details

Cosmas Rinaldi Adithya Lesmana^{1,2*}, Laurentius Adrianto Lesmana¹ and Khek Yu Ho³

1 Digestive Disease and GI Oncology Center, Medistra Hospital, Jakarta, Indonesia

2 Department of Internal Medicine, Hepatobiliary Division, Dr. Cipto Mangunkusumo Hospital, Universitas Indonesia, Jakarta, Indonesia

3 Department of Medicine, National University Singapore, Singapore

*Address all correspondence to: medicaldr2001id@yahoo.com

IntechOpen

© 2019 The Author(s). Licensee IntechOpen. This chapter is distributed under the terms of the Creative Commons Attribution License (<http://creativecommons.org/licenses/by/3.0>), which permits unrestricted use, distribution, and reproduction in any medium, provided the original work is properly cited. 

References

- [1] Quinland JD. Acute pancreatitis. *American Family Physician*. 2014;**90**(9):632-639
- [2] Ballie J. Pancreatic pseudocysts (part I). *Gastrointestinal Endoscopy*. 2004;**59**:873-879
- [3] Cui ML, Kim KH, Kim HG, et al. Incidence, risk factors and clinical course of pancreatic fluid collections in acute pancreatitis. *Digestive Diseases and Sciences*. 2014;**59**:1055-1062
- [4] Holt BA, Varadarajulu S. The endoscopic management of pancreatic pseudocysts. *Gastrointestinal Endoscopy*. 2015;**81**(4):804-812
- [5] Giovannini M. What is the best endoscopic treatment for pancreatic pseudocysts? *Gastrointestinal Endoscopy*. 2007;**65**(4):620-623
- [6] Lesmana CRA, Gani RA, Hasan I, Sulaiman AS, Lesmana LA. Case Reports in Gastroenterology. Therapeutic Interventional Endoscopic Ultrasound Based on Rare Cases in Indonesia: A Single-Center Experience in Unselected patients. 2017;**11**(1):72-77
- [7] ASGE Standards of Practice committee, Jacobson BC, Baron TH, Adler DG, et al. ASGE guideline: The role of endoscopy in the diagnosis and the management of cystic lesions and inflammatory fluid collections of the pancreas. *Gastrointestinal Endoscopy*. 2005;**61**:363-370
- [8] Shah AP, Mourad MM, Bramhall SR. Acute pancreatitis: Current perspectives on diagnosis and management. *The Journal of Inflammation Research*. 2018;**11**:77-85
- [9] Banks PA, Bollen TL, Dervenis C, et al. Classification of acute pancreatitis—2012: Revision of the Atlanta classification and definitions by international consensus. *Gut*. 2013;**62**:102-111
- [10] Toouli J, Brooke-Smith M, Bassi C, et al. Guidelines for the management of acute pancreatitis. *Journal of Gastroenterology and Hepatology*. 2002;**17**:515-539
- [11] Foster BR, Jensesn KK, Bakis G, Shaaban AM, Coakley FV. Revised atlanta classification for acute pancreatitis: A pictorial essay. *RadioGraphics*. 2016;**36**:675-687
- [12] Turkvatan A, Erden A, Secil M, et al. Fluid collections associated with acute pancreatitis: A pictorial essay. *Canadian Association of Radiologists Journal*. 2014;**65**:260-266
- [13] Tyberg A, Karia K, Gabr M, et al. Management of pancreatic fluid collections: A comprehensive review of the literature. *World Journal of Gastroenterology*. 2016;**22**(7):2256-2270
- [14] Ng PY, Rasmussen DN, Vilmann P, et al. Endoscopic ultrasound-guided drainage of pancreatic pseudocysts: Medium-term assessment of outcomes and complications. *Endoscopic Ultrasound*. 2013;**2**(4):199-203
- [15] Sahel J, Bastid C, Pellat B, et al. Endoscopic cystoduodenostomy of cysts of chronic calcifying pancreatitis: A report of 20 cases. *Pancreas*. 1987;**2**:447-453
- [16] Cremer M, Deviere J, Engelhom L. Endoscopic management of cysts and pseudocysts in chronic pancreatitis: Long-term follow up after 7 years of experience. *Gastrointestinal Endoscopy*. 1989;**35**:1-9
- [17] Weckman L, Kylanpaa ML, Puolakkainen P, et al. Endoscopic treatment of pancreatic pseudocysts. *Surgical Endoscopy*. 2006;**20**:603-607. Epub: January 19, 2006

- [18] Catalano MF, Geenen JE, Schmalz MJ, et al. Treatment of pancreatic pseudocysts with ductal communication by transpapillary pancreatic duct endoprosthesis. *Gastrointestinal Endoscopy*. 1995;**42**:214-218
- [19] Brennan PM, Stefaniak T, Palmer KR, et al. Endoscopic transpapillary stenting of pancreatic duct disruption. *Digestive Surgery*. 2006;**23**:250-254
- [20] Nabi Z, Basha J, Reddy DN. Endoscopic management of pancreatic fluid collections-revisited. *World Journal of Gastroenterology*. 2017;**23**(15):2660-2672
- [21] Alali A, Mosko J, May G, Teshima C. Endoscopic ultrasound-guided management of pancreatic fluid collections: Update and review of the literature. *Clinical Endoscopy*. 2017;**50**:117-125
- [22] Jagielski M, Smoczynski M, Jablonska A, Adrych K. The development of endoscopic techniques for treatment of walled-off pancreatic necrosis: A single-center experience. *Gastroenterology Research and Practice*. 2018:8149410. DOI: 10.1155/2018/8149410
- [23] Dupuis CS, Baptista V, Whalen G, et al. Diagnosis and management of acute pancreatitis and its complications. *Gastrointestinal Intervention*. 2013;**2**:36-46
- [24] Teoh AYB, Dhir V, Jin ZD, et al. Systematic review comparing endoscopic, percutaneous and surgical pancreatic pseudocyst drainage. *The World Journal of Gastrointestinal Endoscopy*. 2016;**8**(6):310-318
- [25] Law R, Baron TH. Endoscopic management of pancreatic pseudocysts and necrosis. *Expert Review of Gastroenterology & Hepatology*. Feb 2014;**9**(2):167-175. DOI: 10.1586/17474124.2014.943186
- [26] Saftoiu A, Vilmann A, Vilmann P. Endoscopic ultrasound-guided drainage of pancreatic pseudocysts. *Endoscopy Ultrasound*. 2015;**4**:319-323
- [27] Yusuf TE, Baron TH. Endoscopic transmural drainage of pancreatic pseudocysts: Results of a national and an international survey of ASGE members. *Gastrointestinal Endoscopy*. 2006;**63**:223-227
- [28] Samuelson AL, Shah RJ. Endoscopic management of pancreatic pseudocysts. *Gastroenterology Clinics of North America*. 2012;**41**:47-62. DOI: 10.1016/j.gtc.2011.12.007
- [29] Muthusamy VR, Chandrasekhara V, Acosta RD, et al. The role of endoscopy in the diagnosis and treatment of inflammatory pancreatic fluid collections. *Gastrointestinal Endoscopy*. 2016;**83**(3):481-488
- [30] Yasuda I. Endoscopic necrosectomy for infected pancreatic necrosis. *Gastrointestinal Intervention*. 2012;**1**:36-39
- [31] Bang JY, Varadarajulu S. Metal versus plastic stent for transmural drainage of pancreatic fluid collections. *Clinical Endoscopy*. 2013;**46**:500-502
- [32] Yoon SB, Lee IS, Choi MG. Metal versus plastic stents for drainage of pancreatic fluid collection: A meta-analysis. *United European Gastroenterology Journal*. 2018;**6**(5):729-738
- [33] Bugiantella W, Rondelli F, Boni M, et al. Necrotizing pancreatitis: A review of the interventions. *The International Journal of Surgery*. 2016;**28**:S163-S171

[34] Jurgensen C, Arlt A, Naser F, et al. Endoscopic ultrasound criteria to predict the need for intervention in pancreatic necrosis. *BMC Gastroenterology*. 2012;12:48

[35] Antillon MR, Bechtold ML, Bartalos CR, et al. Transgastric endoscopic necrosectomy with temporary metallic esophageal stent placement for the treatment of infected pancreatic necrosis (with video). *Gastrointestinal Endoscopy*. 2009;69(1):178-180