

# We are IntechOpen, the world's leading publisher of Open Access books Built by scientists, for scientists

6,900

Open access books available

185,000

International authors and editors

200M

Downloads

Our authors are among the

154

Countries delivered to

TOP 1%

most cited scientists

12.2%

Contributors from top 500 universities



WEB OF SCIENCE™

Selection of our books indexed in the Book Citation Index  
in Web of Science™ Core Collection (BKCI)

Interested in publishing with us?  
Contact [book.department@intechopen.com](mailto:book.department@intechopen.com)

Numbers displayed above are based on latest data collected.  
For more information visit [www.intechopen.com](http://www.intechopen.com)



# Scarring After Burn Injury

*Lindsay Damkat-Thomas and John Edward Greenwood*

## Abstract

Burn injury is a trauma that has variable scarring outcomes dependent on both the size and the depth of the burn. This chapter will discuss the pathophysiology of wound healing by both primary and secondary intention and its applicability to burn wounds. The importance of accurate assessment of burn depth and its impact on the primary treatment and subsequent scar outcome will be explored. Special anatomic areas such as the face, hands and neck will be highlighted. Skin grafting and skin substitutes as treatment options will be reviewed. Improvements in burn care have enabled people to survive larger burns that may once have proved fatal. The emphasis of treatment, once healing has been achieved, is now focused upon rehabilitation and scar management. Scar management strategies including pressure garments and silicone therapy are highlighted along with secondary scar revision strategies.

**Keywords:** burn scars, burn surgeon, extensive deep burn injury

## 1. Introduction

Scarring in the aftermath of burn injury is generally perceived (at least by the media and the general public) to be universally both horribly disfiguring and permanently disabling [1]. In reality, the majority of the outcomes that we achieve as burn surgeons are both functionally and aesthetically excellent. Poor outcomes do occur; however these almost exclusively follow the deepest and most extensive burn injuries. The outcome picture is complicated somewhat because certain burn aetiologies are destined to proffer poorer outcomes. One example is the injuries caused by high-voltage-driven electrical current conduction. Such insult is often associated with major limb amputations, which markedly diminish outcome, and this might be expected [2, 3]. However, even when comparing the scarring outcome from an identical aetiology, such as flame burns, the skin injury sustained in a house fire and affecting a high proportion of the total body surface area often generates significantly poorer outcomes than flame injuries from, for example, localised clothing ignition from being too close to a naked flame. This is despite the skin being damaged to the same depth in both scenarios. It could be surmised that the differences in the environment of the burn injury might result in additional injuries (such as smoke inhalation [4]), which will affect treatment course and even survival. However, if all other parameters are negated, extensive burns are associated with poorer scarring outcomes than small burns of the same depth caused by the same agent [5, 6]. The focus of this chapter is to elucidate why this is the case and to suggest strategies to improve scarring outcome, function and appearance in extensive deep burn injury.

## 2. Wound healing: primary versus secondary healing

Before discussing burn injuries, the essential tenets of the process of wound healing must be understood by the reader in order to appreciate the strategies employed in managing burn injuries [7]. The essential components of wound healing occur in the dermis. This mesodermal derivative is incapable of regenerating molecular structure and undergoes instead a process of repair driven by the simultaneous deposition of (predominantly) Type III collagen by fibroblasts, and small blood vessel angiogenesis, succeeding an inflammatory response secondary to vascular fluid and protein leakage into the interstitium surrounding the wound and the attraction of circulating polymorphonuclear neutrophils, lymphocytes and monocytes [8]. The dermal repair provides sufficient structure for re-epithelialisation from the approximated wound edges. The epidermis is ectodermal in origin, cellular in composition and capable of regeneration.

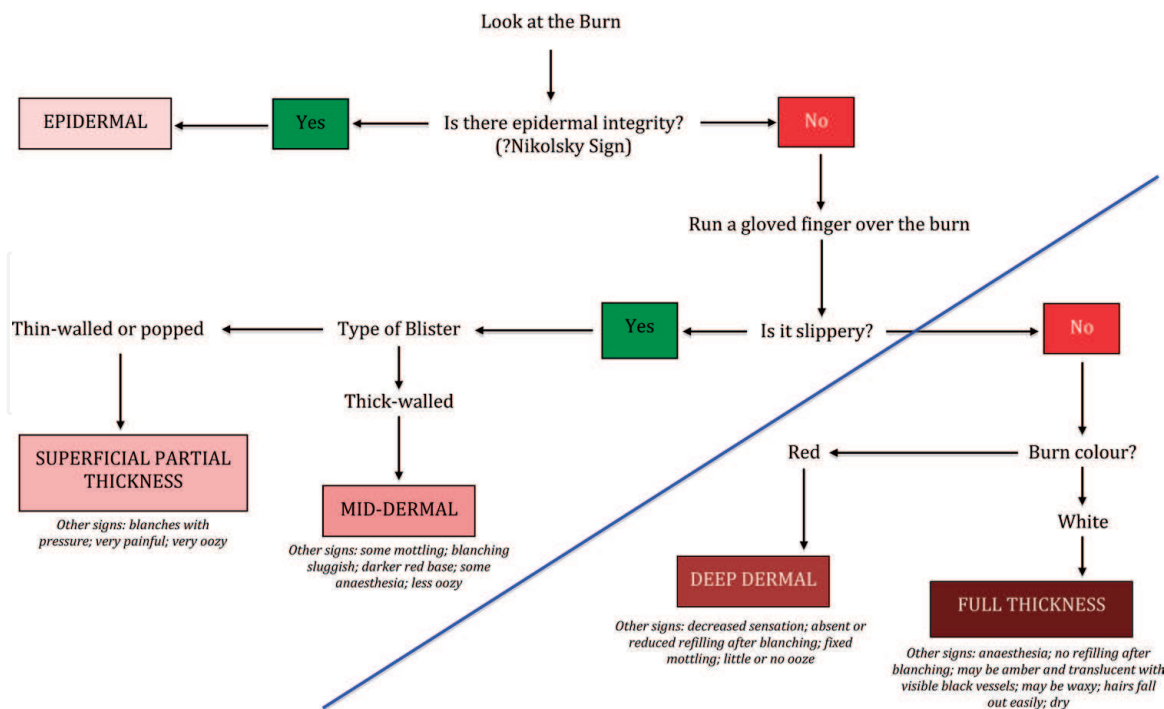
In *primary wound healing*, where the wound edges are in close proximity, haemostasis is followed by inflammation and cellular wound debridement, and the dermal fibroblasts rapidly produce collagen to bridge the ‘narrow’ gap and restore resistance of the skin to external forces [9]. The ratio of collagens in the resulting repair (Type I:III = 1:3) is different than in uninjured skin (Type I:III = 3:1). Type III collagen is not cross-linked and thus has a greater volume than Type I collagen, so the scar is raised above the surrounding skin, and the proliferation of angiogenetic vessels gives it a red appearance. As the scar undergoes maturation, the normal collagen ratio is re-established, the scar volume decreases, and the scar becomes flat, or even depressed, and vascular involution sees it change colour, becoming pale, and resulting in the typical final appearance of the incisional scar.

In *secondary intention healing*, there is considerable tissue loss, and the wound edges are very far apart. Delayed wound closure results. A prolonged inflammatory phase overlaps with excessive deposition of collagen and glycosaminoglycans by dermal fibroblasts and circulating stem cells, accompanied by heavy vascular proliferation (granulation tissue formation) [10]. Polymorphonuclear leukocytes are present to phagocytose bacteria. Since edge epithelialisation can extend only about 5 mm across the wound, myofibroblast differentiation occurs, and these cells act to contract the wound edges to reduce the size in the wound bed to facilitate re-epithelialisation. This results in contracture and problematic scarring [11].

## 3. The importance of the depth of burn injury

In real terms, there are only two burn ‘depths’ (**Figure 1**). Most of the burn injuries seen for emergency assessment and treatment are, with optimal support and good wound management, superficial enough to heal spontaneously, quickly and with an excellent functional and cosmetic result. These are burns individually classified as epidermal, superficial partial thickness and mid-dermal, even though the treatment priorities for all are the same—the *prevention of infection* (which can deepen the injury) and the *control of pain* (which facilitates dressing changes, compliance with therapy and mobilisation and hastens discharge) [12, 13]. Then there are those burns that are sufficiently deep to undergo prolonged healing by *secondary intention* (granulation tissue formation and wound contraction), often complicated by recurrent episodes of wound infection, resulting in ‘pathological’ scarring that

PROTOCOL FOR BURN DEPTH ASSESSMENT



**Figure 1.** Flow chart indicating burn depth: the blue diagonal line represents the boundary between those burns with the ability to heal spontaneously (above the line) and those that will require surgical excision and reconstruction to facilitate healing (below the line) [12]. This method must be used within 24–36 h post-injury since burn wound exudation is required for depth determination.

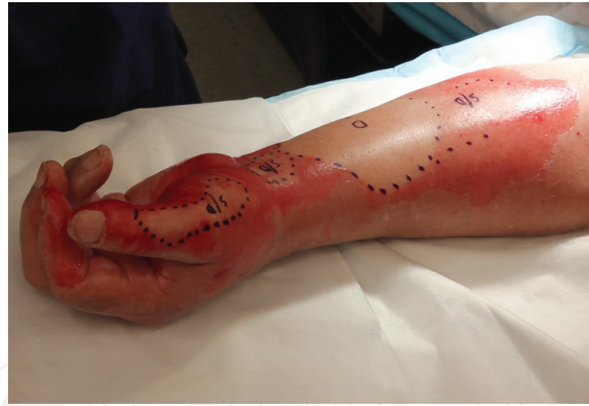reduces, impairs or abolishes function and is hypertrophic, dysaesthetic and often symptomatic (causing itching and pain). It is this second group that contains those burns described clinically as ‘deep dermal’ and ‘full thickness’. The treatment priority in these burns is to *abort the process of secondary intention healing and replace it, as closely as possible with primary intention healing*.

3.1 Spontaneously healing burns

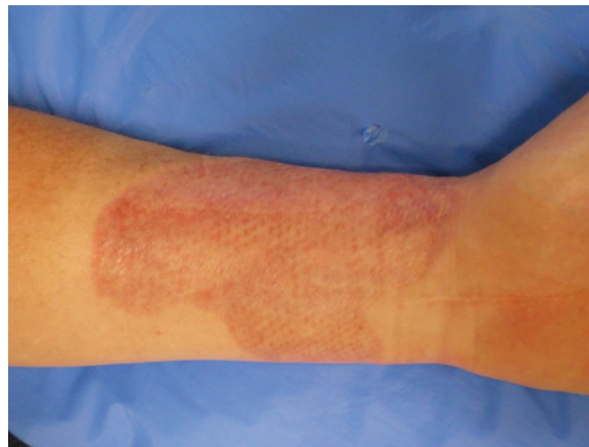For the purposes of this chapter, it is enough to understand that those burns in that spontaneously healing group are sufficiently superficial that there is a volume of good viable residual dermal tissue in the burn bed as well as the survival of multiple nests of epidermal stem cells (keratinocyte progenitor cells) located in the invaginated sheathes of the adnexal structures (hair follicles, sweat glands and sebaceous glands) [14, 15]. These cells can differentiate into keratinocytes, proliferate and migrate across the viable dermis to effect rapid re-epithelialisation. The wound-healing phase of inflammation is thus curtailed (since re-epithelialisation stops further evaporative water loss from the wound surface, signalling that wound healing is complete) and the outcomes excellent, with expedited scar maturation leading to an almost invisible repair after a few months for the majority of patients. **Figure 2** is a photograph of a mixed depth arm burn.

However, in common with all wounds, the phenotype of individual patients can proffer a predilection for substandard scarring, despite appropriate initial burn management. Individuals with a history of hypertrophic or keloid scarring, autoimmune or immunocompromised disorders and collagen or healing impairments may progress to suboptimal scarring [16]. It is for this reason that burn services have





**Figure 2.**  
*Illustrating burn depth: D is deep dermal, S/D superficial/deep junction. The S/D areas have a variable healing time that is dependent on patient and operative factors.*



**Figure 3.**  
*Meshed split skin graft to forearm 6 weeks post-grafting and demonstrating good healing.*

been an early adopter of the multidisciplinary approach, with an emphasis on scar management by occupational therapists and physiotherapists, once wound healing has been achieved [17]. Scar modulation techniques include pressure garments, topical silicone materials, massage, moisturising and steroid injection and will be further discussed in this chapter.

### 3.2 Deep dermal and full-thickness burns

A burn that is significantly deep enough to lack the capacity to heal quickly must undergo prolonged healing by secondary intention and result in pathological scarring [18], determined by a prolonged inflammatory phase and an abnormal proliferative phase. The resultant granulation of the wound bed followed by migration of myofibroblasts and contraction results in unstable scars. The epidermis will only bridge 5 mm across a wound; therefore contraction is inevitable. Unstable and contracted scars are particularly problematic. Contracture across joints will result in reduced movement and function. Contractures of the skin of the head and neck can risk vision (via ectropion and corneal exposure, desiccation and ulceration) and ability to feed (microstomia and lower lip contractures). The microtrauma that consistently causes fissures in the epidermis of the pathological scar can result in recurrent episodes of infection, further inflammation and thus further scarring.

Since the natural history of secondary intention healing of deep burns results in suboptimal scarring, the goal of burn surgery is to abort this process in favour of early physiological wound closure and healing, followed by scar management and rehabilitation, in order to achieve the best functional outcome [19]. The traditional mainstay of this process is the split skin graft, harvested from non-burned skin, which may be meshed to different ratios to enable wider wound coverage. **Figure 3** shows a meshed SSG on the forearm 6 weeks following excision and grafting.

If early physiological closure is our goal, the importance of early and accurate assessment of burn depth is vital. Identification of deeper burn and initiation of early surgical intervention significantly improve function, aesthetic appearance and return for the patient to normal daily activity.

#### 4. Size of the burn

Information regarding burn depth is complimented by knowledge of the size (surface area) of the burn. This is estimated as a percentage of the total body surface area injured (%TBSA) and is an essential factor in determining scar outcome. A small area of full-thickness burn can be reliably treated with early excision and immediate skin grafting. The inflammatory reaction to the burn is localised to the affected area; donor site for the split skin graft can be reliably taken from a non-cosmetic area. Large donor site availability even gives us options for better 'colour-matching' our skin graft! Early scar therapy can begin once the graft has taken and is robust.

However, as burn size increases, the challenges of treatment increase accordingly. Three burn-area percentages are considered important for burn surgeons: 20, 50 and 80% TBSA. At 20% TBSA, intravenous fluid resuscitation is routinely initiated, and the effect of the burn inflammatory response ceases to be localised to the burn area and has systemic consequences. The resultant fluid shifts and loss from the circulation are thus markedly more significant and, if untreated, result in burn shock with cardiac and renal consequences [20, 21]. At 50% TBSA, the burn area usually exceeds the available donor site area (since we do not harvest grafts from the unburned face, neck, palms of hands or soles of feet). Strategies for wound closure become important. At burn sizes just in excess of 50% TBSA, this might merely involve skin graft meshing at a higher ratio (say 1:3, rather than 1:1.5). At greater burn sizes, serial grafting may be necessary and should be planned to heal pivotal areas first (hands, face, neck, major joints, etc.). Additionally, dermal temporising materials are purchased (at great financial cost), and cultured skin equivalents (usually simply epidermal cells, keratinocytes; but occasionally composite cultured tissues) are prepared by those services capable of such technology. Basically, to facilitate skin closure for burns above 50% TBSA, almost all of the unburned skin must be harvested, often repeatedly. Since the dermal component of the skin graft donor site cannot undergo regeneration (and donor sites therefore being progressively 'thinner' after each graft), we tend to take thinner split skin grafts (i.e. with less dermal component) to allow a greater number of graft harvests. The combination of being thinner and more widely meshed reduces functional and aesthetic outcome because such grafts contract more, and more rapidly, than thicker, less/unmeshed graft. Thus, the techniques involved guarantee that the patient with the biggest burn who really needs the best possible outcome to regain important components of their pre-injury existence survives with the poorest functional, aesthetic and symptomatic outcome possible and illustrates why skin burns of the same depth demonstrate poorer scarring outcomes as burn surface area increases. This is further complicated by the fact that these patients are at higher risk of multi-organ dysfunction [21].

Finally, full-thickness burns  $\geq 80\%$  TBSA in adults often prove fatal. These overwhelming skin injuries leave very little or no unburned areas to allow even serial wound repair and are frequently accompanied by smoke inhalation and other co-injuries. Such injuries are classified as unsurvivable in the majority of burn units [22–24], receiving palliative, comfort care only prior to death. For patients who do survive these devastating injuries, long-term scarring issues are daunting, and return to useful function is extremely challenging.

## 5. Special anatomical areas of consideration

In addition to burn depth and size, burns (and subsequently scarring) to certain ‘special’ areas of the body have the potential to be not only functionally disabling but also psychosocially disastrous, requiring immediate or early reconstruction.

### 5.1 Face, neck and hands

The face, neck and hands are areas of extreme functional and aesthetic importance. If reconstruction requires grafting, the best functional and cosmetic outcomes are generated by thicker, unmeshed (sheet) split skin grafts. In the patient with significant burns, this requires a large proportion of the available donor sites to cover relatively small surface area defects, whilst bigger areas are left un-grafted. Protecting the ocular globes and ensuring oral competence are important, but reconstruction of the eyelids and lips is challenging. In the non-burn, or small isolated burn situation, small full-thickness grafts or flaps are often used for such reconstructions, resources sadly lacking in the major burn patient. It is thus crucial during the management of facial burns to identify those areas capable of healing spontaneously, bearing in mind that the deeper adnexal structures in facial skin often allow even burns which appear deep to heal without intervention. The best course of action is often to allow the face to heal spontaneously as much as possible and then plan appropriate reconstruction for scarred areas [25, 26]. The neck is prioritised for early grafting not only for function but also to allow for tracheostomy placement as severely burned patients may require prolonged ICU stay and ventilation. Full-thickness burns on the dorsal aspect of the hands are grafted to allow early mobilisation and return to function, and early intervention by occupational and physiotherapists will improve outcome [27]. A good result for the hand dorsum is important since these scars are constantly in the field of vision and poor results are associated with post-injury depression. The glabrous skin on the palm and areas of partial thickness burn are routinely allowed a ‘trial of life’ to allow preservation of this highly specialised skin [28].

### 5.2 Joints

Split thickness skin graft heal with a variable degree of secondary contraction dependant on their thickness. When a graft is placed over a joint, in particular the elbow and knee, the effect of contracture is reduced range of movement and scar instability. This contracture is much less significant than if the burn had been left to heal by secondary intention, but subsequent scar management requires intensive occupational therapy and physiotherapy to regain and maintain range of motion. Contractures are more likely to occur in the more severe burns, those caused by flame and those in children and females, and burns affecting the neck skin (due to the presence of the platysma) and the upper limb. The prevalence at discharge has been reported as 38–54% [18].

## 6. Scarring issues peculiar to burns

Burn healing can result in hypertrophic scarring, with functional disability and debilitating symptoms including dysaesthesia, pain and itch. It is estimated that up to 70% of burn patients will have some evidence of scar hypertrophy [29].

In addition to optimal surgical management, scar modulation measures include reducing tension across the scar, the provision of taping, hydration and ultraviolet (UV) protection of early scar tissue. Silicone sheeting, or gel, is universally considered as the first-line prophylactic and treatment option for hypertrophic or keloid scars. The efficacy and safety of this gold-standard, non-invasive therapy have been demonstrated in many clinical studies [30]. Hypertrophy is managed by aggressive scar modulation including pressure garments, silicone therapy and moisturising and massage. These interventions are all proven to be beneficial although the exact mechanisms remain to be elucidated [31]. Pressure garments may be indicated for more widespread scarring associated with burn. Both pressure garments and silicone therapy can be referred to as scar modulation. Massage and moisturising are often described as 'softening' scars, most likely due to the reorientation of collagen fibres. An ideal moisturiser should be one that is conducive to scar maturation, is non- or minimally irritant, prevents skin drying, minimises trans-epidermal water loss and has no negative effect on barrier function [32].

The symptomatic manifestations of suboptimal scarring are particularly difficult to manage, particularly pain and itch, which are often interlinked and not uncommon [33]. Intractable itch is challenging as the symptoms are subjective and the treatment is multimodal with no 'magic bullet' to prevent or ameliorate it.

Pain control and analgesia is vitally important, particularly during dressing changes, and pharmacological management facilitated by experts in pain medicine is essential. Pain control is also essential in order to deliver effective rehabilitation.

Newer therapies, such as music therapy and virtual reality distraction, are useful adjuncts to clinical psychology input which provides insight into a patient's reaction to and ability to cope with pain [34, 35].

## 7. Shifting the paradigm

The case for early total excision has been demonstrated in the literature [36, 37], and temporary wound closure is necessary due to lack of donor sites; it is in this area that skin substitutes have been developed to facilitate wound coverage. Cadaver allograft skin has been used extensively as a 'passive' temporiser (holding the wound bed without improving its quality), but access to, and availability of, this resource are highly variable [38].

The dermal matrix strategy sought to redress some of these issues [39]. Scaffolds of varying composition have been employed as 'active' temporisers, allowing autologous tissue ingrowth to form a 'neo-dermis' which improves the wound bed for subsequent definitive closure. Such dermal matrices have historically been a combination of synthetic and biological materials (e.g. Integra<sup>®</sup> Dermal Regeneration Template consists of a network of cross-linked, bovine Type I collagen supported by shark fin-derived chondroitin-6-sulphate glycosaminoglycan (GAG), physiologically closed with a bonded silicone pseudo-epidermis) [40]. The biological aspect can cause issues as burn patients are frequently immunocompromised and rapidly become bacterially colonised, and these biological components have neither intrinsic antimicrobial properties nor are sufficiently rapidly neovascularised to be afforded the innate immune protection provided by a blood supply. As a result, they may be susceptible to infection [41]. The production



of these materials is also complex and time-consuming, making such materials costly. However, the use of Integra<sup>®</sup> and similar materials has been pivotal in saving life and improving outcome over several decades [40].

Since the scaffold supports ingrowth into the spaces within it, it can be argued that it can be composed of any biodegradable material as long as it is biocompatible, bio-tolerated and safe (not cytotoxic, carcinogenic or teratogenic). The development of a completely synthetic biodegradable temporising matrix (BTM) developed from a biodegradable polyurethane is proof in point. BTM is implanted into the wound created after burn excision and integrates by facilitating fibroblast invasion, collagen deposition and neovascular ingrowth to also form a neo-dermal analogue [42–45]. This takes between 3 and 9 weeks, dependant on the quality of the wound bed. The bonded, non-biodegradable polyurethane outer ‘seal’ (or pseudo-epidermis, since it prevents evaporative water loss) ensures the wound is physiologically ‘closed’.

The integration period allows for initial stabilisation and improvement in physiological status prior to administering insults such as skin graft harvesting. In all cases, the patient is off the ICU before skin grafting commences. The improved neo-dermal wound bed receives graft more readily, with negligible graft loss, and with a significantly reduced mesh pattern where meshed graft has been employed [46–48]. This phenomenon has also been observed with collagen-based matrices [40].

The aim of burn reconstruction, in common with all aspects of plastic surgery, is to replace ‘like with like’, and, as such, the standard treatment of excised burns has been the split skin graft (despite the fact that the autograft is a long way from replacing what has been lost!). The major hindrance to this approach is the lack of donor site, the necessity to serially re-harvest donor sites and the resultant suboptimal scarring from using thin, widely meshed autograft. The future of burn surgery lies in creating composite tissue from the patients’ own skin cells, or stem cell progenitors, as a means to abolish the need for extensive donor sites [49]. The preparation of composite tissues takes several weeks, and thus the use of ‘active’ temporising skin substitutes is a fundamental first step.

Cultured skin, like autograft, has the advantage of being ‘self’ and thus accepted immunologically by the patient, as long as the carrier for the cell culture is immunologically inert [50].

## 8. Late scar management

Scars can take up to 24 months to mature fully. This is a window during which scar modulation can be effective and should persist in some form throughout this period. However, if a scar is significantly problematic (in terms of function, aesthetics or intolerable symptoms), early surgical scar revision may be necessary.

Scar revision can be broadly divided into three groups: scar resurfacing, scar excision or scar lengthening/reorientation. Scar resurfacing modalities include dermabrasion, microneedling and laser therapy. Depending on scar size, its excision can be followed by direct closure, split or full-thickness skin grafting, local flaps, free tissue transfer or a combination of dermal matrix and graft. Scar lengthening often involves incising the scar and reorientating the scar banding, usually by geometrically designed local flaps. The main reasons for performing scar revision are to resurface unstable scarring, improve movement at joints or to improve cosmesis [51].

However, it is the senior author’s opinion that the requirement for secondary scar revision is lessened if the appropriate primary reconstruction is performed in a timely manner combined with early adjunctive scar management therapy.

## 9. Conclusion

In summary, the important tenets for the optimal management of burn scarring include:

- Accurate burn depth and burn size assessment
- Immediate/early burn eschar excision and rapid wound closure with either immediate skin grafting or staged with temporising skin substitutes plus skin grafting and/or cultured skin
- Peculiar consideration for burns affecting the special areas: face and neck, hands and joints
- Immediate scar management and mobilisation utilising therapists
- Later scar management including resurfacing and excision.

## Conflict of interest

Professor John Greenwood would like to disclose that he holds shares in PolyNovo Biomaterials Pty Ltd. (the manufacturer of the NovoSorb™ foam and BTM™ device).

Dr. Lindsay Damkat-Thomas has no conflict of interest to declare.

## Author details

Lindsay Damkat-Thomas\* and John Edward Greenwood  
Adult Burn Centre, Royal Adelaide Hospital, Adelaide, Australia

\*Address all correspondence to: [ldamkat@gmail.com](mailto:ldamkat@gmail.com)

## IntechOpen

© 2019 The Author(s). Licensee IntechOpen. This chapter is distributed under the terms of the Creative Commons Attribution License (<http://creativecommons.org/licenses/by/3.0>), which permits unrestricted use, distribution, and reproduction in any medium, provided the original work is properly cited. 

## References

- [1] The experience of life after burn injury: A new bodily awareness. *Journal of Advanced Nursing*. 2008;**64**(3):278-286
- [2] Gille J, Schmidt T, Dragu A, Emich D, Hilbert-Carius P, Kremer T, et al. Electrical injury—A dual center analysis of patient characteristics, therapeutic specifics and outcome predictors. *Scandinavian Journal of Trauma, Resuscitation and Emergency Medicine*. 2018;**26**(1):43
- [3] Shih JG, Shahrokhi S, Jeschke MG. Review of adult electrical burn injury outcomes worldwide: An analysis of low-voltage vs high-voltage electrical injury. *Journal of Burn Care & Research*. 2017;**38**(1):e293-e298
- [4] Toon MH, Maybauer MO, Greenwood JE, Maybauer DM, Fraser JF. Management of acute smoke inhalation injury. *Critical Care and Resuscitation*. 2010;**12**(1):53-61
- [5] Tan Chor Lip H, Tan JH, Thomas M, Imran FH, Azmah Tuan Mat TN. Survival analysis and mortality predictors of hospitalized severe burn victims in a Malaysian burns intensive care unit. *Burns Trauma*. 2019;**7**:3
- [6] Friedstat JS, Ryan CM, Gibran N. Outcome metrics after burn injury: From patient-reported outcome measures to value-based health care. *Clinics in Plastic Surgery*. 2017;**44**(4):911-915. DOI: 10.1016/j.cps.2017.05.023
- [7] Hawkins HK, Pereira CT. Pathophysiology of the burn scar. In: *Total Burn Care*. 3rd ed. Philadelphia, Pennsylvania, USA: Elsevier; 2007. pp. 608-617. ISBN: 978-1-4160-3274-8
- [8] Clark RA. Basics of cutaneous wound repair. *The Journal of Dermatologic Surgery and Oncology*. 1993;**19**:693-706
- [9] Ross R, Odland G. Human wound repair. II Inflammatory cells, epithelial-mesenchymal interrelations, and fibrogenesis. *The Journal of Cell Biology*. 1968;**39**:152-168
- [10] Clark RA. Biology of dermal wound repair. *Dermatologic Clinics*. 1993;**11**:647-666
- [11] Gabbiani D, Ryan GD, Majino G. Presence of modified fibroblasts in granulation tissue and their possible role in wound contraction. *Experientia*. 1971;**27**:549-550
- [12] Greenwood JE, Kavanagh S, Mackie P. Revisiting protocols for burn injury management. *International Journal of Care Pathways*. 2010;**14**:88-95
- [13] Greenwood JE, Clausen J, Kavanagh S. Experience with biobrane: Uses and caveats for success. *Eplasty*. 2009;**9**:243-255
- [14] Stenn KS, Depalma L. In: RAF C, editor. *Re-epithelialization, The Molecular and Cellular Biology of Wound Repair*. New York: Plenum; 1996. pp. 321-335
- [15] Daly TJ. The repair phase of wound healing—Re-epithelialization and contraction. In: Kloth LC, McCullough J, Feedar JS, EDS Wound Healing. Philadelphia: FA Davies; 1990. pp. 14-30
- [16] Burd A, Huang L. Hypertrophic response and keloid diathesis: Two very different forms of scar. *Plastic and Reconstructive Surgery*. 2005;**116**:150e-157e
- [17] Herndon DN, Bleakley PE. Team work for total burn care. In: *Total Burn Care*. 3rd ed. Philadelphia, Pennsylvania, USA: Elsevier; 2007. pp. 9-13. ISBN: 978-1-4160-3274-8

- [18] Oosterwijk AM, Mouton LJ, Schouten H, Disseldorp LM, van der Schans CP, Nieuwenhuis MK. Prevalence of scar contractures after burn: A systematic review. *Burns*. 2017;**43**(1):41-49
- [19] Richard R, Santos-Lozada AR, Dewey WS, Chung KK. Profile of patients without burn scar contracture development. *Journal of Burn Care & Research*. 2017;**38**(1):e62-e69
- [20] Serio-Melvin ML, Salinas J, Chung KK, Collins C, Graybill JC, Harrington DT, et al. Burn shock and resuscitation: Proceedings of a symposium conducted at the meeting of the American Burn Association, Chicago, IL, 21 April 2015. *Journal of Burn Care & Research*. 2017;**38**(1):e423-e431
- [21] Rae L, Fidler P, Gibran N. The physiologic basis of burn shock and the need for aggressive fluid resuscitation. *Critical Care Clinics*. 2016;**32**(4):491-505
- [22] J Partain NS, Subramanian M, Hodgman EI, Isbell CL, Wolf SE, Arnoldo BD, et al. End-of-life care after geriatric burns at a verified level I burn center. *Palliative Medicine*. 2016;**19**(12):1275-1280
- [23] Mahar PD, Wasiak J, Cleland H, Paul E, Loke SY, Fong HC, et al. Clinical differences between major burns patients deemed survivable and non-survivable on admission. *Injury*. 2015;**46**(5):870-873
- [24] Greenwood JE. Development of patient pathways for the surgical management of burn injury. *ANZ Journal of Surgery*. 2006;**76**:805-811
- [25] Friedstat JS, Klein MB. Acute management of facial burns. *Clinics in Plastic Surgery*. 2009;**36**(4):653-660
- [26] Clayton NA, Ward EC, Maitz PK. Orofacial contracture management outcomes following partial thickness facial burns. *Burns*. 2015;**41**(6):1291-1297
- [27] Sorkin M, Cholok D, Levi B. Scar management of the burned hand. *Hand Clinics*. 2017;**33**(2):305-315
- [28] van Zuijlen PP, Kreis RW, Vloemans AF, Groenevelt F, Mackie DP. The prognostic factors regarding long-term functional outcome of full-thickness hand burns. *Burns*. 1999;**25**(8):709-714
- [29] Bombaro KM, Engrav LH, Carrouger GJ, et al. What is the prevalence of hypertrophic scarring following burns? *Burns*. 2003;**29**:299-302
- [30] Monstrey S, Middelkoop E, Vranckx JJ, Bassetto F, Ziegler UE, Meaume S, et al. Updated scar management practical guidelines: Non-invasive and invasive measures. *Journal of Plastic Reconstructive & Aesthetic Surgery*. 2014;**67**(8):1017-1025
- [31] Tredget EE, Shupp JW, Schneider JC. Scar management following burn injury. *Journal of Burn Care & Research*. 2017;**38**(3):146-147. DOI: 10.1097/BCR.0000000000000548
- [32] Klotz T, Kurmis R, Munn Z, Heath K, Greenwood J. Moisturisers in scar management following burn: A survey report. *Burns*. 2017;**43**(5):965-972
- [33] Mauck MC, Smith J, Liu AY, Jones SW, Shupp JW, Villard MA, et al. Chronic pain and itch are common, morbid sequelae among individuals who receive tissue autograft after major thermal burn injury. *The Clinical Journal of Pain*. 2017;**33**(7):627-634
- [34] Hoffman HG, Chambers GT, Meyer WJ 3rd, Arceneaux LL, Russell WJ, Seibel EJ, et al. Virtual reality as an adjunctive non-pharmacologic analgesic for acute burn pain during medical



procedures. *Annals of Behavioral Medicine*. 2011;**41**(2):183-191

[35] Najafi Ghezeljeh T, Mohades Ardebili F, Rafii F. The effects of massage and music on pain, anxiety and relaxation in burn patients: Randomized controlled clinical trial. *Burns*. 2017;**43**(5):1034-1104

[36] Herndon DN, Barrow RE, Rutan RL, Rutan TC, Desai MH, Abston S. A comparison of conservative versus early excision. Therapies in severely burned patients. *Annals of Surgery*. 1989;**209**(5):547-552

[37] Janzekovic Z. A new concept in the early excision and immediate grafting of burns. *The Journal of Trauma*. 1970;**10**(12):1103-1108

[38] Cleland H, Wasiak J, Dobson H, Paul M, Pratt G, Paul E, et al. Clinical application and viability of cryopreserved cadaveric skin allografts in severe burn: A retrospective analysis. *Burns*. 2014;**40**(1):61-66

[39] Branski LK, Herndon DN, Pereira C, Mlcak RP, Celis MM, Lee JO, et al. Longitudinal assessment of Integra in primary burn management: A randomized pediatric clinical trial. *Critical Care Medicine*. 2007;**35**(11):2615-2623

[40] Heimbach DM, Warden GD, Luterman A, Jordan MH, Ozobia N, Ryan CM, et al. Multicenter postapproval clinical trial of Integra dermal regeneration template for burn treatment. *Journal of Burn Care & Rehabilitation*. 2003;**24**(1):42-48

[41] Bargues L, Boyer S, Leclerc T, Duhamel P, Bey E. Incidence and microbiology of infectious complications with the use of artificial skin Integra in burns. *Annales de Chirurgie Plastique et Esthétique*. 2009;**54**(6):533-539

[42] Li A, Dearman BL, Crompton KE, Moore TG, Greenwood JE. Evaluation of a novel biodegradable polymer for the generation of a dermal matrix. *Journal of Burn Care & Research*. 2009;**30**(4):717-728

[43] Greenwood JE, Li A, Dearman B, Moore TG. Evaluation of NovoSorb™ novel biodegradable polymer for the generation of a dermal matrix. Part 1: In-vitro studies. *Wound Practice & Research*. 2010;**18**(1):14-22

[44] Greenwood JE, Li A, Dearman B, Moore TG. Evaluation of NovoSorb™ novel biodegradable polymer for the generation of a dermal matrix. Part 2: In-vivo studies. *Wound Practice & Research*. 2010;**18**(1):24-34

[45] Greenwood JE, Dearman BL. Split-skin graft application over an integrating, biodegradable temporising polymer matrix: Immediate and delayed. *Journal of Burn Care & Research*. 2012;**33**(1):7-19

[46] Greenwood JE, Schmitt BJ, Wagstaff MJD. Experience with a synthetic bilayer biodegradable temporising matrix in significant burn injury. *Burns Open*. 2018;**2**:17-34

[47] Greenwood JE, Wagstaff MJD, Rooke M, Caplash Y. Reconstruction of extensive calvarial exposure after major burn injury in two stages using a biodegradable polyurethane matrix. *Eplasty*. 2016;**16**:151-160

[48] Greenwood JE, Wagstaff MJD. The use of biodegradable polyurethane in the development of dermal scaffolds. Chapter 22. In: Cooper SL, Guan J, editors. *Advances in Polyurethane Biomaterials*. Duxford, UK: Woodhead Publishing Series in Biomaterials, (Elsevier Inc.); 2016. ISBN: 978-0-08-100614-6

[49] Greenwood JE. The evolution of acute burn care—Retiring the

split skin graft. *Annals of the Royal College of Surgeons of England*. 2017;**99**(6):432-438

[50] Dearman BL, Stefani K, Li A, Greenwood JE. "Take" of a polymer-based autologous cultured composite "skin" on an integrated temporizing dermal matrix: Proof of concept. *Journal of Burn Care & Research*. 2013;**34**(11):151-160

[51] Finnerty CC, Jeschke MG, Branski LK, Barret JP, Dziewulski P, Herndon DN. Hypertrophic scarring: The greatest unmet challenge after burn injury. *Lancet*. 2016;**388**(10052):1427-1436