

We are IntechOpen, the world's leading publisher of Open Access books Built by scientists, for scientists

6,900

Open access books available

185,000

International authors and editors

200M

Downloads

Our authors are among the

154

Countries delivered to

TOP 1%

most cited scientists

12.2%

Contributors from top 500 universities



WEB OF SCIENCE™

Selection of our books indexed in the Book Citation Index
in Web of Science™ Core Collection (BKCI)

Interested in publishing with us?
Contact book.department@intechopen.com

Numbers displayed above are based on latest data collected.
For more information visit www.intechopen.com



Laryngological and Dental Manifestations of Sjögren's Syndrome

Bartłomiej Kamiński and Katarzyna Błochowiak

Abstract

Sjögren's syndrome (SS) affects numerous different areas, and many specialists may be involved in the diagnosis and treatment of SS. Otolaryngological and dental manifestations, neurological impairment, and hearing loss may be the initial symptoms of SS. This chapter describes the most common otolaryngological and oral manifestations of SS, its pathomechanism and possible etiology. Dryness accompanying SS is associated with many clinical implications. The rate of dry mouth in SS ranged from 41% at initial diagnosis to 84% 10 years after diagnosis. An unstimulated salivary flow rate of 0.1 ml/min in sialometry gives a score of 1 to the weighted sum of 5 items according to the current EULAR/ACR criteria. The presence of mononuclear cell aggregates around the ducts and acini of salivary glands results in functional and structural alterations at the level of these glands and impairs their secretory function. The most common oral signs and symptoms are dental caries, tooth decay, fungal infections, traumatic oral lesions, dysphagia, dysgeusia, and inflammation of the salivary glands. Saliva in SS is characterized by the increased concentration of lactoferrin, potassium and cystatin C and the decreased concentration of amylase, carbonic anhydrase, mucins, histatines, IgA, statherins, proline-rich proteins, and the loss of salivary buffer properties. The lack of these physiological defense mechanisms increases the risk of opportunistic infections, mainly fungal infections by *Candida albicans*. Candidiasis accompanies angular cheilitis, simple cheilitis, and exfoliative cheilitis. The salivary glands of SS patients are characterized by chronic inflammation with the presence of lymphocytic infiltrates located around the striated ducts. These periductal foci may lead to the development of organized ectopic lymphoid structures resembling secondary lymphoid organs with segregated T- and B-cell areas, and high endothelial venules. These structures become an active center of immune response. The presence of foci in labial salivary glands is a hallmark of SS, and their histopathologic analysis is an important item in the diagnosis and classification. A biopsy can be taken from either the labial or the parotid salivary gland, but currently according to the diagnostic criteria, only labial salivary gland biopsy (LSGB) is recommended to confirm the diagnosis of SS. The authors present their own experience and recommendations in taking labial salivary gland biopsy, the main surgical approaches, and the main limitations for this diagnostic method and describe the possibilities and principles of histopathological examination in SS. The authors present the main ultrasonic signs of SS major salivary glands and perspectives of the usage of salivary gland ultrasonic examination in the diagnosis and monitoring of SS. The presented chapter also includes the most common laryngological manifestations associated with SS: nose dryness, crusting,

or atrophy of the nasal mucosa, dryness of the throat, dysphagia, hoarseness, otalgia and tinnitus, gastro-esophageal reflux, and chronic cough. Patients with SS tend to have a higher prevalence of sensorineural hearing impairment compared with the general population. Idiopathic hearing loss may represent the initial manifestation of SS. Furthermore, authors present and discuss the main neurological symptoms of SS. Neurological manifestations are reported in about 20% of patients with SS. In patients with SS, neurological manifestations may occur, such as peripheral neuropathy and other forms of neuropathies, including sensory ataxia, painful sensory neuropathy without sensory ataxia, multiple mononeuropathy, multiple cranial neuropathy, autonomic neuropathy, radiculoneuropathy and intra- and extraoral paresthesias, facial hypaesthesia, and trigeminal nerve neuropathy.

Keywords: Sjögren's syndrome, hearing loss, cranial nerve neuropathy, xerostomia

1. Introduction

Microscopic findings involving lymphocytic infiltration surrounding the excretory ducts in combination with the destruction of acinar tissue are representative for both minor and major salivary glands and are pathognomonic changes for SS. Parotid, lip, or sublingual salivary gland biopsy is performed in the diagnosis and monitoring of SS, but currently only labial salivary gland biopsy (LSGB) is included into classification criteria of SS. LSGB is used for the diagnosis of Sjögren's syndrome (SS). The current classification criteria of SS, approved by the American College of Rheumatology (ACR) and the European League against Rheumatism (EULAR) in 2016, include LSGB as a part of weighted sum of five items [1]. The presence of focal lymphocytic sialadenitis (FLS) with a focus score of 1 foci/4 mm² glandular tissue is a positive score of LSGB. Lip salivary glands are widely distributed in the labial mucosa of the oral cavity. They are largely used for assisting the diagnosis of SS, because they are easily accessible and lie above the muscle layer. They are separated from the oral mucous membrane by a thin layer of fibrous connective tissue. Orientation and identification of glandular tissue is the easiest. The risk of excessive postoperative bleeding is decreased because the arterial supply to the lip lies deep. These anatomical implications and pathognomic changes predispose of labial salivary glands to the biopsy [1–7].

2. Surgical technique and possible complications of LSGB

Labial salivary gland biopsy is considered a minor surgical procedure and can be performed on the ambulatory basis. There is no standardized technique that yields adequate tissue for analysis and minimizes adverse effects. The lack of uniformity in methodology and potential adverse effects of LSGB hinders its application. LSGB is treated as a safe and simple surgical procedure without severe postoperative complications. One of the most severe complications of LSGB is sensitive nerve injury. This localized sensory alternation can be described as an anesthesia, a reduced or partial loss of sensation, a transitory numbness, or a hypoesthesia. These sensations can last for a few months or can be permanent. Persistent lip numbness occurs in up to 6% of biopsies performed in the lower lip [8]. The branches of the mental nerve in the lower lip are closely associated with the salivary glands, and this anatomical relationship increases the risk of postoperative sensory sensations. Additionally, the branch of the mental nerve usually divides into two sub-branches: a horizontal and a vertical, which have an ascending course toward the vermillion border and are in close relation to the

labial salivary glands. Incisional biopsies shorter than 2 cm performed with a scalpel have reported complications ranging from 0 to 9.3%, whereas those using larger incisions (2–3 cm) have described complications in the range of 3.7–31%. Transient disorders of lip sensitivity are found to occur in up to 11.7% of procedures. Persistent lower lip hypoesthesia is reported in about 3.4–4% of cases. Larger incisional biopsies and punch biopsies are associated with a higher risk of both transient and persistent lower lip numbness. Other possible complications of LSGB are less severe, usually transient or temporary, and are associated with localized postoperative inflammation or improper healing. The symptoms of postoperative inflammations are local pain and swelling. Blood vessel injuries result in hematoma. The possible delayed complications are the formation of granulomas, internal scarring, and cheloid formation. Labial salivary gland injuries can result in mucous extravasation cysts. Some patients can report burning or tingling sensations, and functional deficits during the immediate postbiopsy period such as eating, sleeping, or speech difficulties [9–12].

Labial glands biopsy may be an excisional or incisional technique. The most recommended site is normal-appearing mucosa of the lower lip. Usually, it is a scalpel biopsy. A wide range of surgical approaches have been described for harvesting a few accessory glands from the lower lip using different instruments such as a scalpel, a punch, or cup forceps. The use of a forceps with a fenestrated active end to stabilize the lip has also been suggested. The excisional biopsy is carried out by excising an ellipse of oral mucous membrane down to the muscle layer. Ideally, 6–8 minor glands must be harvested and sent for histopathologic examination. The wound should be closed with 4-0 silk sutures, which are removed after 4–5 days. The modification of this method is the technique with a mucosal excision of 3.0×0.75 cm. Another recommended technique is a 1.0–1.5-cm-wedge-shaped excision of the mucosa between the midline and commissure. The incisional biopsy is described as a 1.5–2.0-cm linear incision of mucosa, parallel to the vermillion border and lateral to the midline. Gorson and Ropper reported a 1-cm vertical incision just behind the wet line through the mucosa and submucosa [31]. It is usually that case that the lateral lip compartments are advocated for biopsy, because of the glandular-free zone in the center of the lower lip. Berquin et al. described an oblique incision, starting 1.5 cm from the midline and proceeding latero-inferiorly to avoid the central glandular-free zone. The vertical incision technique is associated with less pain, less swelling, less scar formation, and less difficulty in eating when compared with the horizontal incision technique. There is insufficient evidence to support the superiority of one technique over the others, and the shape and the size of the incision can be considered a matter of preference. The incision shape includes elliptical, circular, linear, horizontal, vertical, and wedge shapes, and the incision length varies from a few millimeters to 2 cm.

Another recommended modification is using loupe operation glasses to precisely excise the salivary glands without disturbing the direct underlying sensible nerves. The alternative technique to scalpel biopsy is the minor salivary gland punch biopsy. This biopsy can be performed by a single operator, and it is less expensive than classical scalpel biopsy. This technique consists of obtaining the biopsy from the buccal side of the lower lip, which is stabilized by the patient him/herself using a 4–5 mm punch, which permits the retrieval of a cylinder of tissue up to 8 mm in length. The punch biopsy is suggested because of the absence of risk to the patient and because of its simplicity. However, the punch biopsies do not provide enough material for the diagnosis of Sjögren's syndrome. Moreover, the findings of this study strongly discouraged the punch technique for minor salivary gland lip biopsy and provided information on the superiority of the linear incisional biopsy in terms of neural damage [12–16].

Based on our own clinical experience, a 1.0–1.5-cm linear, horizontal incision of mucosa parallel to the vermillion border and lateral to the midline with the

tip of a 15 scalpel is worth to recommend. The lower lip should be retracted and everted under tension to expose the inner surface and allow visualization of the minor salivary glands just to the depth of the mucosa. Local anesthesia injected submucosally with 0.5–1.0 ml of 1% lidocaine with 1:200,000 epinephrine is sufficient. The anesthesia hydrodissects and lifts the mucosa away from the salivary glands, provides delivery of local anesthetic directly to sensory nerve fibers, and temporarily displaces small vessels deep in the glands to promote hemostasis and visualization during the dissection. In this technique, both margins of incision should be gently crafted to access the submucosal layer. This stage of procedure can be performed using blunt-tipped iris scissors or a scalpel by spreading in a plane perpendicular to the mucosal incision and parallel to the direction of the sensory nerve fibers. This technique is fast, simple, and leaves a small scar. The linear incision secures a good adherence of wound margins and proper and fast healing. Unfortunately, this method is not effective in small amounts of salivary glands. Sometimes, it is difficult to find the sufficient amount of labial glands. Moreover, it may be difficult to harvest a sufficient number of labial salivary glands in atrophic mucosa of patients with long-standing SS. In these cases, the recommended method is a 1-cm lenticular incision of mucosa, lateral to the midline, and removal of the mucosa to uncover the submucosal layer and obtain a few adjacent salivary glands. This technique ensures good visibility into the operating field to avoid blood vessels and nerve injuries. This incision provides adequate glandular tissue for diagnosis. The wound should be closed by a few nonresorbable, single, interrupted stitches. One very important issue is to harvest only labial salivary glands without muscular or other tissues. It is the most valuable specimen for histopathological examination, because it only includes glandular tissue. Additionally, this technique decreases the risk of nerve damage and postoperative pain and assures successful healing. Sensory nerve fibers are almost always visible just below the plane of dissection, and care should be taken to identify and preserve them. The next very important issue is not to puncture the labial glands to reduce the risk of mucous extravasation cyst formation. It is even better to remove all visible labial salivary glands from the operating field before suturing in order not to damage the glands or their ducts. Patients should also avoid taking steroids before the biopsy. The factors potentially contributing to a false-negative rate include the use of oral steroids that may result in immunosuppression and confound histopathologic results. The tissue specimens should be immediately placed in a wide-mouthed container, coded, and fixed in a generous amount of 10% formalin buffered saline for 24 h (**Figures 1 and 2**).

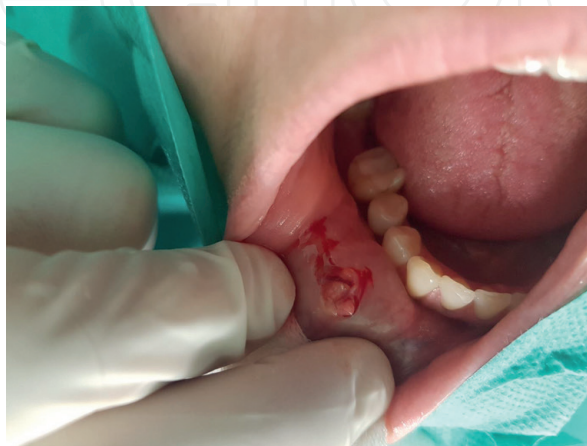

Figure 1.
Linear incision and scalpel biopsy of labial salivary gland biopsy. A few labial salivary glands exposed and visible in the operating field.

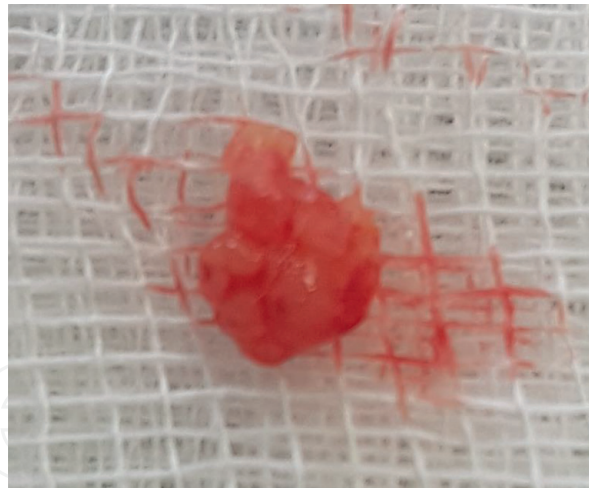


Figure 2.
Labial salivary gland specimen.

3. Histologic criteria for diagnosis of SS on labial salivary gland biopsies

Labial salivary gland biopsy is an objective test of SS and plays a significant role in the diagnostic process. In fact, the presence of either anti-SSA/SSB seropositivity or a positive lip biopsy is a requirement for an individual to be classified as having SS. The microscopic confirmation of SS is based on the presence of focal lymphocytic sialadenitis (FLS) with a focus score ≥ 1 per 4 mm^2 of glandular tissue. According to the revised American-European Consensus Group's (AECG) classification criteria and the ACR classification criteria for SS, an LSGB is considered positive if minor salivary glands demonstrate FLS, with a focus score of 1 or more, as evaluated by an expert histopathologist. A lymphocytic focus is defined as a dense aggregate of 50 or more lymphocytes adjacent to normal-appearing mucous acini in salivary gland lobules that lacked ductal dilatation. Focal lymphocytic sialadenitis is applied to specimens that show the presence of 1 or more foci of lymphocytes located in periductal and perivascular locations. The foci can contain plasma cells, but these must be a minority constituent of the inflammatory infiltrate. The focus score can be calculated for those specimens showing the histopathologic appearance of FLS. The number of lymphocytic foci is then determined for all the gland lobules in a single tissue section. The focus score is then calculated as the number of foci per square millimeter of glandular tissue multiplied by four, which then yields foci/ 4 mm^2 . A focus score of 1 equates to 1 focus/ 4 mm^2 . To determine the focus, a calibrated eyepiece grid or image analysis software with a closed polygon tool is used. FLS has to be distinguished from non-specific chronic sialadenitis. The symptoms of nonspecific sialadenitis are mild to moderate acinar atrophy, interstitial fibrosis, and ductal dilatation, with lymphocytes and macrophages often scattered in the parenchyma, but not forming dense aggregates of 50 or more lymphocytes immediately adjacent to normal-appearing acini. In addition to the focus score (FS), two scoring systems for salivary glands are in use for the diagnosis and classification of SS. These systems are based on the presence of foci [7]. Grading according to Tarpley's system involves destruction of acinar tissue and fibrosis (**Table 1**). Grading according to the Chisholm and Mason system is based on the presence of infiltrates from slight to one or more foci (**Table 2**) [16, 17].

Focus: a cluster of 50 or more lymphocytes and histiocytes.

Aggregate: approximately 50 cells (lymphocytes, plasma cells, or histiocytes).

Grade	Description
0	Normal
1	1 or 2 Aggregates
2	>3 Aggregates
3	Diffuse infiltrate with partial destruction of acinar tissue with or without fibrosis
4	Diffuse infiltrate with or without fibrosis destroying the lobular architecture completely

Table 1.
Grading systems for salivary gland biopsies of Tarpley.

Grade	Description
0	Absent
1	Slight infiltrate
2	Moderate infiltrate or less than one focus
3	One focus
4	More than one focus

Table 2.
Grading systems for salivary gland biopsies of Chisholm and Mason.

4. Differentiation of focus lymphocytic sialadenitis

Focus lymphocytic sialadenitis should be differentiated with other microscopic findings:

- Nonspecific chronic sialadenitis NSCS
- Sclerosing chronic sialadenitis SCS
- Granulomatous inflammation
- Infiltrates within normal limits
- Marginal zone (MALT) lymphoma
- Germinal center

Nonspecific chronic sialadenitis (NSCN) is characterized by scattered or focal infiltrates of lymphocytes, macrophages, and plasma cells that are not adjacent to normal-appearing acini and located in gland lobules that exhibit some combination of acinar atrophy, interstitial fibrosis, duct dilation, and luminal inspissated mucus.

Sclerosing chronic sialadenitis (SCS) is an advanced stage of NSCS in which interstitial fibrosis, various patterns of chronic inflammation, and acinar atrophy predominate.

Granulomatous inflammation is present when there are clusters of CD68 positive macrophages, with or without occasional multinucleated giant cells and absent necrosis.

Infiltrates within normal limits can be diagnosed in minor salivary glands with normal appearing architecture and scattered plasma cells, but without acinar atrophy and few if any lymphocytes.

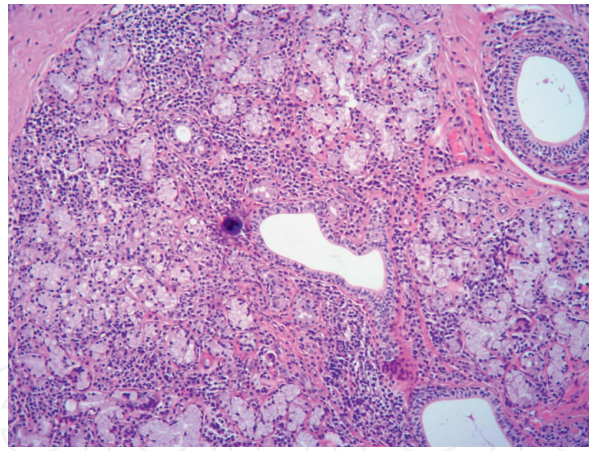


Figure 3.
Confirmation of SS in LSGB. Focus score 4 (staining H&E, magnitude 10×).

Marginal zone (MALT) lymphoma is diagnosed in minor salivary glands exhibiting diffuse lymphocytic infiltration with loss of glandular architecture and composed of sheets of CD20 positive cells without follicular distribution, few scattered CD3 positive cells, and few if any follicular dendritic (CD21 or CD23 positive) cells.

Germinal center presence is estimated in hematoxylin and eosin (H&E) stained sections by the presence of a cluster of relatively clear staining cells within a lymphocytic focus. More specific identification of germinal centers requires immunohistochemical staining for follicular dendritic cells with anti-CD21 or CD23 [4, 9].

There is no standardization of labial salivary gland biopsies in SS, but there are several points of importance in LSGB. The first issue refers to a sufficient amount of glandular tissue. A reasonable compromise is four glands, although a minimum sized evaluable surface area (8 mm²) may be achieved with 2–3 glands. The largest possible area to be sampled would give the best results, but a larger operative field increases the surgical risk. On the other hand, some glands may be atrophic or damaged, and the volume of the material obtained through the biopsy should be sufficient to overcome this artifact and achieve a valid result. It is more recommended to evaluate multiple different lobules than to concentrate on a single abnormal lobule, which may not be typical of the entire gland. In routine management, H&E staining is used in order to determine these structures. For clinical trials, additional staining with CD21 as well as CD20 and CD3 is required. CD21 is a marker of follicular dendritic cells. Germinal centers should be reported and pathologists are advised to use caution in order to avoid overestimating germinal centers by relying solely on CD21. Furthermore, the distribution of the inflammatory cells in the gland may be uneven. Considering this uneven distribution, a single tissue section may result in underdiagnosis. While increasing the number of sections has the potential to reduce this problem, the optimal number of sections has yet to be determined. Some research suggests taking labial salivary glands at different depths from the same incision. Focus score can change significantly at different tissue depths within the minor salivary glands. Multiple sections for LSGB increase the diagnostic value and are more representative than a single section [7, 10] (Figure 3).

5. Limitations of the assessment of focus score

- Differentiation of FLS with nonspecific chronic sialadenitis and sclerosing chronic sialadenitis
- Severe acinar atrophy, interstitial fibrosis, and increase in fat cells in biopsy specimens

- Age-related features in biopsy specimens (increased fibrosis, acinar atrophy, and adipose tissue)
- Lack of the measurement of the infiltrate [7]

6. Other histopathological features of LSGB

There are also other histopathological features in the labial glands that are associated with SS and therefore might be indicative of this disease. Lymphoepithelial lesions (LELs) are striated ducts, which are infiltrated by lymphocytes with concurrent hyperplasia of the epithelial cells. They are found both in parotid and labial glands, and are more representative of parotid glands than labial glands.

Severity of the LELs can be classified into three stages: stage 1: a partial LEL (affecting <50% of the epithelium), stage 2: developed LELs (affecting 50–100% of the epithelium), and stage 3: occluded LELs (fully circumferentially affected epithelium without lumen).

Besides LELs, the salivary gland of SS patients also presents a relative decrease in IgA + plasma cells. Several studies showed that a relative decrease of <70% IgA + plasma cells was more sensitive and more disease specific than the FS. Both features can help assess the salivary gland biopsies for the diagnosis of SS, especially when the FS in the biopsy is <1 [7, 19–23].

7. Alternative types of salivary gland biopsies in SS

The main alternative types of salivary gland biopsies in SS are parotid gland biopsy and sublingual gland biopsy. Parotid gland biopsy allows the clinician to monitor the disease progression and to assess the effect of an intervention treatment in SS. Parotid tissue can be harvested easily, repeated biopsies from the same parotid gland are possible, and the histopathologic results can be compared with other diagnostic results derived from the same gland, such as secretory function, sialographic appearance, and ultrasonography. Furthermore, parotid biopsy is better in the identification of lymphomas. The main possible complications are facial nerve damage, Frey's syndrome, and development of sialoceles and salivary fistulae. A temporary change in sensation in the skin area of the incision is also a well-documented complication after parotid biopsy. Some patients might also develop preauricular hypoesthesia, although this is usually temporary. Furthermore, in SS, the salivary gland tissue is replaced by fatty tissue, and the risk of harvesting fatty tissue is thereby increased if done by inexperienced physicians. Parotid biopsy is particularly recommended in pediatric patients in whom SS is suspected and who have a negative minor salivary gland biopsy result. Incisional biopsy of the parotid gland overcomes most of the disadvantages of labial biopsy. When evaluating the parotid and labial biopsy, sensitivity and specificity are comparable, estimated to be 78 and 86%, respectively. Comparative studies suggest that both procedures—sublingual and parotid biopsy—retain a diagnostic potential comparable to that of lip biopsy and may be associated with lower postoperative morbidity. A comparison of sublingual gland biopsy with labial gland biopsy is better than that of labial gland biopsy, whereas the specificity of the latter is greater than that of the former. Sublingual gland biopsy is a relatively safe procedure, although the postoperative complications of sublingual salivary gland biopsy include ligaturing the Wharton duct, resulting from the placement of sutures, bleeding, and swelling in the floor of the mouth. Damage to the lingual nerve related to this biopsy technique has never

been reported in the literature. No specialized histopathologic criteria have been established for the diagnosis of SS after a sublingual gland biopsy, and researchers merely used the criteria for labial gland biopsies [24–28].

8. Oral involvement and xerostomia

The rate of dry mouth in SS ranged from 41% at initial diagnosis to 84% 10 years after diagnosis. Hyposalivation or xerostomia measured by sialometry is one of the objective clinical criteria in the diagnosis of SS. According to the current classification criteria of SS, an unstimulated salivary flow rate of 0.1 ml/minute in sialometry gives a score of 1 to the weighted sum of 5 items. Dryness is also a subjective symptom of SS and is associated with many clinical implications. There are two possible sources of hyposalivation. The first possible origin is the presence of mononuclear cell aggregates around the ducts and acini of salivary glands resulting in functional and structural alterations of these glands and impairing their secretory function. In addition to the direct relationship between mononuclear cell infiltrations and secretory function, there are alternative pathways, such as induction of apoptosis of epithelial glands, alterations in aquaporin distribution, or inhibition of neurotransmission by antimuscarinic antibodies, lead to impaired glandular homeostasis. The second proposed hypothesis is the destruction of the duct and acinar cells of the salivary glands, and neural degeneration and/or the inhibition of nerve transmission. Hyposialia or decreased salivation can lead to xerostomia with clinical oral symptoms [29]. Dry mouth is associated with both objective and subjective signs and symptoms. The most common complaints related to dry mouth are presented in Table 3.

In SS, the gingiva and mucosa of the oral cavity are not protected by salivary mucins, leading to less lubrication of the tissues. This can cause signs such as oral mucosal inflammation, mucosal sloughing, erythematous mucosa, and traumatic ulcers. Patients may demonstrate depapillation of the tongue in advanced cases. With time, the concentration of lactoferrin, potassium and cystatin C in saliva grows, while the amylase and carbonic anhydrase concentration drops. Decreased secretion of saliva, the loss of its buffer properties, and a lower concentration of saliva proteins such as histatins, mucins, IgA, and proteins rich in proline and statherins increase the risk of opportunistic infections, mainly fungal infections by *Candida albicans*. The prevalence of *Candida albicans* is >68% in patients with SS. Oral candidiasis may be asymptomatic or may show as fissured tongue, rhomboid mid-tongue, nonspecific ulcerations, prosthetic stomatopathies, or generalized candidiasis. It most often takes the form of chronic candidiasis, and less often of pseudodiphtheritic candidiasis. Candida infections often present as atrophic or erythematous candidiasis and are associated with a burning mouth, which is described by approximately one-third of patients with SS. In SS patients,

A dryness of the mouth in the morning and at night
A frequent need to sip water
A lip dryness, exfoliation, fissuring
A predisposition to aphthae, ulcers, and mouth sores
A burning sensation in the mouth
A dysphagia
A dysgeusia

Table 3.
The most common complaints related to dry mouth.

Candidiasis
Angular cheilitis
Simple cheilitis
Exfoliative cheilitis
Aphthae
Aphthoid lesions
Nonspecific ulcerations
Paleness of the oral mucosa
Staphylococcal infection

Table 4.
Symptoms of oral mucosa in the Sjögren's syndrome.

C. albicans, *C. tropicalis*, *C. glabrata*, and *C. parapsilosis* are mainly isolated. Apart from oral candidiasis, a number of other changes and symptoms regarding the oral mucosa may occur (**Table 4**).

Angular cheilitis may be accompanied with fungal infection. In simple cheilitis, dominant manifestations are lip exfoliation and cracking, their proneness to bleeding, periodic swelling, and burning. The lesions are mostly limited to lip vermillion, less often labial mucosa or the facial skin around the vermillion is affected. In exfoliative cheilitis, thick brown keratin plaques are also formed. Skin redness over the lip vermillion and swelling are more often observed [29].

SS patients are predisposed to rampant caries and traumatic oral lesions. Lack of antibacterial salivary proteins results in severe tooth caries, especially on the unexposed tooth spaces. Rampant cervical caries is the most typical manifestation to SS.

9. Laryngological and otological manifestations of SS

The lymphocytic infiltrations are representative for all salivary glands and have other possible consequences. Although the sicca syndrome prevails, in a clinical presentation, a bilateral parotid swelling induced by progressive lymphocyte infiltration leads both to ductal inflammation and acinar destruction in about 50% of patients. Recurrent swelling and inflammations of the parotid or submandibular glands in SS are well documented. Slow salivary flow, acinar destruction, and lymphocytic infiltrations predispose to inflammation and salivary gland enlargement. This enlargement should be distinguished from lymphomas. The most significant complication of SS is the development of lymphoproliferative malignancy, which occurs in about 5% of SS patients. Malignant lymphoma, particularly mucosa-associated lymphoid tissue (MALT) lymphoma, is relatively a frequent complication of SS with an incidence ranging between 5 and 10% and a median time from SS to lymphoma diagnosis of 7.5 years. Lymphomas accompanying SS can be confirmed by histopathological examination of salivary gland biopsy. The detection of germinal centers (GC) in salivary gland biopsy can be a very sensitive and predictive feature for lymphogenesis. Antigen-driven B cell selection normally takes place in GC within secondary lymphoid organs, but there is conclusive evidence that also ectopic GC in the salivary glands of SS patients allow affinity maturation of GC B cells with somatic Ig gene hypermaturation. Parotid gland biopsy is more recommended for diagnosis of lymphomas than labial salivary glands [7, 18–23].

Dryness of the mucosa of the upper respiratory tract is a predominant symptom and results in nasal, oropharynx, nasopharynx, laryngopharynx, vocal cord dryness, and dryness of the skin of the external auditory meatus. The main laryngological symptoms accompanying SS include the following:

- Dry nose with congestion, crusting, and epistaxis
- Dryness, crusting, or atrophy of the nasal mucosa
- Soreness and/or dryness of the throat
- Viscid secretions on the posterior pharyngeal wall and tenacious mucus over the vocal cords
- Dry wax and a “milky” appearance of the tympanic membrane
- Dysphagia
- Hoarseness
- Otalgia
- Tinnitus
- A chronic dry cough
- Dyspnea
- Gastrotracheal reflux
- Otitis externa
- Myringitis
- Sensorineural hearing loss
- Facial hypaesthesia and trigeminal nerve neuropathy, and multiple cranial neuropathy [30–33]

Other possible laryngological manifestations of SS are early and progressive hearing loss and symptoms related to neuropathy of the eighth cranial nerve. Approximately, a quarter of patients suffer from high-frequency hearing loss of cochlear origin, as detected by impedance audiometry or auditory brainstem procedures. The immunologic theory of sensorineural hearing loss (SNHL) in SS is based on antibody activity and cytotoxic T-cell-mediated apoptosis in the inner ear. It has been suggested that these autoantibodies induce thrombosis in the labyrinthine vessels, thereby causing damage to the inner ear, resulting in SNHL. The majority of primary SS patients exhibit hearing impairments of cochlear origin, principally at high frequencies. Sensorineural damage may be attributable to vasculitis or neuritis, or may represent an ototoxic effect of the drugs used to treat primary SS. Although there is no evidence of damage to the central auditory pathways in SS, these patients tend to have a higher prevalence of sensorineural hearing impairment compared with the general population. Idiopathic hearing loss may represent the initial manifestation of systemic vasculitis, including SS. The pathomechanisms underlying cranial neuropathy in SS have not yet been explained, except for trigeminal neuropathy due to ganglionopathy. The two possible mechanisms, vascular origin with damage to the vasa nervorum, and an immunologic cause inducing lymphocytic infiltration of the nerve have been suggested in nerve palsies related to SS. Vasculitis

in peripheral neuropathy and ganglionopathy in trigeminal or ataxic neuropathies have been reported as the main pathogenic etiology. The rapid and almost complete recovery from nerve palsy after therapy with corticosteroids and azathioprine suggests that lymphocytic infiltrate, rather than a vasculitic process, was the cause of cranial neuropathy in SS [33–40].

Author details

Bartłomiej Kamiński^{1*} and Katarzyna Błochowiak²

1 Department of Otolaryngology, District Hospital, Skarzysko-Kamienna, Poland

2 Department of Oral Surgery, Poznan University of Medical Sciences, Poznan, Poland

*Address all correspondence to: bartl.kaminski@gmail.com

IntechOpen

© 2019 The Author(s). Licensee IntechOpen. This chapter is distributed under the terms of the Creative Commons Attribution License (<http://creativecommons.org/licenses/by/3.0>), which permits unrestricted use, distribution, and reproduction in any medium, provided the original work is properly cited. 

References

- [1] Shiboski CH, Shiboski SC, Seror R. 2016 American College of Rheumatology/ European League Against Rheumatism Classification Criteria for primary Sjögren's syndrome. *Arthritis & Rheumatology*. 2017;**69**:35-45
- [2] Shiboski CH, Shiboski SC, le Seror R, Criswell LA, Labetoulle M, Lietman TM, et al. American College of Rheumatology/ European League Against Rheumatism Classification Criteria for Primary Sjögren's Syndrome. A consensus and data-driven methodology involving three international patient cohorts. *Annals of the Rheumatic Diseases*. 2017;**76**:9-16
- [3] Mavragani CP, Moutsopoulos HM. Sjögren's syndrome. *Annual Review of Pathology: Mechanisms of Disease*. 2014;**9**:273-285
- [4] Daniels TE, Cox D, Shiboski CH, Schiødt M, Wu A, Lanfranchi H, et al. Greenspan JS and for the Sjögren's international collaborative clinical Alliance (SICCA) research groups. Associations between salivary gland histopathologic diagnoses and phenotypic features of Sjögren's syndrome (SS) among 1726 registry participants. *Arthritis and Rheumatism*. 2011;**63**:2021-2030
- [5] Pereira DL, Vilela VS, Dos Santos TC, Pires FR. Clinical and laboratorial profile and histological features on minor salivary glands from patients under investigation for Sjögren's syndrome. *Medicina Oral, Patología Oral y Cirugía Bucal*. 2014;**19**:e237-e241
- [6] Kim J, Sun D, Ozl R, Graderbeck T, Birnbaum J, Akpek EK, et al. A validated method of labial minor salivary gland biopsy for the diagnosis of Sjögren's syndrome. *The Laryngoscope*. 2016;**126**:2041-2046
- [7] Kroese F, Haacke E, Bombardieri M. The role of salivary gland histopathology in primary Sjögren's syndrome: Promises and pitfalls. *Clinical and Experimental Rheumatology*. 2018;**36**(Suppl 112): 222-233
- [8] Delli K, Vissink A, Spijkervet FKL. Salivary gland biopsy for Sjögren's syndrome. *Oral and Maxillofacial Surgery Clinics of North America*. 2014;**26**(1):23-33
- [9] Franceschini F, Cavazzana I, Andreoli L, Tincani A. The 2016 classification criteria for primary Sjögren's syndrome: What's new? *BMC Medicine*. 2017;**15**:69
- [10] Sarioğlu S, Küçük Ü, Cetin P, Sari I, Bırlık AM. Minor salivary gland evaluation: Sjögren's syndrome. *Turk J Med Sci*. 2016;**46**:63-65
- [11] Varela-Centelles P, Sanchez-Sanchez M, Seoane J. Lip biopsy for the diagnosis of Sjögren's syndrome: Beware of the punch. *International Journal of Oral and Maxillofacial Surgery*. 2014;**43**(1):127-130
- [12] Giovelli RA, Santos MCS, Serrano E, Valim V. Clinical characteristics and biopsy accuracy in suspected cases of Sjögren's syndrome referred to labial salivary gland biopsy. *BMC Musculoskeletal Disorders*. 2015;**16**:30
- [13] Bamba R, Sweiss NJ, Langerman AJ, Taxy JB, Blair EA. The minor salivary gland biopsy as a diagnostic tool for Sjögren's syndrome. *The Laryngoscope*. 2009;**119**:1922-1926
- [14] Langerman AJ, Blair EA, Sweiss NJ, Taxy JB. Utility of lip biopsy in the diagnosis and treatment of Sjögren's syndrome. *The Laryngoscope*. 2007;**117**(6):1004-1008
- [15] Van Stein-Callenfels D, Tan J, Bloemena E, van Vugt RM, Voskuyl

- AE, Santana NT, et al. The role of labial salivary gland biopsy in the diagnostic procedure for Sjögren's syndrome; a study of 94 cases. *Medicina Oral, Patología Oral y Cirugía Bucal*. 2014;**19**(4):e372-e376
- [16] Tarpley TM Jr, Anderson LG, White CL. Minor salivary gland involvement in Sjögren's syndrome. *Oral Surgery, Oral Medicine, and Oral Pathology*. 1974;**37**(1):64-74
- [17] Chisholm DM, Mason DK. Labial salivary gland biopsy in Sjögren's disease. *Journal of Clinical Pathology*. 1968;**21**(5):656-660
- [18] Keszler A, Adler LI, Gandolfo MS, Masquijo Bisio PA, Smith AC, Vollenweider CF, et al. MALT lymphoma in labial salivary gland biopsy from Sjögren syndrome: Importance of follow-up in early detection. *Oral Surgery, Oral Medicine, Oral Pathology, Oral Radiology*. 2013;**115**:e28-e33
- [19] Theander E, Vasaitis L, Baecklund E, Nordmark G, Warfvinge G, Liedholm R, et al. Lymphoid organisation in labial salivary gland biopsies is a possible predictor for the development of malignant lymphoma in primary Sjögren's syndrome. *Annals of the Rheumatic Diseases*. 2011;**70**:1363-1368
- [20] Bende RJ, Slot LM, Hoogeboom R, Wormhoudt TA, Adeoye AO, Guikema JE, et al. Stereotypic rheumatoid factors that are frequently expressed in mucosa-associated lymphoid tissue-type lymphomas are rare in the labial salivary glands of patients with Sjögren's syndrome. *Arthritis & Rheumatology*. 2015;**67**:1074-1083
- [21] Ferro F, Marcucci E, Orlandi M, Baldini C, Bartoloni-Bocci E. One year in review 2017: Primary Sjögren's syndrome. *Clinical and Experimental Rheumatology*. 2017;**35**:179-191
- [22] Fragoulis GE, Fragkioudaki S, Reilly JH, Kerr SC, McInnes IB, Moutsopoulos HM. Analysis of the cell populations composing the mononuclear cell infiltrates in the labial minor salivary glands from patients with rheumatoid arthritis and sicca syndrome. *Journal of Autoimmunity*. 2016;**73**:85-91
- [23] Soyfoo MS, Catteau X, Delporte C. Parotid gland biopsy as an additional diagnostic tool for supporting the diagnosis of Sjögren's syndrome. *International Journal of Rheumatology*. 2011:302527
- [24] Pijpe J, Kalk WWI, van der Wal JE, et al. Parotid gland biopsy compared with labial biopsy in the diagnosis of patients with primary Sjögren's syndrome. *Rheumatology*. 2007;**46**(10):335-341
- [25] de Sousa Gomes P, Juodzbalsys G, Fernandes MH, Guobis Z. Diagnostic approaches to Sjögren's syndrome: A literature review and own clinical experience. *Journal of Oral & Maxillofacial Research*. 2012;**3**(1):e3
- [26] Błochowiak K, Wyganowska-Świątkowska M. Labial minor salivary gland biopsy in the diagnosis of Sjögren syndrome-own experience. *Dent Forum*. 2018;**46**(2):17-21
- [27] Scardina GA, Spanó G, Carini F, et al. Diagnostic evaluation of serial sections of labial salivary gland biopsies in Sjögren's syndrome. *Medicina Oral, Patología Oral y Cirugía Bucal*. 2007;**12**:565-568
- [28] Błochowiak K, Olewicz-Gawlik A, Polańska A, Nowak-Gabryel M, Kocięcki J, Witmanowski H, et al. Oral mucosal manifestations in primary and secondary Sjögren syndrome and dry mouth syndrome. *Postępy Dermatologii i Alergologii*. 2016;**33**:23-27
- [29] Öztürk AB, Öztürk E, Kasapoğlu E. Chronic cough due to mucosal dryness

in primary Sjögren's syndrome: A case report. *Tüberküloz ve Toraks*. 2014;**62**:243-244

[30] Kumon Y, Kakigi A, Sugiura T. Clinical images: Otagia, an unusual complication of Sjögren's syndrome. *Arthritis and Rheumatism*. 2009;**60**:2542

[31] Fox RI. Sjögren's syndrome. *Lancet*. 2005;**366**:321-331

[32] Calzada AP, Balaker AE, Ishiyama G, Lopez IA, Ishiyama A. Temporal bone histopathology and immunoglobulin deposition in Sjögren's syndrome. *Otology & Neurotology*. 2012;**33**:258-266

[33] Kamiński B. Laryngological manifestations of Sjögren's syndrome. *Reumatologia/Rheumatology*. 2019;**57**(1):37-44

[34] Kim KS, Kim HS. Successful treatment of sensorineural hearing loss in Sjögren's syndrome with corticosteroid. *The Korean Journal of Internal Medicine*. 2016;**31**:612-615

[35] Ramos-Casals M, Tzioufas AG, Font J. Primary Sjögren's syndrome: New clinical and therapeutic concepts. *Annals of the Rheumatic Diseases*. 2005;**64**:347-354

[36] Hadithi M, Stam F, Donker AJ, Dijkmans BA. Sjögren's syndrome: An unusual cause of Bell's palsy. *Annals of the Rheumatic Diseases*. 2001;**60**:724-725

[37] Ashraf VV, Bhasi R, Kumar RP, Girija AS. Primary Sjögren's syndrome manifesting as multiple cranial neuropathies: MRI findings. *Annals of Indian Academy of Neurology*. 2009;**12**:124-126

[38] Sakai K, Hamaguchi T, Yamada M. Multiple cranial nerve enhancement on MRI in primary Sjögren's syndrome. *Internal Medicine*. 2010;**49**:857-859

[39] Tucci M, Quatraro C, Silvestris F. Sjögren's syndrome: An autoimmune disorder with otolaryngological involvement. *Acta Otorhinolaryngologica Italica*. 2005;**25**:139-144

[40] Birnbaum J. Facial Weakness, Otagia, and Hemifacial Spasm: A Novel Neurological Syndrome in a Case-Series of 3 Patient