

We are IntechOpen, the world's leading publisher of Open Access books Built by scientists, for scientists

6,900

Open access books available

185,000

International authors and editors

200M

Downloads

Our authors are among the

154

Countries delivered to

TOP 1%

most cited scientists

12.2%

Contributors from top 500 universities



WEB OF SCIENCE™

Selection of our books indexed in the Book Citation Index
in Web of Science™ Core Collection (BKCI)

Interested in publishing with us?
Contact book.department@intechopen.com

Numbers displayed above are based on latest data collected.
For more information visit www.intechopen.com



Minimally Invasive Right Anterior Mini-Thoracotomy Aortic Valve Replacement

Imran Khan, Julian A. Smith and Naresh Trehan

Abstract

Since the emergence of small skin incision aortic valve surgery in the late 1990s, minimally invasive aortic valve replacement has now become a viable alternative to standard full sternotomy. The spectrum includes (a) upper hemi sternotomy (T or J shaped), (b) lower partial sternotomy, and (c) right anterior mini-thoracotomy. Potential advantages include a cosmetically appealing scar, decreased post-operative pain and bleeding, shorter ventilation time and hospital stay, and early return to active life. The operative challenges include restricted view and access to the operative field, longer aortic cross-clamp time, and cardiopulmonary bypass time. This necessitates detailed pre-operative imaging, correct selection and assessment of patients, and good communication with perfusionists and anesthetists regarding the plan of each surgery, with a solid back-up plan in case conversion to full sternotomy is required intra-operatively. In recent times, the use of suture less valves and rapid deployment bio prosthesis has dramatically reduced operative time. Here, we describe the work-up, selection criteria, key steps, and potential pitfalls of the right anterior mini-thoracotomy approach for aortic valve replacement.

Keywords: minimally invasive aortic valve replacement, suture less valve, rapid deployment bio prosthesis, work-up, pitfalls, imaging

1. Introduction

Conventional full median sternotomy aortic valve replacement (AVR) has remained the standard approach to AVR for many years. In-hospital mortality of 2.3% for isolated conventional AVR (22,107 patients) has been reported in German Aortic Valve Registry [1]. Despite these excellent results, full sternotomy incision has been criticized for its length, postoperative pain and possible complications including sternal wound dehiscence, which dramatically increase the morbidity of the procedure [2].

The introduction of minimally invasive aortic valve surgery began in the last decade of twentieth century. The first minimally invasive AVR was performed by Cosgrove and Sabik in 1996 using a parasternal approach [3]. Bennetti et al. used the right thoracotomy approach in 1997 [4]. In 1998, Gundry et al. [5] reported a partial upper mini sternotomy approach in both adult valve and congenital procedures. Minimally invasive aortic valve surgery has recently moved from simple modifications of conventional steps to totally endoscopic aortic valve replacement (TEAVR) [6].

Although results of many retrospective and prospective studies behold a bright future for this approach, the prevalence of minimally invasive aortic valve replacement (MIAVR) has not met potential expectations: 29% of AVRs are done minimally invasive in Germany [7] and 12% in the UK [8]. Kaneko et al. [9] reported that 12% patients had hemi sternotomy AVR and 3.6% patients were operated via an anterior mini-thoracotomy approach in the USA.

A possibly long learning curve and complexity of the procedure may dissuade the widespread uptake of MIAVR. In an era of trans-catheter aortic valve implantation (TAVI) [10], sufficient motivation should be present for cardiac surgeons to adopt MIAVR in majority of patients, especially considering the recent promising results [11].

2. Why cardiac surgeons should adopt minimally invasive aortic valve surgery?

Minimally invasive cardiac surgery is a thought process that aims to minimize the extent of surgical invasiveness [12]. The American Heart Association (2008) defined it as “a small chest wall incision that does not include the conventional full sternotomy” [13]. The STS database defines minimally invasive cardiac surgery as “any procedure not performed with full sternotomy and cardiopulmonary bypass (CPB) support” [14]. The AHA definition is more realistic in the sense that an open heart surgery procedure is more likely to be conducted with cardiopulmonary bypass support. Based on the current STS definition, only TAVI can be included.

Potential advantages of MIAVR are:

- a. Cosmesis and wound complications: Improved cosmesis and esthetic scar is the unquestionable benefit of MIAVR. Although superficial wound infections have been reported [15], avoiding a full sternotomy leads to complete avoidance of deep sternal wound infection and risk of sternal non-union. Patients are discharged from ICU and hospital earlier and they return to an active work life earlier compared to full sternotomy AVR [16].
- b. Post-operative bleeding and blood transfusions: The need for blood transfusion was reported to be reduced in patients undergoing MIVAR compared to full sternotomy AVR (36 vs. 52.4%, $p < 0.001$) [17]. Burdett et al. [18] showed that MIAVR patients had significantly less post-operative blood loss (232 vs. 513 ml, $p = 0.00021$) and were less likely to require blood products (fresh frozen plasma and platelets) (24 vs. 36%, $p = 0.042$).
- c. Post-operative pain: Randomized control trials (RCTs) [19] and meta-analysis [20] have shown reduced pain scores with MIAVR. Limited spreading and retraction of the chest wall minimizes the disruption of the costo-chondral and costo vertebral joints. It leads to decreased use of narcotic analgesia in the post-operative period and early ambulation, leading to a more rapid return to an active work life.
- d. Ventilation time: Stolinski et al. [21] reported ventilation time of 9.7 ± 5.9 h after AVR and 7.2 ± 3.2 h after ART-AVR ($p < 0.001$). Pulmonary function test results were lower in conventional AVR than RAMT-AVR ($p = 0.001$) for FEV1, vital capacity, total lung capacity. Phan et al. [17] also showed a reduction in ventilation time of more than 4 h with MIAVR.
- e. Cost-benefit analysis: Due to reduced ventilation time, blood transfusion requirements, shorter ICU and hospital stay, total hospital costs were lower in minimally AVR group (\$36,348 vs. \$38,239, $p = 0.02$) [22].

- f. Mortality: Joseph Lamelas [23] reported a 30-day mortality of 1.63% in 857 isolated MIAVR. Glauber et al. [11] reported in-hospital mortality of 1.5% in 593 patients. At 31.5 months mean follow up time, 94.8% survival was observed.

3. Patient selection

Optimum patient selection is essential for MIAVR. The factors to be taken into consideration include individual surgeon preference and skill sets, the patient's anatomical factors and comorbidities. The commitment and experience of the entire surgical team including anesthetists and perfusionists plays a critical role in the successful outcome.

3.1 Indications

Patients presenting with severe and/or symptomatic aortic valve stenosis or insufficiency requiring an isolated AVR are potential candidates for MIAVR.

3.2 Contraindications

1. Unfavorable chest anatomy: Exposure and operative access to the ascending aorta and aortic valve are compromised in severe chest wall deformities and dislocation of heart and great vessels (e.g., pectus excavatum).
2. Previous thoracic surgery: Patients with previous thoracic surgery—pleurodesis, lobectomy, and pneumonectomy have compromised anatomical exposure and access to the operative field. Such a situation also increases the risks [24] of perioperative complications—bleeding, air leak, conversion to full sternotomy.
3. Calcified ascending aorta: Assessment of a safe area for arterial cannulation and applying the aortic cross clamp requires optimum exposure. Control of bleeding from a calcified aorta—cannulation site, aortotomy—is potentially challenging with limited exposure.
4. Re-operation: Previous cardiac surgery is not an absolute contraindication to MIAVR. It may be a suitable option after previous valvular surgery. However, previous CABG is a contraindication due to risk of damaging patient's bypass grafts and also of inadequate myocardial protection. With full sternotomy, myocardial protection through retrograde cardioplegia, topical cooling and temporary occlusion of patent LIMA during cardioplegic arrest is possible.
5. Small aortic root (<19 mm) or aneurysmal dilation of aorta/sinuses: It may necessitate a concomitant aortic root enlargement and/or aortic root replacement procedure which is better achieved through full sternotomy.
6. Severe left ventricular dysfunction: Patients with an ejection fraction <30%, dilated left ventricles are more prone to intra-operative hemodynamic instability and arrhythmias. These situations can be better managed through full sternotomy.
7. Previous radiotherapy or pericarditis: These lead to intra thoracic and pericardial adhesions making dissection difficult. Temporary epicardial pacing wires may not be placed effectively requiring trans-venous pacing.

3.3 Clinical assessment

Pre-operative physical examination is a mandatory step in the work up and appropriate selection of patients. Important considerations are:

- a. Previous incisions in the chest and groin: These indicate adhesions and distortion of anatomy in the area of dissection. If there are adhesions around right atrium, femoral venous cannulation is a good alternative. It allows for increased exposure of aortic root and ascending aorta.
- b. Increased chest rigidity: Partial retraction of sternum in upper hemi-sternotomy (UHS) or ribs in anterior right mini-thoracotomy (ART) is required for exposure. Increased chest rigidity due to previous chest surgery, chest trauma or ankylosing spondylitis can compromise the retraction required for exposure. Very muscular and, more commonly in young patients, slightly stiff chest walls can be encountered. Costochondral cartilages can be transected in patients with narrow intercostal spaces. Such a step helps to increase exposure. These can be sutured back into position at the end of procedure.
- c. Chest wall deformity: Pectus excavatum is the most common chest wall deformity [25]. It displaces heart to the left. Patients with moderate or severe pectus excavatum with Haller index >3.2 are contraindicated.
- d. Morbid obesity: In obese patients the heart is more cranially displaced, due to excess fat in abdomen. It improves the exposure and access to ascending aorta. But there is also increased difficulty in getting into chest cavity due to abundant subcutaneous and mediastinal fat.
- e. Height: In very tall patients (>185 cm), peripheral venous cannula may not reach the superior vena cava leading to insufficient venous drainage and distention of right atrium/ventricle. Insertion of another venous cannula into superior vena cava and connecting it to venous line through Y-connector can help improve the venous drainage. However, the heart is more caudally placed in very tall patients, impacting the distance to be negotiated to reach the aortic valve.

4. Pre-operative investigations

1. Chest X-ray: It helps to (a) identify acute and chronic lung pathology, (b) assess basic thoracic anatomy and (c) To note generally that aortic valve is in close relation to 4th intercostal space.
2. ECG: Pre-operative conduction disorders are an independent risk factor for permanent pacemaker insertion [26]. Use of rapid deployment or suture less bio prosthesis increases the risk of complete atrioventricular block. The possible reason could be increased pressure on aortic annulus and left ventricular outflow tract (LVOT) and then on the conduction tissue.
3. Echocardiography: It is the gold standard to assess the aortic valve pathology. Size of the aortic annulus, gradients across the aortic valve, bicuspid or tricuspid aortic valve, and left ventricle ejection fraction are all the important information to be gathered prior to surgery.

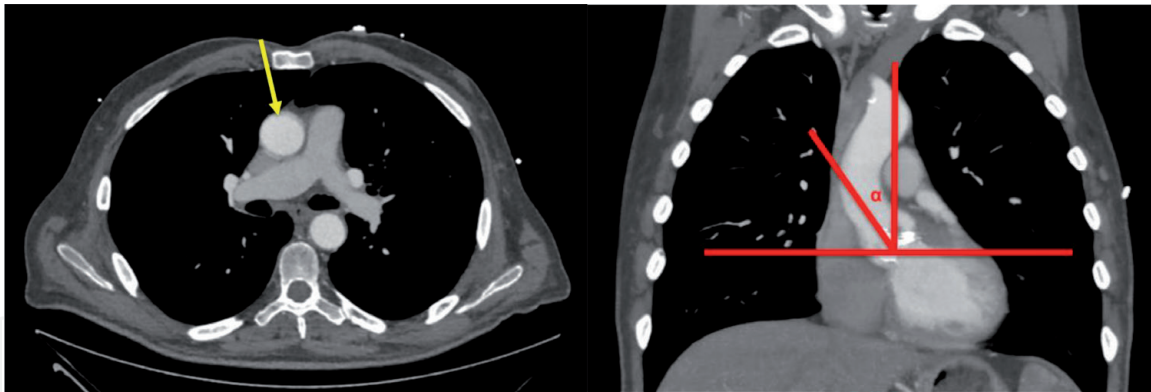


Figure 1.
 At the level of the main pulmonary artery, the ascending aorta is rightward (more than one half located on the right in respect to the right sternal border). The distance from the ascending aorta to the sternum does not exceed 10 cm.

4. CT-scan: Pre-operative non-contrast axial CT scan is mandatory before MIAVR through a right anterior mini-thoracotomy (RAMT) approach, in contrast to mini-sternotomy (MS) approach. Patients are suitable for RAMT-MIAVR only if the following criteria are met: (a) At the level of main pulmonary artery, the ascending aorta is rightward (more than one half located on the right in respect to the right sternal border.) (b) The distance from ascending aorta to sternum does not exceed 10 cm. (c) The alpha angle (angle between angle midline and inclination of ascending aorta) should be $>45^\circ$ (**Figure 1**).
5. Coronary angiography: It is the gold standard investigation for detection of coronary artery anatomy and pathology. Its importance is (a) to detect abnormal coronary anatomy which influences myocardial protection strategies (b) in finding of critical coronary artery lesions which may change an isolated AVR procedure to AVR + CABG. This will change the approach for the procedure required to a full sternotomy.
6. Peripheral femoral Doppler: It is an extremely important investigation to assess the size of femoral vessels especially the femoral artery. Diameter less than 5 mm may not be adequate for femoral arterial cannulation and to maintain adequate flows on cardiopulmonary bypass. Also, it is important to rule out any atherosclerotic plaques in femoral arteries, which can interfere with the passing of a guide wire for femoral cannulation. If so, it may be necessary to change the cannulation site from femoral to central.

5. Surgical techniques

The two most commonly used approaches today are (a) Ministernotomy and (b) Right anterior minithoracotomy (**Figure 2**).

- a. Ministernotomy: It is the most common technique in use. A 6–10 cm midline vertical incision, with a partial J sternotomy is made. Murtuza et al. [27] reported superior results in peri-operative mortality, shorter ventilation time, ICU and hospital stay compared to full sternotomy AVR.
- b. Right anterior minithoracotomy: It is the second most frequently used approach. Few studies have analyzed this approach. Glauber et al. [28] in their 192 patient series reported 0.7% in-hospital mortality. Compared to mini-sternotomy, right anterior mini-thoracotomy patients had lower post-operative

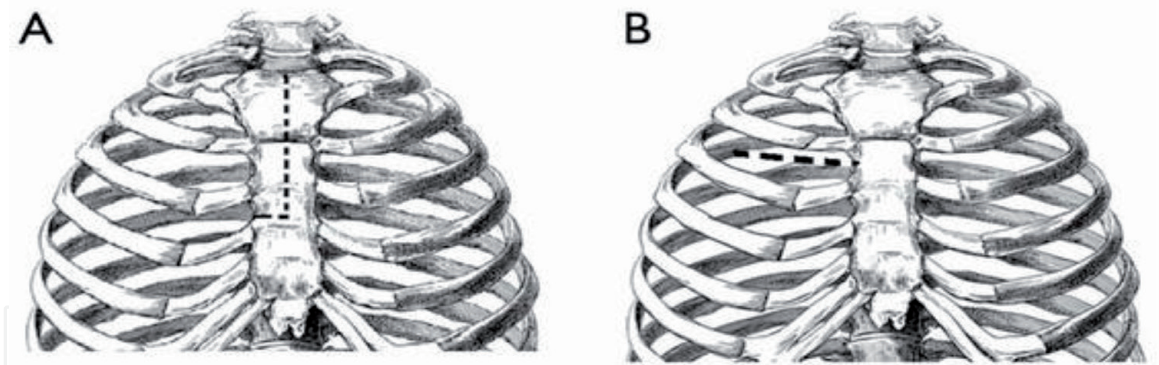


Figure 2.
Minimally invasive incisions: (A) mini sternotomy, (B) right anterior mini thoracotomy.

atrial fibrillation (19.5 vs. 34.2%), shorter ventilation time (median 7 vs. 8 h = 0.003) and a shorter hospital stay (median 5 vs. 6 days) [29].

6. Right anterior mini-thoracotomy approach

We shall now discuss our technique outlining key steps, safeguards and pitfalls.

6.1 Patient positioning and preparation

It is very important to communicate clearly with all team members including anesthetists, perfusionists and theatre nursing staff, the minimally invasive approach planned.

1. Patient is placed supine with a pressure bag inflated below the right shoulder to slightly elevate the right chest.
2. Midline sternotomy incision is marked in case emergency conversion is required intraoperatively. Wide preparation of the chest.
3. Incision is marked in the right 2nd intercostal space for right anterior mini-thoracotomy.
4. Trans-oesophageal echocardiography (TOE) is a mandatory tool to help in placement of femoral venous cannula and retrograde cardioplegia cannula.
5. Defibrillation pads should be attached on the left side of the chest and on the back. Sterile pediatric internal paddles should be available on table, in case external defibrillator pads malfunction.
6. Sternal saw is kept on table, if required in emergency so that precious time is not wasted.
7. Both groins are exposed. It is important to angulate the operation table to optimally expose the groin.
8. Right radial catheter and Swan Ganz catheter is inserted.
9. Left internal jugular vein central line is inserted if central SVC cannulation is planned.

6.2 Chest Approach

1. Chest is opened first as it helps in first hand inspection of pleural cavity and also helps in manual guidance of femoral venous cannula towards superior vena cava.
2. 5–6 cm transverse incision is made over right 2nd intercostal space.
3. Right internal mammary artery and vein are clipped and divided.
4. Inferior rib is transected at the costochondral junction which can be re-approximated with a vicryl suture at the end of the procedure. It increases the operative space and is a much better option than forceful mechanical retraction.
5. Soft tissue retractor and intercostal rib spreader further increase the exposure.
6. Pericardium is opened over right atrium and extended towards the inferior vena cava taking care of the phrenic nerve. Pericardial opening is extended towards the ascending aorta, carefully dissecting the thymic fat. Care is taken not to open the pericardium up to its attachment to aorta, as it can compromise pericardial stay suture placement. Carefully placed pericardial sutures provide exposure of the aorta.

6.3 Cannulation for cardio-pulmonary bypass

About 3–4 cm transverse incision is made above the right inguinal crease. Femoral artery and vein along with branches are dissected and looped with vascular tape. Vascular clamp is placed proximally. Longitudinal incision is made over femoral artery and vein and cannulae are inserted into respective vessels after releasing the vascular clamp. Alternatively, a Seldinger technique may be used for peripheral vessel cannulation (**Figure 3**).

Cannula size is based on the size of the femoral vessels and body surface area. The femoral venous cannula is placed into the SVC under TOE guidance. After femoral decannulation, femoral vessels are repaired with prolene 6-0/7-0.

If peripheral vascular disease is suspected, axillary or central aortic cannulation is performed.

Vacuum assisted venous drainage of 30–70 mmHg as needed may be used to maintain bypass flows and to decompress the right heart. If venous drainage is inadequate, additional central SVC cannulation is required.

6.4 Myocardial protection

Under TOE guidance, a retrograde cardioplegia cannula is inserted through right atrium body/appendage. Its downward retraction facilitates the exposure of the aorta (**Figures 4 and 5**).

A left ventricular vent is passed through right superior pulmonary vein. It is very helpful in unloading the heart and also in deairing the heart while coming off cardiopulmonary bypass.

The aorta is cross clamped using Chitwood clamp through separate incision in the chest wall near the anterior axillary line. Dissection between aorta and pulmonary artery is not required. If bleeding occurs in this area, it is difficult to control.

Antegrade cardioplegia is delivered. If such is not possible due to moderate or severe aortic regurgitation, direct coronary ostial cardioplegia can be given along with retrograde cardioplegia. A CO₂ catheter is placed in the operative field for deairing.

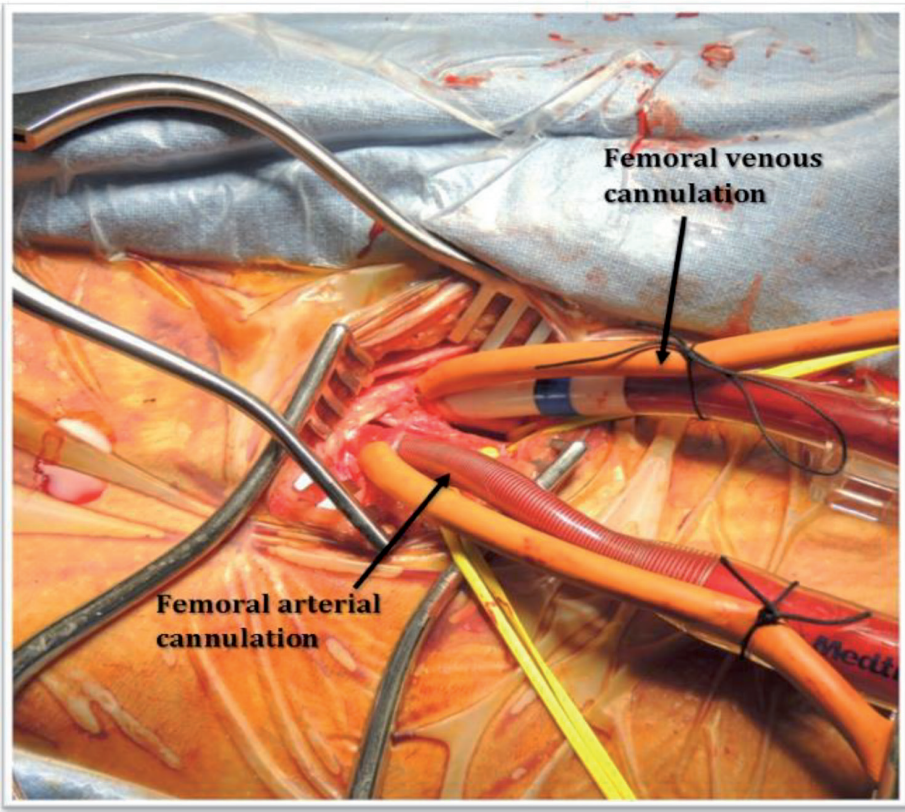


Figure 3.
Peripheral femoral cannulation.

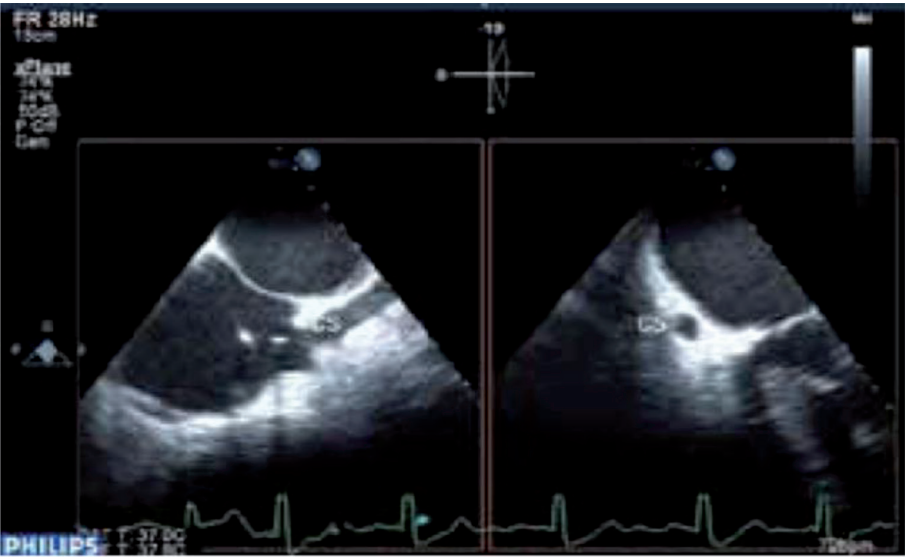

Figure 4.
Retrograde cardioplegia cannula in coronary sinus under TOE guidance.

6.5 Aortotomy

The aortotomy is made at the level of fat pad on aorta. Stay sutures are placed on either edge of the aortotomy for retraction. Resection of valve leaflets, debridement of annulus and valve replacement is done as per standard techniques (**Figures 6 and 7**).

Resection and decalcification of a severely stenotic calcified valve is the most difficult step. Using commissural stay sutures and aortic wall retraction sutures significantly improve the exposure. Placing small wet gauze inside the left ventricle

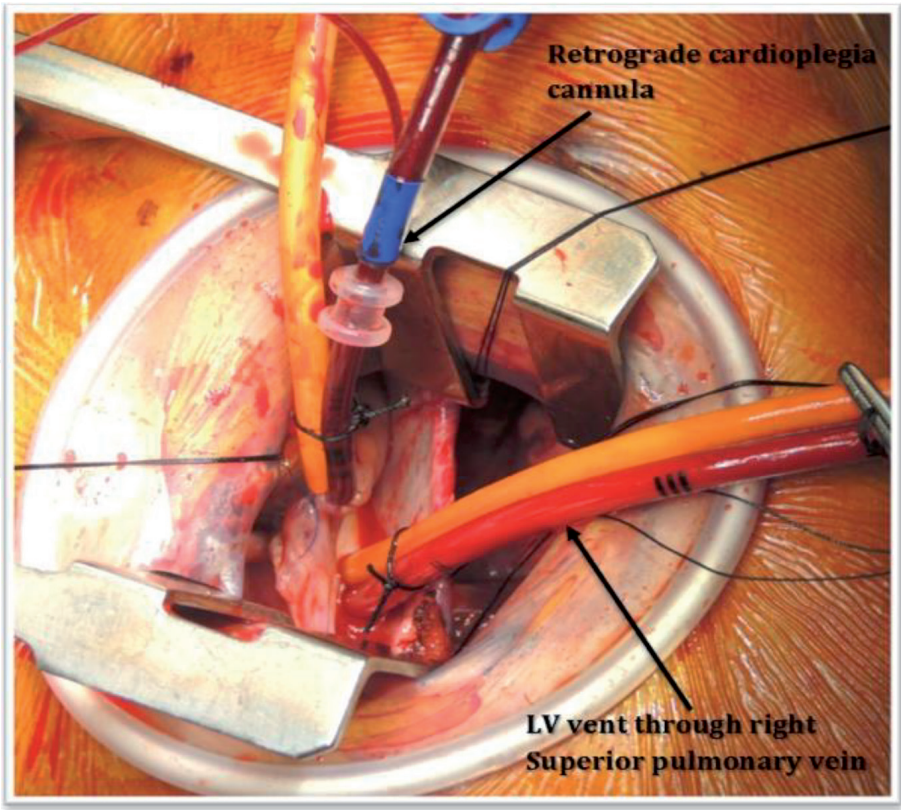


Figure 5.
Retrograde cardioplegia with LV vent in situ.

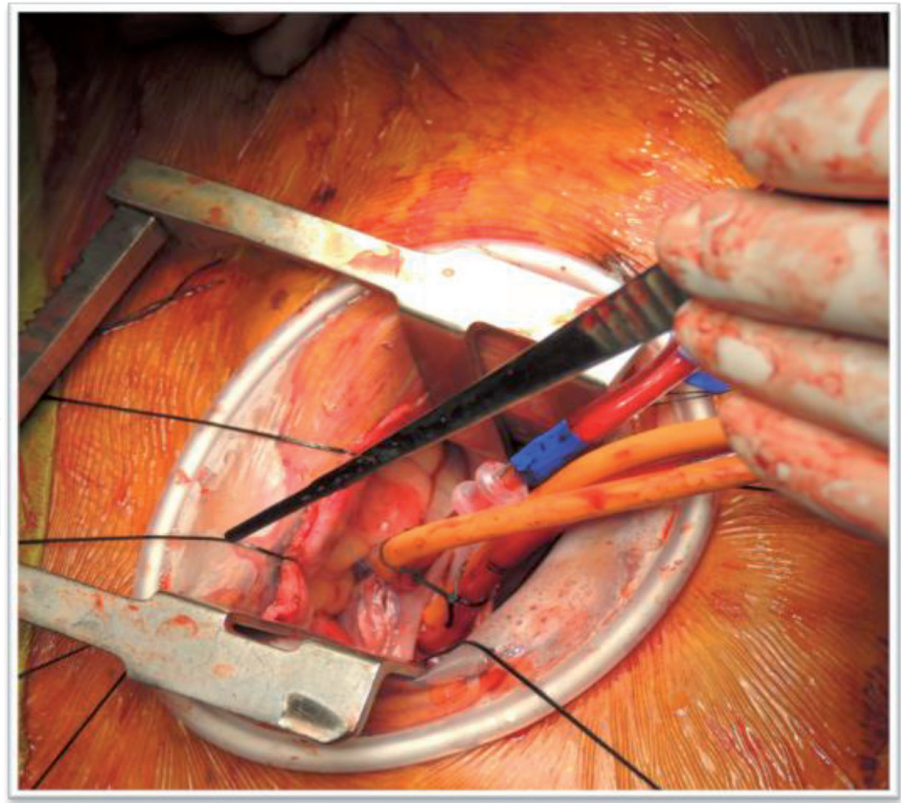


Figure 6.
Aorta cross-clamped with Chitwood clamp through separate skin stab.

while doing decalcification prevents small calcium fragments from getting lost. This wet gauze can be taken out after decalcification has been completed. Similar to the conventional sternotomy approach, decalcification should be followed by thorough saline flushing of the left ventricle (**Figures 8 and 9**).

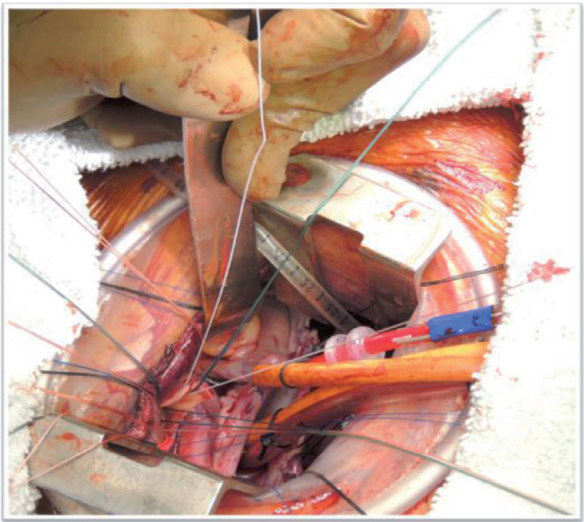


Figure 7.
Aortic valve sutures in place—interrupted pledgeted.

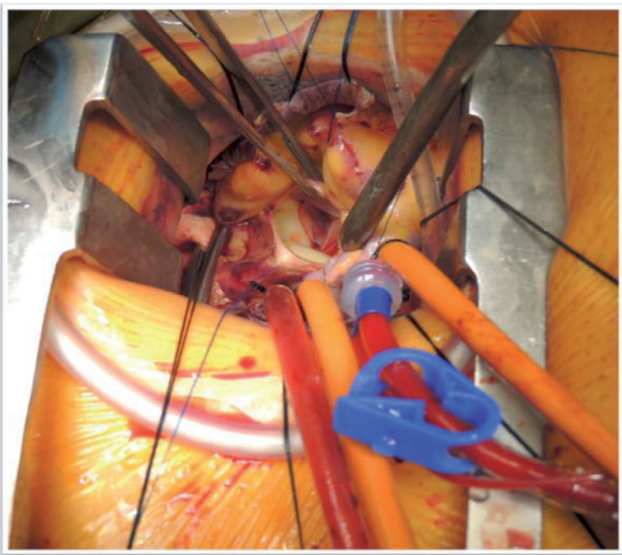


Figure 8.
Aortic valve replaced.

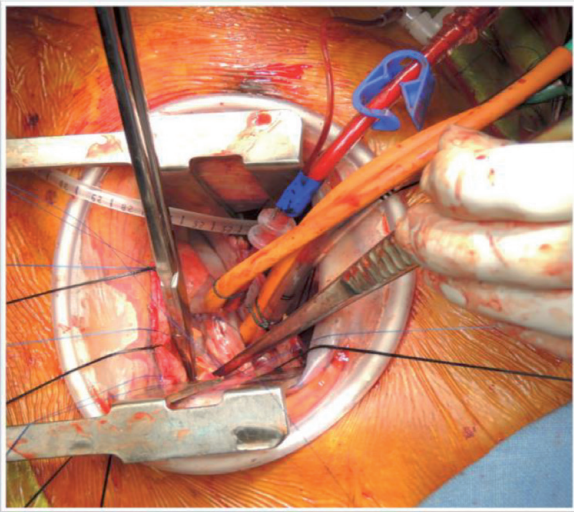


Figure 9.
Aortotomy closure.

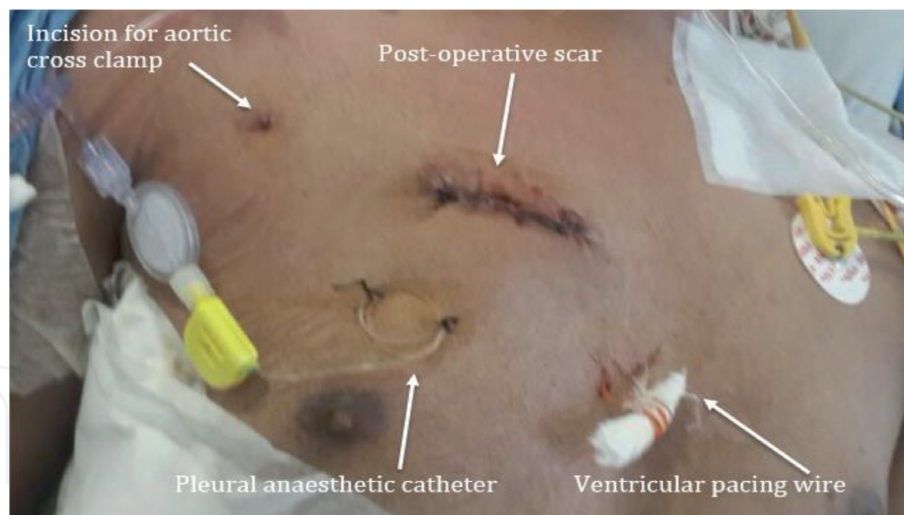


Figure 10.
Post-operative scar.

6.6 Pacemaker wire placement

After aortotomy closure, but before removing the cross clamp, ventricular pac-ing wire (s) is/are placed on the anterior aspect of the right ventricle. It's extremely difficult to place pacing wires on a beating right ventricle and sometimes, bleeding from the right ventricle can force conversion to sternotomy.

Defibrillation is performed using external pads or pediatric paddles if required.

6.7 Deairing

After aortotomy closure and before the cross clamp is removed, ventilate the lungs and fill the heart and remove the air through the aortic root vent. Insufflating the operative field with carbon dioxide gas helps in deairing. It's important to ventilate the lungs and let the heart eject blood during the reperfu-sion period. TOE plays a very important role in assessing the effectiveness of deairing maneuvers.

The heart is not manipulated directly for air removal maneuvers. Left-right positioning of patient and external compression of chest wall and forceful shaking of rib retractor may be performed to agitate and disperse air bubbles.

6.8 Weaning from cardio-pulmonary bypass and closure

After appropriate ABG results and optimum rewarming, CPB is gradually dis-continued. Femoral venous and arterial cannulas are removed and femoral vessels repaired with Prolene 6-0/7-0.

For pain relief, epidural anesthetic catheter is placed into pleural space and 0.25% bupivacaine is given for 72 h.

Ribs are approximated with vicryl or prolene suture and muscle layers closed in standard fashion (**Figure 10**).

7. Conversion to full sternotomy

Conversion to full sternotomy is a psychological stress for the team and an addi-tional scar on the patient. It occurs in 0.8–8.0% with 3–4% average in most of the series [20]. Possible reasons include inadequate exposure, bleeding from the right

ventricle, aortotomy site or right internal mammary, or an inability to defibrillate. A ministernotomy incision can be extended to full sternotomy. With right mini-thoracotomy, incision can be extended to a transverse sternotomy or, alternatively, full sternotomy can be created. It leads to longer bypass times, adding to the morbidity of the procedure [30].

8. Sutureless MIAVR

Encouraging results have been reported with the three different suture less or rapid deployment bio prosthesis [31, 32]. Micelli et al. [33] reported 38 and 40% decrease in cross clamp and CPB time in RAMT group and 43 and 35% decrease in MS group. The operative mortality was 0.7% with a very low incidence of paravalvular leak (1.8%), a frequent complication of TAVI.

Santarpino et al. [34] reported similar improved results with suture less valves, suggesting that suture less MIAVR may become the first line treatment in high risk patients in the spectrum between TAVI and conventional AVR. Randomized controlled trials are required to confirm this.

9. Concerns regarding MIAVR

Although MIAVR has shown consistently good results compared to full sternotomy, there are still areas of concern:

- a. MIAVR is associated with longer cross clamp and CPB times, which are known to have adverse impact upon the results. These times assume greater significance in elderly and high-risk patients. However, the use of suture less valves has significantly reduced these times.
- b. MIAVR is not very “surgeon friendly” due to being a complex and technically challenging procedure. It has a longer learning curve due to the deeper operative field and limited working space for exposure and implantation of the prosthetic valve.
- c. MIAVR has been criticized for the high cost associated with the setting up of a unit of minimally invasive surgery. But these costs are more likely to be compensated by shorter ICU and hospital stays, less blood transfusion requirements and fewer post-operative complications.
- d. There is also known morbidity associated with peripheral cannulation. It may be associated with a wound infection, pseudo aneurysm formation, limb ischemia and neurological complications [35].

10. The future

Developments in minimally invasive techniques could potentially lead to totally endoscopic aortic valve replacement (TEAVR) as standard of care for aortic valve replacement [36]. It aims to avoid any sternal fracture or costal spreading by decreasing iatrogenic chest wall trauma. It also aims to maintain advantages of a surgical approach over TAVI. Suture less bio prosthesis technologies are essential to do valve replacement procedures using trocars.

11. Conclusion

MIAVR using RAMT or MS is a safe and effective procedure with excellent post-operative outcomes. Although cross clamp and CPB times may be longer than conventional AVR, use of suture less valve may increase the permeation of MIAVR in the cardiac surgery community. MIAVR with suture less bio prosthesis may be a real alternative to TAVI for the high risk operable patient.

Conflict of interest

The authors have no conflict of interest.

Abbreviations and acronyms

AVR	aortic valve replacement
CPB	cardiopulmonary bypass
MIAVR	minimally invasive aortic valve replacement
MS	mini-sternotomy
RAMT	right anterior mini-thoracotomy
TEAVR	total endoscopic aortic valve replacement
SVC	superior vena cava
TOE	trans oesophageal echocardiography
ABG	arterial blood gas

Author details

Imran Khan¹, Julian A. Smith^{1*} and Naresh Trehan²

1 Department of Cardiothoracic Surgery, Monash Health and Department of Surgery, School of Clinical Sciences at Monash Health, Monash University, Clayton, Victoria, Australia

2 Medanta Heart Institute, Gurgaon, India

*Address all correspondence to: julian.smith@monash.edu

IntechOpen

© 2019 The Author(s). Licensee IntechOpen. This chapter is distributed under the terms of the Creative Commons Attribution License (<http://creativecommons.org/licenses/by/3.0>), which permits unrestricted use, distribution, and reproduction in any medium, provided the original work is properly cited. 

References

- [1] Holzhey D, Mohr FW, Walther T, Mollmann H, Beckmann A, et al. Current results of surgical aortic valve replacement: Insights from the german aortic valve registry. *The Annals of Thoracic Surgery*. 2016;**101**:658-666
- [2] Joshi P, Doshi C, Vinchurkar M, Thosani R, Mahajan SV. Minimally invasive combined aortic and mitral valve replacement. *Heart, Lung and Circulation*. 2011;**20**(4):231-233
- [3] Cosgrove DM 3rd, Sabik JF. Minimally invasive approach for aortic valve operation. *The Annals of Thoracic Surgery*. 1996;**62**:596-597
- [4] Bennetti FJ, Mariana MA, Rizzardi JL, Bennetti I. Minimally invasive aortic valve replacement. *The Journal of Thoracic and Cardiovascular Surgery*. 1997;**113**:806-807
- [5] Gundry SR, Shattuch OH, Razzouk AJ, Del Rio MJ, Sarawu FF. Facile minimally invasive cardiac surgery via ministernotomy. *The Annals of Thoracic Surgery*. 1998;**65**:1100-1104
- [6] Marcovola FJF, Campisi S, Faure M, Sandri F. Totally endoscopic aortic valve replacement (TEAVR). *Annals of cardiothoracic surgery*. 2015;**4**(2):196-197
- [7] Beckmann A, Funkat AK, Lewandowski J, Frie M, Ernst M, et al. German heart surgery report 2016: The annual updated registry of the german society for thoracic and cardiovascular surgery. *The Thoracic and Cardiovascular Surgeon*. 2017;**65**:505-518
- [8] Hamm CW, Mollman H, Holzhey D, Beckmann A, Veit C, Figulla HR, et al. The german aortic valve registry (GARY): In-hospital outcome. *European Heart Journal*. 2014;**35**:1588-1598
- [9] Kaneko T, Vassileva CM, Englum B, Kim S, Yanmie M, Brennan M, et al. Contemporary outcomes of repeat aortic valve replacement: A benchmark for transcatheter valve-in-valve procedures. *The Annals of Thoracic Surgery*. 2015;**100**:1298-1304
- [10] Thourani VH, Borger MA, Holmes D, Maniar H, Pinto F, et al. Transatlantic commentary on transcatheter aortic valve replacement. *Journal of Thoracic and Cardiovascular Surgery*. 2017;**52**:1-13
- [11] Glauber M, Gilmanov D, Farneti PA, Kalluski E, Miceli A, et al. Right anterior minithoracotomy for aortic valve replacement: 10 year experience of a single centre. *The Journal of Thoracic and Cardiovascular Surgery*. 2015;**150**:548-556
- [12] Schmitto JD, Mokashi SA, Cohn LH. Minimally invasive valve surgery. *American College of Cardiology*. 2010;**56**:455-462
- [13] Rosengart K, Feldman T, Borger MA, et al. Percutaneous and minimally invasive valve procedures: A scientific statement from the american heart association council on cardiovascular surgery and anaesthesia, council on clinical cardiology, functional genomics and translational biology, interdisciplinary working group and quality of care and outcomes research interdisciplinary working group. *Circulation*. 2008;**117**:1750-1767
- [14] STS National Database Spring 2003, Executive Summary. Durham, NC: Duke Clinical Research Institute; 2003
- [15] Tabata M, Fukui T, Takanashi S. Do minimally invasive approaches improve outcomes of heart valve surgery? *Circulation Journal*. 2013;**77**:2232-2239
- [16] Khoshbin E, Prayaga S, Kinsella J, Sutherland FW. Mini-sternotomy for aortic valve replacement reduces the

length of stay in cardiac intensive care unit: Met analysis of randomized control trials. *BMJ Open*. 2011;1:e000266

[17] Phan K, Xie A, Di Eusanio M, Yan TD. A meta-analysis of minimally invasive versus conventional sternotomy for aortic valve replacement. *The Annals of Thoracic Surgery*. 2014;98:1499-1511

[18] Burdett CL, Lage IB, Goodwin AT, White RW, Khan KJ, et al. Manubrium—Limited sternotomy decreases blood loss after aortic valve replacement surgery. *Interactive Cardiovascular and Thoracic Surgery*. 2014;19(4):605-610

[19] Borger M, Vladim M, Lenard C, Knosalla C, Markus R, et al. A randomized multicenter trial of minimally invasive rapid deployment versus conventional full sternotomy aortic valve replacement. *The Annals of Thoracic Surgery*. 2015;99:17-25

[20] Brown ML, Mckellar SH, Sundt TM, Schaff HV. Ministernotomy versus conventional sternotomy for aortic valve replacement: A systemic review and meta-analysis. *The Journal of Thoracic and Cardiovascular Surgery*. 2009;137:670.e5-679.e5

[21] Stolinski J, Musial R, Plicner D, Andres J. Respiratory system function after minimally invasive aortic valve replacement surgery. A case control study. *Innovations*. 2017;12(2):127-136

[22] Ghanta RK, Lapar DJ, Kern JA, Kron IL, Speir AM, et al. Minimally invasive aortic valve replacement provides equivalent outcomes at reduced cost compared with conventional aortic valve replacement: A real-world multi-institutional analysis. *The Journal of Thoracic and Cardiovascular Surgery*. 2015;149(4):1060-1065

[23] Lamellas. Minimally invasive aortic valve replacement: The “Miami Method”. *Annals of cardiothoracic surgery*. 2015;4(1):71-77

[24] Von Segesser LK, Westaby S, Pomar J, Loisanche D, Groscurta P, et al. Less invasive aortic valve surgery: Rational & technique. *European Journal of Cardio-Thoracic Surgery*. 1999;15:781-785

[25] Shaalan AM, Kasbi I, Elwakeel EE, Elkamali YA. Outcome of surgical repair of pectus excavatum in adults. *Journal of Cardiothoracic Surgery*. 2017;12:72

[26] Toledano B, Bisbal P, Camara ML, Labata C, Berastequi E, et al. Incidence and predictors of new onset atrioventricular block requiring pacemaker implantation after sutureless aortic valve replacement. *Interactive Cardiovascular and Thoracic Surgery*. 2016;23:861-868

[27] Murtuza B, Pepper JL, Stanbridge RD, et al. Minimal access aortic valve replacement: Is it worth it? *The Annals of Thoracic Surgery*. 2008;85:1121-1131

[28] Glauber E, Micelli A, Bevilacqua S, et al. Minimally invasive aortic valve replacement via right anterior minithoracotomy: Early outcomes and midterm follow up. *The Journal of Thoracic and Cardiovascular Surgery*. 2011;142:1577-1579

[29] Micelli A, Murzi M, Gilmanov D, Fuga R, Ferrarini M, et al. Minimally invasive aortic valve replacement using right minithoracotomy is associated with better outcomes than ministernotomy. *The Journal of Thoracic and Cardiovascular Surgery*. 2014;148:133-137

[30] Tabata M, Umakanthan R, Khalpey Z, et al. Conversion to full sternotomy during minimal access cardiac surgery: Reasons and results during a 9.5 year experience. *The Journal of Thoracic and Cardiovascular Surgery*. 2007;134:165-169

[31] Folliguet TA, Laborde F, Zannis K, et al. Sutureless Perceval aortic valve replacement: Results of two European

centres. *The Annals of Thoracic Surgery*. 2012;**93**:1483-1488

[32] Kocher AA, Laufer G, Haverich A, et al. One year outcomes of the surgical treatment of aortic stenosis with a next generation surgical aortic valve (TRITON) trial: A prospective multicenter study of rapid—Deployment aortic valve replacement with the EDWARDS INTUITY valve system. *The Journal of Thoracic and Cardiovascular Surgery*. 2013;**145**:110-115; discussion 115-6

[33] Micelli A, Santarpino G, Pfeiffer S, et al. Minimally invasive aortic valve replacement with Perceval S sutureless valve: Early outcomes and one year survival from two European centres. *The Journal of Thoracic and Cardiovascular Surgery*. 2014;**148**:2838-2843

[34] Santarpino G, Pfeiffer S, Jessi J, et al. Sutureless replacement versus transcatheter valve implantation in aortic valve stenosis: A propensity matched analysis of 2 strategies in high risk patients. *The Journal of Thoracic and Cardiovascular Surgery*. 2014;**147**:561-567

[35] Murzi M, Cerillo AG, Miceli A, et al. Antegrade and retrograde arterial perfusion strategy in minimally invasive mitral-valve surgery: A propensity score analysis on 1280 patients. *European Journal of Cardio-Thoracic Surgery*. 2013;**43**:e167-e172

[36] Vola M, Fuzelier JF, Chavent B, et al. First human totally endoscopic aortic valve replacement: An early report. *The Journal of Thoracic and Cardiovascular Surgery*. 2014;**147**:1091-1093