

We are IntechOpen, the world's leading publisher of Open Access books Built by scientists, for scientists

6,900

Open access books available

185,000

International authors and editors

200M

Downloads

Our authors are among the

154

Countries delivered to

TOP 1%

most cited scientists

12.2%

Contributors from top 500 universities



WEB OF SCIENCE™

Selection of our books indexed in the Book Citation Index
in Web of Science™ Core Collection (BKCI)

Interested in publishing with us?
Contact book.department@intechopen.com

Numbers displayed above are based on latest data collected.
For more information visit www.intechopen.com



Behcet's Disease

Karina Julian and Bahram Bodaghi

Abstract

Defined as a systemic vasculitis developing in a particular genetic background, uveitis is one of the hallmarks to diagnose Behcet's disease and also one of the important clinical criteria to start systemic treatment. Isolated anterior non granulomatous uveitis with hypopyon, even though a classic clinical picture, actually develops in a minority of cases. In most patients, uveitis is posterior, associated to small vessel occlusive retinal vasculitis, carrying a high risk of permanent retinal damage and subsequent severe visual loss. The guarded natural prognosis of the disease has positively changed in the last decennials with the introduction of biologic immunosuppressant agents in the field of uveitis. Vision can be preserved in most cases provided a prompt early diagnosis and adequate therapy. The potential role of oral bacteria as a triggering factor for autoinflammation in predisposed hosts is interesting, opening the door to prevention in this still not well-understood severe uveitis.

Keywords: hypopyon uveitis, occlusive vasculitis, retinitis, retinal atrophy, immunosuppressants

1. Introduction

Named after the Turkish ophthalmologist, Hulusi Behcet (who described in 1937 the classic triad of oral aphthosis, genital ulcers, and hypopyon uveitis) [1], Behcet's disease (BD) is a systemic relapsing obliterative vasculitis, affecting arteries, veins, and mainly capillaries. Even though almost all organs can eventually be involved, the compromise of the central nervous system (CNS) and eye makes the disease's prognosis guarded and usually urges to start proper treatment.

There is no specific test to diagnose Behcet's disease: by definition, its diagnosis is a clinical one. In 1990, the International Study Group for Behcet's disease established a set of diagnostic criteria in an attempt to unify the five different ones used by that time [2]. They required the presence of oral ulcerations plus any two of genital ulcerations, typical defined eye lesions, typical defined skin lesions or a positive pathergy test.

Far from being solved, the debate on the diagnostic criteria is still active, and many other sets have been proposed. Among them, the Behcet's Disease Research Committee of Japan defines the diagnosis as complete or incomplete upon the presence of major and minor symptoms (**Table 1**) [3]. The Dilsen criteria (revised in 2000) seems more suitable to the European patients suffering from Behcet's disease (**Table 2**) [4, 5].

1. Major symptoms
(a) Recurrent aphthous oral ulcers
(b) Skin lesions: erythema nodosum-like lesions, thrombophlebitis, folliculitis, and cutaneous hypersensitivity
(c) Ocular symptoms: iridocyclitis, retinitis, and sequelae of uveitis
(d) Genital ulcers
2. Minor symptoms
(a) Arthritis
(b) Intestinal Behcet's disease
(c) Epididymitis
(d) Vascular lesions
(e) Neurologic lesions
3. Examination
Pathergy test
4. Diagnosis
A. Complete type: all four major symptoms present
B. Incomplete type:
• Three major symptoms present
• Two major and two minor symptoms present
• Ocular symptoms and one other major symptom present
• Ocular symptoms and two minor symptoms present

Table 1.
Behcet's Disease Research Committee of Japan: diagnostic criteria.

Three out of the five following criteria are required to diagnose Behcet's disease
1. Recurrent oral ulcers
2. Recurrent genital ulcers
3. Skin lesions
4. Eye lesions
5. Thrombophlebitis
(+) Skin pathergy test
Always exclude other causative factors

Table 2.
Behcet's disease: the Dilsen criteria.

2. Clinical picture

2.1 Non-ocular disease

Almost every organ and system can eventually be affected by this severe vasculitis. Painful, recurrent oral and genital ulcers are so frequent that their presence is part of the diagnostic criteria [6]. Other skin manifestations are papulopustules,

acneiform dermatitis, and erythema nodosum [7]. Arthritis is also a common manifestation of the disease [8]. Gastrointestinal involvement affects around 3–30% of cases with symptoms overlapping inflammatory bowel disease [9]. Central nervous system (CNS) involvement can touch almost 31% of patients and makes the prognosis guarded [10]. Venous thrombosis and arterial aneurysms are present in around 25% of cases [11].

2.2 Ocular disease

The classic clinical picture is the one of recurrent, bilateral, non-granulomatous posterior or panuveitis with retinal vasculitis. This is the case for almost 80% of patients, while in around 10% disease manifests as anterior, non-granulomatous uveitis with hypopyon and eventually synechiae (**Figure 1**) [12].

Disease seems to be more severe in males, and ocular pain, redness, photophobia, and blurred vision are almost always present.

Retinitis is also a classic and sight-threatening manifestation of posterior segment involvement, leading most of the time to retinal atrophy. Indeed, Behcet's disease is one of the differential diagnoses of macular atrophy related to uveitis (**Figure 2**) [13].

Retinal vasculitis is the hallmark of the disease, it is obliterative in nature, it affects both arteries and veins, and, most importantly, it involves the capillaries [14].

Behcet's disease is mainly a capillaropathy, being fluorescein angiography (FA) essential to its proper diagnosis and management. FA will better delineate areas of non-perfusion (**Figure 3**), capillary leakage (**Figure 4**), and vascular remodeling. The “fern-leaf”-shaped leakage pattern from capillaries, even though not pathognomonic, is highly evocative of BD (**Figure 5**).

Given the highly vascularized nature of choroidal tissue, it is not surprising to see choroidal involvement during active disease. Indocyanine green angiography (ICGA) shows irregular filling of the choriocapillaris, choroidal filling defects, and dye leakage from choroidal vessels [15]. Enhanced depth imaging optical coherence tomography (EDI-OCT) shows increased subfoveal choroidal thickness even in eyes without evident uveitis activity, making this finding a possible indicator of subclinical ocular inflammation in patients with BD [16].

Optic neuropathy (ON), although considered a rare manifestation of Behcet's disease, might actually be overshadowed by uveitis' complications. It can appear during the course of already known BD (and should be considered as part of the neuro-BD disease spectrum), or it can even be the first manifestation of the disease (BD should then be kept in mind as a differential diagnosis of optic neuropathy

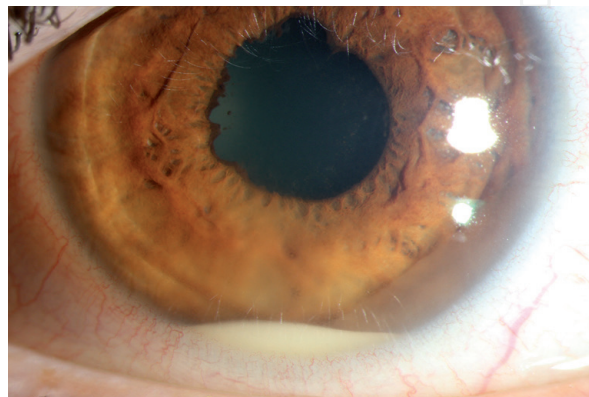


Figure 1.
Hypopyon and nasal synechiae in the left eye of a young patient suffering from acute reactivation of anterior uveitis related to Behcet's disease.

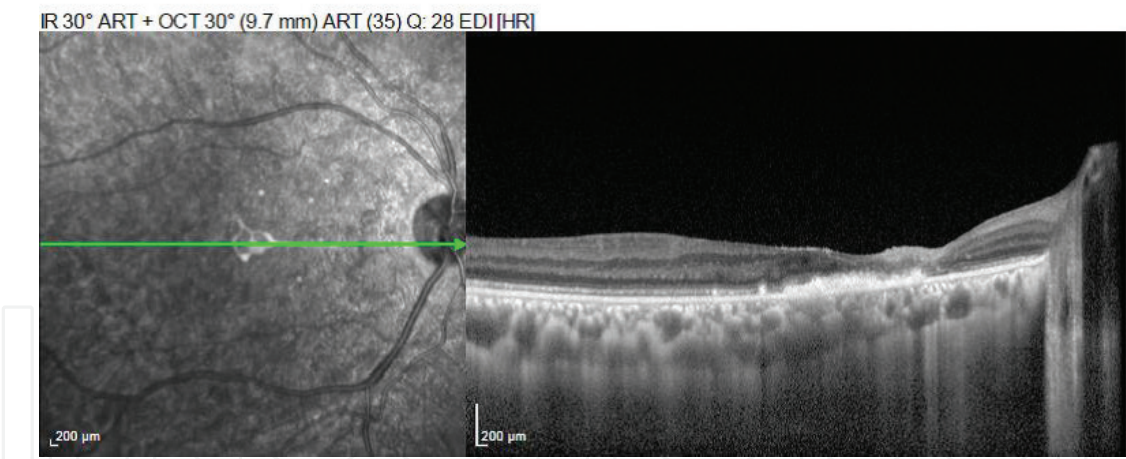


Figure 2.
Horizontal OCT scan from the right eye of a patient with advanced Behcet's disease posterior uveitis. Generalized retinal atrophy and retinal pigment hypertrophy are seen.

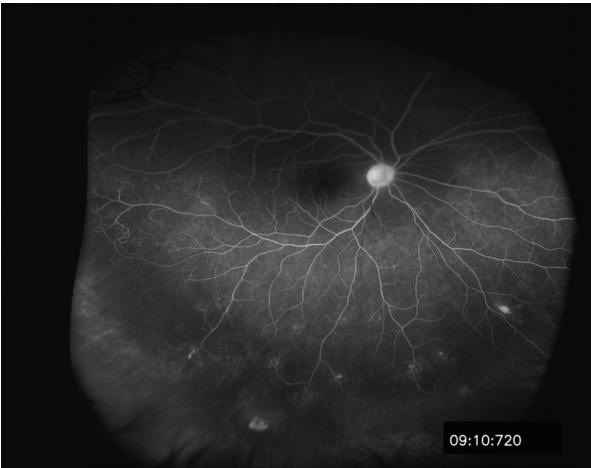

Figure 3.
Late-frame fluorescein angiography showing extensive peripheral areas of retinal non-perfusion affecting the inferior temporal area of the right eye.

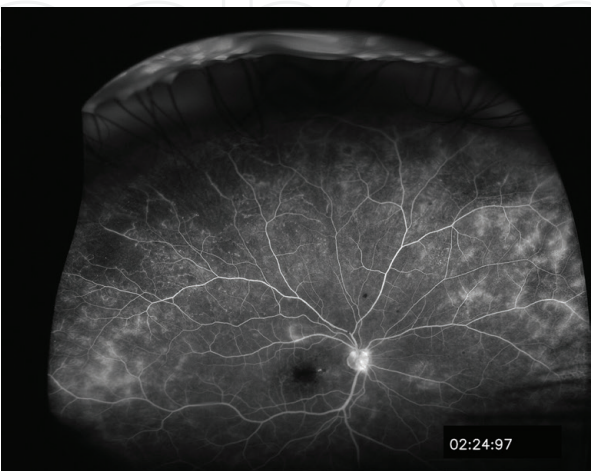


Figure 4.
Early frame fluorescein angiography of the right eye of a patient suffering from Behcet's disease retinal vasculitis. Areas of capillary leakage are present as well as peripheral ischemia and optic disc hyperfluorescence.

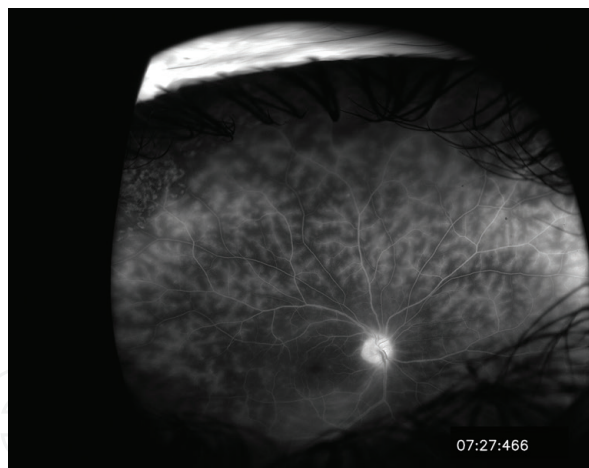

Figure 5.
Late-frame fluorescein angiography of the right and left eye from a patient suffering from Behcet's disease associated with retinal vasculitis. Typical "fern-leaf" pattern of capillary leakage is present.

in regions where its prevalence is high) [17]. The prognosis of BD-associated ON seems not to be as poor as the one of BD uveitis, with excellent response to the combination of corticosteroids and immunosuppressants and recovery as the rule [18, 19]. However, the use of cyclosporine should be avoided in these cases since it could promote the development of neurologic involvement [20].

3. Etiology and pathogenesis

Despite years of research, BD remains idiopathic. Even though there are sporadic cases all around the world, disease is more prevalent along the ancient silk route and in countries located between 30 and 45 north latitude through the Mediterranean Basin, the Middle East, and Far East regions such as China and Japan [21]. This particular geographic distribution points toward a genetic predisposing factor. The high frequency of HLA-B51 among a wide range of affected ethnic populations highlights the importance of a special genetic background: even though not considered as part of the diagnostic criteria, the positivity of HLA-B51 increases the risk of BD in around six times [22].

Besides the classic and well-known predisposition to BD associated with HLA-B51 positivity, new insights on disease's pathogenesis came out from genome-wide association studies (GWAS). The disruption of different biological pathways might determine the intrinsic biological process in multifactorial diseases, as BD. Six biologic pathways have been recently identified as possible mechanisms in the pathogenesis of BD: focal adhesion pathway, MAPK (mitogen-activated protein kinase) signaling, TGF (transforming growth factor) beta signaling, ECM-receptor interaction, complement and coagulation cascades and proteasome pathways [23].

Then, on this special genetic background, environmental factors might play a role as triggers for disease development. Infectious agents have been postulated as these triggering factors. Recently, a relationship between periodontal disease and specific polymorphisms of interleukin (IL)-1alpha and (IL)-1beta in Turkish patients with BD was reported, making periodontitis-induced autoinflammatory response a candidate for the development or severity of BD via IL-1 gene alteration [24]. Improvement of oral health among this high-risk population might affect BD course, leading to a better prognosis [25].

Neutrophils' activation plays a predominant role in BD; this is evidenced through the positivity of pathergy test, one of the diagnostic criteria for the disease [2, 26]. The activation of the innate immune system against environmental and/or autoantigens in this particular genetic background is then perpetuated by the adaptive immune system [27].

4. Diagnosis and differential diagnosis

As it was already stated, diagnosis is clinical and based on the presence of different combinations of symptoms and signs. In the acute attack, patients usually show raised inflammatory acute reactants (sedimentation rate and C-reactive protein) and high levels of white blood cells, mainly neutrophils [28, 29].

HLA-B51 is positive in around 50–70% of cases even though not necessary for the diagnosis [22, 30].

Differential diagnosis of hypopyon uveitis encompasses HLA-B27 associated, endogenous/exogenous endophthalmitis, toxic anterior segment syndrome (TASS) after cataract surgery, and masquerade syndromes [31–35]. BD-associated retinal vasculitis is unique in its predilection for capillaries but a similar picture can eventually be found in cases of HLA-B27 posterior uveitis with retinal vasculitis [36–39].

5. Treatment

Topical treatment is reserved for the minority of cases in which anterior uveitis is the only ocular disease manifestation. Prednisolone acetate with or without cyclopentolate is usually enough to stop episodes of anterior non-granulomatous uveitis. However, if these attacks are frequent or inflammatory quiescence requires more than three drops per day of prednisolone acetate for long periods, systemic treatment should be initiated.

The majority of cases presenting with posterior uveitis will require systemic treatment to control the sight-threatening manifestations of the disease.

High-dose systemic corticosteroids (1 g intravenous of Solu-Medrol or 1 mg/kg/day of oral prednisone) are useful in severe acute inflammatory attacks. However, they should not be administered alone given the high risk of flare up while tapering and the side effect profile of high doses [40].

Azathioprine and cyclosporine have both shown to be effective in BD's uveitis in two different randomized clinical trials (RCT) [41–43]. In many cases, a single agent is not enough to control uveitis, and a combination of them is administered. Drugs are usually well tolerated in long term, providing the proper check of their own side effects' profile is performed (liver toxicity for azathioprine, renal toxicity for cyclosporine). The likelihood of patients on cyclosporine to develop CNS complications should be kept in mind, and the drug is not recommended in the management of BD's associated optic neuropathy [44].

High levels of tumor necrosis factor (TNF) alpha are present in BD's uveitis [45]. The blockage of this inflammatory pathway is therefore a very effective approach to disease control. Infliximab (a chimeric monoclonal antibody against TNF alpha) and adalimumab (a fully humanized monoclonal antibody) are both widely used in the treatment of BD-associated posterior uveitis with high rates of success [46]. Adalimumab has the advantage of subcutaneous administration, theoretically improving patients' quality of life [47].

Other anti-TNF alpha molecules, such as certolizumab pegol and golimumab, have also shown positive results in small case series of BD's uveitis [48, 49].

Interferon alpha-2^a is a very effective biologic treatment for BD's associated posterior uveitis [50]. Subcutaneously administered, it has rapid positive effect and also long relapse-free period making prophylactic maintenance treatment unnecessary [51, 52]. Drug is administered as a monotherapy after discontinuation of all previous immunosuppressive drugs (including corticosteroids). However, the associated flu-like syndrome limits the use of this important agent in the management of BD's uveitis.

Cytotoxic agents (chlorambucil and cyclophosphamide) were in the past the drug of choice for this severe form of uveitis [53, 54]. Nowadays, however, given the more specific and less toxic agents available, they are only used in those settings

Intravitreal steroids (either triamcinolone acetonide, fluocinolone, or dexamethasone implant) are adjuvant rescue treatment in recalcitrant cases not responding to systemic medication or whenever systemic medication is contraindicated [55]. Their effect is always transitory and associated with the risk of local complications (mainly cataract and glaucoma).

6. Prognosis

Visual prognosis is directly related to anatomical location of inflammation and rapid introduction of proper treatment. The minority of cases manifesting only by anterior uveitis usually shows excellent visual prognosis. Posterior uveitis, however, might be sight-threatening even if only one acute attack involves the macula. The development of modern biologic agents has positively changed the natural guarded prognosis of this disease even though there is still a low proportion of cases that will not respond to different combinations of treatment.

Author details

Karina Julian^{1,2*} and Bahram Bodaghi³

1 Eye Institute, Cleveland Clinic Abu Dhabi, Abu Dhabi, United Arab Emirates

2 Cleveland Clinic Lerner College of Medicine, Case Western Reserve University, United States

3 IHU FOReSIGHT, Sorbonne University, Pitié-Salpêtrière Hospital, Paris, France

*Address all correspondence to: karinajulian@hotmail.com

IntechOpen

© 2019 The Author(s). Licensee IntechOpen. This chapter is distributed under the terms of the Creative Commons Attribution License (<http://creativecommons.org/licenses/by/3.0>), which permits unrestricted use, distribution, and reproduction in any medium, provided the original work is properly cited. 

References

- [1] Behçet H. On relapsing, aphthous ulcers of the mouth, eye and genitalia caused by a virus. *Clinical and Experimental Rheumatology*. 2010. DOI: 10.1016/j.irlle.2009.01.004
- [2] International Study Group for Behçet's Disease. Criteria for diagnosis of Behçet's disease. *Lancet*. 1990. DOI: 10.1016/0140-6736(90)92643-V
- [3] Davatchi F. Diagnosis/classification criteria for Behçet's disease. *Pathology Research International*. 2012. DOI: 10.1155/2012/607921
- [4] Dilsen N. History and development of Behçet's disease. *Revue du Rhumatisme (English Ed.)*. 1996
- [5] Davatchi F, Sadeghi Abdollahi B, Chams-Davatchi C, et al. The saga of diagnostic/classification criteria in Behçet's disease. *International Journal of Rheumatic Diseases*. 2015. DOI: 10.1111/1756-185X.12520
- [6] Kronborg C, Mahar PD, Kelly R. Should we keep changing the diagnostic criteria for Behçet's disease? *Dermatology*. 2014. DOI: 10.1159/000355481
- [7] Scherrer MAR, Rocha VB, Garcia LC. Behçet's disease: Review with emphasis on dermatological aspects. *Anais Brasileiros de Dermatologia*. 2017. DOI: 10.1590/abd1806-4841.20177359
- [8] Fatemi A, Shahram F, Akhlaghi M, Smiley A, Nadji A, Davatchi F. Prospective study of articular manifestations in Behçet's disease: Five-year report. *International Journal of Rheumatic Diseases*. 2017. DOI: 10.1111/1756-185X.12633
- [9] Zhu Z, Shu X, Long S, et al. Ulcerative colitis followed by the development of typical intestinal Behçet disease. *Med (United States)*. 2018. DOI: 10.1097/MD.00000000000009882
- [10] Akman-Demir G, Serdaroglu P, Taşçi B. Clinical patterns of neurological involvement in Behçet's disease: Evaluation of 200 patients. *Brain*. 1999. DOI: 10.1093/brain/122.11.2171
- [11] Koc Y, Gullu I, Akpek G, et al. Vascular involvement in Behçet's disease. *The Journal of Rheumatology*. 1992. DOI: 10.1016/j.revmed.2009.09.024
- [12] Zeghidi H, Saadoun D, Bodaghi B. Les manifestations oculaires de la maladie de Behçet. *La Revue de Médecine Interne*. 2014. DOI: 10.1016/j.revmed.2013.10.011
- [13] Takeuchi M, Iwasaki T, Kezuka T, et al. Functional and morphological changes in the eyes of Behçet's patients with uveitis. *Acta Ophthalmologica*. 2010. DOI: 10.1111/j.1755-3768.2009.01536.x
- [14] Tugal-Tutkun I, Ozdal PC, Oray M, Onal S. Review for diagnostics of the year: Multimodal imaging in Behçet uveitis. *Ocular Immunology and Inflammation*. 2017. DOI: 10.1080/09273948.2016.1205100
- [15] Atmaca LS, Sonmez PA. Fluorescein and indocyanine green angiography findings in Behçet's disease. *The British Journal of Ophthalmology*. 2003. DOI: 10.1136/bjo.87.12.1466
- [16] Chung Y-R, Cho EH, Jang S, Lee SY, Lee E-S, Lee K. Choroidal thickness indicates subclinical ocular and systemic inflammation in eyes with Behçet disease without active inflammation. *Korean Journal of Ophthalmology*. 2018. DOI: 10.3341/kjo.2017.0139
- [17] Akdal G, Toydemir HE, Saatci AO, et al. Characteristics of optic neuropathy in Behçet disease. *Neurology: Neuroimmunology & Neuroinflammation*. 2018. DOI: 10.1212/NXI.0000000000000490

- [18] Kidd DP. Optic neuropathy in Behçet's syndrome. *Journal of Neurology*. 2013. DOI: 10.1007/s00415-013-7070-4
- [19] Khanfir MS, Belfeki N, Said F, et al. Inflammatory optic neuropathy in Behçet's disease. *Reumatismo*. 2015. DOI: 10.4081/jlimnol.2014.817
- [20] Akmar-Demir G, Ayranci O, Kurtuncu M, Vanli EN, Mutlu M, Tugal-Tutkun I. Cyclosporine for Behçet's uveitis: Is it associated with an increased risk of neurological involvement? *Clinical and Experimental Rheumatology*. Jul-Aug 2008;26(4 Suppl 50):S84-S90
- [21] Alpsoy E. Behçet's disease: A comprehensive review with a focus on epidemiology, etiology and clinical features, and management of mucocutaneous lesions. *The Journal of Dermatology*. 2016. DOI: 10.1111/1346-8138.13381
- [22] De Menthon M, LaValley MP, Maldini C, Guillevin L, Mahr A. HLA-B51/B5 and the risk of Behçet's disease: A systematic review and meta-analysis of case-control genetic association studies. *Arthritis Care and Research*. 2009. DOI: 10.1002/art.24642
- [23] Bakir-Gungor B, Remmers EF, Meguro A, et al. Identification of possible pathogenic pathways in Behçet's disease using genome-wide association study data from two different populations. *European Journal of Human Genetics*. 2015. DOI: 10.1038/ejhg.2014.158
- [24] Akman A, Ekinçi NC, Kacaroglu H, Yavuzer U, Alpsoy E, Yegin O. Relationship between periodontal findings and specific polymorphisms of interleukin-1 α and -1 β in Turkish patients with Behçet's disease. *Archives of Dermatological Research*. 2008. DOI: 10.1007/s00403-007-0794-1
- [25] Mumcu G, Ergun T, Inanc N, et al. Oral health is impaired in Behçet's disease and is associated with disease severity. *Rheumatology*. 2004. DOI: 10.1093/rheumatology/keh236
- [26] Davatchi F, Chams-Davatchi C, Ghodsi Z, et al. Diagnostic value of pathergy test in Behçet's disease according to the change of incidence over the time. *Clinical Rheumatology*. 2011. DOI: 10.1007/s10067-011-1694-5
- [27] Direskeneli H. Autoimmunity vs autoinflammation in Behçet's disease: Do we oversimplify a complex disorder? *Rheumatology*. 2006. DOI: 10.1093/rheumatology/kel329
- [28] Fordham JN, Davies PG, Kirk A, Currey HLF. Polymorphonuclear function in Behçet's syndrome. *Annals of the Rheumatic Diseases*. 1982. DOI: 10.1136/ard.41.4.421
- [29] Garcia Garcia O, Vidaller Palacin A, Munoz Sanchez J, Roca Linares G. [Granulocyte-apheresis in ocular Behçet's disease resistant to medical treatment]. *Archivos de la Sociedad Española de Oftalmología*. Spanish; Jul 2004;79(7):335-340
- [30] Wallace GR, Niemczyk E. Genetics in ocular inflammation-basic principles. *Ocular Immunology and Inflammation*. 2011. DOI: 10.3109/09273948.2010.543306
- [31] Mamalis N, Edelhauser HF, Dawson DG, Chew J, LeBoyer RM, Werner L. Toxic anterior segment syndrome. *Journal of Cataract and Refractive Surgery*. 2006. DOI: 10.1016/j.jcrs.2006.01.065
- [32] Zaidi AA, Ying GS, Daniel E, et al. Hypopyon in patients with uveitis. *Ophthalmology*. 2010. DOI: 10.1016/j.optha.2009.07.025
- [33] Iannetti L, Corsi C, Iafrate F, Sammartino P, Di Giorgio A, Pezzi PP. Bilateral uveitis with hypopyon as a presenting symptom of metastatic peritoneal carcinomatosis. *European Journal of Ophthalmology*. 2010

- [34] Sudharshan S, Kumari A, Biswas J. Bilateral hypopyon as the presenting feature of chronic myeloid leukemia. *Ocular Immunology and Inflammation*. 2008. DOI: 10.1080/09273940802411437
- [35] Corriveau C, Easterbrook M, Payne D. Lymphoma simulating uveitis (masquerade syndrome). *Canadian Journal of Ophthalmology*. 1986
- [36] Sharma R, Randhawa S. Hemorrhagic ischemic retinal vasculitis and alopecia areata as a manifestation of HLA-B27. *Ophthalmic Surg Lasers Imaging Retina*. 2018. DOI: 10.3928/23258160-20171215-10
- [37] Pathanapitoon K, Dodds EM, Cunningham ET, Rothova A. Clinical spectrum of HLA-B27-associated ocular inflammation. *Ocular Immunology and Inflammation*. 2017. DOI: 10.1080/09273948.2016.1185527
- [38] Braakenburg AM, Rothova A. The clinical characteristics of retinal vasculitis in HLA-B27-positive patients. *Ocular Immunology and Inflammation*. 2014. DOI: 10.3109/09273948.2013.835429
- [39] Dodds EM, Lowder CY, Meisler DM. Posterior segment inflammation in HLA-B27+ acute anterior uveitis: Clinical characteristics. *Ocular Immunology and Inflammation*. 1999;7(2):85-92. DOI: 10.1076/ocii.7.2.85.4015
- [40] Reed JB, Morse LS, Schwab IR. High-dose intravenous pulse methylprednisolone hemisuccinate in acute Behcet retinitis. *American Journal of Ophthalmology*. 1998. DOI: 10.1016/S0002-9394(99)80163-9
- [41] Yazici H, Pazarli H, Barnes CG, et al. A controlled trial of azathioprine in Behçet's syndrome. *The New England Journal of Medicine*. 1990. DOI: 10.1056/NEJM199002013220501
- [42] Saadoun D, Wechsler B, Terrada C, et al. Azathioprine in severe uveitis of Behçet's disease. *Arthritis Care & Research (Hoboken)*. 2010. DOI: 10.1002/acr.20308
- [43] Masuda K, Urayama A, Kogure M, Nakajima A, Nakae K, Inaba G. Double-masked trial of cyclosporin versus colchicine and long-term open study of cyclosporin in Behçet's disease. *Lancet*. 1989. DOI: 10.1016/S0140-6736(89)92381-7
- [44] Kotake S, Higashi K, Yoshikawa K, Sasamoto Y, Okamoto T, Matsuda H. Central nervous system symptoms in patients with Behcet disease receiving cyclosporine therapy. *Ophthalmology*. 1999. DOI: 10.1016/S0161-6420(99)90120-3
- [45] Nalbant S, Sahan B, Durna M, et al. Cytokine profile in Behçet uveitis. *Bratislava Med J*. 2008. DOI: 10.1016/j.solmat.2011.10.028
- [46] Imrie FR, Dick AD. Biologics in the treatment of uveitis. *Current Opinion in Ophthalmology*. 2007. DOI: 10.1097/ICU.0b013e3282f03d42
- [47] Ramanan AV, Benton D, Compeyrot-Lacassagne S, Dawoud D, Hardwick B, Hickey H, et al. A randomised controlled trial of the clinical effectiveness, safety and cost-effectiveness of adalimumab in combination with methotrexate for the treatment of juvenile idiopathic arthritis associated uveitis (SYCAMORE Trial). *Trials*. 2014. DOI: 10.1109/ICM.2008.5393823
- [48] Lopalco G, Emmi G, Gentileschi S, et al. Certolizumab Pegol treatment in Behcet's disease with different organ involvement: A multicenter retrospective observational study. *Modern Rheumatology*. 2017. DOI: 10.1080/14397595.2017.1285857
- [49] Vitale A, Emmi G, Lopalco G, et al. Long-term efficacy and safety of golimumab in the treatment of

multirefractory Behçet's disease.
Clinical Rheumatology. 2017. DOI:
10.1007/s10067-017-3627-4

[50] Yalçındağ FN, Uzun A. Results of
interferon alpha-2a therapy in patients
with Behcet's disease. Journal of Ocular
Pharmacology and Therapeutics. 2012.
DOI: 10.1089/jop.2011.0238

[51] Diwo E, Gueudry J, Saadoun D,
Weschler B, LeHoang P, Bodaghi B.
Long-term efficacy of interferon
in severe uveitis associated with
Behçet disease. Ocular Immunology
and Inflammation. 2017. DOI:
10.1080/09273948.2016.1206204

[52] Onal S, Kazokoglu H, Koc A,
et al. Long-term efficacy and safety
of low-dose and dose-escalating
interferon alfa-2a therapy in
refractory Behçet uveitis. Archives of
Ophthalmology. 2011. DOI: 10.1001/
archophthalmol.2011.3

[53] Mudun BA, Ergen A, Ipcioglu SU,
Burumcek EY, Durlu Y, Arslan
MO. Short-term chlorambucil for
refractory uveitis in Behcet's disease.
Ocular Immunology and Inflammation.
2001. DOI: 10.1007/s00066-005-1394-7

[54] Davatchi F, Sadeghi Abdollahi B,
Shams H, et al. Combination of pulse
cyclophosphamide and azathioprine
in ocular manifestations of Behcet's
disease: Longitudinal study of up
to 10 years. International Journal
of Rheumatic Diseases. 2014. DOI:
10.1111/1756-185X.12248

[55] Fabiani C, Emmi G, Lopalco G, et al.
Intravitreal dexamethasone implant
as an adjunct weapon for severe and
refractory uveitis in Behçet's disease. The
Israel Medical Association Journal. 2017