

# We are IntechOpen, the world's leading publisher of Open Access books Built by scientists, for scientists

6,900

Open access books available

186,000

International authors and editors

200M

Downloads

Our authors are among the

154

Countries delivered to

TOP 1%

most cited scientists

12.2%

Contributors from top 500 universities



WEB OF SCIENCE™

Selection of our books indexed in the Book Citation Index  
in Web of Science™ Core Collection (BKCI)

Interested in publishing with us?  
Contact [book.department@intechopen.com](mailto:book.department@intechopen.com)

Numbers displayed above are based on latest data collected.  
For more information visit [www.intechopen.com](http://www.intechopen.com)



# Hip Arthroplasty

*Carlos Roberto Galia, Tiango Aguiar Ribeiro,  
Cristiano Valter Diesel, Marcelo Reuwsaat Guimarães  
and Fernando Pagnussato*

## Abstract

Hip replacement is one of the most performed surgical procedures in orthopedic hip surgery. Through this surgery, the patient returns to most of his normal life and a life without pain. The primary indication for a hip arthroplasty remains osteoarthritis (OA). OA is a degenerative disease that affects synovial joints. A successful surgery is always preceded by good planning. The planning in turn takes into account the analysis of the patient and his physical examination and the radiological image. But also, the surgical planning must take into account another important factor, the choice of the surgical approach. In this chapter, the authors script a revision on the history of hip arthroplasty, total hip arthroplasty approaches, implant types, complications associated with hip arthroplasty, outcomes, and perspectives to the future. We wish you a good reading.

**Keywords:** bone biology, hip arthroplasty, total hip arthroplasty, orthopedic

## 1. Introduction and history of hip arthroplasty

The hip arthroplasty is considered one of the greatest achievements of modern orthopedics [1, 2]. Through this surgery the patient returns to most of his normal life and a life without pain [3]. The primary indication for a hip arthroplasty remains osteoarthritis (OA). OA is a degenerative disease that affects synovial joints [4]. Because of the rapid recovery and return to most of the activities of daily living, hip arthroplasty was considered one of the few medical procedures with great benefit to the patient as a whole [5], and this surgery was considered the operation of the century by one of the most important medical journals in 2007 [3].

Hip arthroplasty began in Berlin in the late nineteenth century. Themistocles Gluck fashioned heads in ivory to replace the femoral head. This is the first concept of partial hip arthroplasty or hemiarthroplasty prosthesis. Gluck did these experiments in human patients with hip tuberculosis. These experiments demonstrated that the human body is tolerant to foreign bodies [6, 7]. Schmaltz (1817) and White (1821) underwent hip resection arthroplasty for children patients with hip tuberculosis, and they had been successful. This technique was described by Girdlestone in 1943 [8]. Smith-Petersen in Boston (1923) developed studies coating prosthetic glass, bakelite, and synthetic resin [9]. Philip Wiles (1938) [10] in London brought the concept of a femoral head attached to a rod. The first concept of an acetabular reaming was developed, so was born the concept of total hip arthroplasty (THA). Sir John Charnley [11] was the orthopedist who changed the concept of THA. His early experiments with Teflon have failed. But he developed the concepts of

low-friction arthroplasty [12] provided by decreasing the friction area due to the reduction in the diameter of the femoral head (22 mm). And, he used the high-molecular-weight polyethylene associated with methyl methacrylate (cement) [13] developed by Leon Wiltse in Los Angeles. These concepts of alliance were the concepts that changed the course of history of THA surgery. Notice that Haboush was the first orthopedic surgeon to use prosthesis with this cement. Muller was another important surgeon who introduced the prosthesis design with a 32-mm-diameter head [9]. But problems related to cementation generate concerns to improve the cementing techniques. But it was not just that, the search for a better cementation techniques grew. Miller [14] developed the low-viscosity cement, Harris [15, 16] describes techniques for improving cementing, and Robin Ling [17] emphasized the pressurization of the cement in the femoral canal. Despite the problems of cementing, orthopedic surgeons sought new fixation techniques. Pioneers in the area Pillar [18, 19] and Galante [20] introduced the concepts of cementless prosthetic components and the bone growth and pressurization (press fit). The hip arthroplasty surgery is still currently growing and developing. There are several new possibilities: articular surfaces of materials with less friction, more resistant materials, and minimally invasive techniques.

In this chapter, the major aspects of THA surgery will be addressed.

## **2. Total hip arthroplasty approaches**

A successful surgery is always preceded by good planning. The planning in turn takes into account the analysis of the patient and his physical examination and the radiological image. But also, the surgical planning must take into account another important factor, the choice of the surgical approach. The lateral, anterior, and posterior are the main approaches to perform hip arthroplasty. The Moore approach, also named posterior approach [21], is the most used surgical approach. The visibility of the surgical field is wide, and the anatomical approach when known by the surgeon becomes fast and easily accessible. Acetabular and femoral reaming becomes easy to perform due to extensive visibility. Even with an extensive visibility, some authors reported an increased incidence of luxation when this approach is compared to the lateral approach. However, other studies have shown that there is no such correlation [22, 23] and these authors attributed the excessive luxation to the incorrect position of the prosthetic components [22, 23]. Another great and important positive point of this surgical approach is that it does not harm the abductor tendons, so it does not cause limping for operated patients. The lower frequency of deep vein thrombosis (DVT) and bleeding is attributed to this surgical access [22–27]. The anterior surgical approach described by Smith-Petersen [28] and Hueter [29] is less used today, but it has gained new and notorious space among hip surgeons, due to its facilities and strengths for not detaching tendons and muscles. In the same way today, this approach is being used in less invasive and less aggressive surgeries, with the so-called mini-open approach. To the anterior approach, appropriate surgical instruments are needed, and the chance for lesion to occur in the femoral cutaneous nerve during surgery is elevated [30]. The last of the three most commonly used approaches is the direct lateral approach or Hardinge [31]. It has been the most used surgical technique. Hardinge approach is useful because it allows easy placement of the components and it is a familiar approach to a large number of surgeons. This feature makes Hardinge one of the most widely used approaches. Some authors attribute to this approach lower luxation rates than the posterior approach of Moore. But its drawback is that it is able to injure the abductor muscles and cause limping in the patient [22–24].

### 3. Implant types

The choice of the implant type must also be regarded as extremely important to the success of the surgery. Basically, the implants used in hip arthroplasty can be divided into two groups: non-cemented (cementless implants) and cemented. This division is in regard to the different ways of fixation of the implant to the host patient bone. The main characteristic that distinguishes them is the presence or absence of bone cement (polymethyl methacrylate (PMMA)). Alternatively, a hybrid implant may be used, i.e., a component is fixed with PMMA and other not.

The cemented implants wear the interposition of a polymer called PMMA as an interface between the patient's bone and the implant. This form of attachment was designed by Haboush and subsequently disseminated by Charnley in the 1960s [32]. PMMA has a modulus of elasticity very close to the human bone elasticity modulus (elasticity modulus cement +2GPa; elasticity modulus of trabecular bone +0.5–1GPa). This polymer is very resistant to compressive forces but does not have good resistance to tension or shearing forces [33]. The long-term results to cemented implants depend on the quality of the cement mantle both in the acetabulum and in the femur. Initially, the placement of the cement manually, without the use of distal plug in the femoral canal, was used. The cement mixture was done manually, and pressurization into the canal was performed digitally. This technique was first called as the generation cementing technique. The retrograde filling of the femoral canal with the aid of cement pistols was later developed. They began to use femoral canal plug or plug restrictors, which aims to create a distal barrier to the stem that prevents the passage of cement and favors the pressurization and interdigitation of PMMA in the trabecular bone [34]. These advances represent the second generation of cementation. In the third generation, special techniques were introduced to the cement mixture (vacuum mixing or mixture in centrifuge). However, these special techniques for cement mixing are controversial and do not seem to improve the mechanical properties of PMMA [35]. One of the parameters often used to define an appropriate cementation is the presence of a uniform cement mantle, that is, with no bubbles or lines of radiolucency between the cement and the bone [36]. The thickness of the PMMA mantle is another parameter to define appropriate cementation. In this case, a thickness of 2 mm of the mantle between the femoral stem and the bone is considered adequate [36]. In the acetabulum, the mantle must have a thickness of 3 mm [37]. This trivial standard of cementation has the contrast of the controversial “French paradox,” a way of cementation in which the femoral canal is filled with the largest possible stem by using the PMMA to fill the remaining spaces, sometimes getting fine and nonuniform mantles [38]. Other aspects in cemented implants to be observed carefully are:

1. Design—Cemented femoral stems can be classified as simple wedge, double wedge, or triple wedge according to the geometry of the implant. Typical representatives of these subcategories are the stems of Charnley, Exeter, and C-stem, respectively [39]. Although the triple-wedge stems have lower stress in the cement mantle [40], a higher posterior rotation of this implant model is reported [41]. The clinical implications of these findings in the triple-wedge stem are not yet known, and yet this stem type has not demonstrated superiority over other designs [42]. Currently, the stems in double wedge are most often used.
2. The covering of the implant—Traditionally, the best results are obtained with polished implants, i.e., smooth rods. There are femoral stems with rough surface, but these implants are not widely accepted, and its long-term results are not well established in large series [43].



3. The implant material—Usually, the implants are made of chrome-cobalt alloys or stainless steel. Titanium implants were tested; however, the results were very short compared to the traditional metal alloy [44].

The cementless implant aims to obtain a biological fixation between the implant and the host bone. Summarized there is the expectation of bone growth to the porosity of the implant and thus its final attachment to the bone. Unlike cemented implants, the presence of porosity is an indispensable requisite for fixation. There is the use of PMMA in this technique of placing the uncemented prosthesis. The implants do not depend on the cemented macrolocking (primary fixation) and microlocking (secondary fixation). Macrolocking must occur upon insertion of the implant, being obtained by an intimate fit of the implant to the bone. Microlocking is due to the bone ingrowth, i.e., the formation of bony bridges between the host bone and the pores of the implant [45, 46]. Ultimately, this is the factor that determines the longevity and success of a cementless implant. Macrolocking or primary locking can be obtained by various techniques, dependent or not in changes in the design of the implant, such as screw fixing, flaps, or grooves. Currently, the most common technique in primary stabilization is the press fit. This type of stabilization requires the placement of the prosthesis in an undersized cavity. In cementless acetabular beyond the press fit, screws may also be used as an aid to the primary fixation; however, with a suitable press fit, screws can even be dispensed [46–48]. To bone ingrowth occur, macrolocking must produce sufficient stability in order to avoid micromotion. When micromotion occurs, even if slight, it can delay or prevent the formation of bone tissue onto the implant, thus favoring the formation of fibrous tissue [46–49]. For microlocking, porosities are indispensable in the implant surface. Thus, it becomes extremely important different characteristics of the pores, as its size, its geometry, and its interconnection. Studies show that the size of the pores should be between 100 and 400  $\mu\text{m}$ . Pores smaller than 50  $\mu\text{m}$  or greater than 500  $\mu\text{m}$  facilitate the growth of fibrous tissue rather than bone tissue [49]. The pores may have different geometries. There are three traditional types of porosity: the plasma-sprayed coating, the sintered sphere coating, and the fiber mesh coating [49]. In recent years, derived surfaces of trabecular metal porous coating has proven promising in the coverage or in the production of cementless implant, but results with longer follow-up are still waited. It is estimated that the percentage porosity is greater for the fiber mesh coating—between 40 and 50%—and the porous trabecular metal coating—between 75 and 80% [50]. The interconnection between the pores also plays an essential role in bone coupling force to the implant. If it is higher, the interconnection between the pores is resulting in major coupling force between the bone bridges and the prosthesis. Theoretically, the form of the manufacturing fiber mesh coating and the trabecular metal coating allows for a better interconnection between the pores compared to the plasma-sprayed coating and the sphere coating [47].

Another type of arthroplasty are considered hybrid. In this type of prosthesis, one of the implants is cemented and the other does not. It was called hybrid arthroplasty prosthesis in the acetabulum, which is not a cemented and cementless femoral stem. The reverse, i.e., cemented and cementless acetabular rod, was called reverse hybrid arthroplasty.

With regard loading surfaces, tribology has also shown its importance in modern times and has contributed to the THA surgery that increased its longevity. The tribological pair most widely used and studied is the metal-polyethylene. Other tribological pairs are also used: ceramic-polyethylene, metal-metal, and ceramic-ceramic; these last two tribological pairs are also called hard on hard. Currently, there is a trend in replacing the ultrahigh-molecular-weight polyethylene

(UHMWPE) by highly cross-linked polyethylene (XLPE). The XLPE result of a series of interventions during its production seeks to change the connections between the molecules, resulting in a harder and wear-resistant material [51]. It is estimated that 0.04 mm/year is the linear wear rate compared to the XLPE 0:22 mm/year UHMWPE [52, 53]. All new tribological pairs presented as benefit a less volumetric wear, a fact that in theory could be beneficial for the longevity of the arthroplasty. There are, however, some peculiarities in these pairs. The metal-metal surface has an extremely low volumetric wear; however, it is given to metal-metal surface to release chromium and cobalt ions, which can be adsorbed and present local and systemic complications [54]. Among the local complications, pseudotumor formation is the major problem [55]. Systemic effects include neurological and cardiac damage [56]. There are also carcinogenic potential of systemic release of chromium and cobalt, although the exact impact of this exposure is not well known [57]. These systemic effects led to a metal-metal contraindicated in patients with allergies to metals and, in particular, women of childbearing age [58]. The ceramic-ceramic tribological pair has greater resistance to volumetric wear than metal-metal surface. This combination is particularly suitable for very young patients with high activity level and has no contraindication for women of childbearing age. The disadvantages of ceramic-ceramic are fracture risk and the risk of producing noise (squeaking) during hip movement and the stripe wear. The risk of squeaking is multifactorial; the main factors are the malposition of the components, the implant design, and the type of material used in manufacturing, though not always the trigger is recognized [59, 60]. The risk of ceramic fracture is currently between 0.004 and 0.010% being associated with the wrong positioning of the components (acetabular or femoral head) [61]. The stripe wear can occur when there is decreased contact area between the femoral head and acetabular surface, which can arise during swing phase of gait occurs or when the impingement of the trunnion on the acetabular rim and ball leaves right from the socket. The stripe wear is of concern due to the large volumetric wear it can cause. Individuals with tissue hyperlaxity or excellent range of motion (ROM) and those who require placing the hip through the extreme ROM are prone to impingement and consequent stripe wear [62]. The cross-linked polyethylene-ceramic surface adds the benefits of not releasing metal ions, no risk of squeaking besides presenting a very low volumetric wear, however higher than that of the hard-on-hard surfaces. As the head of ceramic is used, there is a minimal risk of fracture of the component. Perhaps, it represents a suitable alternative for young patients and factors that may complicate the use of other types of tribological pairs.

The proper choice of the type of implant, whether cemented or not, and the different tribological pairs should take into account the theoretical knowledge of the design features, materials, and long-term outcomes beyond the patient characteristics and the surgeon's experience.

#### **4. Complications**

Complications associated with hip arthroplasty can vary among groups of patients—age, gender, bone quality, and comorbid. For classification purposes it can be divided by time: acute complications, as in intraoperative and early adverse events—generally within 30–90 days, and late postoperative complications that can be divided in short-term and long-term complications. The most common major complications include mortality, infection, dislocation, revision, and thromboembolic events and will be the center of discussion in this section [63].

## 4.1 Mortality

The indications for arthroplasty have been expanded during recent years. More patients, both younger and old, are operated now, and, in that case, the older group runs a particularly greater natural risk of serious complications. That implicates that higher-risk patients undergo operation than anteriorly. In most recent registries, the short-term mortality rate (90-day mortality) in all patients who undergo hip arthroplasty has an average value of 6.9% [64]. In that period, the dominant causes seem to be cardiac, cerebrovascular, or thromboembolic illnesses. Mortality at 90 days postoperatively in the US Medicare population has been reported as 1% for primary total hip arthroplasty [63]. That shows that mortality can vary significantly, especially when specific groups are studied. In other registries when we divided the mortality rate of partial primary hip replacement—usually used in elderly patients with fractures, we find a rate of 21.53 per 100 person-years. Otherwise, the total primary hip replacement has a rate of 2.54 per 100 person-years [65].

## 4.2 Thromboembolism

Thromboembolism is a potentially catastrophic complication faced by all patients who undergo elective hip arthroplasty. During the 90 days following primary arthroplasty surgery, hospitalization due to symptomatic deep vein thrombosis occurs in 0.7%, while hospitalization due to pulmonary embolism occurs in 0.3% [66]. In early reports prior of routine prophylaxis, venous thrombosis occurred as high as 50% of times in patients after total hip replacement [67]. In 2001, the sixth conference held by the American College of Chest Physicians came to the conclusion that all patients undergoing total joint replacement needed to be placed in the highest-risk category for DVT [68]. Today, there are guidelines from different medical areas with the intent to patronize the use of drugs and to give information about the management of thromboembolic disease. Despite all the attempts to validate and embrace the use of these guidelines, the ideal method of thromboembolic events prophylaxis remains controversial.

The general concern for total joint replacement surgeons, about these publications considered as high-level recommendations (1A), was the promotion of aggressive treatment for all patients, regardless of their risk profile. In 2011 and 2012, reports from the FDA appointed that anticoagulants were the leading drug risk to patients and complications like bleeding, drainage, and wound complications were the critical counterpoint for routine aggressive prophylaxis [69].

Today, there is no current evidence whether factors other than a history of previous venous thromboembolism increase the risk of venous thromboembolism in patients undergoing elective hip arthroplasty [70]. There are many other factors that were appointed to increase risk, like, obesity, or advanced age, but there's no real evidence to support. There is a consensus that any other factor that can cause decrease of mobility can be a risk factor, the same way for hemostatic abnormalities that can cause hypercoagulable states. There are no image exams or laboratory markers that can indicate a greater risk for thromboembolism. Today, there is strong evidence against the routine use of ultrasound for the screening of patients after hip arthroplasty for DVT. Is important to bear in mind that, at least 50% of patients, diagnose is not clinically apparent.

The diagnosis of DVT is based in clinical findings, usually pain and tenderness in the calf or thigh, erythema, and swelling, most of the times unilateral. Venography still stands as the “gold standard” for confirmation of DVT, but the duplex ultrasound seems to be a low-cost, minimal morbidity, good sensitivity option, besides the risk of anaphylactic reaction to contrast and low chances of inducing DVT that



venography carries. Pulmonary embolism can curse with chest pain, breathlessness, and rapid pulse, and it's a cause of sudden death. The diagnosis can be confirmed by pulmonary angiography.

The best method of prophylaxis still is not clear. There is evidence to suggest that pharmacological agents and/or mechanical compression devices reduce DVT rates in patients undergoing elective knee or hip arthroplasty. The results of analyses in recent studies did not consistently suggest that any one strategy is preferable to another. The most commonly used agents are low-molecular-weight heparin (LMWH), aspirin, direct factor Xa inhibitors ("xabans"), and warfarin. Devices of intermittent compression seem to be effective especially in distal emboli. There's no consensus either for the time that prophylaxis is maintained. It varies for at least 10 days as far as 35 days after surgery, depending on the patient and the drug. There has been a tendency to return the use of aspirin after hospital discharge [71].

It is a consensus, even when there's no evidence to support, that patients undergoing elective hip or knee arthroplasty, and who also have a known bleeding disorder (e.g., hemophilia) and/or active liver disease, use a less aggressive treatment with mechanical compressive devices for preventing venous thromboembolism.

Early mobilization still is a low-cost, minimal risk to the patient and consistent method with the current practice. Mobilization as soon as possible following hip arthroplasty addresses the stasis limb of Virchow's triad (hypercoagulability, endothelial injury, and stasis) promoting the regional blood flow and diminishing the risk for formation of clots.

### 4.3 Dislocation

Dislocation is one of the most feared complications after THA. Probably, it is one of the most common indications for revision surgery. An incidence from 1 to 3% of dislocation after THA has been reported [72]. Risk factors include the type of surgical approach, previous surgery, obesity, fracture of proximal femur, malpositioning of components, impingement, insufficient abductor muscle, femoral component head sizes, and others. Many studies tried to isolated these causes, but there's not much medical evidence to support, and the most common conclusion is that retrospective randomized trials examining dislocation rates and other clinical parameters are needed [73]. Clinical finding include pain, shortening, and internal or external rotation of the limb.

Factors like age, height, or race are seen to be associated with bias with at least one technical-related factor when the disclosure is dislocation. However, in many series, dislocation occurred in women more often than men.

The most used surgical approaches for THA are the posterior and direct lateral approaches. The posterior approach is considered to be easy to perform; however, increased rates of dislocation have been reported. The direct lateral approach was related to an increased risk of limp. Studies indicate that soft tissue repair reduces the relative risk of dislocation using the posterior approach and that the dislocation rate for these approaches becomes similar. It has been advocated that bigger head sizes increase instability and have greater ROM [22, 74, 75].

The vast majority of dislocations occur within 3 months of surgery. These early dislocation (<6 months) presents higher chance of success with nonoperative treatment. Late complications, after 5 years in general, are more challenging to treat because of the many factors that can be attributed to these cases [72]. The combination of muscular weakness and malposition implants is seen to be the worst scenario for hip stability.

Besides all the discussion about head sizes and different approaches, the single, most effective way of preventing dislocation still is education of the patients and the people who assist them. They should be aware that which extreme movements



and which specific position are most likely to cause dislocation, and the ways of avoid them without lose their independence. It's important that the patient is able to repeat and understand the instructions for precaution before hospital discharge and has reinforced these directions at follow-up routine.

The surgical options for treatment are as many as the causes for the dislocation can be. Change of components for longer and bigger heads, liner exchange, and elevated rim could be successful sometimes; otherwise, component revision, soft tissue reconstruction, or even constrained liner may be needed. Identifying the causes of instability after THA is essential for the correct approach and satisfactory outcome.

#### **4.4 Nerve and vascular injuries**

Nerve and vascular injuries are very uncommon complications in primary total hip replacement but can be the most distressing ones. With an incidence between 0.8 and 3.5% for nerve injuries, the most common nerve damage followed by femoral nerve has been the sciatic nerve palsy [76]. These numbers can be altered when you observe a specific kind of approach, as with the anterior direct approach, that can present with up to 15% of lateral femoral cutaneous nerve palsy in some reports [77].

Several risk factors were identified for nerve injuries, including previous surgery, revision procedures, type of approach, and excessive leg extension. However, no correlation between the amount of lengthening and nerve palsy in total arthroplasties performed for dysplasia of the hip has been reported [78]. Previous surgery or revisions were correlated with technically difficult in the surgical exposure, anatomical abnormalities, and injudicious retraction. In order to diagnose nerve palsy after orthopedic surgery, an electromyogram can be of use to assess the extent and prognosis. According to the literature, partial recovery can be expected in 70–80% of cases. Latest reports appoint only 50% of full recovery after common peroneal nerve palsy following total hip arthroplasty with the mean time of 12–18 months depending on the severity of lesion. Other studies showed improvement beyond the limit of 2 years and independent of the nerve affected. Obesity was appointed as a factor that adversely influenced the nerve recovery [79, 80].

Vascular injury in primary hip arthroplasty is rare and most frequently associated with the use of screws for fixation of structural grafts, acetabular components, and protrusio rings or cages. The individual risk is determined by multiple factors depending on the surgeon's skills, the number of previous surgeries, and the approach itself. The acetabular quadrant system as described by Wasieleski et al. is a useful tool to understand the neurovascular anatomy of the hip, to detect the safe zone, and subsequently prevents complications that can pose as a threat to the limb and the patient [81].

#### **4.5 Fractures**

The most common are those who affect the femur and are classified by the local of the fracture, the fixation of implant, and the bone stock of the femur. Can also be divided by time, as intraoperative and postoperative fractures, the most common being the intraoperative fractures of the femur with an uncemented stem.

There are moments during the procedure that the fracture is most likely to occur. One of the critical stages seems to be while attempting to dislocate the hip, especially in fragile bones of elderly patients and rheumatoid arthritis patients. During the stage of broaching or during the insertion of the implant, cortical defects and proximal deformities can elicit a fracture of the diaphysis. Acetabular fractures are much more uncommon also because often they are not recognized. The key moment is seen to be, with press-fit components, during the impaction of an underreamed acetabulum.

The Vancouver classification of periprosthetic femoral fractures became known for postoperative fractures and was modified to include this intraoperative ones (**Table 1**).

The treatment can be initiated by taking preventive actions: the anticipation of anatomical challenges in preoperative planning and templating; the choice of implants, by the use of moderate rotational force and with wider approaches; and the liberation of soft tissues that might be restraining to the adequate exposure. Patients with osteoporotic bone, neuromuscular disorders, and previous hip surgery should be of higher concern. The use of fluoroscopy is an important tool to identify these fractures when suspected. Each type of fracture needs a specific treatment. In a review by Misur et al. [83], they summarize recommendations for the treatment of periprosthetic fractures of the femur with grading of published evidence supporting each recommendation (**Table 2**). The need for adjunctive fixation should be assessed, extended approach for the correct assessment is often needed, and the result needs to present a stable construction. Clear orientation for the patient and family about weight-bearing and healing process of the fracture is essential for good results.

4.6 Infection

Periprosthetic joint infection remains a challenge for the orthopedic surgeons. It represents a risk for disastrous and painful consequences for the patients, especially for those submitted to elective primary joint replacement. The incidence reports approximately 1% of infection after THA. Great effort is applied to identify risk factors, minimize, and prevent these complications in a systematic way. Currently, recommendations are based in large, multicenter studies, but still high-level evidence for these practices are few, and many are based on little to none scientific

	Vancouver A		Vancouver B		Vancouver C	
	AG	AL	B1	B2	B3	C
Prosthetic fixation	Stable	Stable	Stable	Loose	Loose	Stable
Bone quality	Good	Good	Good	Good	Poor	Good

**Table 1.**  
*Vancouver classification resume [82].*

Type AG	Nonoperative treatment if nondisplaced; open reduction and internal fixation if displaced fracture in active patient
Type AL	Nonoperative treatment unless implant stability compromised
Type B1	Fixation with minimally invasive lateral locking plate; addition of allograft strut if bone stock compromised
Type B2	Revision with extensively coated tapered fluted stem (modular or nonmodular)
Type B3	Revision with extensively coated tapered fluted stem (modular or nonmodular); if bone stock grossly compromised, use allograft-prosthesis composite with megaprosthesis reserved for salvage procedures and elderly patients
Type C	Fixation with minimally invasive lateral locking plate

*Adapted from [84].*

**Table 2.**  
*Treatment of periprosthetic fractures of the femur after total hip arthroplasty.*

foundation whatsoever. In 2014, the Proceedings of the International Consensus Meeting on Periprosthetic Joint Infection in the attempt to unify the current knowledge and practice was published.

Risk factors were divided as significant and potential risks for development of surgical site infection (SSI) or periprosthetic joint infection (PJI) after elective total joint arthroplasty (TJA). In the first category, 99% of the delegates consensus that active infection of the arthritic joint (septic arthritis), presence of septicemia, and/or presence of active local cutaneous, subcutaneous, or deep tissue infection are all significant risk factors predisposing patients to and are contraindication to undertaking elective TJA. Ninety-four percent agree that history of the previous surgery, poorly controlled diabetes mellitus (glucose > 200 mg/L or HbA1C > 7%), malnutrition, morbid obesity (BMI > 40 Kg/m<sup>2</sup>), active liver disease, chronic renal disease, excessive smoking (>1 pack per day), excessive alcohol consumption (>40 units per week), intravenous drug abuse, recent hospitalization, extended stay in a rehabilitation facility, male gender, diagnosis of posttraumatic arthritis, inflammatory arthropathy, prior surgical procedure in the affected joint, and severe immunodeficiency are potential risk factors for development of SSI or PJI [85].

Active infection in periodontal disease, methicillin-resistant *Staphylococcus aureus* (MRSA), and methicillin-sensitive *Staphylococcus aureus* (MSSA) colonization were appointed as factors that can contribute to development of the infection, as well as urinary tract infection (UTI); however, there's no medical evidence to support screening for these patients. Nevertheless, patients with a known history of recurrent urinary infection or for those with evidence of ongoing urinary symptoms suspicious for infection should receive special attention.

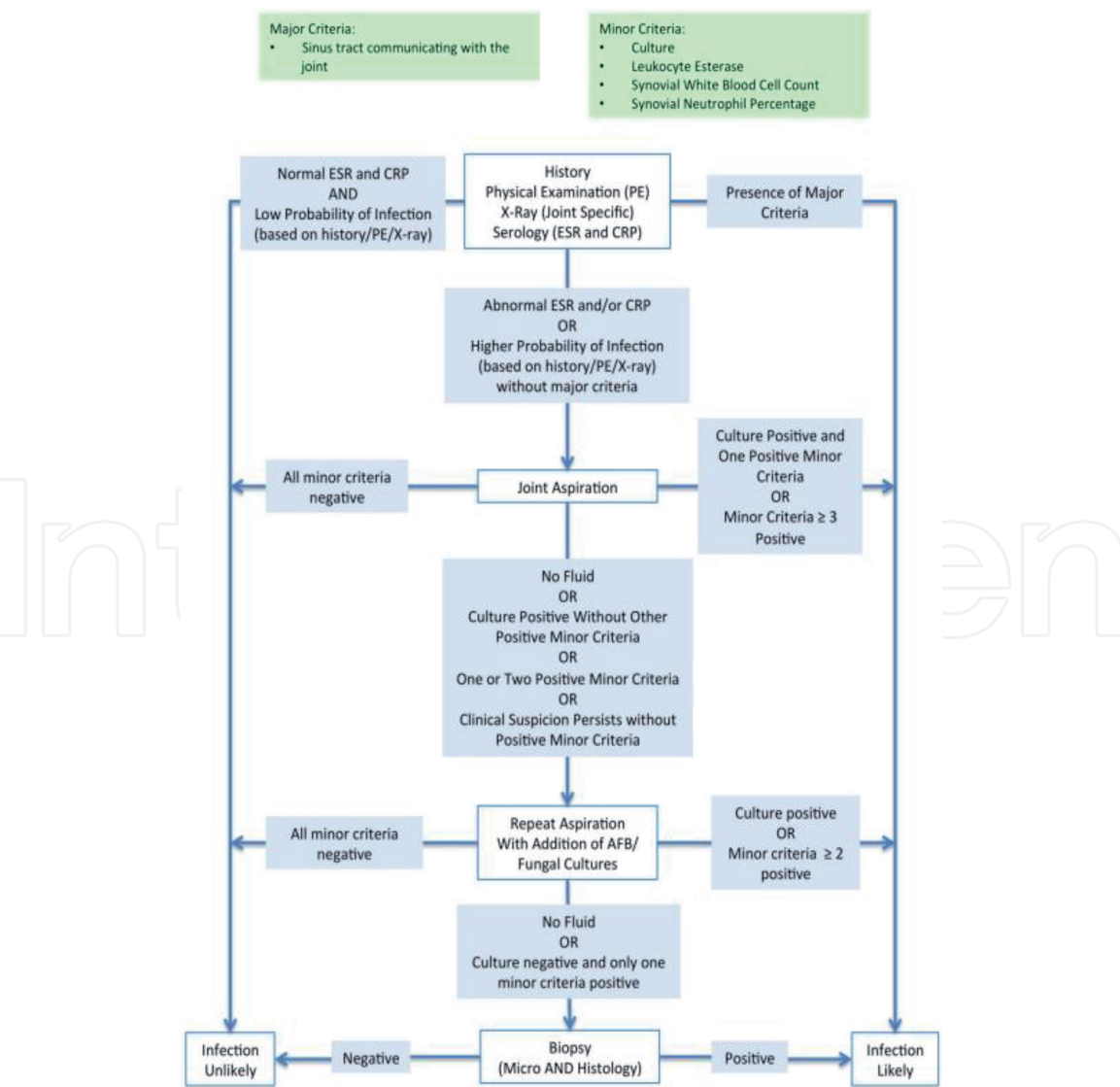
Antibiotic prophylaxis is, in general, the most important factor to reduce the chances of contaminating microorganisms to establish during the procedure exposure. For that it's important that, by the time of the incision, there is adequate tissue concentration of the drug. Most of the guidelines recommend that prophylactic antibiotics be completely infused within 1 hour before the surgical incision. A first- or second-generation cephalosporin is normally administered for routine perioperative surgical prophylaxis, mostly because of its broad spectrum of action, cost-effectiveness, and the need to preserve newer and more expensive therapies for drug-resistant microorganisms. Additionally, they have excellent distribution profiles in the bone, synovium, muscle, and hematomas. Patients who weigh more than 80 kg should receive double the amount of cefazolin usually used. The efficacy of 1 day of cefuroxime vs. 3 days of cefazolin on postoperative wound infections was tested and found to have no statistically significant difference between the two regimens [86]. An additional dose of antibiotic should be administered intraoperatively after two half-lives of the prophylactic agent or after important blood loss. The choice of antibiotics for patients with pre-existing prostheses such as heart valves is the same as that for routine elective arthroplasty.

If infection is suspected, it's important to understand in what moment of the disease the patient presents himself because time is a relevant factor in approaching these complications and might influence in the treatment options. There are many classifications; in general, they are divided as follows: (1) early postoperative infection that can vary between 3 and 6 weeks onset within the time of the surgery, depending on the author; (2) late chronic infection after these periods and with an insidious presentation of symptoms; and (3) acute hematogenous infection, defined by the onset after these 3 to 6 weeks in a previously well-functioning prosthesis, probably by a distant source of infection.

The diagnosis still is in debate; the consensus is defined as PJI as follows:

- Two positive periprosthetic cultures with phenotypically identical organisms
- A sinus tract communicating with the joint
- Having three of the following minor criteria:
  - Elevated serum C-reactive protein (CRP) and erythrocyte sedimentation rate (ESR)
  - Elevated synovial fluid white blood cell (WBC) count OR ++change on leukocyte esterase test strip
  - Elevated synovial fluid polymorphonuclear neutrophil percentage (PMN%)
- Positive histological analysis of periprosthetic tissue
- A single positive culture

The AAOS’s algorithm (**Figure 1**) was adapted to be applied to patients who present with a painful or failed arthroplasty.



**Figure 1.**  
The AAOS’s algorithm for treatment to patients with a painful or failed arthroplasty [85].



The major discussion nowadays among joint replacement hip surgeons is whether to perform a one-stage or two-stage revision in patients with diagnosis of infection. Patients with early postoperative infection apparently have strong chances of cure when an open debridement and change of mobile parts are realized as an early aggressive intervention [87].

Both procedures have the same intent: identification of the organisms; eradication of the foci; physical removal of any organism, tissue, or components that might have been exposed; appropriated treatment with antibiotics; and safe reconstruction of the joint in a healthy environment.

The bone cement loaded with antibiotics has been the main weapon in the one-stage enthusiasts, as the spacers have been for those who advocate four two-stage revisions. The selection of patients has been seen to have an important role in that decision; the tendency has been the single-stage revision. With more studies published each year showing similar outcomes for both types of procedures, the social and economic advantages of one operation, like shorter hospitalization, early return to activities, and higher satisfaction rates, give the one-stage revision an increasing role in the treatment of joint infection.

## **5. Outcomes**

The focus of THA registries traditionally has been on implant longevity and rates of revision surgery. The landmark of failure of the implant and the necessity of revision still are considered the best definition of clinical failure as well. Otherwise, the choice of parameters for the definition of failure, clinical or radiographic, could be troublesome. Short-term mortality rate (90 days postoperative) also has been used as an outcome. However, the latest publications signalize an important change in the outcome reports. Since pain, impaired joint function, and quality of life related to hip disease are the main indications for THA, thus to include this patient-related information in the results reported after primary hip replacement. The patient-reported outcome (PRO) includes pain relief, joint function, and other health-related quality-of-life improvements and represents an important aspect of hip arthroplasty results.

National joint registries are the most reliable and most quoted references when the subject is outcome. Through them it's been possible to have a greater view and more profound understanding of why arthroplasties fail. For example, in the Norwegian report of 2002, 9.2% of 17,323 primary Charnley hip prosthesis implants were revised after 10 years of follow-up, and 71% of the failures involved aseptic loosening of the femoral component. The use of a specific type of cements was appointed as an important and highly significant probable cause in this percentage [88]. Another example was the metal-on-metal surface and the early complications reported in many registries. For that manner, reports became an essential tool to orthopedic surgeons to understand the impact of all these variables—implant design, material, patient selection, surgical techniques, and others—and how they are influencing the outcomes in their clinical practice.

In general the most common causes for revision are the same in every other registry or study published. Sometimes, the percentages can vary depending on the population studied. In the 2012 Swedish reports, for example, aseptic loosening including osteolysis was the most common cause for revision (28%), followed by dislocation (26%), infection (22%), and periprosthetic fracture (13%) [89].

One of the major areas of discussion has been cemented versus cementless implants and how they can influence in the outcome. An increasing use of uncemented implants in the last 10 to 15 years has been reported. Over the same time

period, there was a corresponding reduction in the use of cemented ones. The National Joint Registry for England, Wales, Northern Ireland and the Isle of Man of 2014 reports that in 2003 cemented hip replacement was used in 60.5% in comparison to 33.2% in 2013. Otherwise, cementless increased from 16.8% in 2003 to 42.5% in 2013 [90]. The “new trend” defenses of uncemented implants are that it is faster surgically, avoids the third-body debris, and creates a biological interface of bone ingrown in the implant (and with that less rate of loosening) and less chances of embolic events that can occur during cementation. The cement users appoint that there are less fractures, intra- and postoperatively, less dislocation and leg length discrepancies, and less thigh pain report after surgery, and, mainly, there is registry data of better outcome in patients older than 75 years [91].

All these qualities or failures on both implants are, in fact, correct. Cemented hip arthroplasties have been reported to be better in many nation registries, especially in older patients [92, 93]. Otherwise, specific centers across the globe reported up to 99% of cementless stem survival after 12–26 years of follow-up [94, 95]. There are reports of the accuracy during cup position, and cemented cups seem to have better position than uncemented cups that have the tendency to deviate from their original place [96]. The incidence of periprosthetic femoral fractures is becoming more common, and that could be attributed to the larger use of uncemented implants. Thigh pain is most common with uncemented femoral stems, but in a great way, this can be attributed to the design of the implant that was used. The major issue in using cemented implants still is the technique and its reproducibility. Perfect cementing technique is essential to achieve all these excellent results. Pulsatile jet-lavage to clean the cancellous bone and allow the cement to have good interdigitating as well as good pressurization and homogenous cement mantle is appointed as prerequisite to reach adequate cementation [97].

Other important aspect of failure in hip arthroplasty has been between the implants that are used in partial arthroplasties. In the Australian report of 2014, in patients under the age of 75 years old after the neck of the femur fracture, the revision rate after 10 years for primary unipolar monoblock and unipolar modular hip replacement was the same (16.1%). To the same group of patients, the bipolar presents a 9% rate of revision in the same period of 10 years [93].

In primary hip replacement for osteoarthritis (OA), nation registry reports are similar, in an overall of 5–6% rate of revision in 10 years for all ages. When divided by the type, the British reports 3.2% for all cemented, 7.68% to all cementless implants, and a total of 3.95% for hybrids. The Australian reports 6, 5.4, and 4.8%, respectively. When divided by age and gender, younger females are in greater risk of revision in 10 years. Inversion occurs when the primary replacement is made around 65 years of age in men, showing a slightly higher incidence of revision than women after 10 years [90, 93].

A lot of attention is given to the type of bearing nowadays. The most recent surfaces like ceramics, highly cross-linked polyethylene, and their combination with metal generate a lot of discussion in what would be the ideal, more durable surface, and for whom it should be use. Keeping aside the costs and a few laboratory assays, there is no real evidence in favor or against any of these, except for the metal-on-metal combination that has inferior outcomes in almost all the comparative published. In the 2014 Australian report, ceramic combined with ceramic and highly cross-linked polyethylene had similar 10-year rates, 4.7 and 4.5%, respectively. The lower revision rate was metal on highly cross-linked polyethylene with 4.3% in 1 years. Any of these combinations, when associated with an exchangeable femoral neck, showed two times higher rate of failure in that same period of time [93]. In the British reports, hybrid assembly with ceramic on polyethylene showed the outcome with 2.19% in 10 years [90].

The material that stems are made also has an influence in the outcomes as well as femoral head sizes. Pure titanium seems to have lower revision rates than titanium

and cobalt-chrome in the stem/neck material. Head sizes of 32 mm have a lower rate of revision than head sizes of 28 mm or less. However, there is no difference when head size 32 mm is compared to larger head size. This can probably be attributed to the higher incidence of dislocation that 28 mm or less heads present [93].

It has been advocated that total hip arthroplasty is probably the most successful operative intervention performed by human beings. Still, a constant strive for innovation has a guide progress, especially in the technologic field. Every year more aspects are being reported, and a great volume of information has been gathered. More than never before, more patients, with a wider range of age and comorbidities, are having their hips replaced. The understanding of how this affects their lives and how to meet the changes in the demand and expectations for THA is an essential key to keep improving such celebrated medical procedure.

For this reason, patient-reported outcome measures (PROMs) are becoming increasingly important in the allocation of healthcare resources and the provision of guidelines for optimum care and management [89]. The Swedish reports were pioneer in that area and are still improving the way to collect this information and how to process that in numbers. In 2012 reports, patient satisfaction 1 year of THA (2010–2011) varied from 82.8 to 93.4%. They analyzed other variables such as pain relief, health-related quality of life gained, 90-day mortality, coverage, reoperation within 2 years, 5-year implant survival, 10-year implant survival, and set and nationwide standard for comparison with the obtained by institutions. The conclusions highlight the great challenge that it's to organize the structure of information and engage the participants. Important influences were appointed related to anxiety and depression in the predictor of pain, pain relief, and patient satisfaction [98]. There's no doubt that this patient-related information will have an increasing role in the advanced hip arthroplasty.

## **6. Perspectives to the future**

Although hip arthroplasty celebrates over 50 years since its creation, how the procedure has been slow in recent years. The main lines of research thus far developed are concentrated in areas that seek alternatives to metal implants, the use of new biomaterials, as well as the use of computer tools for planning and development of surgery [99].

Several studies involving existing prostheses on the market seek to improve efficiency by reducing the rejection or failure and to find synergy between the contact areas. With this, new surfaces, such as porous, the use of mesh titanium, and the development of metal-polyethylene interaction, are being researched [100, 101].

The area of biomaterials points to major advances. Examples are the use of hydroxyapatite for surface coating, the use of alternative bone graft as humans or bovine lyophilized to assist in cases of bone loss, as well as the development of multidisciplinary techniques for bone regeneration, as in the case of VasuBone Project [102–104].

Among the computer tools for programming and development of surgery, the navigation techniques are the most researched. The main distinguishing feature of this feature is that it provides real-time measurements and precise alignments [105–109].

## **7. Conclusions**

Regardless of the approach, the chosen implant, the THA surgery, is a major evolution of modern medicine and came as a great benefit to patients. Every technique employed should be well studied, and the patient must always be the most benefited from the surgery.

Acknowledgements

The authors would like to thank the Federal University of Rio Grande do Sul (UFRGS), Department of Orthopedics, Tissue Bank Unit, at the Hospital de Clínicas de Porto Alegre (HCPA), Porto Alegre, Rio Grande do Sul (RS), Brazil.

Conflict of interest

We hereby indicate that there is no financial or business interest concerning any author or their immediate family members of the manuscript entitled “Hip Arthroplasty.” The submitted manuscript is a study on the history of hip arthroplasty, total hip arthroplasty approaches, implant types, complications associated with hip arthroplasty, outcomes, and perspectives to the future.

We also confirm that no conflict of interest for drugs, devices or prosthesis, or any other materials either biological or synthetic exists in this study if they are not being particularly assessed as part of the investigation.

Moreover, no part of the investigation has been carried out or supported in grant by any related company or entity. None of the authors own stock, acted as a consultant, established contract work, served as an officer or member of the board, or received more than US\$ 2000 a year from any related company or entity within the past 2 years.

Each author fulfills the requirements for authorship and publicly and legally responds for the content of the above manuscript, and all authors have read this final version of the paper and are aware of its content and agreed with the submitted version of the manuscript.

We assure that the information above is absolutely accurate.

Notes/thanks/other declarations

The authors would like to thank the Research Group in Hip, Biomaterials and Tissue Bank, Hospital de Clínicas de Porto Alegre, Porto Alegre, Rio Grande do Sul, Brazil, for the opportunity in developing this work.

Nomenclature

OA	osteoarthritis
THA	total hip arthroplasty
DVT	deep vein thrombosis
PMMA	polymethyl methacrylate
Gpa	gigapascal
UHMWPE	ultrahigh-molecular-weight polyethylene
XLPE	highly cross-linked polyethylene
ROM	range of motion
LMWH	low-molecular-weight heparin
SSI	surgical site infection
PJI	periprosthetic joint infection
TJA	total joint arthroplasty
BMI	body mass index
MRSA	methicillin-resistant <i>Staphylococcus aureus</i>
MSSA	methicillin-sensitive <i>Staphylococcus aureus</i>
UTI	urinary tract infection



CRP	C-reactive protein
ESR	erythrocyte sedimentation rate
WBC	white blood cell
PMN%	polymorphonuclear neutrophil percentage
AAOS	American Academy of Orthopaedic Surgeons
PROs	patient-reported outcome
PROMs	patient-reported outcome measures

IntechOpen

### Author details

Carlos Roberto Galia<sup>1,2,3,4\*</sup>, Tiango Aguiar Ribeiro<sup>5,6</sup>, Cristiano Valter Diesel<sup>2,3</sup>,  
Marcelo Reuwsaat Guimarães<sup>7</sup> and Fernando Pagnussato<sup>2,4,8,9</sup>

1 Surgery Department, Federal University of Rio Grande do Sul (UFRGS),  
Porto Alegre, Rio Grande do Sul (RS), Brazil

2 Department of Orthopedics, Hospital de Clínicas de Porto Alegre (HCPA),  
Porto Alegre, Rio Grande do Sul (RS), Brazil

3 Medicine School of Federal University of Rio Grande do Sul (UFRGS),  
Porto Alegre, Rio Grande do Sul (RS), Brazil

4 Hospital de Clínicas de Porto Alegre (HCPA), Porto Alegre,  
Rio Grande do Sul (RS), Brazil

5 Surgery Department, Federal University of Santa Maria (UFSM), Santa Maria,  
Rio Grande do Sul (RS), Brazil

6 Department of Orthopedics (SOT), University Hospital of Santa Maria (UFSM),  
Santa Maria, Rio Grande do Sul (RS), Brazil

7 Orthopedic and Traumatologist Surgeon, Hospital de Clínicas de Porto Alegre  
(HCPA), Porto Alegre, Rio Grande do Sul (RS), Brazil

8 Federal University of Rio Grande do Sul. (UFRGS), Porto Alegre,  
Rio Grande do Sul (RS), Brazil

9 Tissue Bank, Hospital de Clínicas de Porto Alegre (HCPA), Porto Alegre,  
Rio Grande do Sul (RS), Brazil

\*Address all correspondence to: cgalia@hcpa.ufrgs.br

### IntechOpen

© 2019 The Author(s). Licensee IntechOpen. This chapter is distributed under the terms of the Creative Commons Attribution License (<http://creativecommons.org/licenses/by/3.0>), which permits unrestricted use, distribution, and reproduction in any medium, provided the original work is properly cited. 

## References

- [1] Jones CA et al. Health related quality of life outcomes after total hip and knee arthroplasties in a community based population. *The Journal of Rheumatology*. 2000;27(7):1745-1752
- [2] Laupacis A et al. The effect of elective total hip replacement on health-related quality of life. *The Journal of Bone and Joint Surgery*. 1993;75(11):1619-1626
- [3] Learmonth DC et al. The operation of the century: Total hip replacement. *The Lancet*. 2007;370(9597):1508-1519
- [4] Wood AM et al. A review on the management of hip and knee osteoarthritis. *International Journal of Chronic Diseases*. 2013;2013:10
- [5] Della Valle CJ, Rosenberg AG. Primary total hip arthroplasty: Indications and contraindications. In: Callaghan JJ, Rosenberg AG, Rubash HE, editors. *The Adult Hip*. Philadelphia, USA: Lippincott Williams & Wilkins; 2007. pp. 851-858
- [6] Gluck T. Die invaginationsmethode der osteo-und arthroplastik. *Berliner Klinische Wochenschrift*. 1890;28:732-736, 752-757
- [7] Haas J. Neue anwendungsgebiete der lorenz'schen bifurkation (gabelung des oberen femurendes). *Zentralblatt für Chirurgie*. 1927;54:783-785
- [8] Schwartzmann CR, Boschin LC. Quadril do adulto. In: Hebert S et al., editors. *Ortopedia e Traumatologia: Princípios e Prática*. Porto Alegre: Artmed Editora S. A.; 2009. pp. 407-442
- [9] Peltier LF. A history of hip surgery. In: Callaghan JJ, Rosenberg AG, Rubash HE, editors. *The Adult Hip*. Philadelphia, USA: Lippincott Williams & Wilkins; 2007. pp. 3-31
- [10] Wiles P. The Surgery of the osteoarthritic hip. *The British Journal of Surgery*. 1958;45:488-497
- [11] Waugh W. John Charnley: The Man and the Hip. London: Springer-Verlang; 1990
- [12] Charnley J. Total hip replacement by low-friction arthroplasty. *Clinical Orthopaedics and Related Research*. 1970;72:7-21
- [13] Charnley J. Anchorage of the femoral head prosthesis to the shaft of the femur. *The Journal of Bone and Joint Surgery*. 1960;42-B:28-30
- [14] Miller J. Pressure penetration of low viscosity acrylic cement for improved fixation of arthroplasty components. *The Journal of Bone and Joint Surgery*. 1982;64:619
- [15] Harris WH, McCarthy JC Jr, O'Neill DA. Femoral component loosening using contemporary techniques of femoral cement fixation. *The Journal of Bone and Joint Surgery*. 1982;64(7):1063-1067
- [16] Harris WH, McCarthy JC Jr, O'Neill DA. Loosening of the femoral component of total hip replacement after plugging the femoral canal. *The Hip*. 1982:228-238. PMID: 7166501. <https://www.ncbi.nlm.nih.gov/pubmed/7166501>
- [17] Lee AJ, Ling RS, Vangala SS. Some clinically relevant variables affecting the mechanical behaviour of bone cement. *Archives of Orthopaedic and Trauma Surgery*. 1978;92(1):1-18
- [18] Bobyn JD et al. Porous surfaced layered prosthetic devices. *Journal of Biomedical Engineering*. 1975;10:126-131
- [19] Bobyn JD et al. The optimum pore size for the fixation of porous-surfaced metal implants by the ingrowth of bone.

Clinical Orthopaedics and Related Research. 1980;**150**(150):263-270

[20] Galante J. Total hip replacement. The Orthopedic Clinics of North America. 1971;**2**(1):139-155

[21] Moore AT. Metal hip joint; a new self-locking vitallium prosthesis. Southern Medical Journal. 1952;**45**(11):1015-1019

[22] Kwon MS et al. Does surgical approach affect total hip arthroplasty dislocation rates? Clinical Orthopaedics and Related Research. 2006;**447**:34-38

[23] Macedo CAS et al. Comparação das abordagens ântero-lateral e posterior em artroplastia total primária de quadril. Revista Brasileira de Ortopedia. 1997;**32**(10):777-780

[24] Alencar PGC, Abagge M. Artroplastia total do quadril por via de acesso póstero-lateral. Revista Brasileira de Ortopedia. 1995;**30**:509-513

[25] Gore DR et al. Anterolateral compared to posterior approach in total hip arthroplasty: Differences in component positioning, hip strength, and hip motion. Clinical Orthopaedics and Related Research. 1982;**165**:180-187

[26] Vicente JRN et al. A influência da via de acesso na luxação das artroplastias totais do quadril. Revista Brasileira de Ortopedia. 2009;**44**:507-507

[27] Sikorski JM, Hampson WG, Staddon GE. The natural history and aetiology of deep vein thrombosis after total hip replacement. The Journal of Bone and Joint Surgery. 1981;**63-B**(2):171-177

[28] Matta JM, Shahrddar C, Ferguson T. Single-incision anterior approach for total hip arthroplasty on an orthopaedic table. Clinical Orthopaedics and Related Research. 2005;**441**:115-124

[29] DeWal H, Su E, DiCesare PE. Instability following total hip arthroplasty. American Journal of Orthopedics. 2003;**32**(8):377-382

[30] Paillard P. Hip replacement by a minimal anterior approach. International Orthopaedics. 2007;**31**(Suppl. 1):S13-S15

[31] Hardinge K. The direct lateral approach to the hip. The Journal of Bone and Joint Surgery. 1982;**64**(1):17-19

[32] Charnley J. Arthroplasty of the hip. A new operation. Lancet. 1961;**1**(7187):1129-1132

[33] Webb JC, Spencer RF. The role of polymethylmethacrylate bone cement in modern orthopaedic surgery. The Journal of Bone and Joint Surgery. 2007;**89**:851-857

[34] Rice J et al. Femoral cementing techniques in total hip replacement. International Orthopaedics. 1998;**22**(5):308-311

[35] Geiger MH et al. The clinical significance of vacuum mixing bone cement. Clinical Orthopaedics and Related Research. 2001;**382**:258-266

[36] Chambers IR et al. Radiological features predictive of aseptic loosening in cemented Charnley femoral stems. The Journal of Bone and Joint Surgery. 2001;**83**(6):838-842

[37] Ritter MA et al. Radiological factors influencing femoral and acetabular failure in cemented Charnley total hip arthroplasties. The Journal of Bone and Joint Surgery. 1999;**81**(6):982-986

[38] Langlais F et al. The 'French paradox'. The Journal of Bone and Joint Surgery. 2003;**85**(1):17-20

[39] Jayasuriya RL et al. Effect of sliding-taper compared with composite-beam cemented femoral prosthesis loading regime on proximal femoral bone remodeling: A

randomized clinical trial. *The Journal of Bone and Joint Surgery*. 2013;**95**(1):19-27

[40] New AM, Taylor M, Wroblewski BM. Effect of hip stem taper on cement stresses. *Orthopedics*. 2005;**28**(8 Suppl):s857-s862

[41] Sundberg M et al. Movement patterns of the C-stem femoral component: An RSA study of 33 primary total hip arthroplasties followed for two years. *The Journal of Bone and Joint Surgery*. 2005;**87**(10):1352-1356

[42] Ek ET, Choong PF. Comparison between triple-tapered and double-tapered cemented femoral stems in total hip arthroplasty: A prospective study comparing the C-stem versus the exeter universal early results after 5 years of clinical experience. *The Journal of Arthroplasty*. 2005;**20**(1):94-100

[43] Verdonschot N, Tanck E, Huiskes R. Effects of prosthesis surface roughness on the failure process of cemented hip implants after stem-cement debonding. *Journal of Biomedical Materials Research*. 1998;**42**(4):554-559

[44] Noiseux NO et al. Uncemented porous tantalum acetabular components: Early follow-up and failures in 613 primary total hip arthroplasties. *The Journal of Arthroplasty*. 2014;**29**(3):617-620

[45] Blaha JD, Borus TA. Press-fit femoral components. In: Callaghan JJ, Rosenberg AG, Rubash HE, editors. *The Adult Hip*. Philadelphia: Lippincott Williams & Wilkins; 2007. pp. 1036-1043

[46] Sporer SM, Paprosky WG. Biologic fixation and bone ingrowth. *The Orthopedic Clinics of North America*. 2005;**36**(1):105-111, vii

[47] Jasty M, Kienapfel H, Griss P. Fixation by ingrowth. In: Callaghan JJ, Rosenberg AG, Rubash HE, editors.

*The Adult Hip*. Philadelphia: Lippincott Williams & Wilkins; 2007. pp. 195-206

[48] Hozack WJ et al. Primary cementless hip arthroplasty with a titanium plasma sprayed prosthesis. *Clinical Orthopaedics and Related Research*. 1996;**333**:217-225

[49] Jasty M et al. In vivo skeletal responses to porous-surfaced implants subjected to small induced motions. *The Journal of Bone and Joint Surgery*. 1997;**79**(5):707-714

[50] Bobyn JD et al. Characteristics of bone ingrowth and interface mechanics of a new porous tantalum biomaterial. *The Journal of Bone and Joint Surgery*. 1999;**81**(5):907-914

[51] McKellop H et al. Development of an extremely wear-resistant ultra high molecular weight polyethylene for total hip replacements. *Journal of Orthopaedic Research*. 1999;**17**(2):157-167

[52] Engh CA Jr et al. A prospective, randomized study of cross-linked and non-cross-linked polyethylene for total hip arthroplasty at 10-year follow-up. *The Journal of Arthroplasty*. 2012;**27**(8 Suppl):2-7.e1

[53] Schwartzmann CR et al. Novas superfícies em artroplastia total do quadril. *Revista Brasileira de Ortopedia*. 2012;**47**:154-159

[54] Clarke MT et al. Levels of metal ions after small- and large-diameter metal-on-metal hip arthroplasty. *The Journal of Bone and Joint Surgery*. 2003;**85**(6):913-917

[55] Pandit H et al. Pseudotumours associated with metal-on-metal hip resurfacings. *The Journal of Bone and Joint Surgery*. 2008;**90**(7):847-851

[56] Tower SS. Arthroprosthetic cobaltism: Neurological and cardiac



manifestations in two patients with metal-on-metal arthroplasty: A case report. *The Journal of Bone and Joint Surgery*. 2010;**92**(17):2847-2851

[57] Ladon D et al. Changes in metal levels and chromosome aberrations in the peripheral blood of patients after metal-on-metal hip arthroplasty. *The Journal of Arthroplasty*. 2004;**19**(8 Suppl 3):78-83

[58] Ziaee H et al. Transplacental transfer of cobalt and chromium in patients with metal-on-metal hip arthroplasty: A controlled study. *The Journal of Bone and Joint Surgery*. 2007;**89**(3):301-305

[59] Jarrett CA et al. The squeaking hip: A phenomenon of ceramic-on-ceramic total hip arthroplasty. *The Journal of Bone and Joint Surgery*. 2009;**91**(6):1344-1349

[60] Restrepo C et al. The noisy ceramic hip: Is component malpositioning the cause? *The Journal of Arthroplasty*. 2008;**23**(5):643-649

[61] Min BW et al. Delayed fracture of a ceramic insert with modern ceramic total hip replacement. *The Journal of Arthroplasty*. 2007;**22**(1):136-139

[62] Walter WL et al. Edge loading in third generation alumina ceramic-on-ceramic bearings: Stripe wear. *Journal of Arthroplasty*. 2004;**19**(4):402-413

[63] Canale ST, Beaty JH. Arthroplasty of the hip. In: *Campbell's Operative Orthopaedics*. 12th ed. 2012. Vol. I. pp. 158-310

[64] Garellick G, Rogmark C, Kärrholm J, Rolfson O. Swedish Hip Arthroplasty Register Annual Report. 2012; 113-116

[65] Australian Orthopaedic Association National Joint Replacement Registry. Annual Report. 2014—Mortality following Primary Hip and Knee Replacement. Available from: <https://>

[aoanjrr.dmac.adelaide.edu.au/documents/10180/172288/Mortality%20following%20Primary%20Hip%20and%20Knee%20Replacement](http://aoanjrr.dmac.adelaide.edu.au/documents/10180/172288/Mortality%20following%20Primary%20Hip%20and%20Knee%20Replacement)

[66] American Academy of Orthopaedic Surgeons. AAOS Clinical Practice Guidelines (CPG): Preventing Venous Thromboembolic Disease in Patients Undergoing Elective Hip and Knee Arthroplasty. Available from: [http://www.aaos.org/Research/guidelines/VTE/VTE\\_guideline.asp](http://www.aaos.org/Research/guidelines/VTE/VTE_guideline.asp)

[67] Johnson R, Carmichael JH, Almond HG, Loynes RP. Deep venous thrombosis following Charnley arthroplasty. *Clinical Orthopaedics and Related Research*. 1978;**132**:24-30

[68] American College of Chest Physicians. Antithrombotic Therapy and the Prevention of Thrombosis: American College of Chest Physicians Evidence-based Guidelines. Resources related to these guidelines can be found on the ACCP Antithrombotic Guidelines 9th Ed. 2012

[69] ISMP—Institute for Safe Medication Practices. Monitoring FDA MedWatch Reports Anticoagulants the Leading Reported Drug Risk in 2011. Available from: <http://www.ismp.org/quarterwatch/pdfs/2011Q4.pdf>

[70] American Academy of Orthopaedic Surgeons. AAOS Clinical Practice Guidelines (CPG): Preventing Venous Thromboembolic Disease in Patients Undergoing Elective Hip and Knee Arthroplasty. Second edition. 2011

[71] Jevsevar D, Shea K, Cummins D, Murray J, Sanders J. Recent changes in the AAOS evidence-based clinical practice guidelines process. *The Journal of Bone and Joint Surgery*. 2014;**96**(20):1740-1741. DOI: 10.2106/JBJS.N.00658

[72] Brooks PJ. Dislocation following total hip replacement: Causes and cures. *The Bone & Joint Journal*.

2013;**95-B**(11 Suppl A):67-69. DOI: 10.1302/0301-620X.95B11.32645

[73] Lindgren V, Garellick G, Kärrholm J, Wretenberg P. The type of surgical approach influences the risk of revision in total hip arthroplasty: A study from the Swedish Hip Arthroplasty Register of 90,662 total hip replacements with 3 different cemented prostheses. *Acta Orthopaedica*. 2012;**83**(6):559-565. DOI: 10.3109/17453674.2012.742394

[74] Byström S, Espehaug B, Furnes O, Havelin LI, Norwegian Arthroplasty Register. Femoral head size is a risk factor for total hip luxation: A study of 42,987 primary hip arthroplasties from the Norwegian Arthroplasty Register. *Acta Orthopaedica Scandinavica*. 2003;**74**(5):514-524

[75] Prietzel T, Hammer N, Schleifenbaum S, Adler D, Pretzsch M, Köhler L, et al. The impact of capsular repair on the dislocation rate after primary total hip arthroplasty: A retrospective analysis of 1972 cases. *Zeitschrift für Orthopädie und Unfallchirurgie*. 2014;**152**(2):130-143. DOI: 10.1055/s-0034-1368209

[76] Barrack RL. Neurovascular injury: Avoiding catastrophe. *The Journal of Arthroplasty*. 2004;**19**(4 Suppl 1):104-107

[77] Post ZD, Orozco F, Diaz-Ledezma C, Hozack WJ, Ong A. Direct anterior approach for total hip arthroplasty: Indications, technique, and results. *The Journal of the American Academy of Orthopaedic Surgeons*. 2014;**22**(9):595-603

[78] Eggli S, Hankemayer S, Müller ME. Nerve palsy after leg lengthening in total replacement arthroplasty for developmental dysplasia of the hip. *The Journal of Bone and Joint Surgery*. 1999;**81**(5):843-845

[79] Zappe B, Glauser PM, Majewski M, Stöckli HR, Ochsner PE. Long-term

prognosis of nerve palsy after total hip arthroplasty: Results of two-year-follow-ups and long-term results after a mean time of 8 years. *Archives of Orthopaedic and Trauma Surgery*. 2014;**134**(10):1477-1482. DOI: 10.1007/s00402-014-2038-0

[80] JH1 P, Hozack B, Kim P, Norton R, Mandel S, Restrepo C, et al. Common peroneal nerve palsy following total hip arthroplasty: Prognostic factors for recovery. *The Journal of Bone and Joint Surgery*. 2013;**95**(9):e551-e555. DOI: 10.2106/JBJS.L.00160

[81] Wasielewski RC, Cooperstein LA, Kruger MP, Rubash HE. Acetabular anatomy and the transacetabular fixation of screws in total hip arthroplasty. *The Journal of Bone and Joint Surgery*. 1990;**72**(4):501-508

[82] Masri BA, Meek RM, Duncan CP. Periprosthetic fractures evaluation and treatment. *Clinical Orthopaedics and Related Research*. 2004;**420**:80-95. DOI: 10.1097/00003086-200403000-00012

[83] NV1 G, Mitchell PA, Masri BA, Garbuz DS, Duncan CP. Principles of management and results of treating the fractured femur during and after total hip arthroplasty. *Instructional Course Lectures*. 2003;**52**:309-322

[84] Misur PN, Duncan CP, Masri BA. The treatment of periprosthetic femoral fractures after total hip arthroplasty. *JBJS Reviews*. 2014;**2**(8):1-9

[85] Parvizi J, Gehrke T. Proceedings of the International Consensus Meeting on Periprosthetic Joint Infection. Available from: <http://www.msis-na.org/wp-content/themes/msis-temp/pdf/ism-periprosthetic-joint-information.pdf>

[86] Mauerhan DR, Nelson CL, Smith DL, Fitzgerald RH Jr, Slama TG, Petty RW, et al. Prophylaxis against infection in total joint arthroplasty. One day of

cefuroxime compared with three days of cefazolin. *The Journal of Bone and Joint Surgery*. 1994;**76**(1):39-45

[87] Klouche S, Lhotellier L, Mamoudy P. Infected total hip arthroplasty treated by an irrigation-debridement/ component retention protocol. A prospective study in a 12-case series with minimum 2 years' follow-up. *Orthopaedics & Traumatology, Surgery & Research*. 2011;**97**(2):134-138

[88] Espehaug B, Furnes O, Havelin LI, Engesaeter LB, Vollset SEJ. The type of cement and failure of total hip replacements. *The Journal of Bone and Joint Surgery*. 2002;**84**(6):832-838

[89] Garellick G, Rogmark C, Kärrholm J, Rolfson O. Swedish Hip Arthroplasty Register Annual Report. 2012

[90] National Joint Registry for England and Wales. 11th Annual Report. 2014. Available from: [http://www-new.njrcentre.org.uk/njrcentre/Portals/0/Documents/England/Reports/11th\\_annual\\_report/NJR%2011th%20Annual%20Report%202014.pdf](http://www-new.njrcentre.org.uk/njrcentre/Portals/0/Documents/England/Reports/11th_annual_report/NJR%2011th%20Annual%20Report%202014.pdf) [Accessed: Jan 26, 2015]

[91] Troelsen A, Malchau E, Sillesen N, Malchau H. A review of current fixation use and registry outcomes in total hip arthroplasty: The uncemented paradox. *Clinical Orthopaedics and Related Research*. 2013;**471**(7):2052-2059. DOI: 10.1007/s11999-013-2941-7

[92] Wyatt M, Hooper G, Frampton C, Rothwell A. Survival outcomes of cemented compared to uncemented stems in primary total hip replacement. *World Journal of Orthopedics*. 2014;**5**(5): 591-596. DOI: 10.5312/wjov.v5.i5.591

[93] Australian Orthopaedic Association National Joint Replacement Registry. Annual Report. 2014. Available from: <https://aoanjrr.dmac.adelaide.edu.au/documents/10180/172288/Mortality%20following%20Primary%20Hip%20>

[and%20Knee%20Replacement](#) [Accessed: Jan 26, 2015]

[94] McLaughlin JR, Lee KR. Uncemented total hip arthroplasty with a tapered femoral component: A 22- to 26-year follow-up study. *Orthopedics*. 2010;**33**(9):639. DOI: 10.3928/01477447-20100722-40

[95] Evola FR, Evola G, Graceffa A, Sessa A, Pavone V, Costarella L, et al. Performance of the CLS Spotorno uncemented stem in the third decade after implantation. *The Bone & Joint Journal*. 2014;**96-B**(4):455-461. DOI: 10.1302/0301-620X.96B4.32607

[96] Chawda M, Hucker P, Whitehouse SL, Crawford RW, English H, Donnelly WJ. Comparison of cemented vs uncemented acetabular component positioning using an imageless navigation system. *The Journal of Arthroplasty*. 2009;**24**(8):1170-1173. DOI: 10.1016/j.arth.2008.09.018

[97] Breusch SJ, Norman TL, Schneider U, Reitzel T, Blaha JD, Lukoschek M. Lavage technique in total hip arthroplasty: Jet lavage produces better cement penetration than syringe lavage in the proximal femur. *The Journal of Arthroplasty*. 2000;**15**(7):921-927

[98] Rolfson O. Patient-reported Outcome Measures and Health-economic Aspects of Total Hip Arthroplasty—A study of the Swedish Hip Arthroplasty Register. Institute of Clinical Sciences at Sahlgrenska Academy University of Gothenburg, Sweden. 2010

[99] Affatato S. Perspectives in Total Hip Arthroplasty: Advances in Biomaterials and their Tribological Interactions. Netherlands: Amsterdam: Elsevier: Woodhead Publishing; 2014. p. 164

[100] Pulido L, Rachala SR, Cabanela ME. Cementless acetabular revision: Past, present, and future. *Revision total hip arthroplasty: The acetabular*

side using cementless implants.  
International Orthopaedics.  
2011;**35**(2):289-298

[101] Mont MA et al. The Future  
of high performance total hip  
arthroplasty. *Seminars in Arthroplasty*.  
2006;**17**(2):88-92

[102] Galia CR et al. Caracterização  
físico-química de ossos liofilizados  
de origem bovina e humana. *Revista  
do Colégio Brasileiro de Cirurgias*.  
2009;**36**:157-160

[103] Goosen JH et al. Porous-coated  
femoral components with or without  
hydroxyapatite in primary uncemented  
total hip arthroplasty: A systematic  
review of randomized controlled trials.  
*Archives of Orthopaedic and Trauma  
Surgery*. 2009;**129**(9):1165-1169

[104] Walles H, Andrees-Ostovan I.  
VascuBone. 2013. Available from: [http://  
www.vascubone.fraunhofer.eu/](http://www.vascubone.fraunhofer.eu/) [cited  
10-11-2014]

[105] National Joint Registry for  
England and Wales. 11th Annual  
Report. 2014. Available from: [http://  
www-new.njrcentre.org.uk/njrcentre/  
Portals/0/Documents/England/  
Reports/11th\\_annual\\_report/NJR%20  
11th%20Annual%20Report%202014.  
pdf](http://www-new.njrcentre.org.uk/njrcentre/Portals/0/Documents/England/Reports/11th_annual_report/NJR%2011th%20Annual%20Report%202014.pdf) [Accessed: Jan 26, 2015]

[106] Hafez MA, Digioia AM. Computer-  
assisted total hip arthroplasty:  
The present and the future. *Future  
Rheumatology*. 2006;**1**(1):121-131

[107] Kunz M et al. Computer-assisted  
hip resurfacing using individualized  
drill templates. *The Journal of  
Arthroplasty*. 2010;**25**(4):600-606

[108] Sugano N et al. Comparison of  
mini-incision total hip arthroplasty  
through an anterior approach and a  
posterior approach using navigation.  
*The Orthopedic Clinics of North  
America*. 2009;**40**(3):365-370

[109] Tarwala R, Dorr LD. Robotic  
assisted total hip arthroplasty  
using the MAKO platform. *Current  
Reviews in Musculoskeletal Medicine*.  
2011;**4**(3):151-156