

We are IntechOpen, the world's leading publisher of Open Access books Built by scientists, for scientists

6,900

Open access books available

185,000

International authors and editors

200M

Downloads

Our authors are among the

154

Countries delivered to

TOP 1%

most cited scientists

12.2%

Contributors from top 500 universities



WEB OF SCIENCE™

Selection of our books indexed in the Book Citation Index
in Web of Science™ Core Collection (BKCI)

Interested in publishing with us?
Contact book.department@intechopen.com

Numbers displayed above are based on latest data collected.
For more information visit www.intechopen.com



Virtual Bronchoscopy for Tumors and Traumatic Lesions of the Airways

Kotlyarov Peter Mikhaylovich

Abstract

The given MSCT of 26 patients with tumoral damage of a trachea is analyzed. Data of MSCT of 61 patients with tumoral damage of bronchial tubes of primary and secondary genesis and hyperplastic lymph nodes are analyzed. In the analysis, a comprehensive analysis of the native, post-processing data and volumetric reconstructions allows more fully appreciating the nature of the changes, the topography, the extent and prevalence of neoplastic lesions tracheobronchial system. Differential diagnostics of benign and malignant lesions are conducted especially in the stenotic lesions when execution of bronchofibroscopy was impossible. Virtual bronchoscopy (VB) MSCT allowed determining the presence of a complete or partial rupture of the main bronchus, its distance to the bifurcation of the trachea, the state of the collapsed lung, the presence of fluid in the hemithorax, and secondary changes in the bone structures of the chest. The VB played an important role in monitoring the adequacy of reconstructive measures on the damaged bronchus, excluding the occurrence of postoperative stenosis. Virtual bronchoscopy of multispiral computed tomography with the capabilities of multiplanar and volumetric reconstructions and post-processing image processing is an optimal noninvasive method for determining the traumatic lesion of the main bronchi and monitoring the success of the reconstructive surgical manual

Keywords: virtual bronchoscopy, multislice computed tomography, tumor airways, traumatic bronchus rupture

1. Virtual bronchoscopy multislice computer tomography in diagnostics of neoplastic lesions of the tracheobronchial systems

1.1 Introduction

The defeat of the tracheobronchial system (TBS) by cancer is 17.8% in men and 3.7% in women [1]. Trachea, in addition to primary tumors, can be affected a second time with cancers of the esophagus, thyroid, and lungs. A number of benign tumors grow inside the lumen of the trachea and bronchi, causing a violation of the lung ventilation. Large bronchi may be secondarily affected in the central and peripheral forms of lung cancer [2–4]. The introduction of clinical practice of multispiral computed tomography (MSCT) clinical practice, new technologies of data collection, and post-processing image processing allowed developing a program of

3D reconstruction of the tracheobronchial system (TBS) with the ability to view its inner surface in real-time virtual bronchoscopy (VB) [2–16]. In addition to VB methods such as minimum and maximum intensity (MinIP, MIP) images, the mode of shaded surfaces—VTR allow to assess the state of the outer wall of the TBS, the relationship with adjacent organs and tissues [4, 5, 8, 16]. Comparison of the data of FBS and VB of the zone of interest showed their coincidence in the evaluation of the macrostructure of the bronchial lumen, the presence of intrabronchial tumor masses, and their type and localization [4, 9, 12]. In addition, the study of the bronchus distal to the stenosis at bronchoscopy is difficult and VB is the only method giving the possibility to evaluate the macrostructure of the bronchus beyond the area of narrowing [2, 5, 16]. The restrained attitude to VB of radiologists of foreign countries at the initial stage of data accumulation was replaced by a wide application of the method in clinical practice, as indicated by a significant increase in publications in recent years [2, 3, 7–13]. The purpose of the study is to clarify the concept of VB techniques and their role in improving the diagnostic information content of CT in the diagnosis and prevalence of neoplastic lesions of TBS.

1.2 Materials and methods of research

The MSCT data of 26 patients with tracheal tumor lesions were analyzed. Adenoid cystic cancer of the trachea was observed in 10 (32, 25%) patients, squamous cell in 6 (of 19.35%) patients, and neoplastic lesions of the trachea in 5 patients; the process has spread outside the body wall infiltrating the surrounding tissue. Of 10 (32, 25%) patients who had benign tumor, 4 had adenoma of the trachea, 3 had polyp, and 3 had papillomatosis. We analyzed patients' data of 61 MSCT with a neoplastic lesion of the bronchi of primary and secondary origin and hyperplastic lymph nodes. Lung cancer took place in 35 (57.37%) patients, metastatic lung damage and lymph nodes were observed in 5 (8.19%), and post-inflammatory hyperplasia of the lymph node adjacent to the bronchus in 4 (6.55%). In 17 (27, 86%) patients, benign bronchial formations of adenoma—8, polyposis—5 and papillomatosis—4 were revealed.

The diagnosis was verified in all patients in the process of material sampling in FBS and morphology according to the results of surgery.

MSCT was performed on 128-slice computed tomography company “GE Healthcare”, model “Optima CT 660”. Post-processing data processing, obtaining virtual bronchograms, and 3D imaging were performed at the workstation “Optima CT 660”. Постпроцессинговая обработка данных, получение виртуальных бронхограмм. 3D изображений проводилась на рабочей станции Advantage Workstation (GE). Toshiba Aquilion 16 (16-slice) and Aquilion ONE (320-slice) according to the previously described method [4–6, 26]. A comparative analysis of the value of different methods of MSCT VB in determining the lesion of TBS showed the need to use them in a complex for the full characteristics of both the intraluminal part of the trachea, carina, the main bronchi, and the outer wall in the images of the minimum (MinIP) and maximum intensity (MIP). For the reconstruction of 3D data in the images of virtual bronchoscopy, the technique of three-dimensional modeling was used, which produced a three-dimensional array with the display of the inner and the outer surface of the bronchi. Based on these data, a VB examination of the tracheobronchial tree was performed using VB fly-through method and volumetric reconstruction of the lung and its structures. In order to obtain the outer surface of the lung, trachea, or bronchi, the technique of obtaining an image of shaded surfaces and volume conversion was used. The complex analysis necessarily includes the data of native MSCT, the results of which allow avoiding false positive and negative conclusions in the presence of mucus and scar changes in the TBS.

1.3 Results of a research

Data of CT VB of 16 patients with cancer of the trachea were analyzed. At VB tumor mass spreading inside the body lumen was multinodular masses presented heterogeneous density and narrowing the lumen of the organ. The tumor was localized on the wall of the trachea with a wide base, spreading along it or circularly. The tracheal rings of the affected area were not visualized. Followed by multiplanar image reconstruction in MinIP mode, shaded surfaces and volume data transformations allowed visualizing the distribution of neoplastic lesions in the wall of the trachea, the length and volume of the lesion, and the degree of overlap of the organ lumen (**Figure 1**). In 11 patients, the tumor was localized within the tissues of the organ, without infiltrating the surrounding tissue, and in 5 patients, the tracheal wall sprouted and spread to the mediastinal tissue and esophagus (1 patient). In 6 out of 11 patients, the outer edge of the wall had a flat surface and the tumor process spread mainly along the inner surface of the organ, without infiltrating the wall. Thickening of the tracheal wall was observed in five patients, indicating its tumor infiltration. The nonorgan part of the tumor was heterogeneous and multi-nodular, without clear contours with the surrounding tissue. Tumors of the trachea chaotically accumulated a contrast material during bolus contrast enhancement. Followed by multiplanar reconstruction in MIP and MinIP modes, an unorganized component of the trachea cancer was clearly identified. Signs of esophageal germination were compression, overlapping of its lumen, and dilation above the site of infiltration (one patient). Increased regional lymph nodes (diameter 13–17 mm) were additionally determined in five patients, indicating a high degree of probability of metastatic lesions. This MSCT VB did not allow determining the morphological variant of malignant lesions and the state of the tracheal mucosa of the affected area and intact areas.

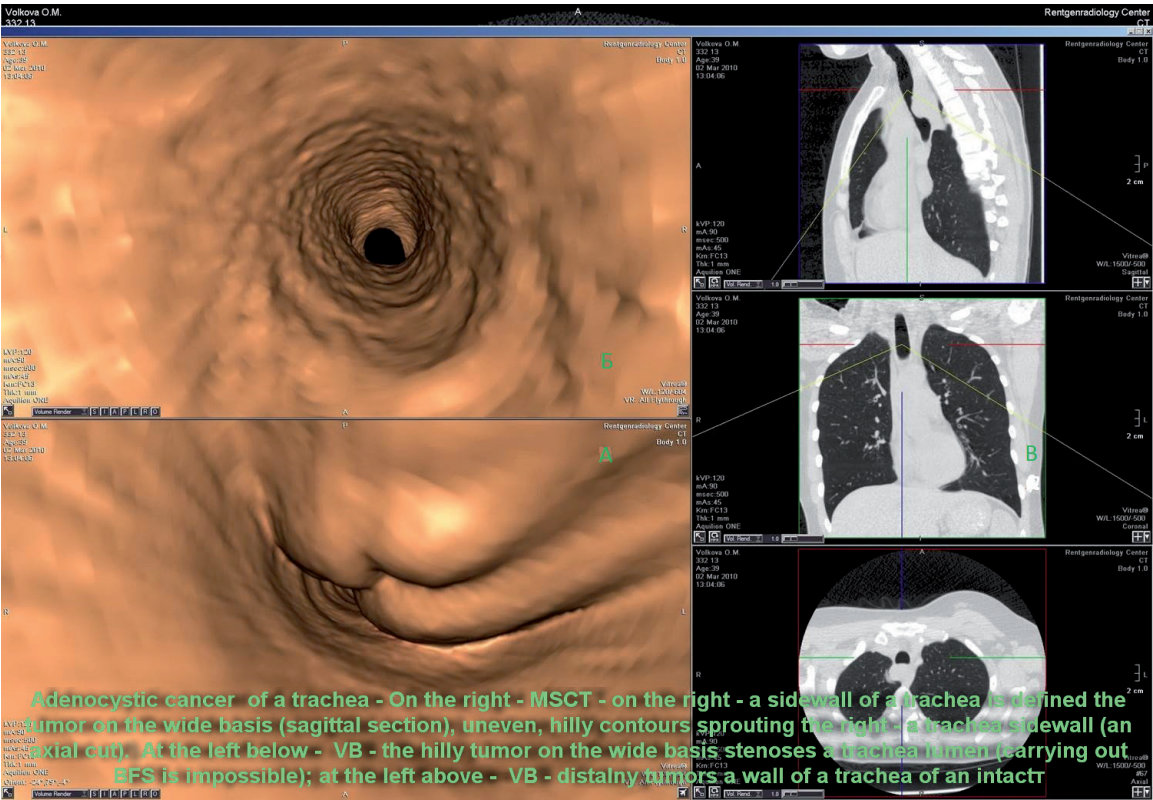


Figure 1.
AQ-Adenocystic cancer of a trachea – On the right – MSCT – on the right – a sidewall of a trachea is defined the tumor on the wide basis (sagittal section), uneven, hilly contours sprouting the right – a trachea sidewall (an axial cut). At the left below – VB – the hilly tumor on the wide basis stenoses a trachea lumen (carrying out BFS is impossible); at the left above – VB – distalny tumors a wall of a trachea of an intact.

The MSCT data of 10 patients with benign tracheal formations were analyzed. Benign formations were characterized by a smooth surface, homogeneous internal structure, no infiltration of the wall, and the destruction of the cartilage of the trachea. Benign tumor of the trachea performed into the lumen of it making its lumen narrowed (**Figure 2a, b**). Focal changes emanating from the exterior pushed them to the opposite side without narrowing of lumen and signs of infiltration of the exterior wall.

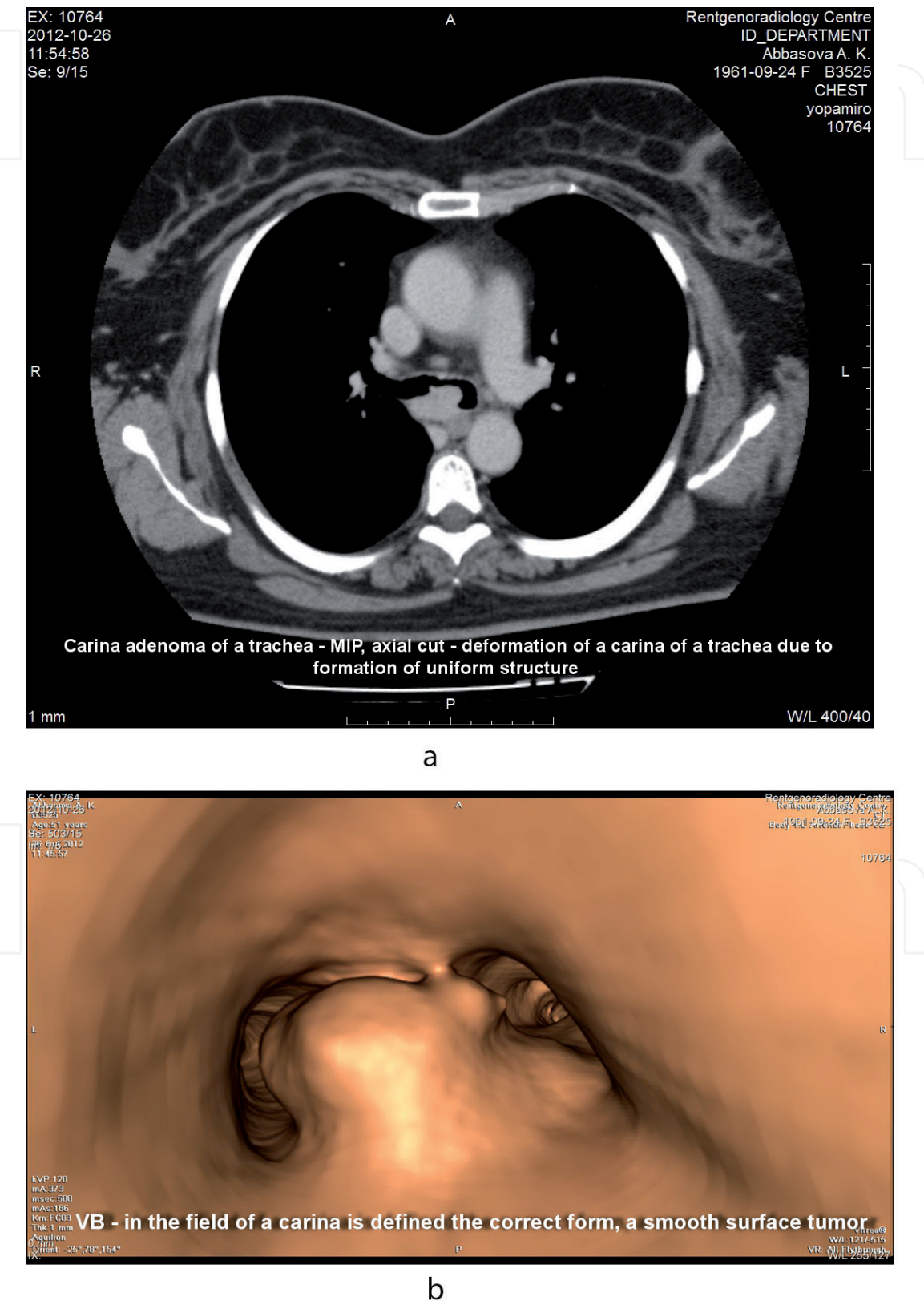

Figure 2.
a. Carina adenoma of a trachea – MIP, axial cut – deformation of a carina of a trachea due to formation of uniform structure. b. VB – in the field of a carina is defined the correct form, a smooth surface tumor.

With growth in the direction of the esophagus, the latter was also pushed aside by the formation without signs of its infiltration. Papillomatosis, polyps manifested by visualization of smooth, on the peduncle, the correct form coming from the mucous linear structures localized on the side wall of the trachea (**Figure 3**).

As shown by the combined analysis of native MSCT data and VB techniques (fly-through, MinIP, MIP, and 3D reconstruction), this approach is highly effective in the predictive test of the nature of both primary and secondary organ damage. Benign formations (adenoma, polyp, and others) were characterized by the presence of peduncles, linking the formation and mucous trachea, the wall of which was not thickened or infiltrated. The benign one went out into the lumen of the trachea. It had the right shape, smooth surface, and homogeneous structure. Secondary displacements of the trachea by benign processes emanating from the mediastinum and the esophagus are manifested by the displacement of the organ to the opposite side from the formation, without signs of infiltration of the wall.

Thus, the signs of malignancy tumors of the trachea were wide base and destruction of the adjacent cartilage structures, a rough bumpy surface, infiltration of the wall of the trachea in length, the output of the process beyond the body with tissue infiltration in the mediastinum, spreading to the esophagus. Additional signs of malignancy of changes were visualizations of enlargement of regional lymph nodes.

The data of MSCT VB in 35 patients with lung cancer were analyzed. Three variant neoplastic lesions of the bronchi, mostly peribronchial, intrabronchial, and a combined form of infiltration were observed. As a result of the study, according to the methods of VB fly-through, the leading method of determining the macrostructure and the border of the intrabronchial lesion that were inside the lumen of the bronchus, multinodal, polypoid masses were visualized, usually located on a wide base, narrowing the bronchus down to complete obstruction (**Figure 4a, b**).

The cartilaginous structures of the bronchus in the affected area were not visualized. The distribution of the lesions in the area of the branching of the bronchi last

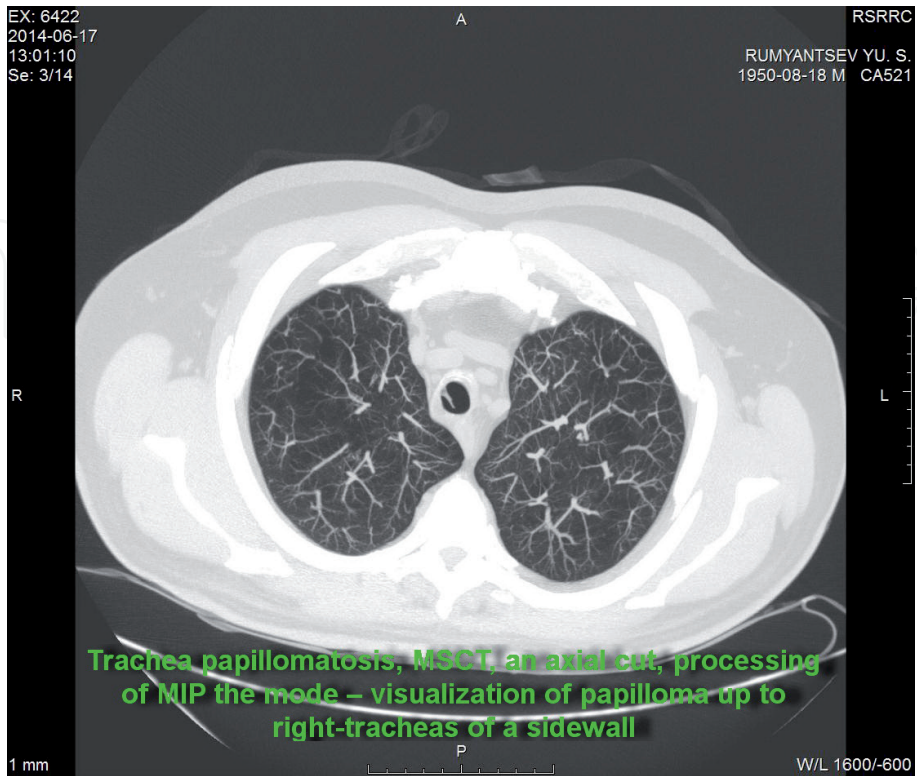
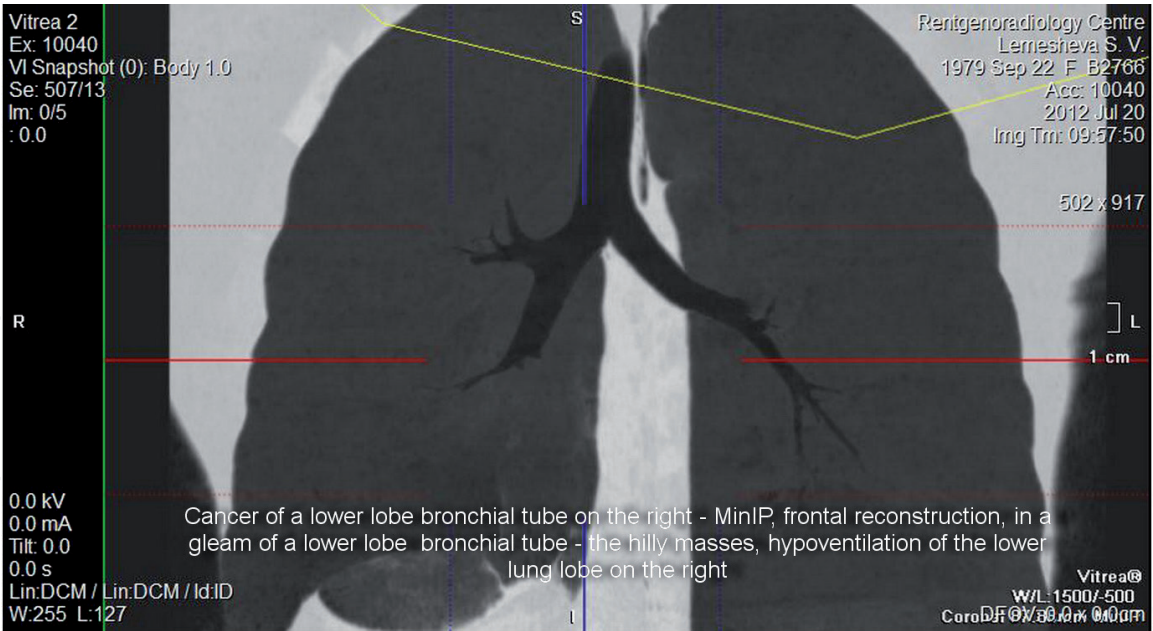
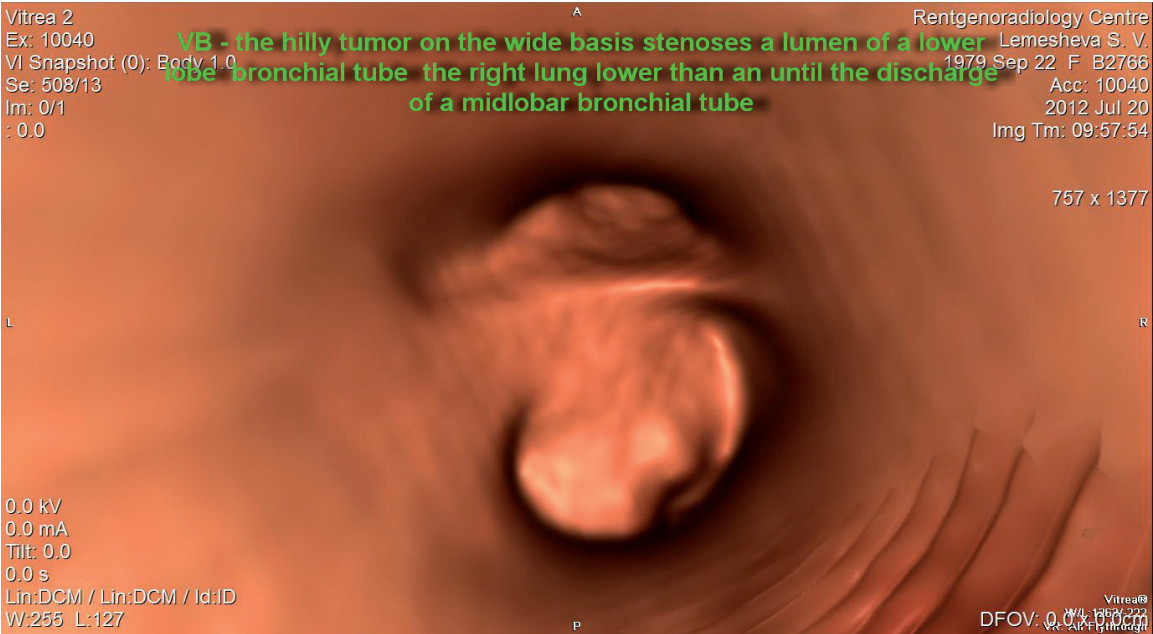


Figure 3.
Trachea papillomatosis, MSCT, an axial cut, processing of MIP the mode – visualization of papilloma up to right-tracheas of a sidewall.



a



b

Figure 4.
a. Cancer of a lower lobe bronchial tube on the right – MinIP, frontal reconstruction, in a gleam of a lower lobe bronchial tube – the hilly masses, hypoventilation of the lower lung lobe on the right. b. VB – the hilly tumor on the wide basis stenoses a lumen of a lower lobe bronchial tube the right lung lower than an until the discharge of a midlobar bronchial tube.

lost “pointed” appearance and grew deformed. Carina of the trachea with peribronchial spread the tumor from smooth and it turned into tumor growths covered with shapeless structure. Image of the trachea and bronchi in MIP and MinIP modes and 3D volumetric reconstructions completed the picture WB flythrough, allowing to evaluate the association of intrabronchial mass with pulmonary part of the tumor, and thus, to obtain a holistic view of the prevalence of lung cancer (**Figure 5a, b**).

In peribronchial infiltration (four patients with central cancer), semiotic signs in the mode of MinIP were visualized with varying degrees of local narrowing of the bronchial lumen. The transition of a changed plot of pathologically unchanged tissue of the bronchus was a border infiltration and was a “bayonet-like” extension of the lumen. The analysis showed the presence of sub-variants of peribronchial

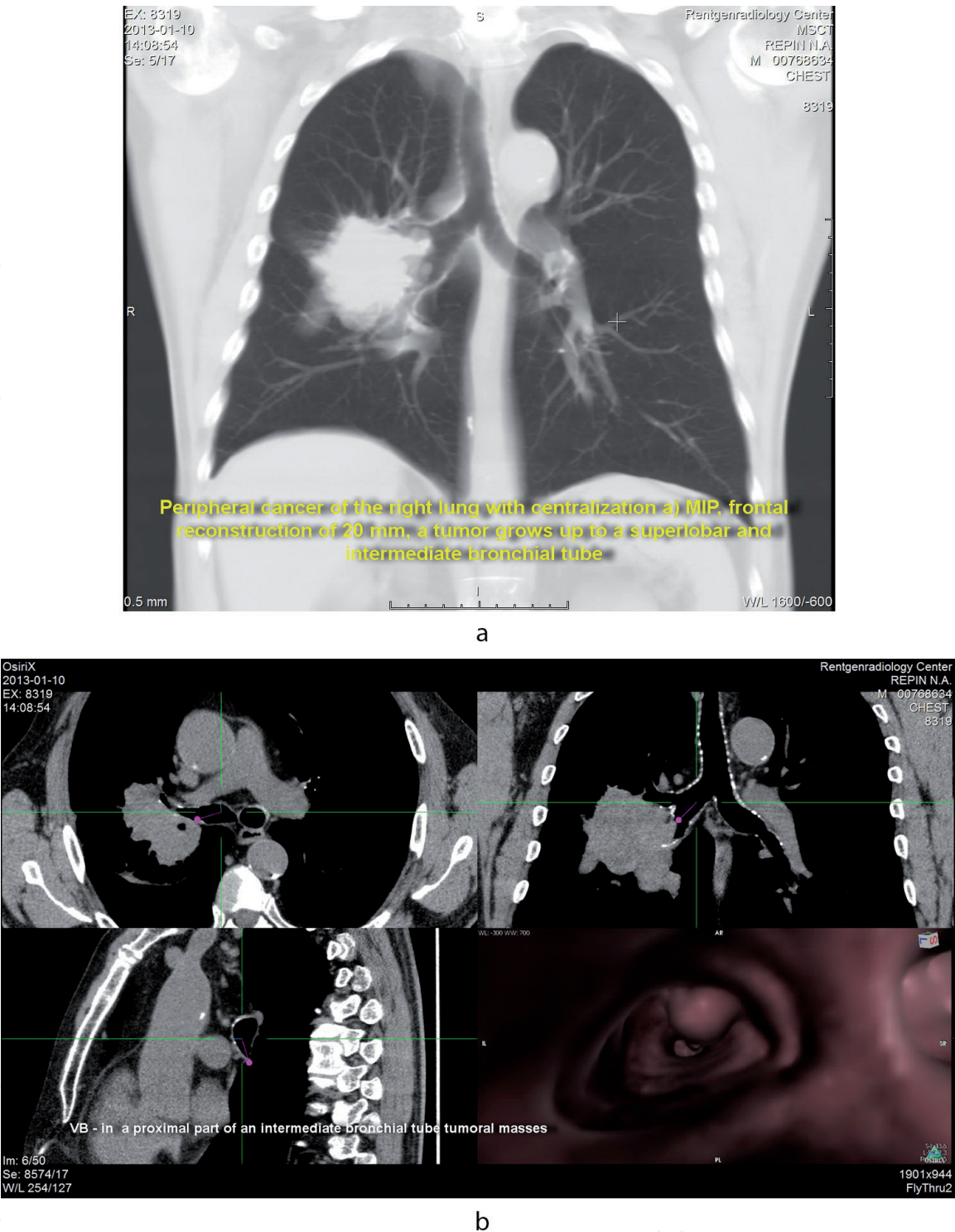


Figure 5.
a. Peripheral cancer of the right lung with centralization a) MIP, frontal reconstruction of 20 mm, a tumor grows up to a superlobar and intermediate bronchial tube. b. VB – in a proximal part of an intermediate bronchial tube tumoral masses.

tumor growth—circular, when they infiltrated all the walls of the bronchi and focal-segmental, in which the tumor struck one of the walls of the bronchus. Method VB fly-through was detected in this group of patients, along with narrowing of the lumen of the bronchus and the disappearance of the rosary-like structure of the bronchi due to infiltration of the cartilaginous structures.

The mixed variant of TBS infiltration was characterized by a combination of symptoms of one and two variants of VB (six patients with central and two peripheral cancer). In addition to intrabronchial component of the tumor, peribronchial growth was determined in the direction of the main, lobar bronchi, trachea.

One of the tasks of MSCT in lung cancer is to determine the boundaries of tumor infiltration and its prevalence in the proximal TBS, which is essential for the planning of the operation. This is due to the close connection in the area of the gates of the lungs and bronchi, large arterial and venous vessels, lymph nodes, and fibrous changes as a result of previous inflammatory processes, which make it difficult to detect tumor infiltration of the main bronchi and trachea according to native CT; however, it is essential for the planning of surgery [17]. Data native MSCT are not always enough to fully answer the question of the defeat of the trachea in lung cancer. Tumor infiltration can be observed in both central and peripheral cancer with centralization. Signs of infiltration at fly-through VB main bronchus, the trachea was narrowing of the lumen, no visualization of cartilage structures: bronchi become deformed tubular structure. The area of preserved cartilage structures indicated the edge of tumor infiltration. According to MSCT VB, three options of neoplastic lesions of the trachea with lung cancer were allocated—predominantly paratracheal (two patients), mainly intrabronchial (three patients), and combined form of infiltration (one patient). In the first variant—peritracheal infiltration—the leading technique was the analysis of images of MinIP, which allowed to clarify the data of the primary MSCT. Semiotic signs in the MinIP mode of infiltration of the external part of the trachea by the tumor were local narrowing of the tracheal lumen. The boundary of the infiltrated tissues, as in the case of bronchial lesions, was determined by the place of visualization of cartilaginous rings and the expansion of the tracheal lumen. With mainly intra-tracheal tumor growth, the leading technique for determining the macrostructure and the lesion boundary was VB and images in MinIP and MIP mode. When this cartilage structure was not visualized, the lumen bumpy, polyp-like mass. Cartilaginous structures of the affected area were not visualized (**Figure 6a–c**).

3D reconstructions in the mode of semitransparent or shaded surfaces were auxiliary in nature, giving a volumetric representation of the extent of changes and supplementing the data of both methods, both in the presence of changes and the boundaries of infiltrative changes. Construction of 3D reconstructions made it possible to obtain a three-dimensional image of the pathology zone and surrounding tissues, including vessels, comparing them with the tumor array, which allows for virtual reconstruction of the surgical intervention zone for optimal choice of surgical tactics.

In five patients, metastatic lesions of the lungs and lymph nodes of the organ gate were revealed (primary kidney cancer in three and colon cancer in two patients). Part of the foci infiltrated segmental, lobar bronchi, enlarged lymph node packages caused their compression, which led to a violation of ventilation of the affected segments and lung lobes up to the development of atelectasis. In VB fly-through of affected bronchi, narrowing lumen nodules and changes in the macrostructure of the bronchial wall in the infiltration zone were clearly identified as secondary foci when compared with the results of the analysis of MinIP images of the zone of interest and data of the native MSCT. When compression of the bronchus of the affected package metastatic lymph nodes were detected luminal narrowing without signs of the wall infiltration (**Figure 7**).

The MSCT data of 17 patients with benign tracheal formations (adenoma, polyp, and others) were analyzed. Benign tumors were characterized by the correct form, a smooth surface, a homogeneous internal structure, the absence of infiltration of the wall, and destruction of the cartilage of the bronchial wall. The localization in the mucous membrane of the tumor was visualized in the lumen of the bronchus, causing narrowing (**Figure 8**).

Papillomatosis, polyps manifested by the visualization of smooth, on the peduncle, the correct form of the structures emanating from the bronchial

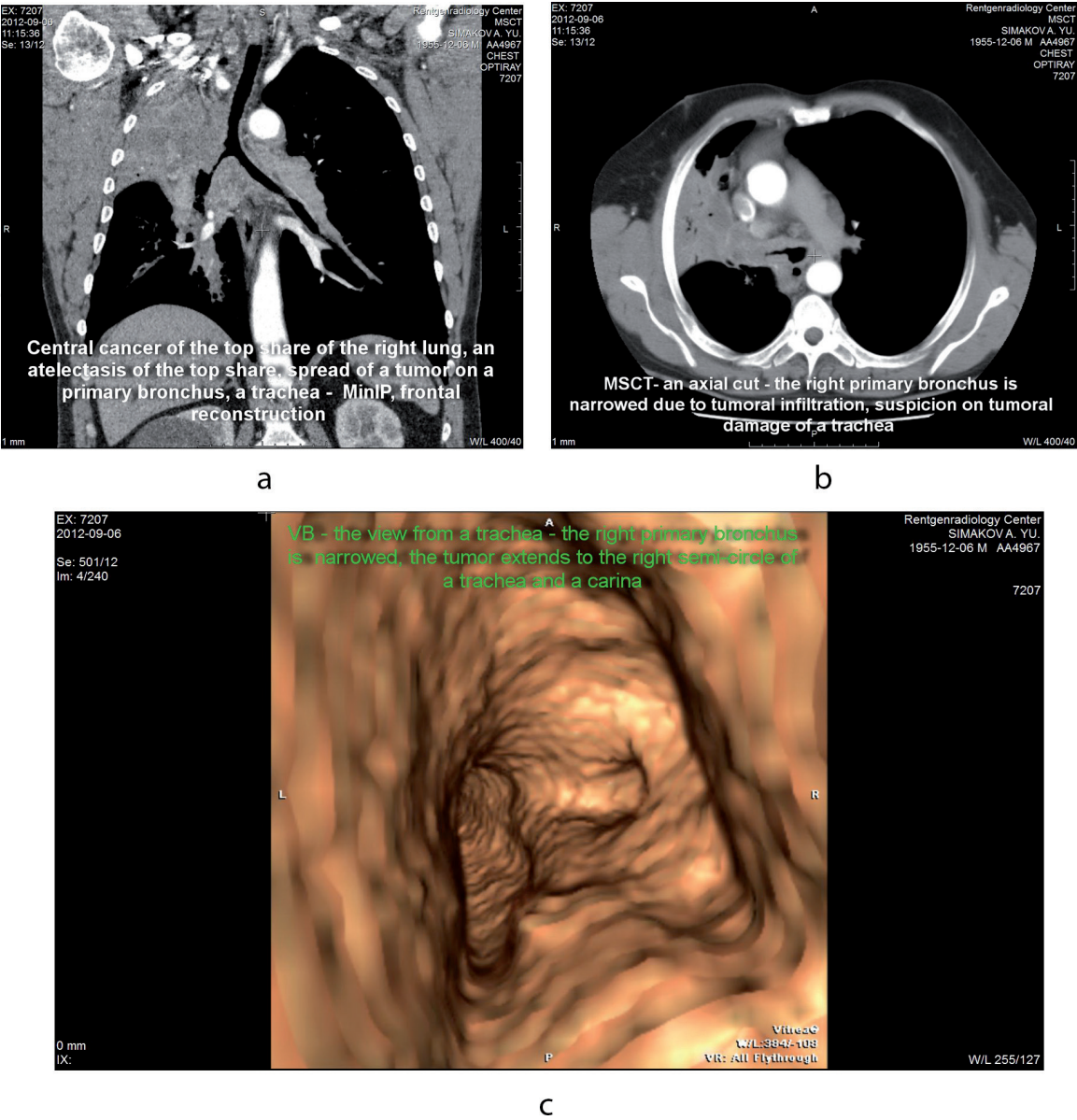


Figure 6.
a. Central cancer of the top share of the right lung, an atelectasis of the top share, spread of a tumor on a primary bronchus, a trachea – MinIP, frontal reconstruction. b. MSCT – an axial cut – the right primary bronchus is narrowed due to tumoral infiltration, suspicion on tumoral damage of a trachea. c. VB – the view from a trachea – the right primary bronchus is narrowed, the tumor extends to the right semi-circle of a trachea and a carina.

mucosa. In some cases, the external pressure of the adjacent single enlarged lymph node can simulate a benign tumor (four patients). Comprehensive data analysis of native MSCT and fly-through VB allowed to determine that the deformation and narrowing of the lumen of the bronchus was associated with the presence of external pressure adjacent to the bronchial lymph node (**Figure 9**). The presence of visual information made it possible to develop a “road map” to perform FBS in order to determine the optimal place for the collection of material for cytological examination, to calculate the depth of the puncture of the wall of the affected bronchus part.

As shown by the combined analysis of native MSCT data and VB techniques, this approach is highly effective in predictive testing of the nature of both primary and secondary TBS lesions. In benign formations (adenoma, polyp, and others), the macrostructure of cartilage structures was preserved, and there was no infiltration of the surrounding tissues. The benign one was protruded into the lumen of the trachea and had the right shape, smooth surface, and homogeneous structure.

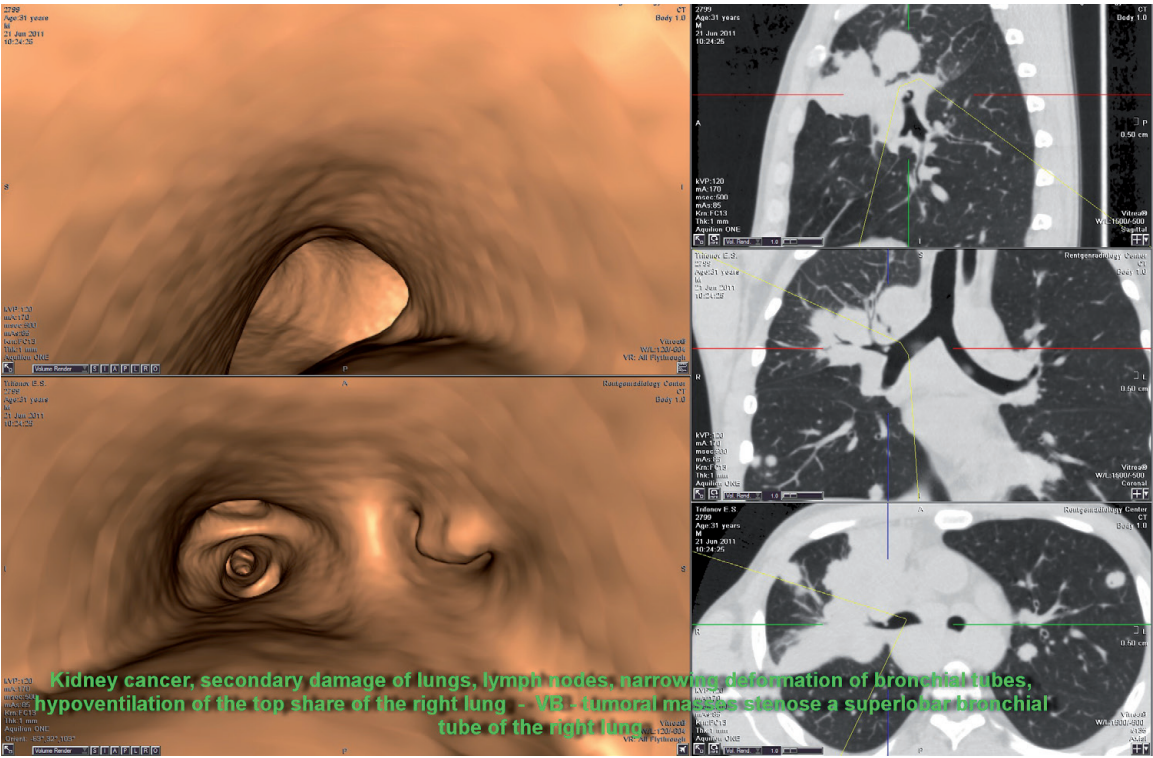


Figure 7.
Kidney cancer, secondary damage of lungs, lymph nodes, narrowing deformation of bronchial tubes, hypoventilation of the top share of the right lung – VB – tumoral masses stenose a superlobar bronchial tube of the right lung.

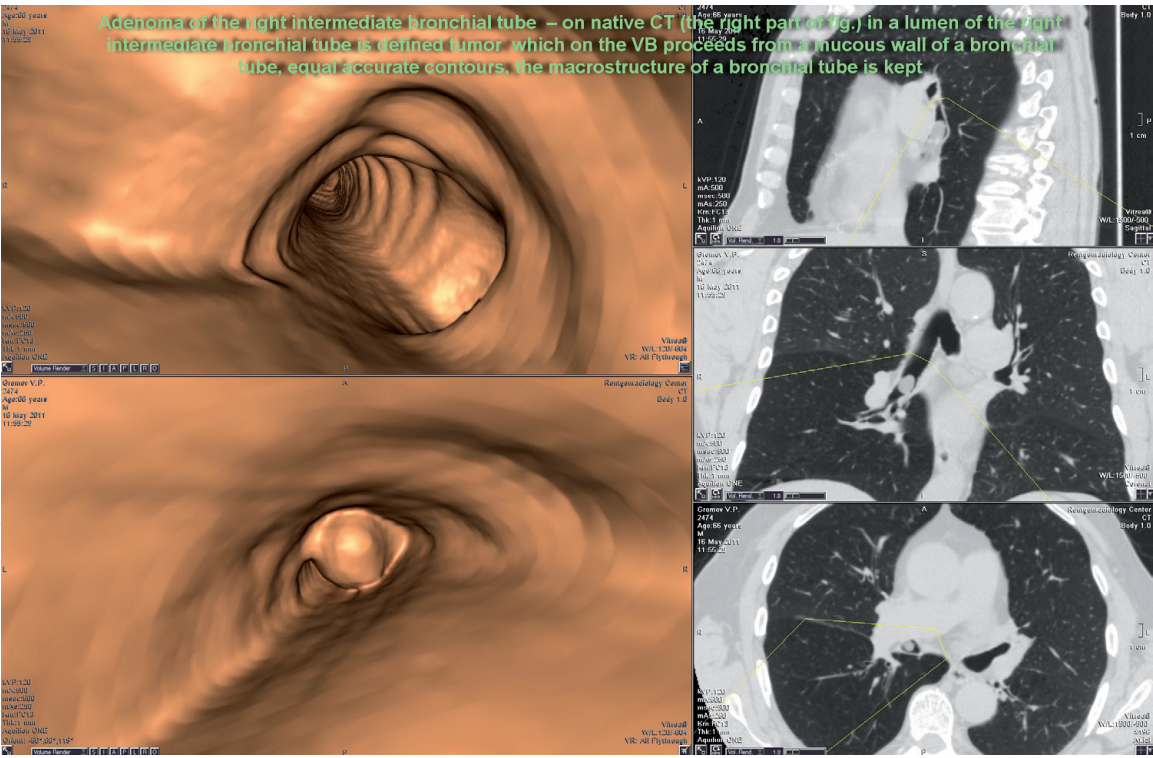


Figure 8.
Adenoma of the right intermediate bronchial tube – on native CT (the right part of fig.) in a lumen of the right intermediate bronchial tube is defined tumor which on the VB proceeds from a mucous wall of a bronchial tube, equal accurate contours, the macrostructure of a bronchial tube is kept.

Malignant lesions were characterized by the presence in the lumen of lumpy tumor masses and the disappearance of the annular structure due to the destruction of cartilage. Peribronchial, paratracheal growth was determined by the narrowing of the lumen with the disappearance of the ring-shaped cartilaginous structures.

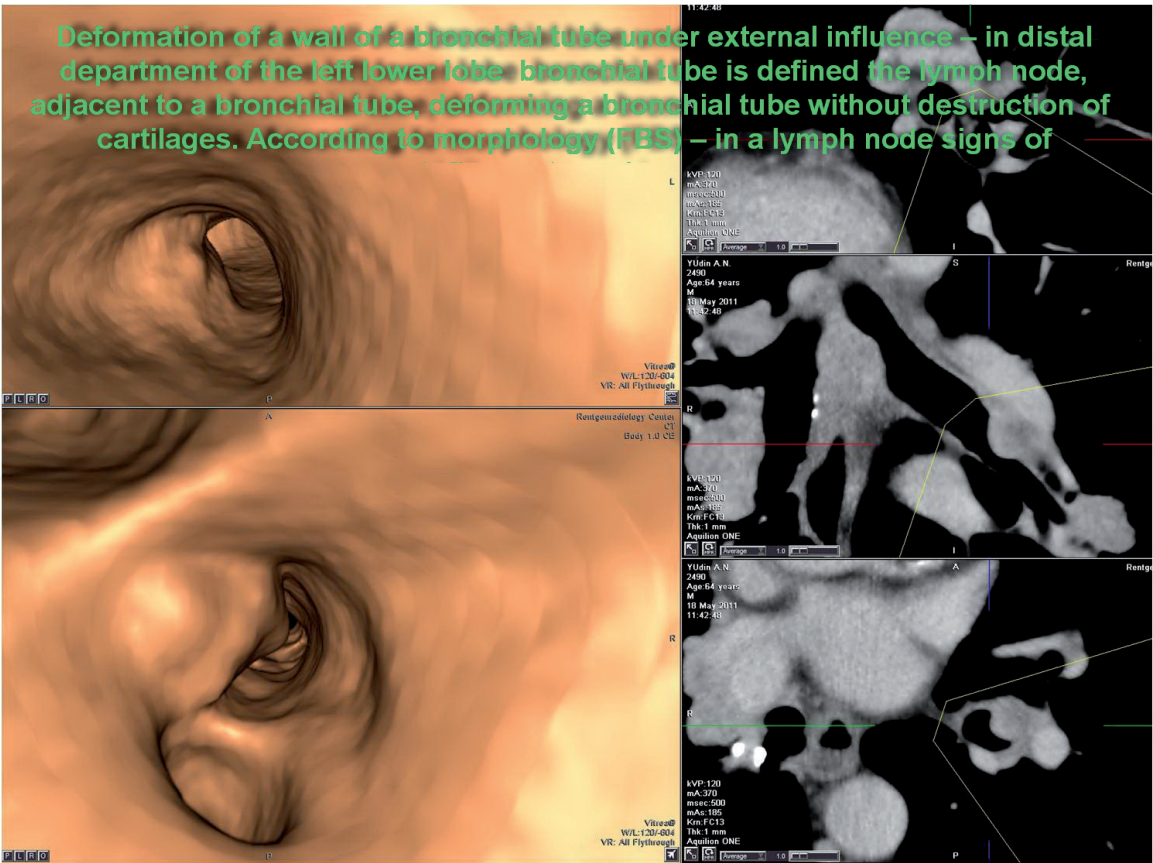


Figure 9.
Deformation of a wall of a bronchial tube under external influence – in distal department of the left lower lobe bronchial tube is defined the lymph node, adjacent to a bronchial tube, deforming a bronchial tube without destruction of cartilages. According to morphology (FBS) – in a lymph node signs of.

1.4 Discussion

The study showed that complex analysis of VB, post-processing images, and native MSCT data allowed obtaining additional information about TBS in lung cancer, secondary lesions, and benign tumors. In contrast to the previous studies, when only the method of VB fly-through was used, it does not allow to agree with the opinion of the authors about the limited possibilities of VB in lung pathology [9, 10]. Most of the studies on VB are based on individual clinical observations and literature data [10, 11, 14, 15]. Our study was conducted on the basis of the analysis of significant clinical material with the development of semiotic signs of TBS lesions and assessment of the diagnostic value of VB methods of their combined analysis with the results of native MSCT. Overall, our opinion about the necessity of wide application in clinical practice CT VB coincides with the result of the work appeared in recent years [11, 13, 15].

1.5 Conclusion

Virtual bronchoscopy of multispiral computed tomography has the possibilities of multiplanar and volumetric reconstructions, post-processing image processing optimal method of diagnosis, determining the probable nature of tumor lesions of the trachea, the prevalence of the process, both outside the body and secondary invasions. In some cases, in stenotic lesions of the trachea, MSCT VB becomes the method of choice in assessing the prevalence of the process. Virtual modeling of intraluminal tracheal tumor, with the data about the surrounding tissues, provides valuable information for the planning of radical treatment.

2. Virtual bronchoscopy multislice computer tomography at traumatic damage of a primary bronchus

2.1 Introduction

Injuries of main bronchi (MB) result from traumatic injury of lungs, as a rule, are combined with injuries of bones of a thorax area. The full separation MB rather rare complication at a thorax injury can be met in 1–3% of cases. In 80% of patients, the rupture comes at the level of bifurcation of a trachea or within 4–2.5 cm from bifurcation of a trachea. Ruptures of MB tubes are met more often on the right. Depending on the severity of the injury, various degrees of damage to the main bronchus are observed—from a small tear to a complete rupture with a divergence of its fragments (partial or complete rupture) are observed [18–20]. The most common clinical manifestations of rupture are chest pain and cough, often accompanied by hemoptysis, shortness of breath, cyanosis due to intense pneumothorax with lung collapse and mediastinal displacement, possible presence of emphysema of the soft tissues of the chest wall and in the neck, and retraction of intercostal spaces. In complicated cases, the presence of intense mediastinal emphysema with extrapericardial cardiac tamponade is noted [21]. Existence or absence of pneumothorax and emphysema generally depends on character and localization of a wound MB. In cases of intrapleural ruptures of the primary and lobar bronchi, there is a tension pneumothorax. At a rupture of a primary bronchus, the lung is switched off from function of breath [22].

Diagnosis of traumatic damages of MB in patients with a thorax injury is a task of tactics of patient treatment; prevention of heavy complications depends on early identification of a rupture of bronchial tubes and a trachea [23]. A MSCT with intravenous administration of a contrast agent the leading noninvasive diagnostic method of consequences of blunt injury of thorax, including their traumatic damage (separation) of a bronchial tube [24–26]. In available literature, studies about the role of the VB of MSCT at traumatic injuries of MB are not found.

2.2 Materials and methods of the research

Data of the VB of MSCT of 10 patients with traumatic injuries of MB as a result of the combined injuries of a thorax—falling from height—3 patients, car accidents—4 patients, and motorcycle—2 patients were analyzed. All patients were brought to the clinic of institute for carrying out reconstructive operations on a primary bronchus from ambulance where they were brought directly after a trauma and received primary medical care and anti-shock therapy.

In seven patients, the rupture was right, and in three, left MB took place (RMB; LMB). The closed pneumothorax took place in eight and opened in two patients. At physical checkup, the expressed dyspnea amplifying at loading, percussion - obtusion of a pulmonary sound, lack of breath. When conducting pneumoscintigraphy with TC-99 m-Makrotekh, a decrease in the size of the lung reduced diffuse inhomogeneous accumulation of the radiotracer at the affected side. The total function of the affected lung was 17–21% and left 82–87%; the difference was 65–66% and violation of 3–4 violation stage capillary blood flow. Capillary blood flow in the intact lung was not disturbed. Traumatic rupture of the MB in all patients is accompanied by fractures of the ribs with displacement on the side of the lesion and hemopneumothorax. All patients underwent reconstructive surgery-isolated resection of the damaged main bronchus with the imposition of tracheobronchial anastomosis. CT with bolus gain of 80–100 ml of the radiopaque medium was carried out on AquilionONE CT scanner (320-slice). Data of native MSCT were

supplemented with 3D-volume, multiplanar reconstruction, MinIP mode, and the VB of fly-through at the earlier described technique [4–6, 26]. Controls were carried out in 14–15 days after the transfer from resuscitation to chamber and 40 and more days after operation. Data of the VB of fly-through were compared with results of a bronchofibroscopy (BFS).

2.3 Results of the research

Native MSCT revealed a collapsed lung and a stump MB was defined. Shift of a mediastinum towards the injured lung and existence in a pleural cavity of nonuniform liquid content (with a density up to 45 HU) were noted. The break of MB was defined at distance of 4–30 mm from bifurcation of a trachea—at this length below a carina, the stump of MB tied from tracheas, distal lumen MB, and lobar and segmental bronchi were not visualized. There was hemo, pneumothorax, fractures of ribs, a humeral bone, in 3 - hypodermic emphysema. MSCT with contrast enhancement—the vascular peduncle of the affected lung was safe (**Figure 10**). VB fly-through in all patients revealed various localization break of a primary bronchus through which the pleural cavity with the collapsed lung and existence of level of liquid in a hemithorax were seen. In the area of a rupture, all patients had an uneven bronchial tube stump perimeter because of the “fragmentary” nature of damage (**Figure 11a, b**).

At survey of a trachea, a carina, a contralateral MB, and its branching of data for pathological changes were not revealed. According to FBS data localization, the extent and the nature of the line of a rupture of MB coincided with results of the VB (**Figure 11c**). 3D volume, multiplanar reconstruction, and the image of TBS in MinIP mode significantly supplemented the localizations given by MSCT and VB fly-through in identification, prevalence of traumatic damages, and planning of operation.

Thus, a complex of techniques of the MSCT and VB allowed giving full information about a condition of a trachea, macrostructural changes of the injured MB, and secondary complications of a lung, to receive virtual model of a zone of interest for planning of an operation. Data of MSCT with contrast enhancement and

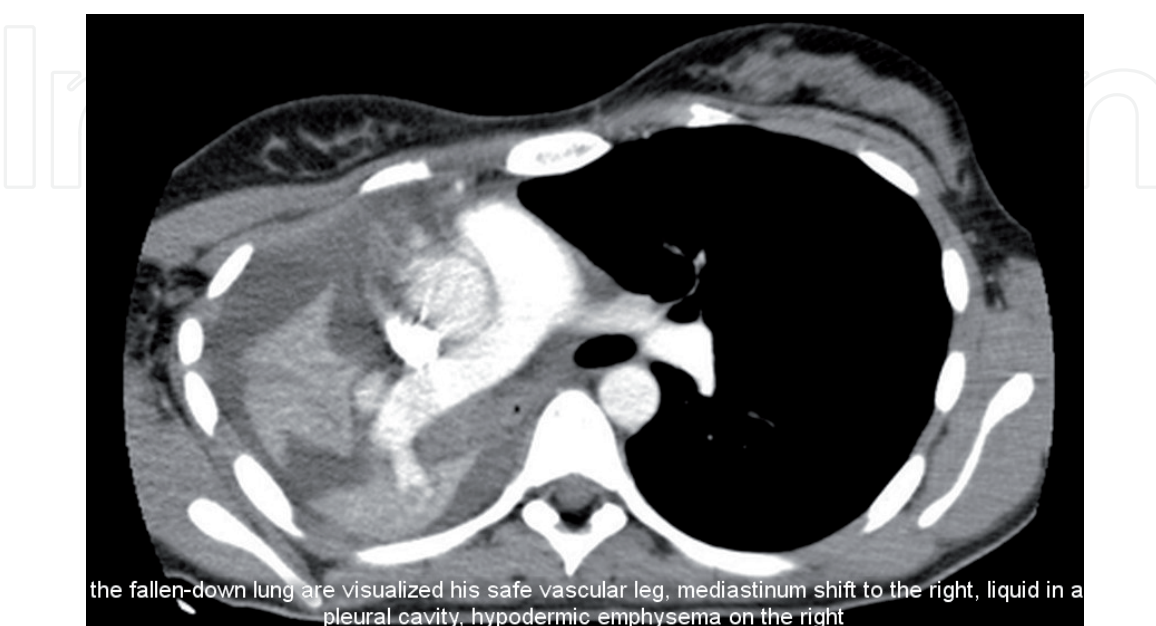

Figure 10.

The fallen-down lung are visualized his safe vascular leg, mediastinum shift to the right, liquid in a pleural cavity, hypodermic emphysema on the right.

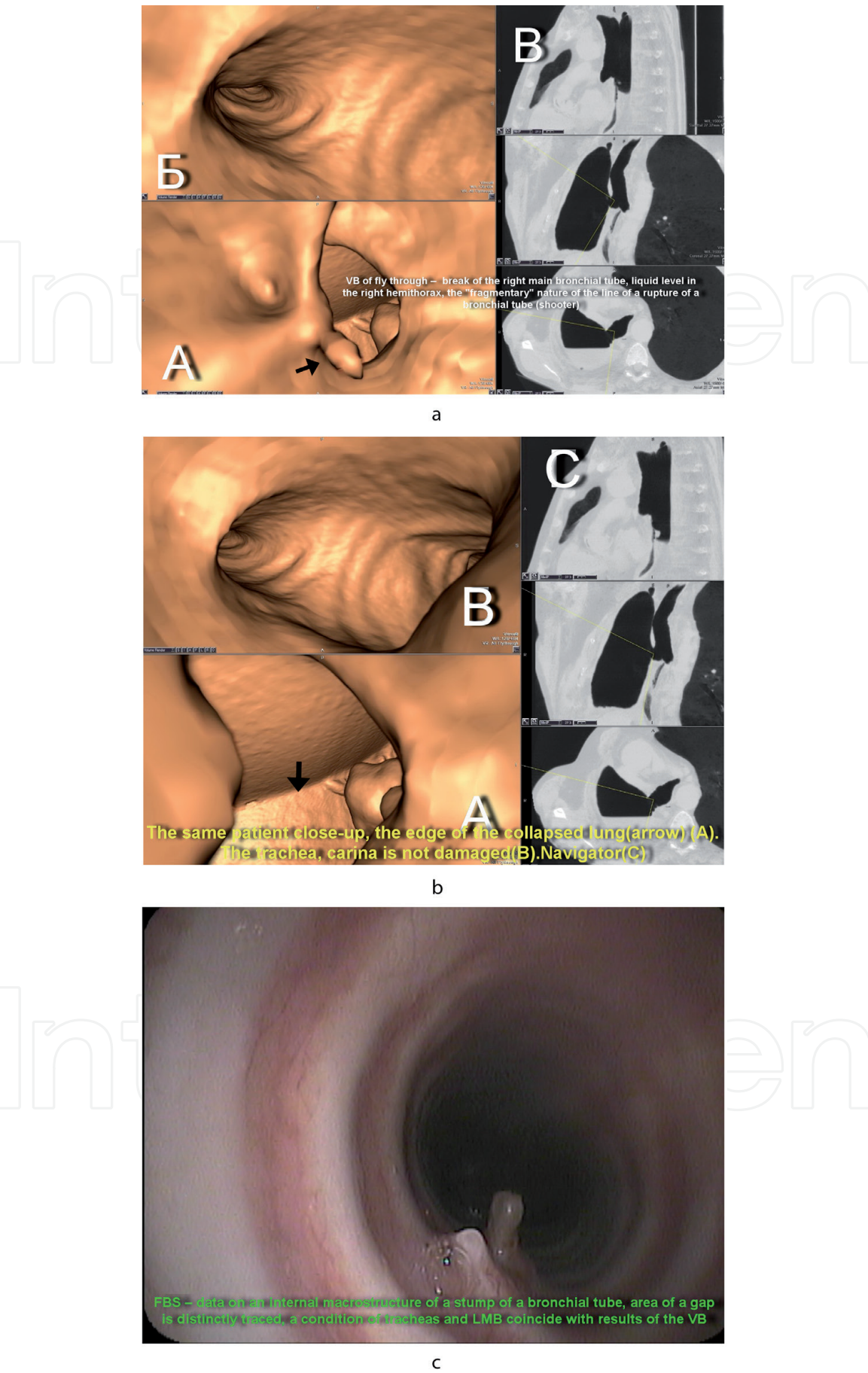


Figure 11.
a. VB of fly-through – break of the right main bronchial tube, liquid level in the right hemithorax, the “fragmentary” nature of the line of a rupture of a bronchial tube (shooter). *b.* The same patient close-up, the edge of the collapsed lung (arrow) (A). The trachea, carina is not damaged (B). Navigator (C). *c.* FBS – data on an internal macrostructure of a stump of a bronchial tube, area of a gap is distinctly traced, a condition of tracheas and LMB coincide with results of the VB.

multiplanar reconstruction specified a condition of a vascular lung peduncle on the party of defeat, a complication from a bone skeleton of a thorax, availability of liquid in a pleural cavity, and pneumothorax options.

In 14–20 days after surgical treatment patient control MSCT at an operated lung was carried out; a small amount of air was found in a pleural cavity. At MSCT, it was defined that the lumen of the reconstructed MB was shortened, narrowed, and deformed in the area of an anastomosis. Air filling the lung, MB, and segmental bronchi was restored, the lung completely filling hemithorax. The lumen of the reconstructed bronchial tube was narrowed in the area of reconstruction (**Figure 12**).

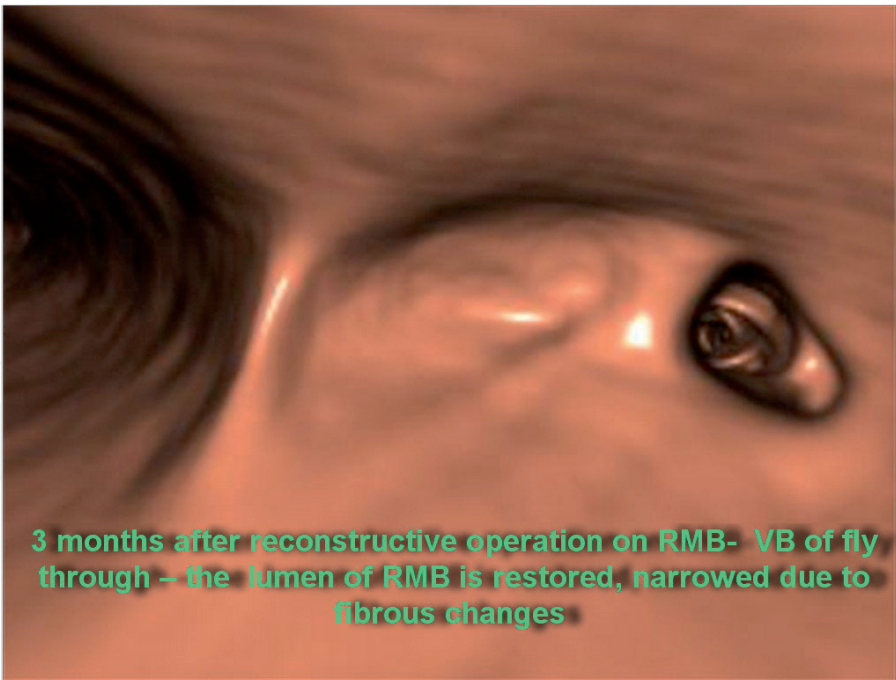
MSCT control in four and more months after operation in all patients revealed that the lung was completely normalized, and air and liquid in a pleural cavity were absent. The VB stated restoration of a lumen of a main bronchus with existence of deformation of a lumen in the area of an anastomosis. Similar data on a macrostructure of a zone of an anastomosis were obtained at FBS (**Figure 13a, b**).

2.4 Discussion

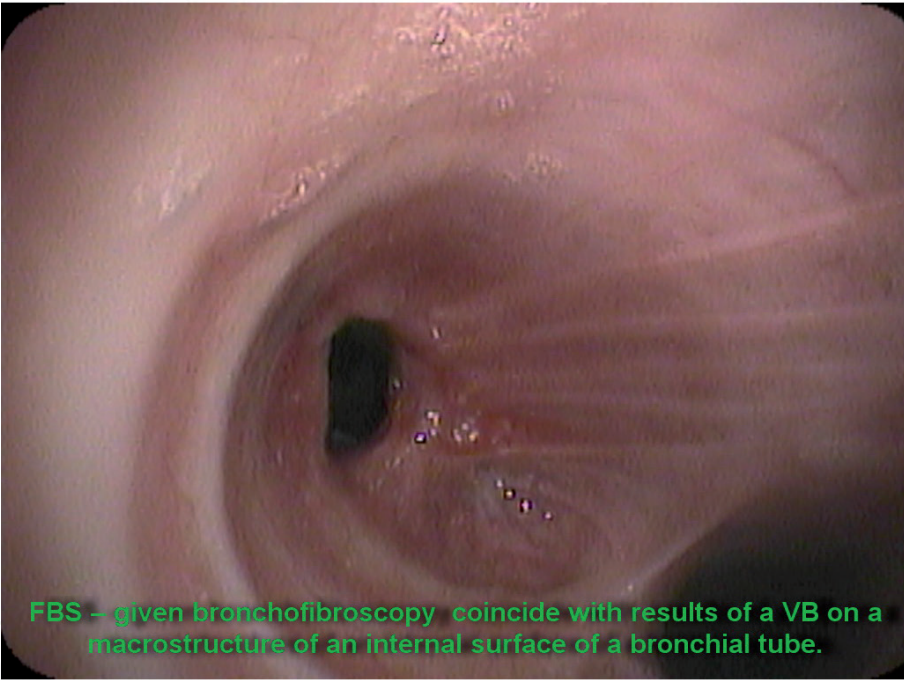
As shown, the conducted research of the VB of MSCT gives the chance of a visual estimation of a macrostructure of area of a posttraumatic rupture of MB and assessment of a condition of a trachea and bronchial tubes of a contralateral lung. The comparison of data of FBS and VB showed their full identity in visualization of anatomy of an internal surface of TBS that allows in believing that the VB of MSCT can be a method of choice in monitoring of dynamics of post-operational changes of the reconstructed MB. Combined analysis of the reconstruction of native CT and 3D images in MinIP mode allows studying also an external wall of a bronchial tube that is inaccessible to FBS. VB allows creating a virtual model of area of reconstructive intervention that plays an important role in its planning. As we noted in the introduction, studies on VB traumatic damage to the main bronchi of the lung us were not found in available literature (except the clinical observation published by us) [27, 28].

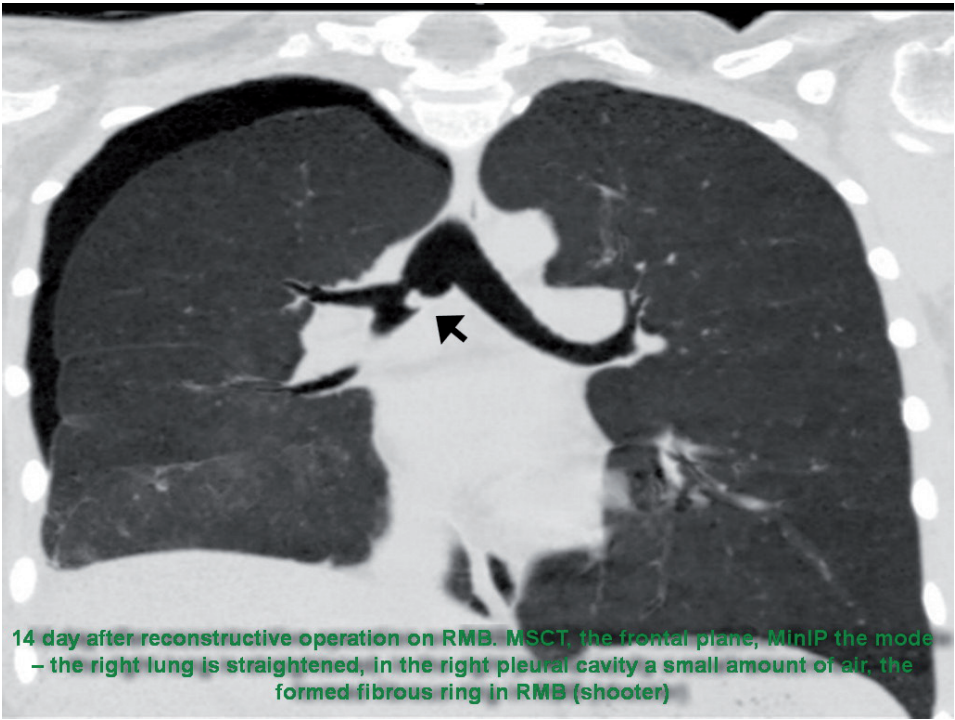

Figure 12.
14 day after reconstructive operation on RMB. MSCT, the frontal plane, MinIP the mode – the right lung is straightened, in the right pleural cavity a small amount of air, the formed fibrous ring in RMB (shooter).



a



b

Figure 13.
a. 3 months after reconstructive operation on RMB – VB of fly-through – the lumen of RMB is restored, narrowed due to fibrous changes. b. FBS – given bronchofibroscopy coincide with results of a VB on a macrostructure of an internal surface of a bronchial tube.

2.5 Conclusion

At traumatic damages of TBS techniques of the VB MSCT allow to define damages of primary bronchi with high precision, to carry out monitoring of efficiency of reconstructive operations. The combined analysis of multiplanar reconstruction, post-processing, 3D images, and the VB of fly-through allows estimating both internal and external walls of a bronchial tube, to receive the virtual image of reconstructive intervention zone.

Acknowledgements

I would like to express my deep gratitude to Chernichenko Natalia Vasilievna MD, Scientific Research Department of Surgery and Surgical Technologies in Oncology, Russian Scientific Center of Roengenordiology (RSCRR), Moscow, **an** endoscopist and a specialist in the field of diseases of the chest and abdominal cavity for cooperation.

Conflict of interest

The author declares no conflict of interest and sponsorship when performing this work. The work was performed within the scientific subject of RSCRR Russian Ministry of Health.

Author details

Kotlyarov Peter Mikhaylovich
Research Department of New Technologies and Semiotics Beam Diagnostics of Diseases of Organs and Systems of Russian Scientific Center of Roengenordiology (RSCRR), Moscow, Russian Federation

*Address all correspondence to: marnad@list.ru

IntechOpen

© 2019 The Author(s). Licensee IntechOpen. This chapter is distributed under the terms of the Creative Commons Attribution License (<http://creativecommons.org/licenses/by/3.0>), which permits unrestricted use, distribution, and reproduction in any medium, provided the original work is properly cited. 

References

- [1] Malignant neoplasms Russia in 2014. edited by Kaprin AD, Starostin VV, Petrova GVM. 2016. p. 250. (Злокачественные новообразования России в 2014 г. под ред. Каприна АД. Старостина ВВ, Петровой ГВМ. 2016. С.250)
- [2] Jugpal TS, Garg A, Sethi GR, et al. Multi-detector computed tomography imaging of large airway pathology: A pictorial review. *World Journal of Radiology*. 2015;7(12):459-474. In Russian
- [3] Debnath J, George RA, Satija L, et al. Virtual bronchoscopy in the era of multi-detector computed tomography: Is there any reality? *Medical Journal Armed Forces India*. 2013;69(3):305-310
- [4] Kotlyarov P, Temirhanov Z, Flerov E. et al. Virtual bronchoscopy in the diagnosis of lung cancer and its prevalence, monitoring of postoperative changes. *Bulletin RSCRR Ministry of Health of Russia*. 2013. (URL: http://vestnik.rncrr.ru/vestnik/v13/papers/flerov_v13.htm). In Russian. (Котляров ПМ, Темирханов ЗС, Флеров ЕИдр. Виртуальная бронхоскопия в диагностике рака легкого и его распространенности, мониторинге послеоперационных изменений. Вестник РНЦПР. 2013. (URL: http://vestnik.rncrr.ru/vestnik/v13/papers/flerov_v13.htm))
- [5] Kotlyarov PM, Temirkhanov ZS, Serbahina EV. Multiplanar reconstruction and virtual bronchoscopy in the evaluation of the state of tracheo – bronchial system according to Multidetector computed tomography. *Radiation Diagnostics and Therapy*. 2011. No.2. (2) pp. 50-55. In Russian. (Котляров ПМ, Темирханов ЗС, Щербихина ЕВ. Мультипланарные реконструкции и виртуальная бронхоскопия в оценке состояния трахео – бронхиальной системы по данным мультисрезовой компьютерной томографии. Лучевая диагностика и терапия. 2011. №2. (2) С. 50-55)
- [6] Kotlyarov PM, Nudnov NV, Egorova EV. Multidetector computed tomography virtual bronchoscopy in bronchiectasis and osteochondroplasty of bronchopathy. *Pulmonology*. 2014, No. 4. pp. 68-72. In Russian. (Котляров ПМ, Нуднов НВ, Егорова ЕВ. Мультиспиральная компьютерно-томографическая виртуальная бронхоскопия при бронхоэктатической болезни и остеохондропластической бронхопатии. Пульмонология, 2014, № 4, С. 68-72)
- [7] Sdvizcov AM, Yudin AL, Kozhanov LG et al. Multislice computed tomography with three-dimensional modeling in diagnosing and treating cancer patients. *Bulletin of Moscow Cancer Society*. 2009. No. 3. pp. 1-4. In Russian. (Сдвижков АМ, Юдин АЛ, Кожанов ЛГ и др. Мультиспиральная компьютерная томография с трехмерным моделированием в диагностике и лечении онкологических больных. Вестник Московского онкологического общества. 2009. № 3. С. 1-4)
- [8] Adamczyk M, Tomaszewski G, Naumczyk P, et al. Usefulness of computed tomography virtual bronchoscopy in the evaluation of bronchi divisions. *Polish Journal of Radiology*. 2013;78(1):30-41
- [9] Aliannejad R. Comment on “Comparison of virtual bronchoscopy to fiber-optic bronchoscopy for assessment of inhalation injury severity”. *Burns*. 2015;41(7):1613-1615
- [10] Bauer TL, Steiner KV. Virtual bronchoscopy: clinical applications and limitations. *Surgical Oncology Clinics of North America*. 2007;16(2):323-328

- [11] Das KM, Lababidi H, Al Dandan S, et al. Computed tomography virtual bronchoscopy: Normal variants, pitfalls, and spectrum of common and rare pathology. *Canadian Association of Radiologists Journal*. 2015;**66**(1):58-70
- [12] Gutiérrez R, Rodríguez SD, Ros Lucas JA. Torsion of middle lobe after lobectomy. correlation between optical bronchoscopy-computed tomography virtual bronchoscopy. *Archivos de Bronconeumología*. 2015;**51**(7):355-359
- [13] Hussein SR. Role of virtual bronchoscopy in the evaluation of bronchial lesions: A pictorial essay. *Current Problems in Diagnostic Radiology*. 2013;**42**(2):33-39
- [14] Luo M, Duan C, Qiu J, et al. Diagnostic value of multidetector CT and its multiplanar reformation, volume rendering and virtual bronchoscopy postprocessing techniques for primary trachea and main bronchus tumors. *PLoS One*. 2015;**10**(9):e0137329
- [15] Osiri X, Sano A, Tsuchiya TJ. Virtual bronchoscopy using OsiriX. *Journal of Bronchology and Interventional Pulmonology*. 2014;**21**(2):113-116
- [16] Terzibaşioğlu E, Dursun M, Güven K et al. The diagnostic efficiency of multislice CT virtual bronchoscopy in detecting endobronchial tumors. *Tuberk Toraks*
- [17] Kharchenko VP, Gvarishvili AA, Eltishev N et al. Examination and treatment of patients with multiple primary malignant tumors of the respiratory system. *Bulletin RSCRR Ministry of Health of Russia*. 2004. (URL: http://vestnik.rncrr.ru/vestnik/v3/papers/harch14_v3.htm. In Russian). (Харченко ВП, Гваришвили АА, Елтышев НА и др. Обследование и лечение больных с первично-множественными злокачественными опухолями органов дыхания. *Вестник РНЦПР Минздрава России*. 2004. (URL: http://vestnik.rncrr.ru/vestnik/v3/papers/harch14_v3.htm))
- [18] Velly JF, Martigne C, Moreau JM, et al. Post traumatic tracheobronchial lesions. A follow-up study of 47 cases. *European Journal of Cardio-Thoracic Surgery*. 1991;**5**(7):352-355
- [19] Scognamiglio G, Solli P, Benni M, et al. Less is more: lung-sparing direct repair of a traumatic rupture of the bronchus intermedius. *Journal of Visualized Surgery*. 2017;**3**:109. DOI: 10.21037/jovs.2017.06.07. e Collection 2017
- [20] Karmy-Jones R, Wood DE. Traumatic injury to the trachea and bronchus. *Thoracic Surgery Clinics*. 2007;**17**:35-46. DOI: 10.1016/j.thorsurg.2007.03.005
- [21] Krawczyk L, Byrczek TP, Łuczyk AM, et al. Traumatic tension pneumopericardium and amputation of the left main bronchus. *Polish Journal of Cardio-Thoracic Surgery*. 2017;**1**(1): 63-65. DOI: 10.5114/kitp.2017.66935
- [22] Nishiumi N, Inokuchi S, Oiwa K, et al. Diagnosis and treatment of deep pulmonary laceration with intrathoracic hemorrhage from blunt trauma. *The Annals of Thoracic Surgery*. 2010;**9**:232-238. DOI: 10.1016/j.athoracsur.2009.09.041
- [23] Kummer C, Netto FS, Rizoli S, et al. A review of traumatic airway injuries: potential implications for airway assessment and management. *Injury*. 2007;**38**:27-33. DOI: 10.1016/j.injury
- [24] Kotlyarov PM. Multislice computed tomography: A new stage of development of radiodiagnostics of diseases of the lungs. *Medical Imaging*. 2011. No. 4. pp. 14-20. In Russian. (Котляров ПМ, Мультисрезовая КТ. новый этап развития лучевой диагностики заболеваний легких. *Медицинская визуализация*. 2011. №4. С. 14-20)

[25] Cui Y, Ma D-q, Liu W-h. Value of multiplanar reconstruction in MSCT in demonstrating the relationship between solitary pulmonary nodule and bronchus. *Clinical Imaging*. 2009;**33**:15-21

[26] Kotlyarov PM. Virtual bronchoscopy in the diagnosis of lung cancer. *Radiation Diagnosis and Therapy*. 2015. № 1. pp. 56-63. In Russian. (Котляров ПМ. Виртуальная бронхоскопия в диагностике рака легкого. Лучевая диагностика и терапия. 2015. № 1. С. 56-63)

[27] Kharchenko VP, Kotlyarov PM, Vinikovetskaya AV et al. Trauma of the right main bronchus (clinical observation). *Medical Imaging*. 2011. N 4. pp. 76-81. In Russian. (Харченко ВП, Котляров ПМ, Виниковецкая АВ и др. Травматический отрыв правого главного бронха (клиническое наблюдение). Медицинская визуализация. 2011. N 4. С. 76-81)

[28] Kotlyarov PM, Chernichenko NV. Virtual bronchoscopy multislice tomography in traumatic injuries of the main bronchi. *Journal of Medical Imaging and Case Reports*. 2018. Proceedings of the First International Conference on Medical Imaging and Case Reports (MICR-2018);**2**(2):S25-S26. DOI: 10.17756/micr.2018-suppl 1