

# We are IntechOpen, the world's leading publisher of Open Access books Built by scientists, for scientists

6,900

Open access books available

185,000

International authors and editors

200M

Downloads

Our authors are among the

154

Countries delivered to

TOP 1%

most cited scientists

12.2%

Contributors from top 500 universities



WEB OF SCIENCE™

Selection of our books indexed in the Book Citation Index  
in Web of Science™ Core Collection (BKCI)

Interested in publishing with us?  
Contact [book.department@intechopen.com](mailto:book.department@intechopen.com)

Numbers displayed above are based on latest data collected.  
For more information visit [www.intechopen.com](http://www.intechopen.com)



# Oesophageal Atresia: Drowning a Child in His/Her Own Saliva

*Samuel Osei-Nketiah and William Appeadu-Mensah*

## Abstract

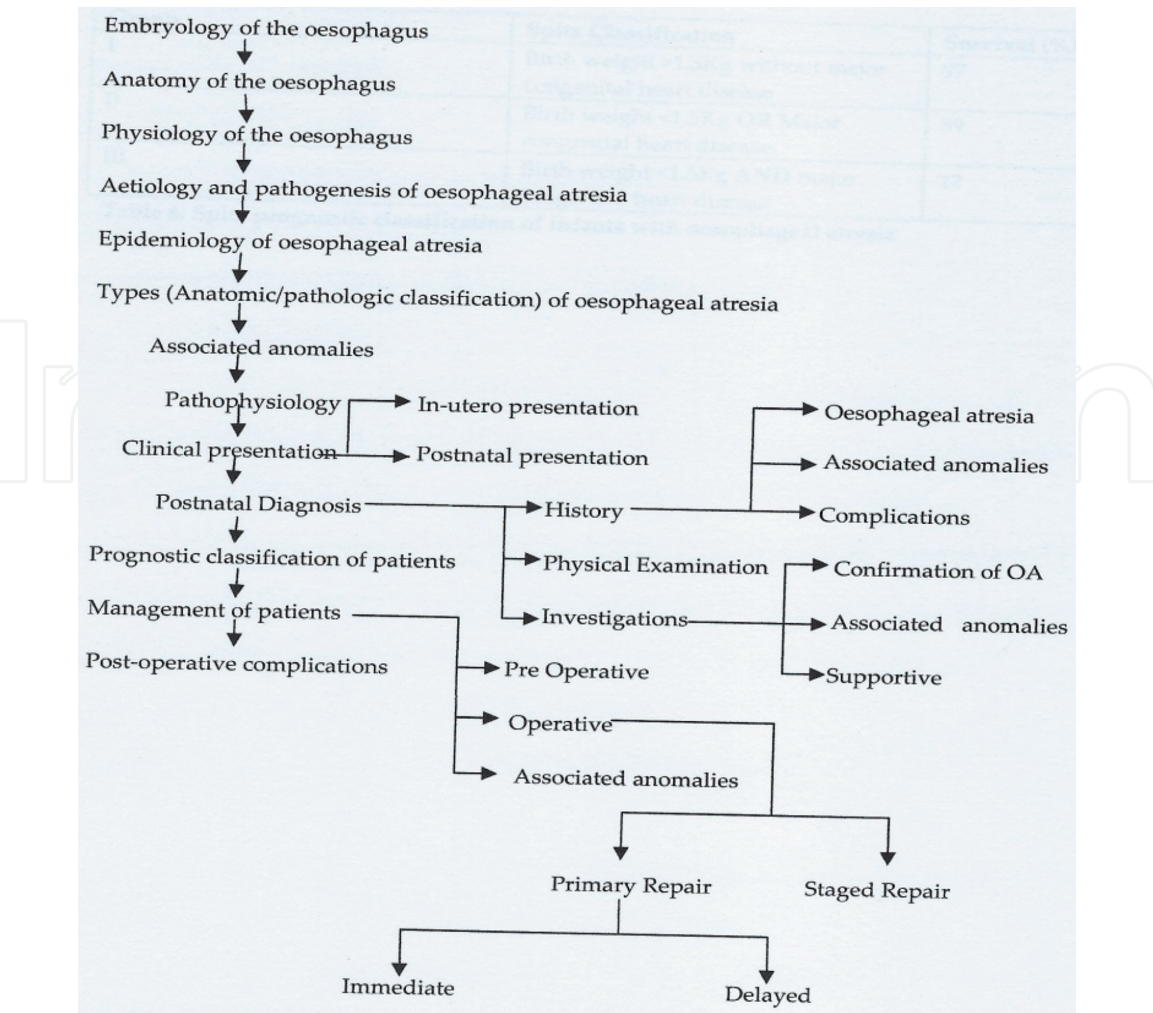
Oesophageal atresia (OA) is a congenital anomaly characterised by absence or loss of a segment of the oesophagus. This commonly affects the thoracic portion of the oesophagus, leaving upper and lower oesophageal segments. Loss of the oesophageal luminal continuity leads to impaired in utero swallowing of amniotic fluid as well as postnatal swallowing of saliva and food. Besides the loss of oesophageal continuity, most of the patients tend to have a connection between the trachea and the lower oesophageal segment and a few between the trachea and the upper oesophageal segment, a condition called tracheo-oesophageal fistula (TOF). In view of these, the main principles guiding the definitive surgical management of OA are (1) to disconnect any TOF and (2) to establish a conduit for swallowing, preferably using the native oesophageal segments. This chapter seeks to discuss OA by focusing on the embryology, anatomy and physiology of the oesophagus, stressing on the embryological basis of OA. Other areas to cover include aetiology, pathogenesis, epidemiology, pathologic classification, associated anomalies, pathophysiology, clinical presentation and diagnosis. Further discussion will focus on prognostic classification of patients, management and post-operative complications.

**Keywords:** oesophageal atresia, pathology, associated anomalies, pathophysiology, clinical presentation, diagnosis, pre-operative management, surgical management, outcome, prognosis

## 1. Introduction

Oesophageal atresia (OA), a congenital anomaly characterised by absence or loss of a segment of the oesophagus, commonly affects the thoracic portion of the oesophagus, leaving upper and lower oesophageal segments. Loss of the oesophageal luminal continuity leads to impaired in utero swallowing of amniotic fluid as well as postnatal swallowing of saliva and food. Besides the loss of oesophageal continuity, most of the patients tend to have a connection between the trachea and the lower oesophageal segment and a few between the trachea and the upper oesophageal segment, a condition called tracheo-oesophageal fistula (TOF). In view of these, the main principles guiding the definitive surgical management of oesophageal atresia are (1) to disconnect any tracheo-oesophageal fistula and (2) to establish a conduit for swallowing, preferably using the native oesophageal segments.

During the early years, the surgical management of oesophageal atresia was associated with lots of challenges and high mortality [1–4]. Over the past two to three decades, however, the surgical outcome has improved significantly in most centres in the developed countries. This improvement is attributed to advances



**Figure 1.**  
Flow chart showing various topics to be discussed under oesophageal atresia.

in neonatal anaesthesia, well-established neonatal intensive care units (NICU), availability of total parental nutrition (TPN) and refined surgical skills [1, 5–8]. Conversely, the surgical outcome of oesophageal atresia in developing countries still remains very poor due to lack of the aforementioned facilities, in addition to late presentation [9–11].

This chapter seeks to discuss OA by focusing on the topics shown in **Figure 1**.

## 2. Embryology of the oesophagus

The oesophagus develops from the primitive foregut as a continuation of the pharynx. It is said to be present by the fifth week of gestation, and it attains its final foetal length (8–10 cm) during the 7th week of gestation [12]. Thus, the length of the oesophagus at birth is 8–10 cm, and this doubles during the first few years of life [12].

The normal embryology of the foregut, as found in most reports and textbooks of embryology, is divided into five developmental steps [13]:

1. During the first step, the endoderm (epithelium) of the primitive foregut differentiates into a ventral area called the *lung field* and a dorsal area called *oesophageal area*. The epithelium of the ventral area (lung field) of the primitive foregut consists of 3–4 cell layers, while that of the dorsal area (oesophageal area) has only one cell layer. This phase occurs when the embryo is about 22–23 days old.

2. Lung (tracheal) bud develops at the caudal end of the lung field.
3. During the third step, beginning caudally at the area of the lung bud, the lateral walls of the foregut start to approximate, developing longitudinal ridges inside the lumen of the foregut. This clearly separates the ventral lung field and the dorsal oesophageal area.
4. Epithelial tracheo-oesophageal septum develops during the fourth step; and it is assumed that this process also starts caudally and ends cranially close to the laryngeal primordium. This process is described by most investigators in four steps: (i) the epithelium of the longitudinal ridges starts to proliferate; (ii) the ridges, therefore, fuse in the midline of the primitive foregut and form an epithelial septum; (iii) cell death takes place in the central areas of the septum, noticeable by the appearance of nuclei pyknosis and (iv) as a result, mesenchymal tissue then expands into the area between the trachea and the oesophagus.
5. Separation of the respiratory tract from the oesophagus becomes definitive between the sixth and the seventh weeks of gestation through the formation of a mesenchymal septum called tracheo-oesophageal septum.

It should be noted that most steps in this schematic description of the foregut embryology lack clear evidence [13].

Other developmental features of the oesophagus include [12]:

Mesenchymal circular coat (muscle) develops early in the sixth week of gestation. The longitudinal muscle forms between the ninth and twelfth weeks of gestation, and the muscularis mucosa develops at approximately the fourth month of gestation [12].

Blood vessels enter the oesophageal wall during the seventh month of gestation and lymph capillaries between the third and fourth months of life [12]. The most important embryologic structure for blood supply to the oesophagus is the fourth branchial arch. The arch produces the subclavian artery and its branches, including the inferior thyroid artery which supplies the cervical oesophagus. The fourth branchial arch also produces the aorta, from which vessels spring to supply the thoracic oesophagus.

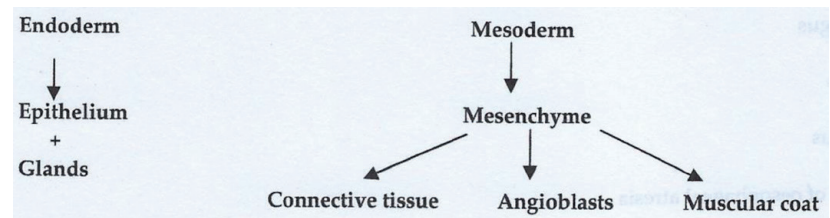
The formation of the oesophageal epithelium is peculiar; it “changes face” four times. The epithelium is stratified columnar at the start of embryonic life, becoming cuboidal later. In foetal life, it is ciliated columnar, and, finally, it becomes stratified squamous soon after birth. Innervation of the oesophageal wall is received from sympathetic nerve fibres from the thoracic trunk and celiac plexus and parasympathetic innervation from the vagus nerve.

The oesophageal wall is formed from endoderm and mesoderm (**Figure 2**). The endoderm produces the oesophageal epithelium and glands, whereas the mesoderm produces the connective tissue, muscular coat, and angioblasts. Splanchnic mesenchyme surrounds the oesophagus and trachea. The splanchnic mesenchyme forms the smooth muscle of the lower oesophagus.

The causal branchial arches (4 and 6) are responsible for the formation of the striated musculature of the upper oesophagus and pharynx. They are innervated by the vagus nerve (nerve to the fourth arch) and the recurrent laryngeal nerve branch of the vagus nerve (nerve to the sixth arch) [12].

The oesophageal lumen is almost filled with vacuolated cells from proliferation of oesophageal epithelium during the seven–eighth weeks of gestation. The filling is never complete, and hence the so-called solid stage does not exist. At 10 weeks' gestation, the lumen of the oesophagus is restored as the vacuolated cells disappear.





**Figure 2.**  
*Embryologic duo responsible for genesis of the oesophagus.*

## 2.1 Anatomy of the oesophagus

The oesophagus is a muscular tube connecting the pharynx to the stomach. At birth, the length of the oesophagus is about 8–10 cm, and this doubles in the first few years of life. The length of the oesophagus in the adult is about 25 cm. It extends from the lower border of the cricoid cartilage (at the level of the C6 vertebra) to the cardiac orifice of the stomach at the level of T11 vertebra. The upper limit in the newborn is found at the level of the fourth or fifth cervical vertebra and ends higher at the level of the T9 vertebra [14, 15].

The oesophageal wall is composed of mucosa, submucosa, muscularis propria and adventitia, lacking a distinct serosa. The mucosa is the strongest layer of the oesophageal wall. Hence, meticulous approximation of the oesophageal mucosa is essential for a technically sound anastomosis.

The oesophagus is divided into three segments—*cervical, thoracic and abdominal segments*. The cervical portion is somewhat curved, with its convex side to the left, thereby projecting to the left of the trachea. Incisions for approaching the cervical oesophagus are commonly made on this side. Anteriorly, the cervical oesophagus is covered by the trachea.

The arterial blood supply to the oesophagus is generally considered with regard to the cervical, thoracic and abdominal segments of the oesophagus. The arterial blood supply to the pharyngo-oesophageal junction and the cervical oesophagus is derived from branches of the inferior thyroid artery. In addition, the pharyngo-oesophageal junctional area of the oesophagus is supplied by small arterial branches of the subclavian (artery of Luschka), common carotid, vertebral, superior thyroid and costo-cervical trunk vessels [12, 16]. The thoracic oesophagus is supplied from oesophageal branches of the aorta, the bronchial arteries and the right intercostal arteries. Accessory oesophageal branches are also present directly from the internal mammary, common carotid and superior intercostal arteries [12, 17]. The left gastric artery provides oesophageal blood supply to the abdominal segment of the oesophagus in most individuals. Rarely, oesophageal arteries will arise from an accessory left hepatic artery. In less than one-half of individuals, the oesophagus receives arterial blood via the left inferior phrenic artery and rarely from the right inferior phrenic artery [16]. A well-developed subepithelial network of capillaries is present in the oesophageal mucosa and submucosa [18, 19]. The excellent submucosa plexus of the proximal oesophagus allows for extensive mobilization without compromise to the blood supply, whereas caution should be taken distally because of the segmental lower oesophageal blood supply.

Venous drainage from the oesophagus includes intrinsic and extrinsic vessels. The intrinsic system includes subepithelial and submucosal veins that join gastric veins and perforating veins that join with the extrinsic system of veins. The extrinsic veins include larger longitudinal vessels that run on the outer surface of the oesophagus and are close to the vagus nerves. These vessels connect the left gastric vein to the azygous or hemiazygous veins either directly or indirectly via the posterior bronchial veins. Extrinsic veins drain into the inferior thyroid, vertebral and deep cervical veins in the cervical region. Oesophageal veins at the level of the

cardia join the phrenic and abdominal oesophageal veins to drain primarily into the left gastric vein, as well as the gastroepiploic and splenic veins [20]. This may be a point of importance when dealing with a patient with portal hypertension.

The oesophageal lymphatics form plexuses in the mucosa (lamina propria), submucosa, muscularis, and adventitia with interconnectivity [12]. Collecting trunks originate in the submucosa and empty into the nearest lymph nodes.

In the oesophageal wall are two plexuses of nerves for intrinsic nerve supply: (i) Meissner's plexus in the submucosa and (ii) Auerbach's plexus in the connective tissue between the circular and longitudinal muscularis externa [12]. These plexuses form networks of multipolar ganglion cells, the processes of which are in contact with one another and receive axons from the vagus. The oesophagus receives extrinsic nerve supply from three sources: the (a) cerebrospinal, (b) sympathetic and (c) parasympathetic (vagal) nervous systems [12].

The cricopharyngeal (CP) muscle, which is located at the pharyngo-oesophageal junction, attaches to the cricoid cartilage and forms a C-shaped muscular band. It is innervated by the pharyngeal plexus of the vagus nerve and the recurrent laryngeal nerve [21]. The main function of the CP muscle is to control luminal flow between the pharynx and oesophagus. The CP sphincter muscle is tonically contracted at rest and relaxes during swallowing. The major component of the upper oesophageal sphincter (UES) is the CP muscle, although the inferior pharyngeal constrictor and striated muscles of the proximal oesophagus also contribute [22].

The function of the lower oesophageal sphincter is abolished by total truncal vagotomy.

## **2.2 Physiology of the oesophagus**

The main function of the oesophagus is for swallowing, and this is achieved through peristalsis. Functionally, the oesophagus is divided into three areas: (i) the upper oesophageal sphincter (UOS), (ii) the oesophageal body and (iii) the lower oesophageal sphincter (LOS). The coordinated activity of these three parts is essential to ensure propulsion of bolus from the pharynx to the stomach. The UOS plays a key role in controlling regurgitation of oesophageal content into the pharynx and the airways, while the LOS prevents reflux of gastric content into the oesophagus.

## **2.3 Aetiology and pathogenesis of oesophageal atresia**

Various theories were developed in the past to explain the embryology of foregut anomalies. These theories are grouped into four [13]: (i) oesophageal occlusion theory, (ii) theories of spontaneous deviation of the tracheo-oesophageal septum, (iii) mechanical theories and (iv) not otherwise specified (NOS) theories.

Tandler postulated the theory of foregut occlusion in 1902 as a physiological occlusion during duodenal development [13]. Such physiological occlusion is also postulated to occur during oesophageal development; and that failure of recanalisation leads to oesophageal atresia [13]. Tracheo-oesophageal septal deviation is found to be another theory that explains the development of OA [13]. Various mechanisms have been used to explain the mechanical theory [13]. These include ventral pressure on the developing oesophagus by a very big anlage of the heart and aberrant vessels. The NOS theories include the development of a very large tracheal field that uses too much tissue to form the trachea, resulting in a shortage of dorsal tissue. Abnormal septation, combined with a disturbance in the organ inducing field, is believed to account for OA with TOF. Isolated TOF is speculated to result from a loss of epithelial proliferation or through an excessive necrosis in the area of the epithelial tracheo-oesophageal septum [13].

Aetiologically, various genetic defects have been found to be associated with oesophageal atresia. Important genes related to the pathogenesis of OA, and mostly involved in developmental pathways, include vitamin A effectors, retinoic acid receptors  $\alpha$  and  $\beta$  (Rara and Rarb), sonic hedgehog pathway effectors (Shh, Gli2, Gli3 and Foxf1) and other homeobox containing transcription factors (Hoxc4, Ttf-1 and Pcsk5) [23]. Various environmental teratogens have also been implicated in the pathogenesis of OA-TOF [23]. Infants born to mothers with prolonged exposure to contraceptive pills (exposure to progesterone and oestrogen) during pregnancy have high risk. Oesophageal atresia has also been reported in some infants of hyperthyroid and uncontrolled diabetic mothers. Intrauterine exposure to thalidomide and diethylstilbestrol are also found to be associated with OA.

2.4 Epidemiology of oesophageal atresia

The incidence of OA, with or without TOF, is reported to be 1:3500 live-born infants. This, however, varies geographically [23] from 1 in 2440 births in Finland to 1 in 4500 births in the United States and Australia. In a European study, 62% of infants with OA-TOF were male, whereas a California database found considerable variations in the male-to-female ratios between types of OA-TOF defects [23]. Mothers of white ethnicity have a higher (>60%) prevalence of OA-TOF than non-white populations do [23]. First pregnancy and increasing maternal age have been found to be associated with an increased risk OA-TOF [23]. The risk is reported to be twofold for women 35–40 years old and threefold for those older than this age [23]. Offspring of in vitro fertilization patients also have a significantly increased risk of developing OA (OR 3.65:CI 2/53–5/26) [23].

2.5 Anatomic (pathologic) classification of oesophageal atresia

Various systems of classifications have been used to classify OA. The two most frequently used ones are shown in Table 1 [24].

2.6 Associated anomalies

About 50–70% of patients with oesophageal atresia have associated congenital anomalies [23]. Cases without tracheo-oesophageal fistula tend to be most commonly associated with other anomalies, while those with the H-type are less commonly associated with other anomalies. Associated anomalies may negatively affect patient management and overall outcome of patients.

Anatomic Description	Gross type	Vogt type	Approximate Incidence (%) <sup>41</sup>
Oesophageal Agenesis	-	I	
Oesophageal Atresia without tracheo-oesophageal fistula	A	II	6
Oesophageal atresia with proximal tracheo-oesophageal fistula	B	IIIa	2
Oesophageal atresia with distal tracheo-oesophageal fistula	C	IIIb	85
Oesophageal atresia with both proximal and distal tracheo-oesophageal fistulae	D	IIIc	1
Tracheo-oesophageal fistula without oesophageal atresia	E	IV	6

Table 1.  
Types of oesophageal atresia—*anatomic (pathologic) classification of oesophageal atresia.*



About 50% of patients with associated anomalies have recognizable syndromes, sequences, and associations [23]. VACTERL (vertebral, anorectal malformation, cardiac, tracheo-oesophageal, renal, limb) association is found in 20% of cases [25]. These syndromes, sequences, and associations usually result from chromosomal anomalies or single gene mutations (**Tables 2 and 3**) [23, 26].

Patients with oesophageal atresia have trisomies 18 and 21 in about 7% of patients. In trisomy 21 (Down syndrome), the possibility of associated duodenal atresia, Hirschsprung's disease and congenital heart disease should be considered. In patients with clinically suspected trisomy 18, surgery should be postponed and chromosomal analysis done immediately since prognosis for trisomy 18 is very poor.

The common associated anomalies in non-syndromic oesophageal atresia include the cardiovascular system (CVS), genitourinary tract (GUT), gastrointestinal tract (GIT), musculoskeletal system (MSS), and central nervous system (CNS) (**Table 4**). Cardiovascular anomalies tend to occur most frequently (**Table 4**) [23, 25, 27]. This is followed by the GUT, GIT, MSS, and CNS (neurologic anomalies). A review of cases seen at our centre in Accra Korle-Bu, however, showed overall incidence of associated anomalies of 32.5%, with GIT system being the most commonly affected, followed by the CVS [9].

The most common CVS anomalies are ventricular septal defect (VSD) and atrial septal defect (ASD). Other CVS defects include tetralogy of Fallot, patent ductus arteriosus (PDA), and coarctation of the aorta. A few patients tend to have the descending thoracic aorta on the right side. Renal agenesis or hypoplasia, undescended testis, cystic renal disease, hydronephrosis, vesicoureteric reflux (VUR) and ureteric duplication are some of the GUT anomalies associated with oesophageal atresia. Other GUT anomalies include pelvi-ureteric junction (PUJ) obstruction, vesicoureteric junction (VUJ) obstruction, urachal anomalies, ambiguous genitalia, bladder exstrophy and cloacal exstrophy. The GIT anomalies found in oesophageal atresia include anorectal malformation (ARM), duodenal atresia, intestinal malrotation, ileal atresia, annular pancreas and pyloric stenosis. Vertebral and radial abnormalities are the usual MSS defects associated with oesophageal atresia. The CNS defects found in oesophageal atresia include neural tube defects, hydrocephalus, holoprosencephaly and anophthalmia or microphthalmia.

2.7 Pathophysiology of oesophageal atresia

The discontinuation of the oesophageal lumen prevents swallowed amniotic fluid by the foetus from reaching the stomach and hence the intestine. In view of this, the physiological control of amniotic fluid volume by the foetus, through swallowing and absorption, is impaired, leading to polyhydramnios. This would in turn lead to premature rupture of membrane, umbilical cord prolapse and premature delivery.

Chromosomal Defect	Resultant Syndrome
Trisomy 21	Down syndrome
Trisomy 18	Edward syndrome
Trisomy 13	Patau syndrome
Chromosome 22q deletion	1. DiGeorge syndrome 2. Autosomal dominant Opitz G/BBB syndrome
Chromosome 17q deletion	Chromosome 17q deletion syndrome, including renal cyst and diabetes (RCAD) syndrome and Mayer-Rokitansky-Kuster-Hauser syndrome
Chromosome 16q deletion	Chromosome 16q deletion syndrome, including Townes-Brocks syndrome
Chromosome 13q deletion	Chromosome 13q deletion syndrome

**Table 2.**  
*Chromosomal abnormalities associated with oesophageal atresia.*



Single Gene Mutation (Chromosomal location)	Resultant Syndrome, Sequence and Associations
MYCN (2p24.1)	Feingold syndrome (ODED syndrome – Oculo-digito-esophageal-duodenal syndrome)
CHD7 (8q12)	CHARGE (Coloboma, Heart defects, Atresia of nasal choanae, Retarded growth/development, Genitourinary abnormalities, Ear anomalies) syndrome
SOX2 (3q26.33)	AEG (Anolphthalmos-Esophageal-Genital) syndrome
GLI3 (7p13)	Pallister-Hall syndrome
FANCA (16q24.3)	Fanconi anaemia
TBX5 (12q24.21)	Holt-Oram syndrome (Heart-hand syndrome)
Multifactorial	Goldenhar syndrome (Oculo-auriculo-vertebral syndrome)
RFX6 (6q22.1)	Martinez-Frias syndrome
FANCB (Xp22.2); FANCC (9q22.3); FANCD1 (13q12.3); FANCD2 (3p25.3); FANCG (9p13.3); PTEN (10q23.31)	VACTERL Association with hydrocephalus (VACTERL-H)
MID1 (Xp22.2)	X-linked Opitz G/BBB

**Table 3.**  
*Single gene mutations associated with oesophageal atresia.*

Postnatally, the neonate is not able to swallow saliva and food. This leads to accumulation of saliva and food in the upper oesophageal segment (pouch). The accumulated saliva and food then spill over into the lungs through the larynx and trachea. Patients are therefore prone to the development of aspiration pneumonia. Patients with distal tracheo-oesophageal fistula also tend to aspirate gastric secretions into the lungs, especially if lying in a head-down position.

The distal tracheo-oesophageal fistula also allows air to escape from the trachea to the stomach and hence the intestines. Consequently, patients can develop gross distention of the stomach and intestine, especially if patient is resuscitated using an Ambu bag. The distended stomach can then splint the diaphragm, impairing diaphragmatic excursion and thereby causing respiratory distress. The distended stomach can also rupture leading to chemical peritonitis.

In patients with delayed diagnosis, the constant regurgitation of swallowed food leads to malnutrition. Such patients tend to have poor surgical outcome and overall survival.

Associated congenital anomalies, especially severe cardiac and renal anomalies, also affect management and survival of patients. Low birth weight that may result from premature delivery owing to polyhydramnios also tends to affect management and survival.

**2.8 Clinical presentation**

Oesophageal atresia may be detected prenatally or postnatally.

*2.8.1 Prenatal presentation and diagnosis*

Prenatal diagnosis helps in planning of delivery and possible prenatal referral to centres that have the facilities to manage such patients.

Oesophageal atresia should be suspected prenatally in patients with evidence of polyhydramnios. Polyhydramnios will present with symphysio-fundal height

Associated anomaly	Incidence (%)
CVS	24
GUT	21
GIT	21
MSS	14
CNS	7

**Table 4.**  
*Common associated anomalies in non-syndromic oesophageal atresia.*

of more than the expected for gestational age. This is confirmed with antenatal ultrasonography with amniotic fluid index (AFI) of more than 24 cm.

Antenatal ultrasonographic features of polyhydramnios, a small stomach, a distended upper oesophageal pouch and abnormal swallowing should raise the suspicion of oesophageal atresia [28–31].

### *2.8.2 Postnatal presentation and diagnosis*

#### *2.8.2.1 History*

Postnatally, patients with oesophageal atresia present with drooling of saliva (excessive salivation). A history of antenatal polyhydramnios gives more credence to the diagnosis of oesophageal atresia. Delayed diagnosis leads to aspiration of saliva from the upper oesophageal pouch, causing aspiration pneumonia with cough, cyanosis and fever. Feeding leads to worsening of the aspiration pneumonia. Hence, early detection and avoidance of oral feeds helps to promote good outcome of patients.

Patients with distal tracheo-oesophageal fistula are also at risk of aspiration of gastric secretions into the lungs. In addition, swallowed air passes through the distal tracheo-oesophageal fistula into the stomach. This can lead to gross gastric distention, especially following Ambu bagging, resulting in diaphragmatic splinting and sometimes gastric rupture. They may thus present with respiratory distress, gross abdominal distention and sometimes peritonitis.

Patients with tracheo-oesophageal fistula without oesophageal atresia are usually diagnosed late. They present with recurrent cough associated with feeding and recurrent episodes of pneumonia.

Other symptoms would depend on associated congenital anomalies. Patients with cardiac anomalies may present with cyanosis. Patients with renal agenesis will have a history of anuria.

During history taking, one should seek for a maternal history of uncontrolled diabetes mellitus and the use of drugs such as oral contraceptives, antithyroid drugs (carbimazole and methimazole) and thalidomide. These are risk factors for oesophageal atresia.

The history of the maturity and weight of the baby at birth are also important considerations.

#### *2.8.2.2 Physical examination*

The principles of physical examination of a patient with suspected oesophageal atresia are to confirm the diagnosis, assess for aspiration pneumonia and evaluate for associated congenital anomalies.

To confirm the diagnosis, a stiff radiopaque 10-gauge French catheter is passed through the mouth into the oesophagus. The tube is not passed through the nose because it may traumatize the nasal passages. The diagnosis of oesophageal atresia is heightened if the tube fails to reach the stomach by getting arrested in the proximal oesophageal pouch at about 10 cm from the alveolar margin. A soft and smaller tube may coil in the upper oesophageal pouch, giving an impression of reaching the stomach. The secretions sucked through the tube can be tested with litmus paper to differentiate between saliva (basic) in the upper oesophageal pouch and gastric secretions (acidic).

The presence of fever, respiratory distress, reduced air entry in the lungs (especially on the right side) and crepitations in the lungs are an indication of aspiration pneumonia. However, patients in heart failure will have similar chest findings, and

these are usually bilateral. Gastric distention and gastric rupture will be associated with respiratory distress, abdominal distention and abdominal signs of peritonitis.

Meticulous examination for associated anomalies is done. The presence of cyanosis may be due to cyanotic heart disease. The chest is examined for heart murmurs and crepitations. The abdomen is examined for any palpable flank mass. The perineum is examined for ARM. The spine and the limbs are also examined for any anomaly. Indeed, the VACTERL association could be used as a guide to take history, examine and investigate for any associated congenital anomaly.

2.8.2.3 Investigations

Investigations are also done to confirm the diagnosis, to assess for complications (aspiration pneumonitis and gastric rupture) and to evaluate for associated anomalies.

Oesophageal atresia is confirmed by taking a plain X-ray of the neck, chest, and abdomen with a radiopaque tube passed through the mouth in situ. In the presence of oesophageal atresia, the X-ray will show the tube arrested in the upper oesophageal pouch or coiled in the upper pouch. The same X-ray is also evaluated for evidence of associated aspiration pneumonia, cardiac enlargement, dextrocardia and vertebral anomalies.

The abdominal portion will help to determine the presence of air in the stomach and intestine. The presence of air in the stomach and intestine indicates the presence of a distal tracheo-oesophageal fistula. Pneumoperitoneum indicates gastric rupture. A gasless abdomen implies the absence of a distal tracheo-oesophageal fistula. Such a patient may either have no tracheo-oesophageal fistula or a proximal fistula. The proximal fistula can be identified with the aid of bronchoscopy [32].

**Table 5** summarises the important diagnostic features of OA.

Abdominal ultrasound to assess the kidneys, ureters and the urinary bladder is also done. Patients with bilateral renal agenesis or severe multicystic dysplastic kidneys will need no further management since such patients will not survive. Renal scintigraphy will confirm non-functioning kidneys.

Ultrasonography (USG) of the spine is used to assess the spinal cord for anomalies, including tethered cord. The USG of the spinal cord should be done before 3 months of age since the bones become ossified after this age, rendering the use of USG impossible. Magnetic resonance imaging (MRI) may be used to evaluate the spinal cord. It is, however, very expensive and implies the need for general anaesthesia in a new born with a relatively high anaesthetic risk. It is not readily available at most centres, especially in the developing countries.

	Prenatal	Postnatal
Clinical Features	<ul style="list-style-type: none"><li>• Polyhydramnios</li></ul>	<ul style="list-style-type: none"><li>• Drooling of saliva (Excessive salivation)</li><li>• Cough, Fever, chest crepitations (Due to associated aspiration pneumonitis)</li><li>• Choking during feeding</li><li>• Prenatal history of polyhydramnios</li><li>• Cynosis due to aspiration pneumonitis and/or associated cyanotic heart disease</li><li>• Stiff radio-opaque 10-French catheter fails to reach the stomach (Arrested at about 10cm from the alveolar margin)</li></ul>
Imaging Features	Ultrasound: <ul style="list-style-type: none"><li>• Dilated upper oesophageal pouch</li><li>• Small stomach</li><li>• Abnormal swallowing</li></ul>	Plain X-Ray of the neck, chest and abdomen with the stiff radio-opaque 10-French catheter insitu: <ul style="list-style-type: none"><li>• Catheter found arrested (sometimes curled up/coiled up) in the upper oesophageal pouch</li><li>• Air in stomach and intestine indicates distal tracheo-oesophageal fistula</li><li>• Gasless abdomen implies no distal trachea-oesophageal fistula</li></ul>

**Table 5.**  
*Important diagnostic features of oesophageal atresia.*



Echocardiogram is used to evaluate the heart for a congenital heart disease and the direction of the arch of the aorta. The direction of the arch of the aorta (normally to the left) is utilised in deciding the side of the thoracotomy incision (usually on the right side since the arch is normally to the left). At our centre, echocardiogram is not routinely done for every patient since it is expensive and not readily available. Hence, we selectively use it for only patients with clinical evidence of congenital heart disease.

Patients with suspected chromosomal and genetic anomalies are evaluated to confirm the anomaly. However, this is not available at most centres in developing centres, including our centre. Patients with confirmed trisomy 18 (Edwards syndrome) should have any planned surgical intervention abandoned since prognosis for these patients is very poor.

Patients with Down syndrome should be evaluated for the possibility of associated duodenal atresia, congenital heart disease and Hirschsprung's disease.

Other investigations that are supportive are full blood count (FBC) and blood urea, electrolytes, and creatinine (BUE&Cr). Blood gases may be analysed in patients who are critically ill.

### 2.9 Clinical prognostic classification of patients

Prognostic classification is done based on risk factors that affect survival of infants with OA. It is used to guide operative treatment and to compare case outcomes over time and between centres. The first prognostic risk stratification of patients with OA was developed in 1962 (Waterston classification) [4]. This is based on birth weight, the presence of pneumonia and associated congenital anomalies (**Table 6**). It has provided important contribution to the care of infants with OA. Patients in group A (good-risk category) are offered immediate primary repair of the defect. Those in group B (moderate-risk category) are treated with delayed primary repair, while those in group C (high-risk category) are managed by staged repair.

Several new classification schemes have been developed because of improvement in neonatal intensive care and availability of more treatment options for multiple congenital anomalies. These new schemes include refinement of the Waterston classification by Randolph and colleagues in 1989 [33]. This is based on the overall physiologic status of the patient. Poenaru et al. [34] also developed a new prognostic classification based on severe pulmonary dysfunction with preoperative mechanical ventilation and severe associated anomalies. Spitz et al. [35] developed a new risk classification based on birth weight and major cardiac anomaly (**Table 7**). Currently, the Spitz classification is the most commonly used system [36, 37]. Another new prognostic classification system has been developed by adding preoperative respiratory distress syndrome and pneumonia to the Spitz classification [38].

Category	Waterston Classification	Survival (%)
A	Birth weight > 2.5Kg and otherwise healthy	100
B	(i) Birth weight 1.8-2.5Kg and well; OR (ii) Birth weight >2.5Kg with moderate pneumonia or moderate congenital anomaly	85
C	(i) Birth weight <1.8Kg; OR (ii) Birth weight >1.8Kg with severe pneumonia or Severe congenital anomaly	65

**Table 6.**  
*Waterston prognostic classification of oesophageal atresia infants.*

Group	Spitz Classification	Survival (%)
I	Birth weight >1.5Kg without major congenital heart disease	97
II	Birth weight <1.5Kg OR Major congenital heart disease	59
III	Birth weight <1.5Kg AND major congenital heart disease	22

**Table 7.**  
*Spitz prognostic classification of infants with oesophageal atresia.*

## 2.10 Management of patients

### 2.10.1 Pre-operative management

The aim of preoperative management is to make patient stable before surgical management of the oesophageal atresia. This involves prevention of complications, treatment of life-threatening complications, management of life-threatening associated congenital anomalies and general supportive measures.

Complications to be prevented are mainly aspiration and diaphragmatic splinting by gaseous distention of the stomach and intestines. Maintaining the child in a partly upright position and by repeated or continuous suctioning of the upper oesophageal pouch prevents aspiration. These measures keep the proximal oesophagus empty and reduce the likelihood of overflow of saliva into the lungs. The repeated suctioning of the upper oesophageal pouch should be done every 10 min or more often if the child appears to have excessive mucus or air bubbles. The best tube for suctioning, especially for continuous suctioning, is the Replogle tube. The partial upright position prevents aspiration of stomach secretions. Infants with OA should not be fed to prevent aspiration. The child should have minimal handling to prevent excessive crying and consequent filling of stomach with air. In addition, vigorous resuscitation by Ambu bagging should be avoided to prevent gastric distention.

The main life-threatening complication is respiratory distress. Respiratory distress may be due to prematurity, other congenital abnormalities, aspiration pneumonia, or diaphragmatic splinting. Diaphragmatic splinting in patients with OA results from excessive escape of air through the distal fistula into the stomach, causing distention of the stomach and intestines and, in some cases, causing gastric rupture. Thorough evaluation of the infant to determine the underlying cause and prompt management is paramount. Gross gastric distension and perforation, causing pneumoperitoneum and elevation of the diaphragm, can cause major morbidity by worsening ventilation. Prompt needle decompression of the abdomen should be offered. This is followed by urgent laparotomy to control the air leakage. This involves insertion of a Foley catheter through the gastric perforation into the lower oesophagus, thereby occluding the distal TOF and allowing thoracotomy to proceed, at which time the distal TOF is divided. Blood gases should be monitored, but if monitoring facilities are not available, the infant must be kept pink at all times, and pulse oximetry for monitoring is considered standard.

Patients with duct-dependent congenital heart disease should be stabilised, by keeping the duct (patent ductus arteriosus) patent with prostaglandin E1 infusion, before surgery is done.

General supportive measures include keeping the child warm, vitamin K administration, provision of IV fluids/parenteral nutrition and administration of broad-spectrum antibiotics.

### 2.10.2 Operative management of oesophageal atresia

The operative management may be immediate primary repair, delayed primary repair or staged repair; and this depends on the prognostic category of the patient and the gap between the upper and the lower oesophageal segments. Patients with pneumonia and duct-dependent congenital heart disease need to be stabilised and planned for delayed primary repair. Patients with long-gap oesophageal atresia could also be managed with delayed primary repair. Further growth of the upper oesophageal pouch tends to occur if primary repair is delayed for about 3 months. Hence, the role of total parenteral nutrition (TPN) becomes significantly important. No consensus has been reached for the definition of long-gap OA. However, long gap is defined by some authorities as a gap of  $\geq 3$  vertebral bodies or  $\geq 5$  cm [39].

Primary repair is achieved mostly through a right thoracotomy (readers should read operative textbooks for details of the surgical procedure). However, in patients with right-sided arch of aorta, left thoracotomy is done. The patient is placed at the right side uppermost and with a towel folded underneath the left chest to give lateral flexion. The right arm is extended above the head and the head slightly flexed. A transverse incision is centred on the inferior angle of the scapula, and the chest is entered through the fourth intercostal space. Approach to the oesophagus may be extrapleural or transpleural. The extrapleural approach is favoured because of the less likelihood of developing empyema following an anastomotic leak. The pleura is swept off the chest wall to identify the structures of the posterior mediastinum. The azygous vein is then ligated and divided.

Any distal TOF is identified and divided close to the trachea. The fistula is then closed with interrupted absorbable sutures such as 4/0 Vicryl, PDS, or Monocryl. Care should be taken to avoid damage to the vagal fibres and blood supply to the distal oesophageal segment.

The upper oesophagus is identified with the aid of a tube passed through the mouth or nose by the anaesthetist. It is then mobilised enough to allow an end-to-end, one-layer, interrupted oesophageal anastomosis, ensuring that the mucosa and the submucosa are included. The upper oesophageal segment can be extensively mobilized along its full length without risk of significant ischemia. If extensive mobilization of the proximal oesophagus fails to provide adequate length, the lower oesophagus may be mobilized to prevent undue tension on the anastomosis. Mobilising the lower oesophagus without complete disruption of its segmental vascular supply is possible. However, care should be taken to avoid excessive or rough handling of the oesophagus. If, despite extensive mobilisation of the two oesophageal segments, an anastomosis cannot be performed without excessive tension, an oesophageal myotomy (Levaditis procedure) can be performed. Myotomy (circular or spiral myotomy) is usually done using the upper pouch. It can cause significant damage to the nerve and blood supply distal to the myotomy and predisposes to diverticulum formation and strictures.

Patients with TOF without atresia have an oblique fistula running downward from the trachea to the oesophagus, usually at the level of T1–T3. This level is somewhat higher than what is seen in most patients with oesophageal atresia. In these patients, a cervical approach provides the best surgical access as most fistulas are in the root of the neck (at about the level of the second thoracic vertebra). Care should be taken to avoid damage to the recurrent laryngeal nerves, which lie in the grooves between the oesophagus and the trachea and closely related to the fistula, during operative dissection.

Staged repair of OA involves division of TOF, placement of feeding gastrostomy and cervical oesophagostomy. Disconnection of distal TOF is done at most centres through thoracotomy. At our centre, however, this is done by dividing the abdominal



oesophagus during the placement of the feeding gastrostomy [27]. This helps to avoid the stress of thoracotomy that may negatively affect patient outcome. Patients who undergo staged repair are later offered oesophageal replacement surgery.

It should be noted that the surgical management of OA has been advanced into the realm of minimally invasive surgery (thoracoscopy) due to recent advances in surgical techniques. [40–49]. Thoracoscopic approach to the repair of OA is associated with early recovery and minimal chest wall musculoskeletal morbidity as compared with open surgery (thoracotomy).

2.11 Manoeuvres for managing long-gap OA to achieve primary repair

Various manoeuvres are used to narrow the gap between the upper and lower oesophageal segments [50]. These manoeuvres are classified as preoperative manoeuvres and intraoperative manoeuvres (Table 8).

Preoperative manoeuvres are those that are done before the surgery for primary repair is attempted; and they may be achieved thoracoscopically [45, 51]. These include external traction technique by Foker [50, 52, 53]; multistage, extrathoracic elongation technique by Kimura [52, 54]; bougienage of the upper oesophageal pouch, sometimes including the lower pouch; placement of magnets in the two ends of the oesophageal segments with patient placed in an electromagnetic field and delaying of surgery for some months to allow growth of the oesophagus.

In the Kimura technique, the upper part of the oesophagus is mobilised and brought out as an end-cervical oesophagostomy. The oesophagus and its cutaneous stoma are surgically mobilised and translocated down the anterior chest wall every 2–3 weeks. This is continued until enough length is achieved to perform an end-to-end oesophageal anastomosis. The Foker technique involves open or thoracoscopic placement of traction sutures on both the proximal and distal oesophageal pouches with the sutures exiting through the chest wall. These sutures are serially pulled in opposite directions until the pouches approximate. This external traction technique of Foker is reported to induce oesophageal growth and expedite approximation of the pouches.

Internal traction techniques have also been used to bridge long gaps [45, 55]. These include open or thoracoscopic suturing of the oesophageal segments to the prevertebral fascia or costal bone under tension.

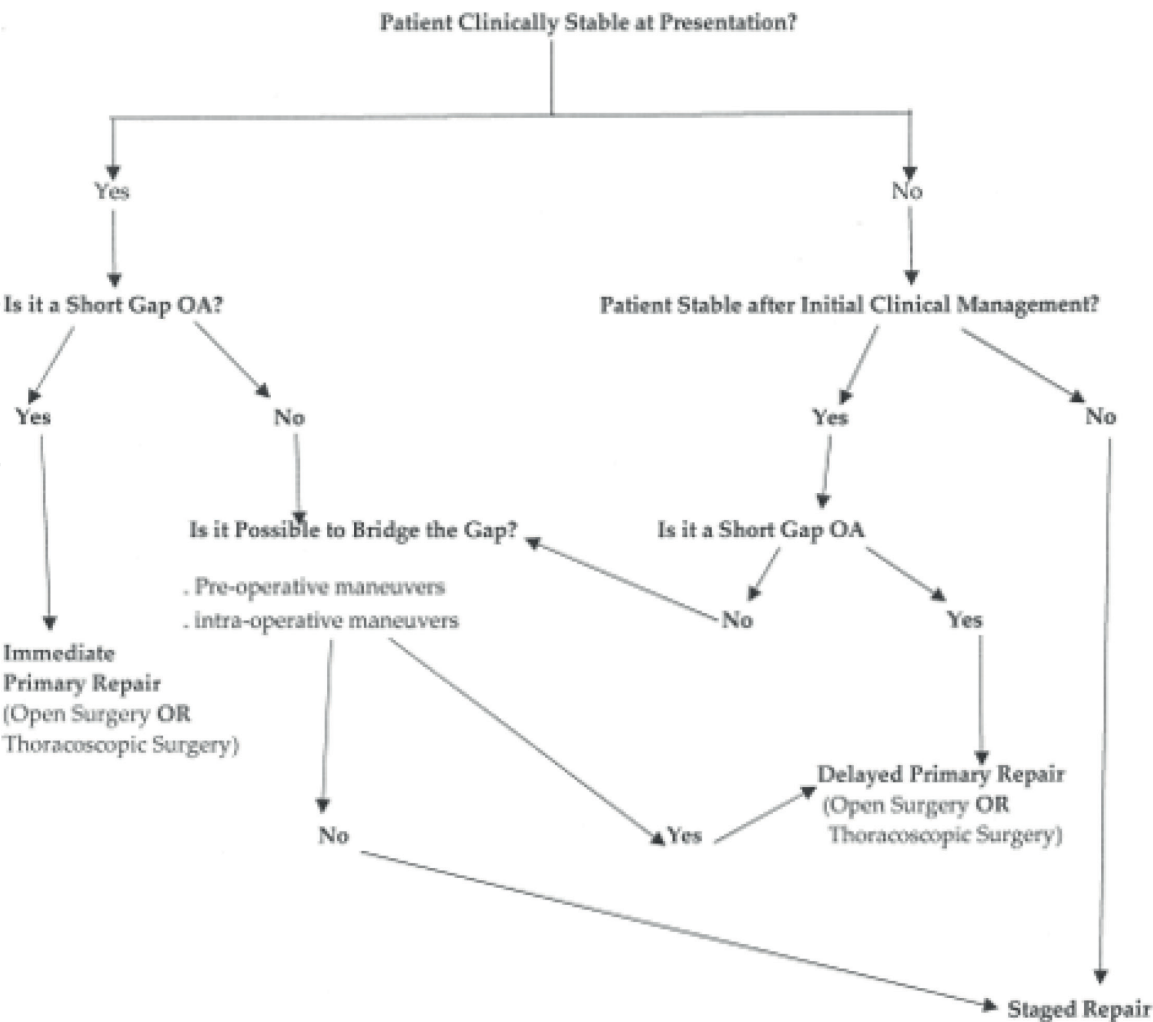
Intra-operative manoeuvres include full mobilisation of the upper segment of the oesophagus; mobilisation of the distal segment; circular myotomy (Levaditis technique) or spiral myotomy, usually of the upper pouch and mobilisation of the stomach into the chest.

Other intraoperative techniques include full-thickness anterior flap of the upper pouch [56] and injection of Botox into the upper segment.

Figure 3 shows an algorithm for the management of patients with oesophageal atresia.

Pre-operative Maneuvers	Intra-operative Maneuvers
<ul style="list-style-type: none"><li>• Delaying surgery for about 3 months</li><li>• Traction techniques<ul style="list-style-type: none"><li>- External traction technique by Foker</li><li>- Internal traction technique (Suturing of oesophageal segments to prevertebral fascia or costal bone under tension)</li></ul></li><li>• Multistage extrathoracic oesophageal elongation technique by Kimura</li><li>• Bougienage of oesophageal pouch</li><li>• Magnetic elongation technique</li></ul>	<ul style="list-style-type: none"><li>• Extensive mobilisation of the upper oesophageal pouch; and sometimes the lower oesophageal pouch</li><li>• Myotomy<ul style="list-style-type: none"><li>- Circular myotomy by Levaditis</li><li>- Spiral myotomy</li></ul></li><li>• Full thickness anterior flap of the upper oesophageal pouch</li><li>• Mobilisation of stomach into the chest</li><li>• Injection of botox into the upper oesophageal segment</li></ul>

Table 8.  
Pre-operative and intraoperative oesophageal elongation manoeuvres for long-gap oesophageal atresia.



**Figure 3.**  
*Algorithm for the management of patients with oesophageal atresia.*

## 2.12 Complications after repair of OA

Complications [57–59] resulting from repair of OA are generally grouped into two: early and late complications (**Table 9**). Early complications include anastomotic leak, anastomotic stricture, and recurrent tracheo-oesophageal fistula. Tracheomalacia, gastro-oesophageal reflux and oesophageal dysmotility are the late complications. Factors that promote postoperative complications include preoperative intubation, birth weight less than 2.5 kg, long-gap OA [60], post-operative intubation for more than 4 days, anastomotic leak and inability to feed orally for more than 1 month [61]. Management of the complications may involve a multidisciplinary approach.

### 2.12.1 Early complications

#### 2.12.1.1 Anastomotic leak

Anastomotic leak at the oesophago-oesophagostomy is found in about 14–16% of patients after primary repair of OA. Most often, the leaks are clinically insignificant and can be managed with adequate drainage and nutritional support. Up to 95% of the leaks close spontaneously when a retropleural approach is undertaken and a patent mediastinal drain is in place [62]. Even in transpleural repair with leakage, spontaneous closure occurs with adequate drainage. Anastomotic breakdown

Early Complications	Late Complications
<ul style="list-style-type: none"><li>• Anastomotic leakage</li><li>• Anastomotic stricture</li><li>• Recurrent trachea-oesophageal fistula</li></ul>	<ul style="list-style-type: none"><li>• Gastro-oesophageal reflux</li><li>• Tracheomalacia</li><li>• Oesophageal dysmotility</li></ul>

**Table 9.**  
*Complications associated with oesophageal atresia repair.*

usually leads to the formation of a stricture at the site and may be associated with a recurrent TOF. Only 3–5% of anastomotic leaks are known to result from major disruptions of the oesophageal anastomosis. They are found to be typically seen within 24–48 h after repair. Patients usually deteriorate as result of tension pneumothorax or mediastinitis. Hence, prompt reoperation with adequate drainage is imperative. Repair of the leak may be attempted, and this may be buttressed with the help of a pleural or pericardial patch, with or without intercostal muscle flap. Contributing factors to anastomotic leak include poor surgical technique, ischemia of the oesophageal ends, the use of myotomy and excessive tension at the anastomotic site [63, 64]. If reanastomosis is not possible, cervical oesophagostomy and delayed oesophageal replacement would be required.

2.12.1.2 *Anastomotic stricture*

Anastomotic stricture is found to be a common complication after repair of OA. It is characterised by dysphagia and recurrent respiratory problems due to aspiration or foreign body obstruction. The narrowing is noted on endoscopy or contrast oesophagography. Poor anastomotic technique (excessive tension, two-layered anastomosis and silk suture material), long gap, ischemia at the ends of the oesophagus, gastro-oesophageal reflux and anastomotic leak are factors implicated in the pathogenesis of oesophageal stricture.

Anastomotic stricture is treated by dilatation. However, a stricture resistant to repeated dilatations will require resection and reanastomosis or oesophageal replacement. Triamcinolone injection may be used at the stricture site. However, repeated injections may lead to adrenal suppression. Application of mitomycin C to the stricture under endoscopic control has also been reported to reduce stricture formation after dilation. It is important to determine whether the oesophageal stricture is associated with gastro-oesophageal reflux. This can be determined using contrast oesophagography, endoscopy, pH monitoring or a combination of these studies. The presence of gastro-oesophageal reflux is initially managed medically with proton pump inhibitors. Failure of medical management may warrant antireflux procedure.

2.12.1.3 *Recurrent tracheo-oesophageal fistula*

Recurrent TOF commonly results from anastomotic leak with local inflammation and erosion through the previous site of TOF repair. Recurrent TOF can be minimised by the use of a pleural flap, vascularized pericardial flap or azygous vein flap interposed between the oesophageal and tracheal suture lines. Symptoms of recurrent TOF can be typical of those seen with a congenital H-type TOF (coughing with feedings and recurrent respiratory distress). However, less obvious symptoms such as recurrent pulmonary infections are more common. Air-filled oesophagus on plain radiographs of the chest is suggestive of the diagnosis. As done in patients with congenital H-type fistula, contrast oesophagography performed in the prone position under videofluoroscopy is a reliable method of establishing the diagnosis. Another reliable diagnostic approach is bronchoscopy with cannulation of the fistula with a 2- to 3-French catheter. It is invaluable in locating the fistula



during the operative procedure. About 50% of recurrent TOF is missed on routine contrast swallow studies. A recurrent TOF rarely closes spontaneously and usually requires surgical repair. Operation of choice is thoracotomy with fistula ligation, and division is the operation of choice. Pleura, intercostal muscle or pericardium should be interposed between the oesophagus and trachea to minimise recurrence. Endoscopic treatment of TOF by means of various chemicals or diathermy has also been reported. Various case reports and case series have reported the use of diathermy or laser deepithelialization followed by fibrin glue.

### *2.12.2 Late complications*

#### *2.12.2.1 Gastro-oesophageal reflux*

Gastro-oesophageal reflux is a common complication after repair of OA [65]. It is probably related to shortening of the intra-abdominal portion of the oesophagus because of anastomotic tension and/or oesophageal motor dysfunction. The motor dysfunction may be intrinsic to the congenital anomaly or acquired from operative manipulation. Clinically, gastro-oesophageal reflux is suspected in patients with symptoms of vomiting, dysphagia and recurrent anastomotic stenosis. Episodes of foreign body or food bolus impaction may occur. Respiratory symptoms such as stridor, cyanotic spells, recurrent pneumonia and reactive airway disease are also suggestive of gastro-oesophageal reflux.

Upper gastrointestinal contrast study and 24-h pH probe data are diagnostic tools for gastro-oesophageal reflux. Multichannel oesophageal impedance combined with pH monitoring may emerge as a superior test. Abnormal oesophageal peristalsis and decreased lower oesophageal sphincter pressures after OA repair have been documented on oesophageal manometry. Medical management typically consists of thickening of feedings, positioning of the infant in a prone or upright posture, administration of acid reduction agents such as histamine-2 blockers, proton pump inhibitors and prokinetic agents. Antireflux operations are offered for patients with failed medical management, failure to thrive, chronic pulmonary infection, refractory anastomotic stricture or the development of a distal oesophageal stricture.

#### *2.12.2.2 Tracheomalacia*

Respiratory symptoms occurring after repair of OA can be due to tracheomalacia. Tracheomalacia is defined as generalized or localized weakness of the trachea that allows the anterior and posterior tracheal walls to come together during expiration or coughing.

Symptoms of tracheomalacia are often difficult to clinically distinguish from those of recurrent TOF, anastomotic leak, or gastro-oesophageal reflux. Embryologic events leading to TOF are believed to contribute to the development of tracheomalacia [61]. The tracheal cartilage is shorter than normal, thereby failing to provide the support necessary to maintain a patent airway [61]. The trachea may also be compressed between the aorta anteriorly and the often dilated upper oesophagus posteriorly after repair of OA; and such compression has been considered a significant contributor to the pathophysiology of tracheomalacia [61]. The tracheal collapse usually occurs in the region of or just above the original site of TOF in the distal third of the trachea which is generally at the level of the aortic arch; and severe tracheomalacia appears less common in infants with pure OA. Tracheomalacia has broad clinical manifestations, ranging from a “brassy” or “barking” cough in mild cases to recurrent pneumonia or acute, life-threatening

apnoeic spells. Because of difficulty in breathing or cyanotic attacks during feeding, infants with tracheomalacia are often reluctant to feed. Life-threatening apnoeic and cyanotic spells occur during or within 5–10 min of a meal. They are characterized by cyanosis progressing to apnoea, bradycardia, and ultimately, cardiorespiratory arrest if not detected and managed promptly. Diagnosis is established by bronchoscopy with spontaneous ventilation. This reveals a slit-like lumen of the trachea at the involved area. However, because the symptoms overlap those of a stricture or gastro-oesophageal reflux, contrast oesophagogram is usually done as an initial investigation. Close attention to the tracheal air column on the lateral views during such a study will often reveal complete tracheal collapse during forced expiration (i.e., crying) or when contrast fills a distended upper oesophagus just above the anastomosis. Most mild to moderate symptoms of tracheomalacia tend to improve with time. Hence, operative intervention is not required. Operative treatment of choice for patients with severe symptoms, including acute life-threatening events, is aortopexy [46, 61, 66]. This is usually performed through a left anterior mediastinotomy (Chamberlain approach) or anterolateral thoracotomy [61]. The ascending aorta and arch are sutured to the posterior surface of the sternum after partial thymectomy [61]. The lifting of the aorta up in this fashion raises the anterior wall of the trachea and opens the tracheal lumen. In cases in which the aortic arch would not reach the posterior aspect of the sternum without undue tension, the use of a flap of pericardium based at the root of the aorta to be sutured to the sternum may be used [61]. Aortopexy and tracheopexy have also been done through anterior mediastinal approach via a low transverse cervical incision.

2.13 Oesophageal replacement

Oesophageal replacement surgery is usually done for patients with OA when primary repair fails or when primary repair is impossible. Various operative procedures have been described; and the most commonly used ones are colon or ileocolon interposition, reversed (antiperistalsis) gastric tube interposition, isoperistalsis gastric tube interposition, jejunum interposition and gastric transposition (gastric pull-up) [67] (**Table 10**).

Among the methods, colon replacement, or ileocolon, has been widely practiced for many years as a method of oesophageal replacement. This involves placement of the right or left colon substernally or behind the hilum of the lung on the right or left side. To avoid stricture or ulceration at the cologastric anastomosis, vagotomy and a gastric drainage procedure are typically performed. Complications after colonic interposition include cervical anastomotic leak, stricture and intrathoracic redundant colon with stasis, gastric reflux, respiratory problems and diarrhoea.

Reversed gastric tube as a substitute is preferred by some surgeons. A tubularised portion of the greater curvature is brought up to the cervical oesophagus in the substernal or retrohilar position. This procedure has similar complications as described for colonic interposition. A portion of the greater curvature of the stomach can be fashioned into a “free” tube graft based on the right gastroepiploic artery; and this is used as a modification of the reversed gastric tube for oesophageal replacement.

<ul style="list-style-type: none"><li>• Colon or ileocolon interposition</li><li>• Gastric tube interposition<ul style="list-style-type: none"><li>- Reversed (antiperistalsis)</li><li>- Isoperistalsis</li></ul></li><li>• Jejunum interposition</li><li>• Gastric transposition (gastric pull-up)</li></ul>
--

**Table 10.**  
*Commonly used oesophageal replacement techniques.*

Oesophageal replacement can also be achieved using the jejunum, both in a Roux-en-Y fashion and as a free graft with microvascular anastomosis. Recently, a well-established method for oesophageal replacement is the use of gastric transposition.

## 2.14 Outcome and conclusion

During the early years, the surgical management of OA was associated with lots of challenges and high mortality [1–4]. Respiratory failure, inadequate resuscitation, and complications of prematurity resulted in most deaths in the past. Complications of the surgical repair of the oesophageal atresia itself, particularly sepsis after dehiscence of the oesophageal anastomosis, and prolonged poor nutrition are other major causes of mortality.

Over the past two to three decades, however, the surgical outcome has improved significantly in most centres in the developed countries. This improvement is attributed to advances in neonatal anaesthesia, well-established neonatal intensive care units (NICU), availability of total parental nutrition (TPN) and refined surgical skills [1, 5–8]. The current major cause of mortality in most developed countries is from associated major congenital abnormalities. Death from prematurity or oesophageal complications is now rare. In view of this, the previously used Waterston classification has little relevance in developed countries. The prognosis however remains poor in developing countries where late presentation is the norm. Waterston classification may remain relevant in these countries.

Gastro-oesophageal reflux and poor oesophageal clearance due to some degree of ongoing oesophageal dysmotility may limit long-term survival. Dysplastic changes in the lower oesophageal mucosa may predispose to oesophageal carcinoma. Ongoing gastro-oesophageal reflux is a significant risk factor for oesophageal carcinoma. Hence, regular surveillance in these patients is important.

## Conflict of interest


Nil.

## Author details

Samuel Osei-Nketiah\* and William Appeadu-Mensah  
Department of Surgery, University of Ghana School of Medicine and Dentistry,  
Accra, Ghana

\*Address all correspondence to: [oseivatican@yahoo.com](mailto:oseivatican@yahoo.com)

## IntechOpen

© 2019 The Author(s). Licensee IntechOpen. This chapter is distributed under the terms of the Creative Commons Attribution License (<http://creativecommons.org/licenses/by/3.0>), which permits unrestricted use, distribution, and reproduction in any medium, provided the original work is properly cited. 



## References

- [1] Pinheiro PF, Simões e Silva AC, Pereira RM. Current knowledge on esophageal atresia. *World Journal of Gastroenterology*. 2012;**18**:3662-3672
- [2] Spitz L. Oesophageal atresia. *Orphanet Journal of Rare Diseases*. 2007;**2**:24
- [3] Lanman TH. Congenital atresia of the oesophagus: A study of thirty-two cases. *Archives of Surgery*. 1940;**7**:1060
- [4] Waterston DJ, Carter RE, Aberdeen E. Oesophageal atresia: Tracheo-oesophageal fistula. A study of survival in 218 infants. *Lancet*. 1962;**1**:819-822
- [5] Spitz L. Esophageal atresia. Lessons I have learned in a 40-year experience. *Journal of Pediatric Surgery*. 2006;**41**:1635-1640
- [6] Grosfeld JL, Ladd AP. Congenital anomalies. In: Silva AC, Pereira RM, Pinheiro PF, editors. *Pediatric Surgery—Clinical and Surgical Conduct*. Rio de Janeiro: Guanabara Koogan; 2005. pp. 291-298
- [7] Nakayana DK. Congenital abnormalities of the esophagus. In: O'Neill JA Jr, Grosfeld JL, Foukalsrud EW, Coran AG, Caldanone AA, editors. *Principles of Pediatric Surgery*. 2nd ed. St. Louis, MO: Mosby; 2003. pp. 385-394
- [8] Goyal A, Jones MO, Couriel JM, Losty PD. Oesophageal atresia and tracheo-oesophageal fistula. *Archives of Disease in Childhood. Fetal and Neonatal Edition*. 2006;**91**:F381-F384
- [9] Osei-Nketiah S, Hesse AA, Appeadu-Mensah W, Glover-Addy H, Etwire VK, Sarpong P. Management of oesophageal atresia in a developing country: Is primary repair forbidden? *African Journal of Paediatric Surgery*. 2016;**13**:114-119
- [10] Karakus SC, Ozokutan BH, Bakal U, Ceylan H, Sarac M, Kul S, et al. Delayed diagnosis: An important prognostic factor for oesophageal atresia in developing countries. *Journal of Paediatrics and Child Health*. 2016;**52**(12):1090-1094
- [11] Ameh EA, Dogo PM, Nmadu PT. Emergency neonatal surgery in a developing country. *Pediatric Surgery International*. 2001;**17**:448-451
- [12] Skandalakis JE, Ellis H. Embryologic and anatomic basis of esophageal surgery. *The Surgical Clinics of North America*. 2000;**80**(1):85
- [13] Kluth D, Fiegel H. The embryology of the foregut. *Seminars in Pediatric Surgery*. 2003;**12**(1):3-9
- [14] Beasley P. Anatomy of the pharynx and esophagus. In: Kerr AG, Gleeson M, editors. *Scott-Brown's Otolaryngology*. 6th ed. Oxford, UK: Butterworth-Heinemann; 1997
- [15] Postma GN, Seybt MW, Rees CJ. Esophagology. In: Snow JB, Wackym PA, editors. *Ballinger's Otolaryngology Head & Neck Surgery*. 17th ed. Shelton, Conn: BC Decker Inc; 2009. pp. 975-995
- [16] Swigart LL. The esophageal arteries. *Surgery, Gynecology & Obstetrics*. 1950;**90**:234-243
- [17] Geboes K, Geboes KP, Maleux G. Vascular anatomy of the gastrointestinal tract. *Best Practice & Research. Clinical Gastroenterology*. 2001;**15**(1):1-14
- [18] Potter SE. Observations on the intrinsic blood supply of the esophagus. *Archives of Surgery*. 1950;**61**:944-948
- [19] Shapiro AL. The esophageal arteries: Their configurational anatomy and variations in relation to surgery. *Annals of Surgery*. 1950;**131**:171-185
- [20] Butler H. The veins of the esophagus. *Thorax*. 1951;**6**:276-296

- [21] Sasaki CT, Kim YH, Sims HS, et al. Motor innervation of the human cricopharyngeus muscle. *Annals of Otology, Rhinology, and Laryngology*. 1999;**108**(12):1132-1139
- [22] Goyal RK, Martin SB, Shapiro J, et al. The role of cricopharyngeus muscle in pharyngoesophageal disorders. *Dysphagia*. 1993;**8**(3):252-258
- [23] Harmon CM, Coran AG. Congenital anomalies of the esophagus. In: Coran AG, Adzick NS, Krummel TM, et al., editors. *Pediatric Surgery*. 7th ed. Vol. 1. Philadelphia, USA: Elsevier Saunders; p. 896 (chapter 69)
- [24] Beasley SW. Esophageal atresia and tracheoesophageal fistula. In: Oldham KT, Colombani PM, Foglia RP, Skinner MA, editors. *Principles and Practice of Pediatric Surgery*. 4th ed. Vol. 2. Philadelphia, USA: Lippincott Williams & Wilkins; p. 1040 (chapter 65)
- [25] Harmon CM, Coran AG. Congenital anomalies of the esophagus. In: Coran AG, Adzick NS, Krummel TM, et al., editors. *Pediatric Surgery*. 7th ed. Vol. 1. Philadelphia, USA: Elsevier Saunders; p. 897 (chapter 69)
- [26] Brosens E, Marsch F, de Jong EM, et al. Copy number variations in 375 patients with oesophageal atresia and/or tracheoesophageal fistula. *European Journal of Human Genetics*. 2016;**24**(12):1715-1723
- [27] Al-Salem AH, Tayeb M, Khogair S, et al. Esophageal atresia with or without tracheoesophageal fistula: Success and failure in 94 cases. *Annals of Saudi Medicine*. 2006;**26**(2):116-119
- [28] Shulman A, Mazkereth R, Zalel Y, et al. Prenatal identification of oesophageal atresia: The role of ultrasonography for evaluation of functional anatomy. *Prenatal Diagnosis*. 2002;**22**(8):669-674
- [29] Tröbs RB, Nissen M, Wald J. The upper pouch in oesophageal atresia shows proportional growth during late foetal life. *Acta Paediatrica*. 2018;**107**(9):1648-1649
- [30] Garabedian C, Sfeir R, Langlois C, Bonnard A, Khen-Dunlop N, Gelas T, et al. Does prenatal diagnosis modify neonatal treatment and early outcome of children with esophageal atresia? *American Journal of Obstetrics and Gynecology*. 2015;**212**:e1-e7
- [31] Bradshaw CJ, Thakkar H, Knutzen L, Marsh R, Pacilli M, Impey L, et al. Accuracy of prenatal detection of tracheoesophageal fistula and oesophageal atresia. *Journal of Pediatric Surgery*. 2016;**51**(8):1268-1272
- [32] Summerour V, Stevens PS, Lander AD, Singh M, Soccorso G, Arul GS. Characterization of the upper pouch tracheo-oesophageal fistula in oesophageal atresia. *Journal of Pediatric Surgery*. 2017;**52**(2):231-234
- [33] Randolph JG, Newman KD, Anderson KD. Current results in repair of esophageal atresia with tracheoesophageal fistula using physiologic status as a guide to therapy. *Annals of Surgery*. 1989;**209**:526, discussion 530
- [34] Poenaru D, Laberge JM, Neilson IR, et al. A new prognostic classification for esophageal atresia. *Surgery*. 1993;**113**:426
- [35] Spitz L, Kiely EM, Morecroft JA, Drake DP. Esophageal atresia: At-risk groups for the 1990s. *Journal of Pediatric Surgery*. 1994;**29**:723
- [36] Driver CP, Shanker KR, Jones MO, et al. Phenotypic presentation and outcome of esophageal atresia in the era of Spitz classification. *Journal of Pediatric Surgery*. 2001;**36**(9):1419-1421
- [37] Konkin DE, O'Hali AW, Webber EM, Blair GK. Outcomes in esophageal

atresia and tracheoesophageal fistula. *Journal of Pediatric Surgery*. 2003;**38**(12):1726-1729

[38] Yagyu M, Gitter H, Richter B, et al. Esophageal atresia in Bremen, Germany—Evaluation of preoperative risk classification in esophageal atresia. *Journal of Pediatric Surgery*. 2000;**35**(4):584-587

[39] Barnhart DC, Area MJ, Coran AG. Esophageal atresia with or without tracheoesophageal fistula. In: Glick PL, Pearl RH, Irish MS, Caty MG, editors. *Pediatric Surgery Secrets*. Philadelphia, USA: Hanley & Belfus Inc.; 2001. p. 35

[40] Prakash KR, Bhardwaj N, Dwivedi D, et al. Thoracoscopic repair of esophageal atresia with tracheoesophageal fistula: Basics of technique and its nuances. *Journal of Indian Association of Pediatric Surgeons*. 2016;**21**(3):120-124

[41] Okuyama H, Koga H, Ishimaru T, et al. Current practice and outcomes of thoracoscopic esophageal atresia and tracheoesophageal fistula repair: A multi-institutional analysis in Japan. *Journal of Laparoendoscopic & Advanced Surgical Techniques. Part A*. 2015;**25**(5):441-444

[42] Lee S, Lee SK, Seo JM. Thoracoscopic repair of esophageal atresia with tracheoesophageal fistula: Overcoming the learning curve. *Journal of Pediatric Surgery*. 2014;**49**(11):1570-1572

[43] Rothenberg S. Thoracoscopic repair of esophageal atresia and tracheo-esophageal fistula in neonates: The current state of the art. *Pediatric Surgery International*. 2014;**30**(10):979-985

[44] Rothenberg SS, Flake AW. Experience with thoracoscopic repair of long gap esophageal atresia in neonates. *Journal of Laparoendoscopic*

*& Advanced Surgical Techniques. Part A*. 2015;**25**(11):932-935

[45] Tainaka T, Uchida H, Tanano A, et al. Two-stage thoracoscopic repair of long-gap esophageal atresia using internal traction is safe and feasible. *Journal of Laparoendoscopic & Advanced Surgical Techniques. Part A*. 2017;**27**(1):71-75

[46] van der Zee DC, Tytgat SHA, van Herwaarden MYA. Esophageal atresia and tracheo-esophageal fistula. *Seminars in Pediatric Surgery*. 2017;**26**(2):67-71

[47] Holcomb GW 3rd. Thoracoscopic surgery for esophageal atresia. *Pediatric Surgery International*. 2017;**33**(4):475-481

[48] García LI, Olivos PM, Santos MM, Guelfand CHM. Thoracoscopic repair of esophageal atresia with and without tracheoesophageal fistula. *Revista Chilena de Pediatría*. 2014;**85**(4):443-447

[49] Woo S, Lau S, Yoo E, Shaul D, Sydorak R. Thoracoscopic versus open repair of tracheoesophageal fistulas and rates of vocal cord paresis. *Journal of Pediatric Surgery*. 2015;**50**(12):2016-2018

[50] Shieh HF, Jennings RW. Long-gap esophageal atresia. *Seminars in Pediatric Surgery*. 2017;**26**(2):72-77

[51] van der Zee DC, Gallo G, Tytgat SH. Thoracoscopic traction technique in long gap esophageal atresia: Entering a new era. *Surgical Endoscopy*. 2015;**29**(11):3324-3330

[52] Sroka M, Wachowiak R, Losin M, et al. The Foker Technique (FT) and Kimura Advancement (KA) for the treatment of children with long-gap esophageal atresia (LGEA): Lessons learned at two European centers. *European Journal of Pediatric Surgery*. 2013;**23**:3-7



- [53] Bobanga ID, Barksdale EM. Foker technique for the management of pure esophageal atresia: Long-term outcomes at a single institution. *European Journal of Pediatric Surgery*. 2016;**26**(2):215-218
- [54] Miyano G, Okuyama H, Koga H, et al. Type-A long-gap esophageal atresia treated by thoracoscopic esophagoesophagostomy after sequential extrathoracic esophageal elongation (Kimura's technique). *Pediatric Surgery International*. 2014;**29**(11):1171-1175
- [55] Bogusz B, Patkowski D, Gerus S, et al. Staged thoracoscopic repair of long-gap esophageal atresia without temporary gastrostomy. *Journal of Laparoendoscopic & Advanced Surgical Techniques. Part A*. 2018;**28**(12):1510-1512
- [56] Sharma AK, Mangal D. Simple technique of bridging wide gap in esophageal atresia with tracheoesophageal fistula—"Surgical innovation". *Journal of Indian Association of Pediatric Surgeons*. 2017;**22**(3):187-188
- [57] Krishnan U, Faure C. Editorial: Oesophageal atresia-tracheoesophageal fistula. *Frontiers in Pediatrics*. 2017;**5**:190
- [58] Sadreameli SC, McGrath-Morrow SA. Respiratory care of infants and children with congenital tracheo-oesophageal fistula and oesophageal atresia. *Paediatric Respiratory Reviews*. 2016;**17**:16-23
- [59] Duvoisin G, Krishnan U. Gastric function in children with oesophageal atresia and tracheoesophageal fistula. *Frontiers in Pediatrics*. 2017;**5**:76
- [60] Thakkar HS, Cooney J, Kumar N, Kiely E. Measured gap length and outcomes in oesophageal atresia. *Journal of Pediatric Surgery*. 2014;**49**(9):1343-1346
- [61] Harmon CM, Coran AG. Congenital anomalies of the esophagus. In: Coran AG, Adzick NS, Krummel TM, et al., editors. *Pediatric Surgery*. 7th ed. Vol. 1. Philadelphia, USA: Elsevier Saunders; p. 911 (chapter 69)
- [62] Manning PB, Morgan RA, Coran AG, et al. Fifty years experience with esophageal atresia and tracheoesophageal fistula. Beginning with Cameron Haight's first operation in 1935. *Annals of Surgery*. 1986;**204**:446
- [63] Velligas-Alvarez F, Olvera-Duran J, Rodriguez-Aranda E, et al. Esophageal anastomotic failure: An experimental study. *Archives of Medical Research*. 2003;**34**:171
- [64] Yanchar NL, Gordon R, Cooper M, et al. Significance of the clinical course of and early upper gastrointestinal studies in predicting complications associated with repair of esophageal atresia. *Journal of Pediatric Surgery*. 2001;**36**(5):815-822
- [65] Svoboda E, Fruithof J, Widenmann-Grolig A, et al. A patient led, international study of long term outcomes of esophageal atresia: EAT 1. *Journal of Pediatric Surgery*. 2018;**53**(4):610-615
- [66] Arnaud AP, Rex D, Elliott MJ, et al. Early experience of thoracoscopic aortopexy for severe tracheomalacia in infants after esophageal atresia and tracheo-esophageal fistula repair. *Journal of Laparoendoscopic & Advanced Surgical Techniques. Part A*. 2014;**24**(7):508-512
- [67] Soccorso G, Parikh D. Esophageal replacement in children: Challenges and long-term outcomes. *Journal of Indian Association of Pediatric Surgeons*. 2016;**21**(3):98-105