

We are IntechOpen, the world's leading publisher of Open Access books Built by scientists, for scientists

6,900

Open access books available

186,000

International authors and editors

200M

Downloads

Our authors are among the

154

Countries delivered to

TOP 1%

most cited scientists

12.2%

Contributors from top 500 universities



WEB OF SCIENCE™

Selection of our books indexed in the Book Citation Index
in Web of Science™ Core Collection (BKCI)

Interested in publishing with us?
Contact book.department@intechopen.com

Numbers displayed above are based on latest data collected.
For more information visit www.intechopen.com



Intraoperative ERCP for Management of Gallbladder and Common Bile Duct Stones

Ahmed Abdelraouf Elgeidie

Abstract

It is not an uncommon scenario to have CBD stones in association with gallbladder stones. There is a general agreement in the surgical society that CBD stones should be removed. The classic option is to do open cholecystectomy and CBD exploration. With the emergence of minimally invasive surgery, namely laparoscopic cholecystectomy and ERCP, the therapist has better option to treat such patients such as preoperative ERCP, postoperative ERCP, and laparoscopic CBD exploration. The latest advance in that field is the use of ERCP at the time of laparoscopic cholecystectomy, i.e. intraoperative ERCP. This chapter with discuss the issue of minimally invasive management of cholecystocholedocholithiasis stressing on intraoperative ERCP.

Keywords: laparoscopic cholecystectomy, ERCP, LCBDE, CBD stones, intraoperative ERCP

1. Introduction

Patients undergoing LC may have concomitant CBD stones in about 15% of cases [1, 2]. These CBD stones may pass spontaneously in about one third of cases [3], but the complications of retained CBD stones are often dangerous. These complications include cholangitis, liver abscess, biliary pancreatitis. Therefore, there is a general agreement among biliary surgeons that CBD stones should be removed once detected even if asymptomatic [1, 4].

The orthodox therapeutic option in this setting is to solve the two problems by removing the gallbladder and at the same time retrieving CBD stones via open surgery. In fact this option is a good option with good outcome. Nevertheless, it may be associated with a considerable morbidity (11–14%) and even mortality (0.6–1%) particularly in elderly patients [5].

Two important revolutions had emerged in the past few decades that changed the face of CBD stone management and gave therapists new safe and minimally invasive options when dealing with such patients. The first one was the development of endoscopic retrograde cholangiopancreatography (ERCP) and the second is laparoscopic cholecystectomy (LC). ERCP has become a widely available and routine procedure, whilst open cholecystectomy has largely been replaced by a laparoscopic approach, which is considered the treatment of choice for gallbladder removal since NIH Consensus on 1993 [6].

Nowadays, not only biliary surgeons and endoscopists but also patients prefer minimally invasive options over old open surgery. This is simply because of the well-known benefits of better cosmesis, less adhesions, less wound complications, less postoperative pain and analgesia, and fast recovery.

2. Minimally invasive option

Minimally invasive options for treatment of gallbladder and concomitant CBD stones may be categorized in two sections; one-stage and two-stage options. In the two-stage option, the two pathologies are treated at timely different occasions. This option includes preoperative ERCP followed by LC and LC followed later on by postoperative ERCP. In the one-stage option, the two pathologies are treated in the same sitting under the same anesthesia, and it includes LC/laparoscopic CBD exploration (LCBDE) and LC/intraoperative ERCP.

2.1 Preoperative ERCP followed by LC

In this two-stage strategy the CBD stones are removed firstly to be followed later on by LC at another setting. Actually this strategy is the most commonly used treatment policy worldwide [7] as it had been proved to be efficient and safe [8–10].

Despite its advantages it has a myriad of disadvantages. Biliary endoscopists may not find CBD stones at the time of ERCP and this means that you are exposing your patient to unnecessary and at the same time risky maneuver. The reported incidence of false negative preoperative ERCP is about 40–70% which is a high figure [11–13]. Ordering magnetic resonance cholangiopancreatography (MRCP) before preoperative ERCP may increase the sensitivity and specificity of preoperative detection of CBD stones [14, 15] but CBD stones may spontaneously pass before ERCP. More than 50% of patients with CBD stones may have spontaneous passage of the stones [16].

At the time of LC, laparoscopists still could identify CBD stones despite successful pre-LC endoscopic clearance during LC. Pierce and collaborators reported an incidence of 12.9% [17]. These stones may be missed at the time of pre-LC ERCP or new stones that passed from the gallbladder onto the CBD in period between the two procedures.

Preoperative ERCP definitely affects the subsequent surgery. Some authors reported more conversion to open cholecystectomy, longer operating time, higher morbidity, especially postoperative infection, and longer hospital stay [18–20].

Finally, the time delay between preoperative ERCP and LC, may allow some patients to escape LC being satisfied by the results of preoperative ERCP [21–23]. Those escaping patients are subjected to recurrent biliary problems [24, 25].

2.2 Post-LC ERCP

Herein, at the first stage the gallbladder is removed by LC to be followed later on by postoperative ERCP as a second stage. The disadvantage of this strategy is obvious. Failed post-LC ERCP, which may be the case in up to 5% of cases, necessitates a third stage for operative removal of CBD stones [26, 27].

2.3 LCBDE

In the surgical literature, LCBDE has been proved to be a safe, efficient and cost-effective minimally invasive option [28, 29]. Many authors reported excellent

results for LCBDE with a high stone clearance rates up to 100% associated with a low morbidity and mortality rates [30–32].

Besides being a one-stage procedure, the most important advantage of LCBDE is avoidance of ERCP and ES. ERCP is not a totally benign procedure, it may have a short-term consequences as pancreatitis, bleeding and perforation, medium-term complications as cholangitis and recurrent stone formation, or even long-term problems as bile duct malignancy.

In the light of all these advantage, LCBDE would be expectedly to be the standard option for management of gallstones and concomitant CBD stones. But this is not the case in real surgical life for many reasons. LCBDE needs experience and a long learning curve. This is mainly due to the need for laparoscopic suturing skills that must be mastered by the surgeon for T-tube insertion or even primary CBD closure. In case of large, multiple or impacted stones the procedure may be time consuming and exhausting. Finally, LCBDE required specialized instruments that may be not readily available (such as real-time fluoroscopy) or delicate and nondurable (such as fragile 3-mm choledochoscope).

3. Intraoperative ERCP

The most recent advance in management of patients with CCL is intraoperative ERCP [33–36] that was found by many experts to be safe, efficient and cost-effective one-stage option [11, 32–34, 36–39].

3.1 Advantages

Intraoperative ERCP has many theoretical benefits that makes this option of big value. It is a one-session option with single anesthesia and single hospital stay and this is not only cost-effective but safer and seems likable by patients and surgeons. Intraoperative ERCP avoids opening the CBD for stone removal and thereby avoids laparoscopic suturing which needs some experience. Unlike postoperative ERCP, there is no possibility of failure of stone extraction. Simply if intraoperative ERCP failed, stones are removed under the same anesthesia either by open or laparoscopic CBD exploration depending on facilities and expertise. Another final advantage is the performance of ES at intraoperative ERCP. This definitely facilitates subsequent postoperative ERCP if indicated for retrieval of any retained CBD stones.

Nevertheless, all the above mentioned benefits of intraoperative ERCP did not result in widespread application and adoption of this approach. This is because of organizational problems. It may be difficult to have the immediate availability of ERCPist with all required equipment and facilities in the operating room at the time of cholecystectomy.

3.2 Technique

There are many described techniques for performing Intraoperative ERCP during LC but they all fall in two big categories; standard ERCP during LC and combined laparoendoscopic (rendezvous) technique.

3.2.1 Standard ERCP

The first described one was standard ERCP during LC. During LC intraoperative cholangiography is performed and if yielded positive result, intraoperative ERCP is performed in the operating room. After verification of clearance of CBD, LC was

continued [37, 40]. This technique has two main shortcomings; firstly, cannulation of the bile duct in the supine position is definitely more difficult than the standard prone/left lateral position and secondly, the resultant bowel distension from endoscopic manipulation may render subsequent LC more challenging.

A variation of this technique is postponing ERCP till after completion of LC and closure of the ports. This is to avoid the two mentioned problems of supine position and bowel distension making LC more demanding [41]. However, the obvious disadvantage of this approach is the problem of failure.

3.2.2 Rendezvous technique

This technique was first described by Cavina et al. [35]. At laparoscopy the surgeon passes a basket through the opened cystic duct and threaded down to the duodenum. At endoscopy a sphincterotome is passed through the scope biopsy channel. The basket caught the sphincterotome and guides it inside the CBD for sphincterotomy.

A simpler modification of the RV technique was proposed by others and now is considered the gold standard technique of intraoperative ERCP [12, 33, 34]. At laparoscopy a standard ERCP guidewire is passed through the opened cystic duct and threaded into the CBD under fluoroscopic guidance till protruding into the duodenum out of the papilla. At endoscopy a snare or basket is passed and catches the protruding guidewire, which is withdrawn into the biopsy channel of the scope and then a standard sphincterotome is threaded over this guidewire for subsequent sphincterotomy (**Figure 1**).

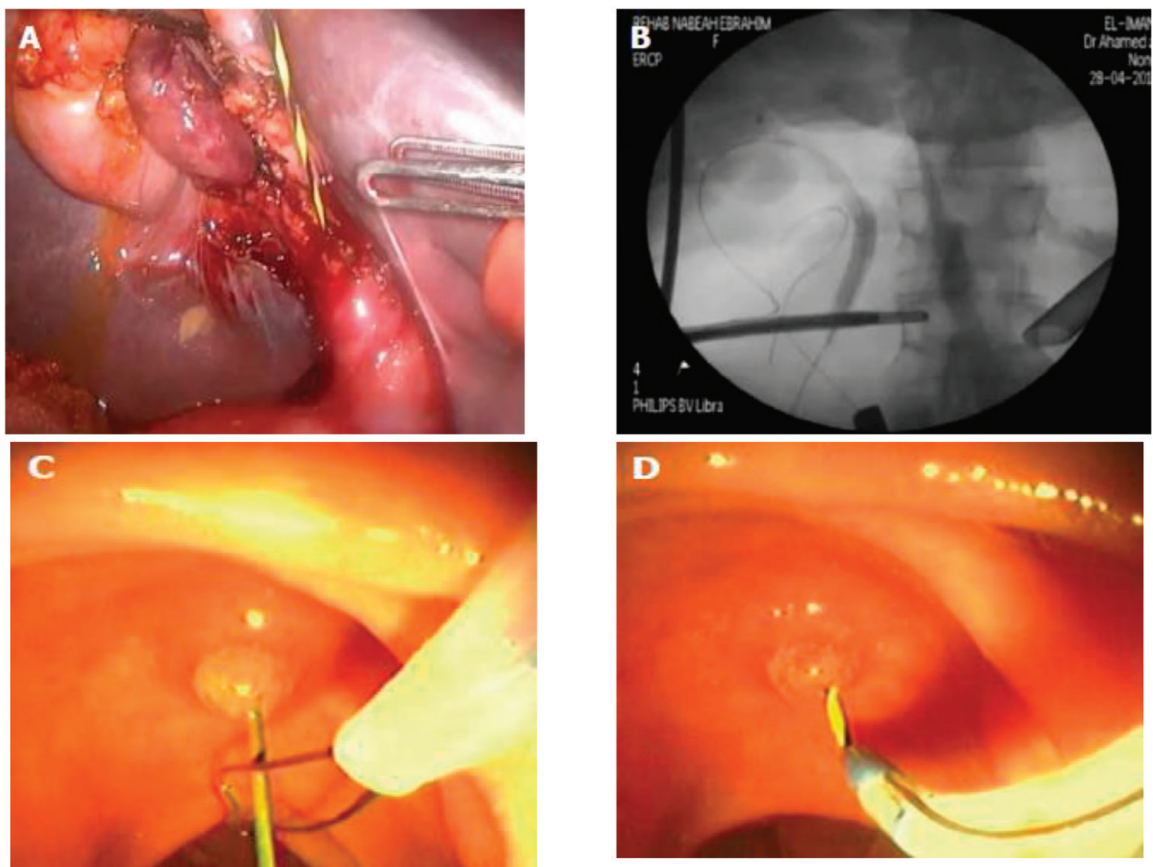


Figure 1. Rendezvous technique of intraoperative ERCP. (A) Laparoscopic view showing standard ERCP guidewire passing through the cystic duct into CBD; (B) fluoroscopic view showing passage of the guidewire into the duodenum; (C) endoscopic view showing snare catching the protruding guidewire; (D) endoscopic view showing standard sphincterotome threaded over the guidewire for sphincterotomy.

RV technique rapidly became the favorite technique of intraoperative ERCP. This is mainly due to two reasons; the high success cannulation rate in supine position and reduction of postprocedural hyperamylasemia and acute pancreatitis [34, 42, 43]. The obvious cause for reduction of the risk of hyperamylasemia and pancreatitis in intraoperative ERCP compared to standard ERCP is selective cannulation of CBD without inadvertent cannulation and dye injection of pancreatic duct, which is one of the risk factors for post-ERCP pancreatitis [12, 44].

Some technical problems may occur during RV technique. Sometimes it may be difficult for the guidewire to negotiate the spiral valves of the cyst duct. This problem can be overcome by opening the cystic duct as close as possible to its juncture with CBD. Rough manipulation may result in tearing of the cystic duct and this definitely makes subsequent steps more difficult. When there is a deeply impacted stone at the papilla, the guidewire may fail to pass into the duodenum. Finally, bowel distension usually make subsequent LC more difficult. This problem can be easily solved by completely dissecting the Calot triangle before the endoscopic phase [42].

4. Conclusion

Intraoperative ERCP for managing patients with concomitant gallbladder stones and CBD stones is a promising technique that is efficient, cost-effective and safe. The only limitation for its widespread use is lack of immediate availability of endoscopists and endoscopic equipment necessary for the procedure. When local resources and expertise are available it should be offered to fit patients. Surgeons are encouraged to learn ERCP and to use it as an important tool in their hands when dealing with such patients.

Conflict of interest

I have no conflict of interest.

Author details

Ahmed Abdelraouf Elgeidie
Gastrointestinal Surgery Center, Mansoura University, Mansoura, Egypt

*Address all correspondence to: ahmedraouf8@gmail.com

IntechOpen

© 2019 The Author(s). Licensee IntechOpen. This chapter is distributed under the terms of the Creative Commons Attribution License (<http://creativecommons.org/licenses/by/3.0>), which permits unrestricted use, distribution, and reproduction in any medium, provided the original work is properly cited. 

References

- [1] Williams EJ, Green J, Beckingham I, Parks R, Martin D, Lombard M. Guidelines on the management of common bile duct stones (CBDS). *Gut*. 2008;**57**:1004-1021. DOI: 10.1136/gut.2007.121657
- [2] Soltan HM, Kow L, Toouli J. A simple scoring system for predicting bile duct stones in patients with cholelithiasis. *Journal of Gastrointestinal Surgery*. 2005;**5**:434-437. DOI: 10.1016/S1091-255X(01)80073-1
- [3] Collins C, Maguire D, Ireland A, Fitzgerald E, O'Sullivan GC. A prospective study of common bile duct calculi in patients undergoing laparoscopic cholecystectomy: Natural history of choledocholithiasis revisited. *Annals of Surgery*. 2004;**239**:28-33
- [4] Scientific Committee of the European Association for Endoscopic Surgery (E.A.E.S.). Diagnosis and treatment of common bile duct stones (CBDS). Results of a consensus development conference. *Surgical Endoscopy*. 1998;**12**:856-864. DOI: 10.1007/s004649900729
- [5] Phillips EH, Toouli J, Pitt HA, Soper NJ. Treatment of common bile duct stones discovered during cholecystectomy. *Journal of Gastrointestinal Surgery*. 2008;**12**:624-628. DOI: 10.1007/s11605-007-0452-0
- [6] NIH Consensus Development Panel on Gallstones and Laparoscopic Cholecystectomy. Gallstones and laparoscopic cholecystectomy. *Surgical Endoscopy*. 1993;**7**:271-279. DOI: 10.1007/BF00594118
- [7] Freitas ML, Bell RL, Duffy AJ. Choledocholithiasis: Evolving standards for diagnosis and management. *World Journal of Gastroenterology*. 2006;**12**:3162-3167
- [8] Lu J, Xiong XZ, Cheng Y, Lin YX, Zhou RX, You Z, et al. One-stage versus two-stage management for concomitant gallbladder stones and common bile duct stones in patients with obstructive jaundice. *The American Surgeon*. 2013;**79**:1142-1148
- [9] Bansal VK, Misra MC, Rajan K, Kilambi R, Kumar S, Krishna A, et al. Single-stage laparoscopic common bile duct exploration and cholecystectomy versus two-stage endoscopic stone extraction followed by laparoscopic cholecystectomy for patients with concomitant gallbladder stones and common bile duct stones: A randomized controlled trial. *Surgical Endoscopy*. 2014;**28**:875-885. DOI: 10.1007/s00464-013-3237-4
- [10] Li MK, Tang CN, Lai EC. Managing concomitant gallbladder stones and common bile duct stones in the laparoscopic era: A systematic review. *Asian Journal of Endoscopic Surgery*. 2011;**4**:53-58. DOI: 10.1111/j.1758-5910.2011.00073.x
- [11] Erickson RA, Carlson B. The role of endoscopic retrograde cholangiopancreatography in patients with laparoscopic cholecystectomies. *Gastroenterology*. 1995;**109**:252-263. DOI: 10.1016/0016-5085(95)90292-9
- [12] Enochsson L, Lindberg B, Swahn F, Arnelo U. Intraoperative endoscopic retrograde cholangiopancreatography (ERCP) to remove common bile duct stones during routine laparoscopic cholecystectomy does not prolong hospitalization: A 2-year experience. *Surgical Endoscopy*. 2004;**18**:367-371. DOI: 10.1007/s00464-003-9021-0
- [13] Coppola R, Riccioni ME, Ciletti S, Cosentino L, Ripetti V, Magistrelli P, et al. Selective use of endoscopic retrograde cholangiopancreatography to facilitate laparoscopic cholecystectomy

- p>without cholangiography. A review of 1139 consecutive cases.
- Surgical Endoscopy*
- . 2001;
- 15**
- :1213-1216. DOI: 10.1007/s004640080019
- [14] Garrow D, Miller S, Sinha D, Conway J, Hoffman BJ, Hawes RH, et al. Endoscopic ultrasound: A meta-analysis of test performance in suspected biliary obstruction. *Clinical Gastroenterology and Hepatology*. 2007;**5**:616-623. DOI: 10.1016/j.cgh.2007.02.027
- [15] Kaltenthaler EC, Walters SJ, Chilcott J, Blakeborough A, Vergel YB, Thomas S. MRCP compared to diagnostic ERCP for diagnosis when biliary obstruction is suspected: A systematic review. *BMC Medical Imaging*. 2006;**6**:9. DOI: 10.1186/1471-2342-6-9
- [16] Lefemine V, Morgan RJ. Spontaneous passage of common bile duct stones in jaundiced patients. *Hepatobiliary & Pancreatic Diseases International*. 2011;**10**:209-213. DOI: 10.1016/S1499-3872(11)60033-7
- [17] Pierce RA, Jonnalagadda S, Spitler JA, Tessier DJ, Liaw JM, Lall SC, et al. Incidence of residual choledocholithiasis detected by intraoperative cholangiography at the time of laparoscopic cholecystectomy in patients having undergone preoperative ERCP. *Surgical Endoscopy*. 2008;**22**:2365-2372. DOI: 10.1007/s00464-008-9785-3
- [18] Ishizaki Y, Miwa K, Yoshimoto J, Sugo H, Kawasaki S. Conversion of elective laparoscopic to open cholecystectomy between 1993 and 2004. *The British Journal of Surgery*. 2006;**93**:987-991. DOI: 10.1002/bjs.5406
- [19] de Vries A, Donkervoort SC, van Geloven AA, Pierik EG. Conversion rate of laparoscopic cholecystectomy after endoscopic retrograde cholangiography in the treatment of choledocholithiasis: Does the time interval matter? *Surgical Endoscopy*. 2005;**19**:996-1001. DOI: 10.1007/s00464-004-2206-3
- [20] Ros A, Gustafsson L, Krook H, Nordgren CE, Thorell A, Wallin G, et al. Laparoscopic cholecystectomy versus mini-laparotomy cholecystectomy: A prospective, randomized, single-blind study. *Annals of Surgery*. 2001;**234**:741-749. DOI: 10.1097/00000658-200112000-00005
- [21] Byrne MF, McLoughlin MT, Mitchell RM, Gerke H, Pappas TN, Branch MS, et al. The fate of patients who undergo “preoperative” ERCP to clear known or suspected bile duct stones. *Surgical Endoscopy*. 2009;**23**:74-79. DOI: 10.1007/s00464-008-9903-2
- [22] Yi SY. Recurrence of biliary symptoms after endoscopic sphincterotomy for choledocholithiasis in patients with gall bladder stones. *Journal of Gastroenterology and Hepatology*. 2000;**15**:661-664. DOI: 10.1046/j.1440-1746.2000.02192.x
- [23] Lau JY, Leow CK, Fung TM, Suen BY, Yu LM, Lai PB, et al. Cholecystectomy or gallbladder in situ after endoscopic sphincterotomy and bile duct stone removal in Chinese patients. *Gastroenterology*. 2006;**130**:96-103. DOI: 10.1053/j.gastro.2005.10.015
- [24] Schiphorst AH, Besselink MG, Boerma D, Timmer R, Wiezer MJ, van Erpecum KJ, et al. Timing of cholecystectomy after endoscopic sphincterotomy for common bile duct stones. *Surgical Endoscopy*. 2008;**22**:2046-2050. DOI: 10.1007/s00464-008-9764-8
- [25] Reinders JS, Goud A, Timmer R, Kruijt PM, Witteman BJ, Smakman N, et al. Early laparoscopic cholecystectomy improves outcomes after endoscopic sphincterotomy for choledochocystolithiasis. *Gastroenterology*. 2010;**138**:2315-2320. DOI: 10.1053/j.gastro.2010.02.052

- [26] Rhodes M, Sussman L, Cohen L, Lewis MP. Randomised trial of laparoscopic exploration of common bile duct versus postoperative endoscopic retrograde cholangiography for common bile duct stones. *Lancet*. 1998;**351**:159-161. DOI: 10.1016/S0140-6736(97)09175-7
- [27] Nathanson LK, O'Rourke NA, Martin IJ, Fielding GA, Cowen AE, Roberts RK, et al. Postoperative ERCP versus laparoscopic choledochotomy for clearance of selected bile duct calculi: A randomized trial. *Annals of Surgery*. 2005;**242**:188-192. DOI: 10.1097/01.sla.0000171035.57236.d7
- [28] Cuschieri A, Croce E, Faggioni A, Jakimowicz J, Lacy A, Lezoche E, et al. EAES ductal stone study. Preliminary findings of multicenter prospective randomized trial comparing two-stage vs single-stage management. *Surgical Endoscopy*. 1996;**10**:1130-1135. DOI: 10.1007/s004649900264
- [29] Tranter SE, Thompson MH. Comparison of endoscopic sphincterotomy and laparoscopic exploration of the common bile duct. *The British Journal of Surgery*. 2002;**89**:1495-1504. DOI: 10.1046/j.1365-2168.2002.02291.x
- [30] Rojas-Ortega S, Arizpe-Bravo D, Marín López ER, Cesin Sánchez R, Roman GR, Gómez C. Transcystic common bile duct exploration in the management of patients with choledocholithiasis. *Journal of Gastrointestinal Surgery*. 2003;**7**:492-496. DOI: 10.1016/S1091-255X(03)00026-X
- [31] Thompson MH, Tranter SE. All-comers policy for laparoscopic exploration of the common bile duct. *The British Journal of Surgery*. 2002;**89**:1608-1612. DOI: 10.1046/j.1365-2168.2002.02298.x
- [32] Tai CK, Tang CN, Ha JP, Chau CH, Siu WT, Li MK. Laparoscopic exploration of common bile duct in difficult choledocholithiasis. *Surgical Endoscopy*. 2004;**18**:910-914. DOI: 10.1007/s00464-003-8216-8
- [33] Hong DF, Li JD, Gao M. One hundred and six cases analyses of laparoscopic technique combined with intraoperative cholangiogram and endoscopic sphincterotomy in sequential treatment of cholelithiasis. *Chinese Journal of General Surgery*. 2003;**15**:648-650
- [34] El-Geidie AA. Laparoendoscopic management of concomitant gallbladder stones and common bile duct stones: What is the best technique? *Surgical Laparoscopy, Endoscopy & Percutaneous Techniques*. 2011;**21**:282-287. DOI: 10.1097/SLE.0b013e3182218908
- [35] DePaula AL, Hashiba K, Bafutto M, Zago R, Machado MM. Laparoscopic antegrade sphincterotomy. *Surgical Laparoscopy Endoscopy & Percutaneous Techniques*. 1993;**3**:157-160
- [36] Curet MJ, Pitcher DE, Martin DT, Zucker KA. Laparoscopic antegrade sphincterotomy. A new technique for the management of complex choledocholithiasis. *Annals of Surgery*. 1995;**221**:149-155. DOI: 10.1097/00000658-199502000-00004
- [37] Tekin A, Ogetman Z, Altunel E. Laparoendoscopic "rendezvous" versus laparoscopic antegrade sphincterotomy for choledocholithiasis. *Surgery*. 2008;**144**:442-447. DOI: 10.1016/j.surg.2008.04.013
- [38] Ponsky JL, Scheeres DE, Simon I. Endoscopic retrograde cholangioscopy. An adjunct to endoscopic exploration of the common bile duct. *The American Surgeon*. 1990;**56**:235-237
- [39] Fitzgibbons RJ, Deeik RK, Martinez-Serna T. Eight years'

experience with the use of a transcystic common bile duct duodenal double-lumen catheter for the treatment of choledocholithiasis. *Surgery*. 1998;**124**:699-705; discussion 705-706. DOI: 10.1067/msy.1998.91268

[40] Morino M, Baracchi F, Miglietta C, Furlan N, Ragona R, Garbarini A. Preoperative endoscopic sphincterotomy versus laparoendoscopic rendezvous in patients with gallbladder and bile duct stones. *Annals of Surgery*. 2006;**244**:889-893; discussion 893-896. DOI: 10.1097/01.sla.0000246913.74870.fc

[41] La Greca G, Barbagallo F, Di Blasi M, Di Stefano M, Castello G, Gagliardo S, et al. Rendezvous technique versus endoscopic retrograde cholangiopancreatography to treat bile duct stones reduces endoscopic time and pancreatic damage. *Journal of Laparoendoscopic & Advanced Surgical Techniques. Part A*. 2007;**17**:167-171. DOI: 10.1089/lap.2006.0030

[42] Dasari BV, Tan CJ, Gurusamy KS, Martin DJ, Kirk G, McKie L, et al. Surgical versus endoscopic treatment of bile duct stones. *Cochrane Database of Systematic Reviews*. 2013;**9**:CD003327. DOI: 10.1002/14651858.CD003327

[43] Hong DF, Xin Y, Chen DW. Comparison of laparoscopic cholecystectomy combined with intraoperative endoscopic sphincterotomy and laparoscopic exploration of the common bile duct for cholecystocholedocholithiasis. *Surgical Endoscopy*. 2006;**20**:424-427

[44] ElGeidie AA, ElShobary MM, Naeem YM. Laparoscopic exploration versus intraoperative endoscopic sphincterotomy for common bile duct stones: A prospective randomized trial. *Digestive Surgery*. 2011;**28**:424-431. DOI: 10.1159/000331470