

# We are IntechOpen, the world's leading publisher of Open Access books Built by scientists, for scientists

6,900

Open access books available

186,000

International authors and editors

200M

Downloads

Our authors are among the

154

Countries delivered to

TOP 1%

most cited scientists

12.2%

Contributors from top 500 universities



WEB OF SCIENCE™

Selection of our books indexed in the Book Citation Index  
in Web of Science™ Core Collection (BKCI)

Interested in publishing with us?  
Contact [book.department@intechopen.com](mailto:book.department@intechopen.com)

Numbers displayed above are based on latest data collected.  
For more information visit [www.intechopen.com](http://www.intechopen.com)



# Optical Coherence Tomography in the Management of Glaucoma and Macular Diseases

*Lawan Abdu*

## Abstract

Optical coherence tomography (OCT) is a non contact, non invasive and reproducible imaging technique that produces thin slices of tissue section images. OCT identifies retinal nerve fiber damage before detection of visual field changes making it a handy and effective tool in early detection and monitoring in glaucoma. Retinal fiber layer thickness measurements provide vital knowledge of extent of neural damage. This enables the clinician to counsel the patient and take the best decision towards achieving glaucoma control. Early and quantifiable macular thickness measurements are obtained, allowing for detection of clinically significant diabetic macular edema. OCT allows monitoring of the impact of laser or other interventions. Changes in age-related macular degeneration are relatively easily determined and impact of treatment interventions monitored. In conclusion, OCT is a vital emerging tool in the evaluation and management glaucoma and macular diseases in all parts of the World, including low income countries of sub-Saharan Africa.

**Keywords:** OCT, glaucoma, macular, diseases, management

## 1. Introduction

Optical coherence tomography (OCT) is a noninvasive, noncontact, and reproducible investigation. The relatively new technology is comparable to ultrasound that utilizes low coherence interferometry to produce cross-sectional images of the retina. The functional principle behind OCT imaging is light interference [1]. Infrared light from a luminescent diode source is divided into two, one of which is reflected from a reference mirror and the other scattered from retinal tissues. The reflected beams from the two sources are made to produce interference pattern, thus obtaining the echo time delay and their amplitude information which makes up an A-scan. The cross-sectional images are generated by measuring the echo time delay and intensity of light reflected from internal structures in the retina [2]. Scattering is a property of heterogonous medium and arises due to variation in refractive index between tissues structures. An interferometric technique analyzes the reflected light signal, and a transverse scanning mechanism captures the A-scans from adjoining retinal locations to produce a two-dimensional image [3]. OCT produces high-resolution images which allows detailed assessment of retinal thickness and morphologic evaluation of retinal layers [4]. The image is colored to enhance tissue recognition. There are two models described: time domain (TD-OCT) and Fourier domain (FD-OCT). In TD-OCT, measurements of the light echoes are detected sequentially by stepwise movement

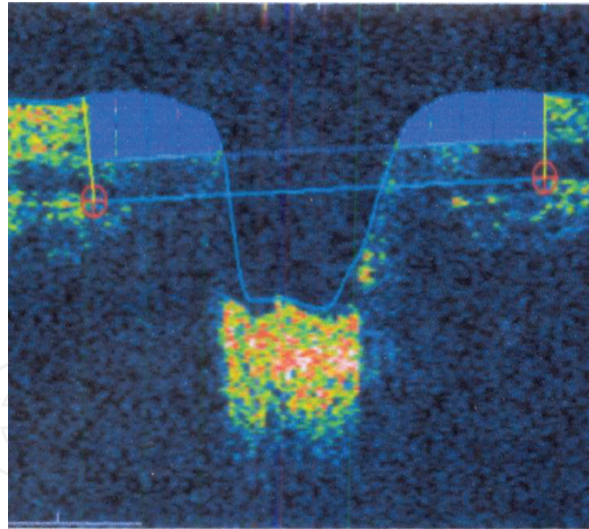
of the reference mirror, while in FD-OCT, the light echoes and the source from all axial depth are detected as modulations in the source spectrum simultaneously [5]. One of the main differences is the reference mirror in TD-OCT. The moving mirror causes inertia and limits mechanical performance of the TD-OCT. Elimination of this mechanical translation leads to faster data acquisition speed in FD-OCT. The instantaneous current generated in an FD-OCT detection system by incoming light is a function dependent on the source wavelength sampled at a particular instance. The acquired data is transformed into axial scan information (A-scan) by an inverse Fourier transform [6]. Fourier Domain OCT consists of two primary methods, spectral domain and swept source OCT. The two variants are abbreviated as SD and SS domain OCT, respectively.

The Spectral domain OCT employs principle of Michelson-type interferometry that utilizes a static reference mirror. The generated interference signal is detected and the dual returning beams are recombined to form an interference pattern at the beam splitter. At this point a diffraction grating disperses the beam which is detected by a high-speed charge-couple device (CCD) camera. The generated interference pattern detected by the line camera produces an array that results in obtaining tissue reflectivity as a depth function. The detection rate of the line sensor defines the acquisition speed of such systems [7]. Interference patterns are dispersed quite rapidly before detection in spectral domain OCT while in the Swept source OCT a laser with a limited spectral line within the available bandwidth of the source scan the tissues in a regulated way. Subsequently, the mirror reflected reference beam generates an interference pattern with the light backscattered by the tissue and this is identified by the detector. Point detection is one advantage that swept source has over spectral domain OCT because of its higher signal-to-noise ratio when compared to line detectors [8]. Fourier domain OCT has reduced artifacts and faster scan acquisition time which permits three dimensional image construction [9]. High reflectivity tissues are depicted in red, medium yellow to green while low appears as blue to black.

The limitations of OCT include poor signal strength in the presence of opacity in the ocular media which prevents data acquisition. Patients with macular problems that reduced the central vision may have difficulty fixating on the target. Motion artifacts can give rise to false observations, and such artifacts are commoner in eyes with underlying pathology [10]. The technology is expensive and not available in most tertiary hospitals in the sub-Saharan African region. The few available ones are mainly located in urban centers away from vast majority in rural communities. OCT scan is not covered by the health insurance scheme which in any way is only available to the few working in regular public/private sectors.

## **2. OCT in glaucoma**

Glaucoma is the second leading cause of blindness [11]. The standard method of diagnosis is based on clinical evaluation of characteristic optic nerve damage and the visual field changes detected by standard automated perimetry (SAP). OCT provides additional evaluation and assessment for monitoring glaucoma progression though it may not be of much value in patients with advanced disease. Visual field changes are not detected in early stages of glaucoma due to the functional overlapping pattern and integration of the visual system which compensate for and to some extent mask early damage. A 6 mm<sup>3</sup> scan centered on the disk provides graphic and quantifiable retinal thickness measurements in addition to providing an objective calculation of the cupping by giving details of the extent of vertical cup-to-disk ratio. Effective management requires detection of early changes in glaucoma even before development of detectable



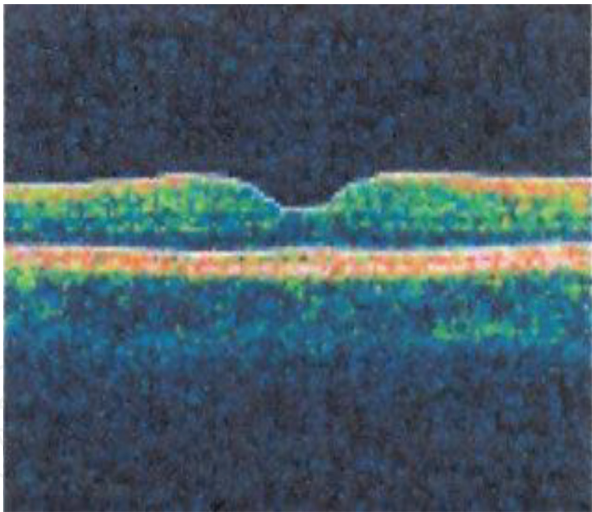
**Figure 1.**  
 OCT illustration of glaucomatous optic disk cupping.

visual field defects as neural damage may precede visual field defects by many years. Significant differences in RNFL thickness have been observed to occur up to 8 years before detectable visual field defects [12]. Thus OCT is quite useful in identifying changes in retinal nerve fiber layer (RNFL) thickness, the optic nerve head structure (ONH), and the macular ganglion cell complex (GCC). A 3.46 mm para-papillary scan entered on the optic nerve head evaluates RNFL thickness in all the quadrants and is useful in assessment and monitoring of glaucoma progression. In most instances, the RNFL thickness is highest in the inferior quadrant followed by superior, nasal, and temporal quadrants in that order (ISNT rule) [13]. Analysis of the RNFL and inner macular thickness has provided additional means of determining glaucomatous optic nerve damage and progression [14]. There is paucity of normative RNFL data in sub-Saharan Africa though some reports indicate an RNFL average of 110 and 104.17  $\mu\text{m}$ , respectively [15, 16]. RNFL below 100  $\mu\text{m}$  is suspect, less than 90  $\mu\text{m}$  requires full glaucoma workup, and values less than 70  $\mu\text{m}$  are not unusual at the time of glaucoma diagnosis. Reduction of the average thickness within certain time frame can be an indicator of progression in addition to perimetric changes. **Figure 1** shows glaucoma optic nerve damage on OCT.

### 3. OCT in macular diseases

The macula serves as the most acute visual function, and conventional assessment includes ophthalmoscopy and slit lamp evaluation in conjunction with contact and noncontact retinal lenses. Naked eye assessment can however not be compared with quantifiable OCT analysis. Fast macular scan protocol can be employed to provide graphic image of the state of the macula. Macular scan results can be displayed as numeric data or as false color display form. Normative data in Africans is not largely available though a study indicates macular thickness and volume of 149.58 and 6.79  $\mu\text{m}^3$ , respectively [17]. Central macular thickness above 200  $\mu\text{m}$  is uncommon in healthy eyes and deserves further evaluation even when the vision is not significantly affected. Macular thickness measurements in diabetic macular edema are based on criteria definition of existing standard protocol. Macular thickness measurement below 110  $\mu\text{m}$  is rarely observed in normal eyes. Disorders of the macula include diabetic maculopathy and other forms of acquired maculopathy such as age-related macular degeneration. A survey report indicated diabetic retinopathy (DR) to be a cause of blindness and visual impairment despite some patients being

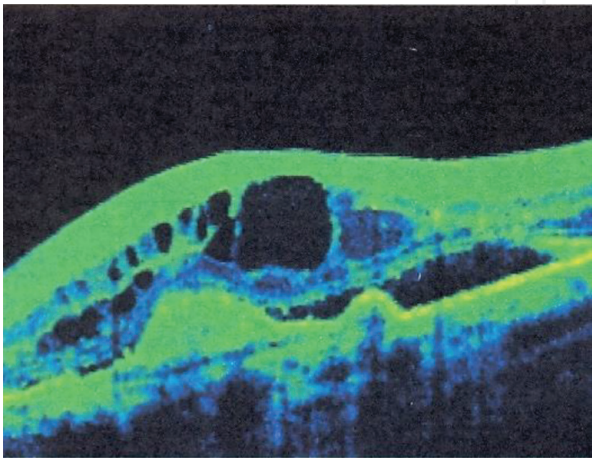




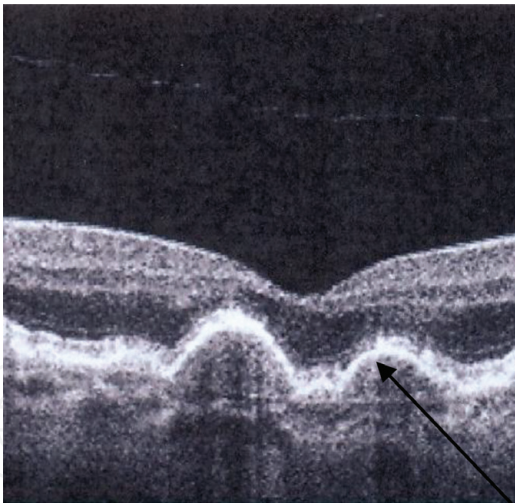
**Figure 2.**  
*OCT showing normal macular scan.*

unaware of their diabetic status [18, 19]. DR rivals cataract and glaucoma as a cause of visual impairment in an institution-based study of diabetic patients [20]. Diabetic cystoid macular edema (CME), diffuse thickening, and serous detachment can objectively be measured with OCT [21, 22]. OCT demonstrates retinal thickening and cystoid spaces in the presence of CME. As OCT was not in use during the ETDRS, [23] clinically significant macular edema was defined by the presence of retinal thickening within 500  $\mu\text{m}$  of fovea or hard exudates within 500  $\mu\text{m}$  of the fovea or retinal thickening more than one disk diameter any part of which is within a disk diameter of the fovea [24]. OCT has been demonstrated to quantify the extent of CSME at diagnosis even more accurately than clinical fundal assessment and can serve in determining response to treatment applied. **Figure 2** shows a normal OCT macular scan, and **Figure 3** shows cystoid spaces in macular edema. Likewise OCT can be used to monitor resolution of CME with appropriate treatment.

Age-related macular degeneration (ARMD) is a group of primary disorders of the retina which are emerging as a significant cause of visual impairment in developed countries. With change in lifestyle, the disease is becoming common even in developing countries though a population survey report showed it was not a significant cause of visual impairment [17]. ARMD has been classified into dry (non-exudative) and wet (exudative) types. The dry type is the most common, and geographic atrophy is the manifestation of the late stage of the disease. The International Age Related

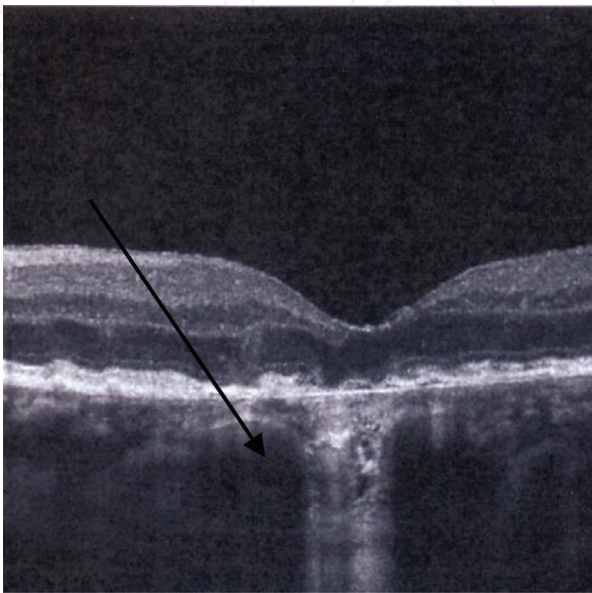


**Figure 3.**  
*Clinically significant macular edema.*

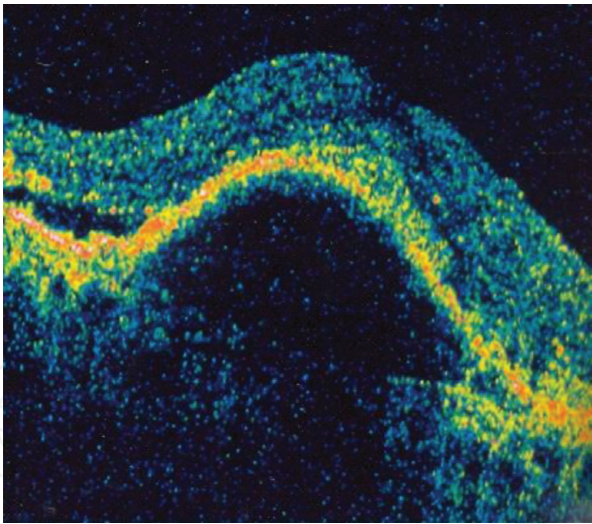


**Figure 4.**  
*OCT features of macula drusen.*

Maculopathy Epidemiological Study Group (IARMESG) has classified the disease further age-related maculopathy (ARM) into early (medium to large drusen, retinal pigment epithelium (RPE) hyperpigmentation and/or hypopigmentation). **Figure 4** shows drusen on OCT scan. Advanced AMD is characterized by geographic atrophy (**Figure 5**) and/or choroidal neovascularization. SD-OCT has been demonstrated to quantify the volume of drusen and thus monitor progression [25]. OCT has been demonstrated to be useful in estimating photoreceptor loss, quantifying the extent, and providing insight as to the structural damage leading to enlargement and progression of geographic atrophy in non-neovascular AMD [26, 27]. Retinal pigment epithelium (RPE) detachment arises from dysfunction of the normal physiologic factors that ensures its adhesion to Bruch's membrane. The separation occurs between the basement membrane of the RPE and the inner collagenous layer of Bruch's membrane which become thickened and dysfunctional. The separation appears as an optically empty space on OCT (**Figure 6**). OCT can distinguish two



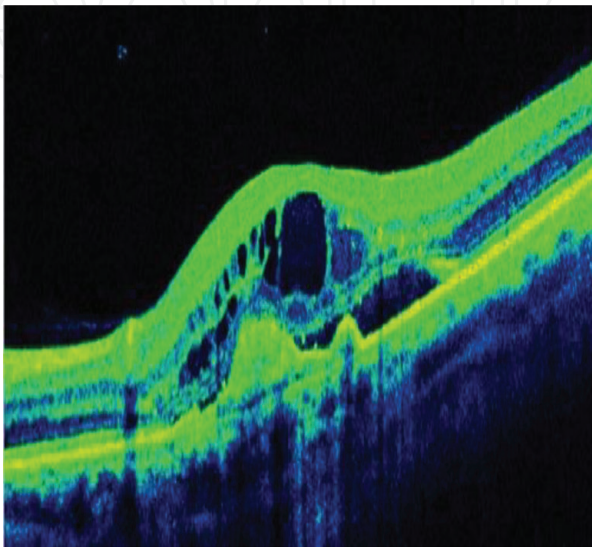
**Figure 5.**  
*OCT features of geographic atrophy (source: [www.octscans.com](http://www.octscans.com)).*



**Figure 6.**  
*Retinal pigment epithelial detachment showing Optically empty space between Bruch's membrane and separated RPE.*

broad types of RPE detachment, thus aiding in making accurate diagnosis [28]. Wet AMD is associated with choroidal neovascularization (CNV). The blood vessels arise from the choriocapillaris and break through Bruch's membrane. CNV membrane (**Figure 7**) can remain in the sub RPE or even extend into the subretinal space. Fundal fluorescein angiography (FFA) is the primary investigation in diagnosis of suspected CNV. The role of OCT is in providing quantifiable monitoring of response to treatment. OCT shows increased thickness and fragmentation of the high reflectivity RPE and choriocapillaris. Improvement in data acquisition and 3-D imaging in SD-OCT provides more detailed images leading to higher and earlier detection of CNV when compared to time-domain technology [29]. Combined OCT angiography provides additional value in diagnosis and monitoring of the impact of treatment in wet ARM.

Macular hole is one of the age-related causes of vision loss, and studies have shown that macular hole is not uncommon in sub-Saharan Africans [30, 31]. Population incidence of 6.8–8.69 has been reported in the Unites States [32]. Occult, lamellar, full-thickness holes, and complete posterior vitreous detachment (PVD) can accurately be quantified on OCT. Full-thickness hole is identified including a pseudo operculum where present. OCT is used for characterization of macular



**Figure 7.**  
*OCT showing choroidal neovascularization.*



holes and to visualize persistent retinal abnormalities which were observed despite achieving anatomical closure [32, 33].

#### **4. Impact of OCT on glaucoma and diabetic macular edema**

OCT has aided the ophthalmologist in early detection and provides a more objective monitoring tool in glaucoma management in sub-Saharan Africa. This is achieved by effective detection of RNFL loss and evaluation of the differential measurements in the four quadrants to detect deviation from normal (normal RNFL thickness declines measurement in this order: inferior, superior, medial, and temporal quadrants—ISN'T rule). OCT RNFL can be utilized alone or better in combination with standard automated perimetry in monitoring for stabilization or deterioration of glaucomatous optic neuropathy over time. This will enable the clinician to counsel the patient using objective criteria and modify the treatment to achieve goal of effective glaucoma control. OCT gives accurate central macular thickness measurement and thus provides effective and early detection of clinically significant diabetic macular edema. The impact of laser and/or intravitreal anti-VEGF on treatment of proliferative diabetic retinopathy and macular edema can be determined.

#### **5. Conclusion**

OCT is still a relatively new technology in the diagnosis and monitoring of glaucoma and macular diseases in the region. Older models are available in few centers and clinicians have limited access. By the poor income of most sub-Saharan Africans, OCT scan is expensive. Most of the machines have no provision for digital data retrieval, thus making research work on impact of the technology more difficult. Normative data on various parameters have to be locally generated in order to make more objective decision when there is variation from normal. In few countries with limited health insurance services (which only cover workers in the national public service), OCT is exempted as has to be paid for as out-of-pocket expense, thus further limited access to the vast population. A public-private partnership could enhance availability to the underserved population.

#### **Acknowledgement**

The author would like to appreciate the management of Bayero University, Kano, Nigeria, for providing an enabling academic environment.

#### **Conflict of interest**

None.



IntechOpen

IntechOpen

### **Author details**

Lawan Abdu

Department of Ophthalmology, Faculty of Clinical Sciences, College of Health Sciences, Bayero University Kano, Nigeria

\*Address all correspondence to: lawal1966@yahoo.com

### **IntechOpen**

© 2019 The Author(s). Licensee IntechOpen. This chapter is distributed under the terms of the Creative Commons Attribution License (<http://creativecommons.org/licenses/by/3.0>), which permits unrestricted use, distribution, and reproduction in any medium, provided the original work is properly cited. 

## References

- [1] Dan PP, Lin-P'ing CS, Costel F, Youxin M, Shoude C, John D, et al. Optical coherence tomography: Fundamental principles, instrumental designs and biomedical applications. *Biophysical Reviews*. 2011;**3**(3):155
- [2] Huang D, Swanson EA, Lin CP, Schuman JS, Stinson WG, Chang W, et al. Optical coherence tomography. *Science*. 1991;**254**:1178-1181
- [3] Muna B, Sharan S, Mohana KP, Ramya S. Optical coherence tomography: A guide to interpretation of common macular diseases. *Indian Journal of Ophthalmology*. 2018;**66**(1):20-35
- [4] J Fernando A, Andres FL, Juan DA, Martin AS, Fernando AA. Clinical applications of optical coherence tomography in the posterior pole: The 2011 José Manuel Espino Lecture—Part II. *Clinical Ophthalmology*. 2013;**7**:2181-2206
- [5] Fercher AF, Hitzenberger CK, Kamp G, Elzaint SY. Measurement of intra ocular distance by back scattering spectral interferometry. *Optics Communication*. 1995;**117**:43-48
- [6] Hauster G, Lindner MW. "Coherence radar" and "spectral radar"—New tools for dermatological diagnosis. *Journal of Biomedical Optics*. 1998;**3**(1):21-31
- [7] Wojtkowski M, Leitgeb R, Kowalczyk A, Bajroszewski T, Fercher AF. In vivo retinal imaging by Fourier domain optical coherence tomography. *Journal of Biomedical Optics*. 2002;**7**(93):457-463
- [8] Golubovic B, Bouma BE, Teomey GJ, Fujimoto JG. Optical frequency-domain reflectometry using rapid wavelength tuning Cr<sup>4</sup>: Forsterite laser. *Optics Letters*. 1997;**22**(22):1704-1706
- [9] Dainty C, Podoleanu A. Evaluation of the signal noise ratio enhancement of SS-OCT versus TD-OCT using full field interferometer. *Proceedings of SPIE*. 2009;**7168**:71682K. DOI: 10.1117/12.809043
- [10] Ghasemi FK, Al-Sheikh M, Akil H, Sadda SR. Image artefacts in swept-source optical coherence tomography angiography. *The British Journal of Ophthalmology*. 2017;**101**(5):564-568
- [11] Quigley HA, Broman AT. The number of people with glaucoma worldwide 2010 and 2020. *The British Journal of Ophthalmology*. 2006;**90**(3):262-267
- [12] Kuang TM, Zhang C, Zangwill LM, Weinreb RN, Medeiros FA. Estimating lead time gained by optical coherence tomography in detecting glaucoma before development of visual field defects. *Ophthalmology*. 2015;**122**(10):2002-2009
- [13] Alasil T, Wang K, Keane PA, Lee H, Baniyadi N, de Boer JF, et al. Analysis of normal retinal nerve fiber layer thickness by age, sex, and race using spectral domain optical coherence tomography. *Journal of Glaucoma*. 2013;**22**(7):532-541
- [14] Leung CK. Diagnosing glaucoma progression with optical coherence tomography. *Current Opinion in Ophthalmology*. 2014;**25**(2):104-111
- [15] Khathutshelo PM, Olalekan AO. Retinal nerve fiber layer thickness values and their associations with ocular and systemic parameters in Black South Africans. *African Health Sciences*. 2016;**16**(4):1188-1194
- [16] Rabi YS, Lawan A, Victoria P. Retinal nerve fiber layer thickness measurements of normal Northern

Nigerian adults using optical coherence tomography. *Annals of African Medicine*. 2016;**15**(2):52-57

[17] Lawan A, Rabi YS. Macular volume and central foveal thickness measurements in normal eyes of healthy Nigerian Adults using optical coherence tomography. *Annals of African Medicine*. 2014;**13**(3):134-137

[18] Mohammed MA, Selvaraj S, Gudlavalleti VS, Murthy G, Clare G, Tafida A, et al. Causes of blindness and visual impairment in Nigeria: The Nigeria national blindness and visual impairment survey. *Investigative Ophthalmology & Visual Science*. 2009;**50**:4114-4120

[19] Fatima K, Abubakar T, Selvaraj S, Gudlavalleti VS, Murthy G, Tunde P, et al. Prevalence and risk factors for diabetes and diabetic retinopathy: Results from the Nigeria national blindness and visual impairment survey. *BMC Public Health*. 2014;**14**:1299

[20] Abdu L, Tijjani BM. Pattern of diabetic retinopathy in Kano, Nigeria. *Annals of African Medicine*. 2012;**11**(2):75-79

[21] Charlotte S, Birgit S, Nicolai L, Michael L, Henrik LA. Diabetic macular edema assessed with optical coherence tomography and stereo fundus photography. *Investigative Ophthalmology & Visual Science*. 2002;**43**(1):241-245

[22] Kim BY, Smith SD, Kaiser PK. Optical coherence tomography patterns of diabetic macular edema. *American Journal of Ophthalmology*. 2006;**142**(3):405-412

[23] Early Treatment Diabetic Retinopathy Study Research (ETDRS) Group. Treatment techniques and clinical guidelines for photocoagulation of diabetic macular edema. Early treatment diabetic retinopathy study

report number 2. *Ophthalmology*. 1987;**94**:761-774

[24] Early Treatment Diabetic Retinopathy Study Research Group. Photocoagulation for diabetic macular edema. Early treatment diabetic retinopathy study report number 1. *Archives of Ophthalmology*. 1985;**103**:1796-1806

[25] Giovanni G, Fenghua W, Philip JR, Zohar Y, Ninel ZG, Brandon JL, et al. Spectral domain optical coherence tomography imaging of drusen in nonexudative age-related macular degeneration. *Ophthalmology*. 2011;**118**(7):1373-1379

[26] Srilaxmi B, Felix YC, Anjum K, Sandra SS, Joseph AI, Cynthia AT. Spectral domain optical coherence tomography imaging of geographic atrophy margins. *Ophthalmology*. 2009;**116**(9):1762-1769

[27] Zohar Y, Philip JR, Giovanni G, William JF, Manuel F, Brandon JL, et al. Progression of geographic atrophy in age-related macular degeneration imaged with spectral domain optical coherence tomography. *Ophthalmology*. 2011;**118**(4):679-686

[28] Yoshida M, Abe T, Kano T, Tumai M. Two types of optical coherence tomography images of retinal pigment epithelial detachment with different prognosis. *British Journal of Ophthalmology*. 2002;**86**:737-739

[29] Caio VR, Lauren B, Jay SD. The role of spectral-domain OCT in the diagnosis and management of neovascular age-related macular degeneration. *Ophthalmic Surgery, Lasers & Imaging*. 2011;**42**:S56-S66

[30] Uhumwangho OM, Itina EI. Retinal diseases in a tertiary hospital in southern Nigeria. *Journal of the West African College of Surgeons*. 2015;**5**(2):1-16

[31] Oluleye TS, Ajaiyeogba AI.  
Retinal diseases in Ibadan. *Eye*.  
2006;**20**:1461-1463

[32] Hee MR, Puliafito CA, Wong C,  
Duker JS, Reichel E, Schuman JS,  
et al. Optical coherence tomography  
of macular holes. *Ophthalmology*.  
1995;**102**(5):748-756

[33] Tony HK, Andre JW, James GF,  
Annie C, Adam HR, Caroline RB, et al.  
Ultrahigh-resolution optical coherence  
tomography of surgically closed macular  
holes. *Archives of Ophthalmology*.  
2006;**124**(6):827-836